

# We are IntechOpen, the world's leading publisher of Open Access books Built by scientists, for scientists

**4,800**

Open access books available

**122,000**

International authors and editors

**135M**

Downloads

Our authors are among the

**154**

Countries delivered to

**TOP 1%**

most cited scientists

**12.2%**

Contributors from top 500 universities



**WEB OF SCIENCE™**

Selection of our books indexed in the Book Citation Index  
in Web of Science™ Core Collection (BKCI)

Interested in publishing with us?  
Contact [book.department@intechopen.com](mailto:book.department@intechopen.com)

Numbers displayed above are based on latest data collected.

For more information visit [www.intechopen.com](http://www.intechopen.com)



# Degeneration of the Human Nervous System and Magnetic Resonance Neuroimaging

Lulé Dorothee and Ludolph Albert Christian  
*Department of Neurology, University of Ulm  
Germany*

## 1. Introduction

Neurodegenerative diseases are progressive, hereditary or sporadic diseases of the nervous system. Progressive neurodegeneration causes i.e. loss of movement ability like in motor neuron diseases or cognitive deficits like in dementia. Despite the fact that many similarities appear on the sub-cellular level that relate different neurodegenerative diseases with each other, the broad variety on the clinical level remains which causes major demands both in clinical care and daily living.

Advances in neuroimaging have led to an extensive application of this technique in clinical and scientific studies. Neuroimaging is a non-invasive approach of measuring either structural properties or activity of the brain. Activity of the brain can be investigated during defined tasks or during rest to observe functional connectivity of cortical and subcortical regions in time and space. Neuroimaging in neurodegenerative diseases has extensively increased our understanding of interaction of functional executive decline e.g. in movement and cognition and of changes in cortical pattern activity. Neuroimaging is a promising candidate for an objective marker for e.g. drug efficacy. By these means, neuroimaging as a biomarker can improve predictability of outcome in clinical trials. Furthermore, discovering patterns of vulnerability of neurons on the cortical and subcortical level helps to disentangle the course of degeneration in different diseases in vivo to support post-mortem findings. Those ex-vivo analyses had been the only means to get an understanding of disease courses before neuroimaging evolved.

The following article will give an introduction to the characteristics of the main neurodegenerative diseases and techniques that have been used in understanding pathogenesis and aetiology of neurodegenerative diseases. It encompasses main findings in structural and functional neuroimaging in Motor Neuron Diseases (MND) and in others like dementias, Parkinson's disease (PD) and Huntington's disease.

With our work we mainly focused on Motor Neuron Diseases like ALS and we provided clear evidence for pathological involvement of areas extending the motor system like emotional and sensory processing pathways. Overall, the article will highlight the capacity of neuroimaging to shed light onto aetiology and pathogenesis of neurodegeneration in the human central nervous system.

## **2. Clinical understanding and differential diagnosis among neurodegenerative diseases**

Neurodegenerative diseases encompass different pathologies with the common feature of progressive loss of structure or function of neurons.

Over the last years, evidence evolved of common pathological processes in different neurodegenerative diseases like accumulation of neurofilaments, protein degradation and induced cell death. For example, accumulated TDP-43 is found in sporadic ALS cases, which links this disease to fronto-temporal dementias (FTD) (Neumann et al., 2006). Furthermore, on behavioural level there is accumulating evidence for a common cognitive decline in some ALS patients and in patients with FTD.

Genetics provide further evidence for an association between different neurodegenerative diseases like polyglutamine repeats in Huntington's disease and spinocerebellar ataxias and mutations in the alpha-synuclein in Parkinson's Disease, dementia with Lewy bodies and multiple system atrophy. Furthermore, mitochondrial dysfunction, disturbed axonal transport and endothelial dysfunction are common pathological hallmarks found in different neurodegenerative diseases. In clinical routine, differential diagnosis is usually done on clinical basis. According to clinical criteria, Amyotrophic lateral sclerosis is regarded as a disease of the peripheral and central nervous system and the other most common neurodegenerative diseases like dementias, Parkinson's disease and Huntington's disease are primarily regarded as diseases of the central nervous system (Hacke, 2007). However, evidence for overlaps in molecular or cellular pathways question this classification and suggests a major overlap of different neurodegenerative pathologies in central and peripheral nervous system (Braak et al., 2006b; Braak & Del Tredici, 2011a, 2011b; Grammas et al., 2011; Neumann et al., 2006). New imaging techniques carry the hope of revolutionizing the diagnosis of neurodegenerative disease to improve staging of patients and follow disease progression and treatment trial efficacy.

## **3. Characteristics of main neurodegenerative diseases**

### **3.1 Diseases of the central and peripheral nervous system and muscles**

#### **3.1.1 Motor Neuron Diseases (MND)**

Motor neuron diseases describe pathologies of the motor system. The most common is Amyotrophic Lateral Sclerosis, which evolves mostly in midlife and is characterised by a fast progression of immobility and loss of verbal communication. Cognition is mostly unaffected; yet, there is an on-going debate on the proportion of patients with cognitive impairments. There are more benign forms of motor degenerative diseases e.g. affecting just the upper or just the lower motor neurons (Ludolph and Dengler, 1999). ALS, which affects upper and lower motor neurons, is usually fast progressing causing death within 3-5 years. The fatal event is usually respiratory failure. There is a gender ratio of men: women of about 1.5: 1.

The cause of ALS is mostly unknown. In the early 1990s there was evidence provided that some patients with a familial form of ALS have a defined mutation in the Superoxide-Dismutase 1 (SOD1). Since then various genetic changes have been detected as a possible cause for ALS. However, for most cases the cause is yet unknown. Riluzole as a glutamate agonist is the only applicable drug in ALS that prolongs life of ALS patients. Numerous drug trials are ongoing to provide new therapeutic targets in ALS.

## **3.2 Disease of the central nervous system**

### **3.2.1 Dementias**

Alzheimer's disease (AD) is the most common form of dementia. It is named after the German psychiatrist and neuropathologist Alois Alzheimer who first described the disease in the early 20<sup>th</sup> century. The other most common form of dementia is vascular dementia. Some other forms are dementia with Lewy bodies, and frontotemporal lobar degeneration, which is subdivided into the behavioural variant (fronto-temporal dementia, FTD), the semantic dementia, primary progressive aphasia, corticobasal degeneration, progressive supranuclear palsy and amyotrophic lateral sclerosis with frontotemporal dementia. Numerous other neurodegenerative illnesses have an associated dementia, including Creutzfeldt-Jakob disease, Huntington's disease, multiple system atrophy, and Parkinson's disease dementia (Tartaglia et al., 2011).

dementias are acquired diseases that clinically affect cognitive abilities and daily activities. Classification of dementias can be done according to different criteria: cortical (memory, language, thinking and social skills are affected) and subcortical pathology (emotional processing, movement and memory are primarily affected). Furthermore, it can be classified according to whether it is a progressive form (cognitive abilities worsen over time), and whether it is primary (results from a specific disease such as Alzheimer's disease) or secondary (occurs because of disease or injury like vascular dementia). Patho-anatomical hallmark is the degeneration of the brain (mainly frontal and temporal areas). Early stages of dementia are often mistakenly considered as normal aging problems like forgetfulness and memory storage problems. With the means of standardised diagnostic tools problems in memory, language (aphasia), attention, planning and concept formation, psychomotor function and personality problems can be detected.

Due to the changing demographics in western countries, the incidence of dementias constantly increases. About 5-10% of the people >65 years and 30-40% of those above 80 develop dementias. Incidence increases exponentially with age. Women are more often affected than men.

The cause of Alzheimer's disease is not fully understood. There are several hypotheses, which have different supporters. The most widely used hypothesis is the amyloid hypothesis. Amyloid beta deposits are found in the brain of AD patients preceding the onset of clinical dementia. However, amyloid beta is not pathological per se and is found in healthy aged people. Furthermore, amyloid plaque deposition do not correlate with neuron loss and also not with clinical symptoms. Abnormally phosphorylated tau protein may start quite early, i.e., before puberty or in early young adulthood and therefore decades before clinical onset of the disease (Braak & Del Tredici, 2011b).

### **3.2.2 Parkinson's Disease (PD)**

Parkinson's disease is the second most common degenerative disease of the central nervous system. Pathological hallmark of the idiopathic Parkinson's syndrome are movement related symptoms like slowness of movements, rigidity and tremor. Subtypes distinguish between the predominance of symptoms in a patient. Changes in mood and cognitive deficits are described as non-motor symptoms in PD. In late stage PD dementia is a common hallmark. Like ALS, PD affects people in midlife. However, there is evidence that disease process starts early in life (Braak & Del Tredici 2011b). The disease is caused by death of

dopaminergic cells in substantia nigra of the midbrain that project to the striatum. The pathological process of PD (formation of proteinaceous intraneuronal Lewy bodies and Lewy neurites) begins at two sites and continues in a topographically predictable sequence in six stages, during which components of the olfactory, autonomic, limbic, and somatomotor systems become progressively involved (Braak et al., 2006a). PD cannot be cured but dopaminergic medication is an effective treatment for the disease. However, medication may become ineffective in the cause of disease. Deep brain stimulation is an available tool in PD if no other therapy is applicable.

### **3.2.3 Huntington's Disease**

Huntington's disease (HD) is a movement disorder with inability to control movements: involuntary, sudden, fast and erratic movements of distal extremities, face, neck and trunk are seen. In early stages of HD slightly exaggerated movements might be considered as nervousness, however, in the course of the disease control of coordinated body movements are becoming more and more difficult, especially affecting walking. Men and women are similarly affected. Disease onset is usually between 30 and 50 years.

Huntington described the disease already in 1872. It has a prevalence of 2-10 per 100 000 inhabitants. It is an autosomal dominant genetic cause with full penetrance. There is a 50% chance of diseased offspring and therefore presymptomatic enrolment in clinical trials is possible.

## **4. Common neuroimaging techniques**

Neuroimaging techniques in degenerative diseases are used to investigate structural or functional changes in the brain and spinal chord. Those techniques may be used to support clinical diagnosis or, as for most of the functional techniques, are used in research to enrich our understanding of pathophysiological outcomes of neurodegenerative processes.

### **4.1 Structural techniques**

#### **4.1.1 Anatomical scans with CT and MRI**

Conventional radiography like computerized tomography (CT) is still widely used in traumatology and other fields of medicine. For CT, x-rays pass through the body and are attenuated in the tissue. The denser a tissue is, the more the x-rays are attenuated. Detectors pick up the signals and digital geometry processing generates three-dimensional images of e.g. the brain. CT has mainly lost its importance in the clinical evaluation of neurodegenerative diseases.

With the finding of magnetic resonance imaging (MRI) in the 1970s, a new era of medical neuroimaging evolved to visualize structures of the central nervous system. MRI uses the property of magnetic resonance in atoms with uneven number of nuclei. In living organisms, protons are mostly used, but any other atom with the according properties can similarly be used. An object (e.g. a human) is placed within a permanent magnetic field. A proportion of the protons align within this field. Gradient pulses in a high radio frequency are pulsed to deflect the spins of the protons. Inbetween those pulsed gradients, spins return to their original position and emit energy. This emission can be detected in MRI.

MRI images provide images of soft tissue e.g. the brain with high contrasts and without bone artefacts. Therefore, MRI is applicable to visualize anatomical and pathological

structures in the skull and in the spinal canal. Furthermore, in functional MRI it is applicable to non-invasively visualise brain function *in vivo*.

#### 4.1.2 Spectroscopy

Whereas MRI gives only information about the structure of the body like the distribution of water and fat, magnetic resonance spectroscopy is suitable to give information of property and chemical structure of tissue. MRS provides information on the nuclei of atoms, which allows deduction on the chemical properties of a tissue. It is a non-invasive technique, which is used in some clinical fields like tumour diagnostic. It can as well provide evidence of longitudinal change in cerebral function using proton-based metabolites (among others choline, creatine, lactate, N-acetylaspartate (NAA), glutamate). NAA is thought to be a marker of neuronal integrity and is therefore used as a diagnostic marker in neurodegenerative diseases. MRS has been used in research but fields of clinical application are expanding i.e. longitudinal change of metabolites in therapeutic intervention (Turner et al., 2011).

#### 4.1.3 Voxel based morphometry MRI

Voxel based morphometry (VBM) in MRI quantifies white or gray matter volume in the CNS. It is a non-invasive technique to detect brain volume changes *in vivo* and compare it between groups e.g. patients with neurodegenerative diseases and healthies. VBM registers every brain to a brain template to provide for main anatomical differences between brains. Statistical comparison of each subvolume of the brain (so called voxels) allows fast quantification of brain volume alterations.

#### 4.1.4 Diffusion tensor imaging

Diffusion tensor imaging (DTI) is based on the physics of diffusion of all molecules in e.g. the human body according to Brownian motion theory. Membranes, fibres and other molecules restrict the movement of molecules and the molecules align along barriers. The stronger the aligned diffusion, the higher is the anisotropy. In living tissue, fractional anisotropy (FA) is at its minimum (0) where there are no barriers and diffusion is not directed. FA is at its maximum (1) if alignment of diffusion is highest. DTI is applicable in white matter pathology in neurodegenerative diseases. DTI based fibre tracking gives additional information on directionality and can therefore be used to visualise e.g. direction and strength of bundles of white matter fibres within the brain. In neurodegenerative diseases it's applicable to detect white and grey matter loss.

### 4.2 Functional neuroimaging

Functional neuroimaging in neurodegenerative disease aims to explore the functional state of the brain as well as the capacity of the adult brain to functionally compensate for progressive loss of neurons. In order to map brain functions, non-invasive neuroimaging techniques have been available for almost 80 years. Since different techniques have different shortcomings, the development and implementation of new functional imaging techniques have been complementary over these years (for review see Lulé et al., 2009). Electroencephalography (EEG), already developed in the 1920s by Hans Berger, is a technique for directly measuring electrical activity of cortical neurons on the surface of the head, thus providing a high temporal but a very low spatial resolution (Berger, 1929). In

1968, the first measurements of the magnetic equivalents of EEG recordings (electrical activity of cortical neurons induce magnetic fields) signalled the beginning of magnetoencephalography (MEG), which complemented the field of non-invasive imaging of neuronal activity in the brain (Cohen, 1968). However, the interpretation of signals in the spatial domain remains challenging and is not suitable for subcortical structures.

Since the mid 1970s, methods for measuring brain metabolism have been established. Changes in metabolism in the brain are a consequence of energy expenditure following neuronal activity in the brain. These data facilitate indirect measurement of overall brain activity. Accordingly, measurements of metabolism have improved spatial resolution especially for subcortical structures. Positron Emission Tomography (PET) and Single Photon Emission Computed Tomography (SPECT) record the dynamic distribution in the human brain of isotopes administered to a subject when assigned to a specific task (Phelps et al., 1975; Ter-Pogossian et al., 1975). Since metabolism is a second order effect following the electrical activity of neurons with latency, the temporal resolution of such measurements is low. Furthermore, radioactive substances have to be applied, limiting the application for scientific research.

In the 1990s, functional MRI was developed. Functional MRI can be used to measure physiological changes not only of metabolism but also of e.g. blood flow in the brain. Like metabolism, blood flow is stimulated following oxygen expenditure of the cortical substrate. Like PET and SPECT, fMRI is a second-order signal with the problem of low temporal resolution but high spatial resolution, with the potential to indirectly measure cortical and subcortical activity easily during the performance of a given task. Accordingly, fMRI combines advantages of different non-invasive functional neuroimaging techniques. However, the indirect nature by which brain activity is currently measured by fMRI continues to limit its role as a “front-line” imaging tool.

Notwithstanding, the clinical potential of a non-invasive probe of brain function with the option of repeated measures over time (e.g. due to a lack of radiation charge) in addition to the wide-spread availability of MRI scanners in many hospitals and research centres have extended its application in clinical science and contributed to an exponential increase in scientific publications on fMRI over the last decade (Jezzard & Buxton, 2006).

#### **4.2.1 Principles of fMRI**

Experimental work in animals first demonstrated that oxygenated blood and deoxygenated blood present different properties in a magnetic field, as noted by Linus Pauling as early as the 1930s (Pauling, 1936). Because of its unshielded iron, deoxygenated blood has paramagnetic properties whereas oxygenated blood has diamagnetic properties. Deoxyhaemoglobin as an endogenous paramagnetic contrast agent dephases nuclear spins of water protons in its vicinity with a physical effect of signal intensity change in T2\*-weighted MR images (Frahms et al., 1999). Ogawa and co-workers realised that those differences in magnetic properties in blood could have implications in the visualisation of local brain function (Ogawa et al., 1990a; 1990b).

The most commonly used fMRI approach is to measure mainly blood flow changes using the blood-oxygenation-level-dependency (BOLD) effect (Kwong et al., 1992; Ogawa et al., 1992), although other parameters can also be measured. A change in neuronal activity causes a decreased local blood oxygenation and an increased demand for oxygen. The local increase in deoxygenated blood level in the corresponding brain area is followed by a rise in cerebral blood flow that at least transiently ‘uncouples’ from oxygen consumption (Frahms

et al., 1992). The increase in blood flow and oxygenation decreases deoxyhaemoglobin concentration and leads to an increase in the corresponding MRI signal intensity and the effective spin-spin relaxation time  $T2^*$ . This can be measured as a BOLD signal change in fMRI (Kim et al., 1997a; Logothetis et al., 2004; Ogawa et al., 1990b).

The time curve of the measured BOLD signal in fMRI may be explained as follows: The local increase in deoxygenated blood level following neuronal activity in the corresponding brain area is assumed to be represented by the "initial dip" in the relevant BOLD signal. Oxygenated blood invades brain areas shortly after to compensate the increased metabolic rate in the neurons which results in a BOLD signal increase that peaks after around 6 s and returns to baseline after 20–30 s (Figure 1).

### Time series of BOLD response

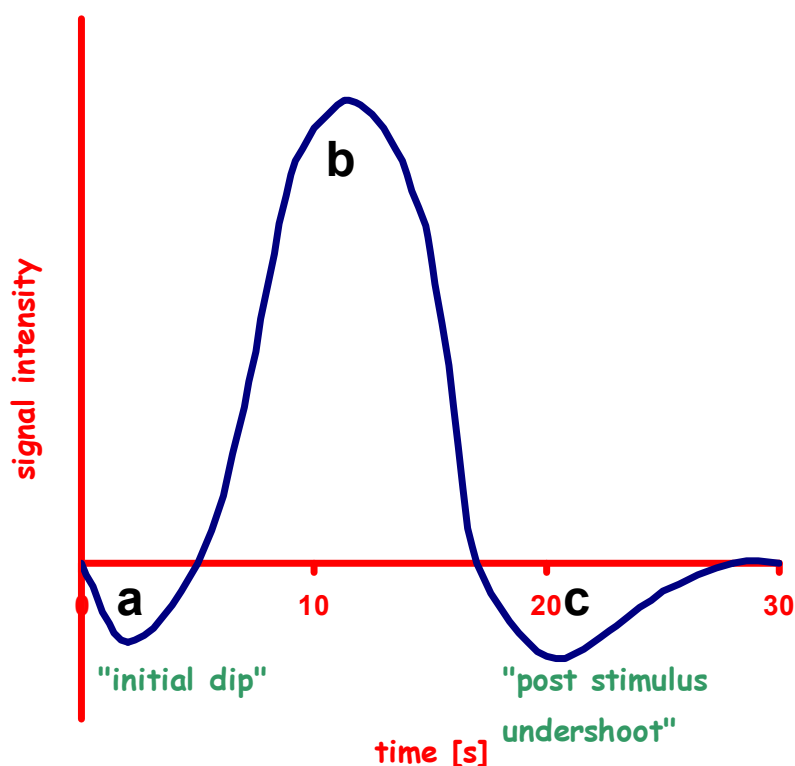


Fig. 1. Time series of BOLD response in fMRI. BOLD signal decreases as oxygen expenditure in the brain tissue (a: initial dip) increases; in the following phase extensive flow of oxygenated blood leads to increase in BOLD signal, reaching its maximum at about 6s (b). The signal returns to baseline within 20–30 s, often combined with a post-stimulus undershoot of the BOLD response (c).

The BOLD in fMRI does not directly measure neural activity but relies on a surrogate 'secondary' signal resulting from changes in oxygenation, perfusion (blood volume and flow), and metabolism (e.g. glucose and oxygen consumption) (Logothetis et al., 2004; Kim et al., 1997b; DiSalle et al., 1999). Neurovascular and metabolic correlates associated with brain activation are not yet fully understood, but there is evidence for a correlation between neuronal activity (or activation) in the brain and the fMRI signal (Logothetis et al., 2001). Functional MRI gives an approximation of neuronal activity, detecting, for example, task-induced changes in local brain function (DiSalle et al., 1999; van Geuns et al., 1999). Because



the BOLD signal, however, derives from the interaction of multiple parameters (e.g. perfusion, metabolic turnover of neurons, density of venous vasculature of tissue, medication etc.) and may vary between brain areas and individuals as well as experimental and clinical settings, quantitative analysis in absolute terms is precluded (Kim et al., 1997a; Di Salle et al., 1999; Logothetis et al., 2001).

MRI sequences that are best suited for functional neuroimaging should be both fast and sensitive to changes in the deoxyhaemoglobin concentration (Frahms et al., 1999). The MRI sequence that is generally considered to be the first choice for measuring BOLD in fMRI is a T2\*-weighted echo-planar imaging (EPI) sequence, with its high speed yielding imaging times which translate into a maximum temporal resolution (Edelman et al., 1994; Kwong et al., 1995; Schmitt et al., 1998; Roberts et al., 2007). Temporal and spatial parameters of MRI scanning such as repetition time (TR) or slice thickness are limited by the T2\* signal decay of the MRI sequence and determined according to study-specific factors, e.g. region of interest and field strength (Schmitt et al., 1998; Turner et al., 1998; Triantafyllou et al., 2005; Norris et al., 2006; Figure 2). Other MRI sequences such as fast low angle shot (FLASH) techniques facilitate access to higher spatial resolution at the expense of temporal resolution and volume coverage of larger volumes leading to higher scanning times (Frahms et al., 1999), which is not always favourable in clinical settings.



Fig. 2. Example of orientation of EPI-sequence (white lines) along the anterior-posterior commissure overlaid onto a t1 weighted image (mprage) of a head (sagittal view)

## 5. Functional neuroimaging in motor neuron diseases

### 5.1 Functional neuroimaging of motor network

In fMRI studies, ALS patients present higher volumes of activated brain areas in motor tasks compared with healthy controls, thus providing evidence for functional reorganisation and cortical plasticity in MND (Brooks et al., 2000; Lulé et al., 2009). Konrad et al. observed this in eleven ALS patients (Konrad et al., 2002) who performed a simple finger flexion task with 10% of each individual's maximum grip force. Increased activity was found in motor areas such as the premotor area, supplementary motor area, and the cerebellum. A similarly

increased activity in motor areas was observed in fifteen ALS patients compared to fifteen healthy controls during a sequential finger tapping movement task (Han et al., 2006) and in ALS patients compared both to patients with upper limb weakness due to peripheral nerve lesions and to controls during freely selected random joystick movements of the right hand (Stanton et al., 2007a). It has been proposed that these changes may represent cortical plasticity, as new synapses and pathways are developed to compensate for the selective loss of pyramidal cells in the motor cortex (Schoenfeld et al., 2005). A shift of activity to more anterior regions of the premotor cortex, i.e. Brodmann area (BA) 6, during upper limb movement has been observed in ALS patients (Konrad et al., 2002; Han et al., 2006), such findings being supported by previous functional imaging studies with PET (Kew et al., 1993a; 1994). Furthermore, there is longitudinal fMRI evidence of progressive involvement of the premotor area in upper limb motor tasks in the course of the disease (Lulé et al., 2007a). Thirteen patients with sporadic ALS and 14 healthy controls were asked to perform tasks involving a grip movement of the left, right, and both hands and to imagine the same without any overt movement of the hand. Motor imagery is known to involve similar areas as motor execution without being affected by confounding factors of effort and strain. In two consecutive fMRI measurements at a six-month interval, evidence for progressive recruitment of premotor areas in motor imagery was found in the course of the disease (Lulé et al., 2007a).

Furthermore, a changed pattern and an anterior shift of activity in ALS were also observed in further cortical areas besides the premotor cortex for various motor tasks. For instance, increased involvement of supplementary motor areas (SMA) (Konrad et al., 2002; 2006; Han et al., 2006) and sensorimotor cortices has been seen (Brooks et al., 2000; Han et al., 2006; Stanton et al., 2007a; Mohammadi et al., 2011). Activity in contralateral sensorimotor cortex activity was increased the stronger the physical impairments were in patients (Mohammadi et al., 2011). Furthermore, activity in adjacent areas such as the bilateral inferior parietal lobe (BA 40) and bilateral superior temporal gyrus (BA 22) was increased in ALS patients compared to healthy controls during upper limb motor task performance in different fMRI studies (Stanton et al., 2007a). Altered somatotopy in the sensorimotor cortices was not observed in patients with exclusive lower motor neuron involvement (Kew et al., 1994), but only in ALS patients with clinical and functional involvement of both upper and lower motor neurons (Han et al., 2006; Kew et al., 1993a; 1994) or upper motor neuron only (Stanton et al., 2007a). This suggests that this changed pattern of activity might represent the loss of the pyramidal tract (Kew et al., 1994). A similar shift of activity in motor tasks into more anterior regions of sensorimotor and premotor areas and the SMA has been demonstrated for different neuropathologies with distinct aetiology such as stroke (Weiller et al., 2006). Thus, it may be assumed that this anterior shift represents a general pattern of plasticity as a response to neuronal loss in primary motor areas as a more or less efficient way to compensate motor function rather than an ALS-specific pattern of altered motor activation (Weiller et al., 2006).

Increasing activity in ipsilateral cortical areas such as the sensorimotor cortex (Han et al., 2006; Stanton et al., 2007a) and primary motor areas (Schoenfeld et al., 2005) has been observed in ALS patients. In a motor task of upper limb movement with varying task difficulty, six ALS patients presented an increased activity in ipsilateral primary motor areas compared to six healthy controls, corresponding to the degree of difficulty (Schoenfeld et al., 2005). The fact that healthy controls recruit ipsilateral areas with increasing complexity of a

task suggests that ipsilateral involvement may reflect difficulty-dependent compensation and not a pathological pattern of activation *per se*. Accordingly, ALS patients may recruit existing neuronal pathways to compensate for functional loss in primary motor cortex (Schoenfeld et al., 2005).

Furthermore, a more pronounced involvement of other motor functional areas at cortical and subcortical levels has been demonstrated in fMRI studies of motor tasks. For motor execution, a stronger involvement of areas involved in motor learning, such as the basal ganglia, cerebellum (Han et al., 2006; Konrad et al., 2006) and/or brainstem (Konrad et al., 2006) is evident. It may be assumed that alterations in functioning of basal ganglia are likely to be related to upper motor neuron pathology since they were observed in patients with exclusive upper motor neuron involvement (Tessitore et al., 2006). For motor imagery, a stronger recruitment of higher cognitive areas of motor control (frontal areas BA 9, 44, 45) and motor representation (inferior parietal activity, BA 40) in the course of the disease has been demonstrated in ALS patients compared to healthy controls (Lulé et al., 2007a). Overall, functional connectivity in the motor system network is altered in ALS (Mohammadi et al., 2009).

Moreover, an increased involvement of extra motor areas, e.g. in the anterior cingulate cortex for movements of the right hand, is evident for patients with exclusive upper motor neuron involvement by fMRI (Tessitore et al., 2006). Similarly, an increased activity in anterior insular cortex and anterior cingulate cortex has been shown in other functional studies of motor execution (Brooks et al., 2000; Kew et al., 1993a; 1994).

Whether the changed pattern of activity in other motor functional areas and higher cognitive areas during motor tasks represents the recruitment of redundant parallel motor system pathways or whether they map functional compensation or reorganisation can only be speculated upon. There is evidence that the change in cortical functioning of other motor and extramotor systems is primarily related to upper motor neuron pathology (Tessitore et al., 2006).

For motor imagery, which is known to involve similar areas as motor execution, a different pattern of cortical activity is seen in ALS compared to motor tasks. In a movement imagery task of the right hand in 16 ALS patients, there was reduced BOLD activity in the left anterior parietal lobe, the anterior cingulate, and medial pre-frontal cortex compared to 17 healthy controls (Stanton et al., 2007b). Reduced BOLD activity in the anterior cingulate cortex was also evident in a movement imagery task of both hands in the study by Lulé et al. (2007a). This reduction in cortical activation during motor imagery is at odds with the pattern observed during motor execution. This may represent the disruption of normal motor imagery networks by ALS pathology outside the primary motor cortex (Lulé et al., 2007a; Stanton et al., 2007b).

In summary, these data suggest an additional recruitment in brains of patients with ALS comprising bilateral areas in the premotor cortex in early stages along with involvement of higher order motor processing areas, determined by motor impairments (especially associated with upper motor neuron pathology) in the long run. This additional recruitment might be a (futile) way to compensate ALS-associated progressive functional loss.

The cardinal feature of ALS is the loss of giant pyramidal Betz cells in the primary motor cortex (Brownell et al., 1970). It is nowadays assumed, however, that degeneration extends beyond the motor cortex. Neurodegeneration in motor areas might lead to progressive compensation of secondary motor areas for movement representation. Compensation terminates in a non-functional distributed cortical and subcortical ALS-specific motor network. More research needs to be done on how well the ALS patients in advanced stages

of the disease retain the potential for compensatory activity and how training of e.g. movement imagery might slow down the “compensatory” process. Functional MRI seems to be an appropriate way to gain more knowledge on this issue.

## 5.2 Functional imaging of extramotor paradigms in MND

The multisystemic character of ALS has been supported by various findings of functional imaging studies, although there are few fMRI studies. Involvement of sensory pathways in ALS has been reported by histopathological (Isaacs et al., 2007) and electrophysiological studies (Mai et al., 1998; Pugdahl et al., 2007). Evidence from fMRI studies for changed cortical patterns for sensory processing suggests the involvement of sensory processing areas in ALS (Lulé et al., 2010). In a visual, auditory and somatosensory stimulus paradigm, ALS patients presented reduced activity in primary and secondary sensory areas and an increased activity in higher associative areas. This increase in activity was correlated with loss of movement ability: The higher the physical restrictions were, the higher was the activity in those areas of third order sensory processing in ALS patients (Figure 3).

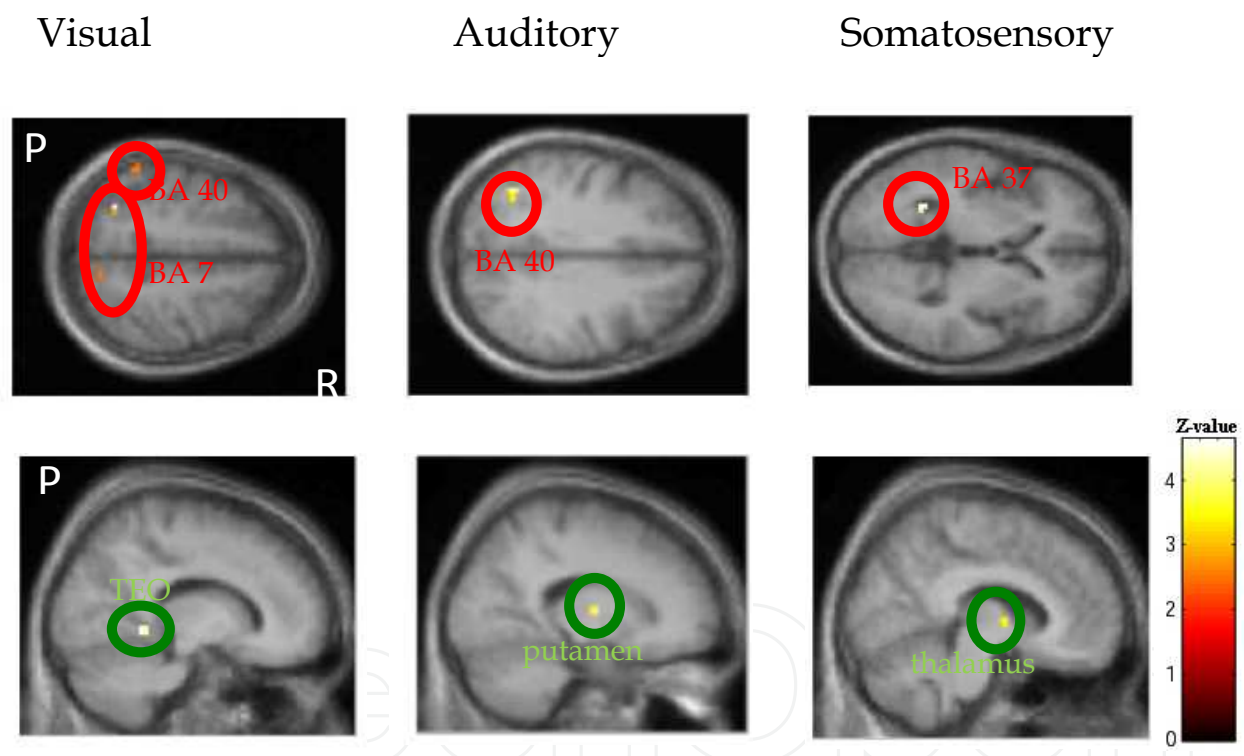


Fig. 3. Changes in brain activity associated with loss of physical function in amyotrophic lateral sclerosis (ALS). Statistical maps presenting significantly increased and decreased blood oxygen level dependent activity associated with loss of physical function (measured with ALS functional rating scale, ALS-FRS) in ALS patients for visual, auditory and somatosensory stimulation. Areas with increasing (upper row, red) and decreasing (lower row, green) activity are shown. Significant activations are overlaid onto an axial (top row) and sagittal (bottom row) mean anatomical image of all subjects. Displayed are clusters >5 voxels with uncorrected threshold  $p < 0.001$ . P, posterior; R, right.

Structural analysis of white matter integrity in this study measured with DTI provided evidence for a disruption of sensory nerve fibres in those ALS patients (Lulé et al., 2010).

Auditory processing underlying stimulus detection measured by MEG and subsequent memory-based comparison processes were abnormal in ten ALS patients with bulbar signs (Pekkonen et al., 2004), and a reduced response to auditory and visual stimuli was observed in ALS patients compared to healthy controls using EEG (Münste et al., 1998; Vieregge et al., 1999). This finding may indicate a changed sensory processing capacity as well as reduced attention capacity (Pinkhardt et al., 2008), an ability assigned to the frontal cortex known to be involved in ALS (Ludolph et al., 1992; Kew et al., 1993b).

The association of functional cortical changes and cognitive deficits has been confirmed by an fMRI paradigm of letter fluency and confrontation naming in 28 non-demented ALS patients compared to 18 healthy controls (Abrahams et al., 2004) and had been demonstrated previously by other functional imaging techniques (Ludolph et al., 1992; Kew et al., 1993b; Abrahams et al., 2004). There is increasing evidence that not only do 2-5% of ALS patients present an ALS/dementia complex but also that patients with classical ALS without obvious clinical evidence of cognitive deficits may have subtle changes in frontal cortical function (Ludolph et al., 1992; Kew et al., 1993b; Lulé et al., 2005; Lomen-Hoerth et al., 2002). The cognitive impairment has been reported as more pronounced in ALS patients with a bulbar onset compared to patients with spinal onset (Abrahams et al., 1997; Strong et al., 1999; Lomen-Hoerth et al., 2002; Schreiber et al., 2005) and is also evident in patients with primary lateral sclerosis (PLS; Piquard et al., 2006). Longitudinal investigation of ALS patients (up to 18 months) revealed that cognitive dysfunction in ALS occurred early in the disease course and that the cognitive deficits may not progress in synchrony with motor decline, but distinctly more slowly (Schreiber et al., 2005). Functional imaging studies confirm hypoperfusion in the resting state in the frontal cortex in ALS with or without cognitive deficits (Ludolph et al., 1992; Anzai et al., 1990; Tanaka et al., 1993). Apart from the local hypometabolism, there is also evidence for decreased activity in different cortical areas during the performance of different tasks. Findings from fMRI studies support the association of reduced frontal executive function and reduced activity in fronto-parietal areas, and confirm findings from studies using other imaging techniques (Kew et al., 1993b; Abrahams et al., 1996). In non-demented ALS patients, a correlation between reduced verbal fluency and reduced activity in middle and inferior frontal gyrus, anterior cingulate cortex, and parietal and temporal lobe have been observed in an fMRI study by Abrahams et al. which included 22 non-demented ALS patients compared with 18 healthy controls (Abrahams et al., 2004). There is no evidence of additional recruitment in other areas to compensate the functional loss in the frontal cortex, as has been shown for the motor system. Cognitive functions of frontal areas do not exhibit redundancy of motor pathways, and compensation is therefore not possible. Further longitudinal fMRI studies of different cognitive functions in ALS might improve our understanding of subclinical cognitive deficits in ALS.

Further differences in cortical pattern activation were observed in ALS patients without significant cognitive impairments during processing of socio-emotional stimuli. Pictures of persons in emotional situations were presented to 13 ALS patients and 15 healthy controls at an initial measurement and to 10 of these ALS patients and 14 healthy controls at a second measurement after six months. ALS patients presented an increased activity in the right-sided supramarginal area (BA 40), which is part of the social-information processing network. This difference in social-information processing pattern increased over the course of six months (Lulé et al., 2007b). The increased activity in the social information-processing

pathway might represent an altered sensitivity to social-emotional cues in ALS patients without cognitive deficits (Lulé et al., 2007b). Reduced activity in right sided frontal areas during processing of aversive emotional stimuli in ALS patients compared to controls support the assumption of an impaired processing pathway in ALS (Palmieri et al., 2010). More research is required to determine how successful and stable this compensatory recruitment is and again fMRI may be an important step.

## **6. Functional neuroimaging in other neurodegenerative diseases like dementia, Parkinson's disease, and Huntington's disease**

### **6.1 Functional neuroimaging in dementia**

There is the described overlap of dementia and motor neuron diseases, however, contrary to the above described prominent role in MND, the role of imaging in dementia has traditionally been directed at ruling out treatable and reversible aetiologies (Tartaglia et al., 2011). Contrary to motor neuron diseases it was rarely used to better understand the pathophysiology of the different dementias.

Structural CT and MRI scans are mainly used to assess volumetric changes in dementias with decreases in gyral and increases in sulcal size secondary to decrease in synaptic density, neuronal loss, and cell shrinkage (Tartaglia et al., 2010). The medial temporal lobes, especially the hippocampus and entorhinal cortex (ERC), are among the earliest sites of pathologic involvement in AD (Braak & Braak, 1991), and studies have repeatedly shown decreased hippocampal and ERC volumes in patients with AD compared with age-matched controls (Appel et al., 2009). Other severely affected areas include the lateral parietal and posterior superior temporal regions and medial posterior portion of the cingulate gyrus (Jones et al., 2006), but atrophy is also evident in the frontal, temporal, and occipital lobes (Rusinek et al., 1991). Recent neuropathological data provide evidence that disease pathology starts in locus coeruleus and propagates into transentorhinal region and other cerebral regions (Braak & Del Tredici, 2011a). MRI of hippocampal and cortical regions in the parietal and lateral temporal regions has been successfully used as prognostic marker in patients with mild cognitive impairment (MCI) to develop AD (Du et al., 2003; Schott et al., 2003). High field MRI provided evidence for a sensitivity of the thickness of CA1 to distinguish subjects with AD from normal controls (Kerchner et al., 2010). Like in ALS, white matter (WM) pathology was long not in focus of research. However, recent work provides evidence for WM changes in AD and MCI in association with cognitive changes (Zhang et al., 2007; Sexton et al., 2010). It might even be useful to distinguish different forms of dementia (Firbank et al., 2007; Zhang et al., 2009). NAA spectroscopy has been used as a possible diagnostic marker in dementia. NAA is consistently reported as being lower in the parietal gray matter and hippocampus of patients with AD than in cognitively normal elderly subjects (Schuff et al., 2002).

On the functional level of the brain, evidence for a reduced function of frontal areas in FTD compared to AD was seen using fMRI (Rombouts et al., 2003). Furthermore, alterations in the default mode network (areas active during rest and idling of the brain) in resting state have been found for AD and MCI patients (Tartaglia et al., 2011). In the future, the application of neuroimaging in dementia will increase, as there will be extended evidence for prognostic and clinical marker for different forms of dementia.

### **6.2 Functional neuroimaging in Parkinson's disease**

Like in most neurodegenerative diseases, neuroimaging in Parkinson's disease has been challenging because the majorities of neurons are affected before clinical symptoms evolve and diagnosis is made. The clinical symptoms of PD appear when approximately 50-80% of the nigral dopamine (DA) neurons have been lost already. Consequently, structural imaging has in general been unrewarding, although some newer MRI techniques, such as diffusion tensor imaging or shape analysis, are somewhat more promising and provided evidence for a reduced volume and changed connectivity of substantia nigra (Stössl, 2011). Functional neuroimaging is a promising candidate to detect specific changes in PD. Functional connectivity measured with resting state MRI provided evidence for changed pattern in motor network (Wu et al., 2009; Helmich et al., 2010) and in the default network (Palmer et al., 2010). MRI spectroscopy may be useful in differentiating between PD and atypical parkinsonian syndromes (Firbank et al., 2002). Functional MRI in PD has been widely used and proven to be sensitive to e.g. polymorphism of catechol-O-methyltransferase (COMT) in PD. Different activation patterns in fronto-parietal areas in an fMRI task provided a clear link to genotype, dopaminergic medication and cognitive performance in PD patients (Williams-Gray et al., 2007, 2008). In the future, functional neuroimaging may be used to get a fast and objective means of functional and genetic status in advanced stage PD patients.

### **6.3 Functional neuroimaging in Huntington's disease**

Among neurodegenerative disorders, HD is unique in that individuals destined to develop symptoms can be identified through genetic testing before clinical signs of the disease begin. This raises the possibility of developing therapies to prevent or delay the onset of clinical manifestations in HD gene carriers. Therefore, substantial effort has been dedicated to the characterization of quantitative descriptors of disease progression in premanifest individuals (Eidelberg & Surmeier, 2011). Neuroimaging may be used to clarify diagnosis in the pre-symptomatic stage. The idea of imaging as a preclinical marker in HD was supported by findings in a prospective observational study (Tabrizi et al., 2011).

The vast number of neuroimaging studies in HD traditionally was on single brain regions like structural and functional studies on the striatum. Several PET studies revealed association of striatal and cortical dysfunction in association with genetic alterations and cognitive function. However, with the evolvement of MRI volumetric studies with low patient load, better insight on striatal function was found in a faster and easier way. However, even with this technique, systems-level changes might not be detectable. Connectivity studies like in resting state MRI might be more susceptible and applicable in the future.

## **7. Conclusion**

Despite different aetiology of neurodegenerative diseases, similar approaches have been used in diseases of the central and peripheral nervous system. MRI based neuroimaging has extended our understanding of involvement of cortical structures which by far outreach the usually described clinical changes. Different neuroimaging techniques provide limitations that can be compensated by other techniques. Structural and functional MRI has taken over radio nucleotide dependent measurements in clinical

setting due to low patient load. Spectroscopy and resting state analysis will extend our understanding of molecular and functional changes of cortical structures and networks. MRI neuroimaging has the potential to fill the gap between pathogenesis and clinical outcome of neurodegenerative diseases.

## **8. Future advances of neuroimaging in neurodegeneration**

### **8.1 Brain-computer interfaces**

Brain computer interfaces (BCIs) are a technique, which transfers and translates brain signals to technical devices for communication, control of environment (e.g. light switches) or prosthetic devices. BCIs are the only applicable means for communication in patients with advanced neurodegenerative diseases and no voluntary muscle control like in complete locked-in patients (CLIS) at end stage of ALS. There has been the unsolved question why patients in CLIS are unable to control EEG BCIs (Kübler & Birbaumer, 2008). With the means of functional neuroimaging, the question of activity of the idling brain of CLIS patients might be solved. Neuroimaging provide essential insight into the brains of patients with neurodegenerative diseases who are unable to communicate due to the loss of motor control like in ALS or cognitive ability like in dementia.

### **8.2 Clinical implications**

MRI based neuroimaging has been extensively applied in diagnosis of neurodegenerative diseases. Low patient load and high applicability are in favour for this technique. Availability of MRI scanner in many clinics has already made neuroimaging an essential key in diagnosis of neurodegenerative diseases. The value of neuroimaging techniques for biomarker is still subject to ongoing debate; yet, there is a strong need for easy to apply biomarkers. In most neurodegenerative diseases, loss and death of motor neurons occur long before onset of clinical symptoms. Diagnosis is usually based on clinical symptoms when the majority of target cells are already affected. Braak and colleagues in Alzheimer's disease have provided evidence for this. Tau tangles are found up to 30-50 years prior to onset of clinical symptoms (Braak & Braak, 1991; Braak & Del Tredici, 2011b). Effective therapeutic trials, however, ask for application as early as possible. Emergence of several disease-modifying drugs in neurodegenerative diseases has particularly highlighted the need for biomarkers of therapeutic response. Unwanted drug effects has brought additional requirement for effective biomarkers for optimal initial patient selection and timing of discontinuation (Turner et al., 2011). In the future, in search for robust biomarkes, MRI based neuroimaging techniques are a promising candidate.

## **9. Acknowledgement**

Volker Diekmann, Hans-Peter Müller, Jan Kassubek and Alexander Unrath (all University of Ulm) are thankfully acknowledged for their help in the course of the fMRI and DTI experiments and data analyses. Special thanks to Sonja Fuchs and Sandra Pauli (University of Ulm) for technical assistance in MRI measurements and Johanna Heimrath for her help with the manuscript. We would like to thank Corinna Hendrich, Regina Gastl and Anne Sperfeld (all University of Ulm) for supporting us in the recruitment of patients. Special thanks to the patients and healthy subjects who participated in our studies.



## 10. References

- Abrahams S, Goldstein LH, Kew JJ, Brooks DJ, Lloyd CM, Frith CD, Leigh PN. Frontal lobe dysfunction in amyotrophic lateral sclerosis. A PET study. *Brain* 1996;119 (6):2105-20.
- Abrahams S, Goldstein LH, Al-Chalabi A, Pickering A, Morris RG, Passingham RE, Brooks DJ, Leigh PN. Relation between cognitive dysfunction and pseudobulbar palsy in amyotrophic lateral sclerosis. *J Neurol Neurosurg Psychiatry* 1997;62(5):464-72.
- Abrahams S, Goldstein LH, Simmons A, Brammer M, Williams SC, Giampietro V, Leigh PN. Word retrieval in amyotrophic lateral sclerosis: a functional magnetic resonance imaging study. *Brain* 2004;127(7):1507-17.
- Anzai E, Shiozawa Z, Shindo K, Tsunoda S, Koizumi K, Uchiyama G. 123I-iodoamphetamine single photon emission computed tomography in three patients with amyotrophic lateral sclerosis. *Kaku Igaku* 1990;27(8):863-7.
- Appel J, Potter E, Shen Q, et al. A comparative analysis of structural brain MRI in the diagnosis of Alzheimer's disease. *Behav Neurol* 2009;21:13-19.
- Berger H. Über das Elektrenkephalogramm des Menschen in: *Arch f Psychiatr* 1929;87:527-570.
- Braak H, Bohl JR, Müller CM, Rüb U, de Vos RA, Del Tredici K. Stanley Fahn Lecture 2005: The staging procedure for the inclusion body pathology associated with sporadic Parkinson's disease reconsidered. *Mov Disord*. 2006a;21(12):2042-51.
- Braak H, Braak E. Neuropathological stageing of Alzheimer-related changes. *Acta Neuropathol (Berl)* 1991;82:239-259.
- Braak H, Del Tredici K. Alzheimer's pathogenesis: is there neuron-to-neuron propagation? *Acta Neuropathol*. 2011a;121(5):589-95.
- Braak H, Del Tredici K. The pathological process underlying Alzheimer's disease in individuals under thirty. *Acta Neuropathol*. 2011b;121(2):171-81.
- Braak H, Rüb U, Schultz C, Del Tredici K. Vulnerability of cortical neurons to Alzheimer's and Parkinson's diseases. *J Alzheimers Dis*. 2006b;9(3):35-44.
- Brooks BR, Bushara K, Khan A, Hershberger J, Wheat JO, Belden D et al. Functional magnetic resonance imaging (fMRI) clinical studies in ALS--paradigms, problems and promises. *Amyotroph Lateral Scler Other Motor Neuron Disord* 2000;1(2):23-32.
- Brownell B, Oppenheimer DR, Hughes JT. The central nervous system in motor neurone disease. *J Neurol Neurosurg Psychiatry* 1970;33:338-357.
- Cohen, D. Magnetoencephalography: evidence of magnetic fields produced by alpha rhythm currents. *Science* 1968;161:784-786
- Di Salle F, Formisano E, Linden DE, Goebel R, Bonavita S, Pepino A, Smaltino F, Tedeschi G. Exploring brain function with magnetic resonance imaging. *Eur J Radiol* 1999;30(2):84-94.
- Du AT, Schuff N, Zhu XP, et al. Atrophy rates of entorhinal cortex in AD and normal aging. *Neurology* 2003;60:481-486.
- Edelman RR, Wielopolski P, Schmitt F. Echo-planar MR imaging. *Radiology* 1994;192(3):600-12.

- Eidelberg D, Surmeier DJ. Brain networks in Huntington disease. *J Clin Invest.* 2011;121(2):484-92.
- Firbank MJ, Harrison RM, O'Brien JT. A comprehensive review of proton magnetic resonance spectroscopy studies in dementia and Parkinson's disease. *Dement Geriatr Cogn Disord* 2002;14:64-76.
- Firbank MJ, Blamire AM, Krishnan MS, et al. Diffusion tensor imaging in dementia with Lewy bodies and Alzheimer's disease. *Psychiatry Res* 2007;155:135-145.
- Frahms J, Fransson P, Krüger G. Magnetic resonance imaging of human brain function. In Winhorst U, Johanssen H (eds.): *Modern techniques in neuroscience research*; Springer, Heidelberg, 1999.
- Grammas P, Martinez J, Miller B. Cerebral microvascular endothelium and the pathogenesis of neurodegenerative diseases. *Expert Rev Mol Med.* 2011 Jun 10;13:e19.
- Hacke W. *Neurologie*; Springer, Heidelberg, 2010.
- Han J, Ma L. Functional magnetic resonance imaging study of the brain in patients with amyotrophic lateral sclerosis. *Chin Med Sci J* 2006;21(4):228-33
- Helmich RC, Derikx LC, Bakker M, Scheeringa R, Bloem BR, Toni I. Spatial remapping of cortico-striatal connectivity in Parkinson's disease. *Cereb Cortex* 2010;20:1175-1186.
- Isaacs JD, Dean AF, Shaw CE, Al-Chalabi A, Mills KR, Leigh PN. Amyotrophic lateral sclerosis with sensory neuropathy: part of a multisystem disorder? *J Neurol Neurosurg Psychiatry* 2007;78(7):750-3.
- Jezzard P, Buxton RB. The clinical potential of functional magnetic resonance imaging. *J Magn Reson Imaging* 2006;23(6):787-93.
- Jones BF, Barnes J, Uylings HB, et al. Differential regional atrophy of the cingulate gyrus in Alzheimer disease: a volumetric MRI study. *Cereb Cortex* 2006;16:1701-1708.
- Kerchner GA, Hess, CP, Hammond-Rosenbluth KE, et al. Hippocampal CA1 apical neuropil atrophy in mild Alzheimer disease visualized with 7-T MRI. *Neurology* 2010;75:1381-1387
- Kew JJM, Leigh PN, Playford ED, Passingham RE, Goldstein LH, Frackowiak RS, Brooks DJ. Cortical function in amyotrophic lateral sclerosis. A positron emission tomography study. *Brain* 1993a;116:655-680.
- Kew JJ, Goldstein LH, Leigh PN, Abrahams S, Cosgrave N, Passingham RE, Frackowiak RS, Brooks DJ. The relationship between abnormalities of cognitive function and cerebral activation in amyotrophic lateral sclerosis. A neuropsychological and positron emission tomography study. *Brain* 1993b;116 (6):1399-423.
- Kew JJM, Brooks DJ, Passingham RE, Rothwell JC, Frackowiak RS, Leigh PN. Cortical function in progressive lower motor neuron disorders and amyotrophic lateral sclerosis: A comparative PET study. *Neurology* 1994;44:1101-1110.
- Kim SG, Ugurbil K. Functional magnetic resonance imaging of the human brain. *J Neurosci Methods* 1997a;74(2):229-43.
- Kim SG, Ugurbil K. Comparison of blood oxygenation and cerebral blood flow effects in fMRI: estimation of relative oxygen consumption change. *Magn Reson Med* 1997b;38(1):59-65.

- Konrad C, Henningsen H, Bremer J, Mock B, Deppe M, Buchinger C, Turski P, Knecht S, Brooks B. Pattern of cortical reorganization in amyotrophic lateral sclerosis: a functional magnetic resonance imaging study. *Exp Brain Res* 2002;143(1):51-56.
- Konrad C, Jansen A, Henningsen H, Sommer J, Turski PA, Brooks BR, Knecht S. Subcortical reorganization in amyotrophic lateral sclerosis. *Exp Brain Res* 2006;172(3):361-9.
- Kübler A, Birbaumer N. Brain-computer interfaces and communication in paralysis: extinction of goal directed thinking in completely paralysed patients? *Clin Neurophysiol*. 2008;119(11):2658-66.
- Kwong KK, Belliveau JW, Chesler DA, Goldberg IE, Weisskoff RM, Poncelet BP, Kennedy DN, Hoppel BE, Cohen MS, Turner R, et al. Dynamic magnetic resonance imaging of human brain activity during primary sensory stimulation. *Proc Natl Acad Sci USA* 1992;89(12):5675-9.
- Kwong KK. Functional magnetic resonance imaging with echo planar imaging. *Magn Reson Q* 1995;11(1):1-20.
- Logothetis NK, Pauls J, Augath M, Trinath T, Oeltermann A. Neurophysiological investigation of the basis of the fMRI signal. *Nature* 2001; 412(6843):150-7.
- Logothetis NK, Pfeuffer J. On the nature of the BOLD fMRI contrast mechanism. *Magn Reson Imaging* 2004;22(10):1517-31.
- Lomen-Hoerth C, Anderson T, Miller B. The overlap of amyotrophic lateral sclerosis and frontotemporal dementia. *Neurology* 2002;59(7):1077-9.
- Ludolph AC, Dengler R: Geschichte, Epidemiologie und diagnostische Kriterien. In: Dengler R, Ludolph A, Zierz S. *Amyotrophe Lateralsklerose*. 2nd ed. Thieme, Stuttgart, 1999., pp. 1-16 (1999)
- Ludolph AC, Langen KJ, Regard M, Herzog H, Kemper B, Kuwert T, Böttger IG, Feinendegen L. Frontal lobe function in amyotrophic lateral sclerosis: a neuropsychologic and positron emission tomography study. *Acta Neurol Scand* 1992;85(2):81-9.
- Lulé D, Kurt A, Jürgens R, Kassubek J, Diekmann V, Kraft E, Neumann N, Ludolph AC, Birbaumer N, Anders S. Emotional responding in amyotrophic lateral sclerosis. *J Neurol* 2005;252:1517-1524.
- Lulé D, Diekmann V, Kassubek J, Kurt A, Birbaumer N, Ludolph AC, Kraft E. Cortical Plasticity in Amyotrophic Lateral Sclerosis: Motor Imagery and Function. *Neurorehabil Neural Repair*. 2007a;21(6):518-26.
- Lulé D, Diekmann V, Anders S, Kassubek J, Kubler A, Ludolph AC, Birbaumer N. Brain responses to emotional stimuli in patients with amyotrophic lateral sclerosis (ALS). *J Neurol*. 2007b;254(4):519-27.
- Lulé D, Ludolph AC, Kassubek J. MRI-based functional neuroimaging in ALS: An update. *Amyotroph Lateral Scler*. 2009;10(5-6):258-68.
- Lulé D, Diekmann V, Müller HP, Kassubek J, Ludolph AC, Birbaumer N. Neuroimaging of multimodal sensory stimulation in Amyotrophic Lateral Sclerosis (ALS). *JNNP* 2010;81(8):899-906.
- Mai R, Facchetti D, Micheli A, Poloni M. Quantitative electroencephalography in amyotrophic lateral sclerosis. *Electroencephalogr Clin Neurophysiol* 1998;106(4): 383-6.

- Mohammadi B, Kollwe K, Samii A, Krampfl K, Dengler R, Münte TF. Changes of resting state brain networks in amyotrophic lateral sclerosis. *Exp Neurol*. 2009;217(1):147-53.
- Mohammadi B, Kollwe K, Samii A, Dengler R, Münte TF. Functional neuroimaging at different disease stages reveals distinct phases of neuroplastic changes in amyotrophic lateral sclerosis. *Hum Brain Mapp*. 2011;32(5):750-8.
- Münte TF, Tröger MC, Nusser I, Wieringa BM, Johannes S, Matzke M, Dengler R. Alteration of early components of the visual evoked potential in amyotrophic lateral sclerosis. *J Neurol* 1998;245(4):206-10.
- Neumann M, Sampathu DM, Kwong LK, Truax AC, Micsenyi MC, Chou TT, Bruce J, Schuck T, Grossman M, Clark CM, McCluskey LF, Miller BL, Masliah E, Mackenzie IR, Feldman H, Feiden W, Kretzschmar HA, Trojanowski JQ, Lee VM. Ubiquitinated TDP-43 in frontotemporal lobar degeneration and amyotrophic lateral sclerosis. *Science*. 2006;314(5796):130-3.
- Norris DG. Principles of magnetic resonance assessment of brain function. *J Magn Reson Imaging* 2006;23(6):794-807.
- Ogawa S, Lee TM, Nayak AS, Glynn P. Oxygenation-sensitive contrast in magnetic resonance image of rodent brain at high magnetic fields. *Magn Reson Med* 1990a;14(1):68-78.
- Ogawa S, Lee TM, Kay AR, Tank DW. Brain magnetic resonance imaging with contrast dependent on blood oxygenation. *Proc Natl Acad Sci USA* 1990b;87(24):9868-72.
- Ogawa S, Tank DW, Menon R, Ellermann JM, Kim SG, Merkle H, Ugurbil K. Intrinsic signal changes accompanying sensory stimulation: functional brain mapping with magnetic resonance imaging. *Proc Natl Acad Sci USA* 1992;89(13):5951-5.
- Palmer SJ, Li J, Wang ZJ, McKeown MJ. Joint amplitude and connectivity compensatory mechanisms in Parkinson's disease. *Neuroscience* 2010;166:1110-1118.
- Palmieri A, Naccarato M, Abrahams S, Bonato M, D'Ascenzo C, Balestreri S, Cima V, Querin G, Dal Borgo R, Barachino L, Volpato C, Semenza C, Pegoraro E, Angelini C, Sorarù G. Right hemisphere dysfunction and emotional processing in ALS: an fMRI study. *J Neurol*. 2010;257(12):1970-8.
- Pauling L, Coryell CD. The Magnetic Properties and Structure of Hemoglobin, Oxyhemoglobin and Carbonmonoxyhemoglobin. *Proc Natl Acad Sci USA* 1936;22(4):210-6.
- Pekkonen E, Osipova D, Laaksovirta H. Magnetoencephalographic evidence of abnormal auditory processing in amyotrophic lateral sclerosis with bulbar signs. *Clin Neurophysiol* 2004;115(2):309-15.
- Phelps ME, Hoffman EJ, Mullani NA, Ter-Pogossian MM. Application of annihilation coincidence detection to transaxial reconstruction tomography. *J Nucl Med* 1975;16(3):210-24.
- Pinkhardt EH, Jürgens R, Becker W, Mölle M, Born J, Ludolph AC, Schreiber H. Signs of impaired selective attention in patients with amyotrophic lateral sclerosis. *J Neurol*. 2008;255(4):532-8.


- Piquard A, Le Forestier N, Baudoin-Madec V, Delgadillo D, Salachas F, Pradat PF, Derouesné C, Meininger V, Lacomblez L. Neuropsychological changes in patients with primary lateral sclerosis. *Amyotroph Lateral Scler.* 2006;7(3):150-60.
- Pugdahl K, Fuglsang-Frederiksen A, de Carvalho M, Johnsen B, Fawcett PR, Labarre-Vila A, Liguori R, Nix WA, Schofield IS. Generalised sensory system abnormalities in amyotrophic lateral sclerosis: a European multicentre study. *J Neurol Neurosurg Psychiatry* 2007;78(7):746-9.
- Roberts TP, Mikulis D. Neuro MR: principles. *J Magn Reson Imaging* 2007;26(4):823-37.
- Rombouts SA, van Swieten JC, Pijnenburg YA, Goekoop R, Barkhof F, Scheltens P. Loss of frontal fMRI activation in early frontotemporal dementia compared to early AD. *Neurology* 2003;60:1904-1908.
- Rusinek H, de Leon MJ, George AE, et al. Alzheimer disease: measuring loss of cerebral gray matter with MR imaging. *Radiology* 1991;178:109-114.
- Schmitt F, Stehling MK, Turner R. Echo-planar imaging theory, technique and application. Berlin: Springer; 1998.
- Schott JM, Fox NC, Frost C, et al. Assessing the onset of structural change in familial Alzheimer's disease. *Ann Neurol* 2003;53:181-188.
- Schreiber H, Gaigalat T, Wiedemuth-Catrinescu U, Graf M, Uttner I, Mucche R, Ludolph AC. Cognitive function in bulbar- and spinal-onset amyotrophic lateral sclerosis. A longitudinal study in 52 patients. *J Neurol* 2005;252(7):772-81.
- Schuff N, Capizzano AA, Du AT, et al. Selective reduction of Nacetylaspartate in medial temporal and parietal lobes in AD. *Neurology* 2002;58:928-935.
- Schoenfeld MA, Tempelmann C, Gaul C, Kühnel GR, Düzel E, Hopf JM, Feistner H, Zierz S, Heinze HJ, Vielhaber S. Functional motor compensation in amyotrophic lateral sclerosis. *J Neurol* 2005;252:944-952.
- Sexton CE, Mackay CE, Lonie JA, et al. MRI correlates of episodic memory in Alzheimer's disease, mild cognitive impairment, and healthy aging. *Psychiatry Res* 2010;184:57-62.
- Stanton BR, Williams VC, Leigh PN, Williams SC, Blain CR, Jarosz JM, Simmons A. Altered cortical activation during a motor task in ALS : Evidence for involvement of central pathways. *J Neurol* 2007a;254(9):1260-7.
- Stanton BR, Williams VC, Leigh PN, Williams SC, Blain CR, Giampietro VP, Simmons A. Cortical activation during motor imagery is reduced in Amyotrophic Lateral Sclerosis. *Brain Res* 2007b;1172:145-51.
- Stoessl AJ. Neuroimaging in Parkinson's disease. *Neurotherapeutics.* 2011;8(1):72-81.
- Strong MJ, Grace GM, Orange JB, Leeper HA, Menon RS, Aere C. A prospective study of cognitive impairment in ALS. *Neurology* 1999;53(8):1665-70.
- Tabrizi SJ, Scahill RI, Durr A, Roos RA, Leavitt BR, Jones R, Landwehrmeyer GB, Fox NC, Johnson H, Hicks SL, Kennard C, Craufurd D, Frost C, Langbehn DR, Reilmann R, Stout JC; TRACK-HD Investigators. Biological and clinical changes in premanifest and early stage Huntington's disease in the TRACK-HD study: the 12-month longitudinal analysis. *Lancet Neurol.* 2011 Jan;10(1):31-42.

- Tanaka M, Kondo S, Hirai S, Sun X, Yamagishi T, Okamoto K. Cerebral blood flow and oxygen metabolism in progressive dementia associated with amyotrophic lateral sclerosis. *J Neurol Sci* 1993;120(1):22-8.
- Tartaglia MC, Rosen HJ, Miller BL. Neuroimaging in dementia. *Neurotherapeutics*. 2011;8(1):82-92.
- Ter-Pogossian MM, Phelps ME, Hoffman EJ, Mullani NA. A positron-emission transaxial tomograph for nuclear imaging (PETT). *Radiology* 1975;114(1):89-98.
- Tessitore A, Esposito F, Monsurro MR, Graziano S, Panza D, Russo A, Migliaccio R, Conforti FL, Morrone R, Quattrone A, Di Salle F, Tedeschi G. Subcortical motor plasticity in patients with sporadic ALS: An fMRI study. *Brain Res Bull* 2006;69(5):489-94.
- Triantafyllou C, Hoge RD, Kruger G, Wiggins CJ, Potthast A, Wiggins GC, Wald LL. Comparison of physiological noise at 1.5 T, 3 T and 7 T and optimization of fMRI acquisition parameters. *Neuroimage* 2005;26:243-250.
- Turner MR, Grosskreutz J, Kassubek J, Abrahams S, Agosta F, Benatar M, Filippi M, Turner R, Howseman A, Rees GE, Josephs O, Friston K. Functional magnetic resonance imaging of the human brain: data acquisition and analysis. *Exp Brain Res* 1998;123:5-12.
- Turner MR, Grosskreutz J, Kassubek J, Abrahams S, Agosta F, Benatar M, Filippi M, Goldstein LH, van den Heuvel M, Kalra S, Lulé D, Mohammadi B; first Neuroimaging Symposium in ALS (NISALS). Towards a neuroimaging biomarker for amyotrophic lateral sclerosis. *Lancet Neurol*. 2011;10(5):400-3.
- van Geuns RJ, Wielopolski PA, de Bruin HG, Rensing BJ, van Ooijen PM, Hulshoff M, Oudkerk M, de Feyter PJ. Basic principles of magnetic resonance imaging. *Prog Cardiovasc Dis* 1999;42(2):149-56.
- Vieregge P, Wauschkuhn B, Heberlein I, Hagenah J, Verleger R. Selective attention is impaired in amyotrophic lateral sclerosis--a study of event-related EEG potentials. *Brain Res Cogn Brain Res* 1999;8(1):27-35.
- Weiller C, May A, Sach M, Buhmann C, Rijntjes M. Role of functional imaging in neurological disorders. *J Magn Reson Imaging* 2006;23(6):840-50.
- Williams-Gray CH, Hampshire A, Robbins TW, Owen AM, Barker RA. Catechol O-methyltransferase Val158Met genotype influences frontoparietal activity during planning in patients with Parkinson's disease. *J Neurosci* 2007;27:4832-4838.
- Williams-Gray CH, Hampshire A, Barker RA, Owen AM. Attentional control in Parkinson's disease is dependent on COMT val 158 met genotype. *Brain* 2008;131:397-408.
- Wu T, Wang L, Chen Y, Zhao C, Li K, Chan P. Changes of functional connectivity of the motor network in the resting state in Parkinson's disease. *Neurosci Lett* 2009;460:6-10.
- Zhang Y, Schuff N, Jahng GH, et al. Diffusion tensor imaging of cingulum fibers in mild cognitive impairment and Alzheimer disease. *Neurology* 2007;68:13-19.

Zhang Y, Schuff N, Du AT, et al. White matter damage in frontotemporal dementia and Alzheimer's disease measured by diffusion MRI. *Brain* 2009;132:2579-2592.

IntechOpen

IntechOpen



## **Neuroimaging for Clinicians - Combining Research and Practice**

Edited by Dr. Julio F. P. Peres

ISBN 978-953-307-450-4

Hard cover, 424 pages

**Publisher** InTech

**Published online** 09, December, 2011

**Published in print edition** December, 2011

Neuroimaging for clinicians sourced 19 chapters from some of the world's top brain-imaging researchers and clinicians to provide a timely review of the state of the art in neuroimaging, covering radiology, neurology, psychiatry, psychology, and geriatrics. Contributors from China, Brazil, France, Germany, Italy, Japan, Macedonia, Poland, Spain, South Africa, and the United States of America have collaborated enthusiastically and efficiently to create this reader-friendly but comprehensive work covering the diagnosis, pathophysiology, and effective treatment of several common health conditions, with many explanatory figures, tables and boxes to enhance legibility and make the book clinically useful. Countless hours have gone into writing these chapters, and our profound appreciation is in order for their consistent advice on the use of neuroimaging in diagnostic work-ups for conditions such as acute stroke, cell biology, ciliopathies, cognitive integration, dementia and other amnesic disorders, Post-Traumatic Stress Disorder, and many more

### **How to reference**

In order to correctly reference this scholarly work, feel free to copy and paste the following:

Lulé Dorothée and Ludolph Albert Christian (2011). Degeneration of the Human Nervous System and Magnetic Resonance Neuroimaging, Neuroimaging for Clinicians - Combining Research and Practice, Dr. Julio F. P. Peres (Ed.), ISBN: 978-953-307-450-4, InTech, Available from:  
<http://www.intechopen.com/books/neuroimaging-for-clinicians-combining-research-and-practice/degeneration-of-the-human-nervous-system-and-magnetic-resonance-neuroimaging>

**INTECH**  
open science | open minds

### **InTech Europe**

University Campus STeP Ri  
Slavka Krautzeka 83/A  
51000 Rijeka, Croatia  
Phone: +385 (51) 770 447  
Fax: +385 (51) 686 166  
[www.intechopen.com](http://www.intechopen.com)

### **InTech China**

Unit 405, Office Block, Hotel Equatorial Shanghai  
No.65, Yan An Road (West), Shanghai, 200040, China  
中国上海市延安西路65号上海国际贵都大饭店办公楼405单元  
Phone: +86-21-62489820  
Fax: +86-21-62489821



© 2011 The Author(s). Licensee IntechOpen. This is an open access article distributed under the terms of the [Creative Commons Attribution 3.0 License](#), which permits unrestricted use, distribution, and reproduction in any medium, provided the original work is properly cited.

IntechOpen

IntechOpen