

# We are IntechOpen, the world's leading publisher of Open Access books Built by scientists, for scientists

**4,800**

Open access books available

**122,000**

International authors and editors

**135M**

Downloads

Our authors are among the

**154**

Countries delivered to

**TOP 1%**

most cited scientists

**12.2%**

Contributors from top 500 universities



**WEB OF SCIENCE™**

Selection of our books indexed in the Book Citation Index  
in Web of Science™ Core Collection (BKCI)

Interested in publishing with us?  
Contact [book.department@intechopen.com](mailto:book.department@intechopen.com)

Numbers displayed above are based on latest data collected.

For more information visit [www.intechopen.com](http://www.intechopen.com)



# Surgical Strategy for Secondary Correction of Unilateral and Bilateral Cleft Lip-Nose Deformities

Norifumi Nakamura

*Department of Oral and Maxillofacial Surgery, Field of Maxillofacial Rehabilitation,  
Kagoshima University Graduate School of Medical and Dental Sciences  
Japan*

## 1. Introduction

In the treatment of cleft deformities, restoring the symmetric and natural-shaped nose as well as the symmetric and functional lip is important to allow patients to lead smooth social lives. Recently primary rhinoplasty with presurgical orthopedic treatment for infants with cleft lip and nose has been highlighted (Grayson, et al. 1999), and these techniques have certainly improved nasal deformity and overall symmetry (Nakamura, et al. 2009). However, definitive rhinoplasty may still be necessary as the child grows. Despite recent developments in cleft surgery, the surgical modality for correction of cleft lip-nose deformity that provides a desirable nasal form with long-term stability has not yet been established. Surgeons have attempted cleft lip-nose correction, but they are often frustrated by unsatisfactory results.

A considerable number of surgical modalities for definitive correction of unilateral and bilateral cleft lip-nose deformities have been reported over the past half century. Generally, it is argued that a clear understanding of the associated complex anatomical and pathological abnormalities is required to obtain a desirable nasal form (Shih, et al. 2002). The abnormalities of cleft lip-nose involve all components of the nose, including the facial skeleton, cartilage, muscle, skin, subcutaneous tissue, and mucosal lining. To obtain desirable and stable outcomes, secondary correction of the cleft lip-nose deformity should approach each abnormality in each of the above components. Based on this concept, the author has established the following strategy for secondary cleft lip-nose correction that approaches each anatomical and pathological abnormality causing the main deformities of unilateral and bilateral cleft lip-nose.

## 2. Treatment strategy for unilateral cleft lip-nose deformity

### 2.1 Anatomical and pathological characteristics of unilateral cleft lip-nose

Unilateral cleft lip (UCL)-nose deformity includes deviated columella, depressed nasal tip, wide and snub nasal ala, and a flat and V-shaped nostril on the cleft side (Millard, 1976a). The position of the nasal ala on the affected side often dislocates in a downward and distal direction in relation to the inadequately unionized upper lip (Fig. 1A).

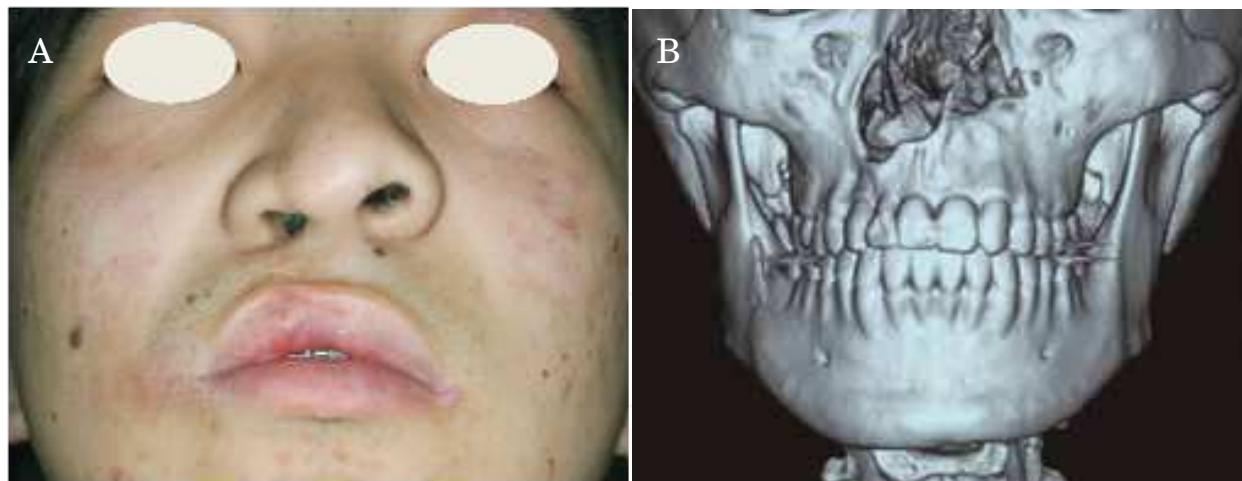


Fig. 1. Facial view (A) and three-dimensional CT finding (B) demonstrating characteristics of UCL-nose deformity

When one considers the characteristics of unilateral cleft lip nose-deformities, the distal, downward, and backward dislocation of the skeletal framework causes all components of the lip and nasal tissue to be malpositioned three-dimensionally on the affected side (Fig. 1A and Fig. 1B). Consequently, the upper and lower lateral cartilages dislocate distally and downwardly, the attachment of the nasalis muscle is malpositioned and skin at the nostril rim forms a web. Additionally, excessive stress over the nasal tip and dorsum causes growth disturbances of the septal cartilage, resulting in a short columella and flared nasal tip on the affected side.

To facilitate an understanding of these abnormalities, the unilateral cleft lip-nose can be thought to be like a house built on a slope (Fig. 2). The center pole corresponds to the nasal septum, the roof is the lower lateral cartilage and skin, the lateral pillar is the vestibule, and the ground is the maxillary bone. In the normal nose, the ground is flat and the house can stand upright (Fig. 2A), but in the unilateral cleft lip-nose, the house is on a slope and the pole and roof incline toward the downward side (Fig. 2B). To create a straight house on a slope, the center pole must stand upright in the center of the face, the pillar should be expanded and roof should be lifted upward (Fig. 2C).

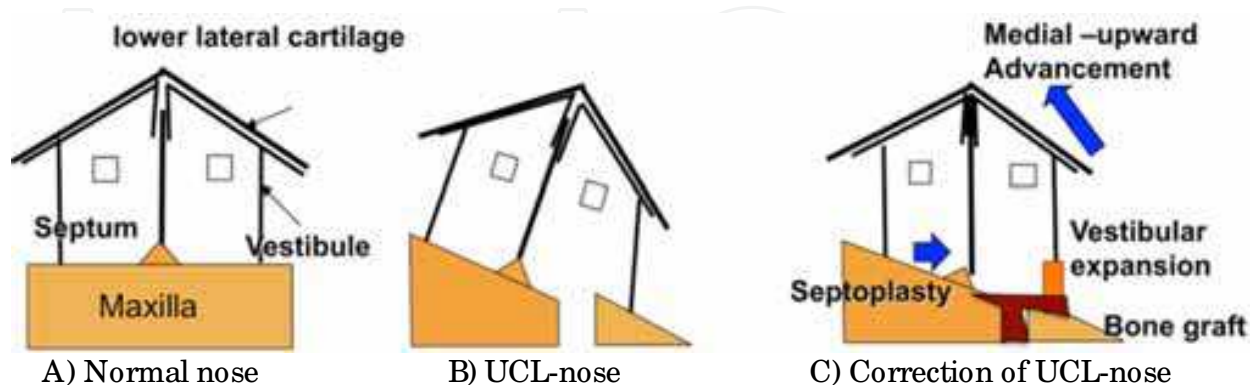


Fig. 2. Anatomical and pathologic abnormalities of UCL-nose; normal nose (A), UCL-nose (B), and correction of UCL-nose (C) (Modified from Nakamura, *Jpn J Oral Maxillofac Surg* 2010)

Table 1 demonstrates the treatment strategy for unilateral cleft lip-nose, showing an approach to each anatomical and pathological abnormality causing the main deformities of

unilateral cleft lip-nose: deviated columella, depressed and deviated nasal tip, wide and snub nasal ala, and flat and V-shaped nostril on the cleft side (Table 1). Therefore, the author's secondary correction involves open rhinoplasty, septoplasty, repositioning of the lower lateral cartilage, medial and upward advancement of the lip and nose components; the nasal vestibular tissues, the nasal ala, nasalis muscle, and the upper part of the lip including orbicular oris muscle, and nasal vestibular expansion with or without bone graft (Fig. 2C).

nasal deformities	anatomical pathological abnormalities	surgical procedures in the secondary correction
● deviated columella	<ul style="list-style-type: none"> <li>• deviation of midline of maxilla</li> <li>• deviated septal cartilage</li> </ul>	<ul style="list-style-type: none"> <li>• dissection around anterior nasal spine</li> <li>• reposition of inferior base of septal cartilage, if necessary</li> </ul>
● depressed and deviated nasal tip	<ul style="list-style-type: none"> <li>• distally and downwardly dislocated lower lateral cartilage on the cleft side</li> <li>• growth disturbances of septal cartilage</li> </ul>	<ul style="list-style-type: none"> <li>• freeing and repositioning of lower lateral cartilage by overlapping on the upper lateral cartilage</li> <li>• caudal septal extension graft</li> </ul>
● wide and snub nasal ala on cleft side	<ul style="list-style-type: none"> <li>• retropositioned anterior maxillary wall</li> <li>• dislocation of the attachment of nasalis muscle</li> </ul>	<ul style="list-style-type: none"> <li>• secondary bone graft, if necessary</li> <li>• supraperiosteal dissection around piriform margin</li> <li>• reposition of the nasalis muscle by medial-upward advancement of nasolabial components</li> </ul>
● flat and V-shaped nostril	<ul style="list-style-type: none"> <li>• webbing of the rim skin</li> <li>• shortage of the nasal vestibular lining</li> <li>• disconnection of orbicularis oris muscle</li> </ul>	<ul style="list-style-type: none"> <li>• bilaterally symmetric reverse-U incision</li> <li>• expansion of the nasal vestibule</li> <li>• overlapped suturing of orbicularis oris muscle</li> </ul>

Table 1. Nasal deformity and treatment strategy for unilateral cleft lip-nose (*Modified form Nakamura, et al. JOral Maxillofac Surg 2010*)

## 2.2 Surgical procedures for correction of unilateral cleft lip-nose deformities (Fig. 3 and Fig. 4)

1. Open rhinoplasty is applied according to the bilateral reverse-U incision and transcolumellar incision. A reverse-U incision is made on the outer skin slightly above the nostril rim in order to lengthen the upper columella on the affected side (Fig. 3A and Fig. 4A). The distal ends of the incision are extended into the nostril and connected to the back cut incision along the nasal vestibule. The lower end of the back cut incision is extended to the nasal floor and to the white lip along previous surgical scars, when simultaneous correction of upper lip deformity is necessary.
2. Through the oral and nasal vestibular incision, supraperiosteal dissection surrounding the piriform margin is performed on the affected side. This dissection provides 3D movement of the nasal alar base and enables the medial-upward advancement of the nasolabial components.
3. Deviation of the columellar base is corrected by supraperiosteal dissection around the anterior nasal spine through the oral vestibular incision. When the base of the nasal septum is severely deviated, the inferior edge of the septal cartilage is excised to allow repositioning to the midline, and then it is secured to the small hole made at the piriform bottom using a 4-0 Nylon thread (Fig. 4B and Fig. 5).
4. Reflecting the nose tip skin, the malpositioned lower lateral alar cartilage is exposed from both the nasal skin and lining mucosa, and the distal ends of the lateral crura are freed from the surrounding tissue (Fig. 3B and Fig. 4C). Since the corrected cartilage is often insufficiently supported, a small, square cartilaginous strut approximately 8 - 10 mm x 15 mm is taken from the lower part of the nasal septum, and transferred to the

anterior edge of the nasal septum; a caudal septal extension graft (Fig. 4D and Fig. 5). When the growth of the nasal septum is too underdeveloped, free auricular cartilage is used for a caudal septal extension graft. The medial crus of the lower lateral cartilage on the affected side is repositioned in a slightly overlapped position on the upper lateral cartilage and fixed symmetrically to the caudal septal extension graft using a 6-0 Nylon thread (Fig. 4E and Fig. 5B).

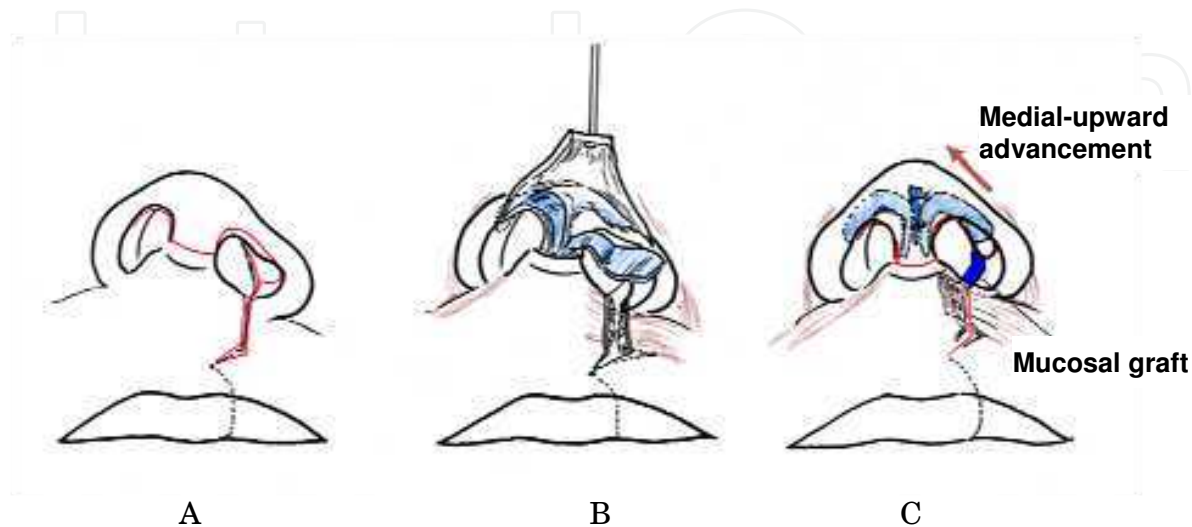


Fig. 3. Surgical procedures for correction of unilateral cleft lip-nose deformity (Nakamura, et al. *JO Oral Maxillofac Surg* 2010)

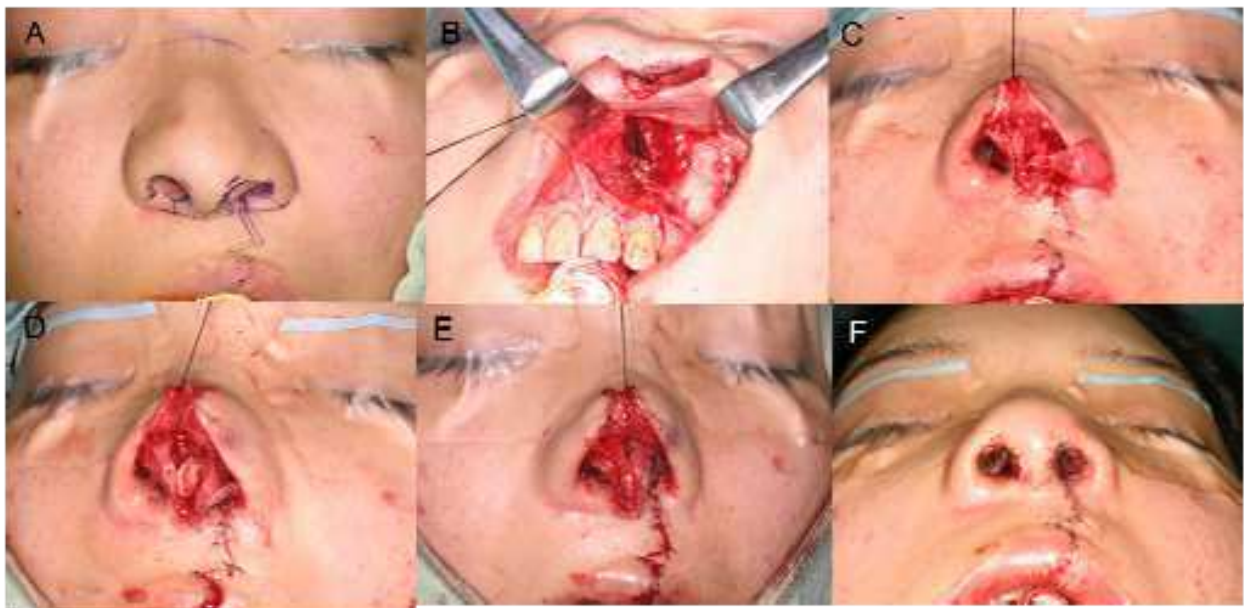


Fig. 4. Step-by-step procedures for correction of unilateral cleft lip-nose deformity (Nakamura, et al. *JO Oral Maxillofac Surg* 2010)

5. After the nasal tip skin is redraped, the nasal lining is advanced medially and upwardly to cover the nostril dome (Fig. 3C). The excess skin at the nostril rim on the cleft side is also reflected and pushbacked into the canopy of the nostril dome. The defect of lining at the nasal vestibule caused by the above advancement is then covered by a free

mucosal graft donated from the buccal area or covered by the tissue advanced from the bottom of the nasal floor (Fig. 3C)

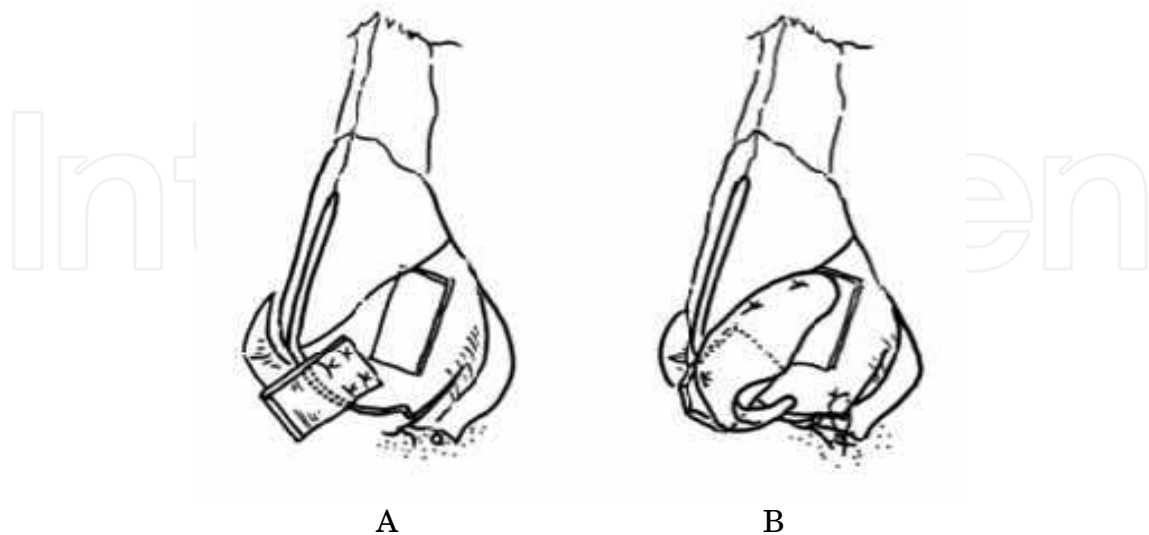


Fig. 5. Reposition of the lower lateral cartilage with a caudal septal extension graft (Nakamura, et al. *JOral Maxillofac Surg* 2010)

6. When simultaneous correction of upper lip deformity is carried out, the nasalis muscle and the orbicularis oris muscle are separated along the previous scar. After dissecting these muscles from the maxillary wall, the distal bundle of nasalis muscle is then connected to the periosteum surrounding the anterior nasal spine, and the medial and distal bundles of orbicularis oris muscle are connected in an overlapping manner using a mattress suture technique (Fig. 3C). At the end of surgery, subcutaneous and cutaneous suturing is carefully performed (Fig. 4F).

### 2.3 Pre- and postoperative views and three-dimensional observation of patients treated for unilateral cleft lip-nose deformity

Pre- and postoperative photos and the three-dimensional (3D) color images of the patients are demonstrated in figure 6 and figure 7. Preoperative views demonstrate the deviated nasal tip, asymmetric and wide peak of the nasal hump and obviously small and flat nasal ala on the affected side. The nostril on the affected side is flatter than that on the healthy side in both patients. 3D color images indicate asymmetry of the alar groove and nasal tip more visually. The top of the alar groove on the cleft side is dislocated distally and downwardly resulting in a small snub ala.

Postoperative photos and 3D color images in the frontal and basal views demonstrate symmetric nasal forms. The nasal tip projection is recovered in the center of the face and the height and the appropriate contour of the nasal ala groove on the cleft side are improved satisfactorily. The nostril demonstrates a symmetric and desirable form postoperatively. The contour between the columella and the upper lip in the lateral view appears quite natural.

The author has performed secondary treatment of unilateral cleft lip-nose on more than 50 patients, and there have not been any serious complications such as necrosis of the skin flap, infection, or airway obstruction, nor any obvious scars or deformities involving the upper lip and/ or columellar base in any patient.

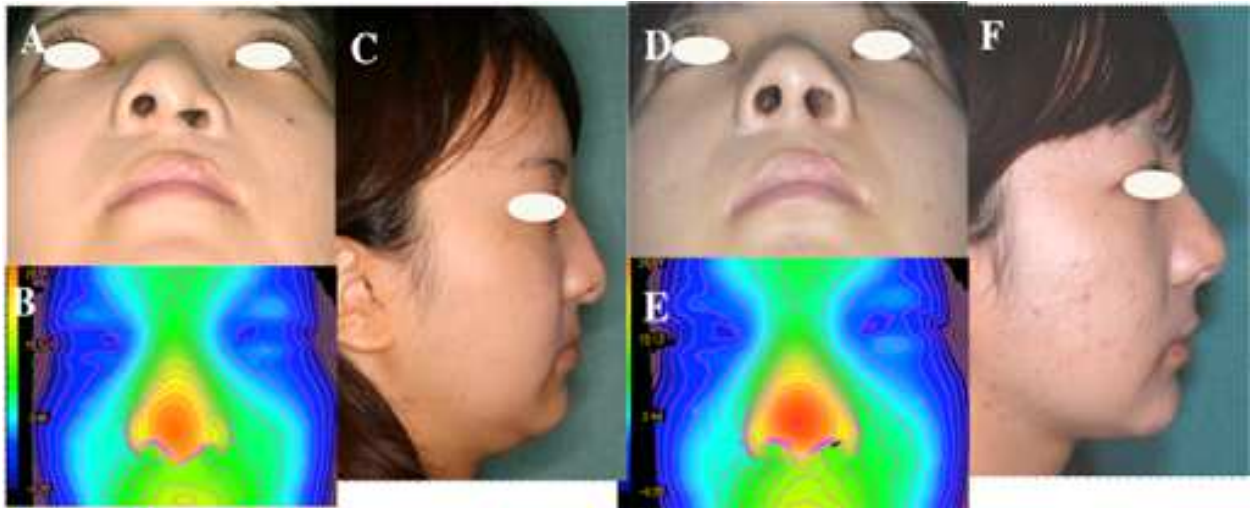


Fig. 6. Pre- and postoperative nasal views and 3D images of a female with UCLP whose correction is shown in figure 4. (Nakamura, et al. *J Oral Maxillofac Surg* 2010)

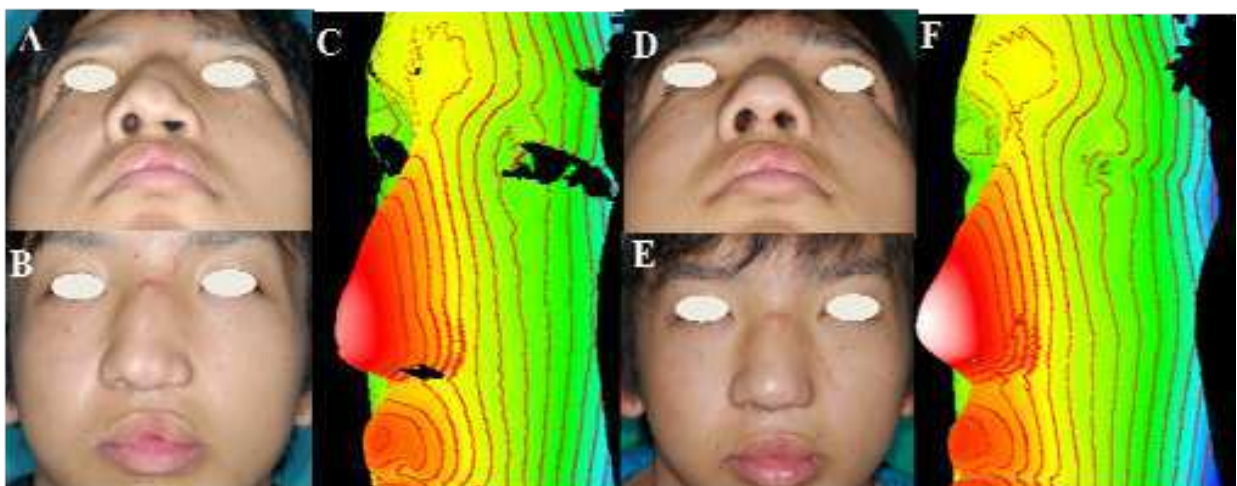


Fig. 7. Pre- and postoperative nasal views and 3D images of a male with UCLP

### 3. Treatment of strategy for bilateral cleft lip-nose deformity

#### 3.1 Anatomical and pathological characteristics of bilateral cleft lip-nose

Bilateral cleft lip (BCL)-nose deformity is characterized mainly by a columella with varying degrees of shortness, a depressed nasal tip, bilateral dislocation of the alar cartilage, and eversion of the alar bases (Fig. 8)(Millard, 1976b). When one considers the characteristics of bilateral cleft lip-nose, the deformities might be basically considered the combined characteristics of a unilateral cleft lip-nose on both sides, including varying degrees of anterior overgrowth of the premaxilla. Due to the lateral, downward, and backward dislocation of the bilateral skeletal framework, all components of the lip and nasal tissues are also malpositioned three dimensionally. Consequently, the attachment of the nasal muscle is malpositioned, bilateral major alar cartilages are separated distally and downwardly, and nostril rim skin forms a web. Additionally, the excessive stress over the nasal tip and dorsum causes growth disturbances of the septal cartilage, resulting in a short

columella and flared nasal tip. Therefore, it is more physiological to advance all nasal tip components medially and upwardly after dissecting free from the dislocated anterior maxillary wall, as in unilateral cleft lip-nose correction, and to supply lateral tissue to the columella rather than the upper lip.

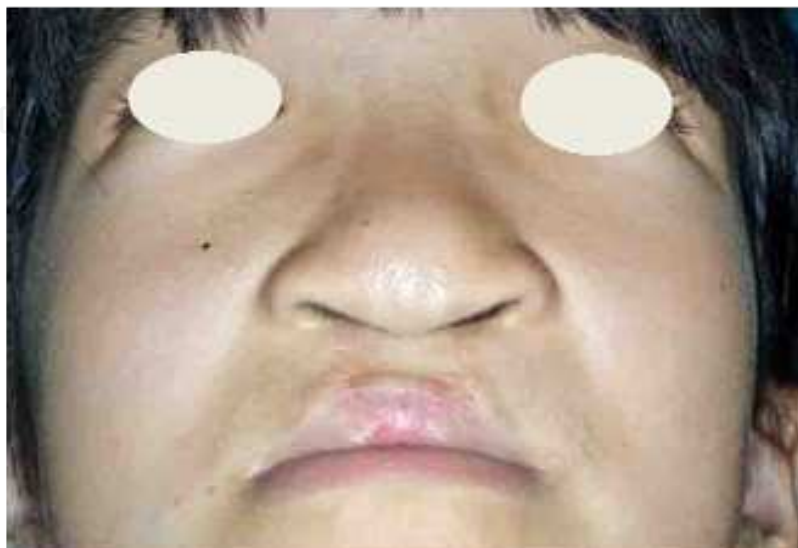

Fig. 8. Characteristics of BCL-nose deformity

The anatomical and pathological abnormality of the bilateral cleft lip-nose can also be explained by the metaphor of a house compressed by stress (Fig. 9). The basic principle is the same as that for the unilateral cleft lip-nose. To create a normal form, the center pole in the house should be extended at the center, and the roof advanced upwardly, and then the pillar on each side should be extended. Most important, the stress should be removed, which corresponds to pulling on the nasal tip due to the shortage of columellar skin.

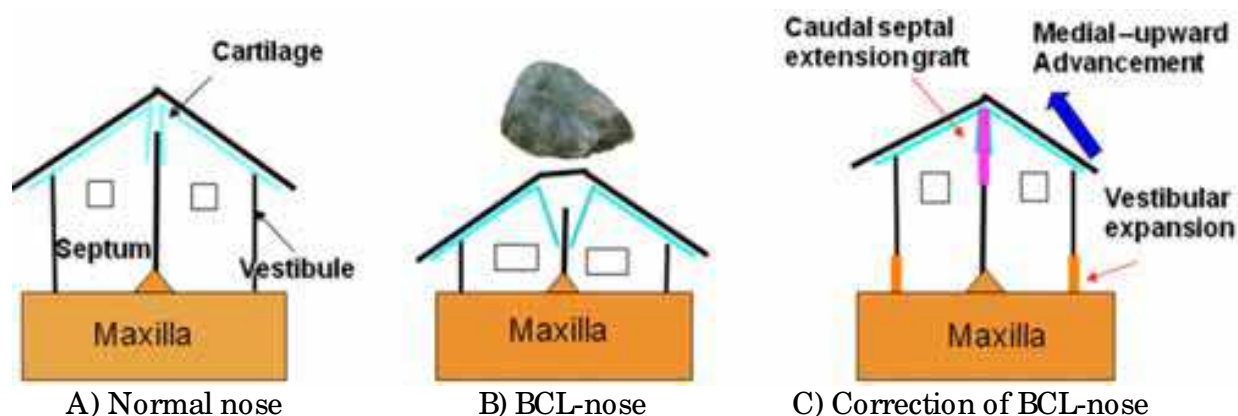


Fig. 9. Anatomical and pathologic abnormality of BCL-nose; normal nose (A), BCL-nose (B), and correction of BCL-nose (C)

The author has established a surgical strategy based on the principle that the ideal technique for secondary treatment of bilateral cleft lip-nose deformity should minimize damage to either or both the upper and lower lip tissue as shown in Table 2. This strategy also approaches each anatomical and pathological abnormality that causes the main deformities of the bilateral cleft lip-nose: short columella, flat and flared nasal tip, wide and snub nasal



alar, and flat and V-shaped nostril (Table 2). Therefore, the author's secondary correction involves open rhinoplasty, repositioning of the lower lateral cartilages, a caudal septal extension graft, medial and upward advancement of the lip and nose components, nasal vestibular expansion, and columella lengthening using a nostril rim rotation flap, if necessary.

nasal deformities	anatomical pathological anomalies	surgical procedures in the secondary correction
● short columella	<ul style="list-style-type: none"> <li>• shortage of the columellar skin</li> <li>• tightness of the subcutaneous tissue in the columella</li> </ul>	<ul style="list-style-type: none"> <li>• bilateral reverse-U incision</li> <li>• nostril rim skin rotation flap, if necessary</li> <li>• V-Y elongation of the fibrous tissue</li> </ul>
● flat and flared nasal tip	<ul style="list-style-type: none"> <li>• growth disturbance of septal cartilage</li> <li>• lateral and downward dislocation of lower lateral cartilage</li> <li>• thin skin envelope of the nasal tip</li> </ul>	<ul style="list-style-type: none"> <li>• caudal septal extension graft</li> <li>• freeing and reposition of lower lateral cartilage by overlapping on the upper lateral cartilage</li> <li>• molding up the fibrous tissue on the nasal tip</li> </ul>
● wide and snub nasal ala	<ul style="list-style-type: none"> <li>• dislocation of attachment of nasal muscle</li> </ul>	<ul style="list-style-type: none"> <li>• suprapariosteal dissection around piriform margin</li> <li>• reposition of nasal muscle by the medial and upper advancement of nasal alar component</li> </ul>
● flat and V-shaped nostril	<ul style="list-style-type: none"> <li>• webbing of the rim skin</li> <li>• shortage of nasal vestibular lining</li> <li>• disconnection of orbicular oris muscle</li> </ul>	<ul style="list-style-type: none"> <li>• bilateral reverse-U incision</li> <li>• free mucosal graft in the nasal vestibule</li> <li>• reposition of orbicularis oris muscle</li> </ul>

Table 2. Nasal deformity and treatment strategy for bilateral cleft lip-nose (*Modified from Nakamura, et al. JCrano-Maxillofac Surg 2011*)

### 3.2 Surgical procedures for correction of bilateral cleft lip-nose deformities (Fig. 10 and Fig. 11)

1. Open rhinoplasty is applied according to the bilateral reverse U incision and transcolumellar incision, but rim incisions on the bilateral side are made on the outer skin slightly above the nostril rim in order to lengthen the upper columella. The distal ends of the incision are extended into the nostril and connected to the back cut incision along the posterior edge of the nasal vestibule (Fig. 10A and Fig. 11A).

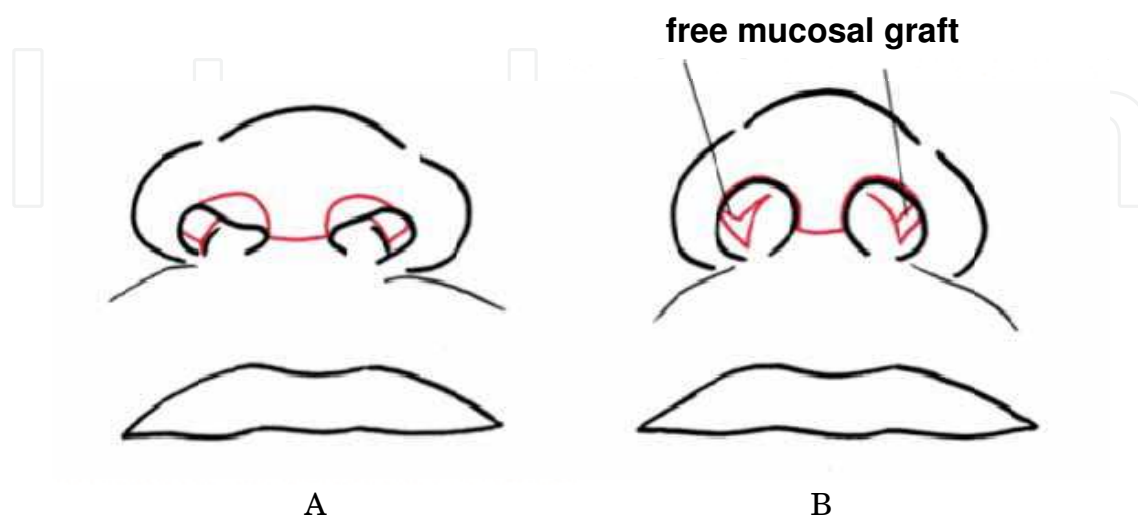


Fig. 10. Surgical procedures for correction of bilateral cleft lip-nose deformity (*Nakamura, et al. JCrano-Maxillofac Surg 2011*)

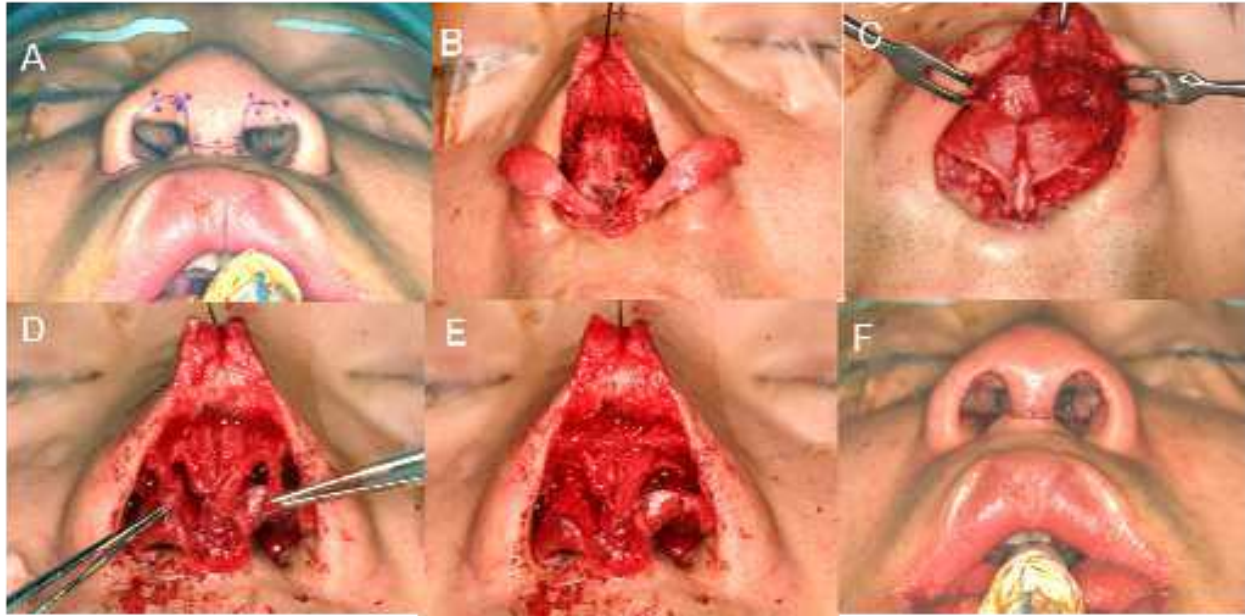


Fig. 11. Step-by-step procedures for correction of bilateral cleft lip-nose deformity (Nakamura, et al. *JCrani-Maxillofac Surg* 2011)

2. Through oral and nasal vestibular incision, supraperiosteal dissection surrounding the piriform margin and lower border of the upper lateral cartilage is performed. These dissections allow repositioning of the nasalis muscle at an adequate position on the anterior maxillary wall and facilitate 3D medial-upward-frontal advancement of the nasal alar base (Fig. 10B).
3. Reflecting the nose tip skin, the malpositioned lower lateral cartilages are exposed from both the nasal skin and lining mucosa, and the distal ends of the lateral crura are freed from the upper lateral cartilages (Fig. 11B). Cartilaginous strut is then transferred to the anterior edge of the nasal septum to produce nasal tip projection. Medial crura of the bilateral lower lateral cartilages are repositioned in a slightly overlapped position on the upper lateral cartilage and fixed to the caudal septal extension graft symmetrically by a 6-0 Nylon thread (Fig. 11C). When the growth of the nasal septum is too underdeveloped to use a cartilaginous graft, free auricular cartilage is transferred to the nasal tip.
4. To resolve the tightness of the skin envelope that often causes the collapse of the caudal septal extension graft, subcutaneous fibrous tissue is widely dissected around the nasal tip, and then elongated by the V-Y method at the columellar base. To produce the nasal tip projection, the lateral parts of the subcutaneous fibrous tissue are dissected vertically and molded on the nasal tip (Fig. 11D and E). When the nasal tip skin is redraped and skin is insufficient to cover the base of columella due to the improved nasal projection, inferiorly based small pedicle flaps (Ohishi, et al. 1996) are made from the rim skin below the incision and rotated medially into the raw area of the columellar base (Fig. 12).
5. After repositioning the lower lateral cartilage, the nasal lining tissue is advanced medially and upwardly to cover the nostril dome. The defects of lining at the nasal vestibule caused by the upward advancement of the alar component are then covered by a free mucosal graft donated from the buccal area (Fig. 10B and Fig. 12C).
6. At the end of the operation, subcutaneous and cutaneous suturing is carefully performed (Fig. 11F), and sponge tube nasal stent is applied for 1 week postoperatively.



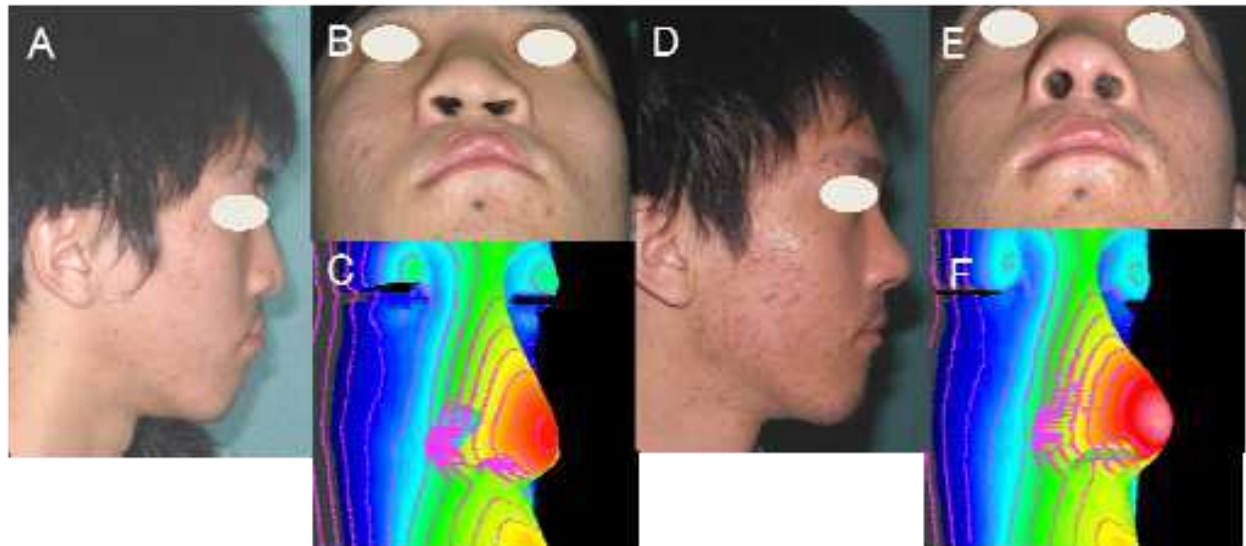


Fig. 14. Pre- and postoperative nasal views and 3D images of a male with BCLP (*Modified from Nakamura, et al. JCraniomaxillofac Surg 2011*)

The author has performed secondary treatment of bilateral cleft lip-nose using these techniques on more than 20 patients. There were no wide necroses of the skin flap, infection, airway obstruction, nor any obvious scars or deformities in the upper lip and/ or columellar base in any patient. A small area of necrosis at the tip of the nostril rim rotation flap was observed in some patients, and the most persistent postoperative problem was contraction of large free mucosal graft in the vestibular lining.

#### 4. Benefits and limitations of the author's correction for unilateral and bilateral cleft lip-nose

Regarding the treatment of unilateral cleft lip-nose, several benefits have been demonstrated from our previous data of pre- and postoperative 3D observations (Okawachi, et al. 2011). First, repositioning of the open reduction of the lower lateral cartilage with slight overlapping of the upper lateral cartilage with the caudal septal extension graft can provide a symmetric and projected nasal tip form. Second, repositioning of the septal cartilage through an oral vestibular incision recovers the nasal midline in half of the nose. Third, medial-upward advancement of the nasolabial components with vestibular expansion repositions the malattached nasalis muscles on the affected side and provides a symmetric and expanded nasal alar form.

One of the most serious problems of the nose is a deviated and depressed nasal tip. There are numerous modalities for unilateral nasal tip correction, and many previous reports mainly focused on correction of the nasal repositioning, and molding (Spira, et al. 1970, Millard, 1976a, Salyer, 1992). In the author's nose correction procedures, nasal tip correction is achieved by repositioning of the lower lateral cartilage through open rhinoplasty and a caudal septal extension graft, and these procedures are the same as those previously reported (Byrd, et al. 1997, Shih, et al. 2002, Rettinger, et al. 2002). For a caudal septal extension graft, the author favors septal cartilage donated from the lower part of the nasal septum because of its straight form and hardness, but when the growth of the nasal septum is too underdeveloped, free auricular cartilage is used. During surgery the affected lower

lateral cartilage is carefully repositioned to a symmetric position to avoid an overprojected nose by measuring the nasolabial angle during surgery. Since the nasolabial angle in Japanese adults (95-100°) is smaller than that of Caucasians (90-110°) (Ozumi, 2006), excessive projection of the nasal tip provides an undesirable nose form. Therefore, the author has prepared an original metal scale to measure the nasolabial angle during the surgery. The metal scale had sample corners with angles of 90°, 100°, 110°, 120°, and 130° (Fig. 15). When the angle was greater than the Japanese average, the position of the strut graft can be changed during surgery; consequently an undesirable overprojection of the nasal tip can be avoided.

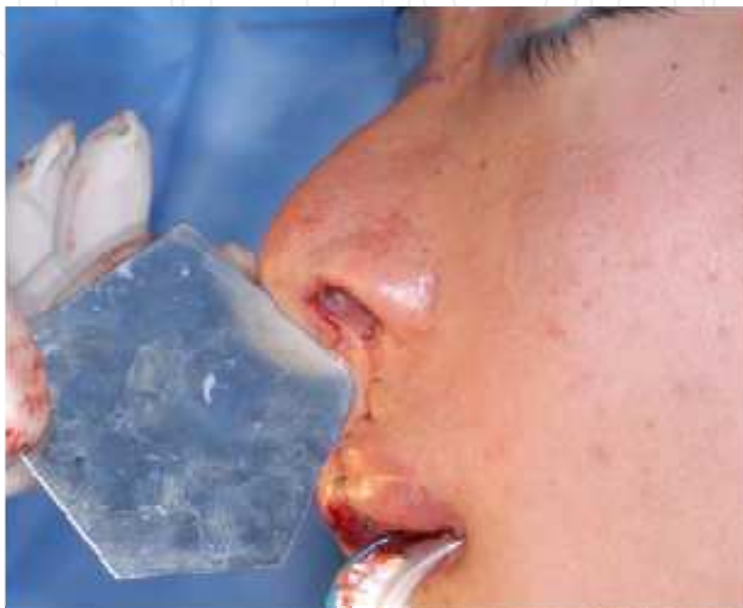

Fig. 15. Original metal scale for measuring nasolabial angle intraoperatively (Nakamura, et al. *JO Oral Maxillofac Surg* 2010)

Another conspicuous deformity of unilateral cleft lip-nose is the small and deviated nasal ala on the affected side. Even though correction of the nasal tip projection is fully achieved, asymmetric and poorly expanded nasal ala is often persistent in patients with unilateral cleft lip. It is considered that the nasal alar form is affected by not only alar cartilage but also anomalies of the surrounding tissues, such as tightness of the skin envelope, dislocated nasalis muscle, and insufficient vestibular lining. Therefore, it is essential to advance the nasal components upwardly repositioning the nasalis muscles as well as reconstruct the nasal cartilages for treatment of a small ala. Vestibular expansion also ensures prevention of postoperative collapse of the support of the lower lateral cartilage. Additionally, the improvement of the maxillary platform by bone graft is important to correct the dislocated nasal ala. The author performs secondary bone graft in the alveolar cleft and anterior surface of the piriform margin at approximately 9-11 years of age. Furthermore, when backward dislocation of the nasal alar base is remarkable at the secondary correction of nose, a veneer graft of cortical bone donated from the anterior edge of the mandibular ramus is used to mold the area around the piriform margin. However, in the author's experience, a medial and upward advancement of nasolabial components and reposition of the nasalis muscle is more effective than bone graft to correct a small nasal ala on the affected nose.

Regarding secondary treatment of bilateral cleft lip-nose, there have been a considerable number of surgical modalities reported for bilateral cleft lip-nose correction, and many of

these methods have focused on elongation of the short columella by a forked-flap technique (Millard, 1976b), Cronin's (1958) and Converse's (1957) method, and advancement of the prolabium into the columella in combination with an Abbe flap (Yonehara et al, 2008). For correction of short columellar skin, we perform bilateral reverse-U incision when the skin shortage is slight or mild, and a nostril rim skin rotation flap is combined when the columella is extremely short (Ohishi, et al, 1996). V-Y elongation of the fibrous tissue in the columellar base is also combined because tension from this often disturbs the nasal tip projection. This technique has several advantages: 1) the flap utilizes the web skin below the incision of the nostril rim; 2) there is no tissue supply needed and no additional scar on the upper lip as a result; and 3) good color matching and the natural contour at the columella-labial junction are possible and no conspicuous scar is observed on the columellar base. Furthermore, 4) the surgical procedure for columella lengthening can be selected from bilateral reverse-U incision alone or in combination with nostril rim skin flap, depending on the severity of the shortage of columellar skin (Nakamura, et al. 2011). Disadvantages of this technique include the fragility and relatively small size of the nostril skin flap. A small area of necrosis at the tip of the nostril rim rotation flap resulting in postoperative scar contraction of the flap tends to create an uneven contour of columella.

One of the challenges in augmentation rhinoplasty is the tissue contracture that has occurred prior to framework surgery, especially in bilateral cleft lip-nose. Tightness of the skin envelope often limits a space for repositioning the lower lateral cartilage and molding the soft tissues around the nasal tip area, even the wide nasal undermining is carried out. To resolve this problem, the author carefully performs nasal undermining along a single plane beyond the lower part of the upper lateral cartilage and piriform margin that enables nasal tissue advancement providing reattachment of the nasalis muscles in a higher position on the anterior maxillary wall. When these procedures are completed, sufficient enlargement of the skin envelop for nasal tip augmentation that is tolerated without inducing or attenuation of the overlying skin can be achieved.

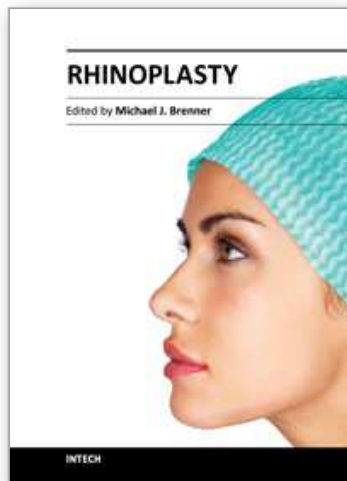
Complications resulting from our correction of bilateral cleft lip-nose deformity were not serious, but the most persistent postoperative problem was postoperative contraction of large free mucosal graft in the vestibular lining. Therefore, a sufficient supply for vestibular lining is thought to be required, and when lip repair is accompanied, it is more reliable to advance the tissue at the nostril floor upwardly to close the defects of the vestibular lining in order to avoid the risk of scar contraction of the grafted tissue. Additionally, the use of vasuclarized mucosal flaps that may be harvested from the nasal interior (e.g. from septum, turbinates, nasal floor, etc.) might be less prone to contracture than the free mucosal graft (Burget and Menick, 1989). Longer application of the nasal stent will be also useful to maintain the nasal form.

## 5. Conclusion

Finally, the author concludes that our surgical strategy for secondary correction of unilateral and bilateral cleft lip-nose is useful for providing satisfactory results, producing symmetric and projected nasal tip and ala without damaging the upper lip tissue for Asian patients. This approach may also be useful in Caucasian patients, when the columella is not too short. Repositioning of the nasalis muscle and sufficient expansion of the nasal vestibule as well as reconstruction of the nasal cartilage are important for correction of unilateral and bilateral cleft lip-nose deformity.

## 6. References

- Burget GC and Menick FJ: Nasal support and lining: The marriage of beauty and blood supply. *Plast Reconstr Surg* 84:189, 1989.
- Byrd HS, Andochick S, Copit S, Waltom KG: Septal extension grafts: A method of controlling tip projection shape. *Plast Reconstr Surg* 100:999, 1997.
- Converse JM: Corrective surgery of the nasal tip. *Laryngoscope* 67:16, 1957.
- Cronin TD: Lengthening columella by use of skin from nasal floor and alae. *Plast Reconstr Surg* 21:417, 1958.
- Grayson BH, Santiago PE, Brecht LE, Cutting CB: Presurgical nasolabial molding in infants with cleft lip and palate. *Cleft Palate-Craniofac J* 36:486, 1999.
- Millard DR Jr: The anatomy of the secondary deformity of the unilateral cleft lip nose. In: *Cleft Craft. The evolution of its surgery*. Vol. I, The Unilateral Deformities. Boston, Little, Brown and Company, 1976a, p629.
- Millard DR Jr: The anatomy of the secondary bilateral nasal deformity. In: *Cleft Craft. The evolution of its surgery*. Vol. II, The Bilateral and Rare Deformities. Boston: Little, Brown and Company 1976b, P477.
- Nakamura N, Sasaguri M, Nozoe E, Nishihara K, Hasegawa H, Nakamura S: Postoperative nasal forms after presurgical nasolabial molding followed by medial-upward advancement of the nasolabial components with vestibular expansion for children with unilateral complete cleft lip and palate. *J Oral Maxillofac Surg* 67:2222, 2009.
- Nakamura N, Okawachi T, Nishihara K, Hirahara N, Nozoe E: Surgical technique for secondary correction of unilateral cleft lip nose deformity –Clinical and three dimensional observations of pre- and postoperative nasal forms-. *J Oral Maxillofac Surg* 68:2248, 2010.
- Nakamura N: Minimally invase treatment of unilateral cleft lip nose deformity by pesurgical nasolabial molding followed by medial-upward advancement of nasolabial components (in *Japanese with English abstract*). *Jpn J Oral Maxillofac Surg* 56:618, 2010.
- Nakamura N, Sasaguri M, Okawachi T, Nishihara K, Nozoe E: Secondary correction of bilateral cleft lip nose deformity –clinical and three-dimensional observations on pre- and postoperative outcomes-. *J Cranio-Maxillofacial Surg* 39:305, 2011.
- Ohishi M, Nakamura N, Yoshikawa H, Goto K, Honda Y: A new method of columella lengthening for correction of cleft lip nose deformity (Abstract). *J Cranio-Maxillofac Surg* 24:84, 1996.
- Okawachi T, Nozoe E, Nishihara K, Nakamura N: 3-Dimensinal analyses of outcomes following secondary treatment of unilateral cleft lip nose deformity. *J Oral Maxillofac Surg* 69:322, 2011.
- Ozumi K: Aesthetic surgery of the nasal tip and columella (in *Japanese with English abstract*). *Keisei Geka* 49:663, 2006.
- Rettinger G, O'Connell M: The nasal base in cleft lip rhinoplasty. *Facial Plast Surg* 18:165, 2002.
- Salzer, KE: Early and late treatment of unilateral cleft nasal deformity. *Cleft Palate-Craniofac J* 29:556, 1992.
- Shih CW, Sykes JM: Correction of the cleft-lip nasal deformity. *Facial Plast Surg* 18:253, 2002.
- Spira M, Hardy SB, Gerow FJ: Correction of nasal deformities accompanying unilateral cleft lip. *Cleft Palate J* 7:112, 1970.
- Yonehara Y, Mori Y, Chikazu D, Saijo H, Takato T: Secondary correction of bilateral cleft lip and nasal deformity by simultaneous placement of an Abbe flap, septal cartilage graft and cantilevered iliac bone graft. *J Oral Maxillofac Surg* 66:581, 2008.



## **Rhinoplasty**

Edited by Dr. Michael Brenner

ISBN 978-953-307-849-6

Hard cover, 146 pages

**Publisher** InTech

**Published online** 09, December, 2011

**Published in print edition** December, 2011

Rhinoplasty is one of the defining procedures of plastic and reconstructive surgery. Its roots stem from early efforts in nasal reconstruction to the emergence of modern rhinoplasty. This book describes the latest clinical and research perspectives in rhinoplasty and balances structural correction with aesthetic refinement. With treatises on rhinoplasty from a diverse set of thought leaders from around the world, the collective experience of this books' authors cover cosmetic and reconstructive approaches with a wealth of proven and innovative approaches ranging from minor refinement to major reconstruction. This diversity reflects the inherent complexity of the art and science of rhinoplasty. Discussion of structural approaches is balanced by consideration of judicious resection and refinement. The overarching goal is to instill an understanding of the subtleties of nasal structure and how the natural complexities of nasal anatomy can be adapted to maximize both function and natural appearance.

### **How to reference**

In order to correctly reference this scholarly work, feel free to copy and paste the following:

Norifumi Nakamura (2011). Surgical Strategy for Secondary Correction of Unilateral and Bilateral Cleft Lip-Nose Deformities, Rhinoplasty, Dr. Michael Brenner (Ed.), ISBN: 978-953-307-849-6, InTech, Available from: <http://www.intechopen.com/books/rhinoplasty/surgical-strategy-for-secondary-correction-of-unilateral-and-bilateral-cleft-lip-nose-deformities>

**INTECH**  
open science | open minds

### **InTech Europe**

University Campus STeP Ri  
Slavka Krautzeka 83/A  
51000 Rijeka, Croatia  
Phone: +385 (51) 770 447  
Fax: +385 (51) 686 166  
[www.intechopen.com](http://www.intechopen.com)

### **InTech China**

Unit 405, Office Block, Hotel Equatorial Shanghai  
No.65, Yan An Road (West), Shanghai, 200040, China  
中国上海市延安西路65号上海国际贵都大饭店办公楼405单元  
Phone: +86-21-62489820  
Fax: +86-21-62489821



© 2011 The Author(s). Licensee IntechOpen. This is an open access article distributed under the terms of the [Creative Commons Attribution 3.0 License](#), which permits unrestricted use, distribution, and reproduction in any medium, provided the original work is properly cited.

IntechOpen

IntechOpen