

We are IntechOpen, the world's leading publisher of Open Access books Built by scientists, for scientists

4,800

Open access books available

122,000

International authors and editors

135M

Downloads

Our authors are among the

154

Countries delivered to

TOP 1%

most cited scientists

12.2%

Contributors from top 500 universities

**WEB OF SCIENCE™**Selection of our books indexed in the Book Citation Index
in Web of Science™ Core Collection (BKCI)

Interested in publishing with us?
Contact book.department@intechopen.com

Numbers displayed above are based on latest data collected.

For more information visit www.intechopen.com

Charcot Neuro-Osteoarthropathy

A.C. van Bon
*Internal Medicine, Academic Medical Center Amsterdam, Amsterdam
The Netherlands*

1. Introduction

Charcot neuro-osteoarthropathy (CN) is most often seen in patients with diabetes although it has been associated with syringomyelia, tabes dorsalis, leprosy and hereditary sensory neuropathy. It is defined by painful or relatively painless bone and joint destruction and deformity in limbs that have lost sensory innervation, it commonly develops in the mid-foot but also in the forefoot and hind foot [1]. The estimated prevalence in diabetic population is between 0,1% and 7,5% [2]. Due to the rapid severe and irreversible foot deformity, recognition of acute CN is extremely important. The clinical presentation between type 1 and type 2 diabetes is not different, but on epidemiological level the age of presentation of an acute CN is at an earlier age and longer disease duration [3].

2. Risk factors and pathophysiology

Trauma, previous ulcer, infection or surgery of the foot are predisposing factors for CN as well as neuropathy, osteopenia and renal impairment, although the exact pathogenesis is still unknown [3].

In peripheral blood monocytes isolated from Charcot patients, the osteoclast formation was significantly increased compared to diabetic patients and healthy controls. The osteoclastic resorption increased after addition of receptor activator of NFκB ligand (RANKL). So in the acute stage of CN, the osteoclast activity is increased probably by increased expression of receptor activator of NFκB ligand (RANKL) via release of proinflammatory cytokines as TNF-α [4,5]. Central role in this process of local inflammation is trauma. Patients with diabetes do not notice most traumas due to the peripheral neuropathy. Trauma will induce pro-inflammatory cytokines like TNF-α and RANKL will be expressed. Due to loss in pain perception by the distal neuropathy, the TNF-α release will persist and the RANKL pathway is persistently stimulated [6].

3. Clinical presentation

The acute stage is characterized by unilateral erythema and oedema of the affected foot. The temperature is at least 2° Celsius higher than the non-affected foot, which can be measured with an infrared skin thermometer. Mostly the mid foot is affected, followed by the fore foot and hind foot.

The differential diagnosis of a red, hot swollen foot is: severe infection (osteomyelitis) in case of a concurrent foot ulcer, cellulitis, bone fracture, gout or septic arthritis. Most difficult is to differentiate between an acute CN and osteomyelitis if a foot ulcer is present. Clinical directions in favour for osteomyelitis are a positive probe to the bone test and radiological abnormalities in relation to the ulcer, that is mostly located on pressure points like metatarsal heads or rocker-bottom. Radiological abnormalities in favour of CN are radiological abnormalities in the mid foot. The chronic not active Charcot foot is characterized with joint deformity, and or (sub) luxation of the metatarsals leading to rocker-bottom. These deformities cause elevated plantar pressure leading to abundant callus formation and an increased risk for foot ulcers.

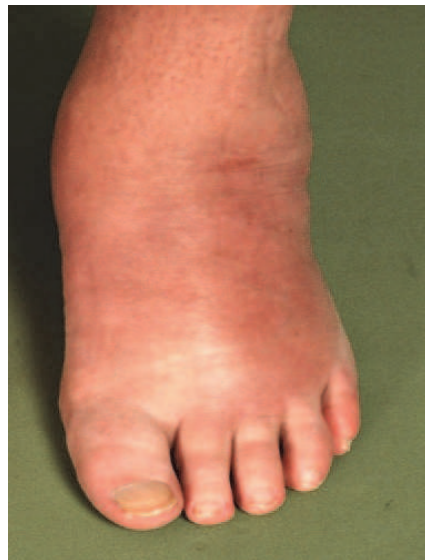

Fig. 1. Red hot swollen foot.

4. Diagnosis

Although in a very early stage of an acute CN the plain X-ray can be false negative, the initial screening tool for an acute CN is still a plain X-ray in three directions: dorsoplantar, lateral and pronated oblique). The radiological description is according to the five D's: bone density, joint distention, bony debris, joint disorganization and dislocation of the joint [2].

The density of the bone is usually normal, except in elderly or type 1 diabetic patients. Large joint effusions cause distention. The most frequent dislocation is the tarsometatarsal subluxation: Lisfranc's dislocation. Less frequent are dislocations of the talonavicular joint (Chopart) or subtalar or intertarsal joints. Sella and Barrette introduced five stage of Charcot deformity based on clinical and radiological features [7].

Stage 0: clinical stage of warm red swollen foot

Stage 1: localized osteoporosis, subchondral cysts, erosions and diastasis

Stage 2: joint subluxations

Stage 3: joint dislocations

Stage 4: sclerosis fusion

Therefore has a plain X-ray an important role in diagnosis and follow up of CN.

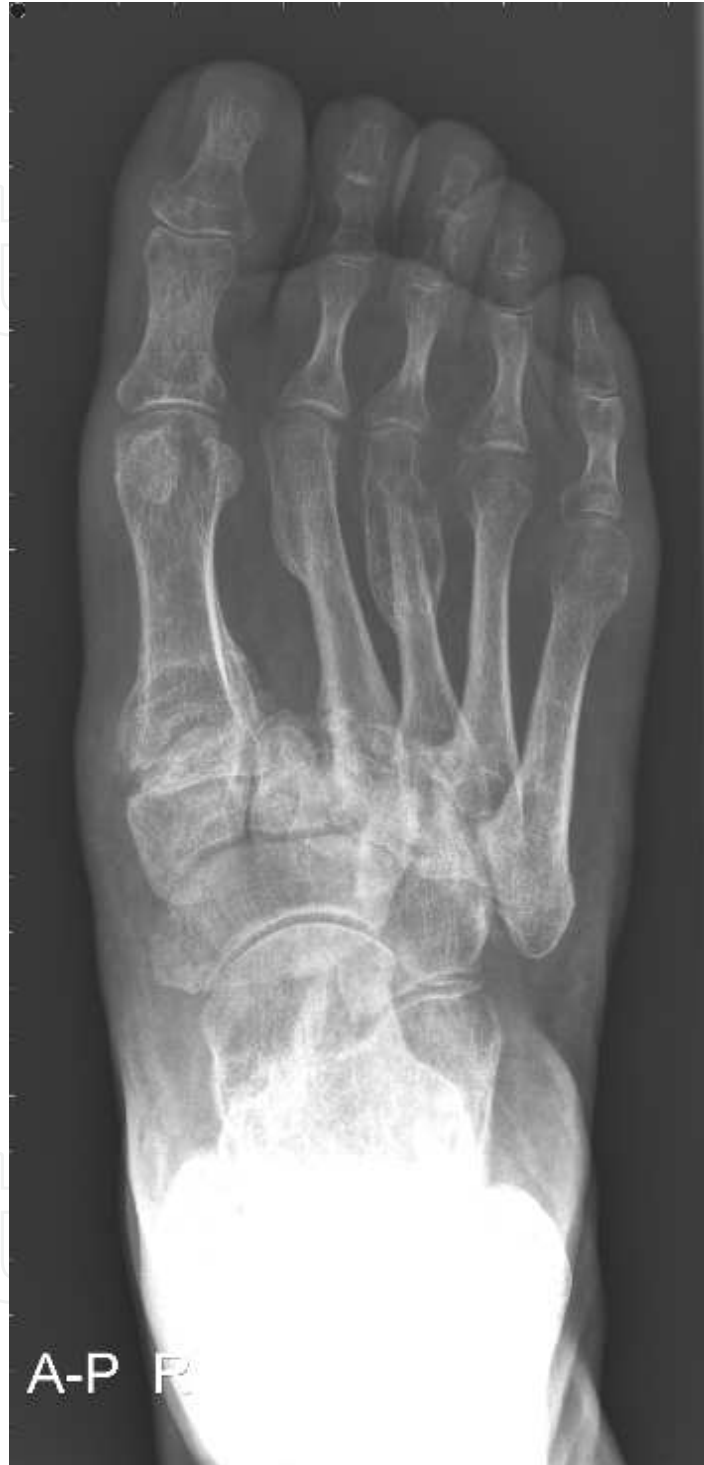

Fig. 2. Dislocation in tarsometatarsal joints: Lisfranc's dislocation

Magnetic resonance imaging (MRI) is the second step in the diagnosis the CN foot. Especially in Sella and Barrette stage 0, the early phase of the acute CN, MRI will show subchondral bone marrow oedema and or microfractures. The images should included T1 and short tau inversion recovery (STIR) or T2 fat saturated sequences. The use of computed

tomography (CT) is not well investigated. The five D's as mentioned above can be adapted to CT images. Bone scintigraphy (technetium) is the most often used nuclear method. Focal hyperperfusion and or focal bony uptake are seen on the scintigraphy but are not specific for CN. Also in osteomyelitis these characteristics are seen.

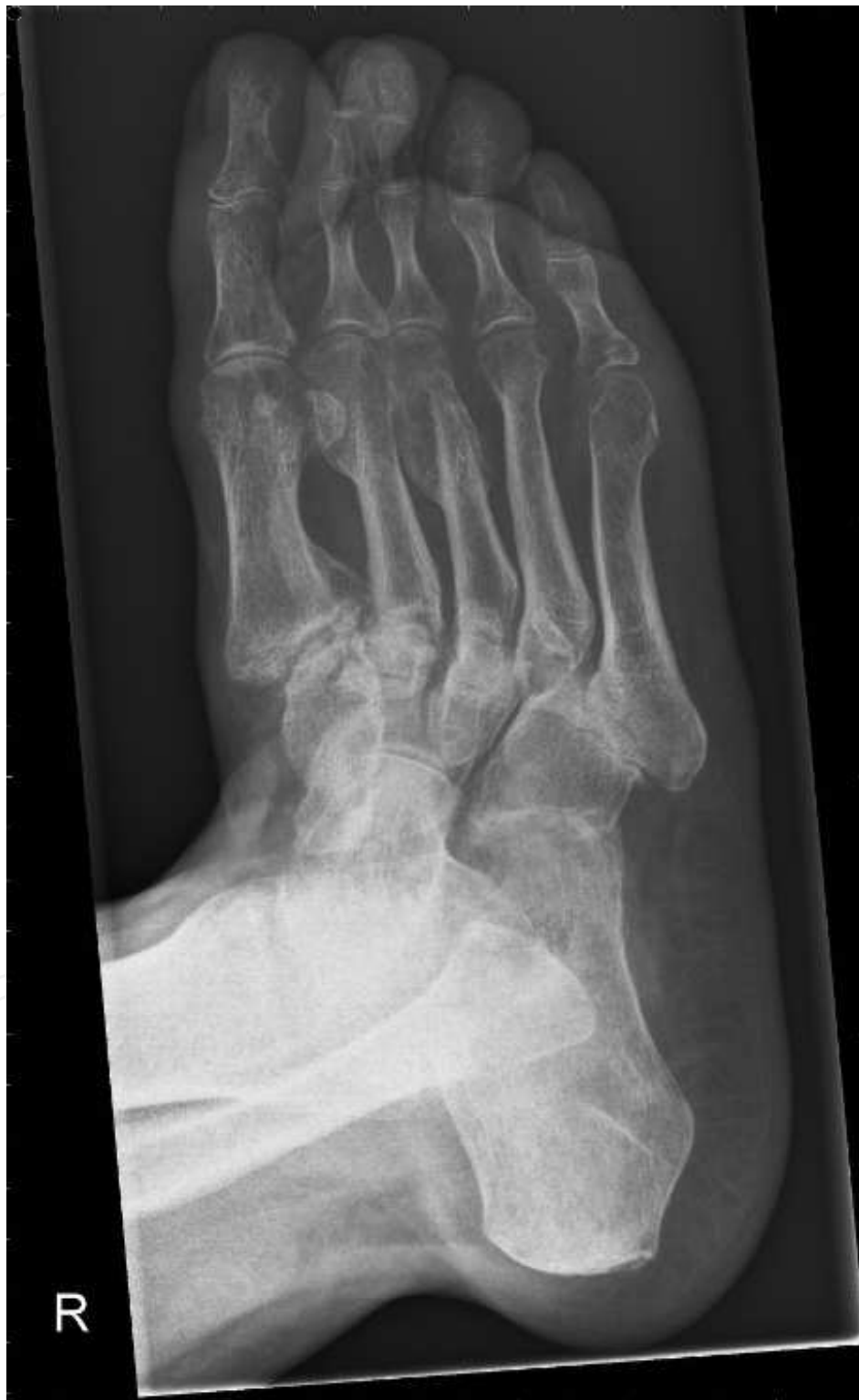

Fig. 3. Dislocation in Lisfranc, talonavicular joint (Chopart) and ankle fork

5. Treatment

Acute CN

The current standard treatment is off-loading the affected foot with a total contact cast or a prefabricated walking cast. Off-loading will prevent extensive bone damage, which can lead to sub-luxation and dislocation leading to severe foot deformity. Off-loading is continued until clinical signs of activity (temperature differential) are resolved and there is no longer evidence on X-ray of continuing bone destruction. Median time of off-loading treatment is 9 (7-12) months [8].

Chronic CN

If the CN is inactive, the patients have to be rehabilitated. This process has to be gradually to prevent recurrence for CN leading to further bone destruction. Patients need orthopaedic shoes during this process and the walking distance is extended slowly, first with two crutches followed with one and finally without.

Operative orthopaedic treatment is indicated for chronic recurrent ulcers on pressure points like rocker-bottom or joint instability. Operative procedures in acute CN are strongly not recommended: the bone structure is too instable for internal or external fixation and every orthopaedic intervention is a risk factor for increase in activity of CN. Osteotomy is possible in inactive CN in combination with bony prominence that cause recurrent ulcers. Obvious, arterial insufficiency is ruled out or has been treated before elective surgery.

6. Additional treatment with bisphosphonates?

To shorten the time of CN activity, intervention at the level of osteoclasts and or osteoblasts might be useful. Because bisphosphonates induce osteoclast apoptosis [9], several trials with bisphosphonates were performed. In the acute setting of CN the use of oral alendronate 70 mg once weekly on top of standard care (total contact cast immobilisation) was studied in a small double blind placebo controlled trial [10]. After 6 months, a reduction in bone turnover markers was demonstrated, but not in skin temperature. In another double blind placebo controlled trial studied the additional effect of one single infusion of intravenous pamidronate in patients with acute CN [11]. The intervention group had a faster fall in temperature of the affected foot at four weeks, a greater reduction in bone turnover markers and significant reduction in Charcot related symptoms during the study. In one not-randomized study confirmed the effect of pamidronate on temperature reduction and fall in bone turnover markers in acute CN [12]. However, all three studies did not report reduction in immobilisation time, as a clinical marker for the activity of CN.

Risk of bisphosphonates

Minor side effects of oral bisphosphonates are gastrointestinal symptoms, hypocalcaemia, skin reactions, acute phase reactions like malaise or fever or skin. These side effects have biological plausibility and causality has been proven.

No causality is proven for some severe adverse effects of bisphosphonates: osteonecrosis of jaw, atypical hip fractures, possible oesophagus cancer, atrial fibrillation and

musculoskeletal pain. But clinical correlations were seen and reported in literature, for example osteonecrosis of the jaw [13]. Risk factors for developing osteonecrosis of the jaw are intravenous administration of bisphosphonates, history of inflammatory dental disease, glucocorticoids use and long duration of bisphosphonates use [14]. Of note, all severe events were seen if the bisphosphonates were used for several years. Furthermore, the reported data are conflicting and sometimes incomplete.

In conclusion, there is no indication for bisphosphonates in the treatment of an acute CN if no data are known about reduction in immobilisation time.

7. Possible candidates for additional treatment in acute CN

Strontium ranelate

Another potential intervention is strontium ranelate that is successfully used in the treatment of osteoporosis [15-17]. This drug has a direct inhibitive action on both osteoclast activity and differentiation. In addition, strontium ranelate stimulates the osteoprogenitor cells and collagen in osteoblasts [18,19]. Recent evidence has shown that strontium ranelate induced osteoprotegerin- (OPG) mRNA expression and suppressed RANKL mRNA in human osteoblasts [20]. Furthermore strontium ranelate induced osteoblast replication and differentiation [20]. Strontium ranelate is to date it has not yet been used as treatment in the acute stage of CN.

Denosumab

Denosumab is a fully human monoclonal antibody to the receptor activator of nuclear factor- κ B ligand (RANKL) that blocks its binding to RANK, inhibiting the development and activity of osteoclasts, decreasing bone resorption, and increasing bone density. Given its unique actions, denosumab may be useful in the treatment of osteoporosis and bone metastatic disease. Some clinical trials have been performed and show favourable results [21,22]. In acute CN, no studies have been performed so far.

8. Summary

Charcot neuro-osteoarthropathy is most often seen in patients with diabetes and is characterized as red, hot swollen foot. In the presence of a foot ulcer, the differential diagnosis with osteomyelitis is very difficult. In the early stage of acute CN, X ray can be false negative in contrast to MRI or CT. The latter investigations can be useful to differentiate between osteomyelitis and acute CN. The treatment of acute CN is offloading in plaster cast until the active CN is clinical and radiological inactive.

9. References


- [1] Edmonds ME. Progress in care of the diabetic foot. *Lancet* 1999; 354(9175): 270-272.
- [2] Schoots IG, Slim FJ, Busch-Westbroek TE, Maas M. Neuro-osteoarthropathy of the foot-radiologist: friend or foe? *Semin Musculoskelet Radiol* 2010; 14(3): 365-376.
- [3] Petrova NL, Edmonds ME. Charcot neuro-osteoarthropathy-current standards. *Diabetes Metab Res Rev* 2008; 24 Suppl 1: S58-S61.

- [4] Mabileau G, Petrova NL, Edmonds ME, Sabokbar A. Increased osteoclastic activity in acute Charcot's osteoarthropathy: the role of receptor activator of nuclear factor-kappaB ligand. *Diabetologia* 2008; 51(6): 1035-1040.
- [5] Piaggese A, arcocci C, olia F, i GregorioS, accetti F, avalesi R. Markers for charcot's neurogenic osteoarthropathy in diabetic patients. *Diabetes* 2000; 49(Suppl 1): A32.
- [6] Jeffcoate WJ. Charcot neuro-osteoarthropathy. *Diabetes Metab Res Rev* 2008; 24 Suppl 1: S62-S65.
- [7] Sella EJ, Barrette C. Staging of Charcot neuroarthropathy along the medial column of the foot in the diabetic patient. *J Foot Ankle Surg* 1999; 38(1): 34-40.
- [8] Bates M, Petrova NL, Edmonds ME. How long does it take to progress from cast to shoes in the management of Charcot osteoarthropathy. *Diabetic Medicine* 23[Suppl 2], 27 -A100. 2006.
- [9] Reszka AA, Rodan GA. Mechanism of action of bisphosphonates. *Curr Osteoporos Rep* 2003; 1(2): 45-52.
- [10] Pitocco D, Ruotolo V, Caputo S, Mancini L, Collina CM, Manto A *et al.* Six-month treatment with alendronate in acute Charcot neuroarthropathy: a randomized controlled trial. *Diabetes Care* 2005; 28(5): 1214-1215.
- [11] Jude EB, Selby PL, Burgess J, Lilleystone P, Mawer EB, Page SR *et al.* Bisphosphonates in the treatment of Charcot neuroarthropathy: a double-blind randomised controlled trial. *Diabetologia* 2001; 44(11): 2032-2037.
- [12] Anderson JJ, Woelffer KE, Holtzman JJ, Jacobs AM. Bisphosphonates for the treatment of Charcot neuroarthropathy. *J Foot Ankle Surg* 2004; 43(5): 285-289.
- [13] Lewiecki EM. Safety of long-term bisphosphonate therapy for the management of osteoporosis. *Drugs* 2011; 71(6): 791-814.
- [14] Ruggiero SL, Mehrotra B. Bisphosphonate-related osteonecrosis of the jaw: diagnosis, prevention, and management. *Annu Rev Med* 2009; 60: 85-96.
- [15] Meunier *et al.* Effects of long-term strontium ranelate treatment on vertebral fracture risk in postmenopausal women with osteoporosis. *Osteoporos Int* 2009; 20: 1663-1673
- [16] Reginster J *et al.* Effects of long-term strontium ranelate treatment on the risk of nonvertebral and vertebral fractures in postmenopausal osteoporosis.. *Arthritis and Rheumatism* 2008; 58: 1687-1695
- [17] O'Donnell S *et al.* Strontium ranelate for preventing and treating postmenopausal osteoporosis (review). *Cochrane database of systematic reviews* 2006; 4
- [18] Hamdy NAT. Strontium ranelate improves bone microarchitecture in osteoporosis. *Rheumatology* 2009; 48: iv9-iv13
- [19] Brennan TC, Rybchyn MS, Green W, Atwa S, Conigrave AD, Mason RS. Osteoblasts play key role in the mechanisms of action of strontium ranelate. *BJP* 2009; 157: 1291-1300
- [20] Brennan *et al.* Osteoblasts play key role in the mechanisms of action of strontium ranelate. *British Journal of pharmacology* 2009; 157: 1291-1300
- [21] SR. Cummings, J San Martin, MR. McClung, ES. Siris, R Eastell, *et al.* FREEDOM Trial Denosumab for Prevention of Fractures in Postmenopausal Women with Osteoporosis. *N Engl J Med* 2009; 361:756-765

- [22] Smith MR, Egerdie B, Hernandez Toriz N, Feldman R, Tannela TL et al HALT Prostate study group. Denosumab in men receiving androgen-deprivation therapy for prostate cancer. *N Engl J Med* 2009; 361: 745-55

IntechOpen

IntechOpen



Global Perspective on Diabetic Foot Ulcerations

Edited by Dr. Thanh Dinh

ISBN 978-953-307-727-7

Hard cover, 278 pages

Publisher InTech

Published online 09, December, 2011

Published in print edition December, 2011

Over the last decade, it is becoming increasingly clear that diabetes mellitus is a global epidemic. The influence of diabetes is most readily apparent in its manifestation in foot complications across cultures and continents. In this unique collaboration of global specialists, we examine the explosion of foot disease in locations that must quickly grapple with both mobilizing medical expertise and shaping public policy to best prevent and treat these serious complications. In other areas of the world where diabetic foot complications have unfortunately been all too common, diagnostic testing and advanced treatments have been developed in response. The bulk of this book is devoted to examining the newest developments in basic and clinical research on the diabetic foot. It is hoped that as our understanding of the pathophysiologic process expands, the devastating impact of diabetic foot complications can be minimized on a global scale.

How to reference

In order to correctly reference this scholarly work, feel free to copy and paste the following:

A.C. van Bon (2011). Charcot Neuro-Osteoarthropathy, Global Perspective on Diabetic Foot Ulcerations, Dr. Thanh Dinh (Ed.), ISBN: 978-953-307-727-7, InTech, Available from: <http://www.intechopen.com/books/global-perspective-on-diabetic-foot-ulcerations/charcot-neuro-osteoarthritis>

INTECH
open science | open minds

InTech Europe

University Campus STeP Ri
Slavka Krautzeka 83/A
51000 Rijeka, Croatia
Phone: +385 (51) 770 447
Fax: +385 (51) 686 166
www.intechopen.com

InTech China

Unit 405, Office Block, Hotel Equatorial Shanghai
No.65, Yan An Road (West), Shanghai, 200040, China
中国上海市延安西路65号上海国际贵都大饭店办公楼405单元
Phone: +86-21-62489820
Fax: +86-21-62489821

© 2011 The Author(s). Licensee IntechOpen. This is an open access article distributed under the terms of the [Creative Commons Attribution 3.0 License](#), which permits unrestricted use, distribution, and reproduction in any medium, provided the original work is properly cited.

IntechOpen

IntechOpen