

We are IntechOpen, the world's leading publisher of Open Access books Built by scientists, for scientists

4,800

Open access books available

122,000

International authors and editors

135M

Downloads

Our authors are among the

154

Countries delivered to

TOP 1%

most cited scientists

12.2%

Contributors from top 500 universities



WEB OF SCIENCE™

Selection of our books indexed in the Book Citation Index
in Web of Science™ Core Collection (BKCI)

Interested in publishing with us?
Contact book.department@intechopen.com

Numbers displayed above are based on latest data collected.

For more information visit www.intechopen.com



Screening of Foot Inflammation in Diabetic Patients by Non-Invasive Imaging Modalities

Takashi Nagase¹, Hiromi Sanada¹, Makoto Oe¹,
Kimie Takehara¹, Kaoru Nishide² and Takashi Kadowaki³

¹*Department of Gerontological Nursing/Wound Care Management
Graduate School of Medicine, The University of Tokyo*

²*Department of Nursing, St. Marianna Medical University Hospital*

³*Department of Metabolic Diseases,
Graduate School of Medicine, The University of Tokyo
Japan*

1. Introduction

Diabetic foot is defined as infection, ulceration and/or destruction of deep tissues associated with neurological abnormalities and various degrees of peripheral vascular disease in the lower limb of the patients with diabetes mellitus (DM) (the International Working Group on the Diabetic Foot, 1999). Foot disorders are among the most serious and costly complications of DM (Apelqvist et al., 2008). When uncontrolled, diabetic foot can result in ulcer formation and subsequent amputation of the lower limb. Foot ulcers occur in 12 to 25 % of DM patients, and precede 84 % of all nontraumatic amputations in the growing DM population (Brem et al., 2006). It is thus quite urgently needed to prevent diabetic ulcer formation in the “at risk” foot by multi-disciplinary team approach (Apelqvist et al., 2008).

How can we identify “at risk” foot in the DM patients? According to the guidelines by the International Working Group of the Diabetic Foot, “at risk” foot should be identified by inspection and examination according to symptoms such as non-sensory or sensory neuropathy, foot deformities, bony prominences, signs of peripheral ischemia, previous ulcer or amputation (Apelqvist et al., 2008). The patients are categorized according to the risk classification system. Based mainly on Lavery et al. (Lavery et al., 1998), these categories include the following: no sensory neuropathy (category 0); sensory neuropathy (category 1); sensory neuropathy and signs of peripheral vascular disease (PAD) and/or foot deformities (category 2); and previous ulcer (category 3) (the International Working Group on the Diabetic Foot, 1999). Clinical effectiveness of this risk classification system was indeed substantiated by Peters et al. (Peters & Lavery, 2001), where ulceration occurred in 5.1, 14.3, 18.8, and 55.8% of the patients in categories 0, 1, 2, and 3, respectively during three years of follow-up. More recently, the International Working Group on the Diabetic Foot revised the risk classification system more focusing on the associated PAD (Lavery et al., 2008). However, we consider that there should be some limitations in these approaches of risk assessment only based on conventional clinical examination. Although the report by Peter et al. (Peters & Lavery, 2001) showed clinical effectiveness of these approaches, occurrence rate

of ulcers was unacceptably high in the higher categories. This fact may indicate necessity of more advanced approaches to detect the pre-ulceration status in the “at risk” foot in the more timely manner.

We consider that the screening of latent inflammation should be a key strategy for the assessment of pre-ulceration of the at risk foot. It should be kept in mind that DM patients may occasionally be insensitive to inflammatory pain in minor traumas caused by ill-fitting shoes, walking barefoot or callus formation, because of their sensory disturbances. If the patients continue walking, the overlooked inflammation may result in subsequent ulceration (Apelqvist et al., 2000; Apelqvist et al., 2008). Temperature elevation and edema should be accompanied by such latent inflammation. Recent advances of non-invasive imaging modalities such as thermography and ultrasonography may provide us with visual information of tissue temperature changes and edema associated with inflammation.

In our previous publications, we used thermography and ultrasonography for assessing wound status of pressure ulcers, confirming their clinical versatility for detecting inflammation. Delayed healing of pressure ulcers due to latent inflammation could be prospectively evaluated by high temperature of wound bed visualized by thermography (Nakagami et al., 2010). Also, the subcutaneous tissue damages such as edema or the discontinuous fascia could be clearly visualized by ultrasonography in the patients with pressure ulcers of the deep tissue injury type (Aoi et al., 2009; Nagase et al., 2007; Yabunaka et al., 2009).

Based on these experiences on pressure ulcers, we have introduced use of thermography and ultrasonography into the management of diabetic foot. In this chapter, we first mention variation of thermographic finding of the diabetic foot according to our own new classification system (Nagase et al., 2011). Furthermore, we describe our clinical research on the thermographic and ultrasonographic screening for the latent inflammation in the diabetic foot callus (Nishide et al., 2009).

2. Variations of thermographic morphological patterns in diabetic foot

2.1 Thermometry of diabetic foot: An overview

Thermometry of the diabetic foot has been established as an effective way for detecting inflammation and for assessing risks of ulceration (Bharara et al., 2006). Acute increase of the plantar temperature is regarded as a predisposing sign for pre-ulcer inflammation, requiring urgent intervention. For example, Armstrong et al. (Armstrong et al., 2007) and Lavery et al. (Lavery et al., 2004; Lavery et al., 2007) showed that foot temperature monitoring can reduce the ulceration rate in the “at risk” foot (category 2 or 3). In their randomized controlled studies, the DM patients in the intervention groups were guided to monitor temperatures of the several landmark points of their feet at home using a digital handheld thermometer. When the skin temperature was elevated compared with the contralateral side ($>2.2^{\circ}\text{C}$), the patients were instructed to contact the research nurses and to reduce their activities until the temperatures normalized. Rates of ulceration were significantly reduced in the intervention groups than in the non-intervention control groups.

It has been already known that chronic temperature elevation may be observed in the neuropathic diabetic feet, mainly due to increased arteriovenous (A-V) shunt flow (Brem et

al., 2006; Chan et al., 1991; Flynn & Tooke, 1995; Sun et al., 2005; Sun et al., 2008). Chronic temperature decrease implies association of PAD (Benbow et al., 1994; Brem et al., 2006). Unstable skin temperature due to impairment of thermoregulation is also noted in the neuropathic diabetic feet (Kang et al., 2003; Rutkove et al., 2005). Bharara et al. (Bharara et al., 2008a, b) demonstrated that foot temperature recovery after cold or warm immersion showed different trends between in the DM patients with and without neuropathy.

2.2 Use of thermography for assessing diabetic foot: Unsolved problems

Thermography is regarded as an imaging modality of thermometry. Thermography can estimate circulation and vascular patency by visualizing temperature distribution (Bharara et al., 2006; Nagase et al., 1996), and thus, it may be a potentially ideal tool for assessing inflammation and vascular stenosis of diabetic foot. We are using infrared (IR) thermography (Nagase et al., 2011; Nishide et al., 2009), which were also used in some of the abovementioned studies of diabetic foot thermometry (Sun et al., 2005; Sun et al., 2008; Sun et al., 2006) and in the more recent report evaluating healing tendency of the diabetic foot ulcer (Bharara et al., 2010). Liquid crystal (LC) thermography was conventionally used in the papers published in 1980's and 90's (Benbow et al., 1994; Chan et al., 1991; Stess et al., 1986). Interestingly, LC thermography has been now reappraised by many recent researchers (Bharara et al., 2008a, b; Frykberg et al., 2009; Roback et al., 2009). IR thermography can visualize thermal patterns without direct contact to the skin or wounds. LC thermography requires direct contact, and thus IR thermography may be better for detecting temperature of the non-contact area (such as the medial arch and the dorsal part of the feet) or the area colonized by pathogens such as the skin with tinea pedis or the infected wounds (Nagase et al., 2011). On the other hand, LC thermography has advantages because it is inexpensive, easy to use even in home-care setting, and appropriate for assessment of plantar temperatures under the influence of load (Bharara et al., 2008a, b; Frykberg et al., 2009). LC thermography costs approximately \$ 1,800, whereas IR thermography costs approximately \$ 25,000, and this fact is one of the factors at present which might prohibit mass production of IR thermography for patient use at home.

In either type, we consider that thermography has an outstanding advantage compared with the conventional pinpoint thermometry: thermography enables visualization of morphological patterns of temperature. A whole image of the plantar temperature distribution can be obtained only by thermography. However, this advantage has not been fully appreciated in most of the previous studies. Temperatures of several anatomical landmark points or areas were measured and analyzed in such papers. For example, Sun et al. (Sun et al., 2005; Sun et al., 2006) indicated that the temperature of the medial plantar arch was the highest and that of the lesser toes was the lowest in the normal and in some of the DM population. We consider, however, that this type of measurement can be accomplished also by the conventional thermometry, as Armstrong et al. (Armstrong et al., 2007) and Lavery et al. (Lavery et al., 2004; Lavery et al., 2007) did in the clinical settings.

Morphological thermographic patterns of the plantar temperature were previously described in a very limited number of articles. Using LC thermography, Chan et al. (Chan et al., 1991) designated temperature distribution in normal subjects as a "symmetrical butterfly pattern" in which the medial arch showed the highest temperature as reported by Sun et al. (Sun et al., 2005; Sun et al., 2006). However, Stess et al. (Stess et al., 1986) indicated that such

a typical symmetrical pattern was observed in only nine out of the 16 normal subjects (56%). They described other atypical thermographic patterns, including those of DM patients, simply as "mottling and discrete areas of color variation." Wang et al. (Wang et al., 2004) also mentioned possible variation of thermographic patterns in the normal subjects, by showing data of the only three healthy volunteers..

We consider that there may be three reasons why interpretation of the plantar thermographic patterns has been so difficult and insufficient. (1) There is an absolute lack of the information of thermographic patterns of the normal subjects. Any interpretation is impossible without a normal control as a reference. (2) It is quite reasonable to consider that the plantar thermographic patterns can be affected by the vascular anatomy and circulatory status of the foot. No previous reports mention this point. (3) There has been no classification system of the plantar thermographic patterns, which enables more detailed description of the individual variations.

2.3 Possible patterns of plantar thermography and the vascular anatomy: A concept of "angiosome"

We have concluded that the new classification system of the thermographic patterns should be established based on the vascular anatomy of the foot. However, the vascular anatomy of the foot is very complicated with considerable individual anomalies (Adachi, 1928; Attinger et al., 1997; Yamada et al., 1993). The lower limb is supplied by the three main arteries: the anterior tibial artery, the posterior tibial artery, and the peroneal artery. The dorsal foot is supplied by the dorsalis pedis artery, which is derived from the anterior tibial artery. The plantar forefoot area is supplied by the two branches of the posterior tibial artery, the medial and lateral plantar arteries. These two arteries are connected to each other by the superficial and deep plantar arches. The medial plantar artery has the superficial and deep branches. The dorsalis pedis artery descends near the first metatarsal bone, making anastomosis with the deep plantar arch. The heel is supplied by the medial and lateral calcaneal arteries, derived from the posterior tibial artery and the peroneal artery, respectively. The concomitant veins run together with the main arteries. There are also the superficial subcutaneous venous networks. How and to what extent should this complex vascular anatomy be reflected to our novel thermographic classification?

A key word is "angiosome." What is angiosome? Angiosome is a concept in the field of plastic surgery, and is defined by Taylor and Palmer (Taylor & Palmer, 1987) as the "composite unit of skin and underlying deep tissue, supplied by a source artery." This "unit" can be considered as a possible tissue flap which can be transplanted to other places of the body by maintaining the vessel circulation, for example, through the microscopic anastomoses of the artery and vein in case of "free" flaps (Harii et al., 1974). It is noteworthy that the neighboring angiosomes are linked by "choke vessels", which act as a safety valve, if the main source artery is damaged (Taylor & Palmer, 1987).

Attinger et al. (Attinger et al., 2006) proposed four angiosomes in the plantar area: the medial plantar artery (MPA) angiosome, the lateral plantar artery (LPA) angiosome, the medial calcaneal artery (MCA) angiosome and the lateral calcaneal artery (LCA) angiosome (Fig.1A). The dorsal foot is composed of the single dorsalis pedis artery (DPA) angiosome. Therefore, it is quite reasonable to consider that the abnormal "mottling" patterns in DM patients are possibly caused by vessel stenosis or A-V shunts, and thus may well correspond to the territories of the plantar angiosomes.

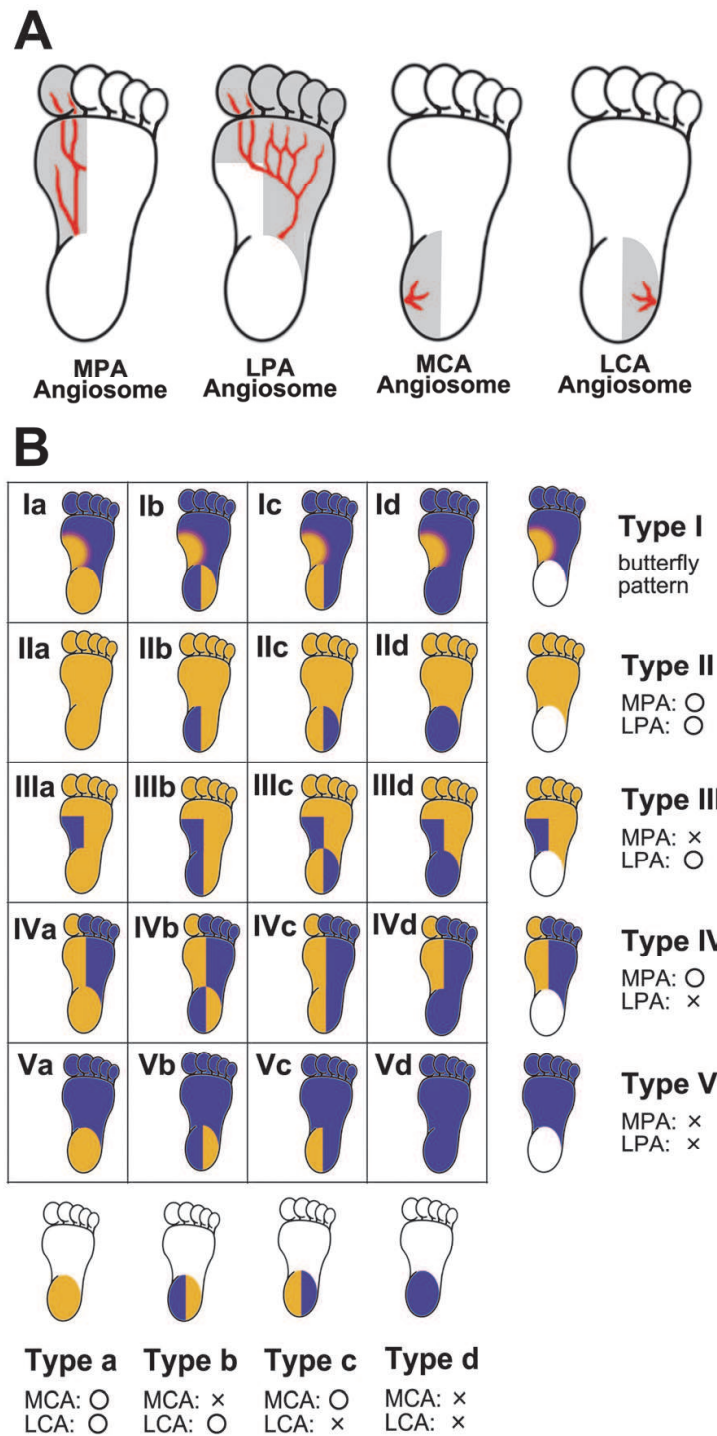


Fig. 1. (A) Four plantar angiosomes by Attinger et al. (Attinger et al., 2006). MPA: medial plantar artery, LPA: lateral plantar artery, MCA: medial calcaneal artery, LCA: lateral calcaneal artery. (B) Conceptual classification of the thermographic patterns with 20 different categories. Orange and blue colors indicate higher and lower temperatures, respectively. Reprinted from Journal of Plastic, Reconstructive & Aesthetic Surgery, Vol. 64 No.7. Nagase, T. et al. Variations of plantar thermographic patterns in normal controls and non-ulcer diabetic patients: Novel classification using angiosome concept. p.860-866, 2011. with permission from Elsevier.

2.4 Development of the novel classification system of the plantar thermographic patterns based on the vascular anatomy

According to the angiosome territories, we developed a novel classification of 20 different categories (Nagase et al., 2011) (Fig.1B). We separated the whole plantar area into the distal forefoot and the heel to build up the conceptual framework of the classification of the thermographic patterns.

We distinguished five different patterns in the forefoot. The normal “butterfly pattern” (Chan et al., 1991; Stess et al., 1986) was designated as Type I. The other four patterns were conceptually defined according to the possible viabilities of the MPA and LPA angiosomes. Type II represents the condition that both the MPA and LPA angiosomes are intact. Type III represents the condition when the MPA is occluded and only the LPA angiosome is intact. (In this type, the MPA angiosome may be nourished by “choke vessels” from the adjacent angiosomes, and, thus, possibly shows lower temperature.) Type IV represents the condition when the LPA is occluded and only the MPA angiosome is intact. Type V represents that both the MPA and LPA are occluded. It is noteworthy that the MPA and LPA angiosomes are overlapped in the hallux, and the lower temperature in the hallux may be observed only in type I and V. We similarly distinguished four different patterns in the heel area. Type a represents the condition that both the MCA and LCA angiosomes are intact. Type b represents that MCA is occluded. Type c represents that LCA is occluded. Type d represents that both the MCA and LCA are occluded. We finally crossed the five forefoot patterns and the four heel patterns, obtaining the conceptual classification with the 20 different categories from Ia to Vd (Nagase et al., 2011)(Fig. 1B).

32 healthy volunteers (36.8 ± 11.8 years old) and 129 diabetic patients (67.2 ± 10.5 years old) were included in our survey as the control group and as the DM group, respectively (Nagase et al., 2011). The DM group participants were recruited from the patients at the Diabetic Foot Outpatient Clinic at the University of Tokyo Hospital between November 2008 and October 2009. Thermographic images of the bilateral feet were taken from the all participants. At the time of temperature measurement by thermography, the subjects were guided to keep resting supine position without shoes and socks for 15 minutes before measurement as equilibration (Nagase et al., 2011; Nishide et al., 2009). The ankle brachial index (ABI) and toe brachial index (TBI) were also measured in the DM group. We used an IR thermography Thermotracer (TH5108ME, NEC Avio Infrared Technology Co.Ltd.Tokyo, Japan) for temperature analysis, and Form pulse-wave velocity/ankle brachial index (PWV/ABI) BP-203RPEII (Omron Colin Co.Ltd., Tokyo, Japan) for measuring ABI and TBI.

Each plantar thermographic image was allocated to the 20 different categories as described above. If the images did not correspond to any of the 20 categories, they were designated as “atypical.” Thermography of the dorsal feet and digital photographs of the skin surfaces were also obtained from some cases with “atypical” thermographic patterns.

2.5 Variations of plantar thermographic patterns in the normal controls

Of 64 feet from the 32 normal controls, 48 feet (75%) were allocated to the seven categories from the 20 categories (Nagase et al., 2011)(Fig.2A). Notably, the typical “butterfly pattern” (Id) was observed in 30 feet (46.9%). The next frequent category was IIa (13 feet, 20.3%). The other five categories were occupied by only one foot for each.

We can consider that the categories Id and Ila may be the normal thermographic patterns. We also consider that these data from the normal subjects should be regarded as a reference for evaluating thermographic patterns of DM population. As stated before, Stess et al. (Stess et al., 1986) described that the “butterfly patterns” was observed in about a half of the normal subjects in their study with the smaller sample size. We confirmed their findings in our larger study. In other words, the normal patterns (Id and Ila) were observed in only about 70% of the normal subjects in our study. This fact should be kept in mind when we interpret the data of plantar thermometry in the normal subjects and in the DM patients.

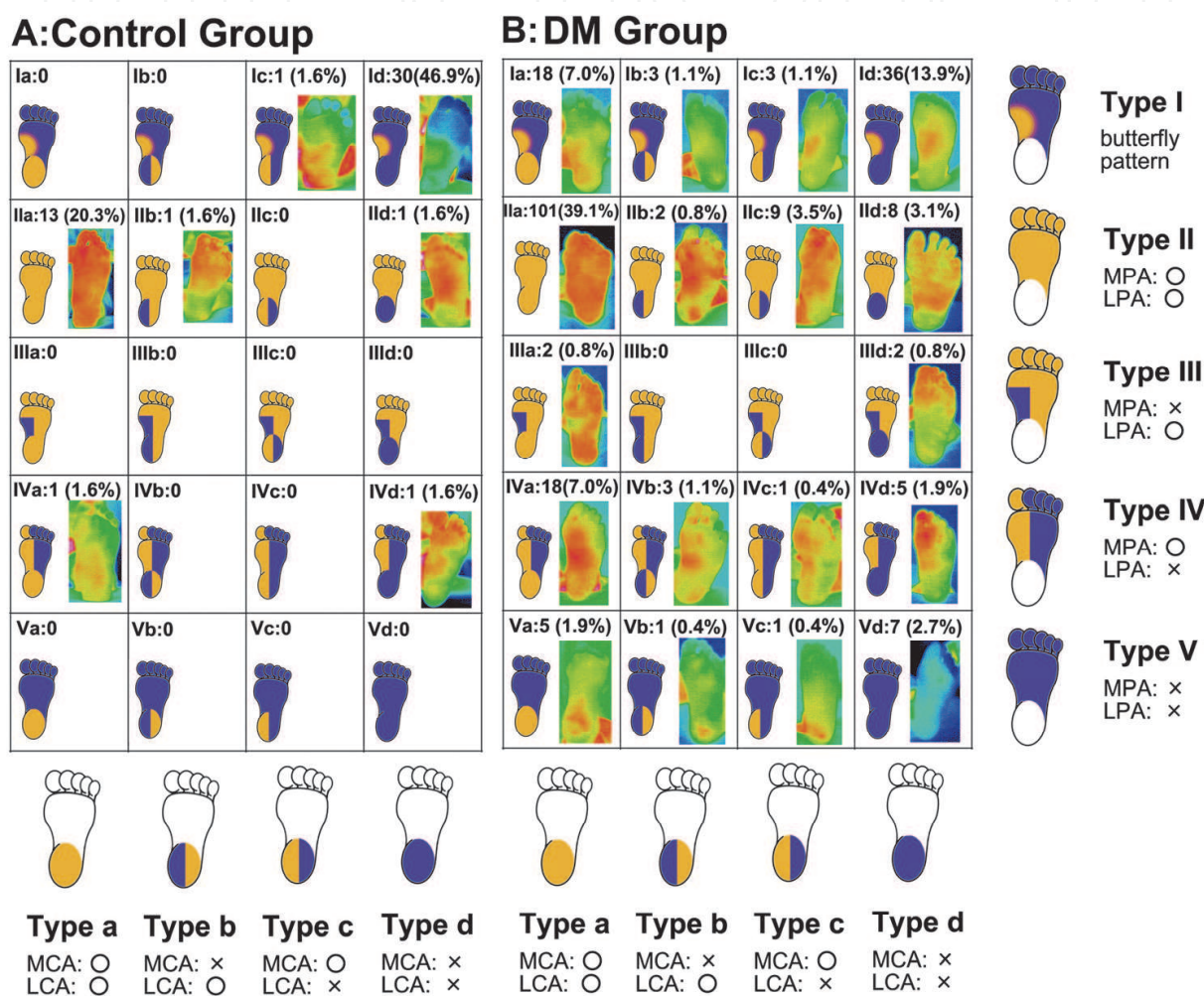


Fig. 2. Variations of the plantar thermographic patterns in the normal control group (A) and in the DM group (B). Representative thermographic images are included in the chart. Note that Id and Ila are the two main categories in the controls. Variations are broader in the DM group than in the control group. Reprinted from Journal of Plastic, Reconstructive & Aesthetic Surgery, Vol. 64 No.7. Nagase, T. et al. Variations of plantar thermographic patterns in normal controls and non-ulcer diabetic patients: Novel classification using angiosome concept. p.860-866, 2011. with permission from Elsevier.

There were 16 “atypical” feet (15.0%) which could not be allocated to any of the 20 categories (data not shown). We consider that 8 feet out of these cases are due to the anatomical variation of the arteries. Four feet from the two participants were characterized

by high temperature in the hallux only. We consider that, from their IR themographic data of the dorsal feet, the hallux is directly supplied by the DPA in these cases, as described by Attinger et al. (Attinger et al., 2006). High temperature was observed in the most toes in the other four feet. We interpreted these cases as follows: As stated above, the vertical descending branch of the DPA reaches the plantar arterial arch and the LPA (Attinger et al., 2006), as the most important “choke vessel.” Adachi (Adachi, 1928) indicated that there is a “watershed” which divides the plantar arterial arch into the DPA dominant territory and the LPA dominant territory. The location of the “watershed” varies among individual, determining to what extent the lesser toes are mainly supplied by the DPA. The cases with high temperature in the most toes can be interpreted as an extreme example where the “watershed” is located at the point more lateral to the fifth toe.

2.6 Variations of plantar thermographic patterns in the DM patients

We revealed that thermographic patterns in the DM groups had a remarkable difference from those in the normal controls: The DM thermographic patterns had a wider variations, being allocated to the 18 out of the 20 categories (Nagase et al., 2011)(Fig.2B). These data can be interpreted as individual irregularity of blood circulation at the level of angiosomes, that is, stenosis of source arteries or A-V shunt between angiosomes.

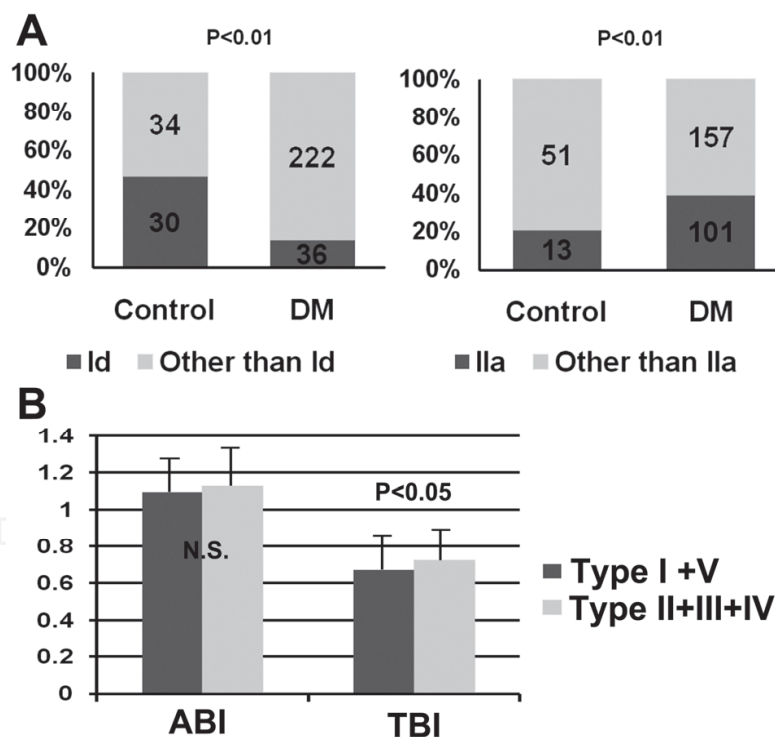


Fig. 3. (A) Comparison of the ratio of Id and Ila feet between the control and the DM groups. By chi-square test. (B) Comparison of ABI and TBI values between the type I + V subgroup and the type II + III + IV subgroups within the DM group. N.S.: not significant. By Student's *t* test. Reprinted from Journal of Plastic, Reconstructive & Aesthetic Surgery, Vol. 64 No.7. Nagase, T. et al. Variations of plantar thermographic patterns in normal controls and non-ulcer diabetic patients: Novel classification using angiosome concept. p.860-866, 2011. with permission from Elsevier.

Although the two most frequent categories were the same, Id and IIa, the frequency was reversed: Statistical analyses confirmed that feet ratio in the Id category was significantly lower and that in the IIa category was significantly higher in the DM group than in the control group (Nagase et al., 2011)(Fig.3A). We consider that the reversal may reflect chronic temperature elevation in the diabetic neuropathic feet (Brem et al., 2006; Chan et al., 1991; Flynn & Tooke, 1995; Sun et al., 2005; Sun et al., 2008). It is also noteworthy that a considerable percentage of the DM feet belonged to type IV (27 feet, 10.5%) and type V (14 feet, 5.4%) (Nagase et al., 2011). These two types suggest stenosis of the LPA or the more proximal artery (such as the posterior tibial artery). We consider that intensive foot care for prevention of ulceration associated with PAD should be required for these two types.

There were 33 “atypical” feet (12.8%) in the DM group (data not shown). An impressive pattern with high temperature only in the hallux and the fifth toe was observed in 5 feet in 4 cases. We consider that this phenomenon may be due to lateral compression by the ill-fitting shoes. Impaired thermoregulation by neuropathy may cause this pattern even after 15 minutes of equilibration.

ABI and TBI are clinical gold standards for estimating blood flow of the lower leg and the toe, respectively. To validate that thermographic patterns really reflect circulatory status, we further compared values of ABI and TBI between the subgroups of the DM group: the type I + V subgroup (in which the hallux temperature should be relatively low) and the type II + III + IV subgroup (in which the hallux temperature should be relatively high). ABI did not show statistically significant difference between these subgroups. However, TBI was significantly lower in the type I + V subgroup than in the type II + III + IV subgroup (Nagase et al., 2011)(Fig.3B). These findings may support our idea that the thermographic pattern with lower temperature in the toes reflects decreased blood supply in that region.

2.7 Discussion and future perspectives: Significance of “atypical” patterns

We newly established the novel classification system of the planter thermographic patterns, by which the morphological evaluation of the whole images is possible. Our paper was a first study clearly demonstrating the more remarkable variation of the planter thermographic patterns in the DM patients compared with those in the normal controls (Nagase et al., 2011).

Our findings described above can be summarized as follows. (1) Id and IIa categories can be regarded as normal patterns, which can be observed in about 70% of the normal subjects. (2) DM patients showed a remarkably wider variation compared with the normal controls, possibly reflecting stenosis of source arteries or A-V shunts. (3) Ratio of Id was lower and that of IIa was higher in the DM group than in the control group, possibly suggesting neuropathic temperature elevation. (4) Type IV and V seen in the DM group may reflect compromised circulation of the LPA, requiring interventions.

There were several limitations in our study which should be reexamined in future. There was a bias between the control group and the DM group, especially in age and sex. Precise evaluation of the circulatory status by angiography or meticulous examination using a Doppler probe (Attinger et al., 2006) should be needed to substantiate relationship between thermographic patterns and circulation more thoroughly. Relationship between neuropathy and thermographic patterns should also be investigated in future. Our classification with the

20 different categories might be too complicated in clinical use. We consider that the distinction of only type I – V may be reasonable in the usual diabetic foot care.

Here, we come to the point where the story should be returned to the Introduction. How can we detect latent inflammation in the at risk diabetic foot by thermography? We only briefly mentioned cases with “atypical” thermographic patterns. However, such atypical findings should be of particular clinical importance for detecting inflammation. The irregular focal elevation of the temperature should be a sign of latent inflammation. In our study, four feet from the four cases among the 16 “atypical” feet in the normal control group exhibited such hot spots of the temperature, which were associated with the ingrown toenails or the callus formation. Also, 19 feet from the 15 cases among the 33 atypical feet in the DM group exhibited similar hot spots associated with the callus, the ingrown nails or tinea pedis, all of which might be potential causal factors of ulceration.

In the next chapter, we further describe our other study of screening for latent inflammation in the diabetic foot by thermography and ultrasonography, focusing on the callus (Nishide et al., 2009). However, it is very reasonable to consider that, in any fields of medicine, the abnormalities cannot be sufficiently evaluated unless the normal findings are well described. In conclusion, we again emphasize that the information described in this chapter should be a basic reference for analyzing the foot thermographic patterns.

3. Thermographic and ultrasonographic screening for latent inflammation in diabetic foot callus

3.1 Callus formation in diabetic foot

Callus is defined a “localized hyperplasia of the horny layer of the epidermis due to pressure or friction” (Dorland’s medical dictionary). Callus is a quite common phenomenon frequently seen in the healthy people. However, callus formation is of particular clinical importance in the DM patients by the following reasons.

First, callus is one of the most frequent among changes in foot structures in the diabetic foot. Foot structure abnormalities which are common in, or specific for, the diabetic population include excessive callus formation, limited joint mobility, foot deformity, and soft-tissue modifications not showing as bony deformity. Bus (Bus, 2008) indicated that callus formation (prevalence 51-59%) and prominent metatarsal heads (65%) are the most common, followed by claw/hammer toe deformity (32-49%), hallux valgus (33%) and limited joint mobility (23-35%).

Second, pathophysiology of callus formation is very complicated and clinically relevant in DM patients. Peripheral neuropathy is associated with atrophy of the intrinsic foot muscles, hyperextension of the metatarsophalangeal joints, clawing of the toes, and distal displacement of the protective sub-metatarsal head fat pads, contributing to an increase in plantar pressures (Abouaesha et al., 2001; Bus, 2008; Pavicic & Korting, 2006). Autonomic neuropathy causes dry skin with fissures and tears more susceptible to pressure, and motor neuropathy also contributes to gait changes further resulting in pressure increase (Pavicic & Korting, 2006). Once callus is formed, abnormal loading is further increased forming vicious cycle (Apelqvist et al., 2008). Pataky et al. (Pataky et al., 2002) indicated that peak plantar pressure and duration of pressure was significantly larger in the DM patients with callus

than in those without callus. Assuming that an average person takes about 10,000 steps a day, they discussed that the callus skin is exposed to the excessive pressure of 18.600 kg per day!

Third, callus is one of the most important predisposing factors of ulcer formation in DM patients (Edmonds & Foster, 2006). As stated in the Introduction, diabetic patients with sensory neuropathy often overlooked their callus because of absence of the pain. They continue walking on the insensitive feet, and subcutaneous hemorrhage, autolytic seroma and subsequent skin breakdown are easily developed at the callus in DM patients (Apelqvist et al., 2000; Apelqvist et al., 2008; Edmonds & Foster, 2006). Indeed, it was reported that callus formation preceded ulceration in 82.4 % of diabetic foot ulcer patients (Sage et al., 2001). Murray et al. (Murray et al., 1996) also reported a relative risk of 11.0 for an ulcer developing under an area of callus in DM patients with neuropathy.

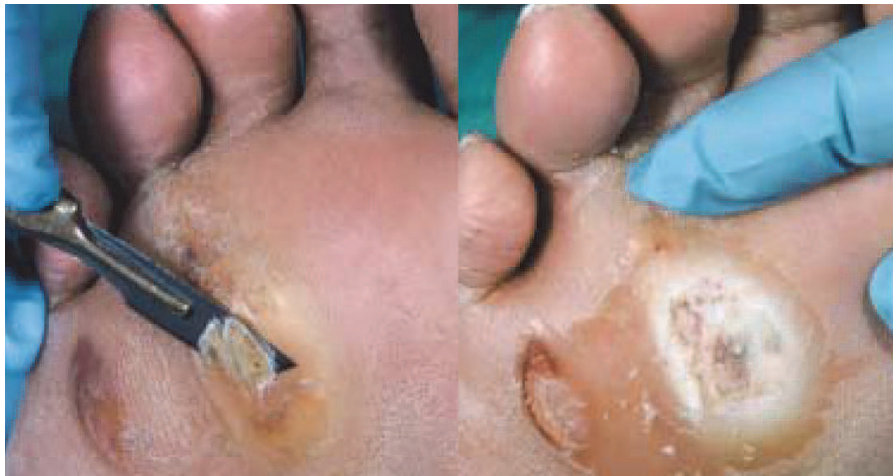

Fig. 4. Callus removal by sharp debridement. Whitish, macerated, moist tissue is found under surface of callus, indicating imminent ulceration. Reproduced from British Medical Journal, Diabetic foot ulcers, Edmonds, M. E. & Foster, A. V. Vol. 332, p.407-410, 2006. with permission from BMJ Publishing Group Ltd.

It is noteworthy that foot ulceration derived from the callus may be quite rare in healthy population, although callus is commonly seen in non-diabetic subjects. This may be due to insensitivity to inflammatory pain in the neuropathic patients, and also due to difficulty of noticing inflammatory edema and erythema associated with ulcer progression, because the plantar skin has thicker layer of the stratum corneum. Even if the surface of the callus is seemingly dry in DM patients, macerated, moist tissue can occasionally be found underneath the callus when the surface is debrided, indicating that the foot is close to ulceration (Fig.4)(Edmonds & Foster, 2006). Then, how can we detect such latent inflammation in the callus before ulcer formation is completed? Is the latent inflammation in the callus absent in healthy population?

3.2 Our strategy of screening for latent inflammation in the callus: Thermography and ultrasonography

In order to solve these problems, we decided to use thermography and ultrasonography in the next study (Nishide et al., 2009). Because the DM patients have a difficulty in noticing

inflammation in their calluses by themselves, and because inflammatory calluses may be difficult to detect by the physical inspection and examination, "latent inflammation" was operationally defined in this study when both of the two following findings were observed in order to reduce the possibility of the false positive case: skin temperature elevation by thermography, and identification of low echoic lesion by ultrasonography (Nishide et al., 2009).

In this study, we compared 30 DM neuropathy patients having plantar calluses (the DM group) with 30 non-diabetic callus patients of matched age and sex (the non-DM group) (Nishide et al., 2009). The DM group was recruited from the patients at the Diabetic Foot Outpatient Clinic at the University of Tokyo Hospital between November 2006 and October 2007. The non-DM group was the volunteers selected by the snowball sample method. Diagnosis of associated neuropathy was required as an inclusion criterion for the DM group. It was defined by the criteria by Japanese Diabetic Neuropathy Association, or by detection of sensory loss using 5.07 (10g) monofilament touch test in at least one of the three plantar regions (Pham et al., 2000). All the patients and volunteers were inspected and examined by a dermatologist and two experienced and certified Wound, Ostomy and Continence Nurses (WOCNs.) The subjects with visible inflammation, pain around the calluses, preformed foot ulcers, autoimmune diseases or other acute inflammatory diseases were excluded from the study.

IR thermographic measurement of the skin temperature was performed as described in the previous chapter, with 15 minutes equilibration (Nagase et al., 2011; Nishide et al., 2009). In this study, we focused on temperature of the callus and the surrounding skin. The callus temperature was defined as an average temperature value of the 4 mm x 4 mm square, the center of which was on the highest temperature point. The temperature of the surrounding skin was defined as an average of the 4 mm x 4 mm square in an adjacent area unaffected by the temperature change of the callus. Previous studies suggested different criteria of temperature elevation in inflammatory skin: 2.2°C for prevention of diabetic foot disorder (Armstrong et al., 2007; Lavery et al., 2007), and 1.2°C for inflammatory leg ulcers (Sayre et al., 2007). We selected 1.2°C as a criterion of temperature elevation since our focus of this study was early screening and prevention.

We also used ultrasonography (LOGIQ Book XP, GE Medical Systems, UK. 10 MHz, B-mode) for detecting edematous and fluid-filled changes of the latent inflammatory callus (Nishide et al., 2009). Identification of low echoic lesion was defined in this study when lowered ultrasonographic signal was clearly observed in either the dermal, subdermal or muscle layers. Ultrasonography has been increasingly used as a diagnostic and assessment tool in the field of skin care. 20 MHz ultrasonography is more popular among dermatologic specialists because of higher image resolution of the more superficial skin layer such as the epidermis and the dermis (Schmid-Wendtner & Burgdorf, 2005). However, 20 MHz ultrasonography can only produce images 20 mm below the skin surface (Yabunaka et al., 2009). We selected 10MHz ultrasonography in this study for focusing on the subcutaneous or muscle layers which may be more prone to be damaged by external forces (Nishide et al., 2009). Our group routinely uses 10 MHz ultrasonography for obtaining sufficient visualization of the pressure-related deep tissue injury (Aoi et al., 2009; Nagase et al., 2007; Yabunaka et al., 2009), providing considerable justification for our choice in this study.

3.3 Inflammation was detected in 10% of the diabetic foot callus

In this study, 63 and 94 calluses were observed in the 30 DM group participants and in the 30 non-DM group participants, respectively (Nishide et al., 2009). 40 (63.5%) and 23 (36.5%) calluses were located in the toes and metatarsal areas in the DM group, respectively. 50 (53.2%) and 44 (46.8%) calluses were located in the toes and metatarsal areas in the non-DM group, respectively. There were no significant differences in the number per person, location and size of the calluses between the two groups.

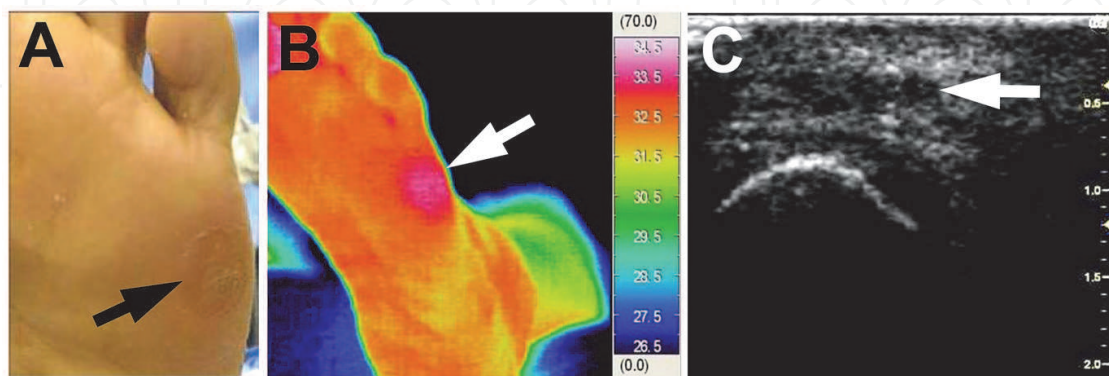


Fig. 5. An example of latent inflammation identified by thermography and ultrasonography. (A) Photograph. An arrow indicates the callus. (B) Thermography. An arrow indicates elevated temperature. (C) Ultrasonography. An arrow indicates low echoic lesion in the subcutaneous layer. Reprinted from *Diabetes Research and Clinical Practice*, Vol. 85 No.3. Nishide, K. et al. Ultrasonographic and thermographic screening for latent inflammation in diabetic foot callus. p.304-309, 2009. with permission from Elsevier.

Both thermographic and ultrasonographic data were available in 50 calluses in the DM group and 65 calluses in the non-DM group. These calluses were assessed for latent inflammation. Notably, no inflammatory findings were observed by thermography and ultrasonography in the non-DM group. Whereas, five (10%) calluses in the DM group were regarded as positive inflammation. Skin temperature increase could be clearly detected by thermography (Nishide et al., 2009) (Figs. 5A, B). Low echoic lesion was also sufficiently identified using ultrasonography (Fig. 5C).

More detailed explanations of the five inflammatory calluses are given below.

Case 1: The callus was located at the base of the first metatarsus. Temperature elevation was 2.3 °C. Low echoic lesion was noted in the muscle layer.

Case 2 (Fig.5): The callus was located at the base of the fifth metatarsus. Temperature elevation was 1.6 °C. Low echoic lesion was noted in the subcutaneous fatty layer.

Case 3: The callus was located at the lateral side of the great toe. Temperature elevation was 2.8 °C. Low echoic lesions were noted in the epidermis, dermis and muscle layers.

Case 4: The callus was located at the tip of the fourth toe. Temperature elevation was 1.6 °C. Low echoic lesion was noted in the muscle layer.

Case 5: The callus was located at the lateral side of the fifth toe. Temperature elevation was 1.9 °C. Low echoic lesion was noted in the subcutaneous fatty layer.

3.4 Discussion and future perspectives

This study was the first paper demonstrating significant versatility of thermography and ultrasonography as screening tools for latent asymptomatic inflammation underneath the foot callus in DM patients. As stated above, inflammatory change in the callus has been considered as a high risk factor for later ulcer development. In this study, 10% of the calluses in the DM group had the inflammatory findings, whereas none in the non-DM group.

In this study, it is noteworthy that thermography and ultrasonography were able to detect latent inflammatory changes in the callus, which could not be identified even by physical examination by the wound care specialists including a dermatologist and two certified WOCNs. This fact indicates that the inflammation underneath the seemingly dry callus can be easily overlooked by physicians and medical staffs not specialized in wound and foot care and by patients themselves. We consider that 10% of inflammatory rate in our DM group is awfully high. Although callus is a very common phenomenon often seen in healthy people, we should not underestimate clinical relevance of callus as a predisposing status of ulcer formation in DM population.

As stated earlier, thermometry has been proposed as a promising way of identifying “at risk” foot, as shown in the randomized controlled trials by Armstrong et al. (Armstrong et al., 2007) and Lavery et al. (Lavery et al., 2004; Lavery et al., 2007). We again consider that thermography has several great advantages for identifying latent inflammation in the foot callus, compared with their pinpoint thermometric measurements in the bilateral plantar landmark points. First, their methods may overlook the inflammatory site not located in the anatomical landmark points. Second, temperature differences of bilateral landmark points are estimated in their methods. However, calluses are often developed in the same location of both feet, which makes the bilateral comparison difficult. Third, thermography enables clear visualization of morphological temperature distribution as stated in the previous chapter, and this advantage may also be of importance for finding the inflammation of the callus “at a glance.”

We could identify subcutaneous inflammatory changes underneath the calluses by 10 MHz ultrasonography. Ultrasonography is a non-invasive, inexpensive and portable technique, and thus it has been gradually used in the broad area of medicine. For the assessment of the skin, a 20 MHz probe is more widely used for the search and imaging of lymph nodes, chronic ulcers and subcutaneous tumors in a variety of clinical settings (Schmid-Wendtner & Burgdorf, 2005; Yabunaka et al., 2009). However, we focused on the subcutaneous tissue damage using a 10 MHz probe in this study, because it is known that the deep tissue damages precede skin breakdown when the callus is developed into the full thickness skin ulcer (Apelqvist et al., 2000; Apelqvist et al., 2008; Edmonds & Foster, 2006). Indeed, our current study using ultrasonography revealed that three of the five inflammatory calluses had tissue damage downward to the muscle layer. This fact clearly indicates that the calluses in the diabetic foot may not be just a thickening of the horny layer. We also consider that the thermography should be used for the initial screening of inflammation, and that ultrasonography may be useful for determining severity of tissue damage after thermographic assessment. It is also of note that latent inflammatory findings by combination of thermography and ultrasonography were detected only in the DM group, without any observational symptoms and pains. Our data strongly suggests that “asymptomatic inflammation” in the callus may be a specific feature in the DM population.

There were several limitations in this study. Because this study was cross-sectional, we could not follow up patients with latent inflammation until subsequent ulceration develop. Our study provides no evidence to suggest that the calluses with latent inflammation eventually ulcerated. Future prospective observation is needed to confirm whether our findings of “latent inflammation” really result in diabetic foot ulcers. It should also be kept in mind that we used the strict criteria of latent inflammation by two methods, that is, both elevated temperature and low echoic lesion. Although this method can reduce the probability of the false positive, which ensures the patients with latent inflammatory callus were truly at risk, there would be more than 10 % of the cases if we used more sensitive method. (Please remember that there were four feet with hot spots identified by only thermography in the normal controls, and that some of them were associated with the callus in the previous chapter.) It will be necessary in future to determine the most suitable cut-off point.

In summary, although there were such limitations in this study, we believe that thermographic and ultrasonographic screening for latent inflammation will effectively prevent callus-derived foot ulceration in DM patients in future.

4. Concluding remarks

Through the two abovementioned studies, we successfully showed that the non-invasive imaging modalities such as thermography and ultrasonography are very promising tools for evaluating blood circulation and inflammatory status and for preventing ulcer formation in the diabetic foot. The latter study (Nishide et al., 2009) was completed and published before the thermographic classification in the former study (Nagase et al., 2011) was established. One of the reasons why the work by Nishide et al. (Nishide et al., 2009) was successful without the classification was, probably, that we focused on the thermographic findings of the callus, a clinically visible skin disorder. For the broader application of thermography to a variety of clinical spectrum of diabetic foot in future, the knowledge about the normal thermographic findings should be essential as a reference. In this sense, we believe that future clinical importance of thermographic and ultrasonographic evaluation of the diabetic foot will be based on our classification described above.

We consider that there may be some difficulties in interpreting atypical temperature increase in thermography. Temperature increase can be caused by not only latent inflammation, but also A-V shunting and increased plantar pressure as seen in the atypical diabetic foot with increased loading of the hallux and fifth toe described in section 2.6. For discriminating these causes, we consider that careful inspection of the foot and parallel use of ultrasonography will be helpful. Further research will provide us with a key to solve this problem.

Management of diabetic foot requires intimate contact between medical staffs and patients. Behavioral factors, such as patients' poor compliance with self foot care, also contribute to the deterioration of diabetic foot. We previously reported that prevalence of onychomycosis, another important predisposing factor of diabetic foot ulcers, was significantly associated with not washing of feet every day (Takehara et al., 2011). Temperature measurement by patients themselves at home will also become an important part of self care in future. The preventive strategies of self monitoring of the foot temperature using a handheld IR thermometer or recent LC thermography have a reasonable advantage in this regard

(Armstrong et al., 2007; Frykberg et al., 2009; Lavery et al., 2004; Lavery et al., 2007). On the contrary, IR thermography and ultrasonography have been previously performed mainly by medical doctors, radiologists and related technologists, because they require considerable expertise in their handling and data analyses. In order to popularize our strategy described above using IR thermography and ultrasonography in a community based manner, specific education of handling these modalities should be needed for staffs engaged in community health (such as nurse practitioners in United States). How is it possible?

Our research group is composed of multidisciplinary scientists. The first author of this chapter (Nagase) is a plastic surgeon. Our laboratory also includes research nurses (including WOCNs), molecular biologists and engineering specialists. As our research described above has been progressed, the nursing staffs in our group have increasingly showed a great improvement in their technique of using thermography and ultrasonography. Now we routinely use these modalities without any difficulties. Our experience may support the idea that these modalities will be well handled by community based medical staffs in future under the appropriate educational system. As these technologies are non-invasive and "patient-friendly" without any pain and discomfort, they are really promising as future nursing tools. In this regard, our researches described above can be regarded as a pioneering attempt integrating medical technologies and nursing care, based on the intimate discussion and collaboration among our multidisciplinary research members.

5. References

- Abouaasha, F., van Schie, C. H., Griffiths, G. D., Young, R. J., & Boulton, A. J. (2001). Plantar tissue thickness is related to peak plantar pressure in the high-risk diabetic foot. *Diabetes Care*, Vol.24, No.7, (July 2001), pp. 1270-1274, ISSN 0149-5992
- Adachi, B. (1928). *Das Arteriensystem der Japaner. Band II*, Maruzen, Kyoto, Japan.
- Aoi, N., Yoshimura, K., Kadono, T., Nakagami, G., Iizuka, S., Higashino, T., Araki, J., Koshima, I., & Sanada, H. (2009). Ultrasound assessment of deep tissue injury in pressure ulcers: possible prediction of pressure ulcer progression. *Plastic and Reconstructive Surgery*, Vol.124, No.2, (August 2009), pp. 540-550, ISSN 1529-4242
- Apelqvist, J., Bakker, K., van Houtum, W. H., Nabuurs-Franssen, M. H., & Schaper, N. C. (2000). International consensus and practical guidelines on the management and the prevention of the diabetic foot. International Working Group on the Diabetic Foot. *Diabetes/Metabolism Research and Reviews*, Vol.16 Suppl 1, (September-October 2000), pp. S84-92, ISSN 1520-7552
- Apelqvist, J., Bakker, K., van Houtum, W. H., & Schaper, N. C. (2008). Practical guidelines on the management and prevention of the diabetic foot: based upon the International Consensus on the Diabetic Foot (2007) Prepared by the International Working Group on the Diabetic Foot. *Diabetes/Metabolism Research and Reviews*, Vol.24 Suppl 1, (May-June 2008), pp. S181-187, ISSN 1520-7552
- Armstrong, D. G., Holtz-Neiderer, K., Wendel, C., Mohler, M. J., Kimbriel, H. R., & Lavery, L. A. (2007). Skin temperature monitoring reduces the risk for diabetic foot ulceration in high-risk patients. *The American Journal of Medicine*, Vol.120, No.12, (December 2007), pp. 1042-1046, ISSN 0002-9343


- Attinger, C., Cooper, P., & Blume, P. (1997). Vascular anatomy of the foot and ankle. *Operative Techniques in Plastic and Reconstructive Surgery*, Vol.4, No.4, (November 1997), pp. 183-198, ISSN 1071-0949
- Attinger, C. E., Evans, K. K., Bulan, E., Blume, P., & Cooper, P. (2006). Angiosomes of the foot and ankle and clinical implications for limb salvage: reconstruction, incisions, and revascularization. *Plastic and Reconstructive Surgery*, Vol.117, No.7 Suppl, (June 2006), pp. 261S-293S, ISSN 0007-1226
- Benbow, S. J., Chan, A. W., Bowsher, D. R., Williams, G., & Macfarlane, I. A. (1994). The prediction of diabetic neuropathic plantar foot ulceration by liquid-crystal contact thermography. *Diabetes Care*, Vol.17, No.8, (August 1994), pp. 835-839, ISSN 0149-5992
- Bharara, M., Cobb, J. E., & Claremont, D. J. (2006). Thermography and thermometry in the assessment of diabetic neuropathic foot: a case for furthering the role of thermal techniques. *The International Journal of Lower Extremity Wounds*, Vol.5, No.4, (December 2006), pp. 250-260, ISSN 1534-7346
- Bharara, M., Schoess, J., Nouvong, A., & Armstrong, D. G. (2010). Wound inflammatory index: a "proof of concept" study to assess wound healing trajectory. *Journal of Diabetes Science and Technology*, Vol.4, No.4, (July 2010), pp. 773-779, ISSN 1932-2968
- Bharara, M., Viswanathan, V., & Cobb, J. E. (2008a). Cold immersion recovery responses in the diabetic foot with neuropathy. *International Wound Journal*, Vol.5, No.4, (October 2008), pp. 562-569, ISSN 1742-481X
- Bharara, M., Viswanathan, V., & Cobb, J. E. (2008b). Warm immersion recovery test in assessment of diabetic neuropathy--a proof of concept study. *International Wound Journal*, Vol.5, No.4, (October 2008), pp. 570-576, ISSN 1742-481X
- Brem, H., Sheehan, P., Rosenberg, H. J., Schneider, J. S., & Boulton, A. J. (2006). Evidence-based protocol for diabetic foot ulcers. *Plastic and Reconstructive Surgery*, Vol.117, No.7 Suppl, (June 2006), pp. 193S-209S, ISSN 0007-1226
- Bus, S. A. (2008). Foot structure and footwear prescription in diabetes mellitus. *Diabetes/Metabolism Research and Reviews*, Vol.24 Suppl 1, (May-June 2008), pp. S90-95, ISSN 1520-7552
- Chan, A. W., MacFarlane, I. A., & Bowsher, D. R. (1991). Contact thermography of painful diabetic neuropathic foot. *Diabetes Care*, Vol.14, No.10, (October 1991), pp. 918-922, ISSN 0149-5992
- Edmonds, M. E., & Foster, A. V. (2006). Diabetic foot ulcers. *British Medical Journal*, Vol.332, No.7538, (February 2006), pp. 407-410, ISSN 1468-5833
- Flynn, M. D., & Tooke, J. E. (1995). Diabetic neuropathy and the microcirculation. *Diabetic Medicine*, Vol.12, No.4, (April 1995), pp. 298-301, ISSN 0742-3071
- Frykberg, R. G., Tallis, A., & Tierney, E. (2009). Diabetic foot self examination with the Tempstat™ as an integral component of a comprehensive prevention program. *The Journal of Diabetic Foot Complications*, Vol.1, No.1, (2009), pp. 13-18
- Harii, K., Omori, K., & Omori, S. (1974). Hair transplantation with free scalp flaps. *Plastic and Reconstructive Surgery*, Vol.53, No.4, (April 1974), pp. 410-413, ISSN 0032-1052
- Kang, P. B., Hoffman, S. N., Krimitsos, E., & Rutkove, S. B. (2003). Ambulatory foot temperature measurement: a new technique in polyneuropathy evaluation. *Muscle & Nerve*, Vol.27, No.6, (June 2003), pp. 737-742, ISSN 0148-639X

- Lavery, L. A., Armstrong, D. G., Vela, S. A., Quebedeaux, T. L., & Fleischli, J. G. (1998). Practical criteria for screening patients at high risk for diabetic foot ulceration. *Archives of Internal Medicine*, Vol.158, No.2, (January 1998), pp. 157-162, ISSN 0003-9926
- Lavery, L. A., Higgins, K. R., Lanctot, D. R., Constantinides, G. P., Zamorano, R. G., Armstrong, D. G., Athanasiou, K. A., & Agrawal, C. M. (2004). Home monitoring of foot skin temperatures to prevent ulceration. *Diabetes Care*, Vol.27, No.11, (November 2004), pp. 2642-2647, ISSN 0149-5992
- Lavery, L. A., Higgins, K. R., Lanctot, D. R., Constantinides, G. P., Zamorano, R. G., Athanasiou, K. A., Armstrong, D. G., & Agrawal, C. M. (2007). Preventing diabetic foot ulcer recurrence in high-risk patients: use of temperature monitoring as a self-assessment tool. *Diabetes Care*, Vol.30, No.1, (January 2007), pp. 14-20, ISSN 0149-5992
- Lavery, L. A., Peters, E. J., Williams, J. R., Murdoch, D. P., Hudson, A., & Lavery, D. C. (2008). Reevaluating the way we classify the diabetic foot: restructuring the diabetic foot risk classification system of the International Working Group on the Diabetic Foot. *Diabetes Care*, Vol.31, No.1, (January 2008), pp. 154-156, ISSN 0149-5992
- Murray, H. J., Young, M. J., Hollis, S., & Boulton, A. J. (1996). The association between callus formation, high pressures and neuropathy in diabetic foot ulceration. *Diabetic Medicine*, Vol.13, No.11, (November 1996), pp. 979-982, ISSN 0742-3071
- Nagase, T., Koshima, I., Maekawa, T., Kaneko, J., Sugawara, Y., Makuuchi, M., Koyanagi, H., Nakagami, G., & Sanada, H. (2007). Ultrasonographic evaluation of an unusual peri-anal induration: a possible case of deep tissue injury. *Journal of Wound Care*, Vol.16, No.8, (September 2007), pp. 365-367, ISSN 0969-0700
- Nagase, T., Sanada, H., Takehara, K., Oe, M., Iizaka, S., Ohashi, Y., Oba, M., Kadowaki, T., & Nakagami, G. (2011). Variations of plantar thermographic patterns in normal controls and non-ulcer diabetic patients: Novel classification using angiosome concept. *Journal of Plastic, Reconstructive & Aesthet Surg*, Vol.64, No.7, (July 2011), pp. 860-866, ISSN 1748-6815
- Nagase, T., Sekiguchi, J., & Ohmori, K. (1996). Finger replantation in a 12-month-old child: a long-term follow-up. *British Journal of Plastic Surgery*, Vol.49, No.8, (December 1996), pp. 555-558, ISSN 0007-1226
- Nakagami, G., Sanada, H., Iizaka, S., Kadono, T., Higashino, T., Koyanagi, H., & Haga, N. (2010). Predicting delayed pressure ulcer healing using thermography: a prospective cohort study. *Journal of Wound Care*, Vol.19, No.11, (November 2010), pp. 465-470, ISSN 0969-0700
- Nishide, K., Nagase, T., Oba, M., Oe, M., Ohashi, Y., Iizaka, S., Nakagami, G., Kadowaki, T., & Sanada, H. (2009). Ultrasonographic and thermographic screening for latent inflammation in diabetic foot callus. *Diabetes Research and Clinical Practice*, Vol.85, No.3, (September 2009), pp. 304-309, ISSN 0168-8227
- Pataky, Z., Golay, A., Faravel, L., Da Silva, J., Makoundou, V., Peter-Riesch, B., & Assal, J. P. (2002). The impact of callosities on the magnitude and duration of plantar pressure in patients with diabetes mellitus. A callus may cause 18,600 kilograms of excess plantar pressure per day. *Diabetes & Metabolism*, Vol.28, No.5, (November 2002), pp. 356-361, ISSN 1262-3636

- Pavicic, T., & Korting, H. C. (2006). Xerosis and callus formation as a key to the diabetic foot syndrome: dermatologic view of the problem and its management. *Journal der Deutschen Dermatologischen Gesellschaft*, Vol.4, No.11, (November 2006), pp. 935-941, ISSN 1610-0389
- Peters, E. J., & Lavery, L. A. (2001). Effectiveness of the diabetic foot risk classification system of the International Working Group on the Diabetic Foot. *Diabetes Care*, Vol.24, No.8, (August 2001), pp. 1442-1447, ISSN 0149-5992
- Pham, H., Armstrong, D. G., Harvey, C., Harkless, L. B., Giurini, J. M., & Veves, A. (2000). Screening techniques to identify people at high risk for diabetic foot ulceration: a prospective multicenter trial. *Diabetes Care*, Vol.23, No.5, (May 2000), pp. 606-611, ISSN 0149-5992
- Roback, K., Johansson, M., & Starkhammar, A. (2009). Feasibility of a thermographic method for early detection of foot disorders in diabetes. *Diabetes Technology & Therapeutics*, Vol.11, No.10, (Oct 2009), pp. 663-667, ISSN 1520-9156
- Rutkove, S. B., Chapman, K. M., Acosta, J. A., & Larrabee, J. E. (2005). Foot temperature in diabetic polyneuropathy: innocent bystander or unrecognized accomplice? *Diabetic Medicine*, Vol.22, No.3, (March 2005), pp. 231-238, ISSN 0742-3071
- Sage, R. A., Webster, J. K., & Fisher, S. G. (2001). Outpatient care and morbidity reduction in diabetic foot ulcers associated with chronic pressure callus. *Journal of American Podiatric Medical Association*, Vol.91, No.6, (June 2001), pp. 275-279, ISSN 8750-7315
- Sayre, E. K., Kelechi, T. J., & Neal, D. (2007). Sudden increase in skin temperature predicts venous ulcers: a case study. *Journal of Vascular Nursing*, Vol.25, No.3, (September 2007), pp. 46-50, ISSN 1062-0303
- Schmid-Wendtner, M. H., & Burgdorf, W. (2005). Ultrasound scanning in dermatology. *Archives of Dermatology*, Vol.141, No.2, (February 2005), pp. 217-224, ISSN 0003-987X
- Stess, R. M., Sisney, P. C., Moss, K. M., Graf, P. M., Louie, K. S., Gooding, G. A., & Grunfeld, C. (1986). Use of liquid crystal thermography in the evaluation of the diabetic foot. *Diabetes Care*, Vol.9, No.3, (May-June 1986), pp. 267-272, ISSN 0149-5992
- Sun, P. C., Jao, S. H., & Cheng, C. K. (2005). Assessing foot temperature using infrared thermography. *Foot & Ankle International*, Vol.26, No.10, (October 2005), pp. 847-853, ISSN 1071-1007
- Sun, P. C., Lin, H. D., Jao, S. H., Chan, R. C., Kao, M. J., & Cheng, C. K. (2008). Thermoregulatory sudomotor dysfunction and diabetic neuropathy develop in parallel in at-risk feet. *Diabetic Medicine*, Vol.25, No.4, (April 2008), pp. 413-418, ISSN 0742-3071
- Sun, P. C., Lin, H. D., Jao, S. H., Ku, Y. C., Chan, R. C., & Cheng, C. K. (2006). Relationship of skin temperature to sympathetic dysfunction in diabetic at-risk feet. *Diabetes Research and Clinical Practice*, Vol.73, No.1, (July 2006), pp. 41-46, ISSN 0168-8227
- Takehara, K., Oe, M., Tsunemi, Y., Nagase, T., Ohashi, Y., Iizaka, S., Ueki, K., Tsukamoto, K., Kadowaki, T., & Sanada, H. (2011). Factors associated with presence and severity of toenail onychomycosis in patients with diabetes: A cross-sectional study. *International Journal of Nursing Studies*, Vol.48, No.9, (September 2011), pp. 1101-1108, ISSN 0020-7489
- Taylor, G. I., & Palmer, J. H. (1987). The vascular territories (angiosomes) of the body: experimental study and clinical applications. *British Journal of Plastic Surgery*, Vol.40, No.2, (March 1987), pp. 113-141, ISSN 0007-1226

- The International Working Group on the Diabetic Foot (1999). *International Consensus on the Diabetic Foot*, The International Working Group on the Diabetic Foot, ISBN 90-9012716-x, Maastricht, Netherlands.
- Wang, H., Wade, D. R. J., & Kam, J. (2004). IR imaging of blood circulation of patients with vascular disease. *Proceeding of Thermosense XXVI*, ISBN 9780819453280, Bellingham, WA, USA, April, 2004.
- Yabunaka, K., Iizaka, S., Nakagami, G., Aoi, N., Kadono, T., Koyanagi, H., Uno, M., Ohue, M., Sanada, S., & Sanada, H. (2009). Can ultrasonographic evaluation of subcutaneous fat predict pressure ulceration? *Journal of Wound Care*, Vol.18, No.5, (May 2009), pp. 192-196 ISSN 0969-0700
- Yamada, T., Gloviczki, P., Bower, T. C., Naessens, J. M., & Carmichael, S. W. (1993). Variations of the arterial anatomy of the foot. *American Journal of Surgery*, Vol.166, No.2, (August 1993), pp. 130-135, ISSN 0002-9610

IntechOpen



Global Perspective on Diabetic Foot Ulcerations

Edited by Dr. Thanh Dinh

ISBN 978-953-307-727-7

Hard cover, 278 pages

Publisher InTech

Published online 09, December, 2011

Published in print edition December, 2011

Over the last decade, it is becoming increasingly clear that diabetes mellitus is a global epidemic. The influence of diabetes is most readily apparent in its manifestation in foot complications across cultures and continents. In this unique collaboration of global specialists, we examine the explosion of foot disease in locations that must quickly grapple with both mobilizing medical expertise and shaping public policy to best prevent and treat these serious complications. In other areas of the world where diabetic foot complications have unfortunately been all too common, diagnostic testing and advanced treatments have been developed in response. The bulk of this book is devoted to examining the newest developments in basic and clinical research on the diabetic foot. It is hoped that as our understanding of the pathophysiologic process expands, the devastating impact of diabetic foot complications can be minimized on a global scale.

How to reference

In order to correctly reference this scholarly work, feel free to copy and paste the following:

Takashi Nagase, Hiromi Sanada, Makoto Oe, Kimie Takehara, Kaoru Nishide and Takashi Kadowaki (2011). Screening of Foot Inflammation in Diabetic Patients by Non-Invasive Imaging Modalities, Global Perspective on Diabetic Foot Ulcerations, Dr. Thanh Dinh (Ed.), ISBN: 978-953-307-727-7, InTech, Available from: <http://www.intechopen.com/books/global-perspective-on-diabetic-foot-ulcerations/screening-of-foot-inflammation-in-diabetic-patients-by-non-invasive-imaging-modalities>

INTECH
open science | open minds

InTech Europe

University Campus STeP Ri
Slavka Krautzeka 83/A
51000 Rijeka, Croatia
Phone: +385 (51) 770 447
Fax: +385 (51) 686 166
www.intechopen.com

InTech China

Unit 405, Office Block, Hotel Equatorial Shanghai
No.65, Yan An Road (West), Shanghai, 200040, China
中国上海市延安西路65号上海国际贵都大饭店办公楼405单元
Phone: +86-21-62489820
Fax: +86-21-62489821

© 2011 The Author(s). Licensee IntechOpen. This is an open access article distributed under the terms of the [Creative Commons Attribution 3.0 License](#), which permits unrestricted use, distribution, and reproduction in any medium, provided the original work is properly cited.

IntechOpen

IntechOpen