

# We are IntechOpen, the world's leading publisher of Open Access books Built by scientists, for scientists

**4,800**

Open access books available

**122,000**

International authors and editors

**135M**

Downloads

Our authors are among the

**154**

Countries delivered to

**TOP 1%**

most cited scientists

**12.2%**

Contributors from top 500 universities



**WEB OF SCIENCE™**

Selection of our books indexed in the Book Citation Index  
in Web of Science™ Core Collection (BKCI)

Interested in publishing with us?  
Contact [book.department@intechopen.com](mailto:book.department@intechopen.com)

Numbers displayed above are based on latest data collected.

For more information visit [www.intechopen.com](http://www.intechopen.com)



# The Development of the Modern Prostate Biopsy

Lehana Yeo, Dharmesh Patel, Christian Bach, Athanasios Papatsoris,  
Noor Buchholz, Islam Junaid and Junaid Masood  
*Barts and the London NHS Trust*  
UK

## 1. Introduction

In the 1950s prostate cancer was known to occur in about 20% of men over the age of 55 and was the cause of death in about 5% of white men over the age of 50 (Huggins and Johnson, 1947). It accounted for 90% of all male genital cancers and 63% of male genitourinary cancers and it was believed that 5-10% of prostatic cancers were diagnosed early enough to permit operation with a reasonable chance of cure (Kaufman et al., 1954). Clearly diagnosis was paramount in order to initiate treatment and improve prognosis.

The current accepted practice of diagnosing prostate cancer relies on histopathological examination of prostatic tissue obtained through transrectal ultrasound (TRUS) guided biopsy of the gland (Heidenreich et al, 2010). The TRUS-guided transrectal method of obtaining prostatic tissue has been described since the mid-1980s but before then, other methods of sampling the prostate gland were used.

This chapter describes the development of the modern prostate biopsy from the techniques of the early 1900s of transperineal open biopsy to the current method of using ultrasound guidance to allow transrectal prostate biopsies.

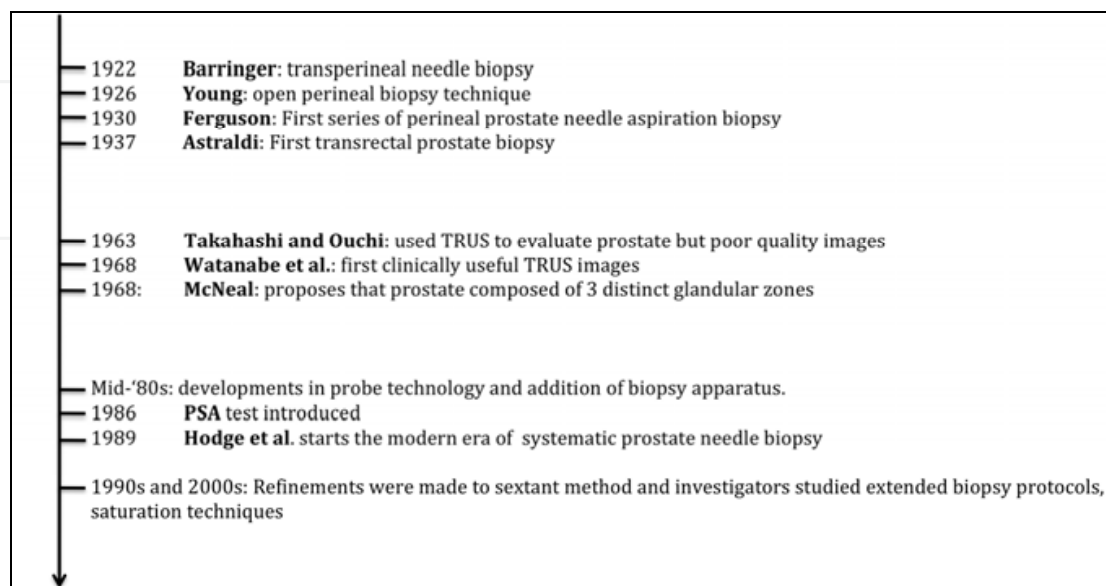


Fig. 1. A timeline of the development of the modern prostate biopsy

## 2. Digital rectal examination

Prior to the development of prostate ultrasound imaging the only method available to examine the prostate was by the subjective digital examination of the anterior rectal wall. Any nodularity, firmness or irregularity of the prostate raised the suspicion of prostate cancer (figure 2).

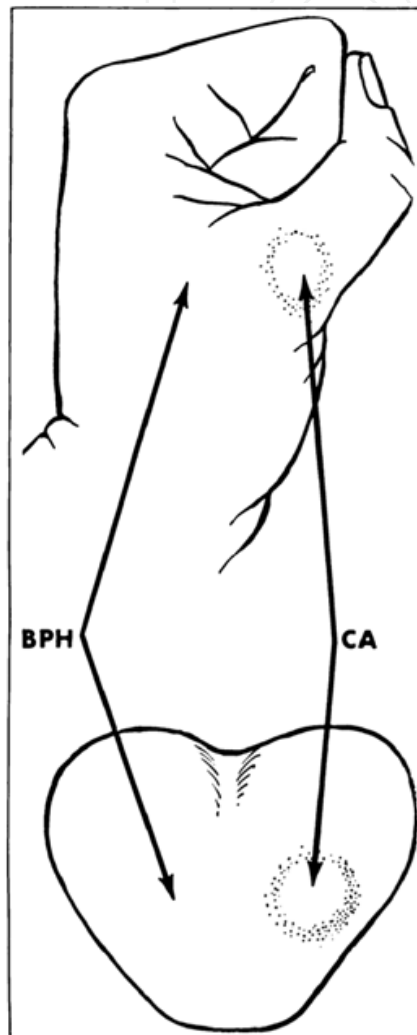


Fig. 2. Any hard lump of prostate was considered indicative of cancer unless proven otherwise (Grabstald, 1965a; Kaufman et al., 1954)

These findings along with a freely mobile prostate, normal serum acid phosphatase and normal skeletal radiographs suggested organ-confined disease and provided enough evidence to initiate radical treatment.

In 1953, Colby retrospectively reviewed 100 prostatectomy specimens for presumed prostate cancer and of these 42 were performed solely on the basis of an abnormal digital rectal examination (DRE) (Colby 1953). He found that without a histological diagnosis the surgeon correctly diagnosed cancer only 58% of the time consequently 42% of patients had had prostatectomy for benign disease. He concluded that "it seems unwise to embark upon

radical surgery of the prostate without definite histological evidence of cancer". Clearly over diagnosis of prostate cancer was a significant problem and therefore it was important for the physician to obtain prostate biopsies for tissue diagnosis if there was any suspicion of prostate cancer, and certainly prior to any planned radical surgery or indeed surgical castration by way of orchidectomy.

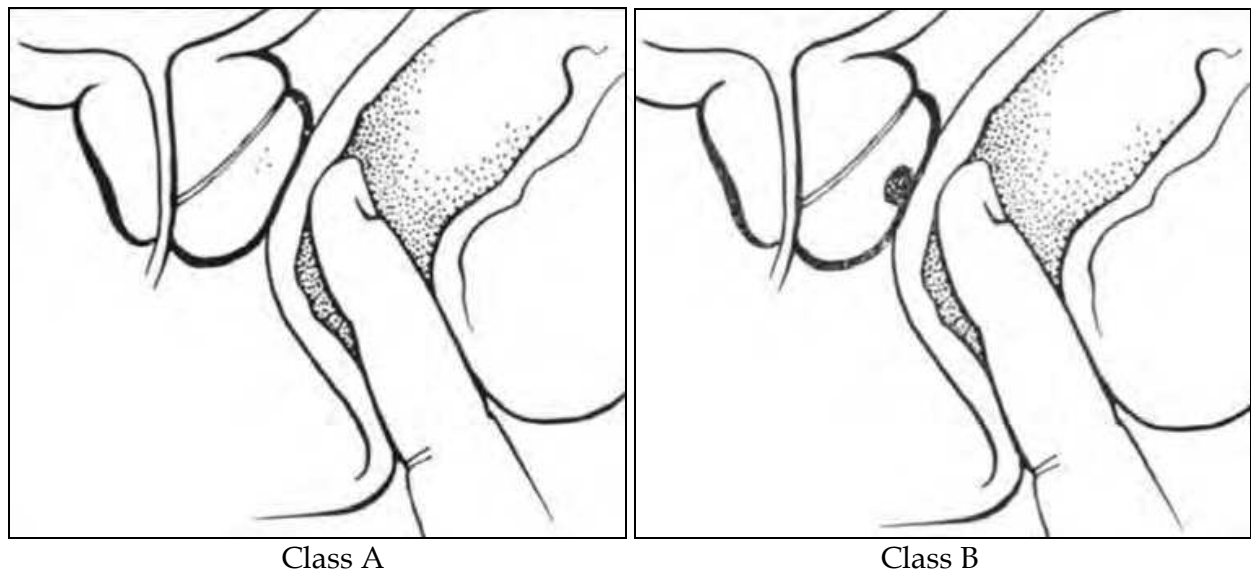


Fig. 3. The early clinical classification of prostate based on digital rectal examination.

Class A (Latent): occult cancer and normal DRE, diagnosis is usually made following surgical removal for supposedly benign prostatic hypertrophy; class B (Early): an isolated small nodule is palpated within the prostatic capsule and has not metastasized (Grabstald, 1965c)

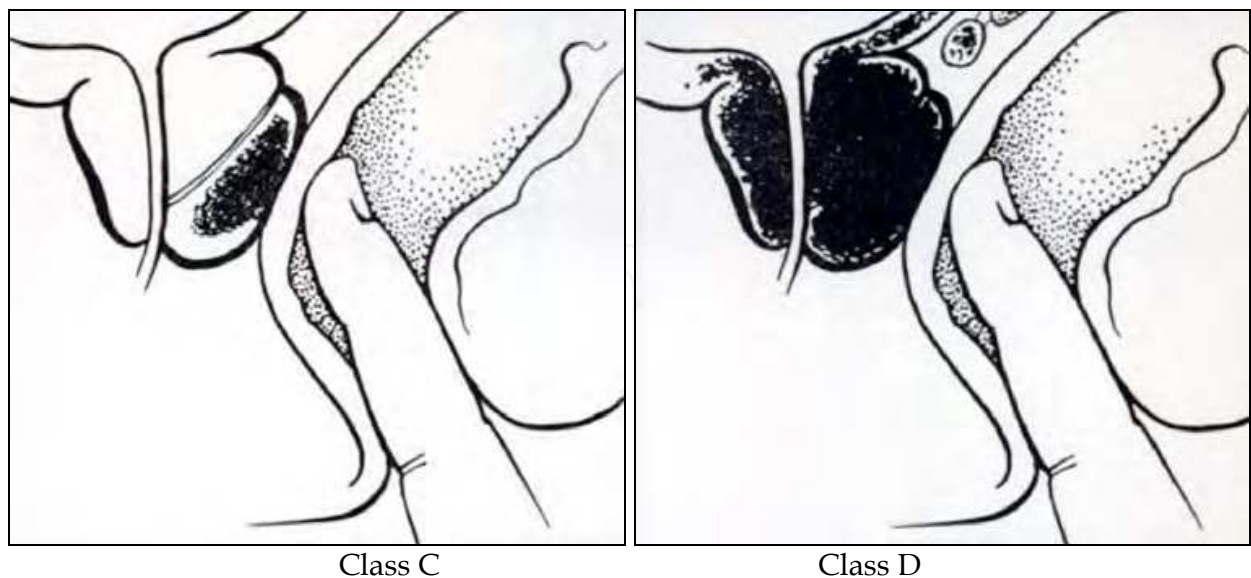


Fig. 4. The early clinical classification of prostate based on digital rectal examination.

Class C (Advanced): locally extensive and may involve one or both lobes, but has not metastasized; class D (Metastases): usually similar to class C but has metastasized (Grabstald, 1965c)

### 3. Transperineal biopsy

#### 3.1 Open

The earliest method of collecting prostatic tissue was by open perineal biopsy and this was once considered the most accurate technique available to detect prostate cancer. The method was mainly used in patients who were subsequently likely to require curative prostatectomy.

The procedure described by Young involved a transverse incision between the ischial tuberosities 2 cm above the anus (Young, 1926). The ischiorectal fossa was then opened by blunt finger dissection, carrying the dissection medially and reflecting the rectum posteriorly. The central tendon of the perineum was then cut exposing the recto-urethralis muscle which was opened by sharp dissection and reflected laterally, exposing the capsule of the prostate (figure 5). The abnormal area on the prostate was grasped with Allis forceps and excised widely and deeply. The cut edges of the prostate were then brought together with sutures.

Reports suggested frozen-section diagnoses should be more than 95% accurate although the risks of incontinence and erectile dysfunction were present. Consequently it was not a technique to be used in any numbers and also required a general anaesthetic and a week of hospitalization (Peirson and Nickerson, 1943).

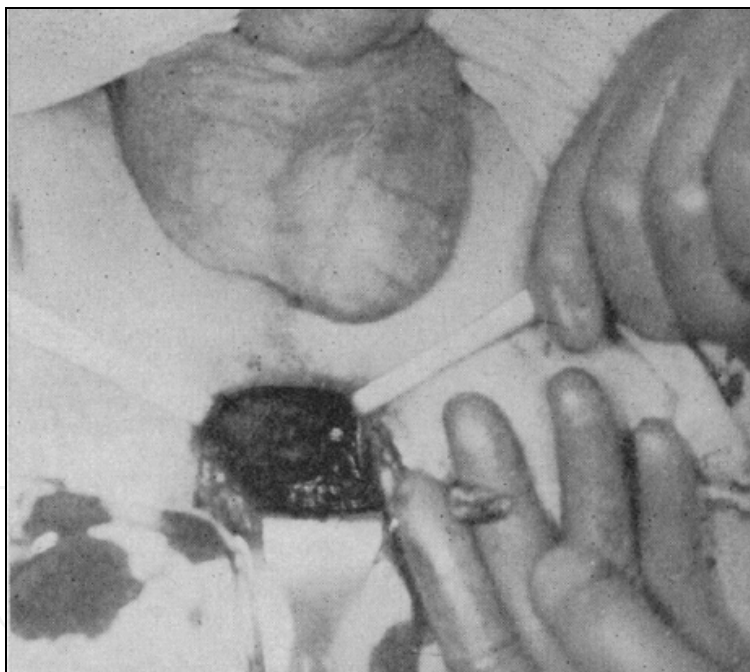


Fig. 5. Open perineal biopsy of prostate with the prostate exposed (Kaufman et al., 1954).

#### 3.2 Needle

A technique that carried less risk and could be performed as an office procedure was the method of needle biopsy of the prostate through the perineum. The first description came in 1922 from Barringer who adopted Martin and Ellis' technique of needle puncture for acquiring tissue for histological analysis (Barringer, 1922). He described the use of a screw tip needle to obtain a perineal punch biopsy and was successful in obtaining prostatic tissue in 16 out of 33 patients.

In 1930 Ferguson modified the technique and published his series of 280 patients who had prostate needle aspiration biopsy using an 18-gauge needle via the transperineal approach and was able to remove adequate tissue in 78 to 86% of his cases (Ferguson, 1930) (figure 6). The patient was placed in the lithotomy position and local anaesthetic was infiltrated just lateral to the median raphe 1cm anterior to the anus. The index finger of the left hand was introduced into the rectum guiding an 18 gauge needle introduced into the perineum taking care to avoid the rectum and urethra. As the needle reached the prostatic capsule the plunger attached to the needle was drawn out creating a high vacuum system and simultaneously the needle was advanced through the abnormal nodule. This resulted in a small plug of tissue sharply cut within the needle. In order to cut off the tissue the needle was withdrawn 0.5-1 cm and advanced at a different angle ensuring negative pressure was maintained on the plunger whilst the needle was withdrawn to the prostatic capsule and only then the plunger was slowly released and disconnected from the needle. The biopsy needle was the quickly removed from the perineum and the tissue in the needle expressed onto a slide by re-inserting the obturator through the needle.

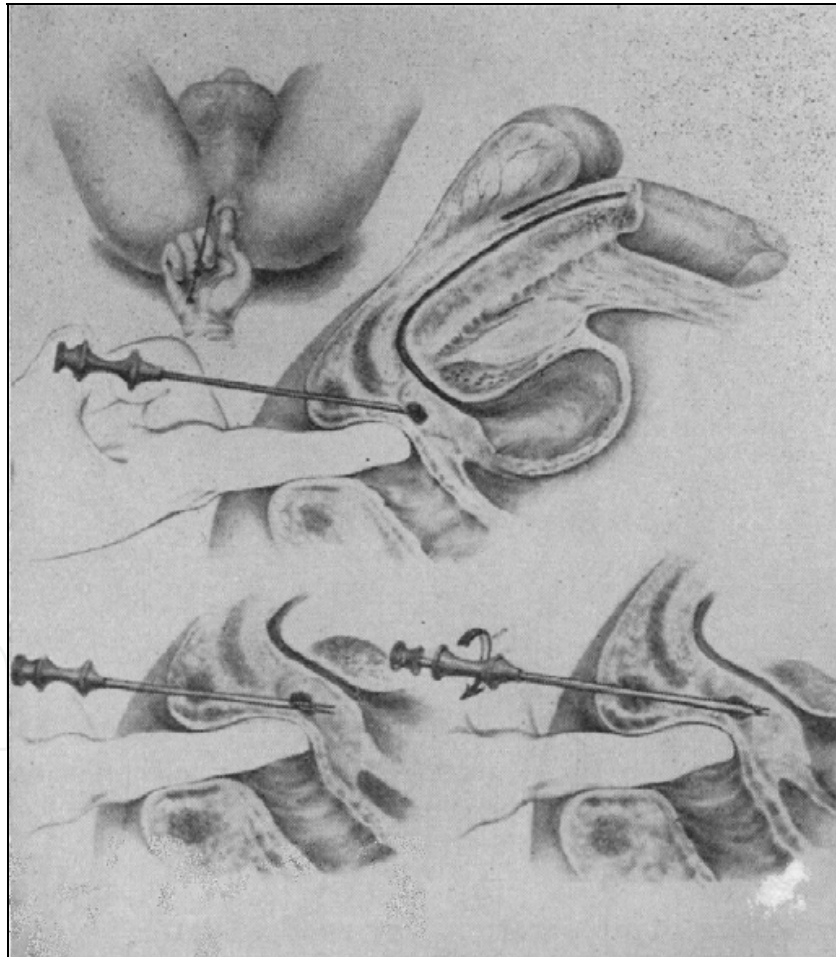


Fig. 6. Transperineal needle biopsy of the prostate (Kaufman et al., 1954)

With regards to needle aspiration, Peirson and Nickerson argued that the punch technique was more useful since in their experience it was not always possible to obtain sufficient tissue via needle aspiration and furthermore the tissue obtained amounted to a smear of

cells on the slide with loss of architecture thus making diagnosis difficult (Peirson and Nickerson, 1943). Barringer also commented that they could detect prostate cancer early only 50% of the time by aspiration biopsy (Barringer 1942).

Enthusiasm for needle prostate biopsy dwindled during the 1940s as a number of negative articles were published by prominent urologists. One report described two patients who had negative prostate biopsies and later developed advanced prostate cancer (Boyd and Nuckells, 1940).

Unfortunately not much more was published about prostate aspiration biopsies for the next 20 years. Then in 1960 Parry and Finelli described a modified method which was highly successful in allowing a directed biopsy through the perineum (Parry and Finelli, 1960). Their technique afforded greater needle control by using digital-guidance. The needle was introduced 1cm above the anus just to the right of the midline depending on the location of the lesion and with a finger in the rectum the surgeon follows the needle point along its entire course from within the anal sphincter to the prostatic nodule allowing the prostate to be stabilized in contrast to the later described method of transrectal digital guided biopsy where the nodule tended to get pushed away from the needle. Kaufman et al. also used the same technique (figure 6) and recommended that if the biopsy was benign the test could be repeated or the urologist could even proceed to open perineal exposure (figure 5) to take more histological material (Kaufman et al., 1954).

Certainly as the techniques and expertise improved reports suggested an overall 88% rate of accuracy when used to obtain tissue from a suspicious area in the prostate. Furthermore advantages were that the tissue could be studied on permanent rather than on frozen sections and repeat biopsy was easily accomplished, local anaesthetic was generally sufficient, there were little risks of erectile dysfunction, rectal injury or incontinence (Grabstald, 1965b) and it was believed that the possibility of causing seeding along the needle tract was remote (Kaufman et al., 1954).

#### **4. Transurethral biopsy**

Transurethral biopsy of the prostate was another approach that had been described but unlike the previous method described it required a general anaesthetic and a period of hospitalization. Denton et al. held that an extensive transurethral prostatectomy would nearly always confirm the diagnosis (Denton et al., 1967) and Grabstald commented that this transurethral biopsy might be useful in advanced tumours (Grabstald, 1965b).

However it was well known that prostate cancer was more frequently seen posteriorly and near the capsule and thus was not easily reached with the resecting loop since only the tissue within the prostatic urethra was sampled (Peirson and Nickerson, 1943; Kaufman et al., 1954). In a series published by Peirson and Nickerson, one patient had 4 grams of tissue resected for histology during transurethral prostate biopsy and this was later found to be benign. However since DRE was suspicious for cancer a perineal punch biopsy with the Silverman needle was performed and this subsequently revealed malignancy (figure 7) (Peirson and Nickerson, 1943). Consequently Kaufman et al. held that the procedure should not be performed as a primary biopsy technique but it may be useful to perform transurethral resection in those symptomatic of obstructive urinary symptoms (Kaufman et al., 1954). Indeed Purser et al. found that tissue taken via needle biopsy was more reliable than a limited specimen obtained via the urethra (Purser et al, 1967).

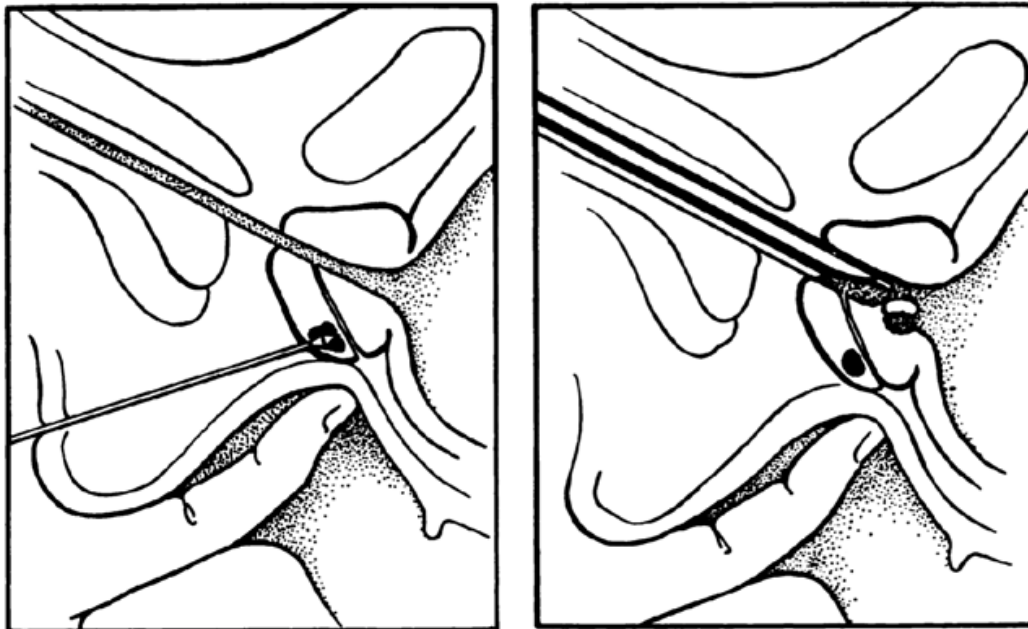


Fig. 7. The methods of perineal and transurethral prostate biopsies (Grabstald, 1965b)

## 5. Transrectal approach

By this period the usual procedure to obtain prostate biopsies was via the perineal route, however, the safety of transrectal approach was assured (Grabstald and Elliot, 1953; Grabstald, 1955 and 1956; Graham, 1958; Daves et al., 1961).

### 5.1 Transrectal needles: Aspiration and core biopsy

Various needles were used to collect tissue for cytological or histological diagnosis. Franzen et al. developed a fine needle and guide for prostatic aspiration by the transrectal route (figure 8). The Franzen needle and guide were designed to allow accurate needle placement into the abnormal area palpated by the fingertip. It was secured by the metal ring fixed to the fingertip and a plate in the palm of the hand. A rubber fingerstall was pulled over it and a 23- or 25-gauge needle was used. Up to six passes could be made in one session (Berner and Orell, 2010). Using this needle Williams et al. were able to achieve satisfactory results (Williams et al., 1967).

The Silverman needle, designed in 1938, was first to be used to take prostatic tissue by Peirson and Nickerson and they published their cohort of 36 patients (Peirson and Nickerson, 1943). They were able to achieve satisfactory histological specimens in 86% of cases.

A specific comparison of the Franzen and Silverman needles was undertaken by Hendry and Williams and their findings were published in 1971 (Hendry and Williams, 1971). The Franzen needle provided cytological diagnosis and carried advantages of causing less morbidity and could be carried out on an outpatient basis, however the likelihood of missing a cancer was greater compared with using the Silverman needle. The latter provided histological diagnosis and resulted in a lower false negative rate but required a general anaesthetic. Ultimately their recommendations were that the Franzen technique could be used as an initial investigation, however should the test prove negative then it could be repeated, and thereafter the urologist could proceed to the Silverman technique.






Fig. 8. The Franzen needle and guide with Gillette Scmitar disposable syringe

The Gillette Scmitar was found to be more effective at aspiration (Hendry and Williams, 1971). Other investigators found that using either the Franzen needle method or a larger bore needle to withdraw histological material produced equal chances of obtaining sufficient tissue for diagnosis (Andersson et al., 1967; Ekman et al., 1967). Furthermore Alfthan et al. documented that tissue obtained by needle aspiration was as reliable for diagnosis as histological samples produced by transperineal Silverman needle (Alfthan et al., 1968).

### 5.2 Digital-guidance

Finger-guided needle biopsy of the prostate through the rectum was used widely as a technique from the mid 1950s, although Astraldi can be credited with carrying out the first transrectal prostate biopsy (Astraldi, 1937). This approach offered more promise of diagnostic accuracy when sampling a prostatic nodule compared with perineal needle biopsy (Barnes, 1959).

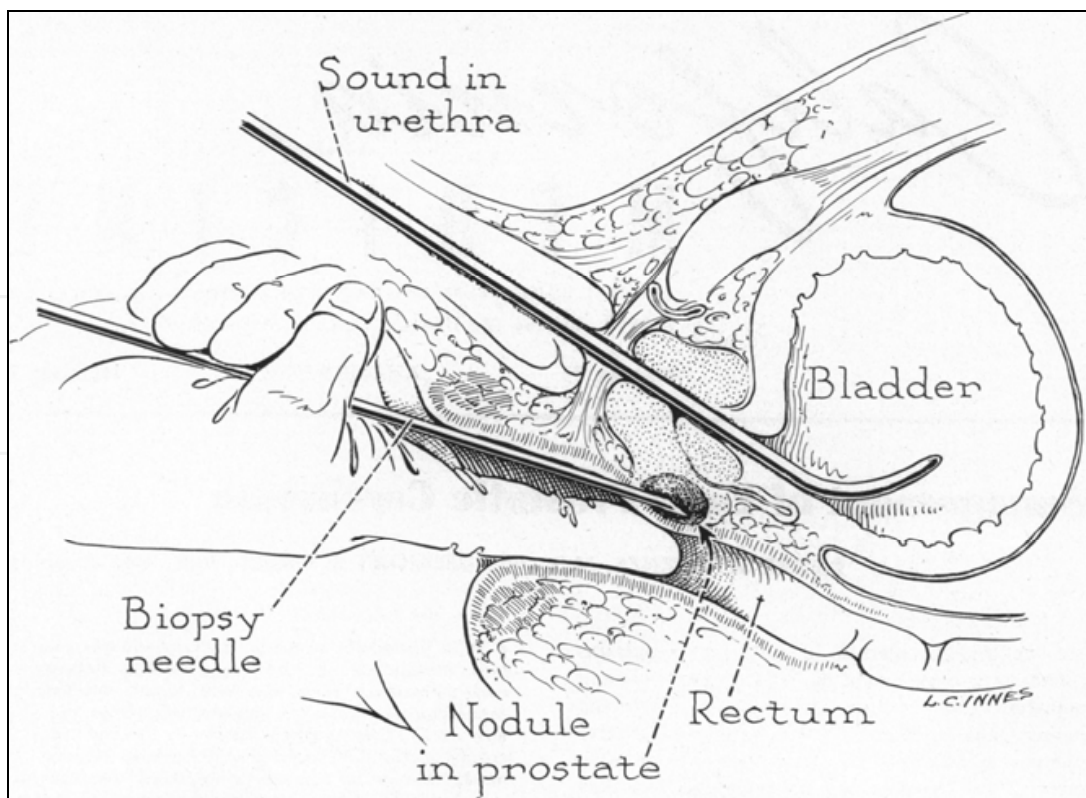


Fig. 9. Digitally-guided transrectal biopsy of the prostate with the aid of a urethral sound.

The sound in the urethra allowed the prostate to be directed posteriorly to facilitate palpation of the nodule and placement of the Silverman needle (Barnes & Emery, 1959).

The patient would be anaesthetized and positioned in lithotomy. An initial digital rectal examination (DRE) was performed to ensure an empty rectum and an ounce of antiseptic solution was instilled per rectally for ten minutes. Agents used included Vioform (iodochlorhydroxyquin U.S.P) 3% Betadine (providone-iodine) or Triophyll (tri-iodophynol). A sound was inserted transurethrally by an assistant to displace the prostate dorsally and towards the anal outlet (figure 10). With a gloved index finger inserted into the rectum with a Silverman biopsy needle applied close to the finger with the tip of the needle in line with the tip of the finger and the bevel edge facing away from the finger. The needle is then rotated half a turn so that the beveled edge is against the finger. This avoided an inadvertent needlestick injury. The abnormal area was palpated and the needle directed through the rectal mucosa and towards the area, but not into it. The obturator was then removed and a bivalved biopsy obturator was inserted through the needle and into the prostate. The bivalved biopsy obturator is held static whilst the needle is rotated and advanced about 1.5cm. The bivalved obturator is then removed from the needle and a core of tissue is taken from between its blades

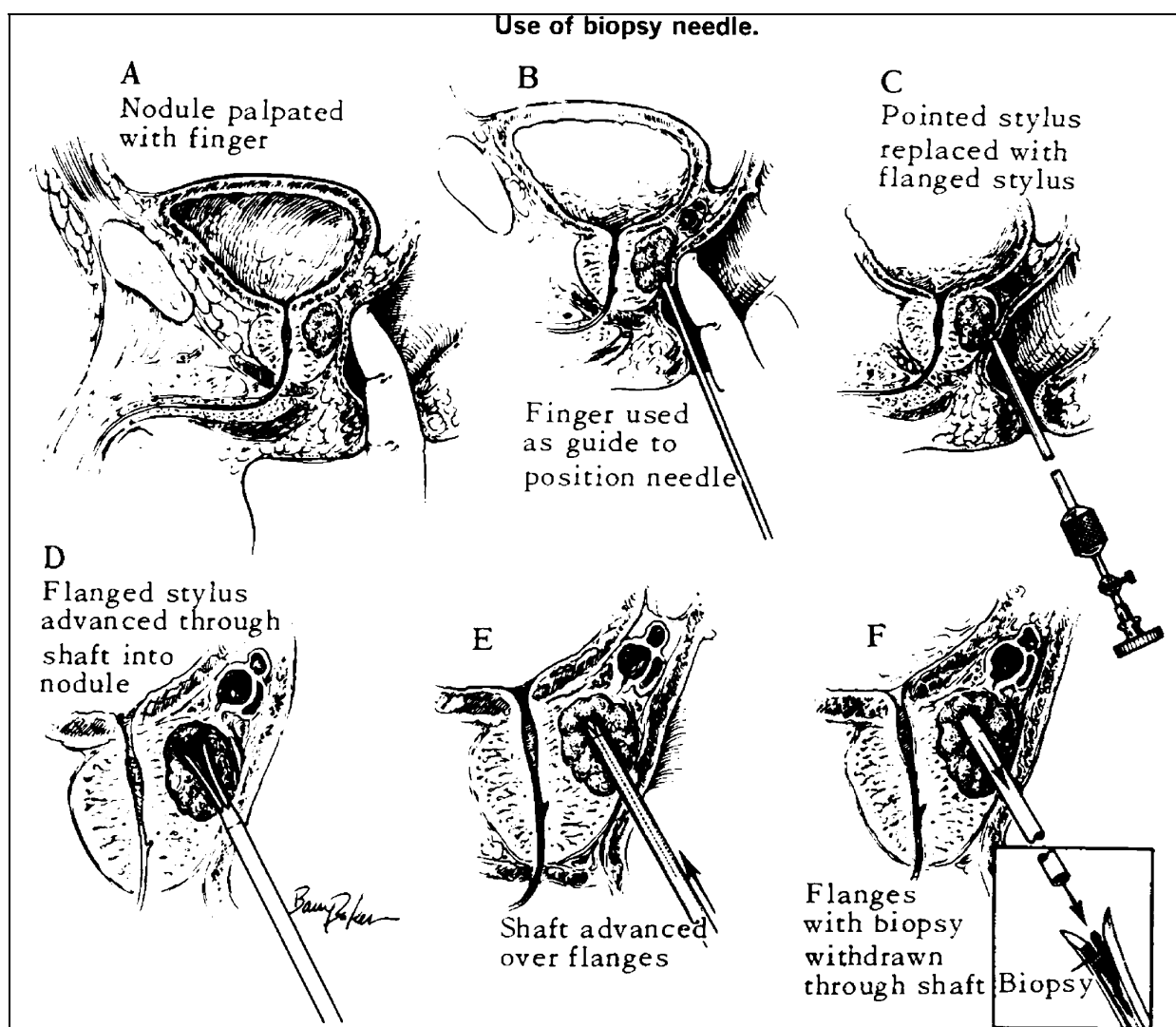


Fig. 10. Digital-guided transrectal biopsy of the prostate

### 5.3 Open transrectal biopsy

This method was performed using a proctotomy incision and the advantage of this was that it allowed access to the very portion of the prostate that was most often involved in cancer, the posterior lobe, and furthermore larger pieces of material could be extracted (figure 11) (Grabstald, 1965b). The drawback of the procedure was that subsequent radical surgery was difficult using the retropubic approach in terms of dissection and also cases of rectourethral fistulae had been reported (Grabstald, 1965b).

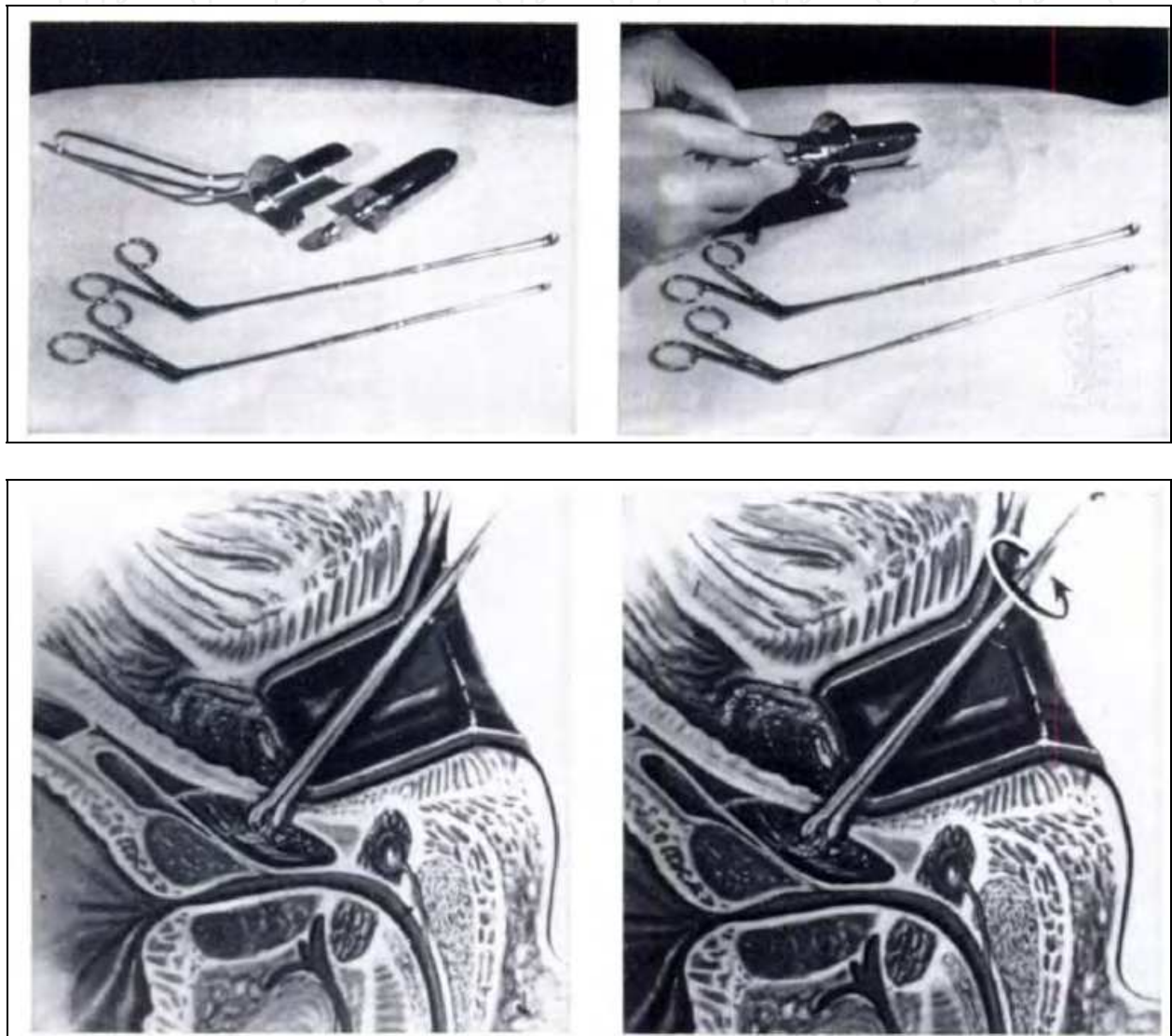


Fig. 11. Open transrectal biopsy of the prostate (Grabstald, 1965b)

### 5.4 Ultrasound-guided transrectal biopsy

#### 5.4.1 The development of ultrasound imaging

Biopsy techniques continued to be digitally-guided until the development of ultrasound imaging. Takahashi and Ouchi were the first to describe the use of transrectal ultrasound to evaluate the prostate (Takahashi & Ouchi, 1963). However the image quality was too poor to be of any clinical use. It was Watanabe et al. who are credited with obtaining the first clinically useful transrectal images of the prostate. They used a 3.5MHz probe, which was

considered to be state of the art at the time, although image quality was relatively poor (Watanabe et al., 1967).

It was not until the 1980s when technological advances in probe manufacture and the development of attachable biopsy apparatus that ultrasound became clinically useful for the diagnosis of prostate cancer. A 7MHz probe was developed allowing delineation of the architecture of the prostate and extensive research was carried out to identify sonographic appearances of prostate cancer. Concurrently serum prostate specific antigen (PSA) testing was introduced and elevated levels prompted further investigations.

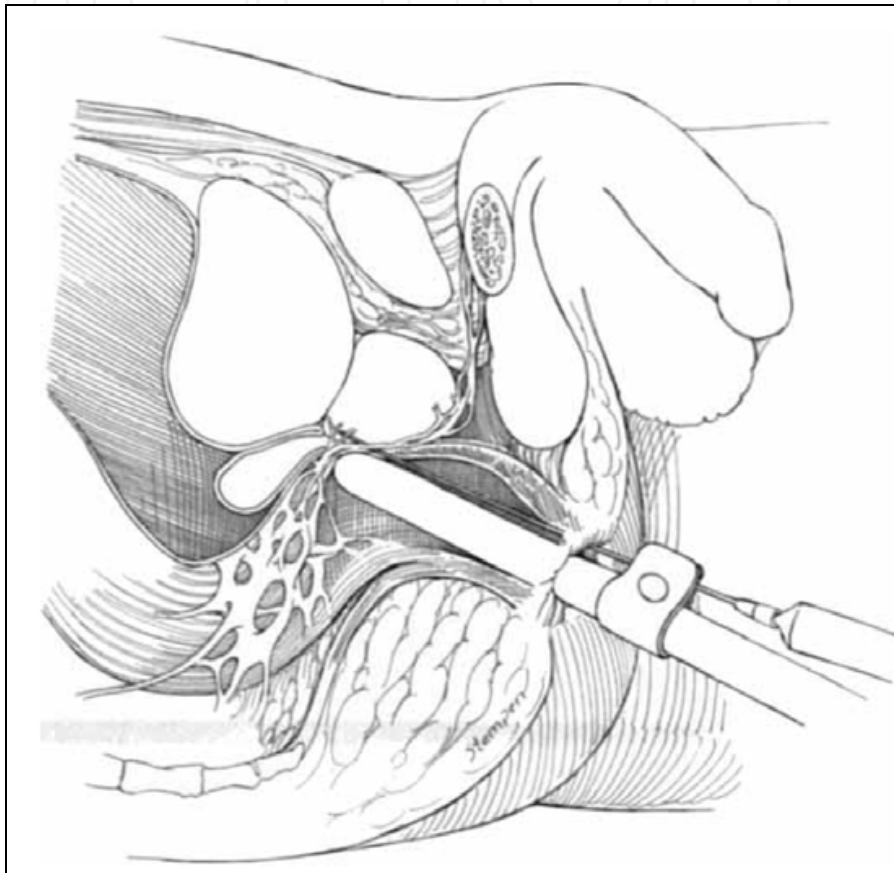


Fig. 12. Transrectal ultrasound probe in situ (Nash et al., 1996)

#### 5.4.2 Sonographic appearances of prostate cancer

Detailed research on prostate anatomy was also carried out and McNeal proposed that the prostate was composed of three distinct glandular zones, namely transitional zone, peripheral zone and central zone (McNeal, 1968). The clinical relevance became important considering that the majority (70-80%) of cancers arise in the peripheral zone.

The findings of research into ultrasound appearances of prostate cancer confirmed varying characteristics and early stage lesions were seen to be indistinct from normal prostatic tissue, indicating that TRUS as a diagnostic tool lacked specificity and had limitations. With the widespread use of serum PSA testing came the detection of early stage, low volume cancers that did not necessarily have any palpable abnormality or specific sonographic findings. In response, the method of sampling the prostate gland had to change and that change occurred in 1989.

## 6. The modern era of prostate needle biopsy

### 6.1 The sextant method

In 1989, Hodge et al. published two papers in the *Journal of Urology* (Hodge et al., 1989a and 1989b). The first paper described directed transrectal prostate biopsies of palpable abnormalities, 90% of which had corresponding hypoechoic lesions on ultrasound (Hodge 1989a). Additional biopsies were also taken of isoechoic areas of the peripheral and central zones. These biopsies were not systematic and they were found to be positive in 66% of cases.

The second article was a landmark paper which marked the start of the modern era of prostate needle biopsy (Hodge et al., 1989b). Hodge et al. compared the use of transrectal prostate biopsies taken of palpable or sonographic abnormalities to those taken in a random systematic fashion. The latter method involved taking biopsies from six sites: the apex, middle and base of each prostate lobe, parasagittally, in addition to any hypoechoic lesion seen on ultrasound. This sextant technique detected 9% more cancers compared with the former method. As a result of this there was a shift away from lesion-directed biopsies to a method of systematic sampling of the prostate using transrectal ultrasound to guide accurate needle placement.

The Hodge protocol of systematic sextant biopsy of the prostate became the gold standard for many years in an era when an elevated PSA was an acceptable indication for prostate biopsy regardless of DRE findings.

### 6.2 Beyond sextant biopsies

Some years later Stamey modified the sextant technique and took sextant biopsies that were lateral to the mid-sagittal plane in the peripheral zone where most prostate cancers are typically located (Stamey, 1995). Other investigators went on to study alternatives to the traditional sextant biopsy, namely the optimum number of core biopsies for diagnosis as well as sampling of the transition zone in an effort to improve the negative predictive value of prostate biopsy.

Intuitively researchers began sampling more prostatic tissue however the procedure was not without pain. Sixty-five to 90% of patients experienced discomfort (Clements et al., 1993; Collins et al., 1993) and this discomfort was proportional to number of cores taken (Nash et al., 1996). A pioneering report published by Nash et al. provided evidence that effective pain relief could be achieved by infiltrating local anaesthetic (Nash et al., 1996). And so with the introduction of the peri-prostatic nerve blockade it became possible to take 10 to 18 or even 20 biopsies.

Eskew et al. introduced the systematic extended biopsy technique and described the 5-region biopsy protocol whereby conventional sextant biopsies were taken along with two additional cores from the far lateral portion of each side and three centralized cores (Eskew et al., 1997). When the prostate gland was over 50cc, one additional core is taken per region. Thirty-five percent of those patients diagnosed with prostate cancer were found to have cancers in the extra five biopsies sites and not in the sextant regions. Eighty-eight percent of those were located in the far lateral zones, 12% in the central zone.

Levine et al. published a series which involved 137 men with abnormal DRE findings or a raised serum PSA. These patients underwent two independent consecutive sets of sextant biopsies at the same sitting (Levine et al., 1999). They showed an increase in prostate cancer detection from 21% in sextant biopsy alone to 31% with the additional six biopsies.

Presti et al. took two extra biopsies laterally on each side at the base and mid gland in addition to the traditional sextant technique in an effort to include more peripheral zone tissue in their sampling (Presti et al., 2000). This produced a 10-core biopsy. They enrolled 483 men with either abnormal DRE or a PSA  $\geq 4$  ng/mL. On analysis of the cancer detection rate from each side, it was discovered that the traditional sextant technique missed 20% of cancers. Eight cancers were missed by the 10-biopsy scheme and were detected by lesion-directed or transition zone biopsies instead, for a detection rate of 96%. By eliminating the sextant base biopsies, the detection rate was 95%. Therefore the authors concluded that the optimum protocol was an 8-core biopsy scheme.

An 11-core biopsy protocol was investigated by Babaian et al. and involved using the traditional sextant sites as well as the anterior horn on each side (lateral anterior peripheral zone), transition zone on each side (anterior to and next to the urethra), and one mid-gland biopsy (Babaian et al., 2000). A 33% increase in prostate cancer was found using these additional zones, with the anterior horn being the most frequently positive biopsy site.

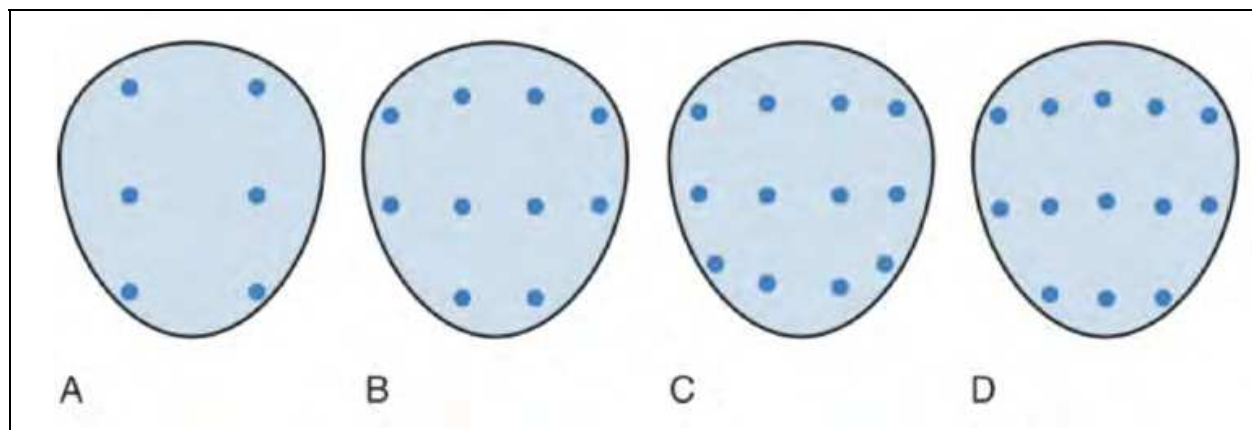


Fig. 13. Various reported systematic biopsy schemes.

Base is at the top of the figure, apex is at the bottom.

A. Sextant biopsy scheme originally proposed by Hodge et al.; B. The 10-core biopsy of Presti et al.; C. The 12-core, or double sextant biopsy of Levine et al. D. The 13-core, 5-region biopsy of Eskew et al. (Wein et al., 2007)

Studies were also carried out on digitally-reconstructed radical prostatectomy specimens which showed the inadequacy of the traditional sextant biopsy method. In one study by Chen et al., simulation biopsy strategies were conducted on whole-mount radical prostatectomy specimens from 180 patients and it was found that only 73% of cancers were detected by sextant biopsy (Chen et al., 1997). Using a 10-core biopsy scheme, incorporating the midline peripheral zone, the inferior portion of the anterior horn of the peripheral zone, and the transition zone, they picked up 96% of cancers with a volume  $\geq 0.5$ cc (clinically significant).

Bauer et al. studied 201 step-sectioned whole mount radical prostatectomy specimens and mapped out the location of the cancers using a 3-dimensional computer simulation (Bauer et al., 1999). They calculated that a 10- or 12-core, laterally-directed biopsy protocol would detect 99% of the cancers, while the traditional sextant protocol would detect only 72.6%.

One of the concerns of increasing the number of prostate biopsies was causing the patient increased discomfort. Naughton et al. carried out a prospective randomized study to assess the pain and morbidity associated with 6 biopsies compared with 12 (Naughton et al., 2000). They concluded that there was no difference in the discomfort experienced, and no increase rate in moderate or major problems, although there was a higher rate of haemospermia (89% versus 71%) and rectal bleeding (24% versus 10%).

### **6.3 Saturation biopsies**

With increasing number of cores came the concept of saturation biopsy, a term coined by Stewart et al. (Stewart et al., 2001), in which 20 or more systematic cores were taken. Djavan et al. developed tables to recommend more cores for larger glands, but these met with little clinical acceptance (Djavan et al., 1999).

These saturation biopsies have been offered to those who have had previous negative biopsies but continue to have clinical suspicion for prostate cancer. This technique is generally not considered as an initial biopsy strategy since the cancer detection rates compared with extended protocols is no greater (de la Taille et al., 2003; Guichard et al., 2007).

In a series by Djavan et al. a 24-core biopsy template was used in 116 patients with a previous negative biopsy and yet suspicious findings for a missed tumour (Djavan et al., 2001). The saturation biopsy technique noted a 41% cancer detection rate in patients who had undergone previous sextant biopsy.

### **6.4 Transperineal template biopsies**

Although transperineal prostate biopsy with TRUS guidance was described in 1981 (Holm and Gammelgaard, 1981), more recent research has been undertaken on this previously used transperineal approach with the additional use of templates. This has facilitated control of the biopsy gun and allowed uniform sampling of the whole prostate. Furthermore there has been growing interest in the use of brachytherapy grid to take transperineal biopsies and therefore saturate the entire gland. Fewer complications have been reported with this technique and yet a greater detection rate of prostate cancer.

## **7. Conclusion**

The history of the development of prostate biopsy has changed significantly from random biopsies, to systematic to extended biopsy schemes. Systematic sextant biopsies, even when laterally directed, do not provide adequate sampling of the prostate. Ultimately the sextant biopsy technique has now become obsolete in favour of more extended biopsy protocols. To date there is no consensus on the optimal number of cores without significantly increasing morbidity but it has been shown that as prostate gland size increases, the yield of sextant biopsy has decreased (Karakiewicz et al., 1997). Based on published data it appears that between 8 and 12 cores would be an acceptable protocol.

Essentially the role of TRUS as an imaging tool of the prostate remains vital for accurate needle placement and sampling of the prostate as well as taking volume measurement. TRUS technology has also become the mainstay of other image-guided prostate interventions such as brachytherapy, cryotherapy and high-intensity frequency ultrasound (HIFU), as well as being used in the evaluation of appropriate patients for treatment of benign prostatic hyperplasia (Beerlage, 2003).

## 8. References

- Aarnink, R.G., Beerlage, H.P., de la Rosette, J.J. et al. Transrectal ultrasound of the prostate: innovations and future applications. *J Urol.* 1998; 159: 1568-1579
- Alfthan, O., Klintrup, H.E., Koivuniemi, A. et al. Comparison of thin-needle and Vim-Silverman-needle biopsy in the diagnosis of prostatic cancer. *Duodecim.* 1968; 84: 506
- Andersson, L., Jonsson, G. and Brunk, U. Puncture biopsy of the prostate in the diagnosis of prostatic cancer. *Scand J Urol and Neph.* 1967; 1: 227
- Applewhite, J.C., Matlaga, B.R, McCullough, D.L. et al. Transrectal ultrasound and biopsy in early diagnosis of prostate cancer. *Cancer Control.* 2001; 8(2): 141-150
- AstralDI, A. Diagnosis of cancer of the prostate: biopsy by rectal route. *Urol Cutan Rev.* 1937; 41: 421-427
- Babaian, RJ, Toi, A., Kamoi, K., et al. A comparative analysis of sextant and an extended 11-core multisite directed biopsy Strategy. *J Urol.* 2000; 163: 152-157
- Barnes, R.W. and Emery, D.S. Management of early prostatic carcinoma. *Calif Med.* 1959; 91(2): 57-61
- Barringer, B.S. Carcinoma of the prostate. *Surg Gynecol Obstet.* 1922; 34: 168-176
- Barringer, B.S. Prostatic carcinoma. *J Urol.* 1942; 47: 306-310
- Bauer, J.J., Zeng, J., Weir, J., et al. Three-dimensional computer-simulated prostate models: Lateral prostate biopsies increase the detection rate of prostate cancer. *Urology.* 1999; 53: 961-967
- Beerlage, H.P. Alternative therapies for localized prostate cancer. *Curr Urol Rep* 2003; 4: 216-220
- Berner, A. and Orell, S.R. Prostate gland, In: *Diagnostic Cytopathology*, Gray W and Kocjan G (Ed.), 527-536. ISBN 0702031542, 9780702031540, Elsevier Health Sciences, Churchill Livingstone, 2010
- Boyd, M.L., Nuckolls, J.B. Carcinoma of the prostate. *J Med Assoc Georgia.* 1940; 29: 493-499
- Chen, M.E., Troncoso, P., Johnston, D.A., et al. Optimization of prostate biopsy strategy using computer based analysis. *J Urol.* 1997; 158: 2168-2175
- Clements, R., Aideyan, O.U., Griffiths, G.J. et al. Side effects and patient acceptability of transrectal biopsy of the prostate. *Clin. Rad.* 1993; 47: 125
- Colby, F.H. Carcinoma of the prostate: results of the total prostatectomy. *J Urol.* 1953; 69: 797-806
- Collins, G.N, Lloyd, S.N., Hehir, M. et al. Multiple transrectal ultrasound-guided prostatic biopsies - true morbidity and patient acceptance. *BJU.* 1993; 71: 460
- Daves, J.A., Tomskey, G.C., and Cohen, A.E. Transrectal needle biopsy of the prostate. *J Urol.* 1961; 85: 180
- de la Taille, A., Antiphon, P., Salomon, L., et al. Prospective evaluation of a 21-sample needle biopsy procedure designed to improve the prostate cancer detection rate. *Urology* 2003; 61: 1181-1186
- Denton, S.E., Valk, W.L., Jacobson, J.M. et al. Comparison of the perineal needle biopsy and the transurethral prostatectomy in the diagnosis of prostatic carcinoma: an analysis of 300 cases. *J Urol.* 1967; 97: 127




- Djavan, B., Zlotta, A.R., Remzi, M., et al. Total and transition zone prostate volume and age: how do they affect the utility of PSA-based diagnostic parameters for early prostate cancer detection? *Urology* 1999; 54: 846–852
- Djavan, B., Ravery, V. and Zlotta, A.R. Prospective evaluation of prostate cancer detected on biopsies 1, 2, 3 and 4: when should we stop? *J Urol.* 2001; 166: 1269–1283
- Ekman, H., Hedberg, K. and Person, P.S. Cytological versus histological examination of needle biopsy specimens in the diagnosis of prostatic cancer. *BJU.* 1967; 39: 544
- Eskew, L.A., Bare, R.L. and McCullough, D.L. Systematic 5 region prostate biopsy is superior to sextant method for diagnosing carcinoma of the prostate. *J Urol.* 1997; 157: 199–202
- Ferguson, R.S. Prostatic neoplasms: their diagnosis by needle puncture and aspiration. *Am J Surg* 1930; 9: 507–511
- Ferguson, R.S. Diagnosis and treatment of early carcinoma of the prostate. *J Urol.* 1937; 37: 774–782
- Grabstald, H. Further experience with transrectal biopsy of the prostate. *J Urol.* 1955; 74: 211–212
- Grabstald, H. Summary of currently employed prostatic biopsy methods, with comments concerning combined transrectal biopsy and radical retropubic prostatectomy. *BJU.* 1956; 28: 176.
- Grabstald, H. The clinical and laboratory diagnosis of cancer of the prostate. *A Cancer Journal for Clinicians*; 1965a: 15: 76–81
- Grabstald, H. Biopsy techniques in the diagnosis of cancer of the prostate. *A Cancer Journal for Clinicians*; 1965b: 15: 134–138
- Grabstald, H. The incidence, clinical and pathological classification of cancer of the prostate. *A Cancer Journal for Clinicians.* 1965c; 15: 31–35
- Grabstald, H. and Elliott, J.L. Transrectal biopsy of the prostate. *JAMA.* 1953; 153, 563
- Graham, W.H. Carcinoma of the prostate. *BJU.* 1958; 30: 389
- Guichard, G., Larre, S., Gallina, A., et al. Extended 21-sample needle biopsy protocol for diagnosis of prostate cancer in 1000 consecutive patients. *Eur Urol* 2007; 52: 430–435
- Heidenreich, A., Bolla, M., Joniau, S. et al. Guidelines on prostate cancer. *European Association of Urology*, 2010
- Hendry, W.F. and Williams, J.P. Transrectal Prostatic Biopsy. *BMJ.* 1971; 4: 595–597
- Hodge, K.K., McNeal, J.E., Stamey, T.A. Ultrasound guided transrectal core biopsies of the palpably abnormal prostate. *J Urol.* 1989a; 142: 66–7
- Hodge, K.K., McNeal, J.E., Terris, M.K., et al. Random systematic versus directed ultrasound guided transrectal core biopsies of the prostate. *J Urol.* 1989b; 142: 71–74
- Holm, H.H. and Gammelgaard, J. Ultrasonically guided precise needle placement in the prostate and the seminal vesicles. *J Urol.* 1981; 126: 385
- Huggins, C., and Johnson, M.A.. Cancer of the bladder and prostate. *JAMA.* 1947; 135: 1146–1152
- Jewett, H.J. The present status of radical prostatectomy for stages A and B prostatic cancer. *Urol Clin N Am.* 1975; 2: 105
- Karakiewicz, P.I., Bazinet, M., Aprikian, A.G., et al. Outcome of sextant biopsy according to gland volume. *Urology* 1997; 49:55–59

- Kaufman, J.J., Rosenthal, M. and Goodwin, W.E.. Needle biopsy in diagnosis of prostate cancer. *California Medicine*. 1954; 81; 5: 308-313
- Levine, M.A., Ittman, M., Melamed, J., et al. Two consecutive sets of transrectal ultrasound guided sextant biopsies of the prostate for the detection of prostate cancer. *J Urol*. 1998; 159: 471-475
- McNeal, J.E. Regional morphology and pathology of the prostate. *Am J Clin Pathol*. 1968; 49: 347
- Nash, P.A., Bruce, J.E., Indudhara, R. et al. Transrectal ultrasound guided prostatic nerve blockade eases systematic needle biopsy of the prostate. *J Urol*. 1996; 155: 607-609
- Naughton, C.K., Ornstein, D.K., Smith, D.S., et al. Pain and morbidity of transrectal ultrasound guided prostate biopsy: A prospective randomized trial of 6 versus 12 cores. *J Urol*. 2000; 163: 168-171
- Parry, W.L., and Finelli, J.F. Biopsy of the prostate. *J Urol*. 1960; 84: 643-648
- Peirson, E.L. and Nickerson, D.A.: Biopsy of the prostate with the Silverman Needle. *N Engl J Med*. 1943; 228: 675-678
- Presti, J.C., Chang, J.J., Bhargava, V., et al: The optimal systematic prostate biopsy scheme should include 8 rather than 6 biopsies: results of a prospective clinical trial. *J Urol*. 2000; 163: 163-166
- Purser, B.N., Robinson, B.C., and Mostofi, F.K. Comparison of needle biopsy and transurethral resection biopsy in the diagnosis of carcinoma of the prostate. *J Urol*. 1967; 98, 224
- Scattoni, V., Maccagnano, C., Zanni, G. et al. Is extended and saturation biopsy necessary? *Int J Urol*. 2010; 17: 432-47
- Silletti, J.P., Gordon, G.J., Bueno, R. et al. Prostate biopsy: Past, present and future. *Urology*. 2007; 69: 413-416
- Smith, J.A. Jr. Transrectal ultrasonography for the detection and staging of carcinoma of the prostate. *J Clin Ultrasound*. 1996; 24: 455-461
- Stamey, T.A. Making the most out of six systematic sextant biopsies. *Urology* 1995; 45: 2-12
- Stewart, C.S., Leibovich, B.C., Weaver, A.L. et al. Prostate cancer diagnosis using a saturation needle biopsy technique after previous negative sextant biopsies. *J Urol*. 2001; 166: 1, 86-91
- Takahashi, H. and Ouchi, T. The ultrasonic diagnosis in the field of urology. *Proc Jpn Soc Ultrasonics Med*. 1963; 3: 7
- Watanabe, H., Igari, D., Tanahasi, Y., et al. Development and application of new equipment for transrectal ultrasonography. *J Clin Ultrasound*. 1974; 2: 91-98
- Wein, A.J., Kavoussi, L.R., Novick, A.C., et al (Ed.). *Campbell-Walsh Urology*. Saunders Elsevier. ISBN 13: 978-0-8089-2353-4. 9th Ed, 2007
- Whitmore, W.F., Jr. Hormone therapy in prostate cancer. *Am J Med*. 1956; 21: 697
- Wild, J.J., Reid, J.M. Progress in techniques of soft tissue examination by 15 MC pulsed ultrasound. In: Kelley-Fry E, ed. *Ultrasound in biology and medicine: a symposium sponsored by the Bioacoustics Laboratory of the University of Illinois and the Physiology Branch of the Office of Naval Research*. Robert Allerton Park, Monticello, Ill; June 20-22, 1955. Washington, DC: American Institute of Biological Sciences; 1957: 30-45

- Williams, J.P., Still, B.M., and Pugh, R.C.B. The diagnosis of prostatic cancer: cytological and biochemical studies using the franzen biopsy needle. *BJU*. 1967; 39: 549
- Young, H.H. and Davis, D.M.: *Young's Practice of Urology*. Philadelphia, WB Saunders, 1926; 2: 414-512

IntechOpen

IntechOpen



### **Prostate Biopsy**

Edited by Dr. Nabil K. Bissada

ISBN 978-953-307-702-4

Hard cover, 134 pages

**Publisher** InTech

**Published online** 02, December, 2011

**Published in print edition** December, 2011

Prostate Biopsy represents the standard procedure for diagnosing Prostate Cancer. This procedure can be performed transrectally, through perineum or occasionally through the urethra. Although the procedures of Prostate Biopsy are covered in numerous publications, there is still a need for gathering different aspects and methods in one source. Hopefully, this book will help physicians in their effort to provide the best treatment for their patients.

#### **How to reference**

In order to correctly reference this scholarly work, feel free to copy and paste the following:

Lehana Yeo, Dharmesh Patel, Christian Bach, Athanasios Papatsoris, Noor Buchholz, Islam Junaid and Junaid Masood (2011). The Development of the Modern Prostate Biopsy, Prostate Biopsy, Dr. Nabil K. Bissada (Ed.), ISBN: 978-953-307-702-4, InTech, Available from: <http://www.intechopen.com/books/prostate-biopsy/the-development-of-the-modern-prostate-biopsy>

**INTECH**  
open science | open minds

#### **InTech Europe**

University Campus STeP Ri  
Slavka Krautzeka 83/A  
51000 Rijeka, Croatia  
Phone: +385 (51) 770 447  
Fax: +385 (51) 686 166  
[www.intechopen.com](http://www.intechopen.com)

#### **InTech China**

Unit 405, Office Block, Hotel Equatorial Shanghai  
No.65, Yan An Road (West), Shanghai, 200040, China  
中国上海市延安西路65号上海国际贵都大饭店办公楼405单元  
Phone: +86-21-62489820  
Fax: +86-21-62489821

© 2011 The Author(s). Licensee IntechOpen. This is an open access article distributed under the terms of the [Creative Commons Attribution 3.0 License](#), which permits unrestricted use, distribution, and reproduction in any medium, provided the original work is properly cited.

IntechOpen

IntechOpen