

# We are IntechOpen, the world's leading publisher of Open Access books Built by scientists, for scientists

## 4,800

Open access books available

## 122,000

International authors and editors

## 135M

Downloads

Our authors are among the

## 154

Countries delivered to

## TOP 1%

most cited scientists

## 12.2%

Contributors from top 500 universities

**WEB OF SCIENCE™**Selection of our books indexed in the Book Citation Index  
in Web of Science™ Core Collection (BKCI)

Interested in publishing with us?  
Contact [book.department@intechopen.com](mailto:book.department@intechopen.com)

Numbers displayed above are based on latest data collected.

For more information visit [www.intechopen.com](http://www.intechopen.com)

# Adjuvant Therapy for Resectable Colorectal Cancer Liver Metastases

Yukihide Kanemitsu

*Department of Gastroenterological Surgery, Aichi Cancer Center Hospital  
Japan*

## 1. Introduction

The most effective treatment for liver metastases from colorectal cancer is surgical resection. When curative resection is possible, a 5-year survival rate of 25% to 58% can be expected; the mortality rate associated with surgery is as low as 1% to 5% (Adson et al., 1984; Huges et al., 1986; Scheele et al., 1995; Nordlinger et al., 1996; Jamison et al., 1997; Iwatsuki et al., 1999; Fong et al., 1999; Minagawa et al., 2000; Figueras et al., 2001; Choti et al., 2002; Kato et al., 2003; Abdalla et al., 2004; Fernandez et al., 2004; Wei et al., 2006; Rees et al., 2008) (Table 1).

Surgical procedures are improving for liver resection. In cases with synchronous liver metastases, resection of primary colorectal cancer with lymph node dissection and liver resection were indicated if tumors would be completely removed surgically. In cases with metachronous liver metastases, the indication for liver resection was the same as synchronous liver metastases if extrahepatic metastases were not detected. More recently, experience has demonstrated that patients with the traditional adverse factors can experience long-term survival following liver resection (Minagawa et al., 2000; Elias et al., 2003). Thus, a shift has occurred in the criteria used for assessing resectability, from morphologic criteria to new ones based on whether a macroscopically and microscopically complete resection of the liver can be achieved. These advancements were reported to improve the resectability and survivals of patients. Although evidence from cohort studies or randomized controlled trials are not available to support this conclusion, cases of long-term survival are almost nonexistent among patients who were eligible for surgical resection of liver metastases but did not undergo the procedure. Outcomes after hepatectomy are so good that studies comparing this treatment with other treatments may be difficult to accept. Despite this, recurrence is common after resection of liver metastases. Recurrence in the remaining liver occurs with a frequency of 50% to 60%, followed by lung metastasis at 20% to 30%, and they occur within the first 2 years after surgery. Based on these observations, liver metastasis can be thought of as a local or systemic disease. Thus, improving prognosis after resection of liver metastases likely involves controlling local recurrence (in the remaining liver) and extrahepatic metastases (primarily lung metastases). However, few clinical trials have focused on cases of colorectal cancer after hepatic resection; no adjuvant chemotherapy has yet been proven effective in this context.

Author	Year	Number of patients	Median survival, months	5 year overall survival rate	Mortality, percent
Adson	1984	141	-	25	4
Huges	1986	607	-	33	5
Scheele	1995	350	40	39	4
Nordlinger	1996	1568	-	28	2
Jamison	1997	280	33	27	4
Iwatsuki	1999	305	-	32	1
Fong	1999	1001	42	37	3
Minagawa	2000	235	37	38	-
Figueras	2001	235	46	36	4
Choti	2002	133	-	58	0
Kato	2003	585	-	32	-
Abdalla	2004	190	-	58	-
Fernandez	2004	100	-	58	-
Wei	2006	423	-	47	1
Rees	2008	929	42.5	36	1

Table 1. Results of hepatic resection for metastatic colorectal cancer

## 2. Evidence of adjuvant therapy for resectable liver metastases

### 2.1 Hepatic infusion therapy as adjuvant therapy

Liver metastasis is a local disease limited to the liver. Several comparative studies have evaluated the use of hepatic infusion therapy to prevent recurrence in the remaining liver before secondary metastasis (e.g., lung metastasis) can occur (Table 2). Lorenz et al. conducted a randomized controlled study in Germany with 226 colorectal cancer patients who underwent resection of liver metastasis, comparing the efficacy of surgical resection alone with that of postoperative adjuvant chemotherapy by hepatic arterial infusion of 5-fluorouracil (5-FU) (Lorenz et al., 1998). Results of the interim analysis indicated that the median survival time (MST) after resection alone was 40.8 months, whereas the MST after resection and hepatic arterial infusion chemotherapy was 34.5 months. Because the hepatic infusion group had a lower survival rate at the interim analysis, enrollment was terminated. This study used the “surgery only” group as the control. Hepatic infusion therapy appeared to suppress recurrence in the remaining liver but did not improve survival. With the objective of suppressing both recurrence in the remaining liver and extrahepatic recurrence, Kemeny et al. conducted a randomized controlled study in the United States with 109 colorectal cancer patients after resection of 1 to 3 liver metastases.

They compared results of surgical resection alone with those of postoperative hepatic arterial infusion with floxuridine (FUDR) in combination with systemic chemotherapy with 5-FU (Kemeny et al., 2002). The 4-year disease-free survival rate was 25% for the surgery alone group and 46% for the postoperative adjuvant chemotherapy group. However, MST did not differ significantly between the two groups (surgery alone, 49.0 months; postoperative adjuvant chemotherapy, 63.7 months;  $p=0.60$ ), i.e., adjuvant chemotherapy did not prolong survival in this study population. Using a somewhat different approach, Kemeny et al. compared two systemic chemotherapies: 5-FU with or without leucovorin versus hepatic arterial infusion of FUDR plus 5-FU with or without leucovorin. The investigators reported that FUDR combination chemotherapy resulted in better 2-year disease-free survival and 2-year survival rates (Kemeny et al., 1999). However, none of the studies shown in Table 2 clearly demonstrated that adjuvant hepatic arterial infusion chemotherapy is more effective than surgery alone.

Author	Year	N	Regimen	DFS MST, months	DFS, percent	P value	OS MST, mons	OS, percent	P value
Lorenz	1998	226	no	13.7		0.75	40.8		0.15
			HAI 5FU/LV	14.2			34.5		
Kemeny	2002	109	no		4 year, 25%	0.04	49		0.6
			5FU+HAI FUDR		4 year, 46%		63.7		
Kemeny	1999	156	5FU/LV		2 year, 42%	0.07		2 year, 76%	0.03
			5FU/LV+HAI FUDR		2 year, 57%			2 year, 86%	

Table 2. Randomized adjuvant studies comparing HAI with surgery  $\pm$  systemic chemotherapy for resectable liver metastases. HAI=hepatic arterial infusion, DFS=disease-free survival, OS=overall survival, NS=not significant

## 2.2 Systemic chemotherapy as adjuvant therapy

Few high-quality studies have evaluated the efficacy of systemic chemotherapy as a postoperative adjuvant therapy for cases of liver metastasis resection in colorectal cancer. One was a randomized controlled study (Portier et al., 2006), and the other was a pooled analysis (Mitry et al., 2008) (Table 3).

Using cases of curative resection, Portier et al. compared outcomes after surgery alone with outcomes after 6-month systemic chemotherapy using 5-FU and leucovorin. The 5-year recurrence-free survival rate was higher after adjuvant chemotherapy, but overall survival did not differ significantly (Portier et al., 2006). Mitry et al. re-analyzed the data from this study and an intergroup study (ENG trial) that had been terminated prematurely due to slow subject accumulation. Multivariate analysis showed that chemotherapy consisting of 5-FU and leucovorin improved life prognosis, but survival time did not differ significantly compared with surgery alone (Mitry et al., 2008).

Author	year	Number of patients	Regimen	DFS MST, months	<i>P</i> value	OS MST, months	<i>P</i> value
Portier	2006	171	no	17.6	0.028	46.4	0.13
			5FU/LV	24.4		62.1	
Mitry	2008	302	no	18.8	0.058	47.3	0.095
			5FU/LV	27.9		62.2	

Table 3. Randomized adjuvant studies comparing systemic chemotherapy with surgery alone for resectable liver metastases. DFS=disease-free survival, OS=overall survival

The European Organization for Research and Treatment of Cancer (EORTC) conducted a randomized controlled study (EORTC40983) that enrolled 364 colorectal cancer patients with liver metastasis eligible for curative resection (Table 4). The study compared results of surgical resection alone with results of surgical resection combined with leucovorin, 5-FU, and oxaliplatin (FOLFOX4) chemotherapy administered before and after surgery. The results were published in 2008 in *The Lancet* (Nordlinger et al., 2008). In the subgroup that underwent hepatectomy, the 3-year recurrence-free survival rate after hepatectomy was 33% for patients who underwent surgery alone and 42% for those who also received adjuvant chemotherapy ( $p=0.025$ ). However, the trial design has been criticized. Although the secondary analysis showed significantly improved 3-year progression-free survival with adjuvant chemotherapy, the intention-to-treat analysis, which was the main analysis, did not show a significant difference. Overall survival time, the true endpoint, has not been published. The secondary analysis purportedly demonstrated a significant difference in progression-free survival time, but questions have been raised as to how this endpoint was defined (Nakamura et al., 2008). For example, to counteract a clear bias during the hepatectomy period for each group, they calculated early events by combining them at a single point; the chemotherapy group included cases in which hepatectomy was not indicated due to progression of the hepatic lesion or appearance of extrahepatic lesions after chemotherapy was initiated. For that reason, interpretation of the results is difficult.

Analysis by treatment group	chemotherapy group N	surgery group N	difference in rate of PFS at 3 years	HR	<i>P</i> value
All assigned patients (ITT analysis)	182	182	7.2	0.79	0.058
All eligible patients	171	171	8.1	0.77	0.041
All resected patients	151	152	9.2	0.73	0.025

Table 4. Results of EORTC40983 trial. ITT=intention-to-treat, PFS=progression-free survival, HR=hazard ratio

These data were not sufficient to establish preoperative and postoperative chemotherapy as a new standard treatment. Further, the subjects enrolled in EORTC40983 were limited to cases with no more than four liver metastases, corresponding to the H1 stage of the liver metastasis classification of the Japanese Society for Cancer of the Colon and Rectum (Kanahara Shuppan, 2009). The H1 stage is the earliest stage of metastasis, comprising fewer than half of liver metastasis resection cases encountered in clinical practice ("Study on liver metastasis in colorectal cancer," Project Study by Japanese Society for Cancer of the Colon and Rectum, 2004).

Thus, results of EORTC40983 demonstrated that the perioperative addition of FOLFOX4, a potent chemotherapy regimen, could improve prognosis after liver metastasis resection. Nevertheless, the optimal method of administering adjuvant therapy has not yet been established for liver metastasis resection in colorectal cancer.

### **2.3 Preoperative adjuvant chemotherapy for resectable liver metastases**

The National Comprehensive Cancer Network guidelines (<http://www.nccn.org>) recommend multimodality therapy involving hepatectomy and chemotherapy for liver metastasis. For resectable liver metastasis, it recommends FOLFOX with or without bevacizumab or combined systemic and hepatic arterial infusion therapies after hepatectomy. Alternatively, systemic chemotherapy (FOLFOX, FOLFIRI, bevacizumab, cetuximab) should be administered before and after hepatectomy.

#### **2.3.1 Clinical trials of preoperative adjuvant chemotherapy**

To date, no study has reported the effectiveness of preoperative adjuvant chemotherapy for cases in which curative hepatectomy is suitable. An aforementioned EORTC40983 study (Nordlinger et al., 2008) shows a questionable survival benefit with chemotherapy; however, the EORTC40983 trial can be used as a reference.

#### **2.3.2 Advantage of administering adjuvant chemotherapy before hepatectomy**

What are the advantages of preoperative adjuvant chemotherapy compared with postoperative chemotherapy?

##### **2.3.2.1 Increase in complete (R0) resection due to the shrinkage of liver metastases**

Compared with prognosis after R0 resection, prognosis after incomplete resection (R1, R2) is significantly poorer. Charnasangavej et al. reported that cases with positive margins at hepatectomy frequently result in local recurrence at the site of resection, leading to poor prognosis (Charnasangavej et al., 2006). When liver metastasis foci are large or near the root of the hepatic vein or hepatic portal vessel, there is little room to obtain wide margins of normal tissue. A diameter greater than 5 cm for liver metastasis is an adverse prognostic factor (Kato et al., 2003). If neoadjuvant chemotherapy shrinks the liver metastasis, an adequate resection margin is easier to ensure, increasing the likelihood of R0 resection.

##### **2.3.2.2 Preoperative chemotherapy is more effective at targeting micrometastatic foci and suppressing recurrence**

Compared with healthy individuals, patients with liver metastasis from colorectal cancer have significantly higher levels of tumor growth factors, including vascular endothelial growth factor (VEGF), epidermal growth factor (EGF), basic fibroblast growth factor (bFGF), and hepatocyte growth factor (HGF). Levels of HGF and bFGF further increase after



hepatectomy to promote regeneration of the liver (Yoon et al., 2006). HGF enhances the movement and proliferation potential of colorectal cancer cells (Fukuura et al., 1998), and other growth factors likely stimulate and expand cancer microfoci. Elimination of cancer microfoci with preoperative chemotherapy would prevent recurrence after hepatectomy, even in the presence of high levels of growth factors. Tanaka et al. reported that preoperative hepatic arterial infusion chemotherapy suppressed microvascular invasion near liver metastasis foci in cases of multiple liver metastases in bilateral lobes (Tanaka et al., 2004). Therefore, preoperative chemotherapy is expected to exert some suppressive effects on micrometastatic foci.

### **2.3.2.3 Preoperative chemotherapy can be used to evaluate drug sensitivities**

Sensitivity to chemotherapy can be evaluated by computed tomography, magnetic resonance imaging studies, or by histologic evaluation of the excised specimen. The most effective chemotherapy regimen is thus a strong candidate for postoperative adjuvant therapy. Ineffective regimens should not be used for later treatment.

### **2.3.2.4 Tolerance to chemotherapy is higher in the preoperative period than the postoperative period**

For effective adjuvant chemotherapy, the planned dose should generally be administered without dose reduction. Preoperative chemoradiation for rectal cancer is thought to produce milder adverse events and a higher completion rate than postoperative treatment (Sauer et al., 2004). Similarly, liver metastasis tolerance to chemotherapy may be higher before hepatectomy.

## **2.3.3 Issues in neoadjuvant chemotherapy**

### **2.3.3.1 Does neoadjuvant chemotherapy increase postoperative complications due to toxicity in normal liver tissue?**

Neoadjuvant chemotherapy combining FOLFOX or FOLFIRI with bevacizumab and/or cetuximab exerts a strong tumor cell-killing effect; however, chemotherapy also damages normal liver tissue. A high degree of liver damage induced by chemotherapy may cause serious postoperative complications after hepatectomy. For example, the EORTC40983 trial (Nordlinger et al., 2008) reported that six courses of FOLFOX4 significantly increased postoperative complications. When choosing drugs and planning the duration of preoperative chemotherapy, a balance must be made between the tumor cell-killing effects of treatment and liver damage. Many cases of steatohepatitis were observed after treatment with the CPT-11 regimen, and the death rate soon after surgery was high (Vauthery et al., 2006); therefore FOLFOX is preferred. Results of the EFC2962 trial conducted by De Gramont et al., which evaluated progressive and recurrent colorectal cancer not treated with chemotherapy, and the V308 trial conducted by Tournigand et al. indicate that it takes about 2 to 3 months before the effects of FOLFOX therapy begin to appear (de Gramont et al., 2000; Tournigand et al., 2004). Neoadjuvant FOLFOX chemotherapy likely requires at least 4 to 6 courses.

### **2.3.3.2 When complete remission (CR) is achieved, resection of liver metastasis foci is difficult**

Benoist et al. administered chemotherapy to 586 patients with liver metastasis, and 38 cases (6%), or 66 foci, were determined to have achieved CR based on imaging. Post-hepatectomy

pathologic examination revealed that 55 of the 66 (83%) foci were viable tumor foci (Benoist et al., 2006). Thus, metastatic foci may contain residual viable cancer cells, even if CR is noted on imaging; if not removed, residual cancer cells are likely to cause recurrence. Further, the lesion that demonstrated CR on imaging after preoperative chemotherapy cannot always be detected during surgery. While it is desirable to shrink cancer foci with preoperative chemotherapy, the danger is that the lesion cannot be later identified and resected.

At this point, neither safety nor effectiveness has been established for preoperative chemotherapy for resectable liver metastasis. Additional clinical trials will be needed to address this issue.

## 2.4 Future research

Surgery and chemotherapy combined can reduce the risk of relapse. However, until recently the role of adjuvant chemotherapy in the perioperative setting has been of unclear benefit. EORTC40983 trial (Nordlinger et al., 2008) fulfill a profound need for a well done randomized trial to compare surgery alone with surgery and chemotherapy for patients with resectable colorectal liver metastases. However, their decision to give preoperative chemotherapy to patients with resectable colorectal liver metastases, thereby postponing a possible curative treatment, can be disputed. Patients who receive preoperative chemotherapy increase their chance of postoperative complications, as stated in their report (25% vs 16%,  $p=0.04$ ). Postoperative chemotherapy should theoretically be effective in dormant cancer cells in the remnant liver or body. Until the report of the trial by Portier *et al* (Portier et al., 2006), there has been no clear evidence that adjuvant chemotherapy, either systemic or by hepatic arterial infusion, added benefit over surgery alone from a randomized trial. The results of the trial led by Portier *et al* (Portier et al., 2006) represents that patients receiving postoperative systemic fluorouracil (FU) plus leucovorin (LV) fared significantly better than those receiving surgery alone (24.4 months vs 17.6 months, respectively) in disease-free survival. However, enrollment to the trial was suspended after 173 patients due to slow accrual and this trial did not have sufficient statistic power. When such trial took 10 years to finish accrual, the original question became outdated since the chemotherapy used in it is now considered inferior to currently available regimens containing potentially more active agents such as oxaliplatin, irinotecan, bevacizumab or cetuximab. Thus, there remains a need for clear evidence for whether combined treatment with chemotherapy is better than surgery alone in patients with resectable liver metastases from colorectal cancer. We, therefore, conducted a phase II/III randomized controlled trial to evaluate modified FOLFOX (mFOLFOX) as adjuvant chemotherapy for patients with curatively resected liver metastases from colorectal cancer.

The study protocol was designed by the Colorectal Cancer Study Group (CCSG) of the Japan Clinical Oncology Group (JCOG), approved by the Protocol Review Committee of JCOG on 15 February 2007. This trial was registered as JCOG0603 study (Kanemitsu et al., 2009) at the UMIN Clinical Trials Registry as UMIN000000653 (<http://www.umin.ac.jp/ctr/index.htm>).

### 2.4.1 Digest of the JCOG0603 study protocol

#### 2.4.1.1 Purpose

To evaluate systemic intravenous adjuvant chemotherapy in comparison with observation alone after curative resection of liver metastases from colorectal cancer (Fig. 1).



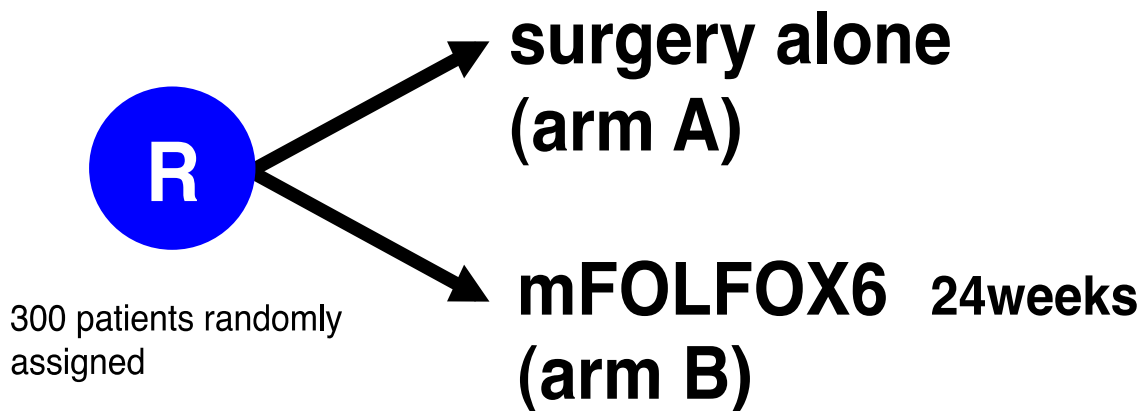


Fig. 1. JCOG0603 study scheme

#### 2.4.1.2 Study setting

A multi-institutional prospective randomized controlled trial, with participating institutions including 39 specialized centers as of 4 September 2008.

#### 2.4.1.3 Resources

Health and Labour Sciences Research Grants for Clinical Research for Evidenced Based Medicine, Clinical Cancer Research and Grants-in-Aid for Cancer Research (17S-3, 17S-5), from the Ministry of Health, Labour and Welfare, Japan.

#### 2.4.1.4 Endpoints

The primary endpoint is treatment compliance at 9 courses after beginning mFOLFOX (bolus and infusion FU and LV with oxaliplatin) in phase II and is disease-free survival in phase III, respectively. Secondary endpoints are overall survival, incidence of adverse events defined by Common Terminology Criteria for Adverse Events (CTCAE) v. 3.0 and mode of recurrence after liver resection.

#### 2.4.1.5 Eligibility criteria

Primary tumors are staged according to the sixth edition of the tumor-nodes-metastasis (TNM) classification system of the Union International Contre Cancer (UICC).

#### 2.4.1.6 Inclusion criteria

Prior to entry to the study, the patients must fulfill the following criteria:

- i. histologically proven adenocarcinoma of the colorectum.
- ii. Complete macroscopic and microscopic (R0) resection of both primary and secondary lesions.
- iii. No extrahepatic disease.
- iv. No prior chemotherapy except oxaliplatin or radiotherapy within 3 months preceding registration.
- v. No prior radiofrequency ablation or cryotherapy for liver metastasis.
- vi. At 42 to 70 days after hepatectomy.
- vii. Age ranging between 20 and 75 years old.

- viii. Preoperative ECOG performance status 0-1.
- ix. Sufficient organ functions before chemotherapy.
- x. Written informed consent.

#### 2.4.1.7 Exclusion criteria

Exclusion criteria are as follows: (i) synchronous or metachronous cancer; (ii) pregnancy; (iii) psychological disorder; (iv) steroid administration; (v) patients must use flucytosine, phenytoin or warfarin potassium; (vi) insulin dependent or uncontrollable diabetes mellitus; (vii) diarrhea or peripheral neuropathy greater than grade 1 and (viii) medical history of allergy or hypersensitivity to any drug.

#### 2.4.1.8 Registration

Using telephone or fax to the JCOG Data Center, eligible patients between 42 and 70 days after liver surgery are registered centrally and assigned randomly by the minimization method of balancing the arm according to the synchronous or metachronous metastases to the liver, the number of metastases, the largest size of metastases, number of metastatic lymph nodes in the primary lesion and institution.

#### 2.4.1.9 Treatment Methods (Fig. 2)

Enrolled patients are assigned to surgery alone (arm A, control group) or to mFOLFOX6 and surgery (arm B, treatment group). In arm B, adjuvant treatment is started between 56 and 84 days after liver surgery. Chemotherapy consisted of an intravenous injection of oxaliplatin 85mg/m<sup>2</sup> with l-LV 200mg over 2 hours plus 5FU 400mg/m<sup>2</sup> bolus and 2400mg/m<sup>2</sup> continuous infusion over 46 hours every 2 weeks. This cycle is repeated for 12 courses in the absence of disease progression or unacceptable toxicity.

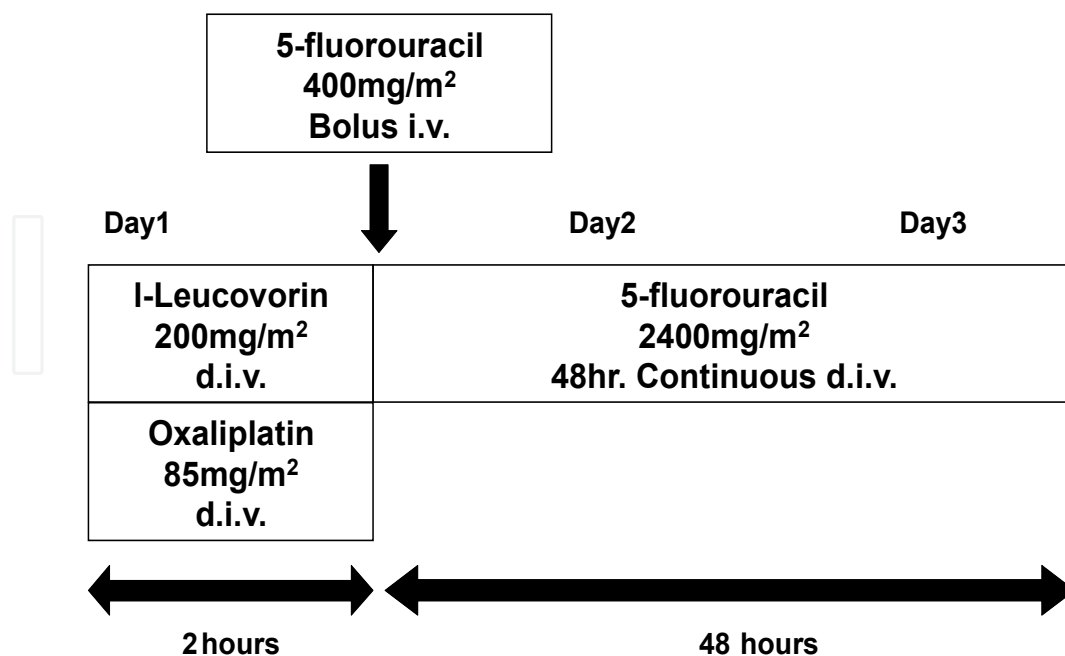


Fig. 2. Treatment schedule in postoperative chemotherapy arm

### 3. Conclusion

To date, no studies have demonstrated that adjuvant chemotherapy before or after radical resection clearly improves life prognosis for patients with liver metastasis from colorectal cancer. After EORTC40983, regimens involving strong preoperative chemotherapy attracted attention. However, preoperative chemotherapy increases the risk of hepatic dysfunction and postoperative complications. Thus, doubt has been raised regarding the use of preoperative adjuvant chemotherapy for resectable liver metastasis. Furthermore, hepatectomy may become impossible if the tumor grows because preoperative chemotherapy is ineffective or if target lesions disappear in cases of complete response. To improve outcomes for cases of resectable liver metastasis, postoperative adjuvant therapy strategies may be useful; however, there is insufficient evidence to recommend postoperative adjuvant therapy in clinical practice. This therapy should be considered experimental, and participation in a clinical trial is recommended to obtain high-level evidence. The Japan Clinical Oncology Group initiated a comparative study of surgery alone versus FOLFOX6 after curative resection of liver metastasis from colorectal cancer (JCOG0603). The active drugs (5-FU, CPT-11, oxaliplatin, and the molecular-targeted drugs bevacizumab and cetuximab) are available for use. In addition, the EORTC40983 trial suggested the usefulness of perioperative chemotherapy. Although the efficacy of these treatments has not yet been fully established, the use of adjuvant therapy before and/or after hepatectomy may be increasing. Opinion leaders in the world acknowledge that a no-treatment group control arm is necessary to obtain highly accurate study results (Alberts et al., 2006); however, the difficulty of enrolling patients in past trials (Langer et al., 2002; Portier et al., 2006) has led to study designs that no longer include a no-treatment group. This has hampered the accumulation of evidence supporting adjuvant chemotherapy in liver metastasis resection in colorectal cancer (Alberts et al., 2006). Combination chemotherapy has improved outcomes for colorectal cancer, but studies of adjuvant therapy for cases of liver metastasis resection in colorectal cancer are increasingly designed with technical rather than scientific considerations in mind. The no-treatment control group in the JCOG0603 trial allowed high-level evidence to be obtained, and the significance of these results is unquestionable. On the other hand, EORTC40983 presented ambiguous results. We conclude that the JCOG0603 trial is the only randomized controlled trial that may be able to clarify the effectiveness of postoperative adjuvant chemotherapy when liver metastasis is completely resected. We eagerly await the results of this trial.

### 4. References

- Abdalla EK, Vauthey JN, Ellis LM et al: Recurrence and outcomes following hepatic resection, radiofrequency ablation, and combined resection/ablation for colorectal liver metastases. *Ann Surg* 239(6)2004 Jun:818-825, ISSN00034932
- Adson, M.; van Heerden, J.; Wagner, J. & Ilstrup, D. (1984). Resection of hepatic metastases from colorectal cancer. *Arch Surg* 119(6)1984 Jun:647-651, ISSN02725533

- Alberts SR. Evolving role of chemotherapy in resected liver metastases. *J Clin Oncol* 24(31)2006 Nov:4952-4953, ISSN0732183X
- Benoist S, Brouquet A, Penna C, Julié C, El Hajjam M, Chagnon S, Mitry E, Rougier P, Nordlinger B. Complete response of colorectal liver metastases after chemotherapy: does it mean cure? *J Clin Oncol* 24(24)2006 Aug:3939-45 ISSN0732183X
- Charnsangavej C, Clary B, Fong Y, Grothey A, Pawlik TM, Choti MA. Selection of patients for resection of hepatic colorectal metastases: expert consensus statement. *Ann Surg Oncol* 13(10)2006 Oct:1261-8,ISSN00034932
- Choti MA, Sitzmann JV, Tiburi MF et al: Trends in long-term survival following liver resection for hepatic colorectal metastases. *Ann Surg* 235(6)2002 Jun:759-766, ISSN00034932
- de Gramont A, Figier A, Seymour M, Homerin M, Hmissi A, Cassidy J, Boni C, Cortes-Funes H, Cervantes A, Freyer G, Papamichael D, Le Bail N, Louvet C, Hendler D, de Braud F, Wilson C, Morvan F, Bonetti A. Leucovorin and fluorouracil with or without oxaliplatin as first-line treatment in advanced colorectal cancer. *J Clin Oncol* 18(16)2008 Aug :2938-47, ISSN0732183X
- Elias D, Ouellet JF, Bellon N, et al. Extrahepatic disease does not contraindicate hepatectomy for colorectal liver metastases. *Br J Surg* 90(5)2003 May:567-574,ISSN00071323
- Fernandez FG, Drebin JA, Linehan DC et al: Recurrence and outcomes following hepatic resection, radiofrequency ablation, and combined resection/ablation for colorectal liver metastases. Five-year survival after resection of hepatic metastases from colorectal cancer in patients screened by positron emission tomography with F-18 fluorodeoxyglucose(FDG-PET). *Ann Surg* 240(3)2004 Sep:438-447, ISSN0034932
- Figueras J, Valls C, Rafecas A et al: Resection rate and effect of postoperative chemotherapy on survival after surgery for colorectal liver metastases. *Br J Surg* 88(7)2001 Jul :980-985, ISSN00071323
- Fong Y, Fortner J, Sun RL et al: Clinical score for predicting recurrence after hepatic resection for metastatic colorectal cancer: analysis of 1001 consecutive cases. *Ann Surg* 230(3)1999 Sep:309-318, ISSN00034932
- Fukuura T, Miki C, Inoue T, Matsumoto K, Suzuki H. Serum hepatocyte growth factor as an index of disease status of patients with colorectal carcinoma. *Br J Cancer* 78(4)1998 Aug:454-9 ,ISSN00070920
- Hughes KS, Simon R, Songhorabodi S et al: Resection of the liver for colorectal carcinoma metastases: a multi-institutional study of patterns of recurrence. *Surgery* 100(2)1986 Aug:278-284, ISSN00396060
- Iwatsuki S, Dvorchik I, Madariaga JR et al: Hepatic resection for metastatic colorectal adenocarcinoma: a proposal of a prognostic scoring system. *J Am Coll Surg* 189(3)1999 Sep:291-299, ISS10727515
- Jamison RL, Donohue JH, Nagorney DM et al: Hepatic resection for metastatic colorectal cancer results in cure for some patients. *Arch Surg* 132(5)1997May:505-510, ISSN02725533

- Japanese Research Society for Cancer of the Colon and Rectum. Jan 13,2009 *Japanese Classification of Colorectal Carcinoma. Second English Edition*. Kanehara &Co., Ltd. ISBN 978-4-307-20244-2 Japan
- Kato T, Yasui K, Hirai T et al: Therapeutic results for hepatic metastasis of colorectal cancer with special reference to effectiveness of hepatectomy: analysis of prognostic factors for 763 cases recorded at 18 institutions. *Dis Colon Rectum* 46(10Suppl)2003 Oct:S22-31, ISSN15300358
- Kanemitsu Y, Kato T, Shimizu Y, Inaba Y, Shimada Y, Nakamura K, Sato A, Moriya Y; Colorectal Cancer Study Group (CCSG) of Japan Clinical Oncology Group. A randomized phase II/III trial comparing hepatectomy followed by mFOLFOX6 with hepatectomy alone as treatment for liver metastasis from colorectal cancer: Japan Clinical Oncology Group Study JCOG0603. *Jpn J Clin Oncol* 39(6)2009 Jun :406-9,ISSN14653621
- Kemeny N, Huang Y, Cohen AM et al: Hepatic arterial infusion of chemotherapy after resection of hepatic metastases from colorectal cancer. *N Engl J Med* 341(27)1999 Dec30:2039-2048, ISSN00284793
- Kemeny MM, Adak S, Gray B et al: Combined-modality treatment for resectable metastatic colorectal carcinoma to the liver: surgical resection of hepatic metastases in combination with continuous infusion of chemotherapy--an intergroup study. *J Clin Oncol* 20(6)2002 Mar15:1499-1505, ISSN0732183X
- Langer B, Bleiberg H, Labianca R, et al: Fluorouracil (FU) plus l-leucovorin (l-LV) versus observation after potentially curative resection of liver or lung metastases from colorectal cancer (CRC): Results of the ENG (EORTC/NCIC CTG/GIVIO) randomized trial. *Proc Am Soc Clin Oncol* 21:149a, 2002 (abstr 592) 8. Portier G, Elias D, Bouche O, et al: Multicenter randomized trial of adjuvant fluorouracil and folinic acid compared with surgery alone after resection of colorectal liver metastases: FFCD ACHBTH AURC 9002 trial. *J Clin Oncol* 24(31)2006 Nov 4976-4982, ISSN0732183X
- Lorenz M, Müller HH, Schramm H et al: Randomized trial of surgery versus surgery followed by adjuvant hepatic arterial infusion with 5-fluorouracil and folinic acid for liver metastases of colorectal cancer. German Cooperative on Liver Metastases (Arbeitsgruppe Lebermetastasen) *Ann Surg* 228(6)1998 Dec :756-762, ISSN00034932
- Mitry E, Fields AL, Bleiberg H et al: Adjuvant chemotherapy after potentially curative resection of metastases from colorectal cancer: a pooled analysis of two randomized trials. *J Clin Oncol* 26(30)2008 Oct :4906-11, ISSN0732183X
- Minagawa M, Makuuchi M, Torzilli G et al: Extension of the frontiers of surgical indications in the treatment of liver metastases from colorectal cancer: long-term results. *Ann Surg* 231(4)2000 Apr :487-499, ISSN00034932
- Nakamura K, Shibata T, Saito I, et al : Exploratory analysis to seek for the optimal definition of progression-free survival in preoperative cancer therapy: using phase III trials of




- Japan Clinical Oncology Group (JCOG0801-A): *Journal of Clinical Oncology* 26(15S):2008 May 362s ISSN073218
- Nordlinger B, Guiguet M, Vaillant JC et al: Surgical resection of colorectal carcinoma metastases to the liver. A prognostic scoring system to improve case selection, based on 1568 patients. Association Française de Chirurgie. *Cancer* 77(7)1996 Apr:1254-1262, ISSN0008543X
- Nordlinger B, Sorbye H, Glimelius B et al: Perioperative chemotherapy with FOLFOX4 and surgery versus surgery alone for resectable liver metastases from colorectal cancer (EORTC Intergroup trial 40983): a randomised controlled trial. *Lancet* 371(9617) 2008 Mar :1007-16, ISSN01406736
- Portier G, Elias D, Bouche O et al: Multicenter randomized trial of adjuvant fluorouracil and folinic acid compared with surgery alone after resection of colorectal liver metastases: FFCD ACHBTHAURC 9002 trial. *J Clin Oncol* 24(31)2006 Nov:4976-4982, ISSN0732183X
- Rees M, Tekkis PP, Welsh FK et al: Rees M, Tekkis PP, Welsh FK. Evaluation of long-term survival after hepatic resection for metastatic colorectal cancer: a multifactorial model of 929 patients. *Ann Surg* 247(1)2008 Jan :125-135, ISSN00034932
- Sauer R, Becker H, Hohenberger W, Rödel C, Wittekind C, Fietkau R, Martus P, Tschmelitsch J, Hager E, Hess CF, Karstens JH, Liersch T, Schmidberger H, Raab R; German Rectal Cancer Study Group. Preoperative versus postoperative chemoradiotherapy for rectal cancer. *N Engl J Med* 351(17) 2004 Oct :1731-40,ISSN00284793
- Scheele J, Stang R, Altendorf-Hofmann A et al: Resection of colorectal liver metastases. *World J Surg* 19(1)1995 Jan Feb :59-71, ISSN03642313
- Tanaka K, Shimada H, Miura M, Fujii Y, Yamaguchi S, Endo I, Sekido H, Togo S, Ike H. Metastatic tumor doubling time: most important prehepatectomy predictor of survival and nonrecurrence of hepatic colorectal cancer metastasis. *World J Surg* 28(3)2004 Mar:263-70,ISSN03642313
- Tournigand C, André T, Achille E, Lledo G, Flesh M, Mery-Mignard D, Quinaux E, Couteau C, Buyse M, Ganem G, Landi B, Colin P, Louvet C, de Gramont A. FOLFIRI followed by FOLFOX6 or the reverse sequence in advanced colorectal cancer: a randomized GERCOR study. *J Clin Oncol* 22(2) 2004 Jan:229-37,ISSN0732183X
- Vauthey JN, Pawlik TM, Ribero D, Wu TT, Zorzi D, Hoff PM, Xiong HQ, Eng C, Lauwers GY, Mino-Kenudson M, Risio M, Muratore A, Capussotti L, Curley SA, Abdalla EK. Chemotherapy regimen predicts steatohepatitis and an increase in 90-day mortality after surgery for hepatic colorectal metastases. *J Clin Oncol* 24(13) 2006 May:2065-72,ISSN0732183X
- Wei AC, Greig PD, Grant D et al: Survival after hepatic resection for colorectal metastases: a 10-year experience. *Ann Surg Oncol* 13(5)2006 May :668-76, ISSN10689265

Yoon SS, Kim SH, Gonen M, Heffernan NM, Detwiler KY, Jarnagin WR, D'Angelica M, Blumgart LH, Tanabe KK, Dematteo RP. Profile of plasma angiogenic factors before and after hepatectomy for colorectal cancer liver metastases. *Ann Surg Oncol* 13(3) 2006 Mar :353-62,ISSN10689265

IntechOpen

IntechOpen



## **Current Cancer Treatment - Novel Beyond Conventional Approaches**

Edited by Prof. Oner Ozdemir

ISBN 978-953-307-397-2

Hard cover, 810 pages

**Publisher** InTech

**Published online** 09, December, 2011

**Published in print edition** December, 2011

Currently there have been many armamentaria to be used in cancer treatment. This indeed indicates that the final treatment has not yet been found. It seems this will take a long period of time to achieve. Thus, cancer treatment in general still seems to need new and more effective approaches. The book "Current Cancer Treatment - Novel Beyond Conventional Approaches", consisting of 33 chapters, will help get us physicians as well as patients enlightened with new research and developments in this area. This book is a valuable contribution to this area mentioning various modalities in cancer treatment such as some rare classic treatment approaches: treatment of metastatic liver disease of colorectal origin, radiation treatment of skull and spine chordoma, changing the face of adjuvant therapy for early breast cancer; new therapeutic approaches of old techniques: laser-driven radiation therapy, laser photo-chemotherapy, new approaches targeting androgen receptor and many more emerging techniques.

### **How to reference**

In order to correctly reference this scholarly work, feel free to copy and paste the following:

Yukihide Kanemitsu (2011). Adjuvant Therapy for Resectable Colorectal Cancer Liver Metastases, Current Cancer Treatment - Novel Beyond Conventional Approaches, Prof. Oner Ozdemir (Ed.), ISBN: 978-953-307-397-2, InTech, Available from: <http://www.intechopen.com/books/current-cancer-treatment-novel-beyond-conventional-approaches/adjuvant-therapy-for-resectable-colorectal-cancer-liver-metastases>

**INTECH**  
open science | open minds

### **InTech Europe**

University Campus STeP Ri  
Slavka Krautzeka 83/A  
51000 Rijeka, Croatia  
Phone: +385 (51) 770 447  
Fax: +385 (51) 686 166  
[www.intechopen.com](http://www.intechopen.com)

### **InTech China**

Unit 405, Office Block, Hotel Equatorial Shanghai  
No.65, Yan An Road (West), Shanghai, 200040, China  
中国上海市延安西路65号上海国际贵都大饭店办公楼405单元  
Phone: +86-21-62489820  
Fax: +86-21-62489821

© 2011 The Author(s). Licensee IntechOpen. This is an open access article distributed under the terms of the [Creative Commons Attribution 3.0 License](#), which permits unrestricted use, distribution, and reproduction in any medium, provided the original work is properly cited.

IntechOpen

IntechOpen