

We are IntechOpen, the world's leading publisher of Open Access books Built by scientists, for scientists

4,800

Open access books available

122,000

International authors and editors

135M

Downloads

Our authors are among the

154

Countries delivered to

TOP 1%

most cited scientists

12.2%

Contributors from top 500 universities

**WEB OF SCIENCE™**Selection of our books indexed in the Book Citation Index
in Web of Science™ Core Collection (BKCI)

Interested in publishing with us? Contact book.department@intechopen.com

Numbers displayed above are based on latest data collected.

For more information visit www.intechopen.com

Technical and Clinical Evolution of Modern Neuroendoscopy

P. Grunert and J. Oertel
*Johannes Gutenberg University
Germany*

1. Introduction

Endoscopy plays an important part in the present minimally invasive neurosurgery. The concept, the indications and the technical development have a long history. We can distinguish an early period at the end of 19th and beginning of 20th century and an advanced period toward the end of the 20th century. Each of these periods can be further divided in a time of an obvious medical problem and first idea of possible solution, further in the next step a time of intensive technical improvements and finally the clinical application of endoscopes during surgical interventions. This historical development of endoscopy is true for all branches of surgical application. In this chapter it will be described in the field of neurosurgery.

2. History of neuroendoscopy

2.1 Early endoscopic period in the 19th and beginning 20th century

2.1.1 The problem and the first technical solution by Philipp Bozzini

Originally the direct visual inspection of organs such as bladder, female genital organs or digestive tract through natural orifices was restricted to few centimetres with a speculum. To see deeper into the human cavities and to improve the visual quality, a better illumination was necessary.

The physician Philipp Bozzini constructed at the beginning of the 19th century an optical device which enabled to look deeper into the human cavities. Bozzini was born in Mainz Germany 1773 as a son of Italian immigrants (Doglietto et al 2005; Netzhat 2005; Shah 2002). He studied medicine in Mainz and Jena. After obtaining his degree he settled as a physician in Mainz and later in Frankfurt. He constructed a device equipped with a speculum and two chambers one for light conduction and a second for direct visual inspection. Candle light was used for the illumination of the cavity. The isolation between these two chambers was necessary to be not blinded during the inspection. Bozzini called this device "Lichtleiter" (illuminating conduction) (Fig. 1).

First experiments with this "Lichtleiter" were demonstrated in Vienna 1806/1807 in the Josephinum, a foundation of the emperor Joseph II as a college for training of surgeons for the Habsburg army. Bozzini performed there with his optical instrument experiments on cadavers in different orifices of the body. However the medical academy of the Josephinum had not recognized the diagnostic potential of his invention. They estimated the device as a mere curiosity and called the instrument *laterna magica in corpore humano* (magic lamp in human body). Unfortunately Bozzini died 1809 on typhus and his invention fell for long time into oblivion.

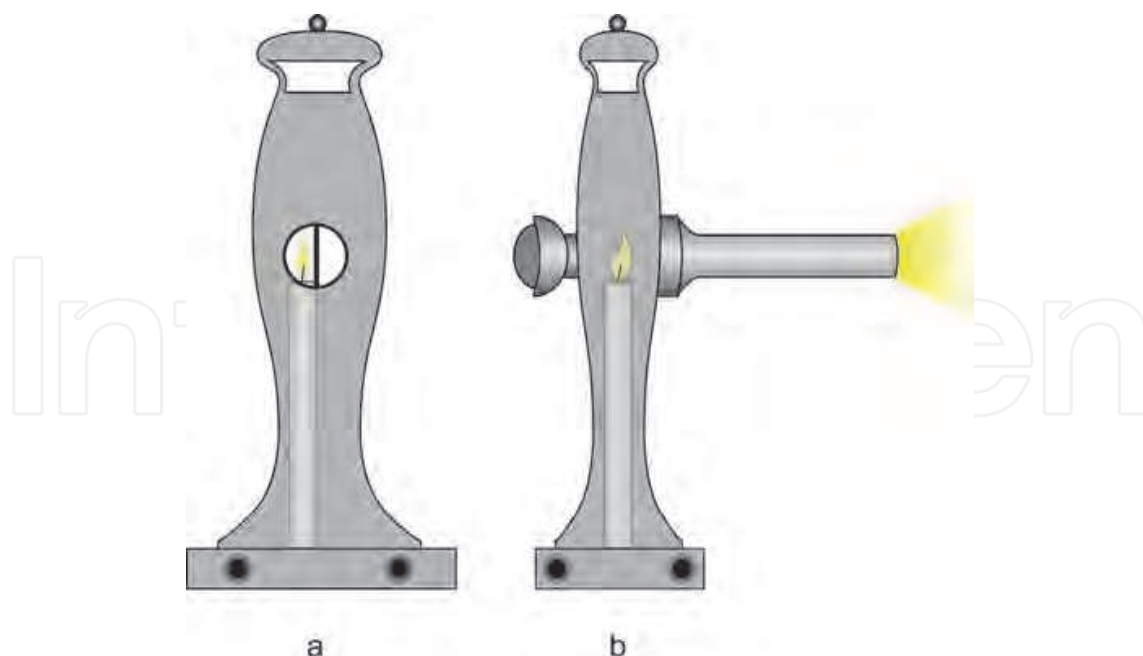


Fig. 1. Bozzini's "Lichtleiter". Front view(a). Notice the separated chambers for illumination and for observation. The black holes at the bottom are connected with the chamber and provide oxygen for the candle light. The opening on the top should protect against overheating. Side view(b) with an attached speculum.

2.1.2 Technical development of endoscopes

50 years after the death of Bozzini his idea of illumination was again picked up. The French physician Antoine Jean Dèsortmeaux constructed around 1853 a technically improved version of Bozzini's "Lichtleiter". He called this instrument an endoscope (Shah 2002). As the instrument of Bozzini the device was without optical lenses. The innovation in comparison to Bozzini's "Lichtleiter" consisted in the use of a single optical canal without separation of canals for light conductance and for observation. Additionally the candle light of the "Lichtleiter" was replaced by an external light source using gas oil, the light of which was reflected by means of a mirror from a side arm into the optic canal. 1865 he reported about the first clinical applications of this endoscope in the urethra and the bladder (Dèsortmeaux 1865). In the second half of the 19th century the endoscopes became increasingly important in urology and gynaecology.

Although having precursors in the second half of the 19th century such as Joseph Grünfeld in Vienna and Gustave Trouve in Paris, the development of the modern endoscopes is ascribed to Maximilian Nitze (1848-1912). Nitze organized partly in Berlin, partly in Dresden and partly in Vienna the development of each module of the endoscope the illumination, the optical system and the mechanical system. Under his surveillance the modules were set together to a functioning clinically applicable device. Therefore it is correct to speak of Nitze as the inventor of the modern endoscopy.

Nitze was born in Berlin 1848 (Doglietto et al 2005; Netzhat 2005; Verger-Kuhnke 2007). He studied medicine at different German universities and obtained his medical degree 1874. In 1875 he worked in the state hospital of Dresden. There in the department of gynaecology he saw the necessity to develop an optical device allowing better inspection of the female genital organs. The main idea of Nitze was to transfer the illumination source into the tip of

the instrument and to use a system of lenses in imitation of a microscope. The optical problem solved by an order of Nitze Louis Charles Bénèche (Schultheiss & Moll 2009). Bénèche was borne in Berlin as a son of reformed Huguenots. He was specialized in construction of microscopes. Regarding endoscopes he was confronted with the problem of a long shaft in relation to a very small diameter and thus a very restricted and small view. His ingenious basic solution was to construct a lens system based on the principle of a Kepler telescope (Fig. 2b). In front of the lens system at the very tip was placed wide-angle lens to increase the viewing angle and to bundle the rays inside the shaft. The first lens of the optic system at the tip with a short focus distance f_1 produced a real image inside the shaft close to the tip in an upside down position. This image was zoomed by a second lens positioned at the middle of the shaft with a focus distance f_2 measuring half of the shaft length. By this optical construction at the proximal end of the endoscope a zoomed and virtual image in upside down position was created (Fig. 2). The mechanical realisation was difficult to be performed in Dresden and Nitze was referred to the Viennes instrument maker Joseph Leiter. For this reason Nitze quit in Dresden and moved to Vienna where he started to work in the surgical department of Leopold knight of Dittel, who was professor of surgery at the university of Vienna and highly interested in urology and endoscopy. There Nitze found the best presuppositions for his scientific work. Already 1879 he presented with Leiter the first cystoscope. Leiter published the prototype 1880 with the title "electro-

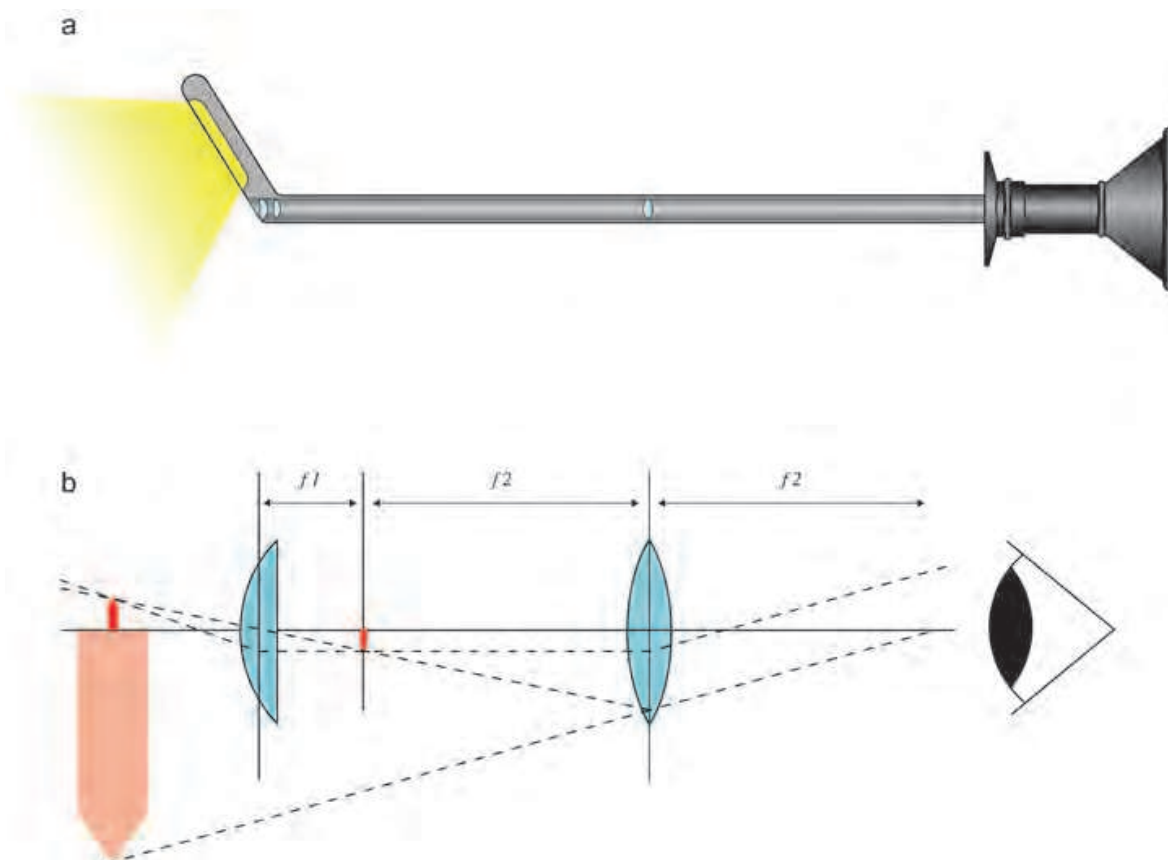


Fig. 2. Principle of Nitze endoscope. Mechanical construction of the cystoscope with lenses within the shaft and the illumination at the tip of the endoscope(a). Optic principle of Nitze endoscope constructed as a "Kepler" telescope producing an imaginary zoomed image in upside down position(b).

endoscopic instruments description and instruction by M. Nitze and J Leiter". Using platinum wire as distal illumination source this prototype had to be equipped with an expensive cooling system to prevent burning (Leiter 1880). After invention of the incandescent electric light bulb 1878 by Thomas Alva Edison the platinum wire was replaced in the endoscope by an electric lamp, which needed no additional cooling system. This endoscope became known as "von Dittel-Leiter cystoscope". The experiences with endoscopic diagnosis and treatment of the bladder published Nitze 1889 as a text book "Lehrbuch der Kystoskopie. Technik und klinische Bedeutung" (text book of cystoscopy: Technique and clinical relevance) (Nitze 1889). The handling of the Nitze endoscopes needed experience and practice because the images were originally upside down. Only 1907 the Swiss Zeiss company developed a prism for the endoscope which reversed the picture again into the upside position.

2.1.3 First clinical applications of endoscopy in neurosurgery

Although the basic development of endoscopes was associated with Germany and Austria, the serial production at the beginning of 20th century shifted to US where Reinhold Wappler (Shah 2002) a manufacturer for medical instruments who emigrated 1890 from Germany to the United States founded the American Cystoscope Makers Incorporation (ACMI). Thus at the beginning of the 20th century endoscopes mostly in form of Nitze type cystoscopes were available in the medical centres in the most American universities. Neurosurgery was in that time a new surgical field with great potential of innovation and technical improvement. Additionally at this time in the US neurosurgery much earlier than in Europe started to separate from the general surgery and was becoming an independent discipline with own development of instruments, new operative approaches and own medical training. This gave an additional push for neurosurgeons to apply new technologies in this promising surgical field. It is therefore not surprising that first endoscopic procedures in the brain started nearly simultaneously at different universities just in the United States in the 20s of the 20th century.

The first neuroendoscopic procedure was performed 1910 in the department of neurological surgery at the Northwest University, Chicago by the urologist Victor Darwin Lespinasse and the neurosurgeon Allen Buckner Kanavel, an innovative neurosurgeon who described also 1909 the infranasal transphenoidal approach to the sella turcica (Northwestern University, Dept. of History). With a cystoscope they coagulated the plexus chorioideus in two children with hydrocephalus. They had not continued with this type of procedure because one child died just after the operation and the other survived only 5 years.

Walter Edward Dandy is also associated with early neuroendoscopy (Hsu et al. 2009). Dandy was in the first half of 20th century one of the most innovative neurosurgeons making substantial contributions to all fields of neurosurgery. Dandy was a son of British immigrants. He attended the medical school at John Hopkins University in Baltimore, Maryland and passed the examinations 1910. From 1910-1911 he worked in Cushing's Hunterian laboratory at the John Hopkins University. Among many other topics, Dandy studied there experimental hydrocephalus produced in dogs by obstructions of the aqueduct with a cotton piece introduced from the posterior fossa through the IV. ventricle (Aschoff 1999, Dandy & Blackfan 1913, 1914). He published these results together with Blackfan 1913 as a short communication in JAMA (Dandy & Blackfan 1913) and 1914 as a comprehensive basic work in A. J. dis. Child (Dandy & Blackfan 1914). As consequence of their experimental study they distinguished between an obstructive and a communicating hydrocephalus. Based on the experimental work Dandy tried also to explain the so called "idiopathic" hydrocephalus of adults which corresponds mostly to the low pressure

hydrocephalus in our present terminology (Dandy 1921). Due to their theoretical results on hydrocephalus the logical therapeutic approach for communicating hydrocephalus consisted in reduction of the CSF production by extirpation or coagulation the choroid plexus in the lateral ventricle (Dandy 1918) and for obstructive hydrocephalus in producing an artificial bypass from the ventricles into the subarachnoidal space. This was achieved anatomically by means of an open ventriculostomy perforating the lamina terminalis from a temporopolar approach (Aschoff et al 1999; King 2003). The disadvantage of this method consisted besides of the occasional necessity to sacrifice the optic nerve also in the frequent occurrence of hygromas (King 2003). To overcome this problem Dandy preferred since 1933 a more posterior extradural subtemporal approach (Aschoff et al 1999, Dandy 1933, King 2003). It is reported that Dandy performed also 2 endoscopic inspections in children with hydrocephalus. However he was not able to complete the operation endoscopically and he had to change to the open approach. Dandy called this endoscope due to the application in the human ventricles from this time on a "ventriculoscope". It is further reported that Dandy published the results of these two endoscopic operations in Johns Hopkins Hospital Bulletin 1922 in two papers "Cerebral ventriculostomy" and "An operative procedure for hydrocephalus". These citations although often cited remain however dubious because a closer inspection of all publications of Dandy in John Hopkins Hosp. Bull shows, that in this journal were no publications concerning his neuroendoscopic work. Nevertheless the very thorough evaluation of Dandy's correspondence by Hsu (Hsu et al 2009) speaks in favour that Dandy was initially interested in the application of endoscopes in the ventricles and probably he performed also few endoscopic procedures in children with hydrocephalus but gave up very early this technique without publishing his experience on this topic.

Temple Fay and Francis Grant were other two neurosurgeons who tried endoscopically to treat hydrocephalus in children. Temple Fay born in Seattle worked as neurosurgeon at the Temple University Philadelphia. 1923 he published an endoscopic operation of a child with the title "Ventriculostomy and intraventricular photography in internal hydrocephalus" (Fay & Grant 1923) he treated one year ago together with Francis Grant, the later chairman of the neurosurgery at the Temple University. They described the operation and discussed the potential and the limitations of this method. However their endoscopic operation was not successful.

The most successful pioneer of neuroendoscopy was William Jason Mixer.

Mixer graduated at the Harvard medical school and worked as surgeon in the Massachusetts general hospital. There he worked together with his father Samuel Jason Mixer, a recognized surgeon, who described the spinal dorsal stabilisation at the level C1/C2 as early as 1910. With his father William Mixer had 2 beds for treating also neurosurgical patients. Their neurosurgical results were so good, that a neurosurgical unit was established. From 1933-1946 William Mixer was there the chief of the department of neurosurgery. He is well known to the neurosurgery by describing 1934 a disc herniation as reason for sciatica. 1923 William Mixer published the first successful endoscopic ventriculocisternostomy, performed with an cystoscope by transventricular approach through the foramen of Monroe by perforating the floor of the third ventricle (Mixer 1923). Exactly this technique was the example for later endoscopic ventriculostomies in the modern advanced neuroendoscopy.

The only neurosurgeon who continued with neuroendoscopy in the treatment of hydrocephalus till the development of shunt systems was John E. Scarff.

Scarff, finished his study at John Hopkins University 1924 and worked in the Hunterian laboratory at John Hopkins University between 1925-1927. He operated there also with

Dandy. Later working at the Columbia University in New York he continued with the neurosurgeon Byron Stookey to treat hydrocephalus as developed in the 20s (Scarff 1936, 1951, Scarff & Stookey 1936) perforating the lamina terminalis and the floor of the third ventricle in patients with obstructive hydrocephalus.

2.2 Advanced period of neuroendoscopy at the end of 20th century

2.2.1 Idea and motivation

Although the shunt operations were very successful in the treatment of hydrocephalus of any origin, they had typical complications due to implanted material such as shunt infections and shunt obstructions. This drawback made necessary in the life of the patient often repeated operative revisions. One of the starting ideas of the modern neuroendoscopy was therefore to reintroduce the endoscopic methods instead of shunt implantations in the treatment of obstructive hydrocephalus with technically advanced instruments. The endoscopic procedure in form of the ventriculocysternostomy had the advantage of being a single procedure and being more physiological regarding the CSF circulation than the shunt systems using a valve with constant flow. Other motivation to apply endoscopy in neurosurgery was the general trend in the operative disciplines in the late 80th toward a minimally invasive surgery.

2.2.2 Technical development

Present neuroendoscopy would not be possible without substantial improvements in image quality and endoscope flexibility. The major breakthrough in the endoscope technology and optical quality goes back to the work of Harold Horaz Hopkins (1918–1994), a professor of physics at the university of Reading, United Kingdom (Mc Combie & Smith 1998). He probably remained only a recognized physicist, if he had not been approached 1951 at a dinner party by a physician who complained about the poor image quality and rigidity of the endoscopes. Encouraged by the subsequent discussion Hopkins developed the idea of using glass fibres for image transmission. 1951 he assembled a bundle of glass fibres with a higher refractory index of the core than of the cladded coat to improve light transmission over a longer distance by total reflexion (Fig. 3).

1953 he and his fellow researcher produced a bundle of fibres with precisely the same order at the proximal and distal ends, leading to a coherent image. They published their results in Nature 1954 (Hopkins & Kapany 1954). In the following years there was no interest from the industry in the technique and Hopkins could not continue his research. He sent letters about his invention and obtained a positive response only from Basil Hirschowitz, a gastroenterologist in Ann Arbor, US. He visited Hopkins and discussed the details of his work. After his return to US Hirschowitz continued the work of Hopkins. He improved the technique using a better permanent coating of the fibres. The prototype of this flexible fiberscope was presented for the first time at a meeting of gastroenterologists in Colorado Springs in 1957 (Hirschowitz et al 1958, McCombie & Smith 1998). To improve the image quality the number of glass fibres increased up to 200 000. For this amount of fibres the preservation of the topological fibre arrangement at both ends of the fibre bundle was essential. 1975 Max Eppstein, a German scientist developed a system of isolation which preserved the alignment of the fibers and thus guaranteed an undistorted image during twisting of the endoscope (Eppstein 1975, 1980). The development of the flexible fiberscope was completed by implementation of an external cold light source and an adjustable tip of the endoscope.

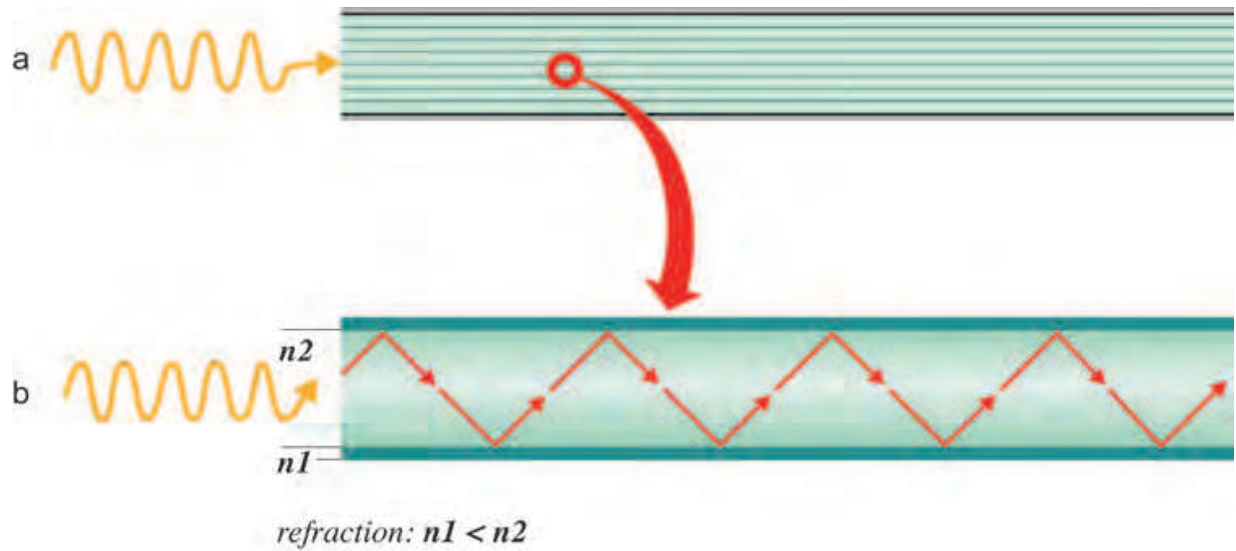


Fig. 3. Principle of Hopkins flexible glass fiberscope. Complete fibre bundle (a). Single fibre showing the propagation of the image over long distance inside the endoscope(b). This works by total reflection based on the lower refraction of the coating $n1$ in comparison to the glass fibre $n2$.

In his theoretical work as physicist Hopkins made substantial contributions to mathematical calculations of relay lenses aberrations and its possible compensation (Hopkins 1950, Hopkins & Tiziani 1966). This theoretical knowledge was the presupposition for his main endoscopic invention the improvement of the image quality of the rigid endoscopes. His main idea was to replace the relay of lenses with long interspaces of air by rod glass lenses with small air gaps between the appropriate cut rod edges. This reversed the proportion of air and glass inside the shaft. The higher refractive index of glass in comparison with air improved the light transmission by a factor of 9 (Fig. 4).

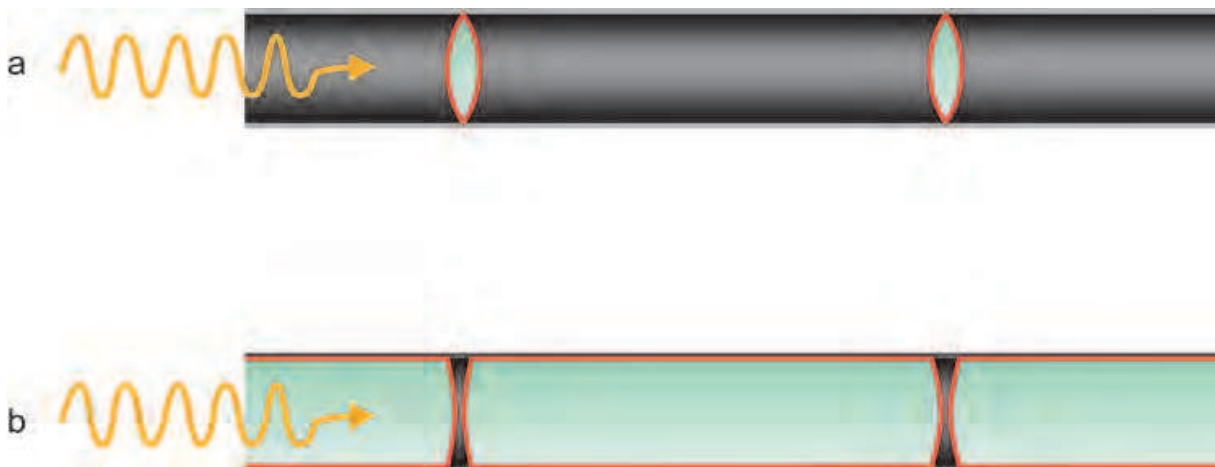


Fig. 4. Principle of rigid rod lens endoscope. Nitze optics with small lenses and long air interspaces between the lenses (a). Hopkins rigid rod lens endoscope (b) with reversed portion of glass to air in comparison to Nitze optic improving the optical quality and illumination by a factor of 9.

Additionally this increased the viewing angle and allowed simultaneously to decrease the diameter of the optics. Supported was the light transmission by an anti-reflection coating of the lenses. All these improvements resulted in an approximately 80 fold increase of illumination in comparison to the available standard rigid endoscopes of that time. The invention was made 1960 and the first prototype was presented 1961 during an urological meeting in Brazil (McCombie & Smith 1998). It followed the same silence and ignorance. In 1964 Hopkins presented the same invention again during a lecture in Düsseldorf. This time, however, the potential of his invention was immediately recognized by the attending Karl Storz, the head of the Storz Company for optical instruments. A fruitful cooperation began. Storz contributed substantially by replacing the illumination source from the tip of the endoscope with a remote external device. This so-called "cold light" was originally a halogen light that was transported via separate glass fibres through the shaft of the endoscope to its tip. 1967 the first commercial product was introduced to the market. Today xenon light sources are used instead halogen, whose effective power was restricted to 250 W and caused a yellow image quality.

The technical development of rigid rod-lens endoscopes was completed by the introduction of video cameras for imaging to replace direct observation by surgeon looking through the endoscope. For this purpose light, miniature electronic cameras equipped with charge-coupled (CCDs) transforming the light into a digital signal contributed essentially to the miniaturization of the cameras, which could be directly connected to the endoscope oculars with a sterile cover. This set up originally assembled for urology, minimally invasive abdominal surgery and arthroscopy was commercially available at the end of the 1980s.

For optical reasons the application of endoscopy is restricted to cavities of the human body. In the intracranial space these are the ventricles and the subarachnoid space. Therefore pathologies in the ventricles constituted also the first applications of this minimally invasive endoscopic technique.

2.2.3 Clinical application

In the late 80s several groups of neurosurgeons scattered around the world such as Patrick Kelly (Kelly et al 1986), Kim Manwaring and Allan Cohen in US, Jacques Caemaert in Belgium (Caemaert 1992), (Jones et al 1996). Christiane Sainte-Rose in France (Sainte-Rose 1992) and Nigel Jones and Charles Teo in Australia made positive experience with the ETV technique. Strong activity regarding the systematic endoscope related basic anatomical research, the adaptation of endoscopic instruments to neurosurgical requirements and the indications, applications and standards in the neuroendoscopy are associated with 5 centres on the European continent. Activity at these centres started nearly simultaneously and independently of each other around 1990. Notable neurosurgical centres were in Germany Dieter Hellwig and Bernhard Bauer in Marburg (Hellwig & Bauer 1992, Hellwig et al 1997), Axel Perneczky, Peter Grunert, Nikolai Hopf and Klaus Resch in Mainz (Perneczky et al 1994, 1998) and Michael Gaab, Henry Schröder and Joachim Oertel in Greifswald (Gaab & Schröder 1998, Oertel et al 2009). Further in Netherland Nijmegen Andre Grotenhuis a close friend of Perneczky and in Belgium Ghent Jacques Caemaert. These centres had a common endoscopic concept and a synchronous development regarding neuroendoscopic technical innovations and an increase in clinical experience with a similar number of surgical patients. Despite some different opinions on details, the activity of these centres can be summarized due to their lasting effect abroad as a common "continental" development of modern

contemporary neuroendoscopy. Their knowledge on endoscopy spread over the world due to many practical international courses organized in each centre every year.

The first practical experience in neuroendoscopy was gathered during intraventricular third ventriculostomies for the treatment of obstructive hydrocephalus. This was also in the 90s the most frequent type of neuroendoscopic operations.

Most of the centres performed initially the endoscopic third ventriculostomies (ETV) by frame based stereotactic technique. This enabled the planning of a precise trajectory through the foramen of Monro to the floor of the third ventricle. Additionally for the long nose-heavy cystoscopes the stereotactic frame provided in that time an excellent stable holding of the endoscope and made possible for the surgeon to work with both hands simultaneously. A disadvantage of framebased endoscopy consisted in the restricted mechanical flexibility to change the position of the endoscope under visual endoscopic view. This was partially overcome by construction of a guiding block with a ball joint which allowed under 0° a straight precise introduction of the endoscope and simultaneously after unlocking the endoscope in the block to have a free play in every direction under visual endoscopic view of 15° (Fig. 5).

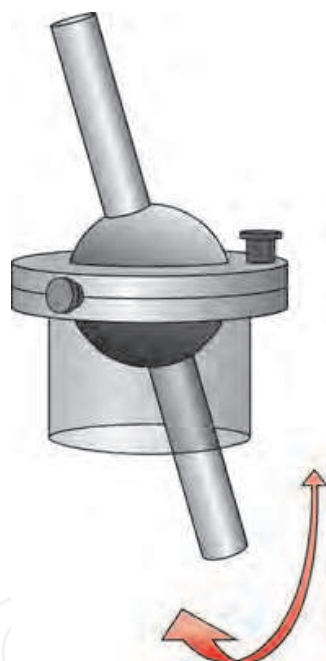


Fig. 5. Guiding block with ball joint. The ball joint allowed movement of the endoscope in any direction in a range of 15° . The upper metallic disc with the screws at the guiding block provided a fixation of the endoscope.

The stereotactic endoscopic third ventriculostomy was performed using CT images. With the CT adapted localisation frame the coordinates of two target points were calculated one at the level of the foramen of Monro and a second few slices below at the level of the floor of the third ventricle. Since in transversal CT slices the floor of the third ventricle was in general not visible the slice at the upper level of dorsum sellae was chosen for calculation. To protect the important surrounding anatomical structures the optimal target point was in the midline immediately behind the dorsum sellae and in front of the tip of the basilar artery (Fig. 6).

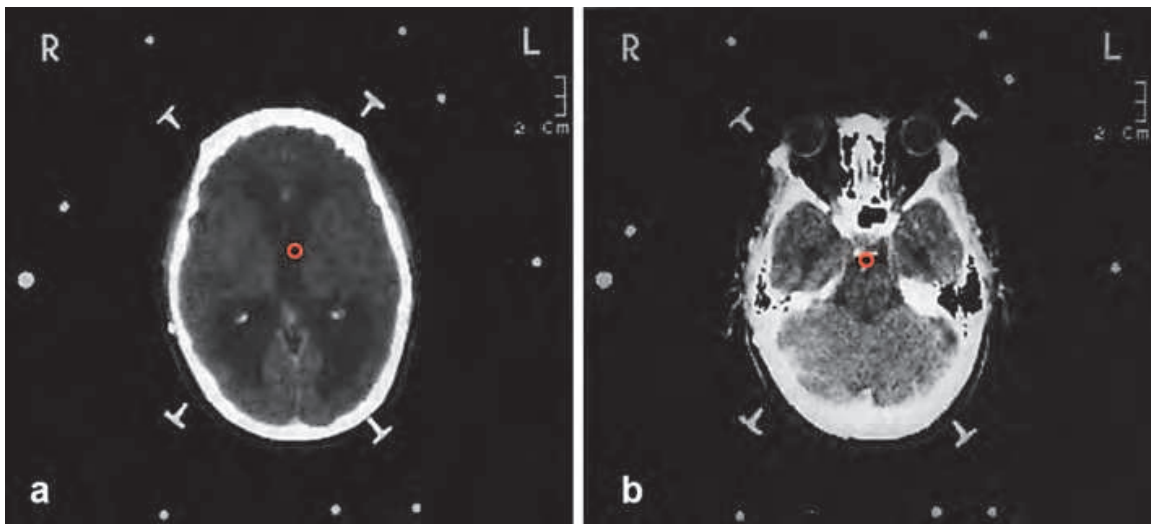


Fig. 6. CT-based stereotactic calculation of two target points for the ventriculostomy. Calculation of the foramen of Monro visualized by a circle (a) and the target at the floor of the third ventricle between the dorsum sellae and the basilar artery in the midline (b).

This CT -based calculation constituted the planned area for perforation. The final area for perforation was decided during the endoscopic procedure respecting the directly visible anatomical structures at the floor of the third ventricle. These two calculated target points one at the level of the foramen Monro and the second behind the dorsum sellae defined geometrically a line in the space which corresponded to the optimal trajectory (Fig. 7).

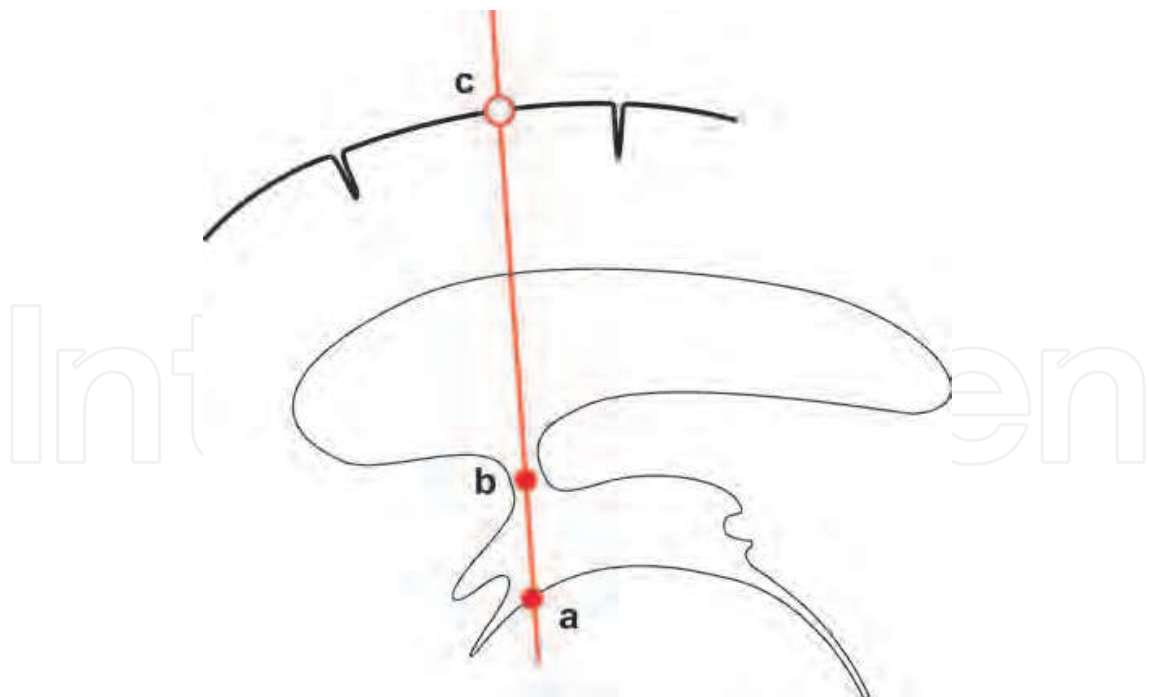


Fig. 7. Principle of stereotactic ventriculostomy. The coordinates of two points in the space were calculated, (a) at the level of the floor of the third ventricle and (b) at the level of the foramen of Monro. These two points defined a straight line in the space and thus implicitly also the trepanation point respectively the point (c) where the cortex was perforated.

Additionally these two target points determined implicitly the trepanation point. In most of the cases area thus defined trepanation point was within an area 1cm before till 1cm behind the coronar suture in the anterior posterior direction and 1.5 cm–3 cm laterally from the midline. For these stereotactic procedures originally a 6 mm diameter rigid Wolff cystoscope (Fig. 8) with four channels one 1.5 mm diameter working channel 2.3 mm optical channel, and two channels for rinsing were used. Because of their much better optical quality the rigid endoscopes were superior for neurosurgical purposes in the ventricles than the flexible fibrescopes.




Fig. 8. First stereotactic endoscopic equipment in Mainz. Wolff 6mm cystoscope with 4 channels at the top. At the bottom: guiding block with the ball joint (right side) and a plastic disc for adjusting the endoscope in a coaxial direction of 0°.

After stereotactic calculation of the trajectory the head of the patient in the frame was fixed in the operating theatre by Mayfield adapter to the operating table in an inclination of 20°–30°. By this inclination the burr-hole was at the top and CSF leakage from the lateral ventricle during the endoscopy was minimal. This precaution guaranteed that the endoscope was advanced in the ventricles entirely within CSF and disturbing optical artefacts in form of mirror images could be avoided. After setting a burr-hole, opening of the dura mater a corticotomy was performed and slightly dilated on the surface to let easily introduce the endoscope into the brain substance. In the depth of 4.5 cm–5 cm the endoscope was fixed the trocar removed and the optic introduced. Usually at this level the endoscope tip was inside the lateral ventricle and a view of the lateral ventricle centred on the foramen of Monro was possible (Fig. 9).

Inside the lateral ventricle under visual control the endoscope was advanced to the foramen of Monro. To prevent injury during the passage through the foramen of Monro it was essential that the optical and mechanical axes coincided. For this reason during introduction of the endoscope the 0° optics was always used. At the level of the foramen the anatomical structures of the fornix and the deep intracerebral veins had to be respected. In the third ventricle the perforation was performed in front of the mamillary bodies and behind the dorsum sellae and the infundibular recessus (Fig. 10).

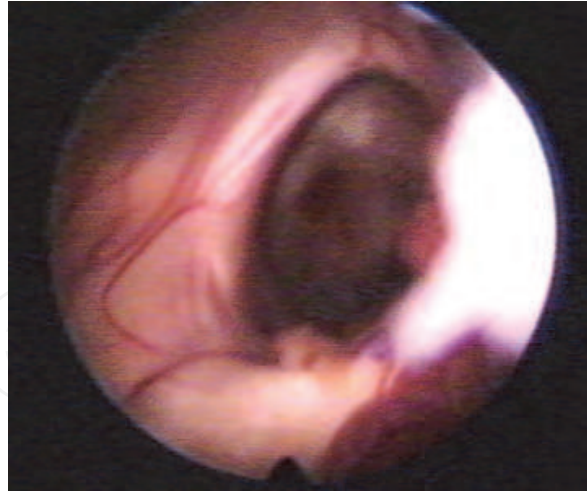


Fig. 9. Foramen of Monro during first endoscopic ventriculostomy in Mainz 1992. Endoscopic view of the right foramen of Monro confined medially by the fornix. The white spot in the image corresponds to a piece of ependyma wall sticking on the optics of the endoscope. It covers partially the choroid plexus and the thalamostriatal vein. The floor of the third ventricle is visible through the foramen of Monro with a red vascularized spot corresponding to the infundibular recessus.

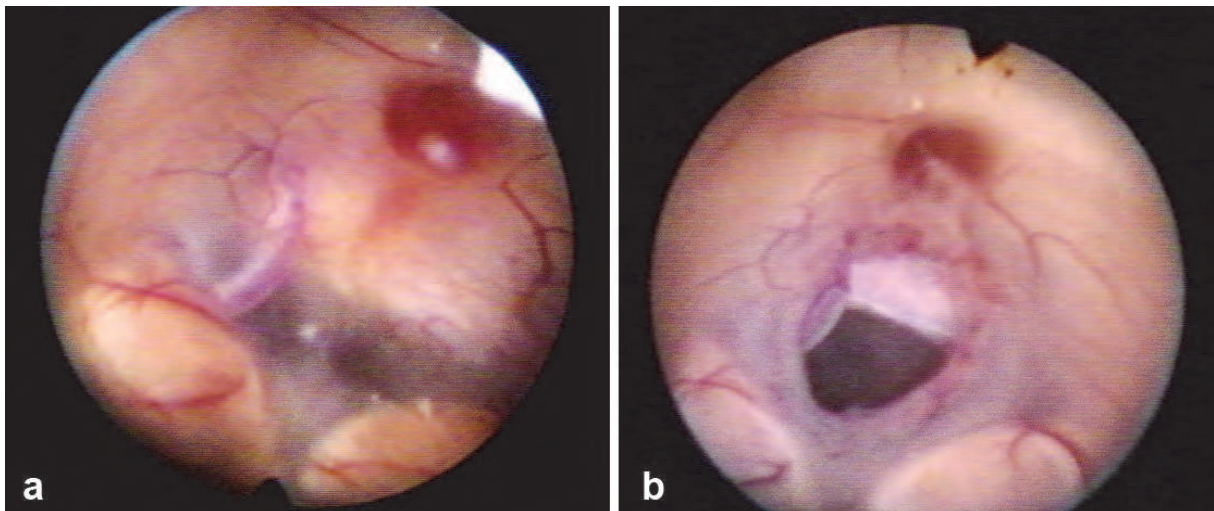


Fig. 10. Endoscopic view of the floor of the third ventricle during first ventriculostomy in Mainz 1992. Anatomy before perforation (a). Notice the mamillary bodies, and the posterior communicating artery. The red spot is the recessus infudibularis. Floor of the third ventricle after perforation (b). Notice the perforation between the dorsum sellae and in front of the mamillary bodies.

In patients with long lasting hydrocephalus the floor of the third ventricle was often thinned out to a translucent membrane. In these cases the whole anatomical structures laterally and under the floor of the third ventricle were visible including the basilar artery, the posterior communicating arteries and the oculomotor nerves. The perforation was performed bluntly with a Fogarty catheter or a forceps and dilated in steps with a balloon catheter till a diameter between 5 mm – 7 mm was reached.

The ventriculocysternostomies were very effective in the treatment of obstructive hydrocephalus. We performed the first 40 patients with the stereotactic framebased technique and the consecutive with free hand technique. From 150 evaluated patients operated between 1992–2000 best results with a long lasting success rate of 84% were obtained in adults with benign aqueduct stenosis followed by adults with a tumour obstructing the aqueduct with a success rate of 81.6%. Infants had less good outcome. A closure of the stoma was a rare event. In these patients we performed a reventriculostomy and were successful in 75% of the patients. Patients who had no profit of the ventriculostomy or worsened obtained a ventriculo-peritoneal shunt.

Comprehensive survey of the techniques and results of the third ventriculostomy in obstructive hydrocephalus can be found in the excellent review article of Hellwig published in the *Neurosurgical Review* (Hellwig et al 2005).

This above mentioned basic endoscopic technique with slight modifications was applied in the 90th for pellucidotomies in cases of unilateral dilatation of the lateral ventricle. Further the endoscopic technique was used for opening of cysts inside the ventricle or in the ventricle wall including the so called “captured fourth ventricle” in the posterior fossa. To prevent a secondary closure of the perforation for this last type of pathology a catheter was implanted through the aqueduct into the cyst in the fourth ventricle connecting the fourth ventricle with the third and lateral ventricles. Additionally in selected patients with thin good accessible membrane in the aqueduct an aqueductoplasty by opening and dilatation of the membrane inside the aqueduct was performed. However the complication rate of the aqueductoplasty was due to the nuclei and pathways in the midbrain immediately around the aqueduct higher than for the ventriculostomies. With higher experience and improved technology for hemostasis intraventricular lesions such as colloid cysts and intraventricular tumours were also removed or biopsied by minimally invasive endoscopic technique.

Hopf adapted the neuronavigation systems to endoscopes and the endoscopes could be used as pointers for planning the trajectory and for additional orientation during surgery (Hopf et al 1999). The second generation of endoscopes were already adapted to the neurosurgical requirements they were shorter and not so nose-heavy. This improved the handling of the endoscope by one person. With greater experience the frame based stereotactic technique was replaced by a free hand technique supported by holding arms. These were at the beginning two Leila retractor arms and later special arm holders which were attached to the operating table. The development of the endoscopes was pushed on ahead by the Storz, Wolff and Aesculap companies.

At the beginning of 90s Norbert Hüwel from Mainz used flexible endoscopes during syringostomies in the treatment of syringomyelia. He introduced the flexible endoscope into the syrinx cavity and fenestrated the membranes inside the syrinx in addition to the implantation of a syringo-subarachnoidal tube. However in patients with a syringomyelia due to Arnold Chiari II malformation the resection of the cerebellar tonsil with the aim to improve the CSF flow at the craniospinal level was superior to the endoscopic treatment.

In this time in Mainz Perneczky integrated the endoscope during microvascular procedures and resections of tumours to control the position of the aneurysma clip or with high degree optics “around the corner” to control the completeness of the tumour resection at the skull base. The idea was to use the endoscope during microsurgical interventions at a particular stage of the operation as a tool similar as any other surgical instrument such as the scalpel the suction or the drill. By means of the endoscope the illumination was transported into the

depth of the operating area and complemented the view from the perspective of the microscope. By the endoscope more anatomical details could be distinguished. This proved to be valuable for instance during microvascular decompressions and all types of skull base surgery. Perneczky coined for this type of operations the term “endoscope assisted microsurgery” (Perneczky et al 1994, Pernecky & Fries 1998).

This idea of transportation of the illumination by means of an endoscope into the depth of the operating area was quickly picked up by neurosurgeons in the US and applied for transnasal pituitary surgery by Hae-Dong Jho (Jho 1996a, 1996b) 1996 in the endoscopic department of the centre for minimally invasive neurosurgery in Pittsburg. In Europe this type of endoscopic pituitary surgery was introduced 1998 by Cappabianca in Naples (Cappabianca et al 1998). By this minimally invasive endoscopic approach Amin Kassam (Kassam et al 2010) described removal also of lesions at the frontal skull base and clivus. In Mainz endoscopic pituitary and skull base surgery was introduced 2003 by the pupils of Perneczky, Robert Reisch and Patra Charalampaki. After both left Mainz, this work was continued by Ali Ayyad and Jens Conrad. Meanwhile the scope of endoscopic neurosurgical operations includes also spinal and peripheral nerve surgery. Joachim Oertel coming from Hannover, where he was working with Gaab, introduced 2009 the spinal endoscopy also in Mainz.

3. Conclusion

From the historical point of view we can distinguish two periods in neuroendoscopy. An early period at the beginning of the modern neurosurgery in the 20s of the 20th century and an advanced period since the late 80s of the 20th century. In each period the clinical application was proceeded, accompanied and closely related to the technical development of the appropriate endoscopes. We can summarize this early neuroendoscopy period as a time of the first trials. They took place at different universities in the United States by pioneers of the modern neurosurgery. They recognized already in that time the potential use of the neuroendoscopy in the ventricles, but they gave up this technique after few trials due to technical and optical limitations of the available endoscopes. In contrary to the early period of neuroendoscopy the modern endoscopes fulfil all requirements and expectations regarding optical quality, safety and flexibility necessary also for neurosurgical applications. Therefore in this advanced period of neuroendoscopy the endoscopes became an accepted and permanent tool during neurosurgical interventions in a variety of neurosurgical fields.

4. Acknowledgment


The authors thank Stefan Kindel for his accurate, detailed and likewise artistically attractive illustrations.

5. References

- Aschoff, A.; Kremer, P.; Hashemi, B. & Kunze S. (1999). The scientific history of hydrocephalus and its treatment. *Neurosurg. Review* 22: 67-93
- Cappabianca, P.; Alfieri, A. & Devitiis, E. (1998). Endoscopic endonasal transsphenoidal approach to the sella: towards functional endoscopic pituitary surgery (FEPS) Minim invas neurosurg. 41: 66-73

- Caemaert, J.; Abdullah, J.; Calliaw, L.; Carton, D.; Dhooge, C. & Coster, R. (1992). Endoscopic treatment of suprasellar arachnoidal cysts. *Acta neurochirurgica (Wien)* 119: 68-73
- Dandy, WE. & Blackfan, KD. (1913). An experimental and clinical study on internal hydrocephalus. *JAMA*. 61: 2216-2217
- Dandy, WE. & Blackfan, KD. (1914). Internal hydrocephalus. An experimental clinical and pathological study. *Am J. Dis Child* 8: 406-482
- Dandy, WE. (1918). Extirpation of the choroid plexus of the lateral ventricles in communicating hydrocephalus. *Ann. Surg.* 37: 569-579
- Dandy, WE. (1921). The cause of so called idiopathic hydrocephalus *Johns Hopkins Hosp. Bull.* 32: 67-74
- Dandy, WE. (1932). *Practice of surgery*, vol XII, chapter 1, (Dean Lewis ed.), WF Prior Company, Hagerstown
- Dèsormeaux, AJ. (1865). *De l'endoscope et de ses applications au diagnostique et au traitement de affections de l'urethre et de la vessie*, JB Baillier, Paris
- Doglietto, F.; Prevello, DM.; Jane, JA.; Han, J. & Laws ER. (2005). A brief history of endoscopic transsphenoidal surgery - from Philipp Bozzini to the first world congress of endoscopic skull base surgery. *JNS Neurosurgical focus*: vol 19(6) DOI: 10.3171/foc.2005.19.6.4
- Eppstein, M. & Marhic, ME. (1975) Fiber optic laser illumination. *Proc IEEE* 63: 727
- Eppstein, M. (1980). Developments of optical instrumentation. *Science* 210:280-285
- Fay, T. & Grant, FC. (1923). Ventriculography and intraventricular photography in internal hydrocephalus. *JAMA* 80:461-463
- Gaab, MR. & Schröder, HW. (1998). Neuroendoscopic approach to intraventricular lesions. *J. Neurosurg.* 88: 496-505
- Hellwig, D.; Grotenhuis, JA.; Tirakotai, W.; Riegel, T.; Schulte, DM.; Bauer, BL. & Bertalanffy, H. (2005). Endoscopic third ventriculostomy for obstructive hydrocephalus. *Neurosurg. Rev.* 28: 1-34
- Hellwig, D. & Bauer, BL. (1992). Minimally invasive neurosurgery by means of ultrathin endoscope. *Acta neurochir Suppl. (Wien)* 54: 63-68
- Hellwig, D.; Benes, L.; Bertalanffy, H. & Bauer, BL. (1997). Endoscopic stereotaxy - an eight year experience. *Stereotact. Funct. Neurosurg.* 68: 90-97
- Hirschowitz, BL.; Curtis, LE.; Peters, CW. & Pollard, HP. (1958). Demonstration of a new gastroscope the "fiberscope". *Gastroenterology* 35: 50-53
- Hopf, N.; Grunert, P.; Darabi, K.; Busert, C. & Bettag, M. (1999). Frameless neuronavigation applied to endoscopic surgery. *Minim. Invas Neurosurg.* 42: 187-193
- Hopkins, HH. (1950). *Wave theory of aberrations*. Oxford university press.
- Hopkins, HH. & Kapany, NS. (1954). A flexible fiberscope using static scanning. *Nature* 1954; 173:39-41
- Hopkins, HH. & Tiziani, HJ. (1966). A theoretical and experimental study of lens centring errors and their influence on image quality. *Brit J. Appl. Phys.* 17: 33-55
- Huwel, N.; Perneczky, A.; Urban V. & Fries G. (1992). Neuroendoscopic technique for the operative treatment of septated syringomyelia. *Acta Neurochir. Suppl.* 54:59-62
- Walter Dandy and neuroendoscopy. Historical vignette. *JNS Neurosurgical Focus* (3) DOI: 10.3171/2009.1. PEDS08342

- Jho, HD. & Carau, RL. (1996). Endoscopy assisted transsphenoidal surgery of pituitary adenoma. Technical note. *Acta neurochirurgica*. 138:1416-1425
- Jones, RFC.; Stenting WA.& Brydon M.(1990). Endoscopic third ventriculostomy. *Neurosurgery* 26: 86-92
- Kassam, AB.; Prevedello, DM.; Carau, RL.; Suyderman, CH.; Thomas, A. & Horowitz, MB. (2010). Endoscopic endonasal skullbase surgery. Analysis of complications in the author's initial 800 patients. *J. Neurosurgery*. PMID 21166570
- Kelly, PJ.; Goerss, SJ.; Kall, BA. & Kispert, DB. (1986). Computed tomography based stereotactic third ventriculostomy: technical note. *Neurosurgery*. 18: 791-794
- King, RB. (2003). Third ventriculostomy for internal hydrocephalus complicated by unrecognized subdural hygroma and hematoma: a case report of a patient treated by Walter Dandy. *JNS*. DOI: 10.3171/jns.2003.985.1136
- Leiter, J. (1880). *Elektro-Endoskopische Instrumente. Beschreibung und Instruction durch M. Nitze und J. Leiter. Wilhelm Braunmüller und Söhne Wien.*
- Mc Combie, CW. & Smith, J. (1998). Harold Horaz Hopkins. 6. December 1918-22. October 1994. *Biographical memories fellows of the royal society*. 44: 239-252
- WJ Mixer, WJ. (1923). Ventriculoscopy and puncture of the floor of the third ventricle. *Boston med Surg J*. 188: 277-278
- Netzhat, C. (2005). Bozzini the beginning of early modern endoscopy, chapter 6 (a), the era Nitze chapter 11(b) *History of Endoscopy*, <http://laparoscopy.blogs.com/endoscopyhistory>
- Nitze, M. (1889). *Lehrbuch der Kystoskopie. Technik und klinische Bedeutung. Von Bergmann Verlag, Wiesbaden*
- Northwestern university Feinberg school of medicine. Dept. of history. <http://www.feinberg.northwestern.edu/neurosurgery/residency/history>
- Oertel, JM.; Baldauf, J.; Schröder, HW. & Gaab, MR. (2009). Endoscopic options in children: experience with 134 procedures *J. Neurosurg. (Suppl. Pädiatr.)* 3:81-89
- Pernecky, A.; Cohen, A.; George, B. & Kanno, T. (1994). Editorial. *Minimal. Invas. Neurosurgery*. 37:1
- Pernecky, A. & Fries, G. (1998). Endoscope-assisted brain surgery Part I. Evolution, basic concept and current technique. *Neurosurgery*. 42: 557-569
- Sainte- Rose, C. (1992). *Third ventriculostomy. Neuroendoscopy, Manwaring HK.& Crone KR,eds, Neuroendoscopy, Mary Ann Lieber, New York*
- Scarff, JE. (1936). Endoscopic treatment of hydrocephalus: description of the ventriculoscope and primary report of cases. *Arch. Neurol.Psychiatry* 35: 853-861
- Scarff, JE.& B. Stookey, B. (1936). Treatment of obstructive hydrocephalus by third ventriculostomy. Report of two cases. *Arch Neur*. 36: 1400-1411
- Scarff, JE. (1951). Treatment of obstructive hydrocephalus by puncture of lamina terminalis at the floor of the third ventricle. *J. Neurosurg*. 8: 204-213
- Shah. J. (2002). Endoscopy through the ages. *BJU International*. 89: 645-652
- Schultheiss, D.& Moll, F. (2009). *Die Geschichte der Urologie in Dresden (The history of urology in Dresden)*, Springer Verlag, ISBN 9783642035937, Berlin
- Verger-Kuhnke, AB.; Reuter, MA. & Beccaria,ML. (2007). Biography of Maximilian Nitze (1848-1906) and his contribution to urology. *Acta Urol. Esp*. 31: 697-704



Advances in Endoscopic Surgery

Edited by Prof. Cornel Iancu

ISBN 978-953-307-717-8

Hard cover, 444 pages

Publisher InTech

Published online 25, November, 2011

Published in print edition November, 2011

Surgeons from various domains have become fascinated by endoscopy with its very low complications rates, high diagnostic yields and the possibility to perform a large variety of therapeutic procedures. Therefore during the last 30 years, the number and diversity of surgical endoscopic procedures has advanced with many new methods for both diagnoses and treatment, and these achievements are presented in this book. Contributing to the development of endoscopic surgery from all over the world, this is a modern, educational, and engrossing publication precisely presenting the most recent development in the field. New technologies are described in detail and all aspects of both standard and advanced endoscopic maneuvers applied in gastroenterology, urogynecology, otorhinolaryngology, pediatrics and neurology are presented. The intended audience for this book includes surgeons from various specialities, radiologists, internists, and subspecialists.

How to reference

In order to correctly reference this scholarly work, feel free to copy and paste the following:

P. Grunert and J. Oertel (2011). Technical and Clinical Evolution of Modern Neuroendoscopy, Advances in Endoscopic Surgery, Prof. Cornel Iancu (Ed.), ISBN: 978-953-307-717-8, InTech, Available from: <http://www.intechopen.com/books/advances-in-endoscopic-surgery/technical-and-clinical-evolution-of-modern-neuroendoscopy>

INTECH
open science | open minds

InTech Europe

University Campus STeP Ri
Slavka Krautzeka 83/A
51000 Rijeka, Croatia
Phone: +385 (51) 770 447
Fax: +385 (51) 686 166
www.intechopen.com

InTech China

Unit 405, Office Block, Hotel Equatorial Shanghai
No.65, Yan An Road (West), Shanghai, 200040, China
中国上海市延安西路65号上海国际贵都大饭店办公楼405单元
Phone: +86-21-62489820
Fax: +86-21-62489821

© 2011 The Author(s). Licensee IntechOpen. This is an open access article distributed under the terms of the [Creative Commons Attribution 3.0 License](#), which permits unrestricted use, distribution, and reproduction in any medium, provided the original work is properly cited.

IntechOpen

IntechOpen