

# We are IntechOpen, the world's leading publisher of Open Access books Built by scientists, for scientists

**4,800**

Open access books available

**122,000**

International authors and editors

**135M**

Downloads

Our authors are among the

**154**

Countries delivered to

**TOP 1%**

most cited scientists

**12.2%**

Contributors from top 500 universities



**WEB OF SCIENCE™**

Selection of our books indexed in the Book Citation Index  
in Web of Science™ Core Collection (BKCI)

Interested in publishing with us?  
Contact [book.department@intechopen.com](mailto:book.department@intechopen.com)

Numbers displayed above are based on latest data collected.

For more information visit [www.intechopen.com](http://www.intechopen.com)



# Virtual Endoscopy of the Nasal Cavity and the Paranasal Sinuses

Sumeet Anand, Rickul Varshney and Saul Frenkiel  
*McGill University, Department of Otolaryngology – Head & Neck Surgery  
Canada*

## 1. Introduction

The ideal approach to sinus surgery has been a mystery that many Otolaryngologists have attempted to discover throughout their career. The intricate and complex anatomy of the nasal cavity and paranasal sinuses has challenged many in terms of adequate exposure during surgery, as well as proper relief of patient symptoms. From the days of Hirschmann, who used a modified cystoscope to examine the sinuses in 1901 (Draf, 1983, as cited in Rice & Schaefer, 2004), to the work of Messerklinger and Wigand in establishing operative techniques later in that century (Rice & Schaefer, 2004), surgeons have appreciated the obscurity and complexity of endoscopic sinus surgery for decades.

Traditionally, pre-operative planning has consisted of imaging modalities, namely x-rays and computed tomography (CT) scans, as well as flexible or rigid endoscopy in the clinic. With the advent of helical CT in the late 1980s, pre-operative imaging has improved dramatically. It is faster than the conventional CT scanner and provides more details (Wood & Razavi, 2002). In fact, helical CT has provided physicians with the ability to attain reconstruction of axial images into coronal and sagittal views with resolution quality equivalent to the original axial cuts. Imaging for the paranasal sinuses is ideally viewed in coronal slices as Otolaryngologists enter the nasal cavity in an anterior-posterior direction rather than the cephalocaudal direction represented by axial slices. Furthermore, the coronal view allows the examination of critical relationships such as the osteomeatal complex, not provided by axial imaging. The use of MRI for better soft tissue examination and less artifacts has also improved imaging of the head and neck (Kettenbach et al., 2008). The dependence of Otolaryngologists on proper pre-operative imaging highlights the strong relationship between radiologists and otolaryngologists in endoscopic sinus surgery in order to precisely locate numerous vital structures, such as the orbits and the internal carotid arteries, surrounding the nasal cavity and the paranasal sinuses and to identify benign and pathologic anomalies.

Recently, virtual endoscopy (VE) through reconstruction of CT images has interested Otolaryngologists that perform endoscopic sinus surgery. This contemporary technology facilitates the difficult task of mentally conceptualizing complex and intricate anatomy in a three-dimensional model from two-dimensional CT images, a task that requires years of experience to truly master. VE utilizes the technique of surface or volumetric rendering to process data provided by CT images to allow three-dimensional visualization of tubular

anatomical structures (Rubin et al., 1996). This modality has been used in the past for imaging of the colon (Pineau et al., 2003) and more recently in imaging of the tracheobronchial tree (Vining et al., 1996), urinary tract, vessels, the middle ear and the paranasal sinuses (Han et al., 2000; Ossoff & Reinisch, 1994; Rogalla et al., 1998). This chapter explores the use of VE in the imaging of the nasal cavity and the paranasal sinuses. The technical aspects of VE, the uses in Otolaryngology and Radiology, the benefits for pre-operative and intra-operative planning, the roles in endoscopic sinus surgery training, as well as future directions will be discussed.

## 2. Technical aspects of Virtual Endoscopy

In essence, VE is a reformation of axial CT images into a 3D model using sophisticated software. In the present age where the medical system is influenced by a paucity of resources and increasing waiting times for diagnostic tests, VE provides a useful diagnostic adjunct for the surgeon, without the need of additional tests. There are no required particular CT specifications over the standard scanner and thus, any patient who can undergo a CT sinus can have a three-dimensional model created.

The process begins with a low-dose spiral CT scan, as routinely performed for sinus imaging. Axial slices of 2.5mm thickness are acquired at an interval of 1.25 mm, therefore providing an overlap of collected information. No intravenous contrast is used for the scan. The images are then reconstructed into thinner 0.625 mm slices at an increment of 0.625 mm using a standard algorithm. Thereafter, these images are processed through rendering into a three-dimensional model using software provided with a 64-multislice General Electrics (GE) LightSpeed scanner (Milwaukee, WI). VE software is accessed on a GE workstation in our radiology department, which was provided with the scanner without an additional fee. There are two main methods for post-processing, namely surface rendering and volume rendering. We use volume rendering at our institution for reasons that will be explained later in this chapter. Although the process of post-processing is complex, we present a brief overview of the two methods.

In order to understand the process of reformatting, it is useful to appreciate the significance of a voxel. The latter is defined as a volume element (Rogalla et al., 2000) or the smallest distinguishable volume part of a 3D space. These individual voxels merge to create the three-dimensional model, analogous to a two-dimensional image formed by pixels (Gilani et al., 1997).

### 2.1 Surface rendering

Surface rendering works by defining a certain threshold as to determine which pixels will be included in the model and which ones will not (Rogalla et al., 2000). Surface rendering then creates a 3D model by linking the contours of selected objects from one slice of a CT with the adjacent slices (Wood & Razavi, 2002). Segmentation, as an intermediate step, is done to transform the volume into a mesh of polygons (Kettenbach et al, 2008; Rogalla et al., 2000). The polygons are then formed into a 3D model using specialized software often provided with the CT scan machine. Authors have suggested threshold ranges from -520 to -200 Hounsfield units (HU) in order to remove voxels denser than -500 HU. They recommend that thresholds of -250 and -400 HU be used to optimally view the nasal anatomy in healthy patients or those with sinonasal disease (Kettenbach et al, 2008). Although it is faster than

volume rendering, surface rendering has poorer definition (Wood & Razavi., 2002), as there is data loss about the inner aspects of the polygons and artifacts. Furthermore, the axial images can be manipulated to show the surface structures modified by shading techniques, a process entitled surface shaded display. Surface shading can be done based on distance of the surface from the observer or the orientation of the surface in question. This differential shading pattern allows the surgeon to appreciate the position of one structure relative to another (Rogalla et al., 2000).

## **2.2 Volume rendering**

Volume rendering consists of creating images by casting rays from an observation point from two possible locations, either outside the volume being visualized or from within it. The difference between surface and volume rendering is that it does not focus solely on the surface features, but also displays the structures as though they are partially transparent by modifying the percentage of light ray within a voxel (Kettenbach et al, 2008). In volume rendering, the volume data itself is analysed without the surface representation step of surface rendering.. (Rogalla et al., 2000) Also, all the pixels are kept in memory, as oppose to surface rendering which has a set threshold (Rogalla et al., 2000). This allows the acquisition of more information and increased detail with an expense, however, of increased need of data processing and time consumption. The quality of the processed three-dimensional model can be improved with increased quality of the original axial images, namely through thinner slices and greater pixel formatting (Kettenbach et al., 2008).

## **2.3 Flight path**

The three-dimensional model provides the surgeons the ability to navigate through the created structure. VE software displays an optical electronic apparatus to dynamically navigate an organ lumen – the virtual endoscope. The navigation tool allows the operator to “fly through” or “sail through” the three-dimensional anatomy, traveling in any direction or any position in the nasal cavity and paranasal sinuses. The virtual endoscope is shown here (Figure 1) simultaneously traveling in the axial, sagittal and coronal planes. Orientation to the virtual endoscope is made easier to follow by these corresponding reference planes. Images are initially presented in a greyscale, though functions of the software allow subjective colour assignments to represent anticipated anatomic tissue hues.

The “flight path” is the route of flight as determined by the operator. This course can be set to emulate a course similar to conventional fiberoptic endoscopy or can be set to explore areas and obtain perspectives not available by routine fiberoptic exam. Pre-operatively, this has the potential to allow adequate planning and mapping of the operative approach in a safe manner, while localizing delicate and vital structures. Also, the surgeon can correlate the 3D images with the endoscopic view as to understand the limitations and imperfections of surface and volume rendering of the CT images, as there is a certain learning curve as with most novel technologies.

## **3. Virtual Endoscopy in otolaryngology and radiology**

In the past two decades, multiplanar reformatting in coronal and sagittal planes of cross-sectional axial imaging has offered a capability to visualize with detail complex bony and

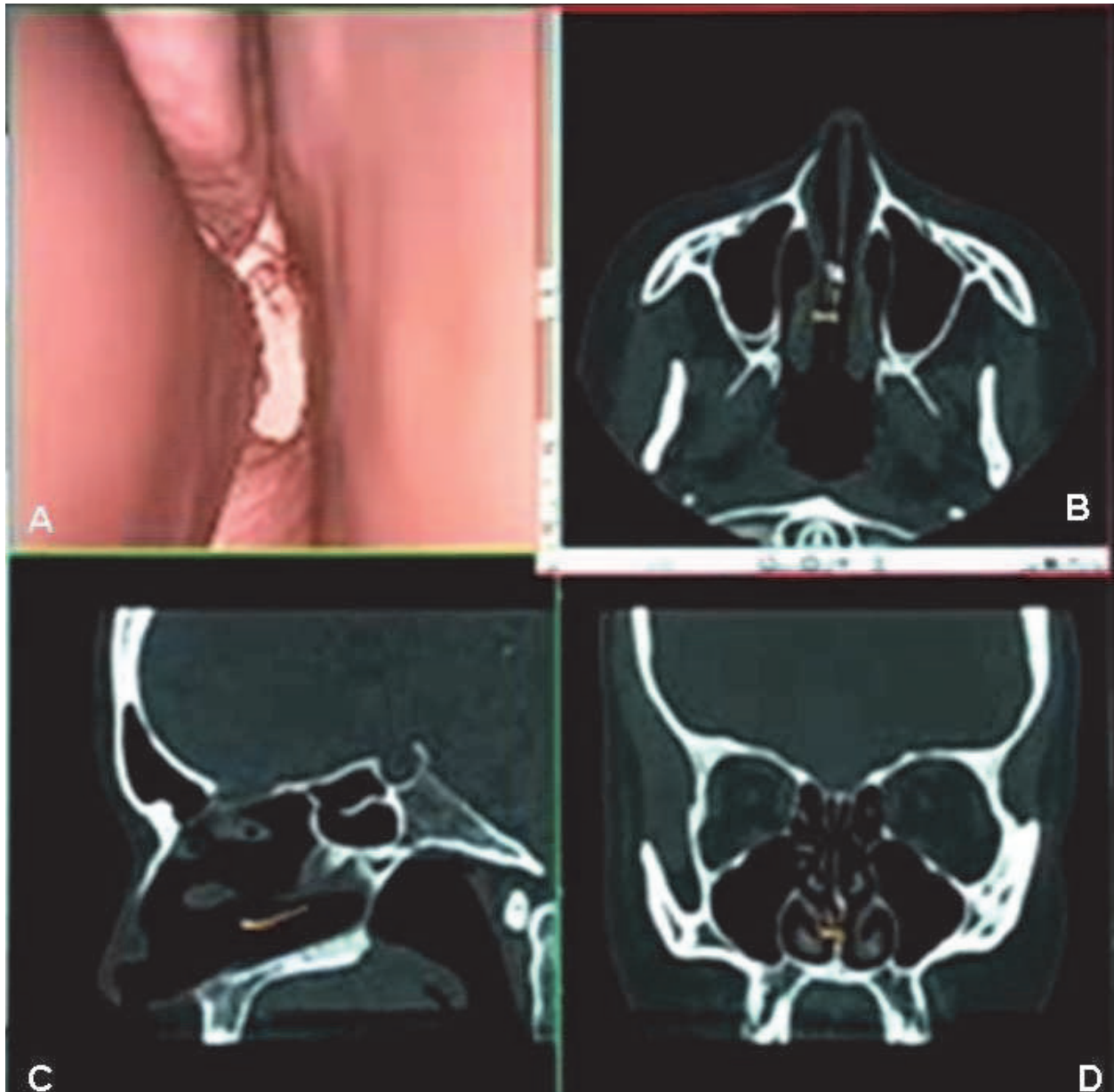


Fig. 1. Virtual Endoscopy

Virtual endoscope traveling in the right nasal cavity towards the nasopharynx (A), simultaneously being pursued in the axial (B), sagittal (C), and coronal planes (D); original figure.

soft tissue nasal structures. The otolaryngologist and radiologist, however, must routinely undertake a practice of mentally unifying two-dimensional images to accurately envision three-dimensional anatomy. VE offers a unique advantage of noninvasively carrying out this mental practice for the user to pictorially display the true anatomical site. Used in complement with high resolution thin-slice CT, VE significantly advances a users level of visualization of the paranasal sinuses, providing great utility to the clinical practice of both the otolaryngologist and radiologist. Many of the applications described here are relevant to the practice of both specialties, emphasizing the multidisciplinary utility of this technology.

### 3.1 Clinical applications

In direct patient care, VE offers numerous advantages that can complement office-based rhinoscopy. Foremost, VE has the ability to surmount the anatomical boundaries of the sinuses, visualizing areas and obtaining perspectives that are not achievable with conventional fiberoptic rhinoscopy. The virtual endoscope can in effect be directed in an innumerable array of flight paths, limited only by the creativity of the operator. A user can instantly traverse across bony and soft tissue landmarks such as the medial maxillary wall or the curvature of the turbinates to visualize an adjacent structure. Systematically, the user can follow pathways of mucociliary clearance from the originating sinus, via the narrow ostia, to ultimately the area of natural drainage. For instance, drainage of the maxillary sinus can be followed from within the cavity, through the narrow maxillary sinus ostia to the ethmoid infundibulum and ultimately the maxillary sinus meatus at the semilunar hiatus (see figure 2A). Distinctively, VE allows the user to reach anatomically arduous to reach landmarks not amenable via conventional endoscopy such as the frontal and sphenoid sinus cavities or ostia (see figure 2B).

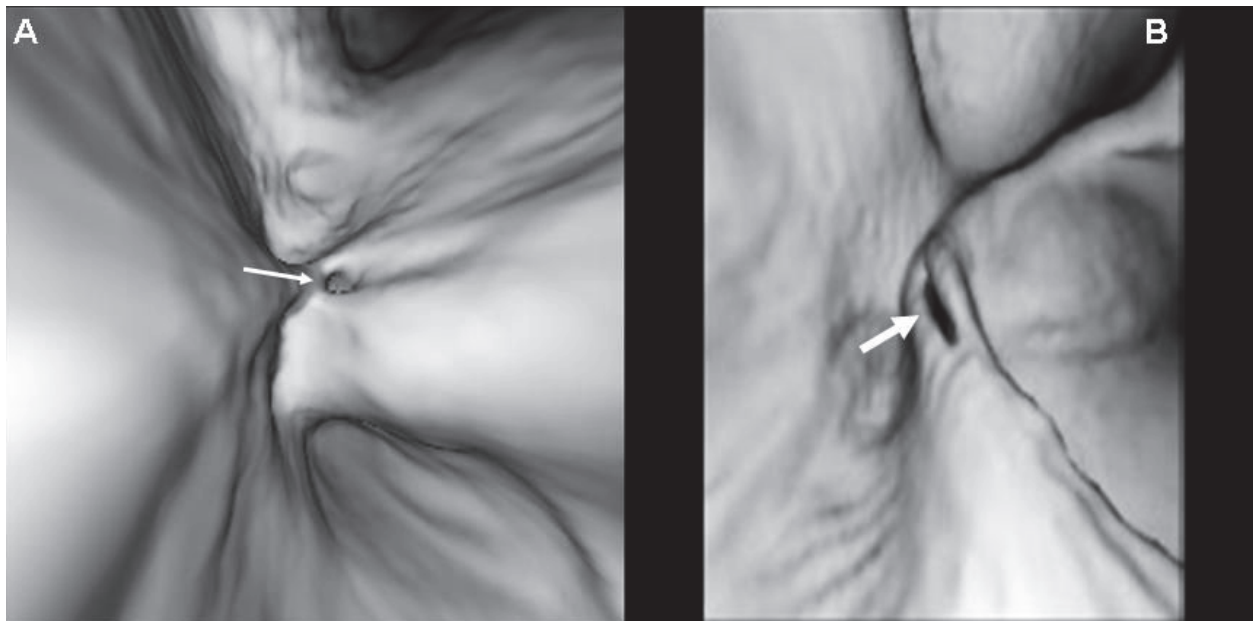


Fig. 2. Interior Views

En face three-dimensional view of a non-diseased right maxillary sinus ostium (A; thin arrow) and right sphenothmoidal recess (B; thick arrow); original figure.

Unique perspectives, such as a retrograde evaluation of the nasal choanae via the nasopharynx or looking medially towards a maxillary sinus ostia from within the maxillary sinus, can be appreciated. VE also permits access to narrow and painful areas as small as 1-2 mm in diameter including the inferior meatus and stenotic pathology such as an obstructed osteomeatal complex or choanal atresia (Han et al., 2000). In each of these instances, VE affords superior visualization than fiberoptic rhinoscopy.

We have previously reported that VE has great utility in visualizing anatomical landmarks of the sinonasal tract (Anand et al., 2009). Similar to CT, in the presence of an air-tissue or air-fluid interface, VE has equivocal utility in recognizing sinonasal pathology (Figures 3 and 4). Visualization is strongly dependent on this interface to delineate the surface anatomy of a structure as viewed en face by the virtual endoscope. In instances of soft tissue obliteration, like CT, VE finds difficulty in distinguishing mucinous secretions from soft-tissue anatomy.

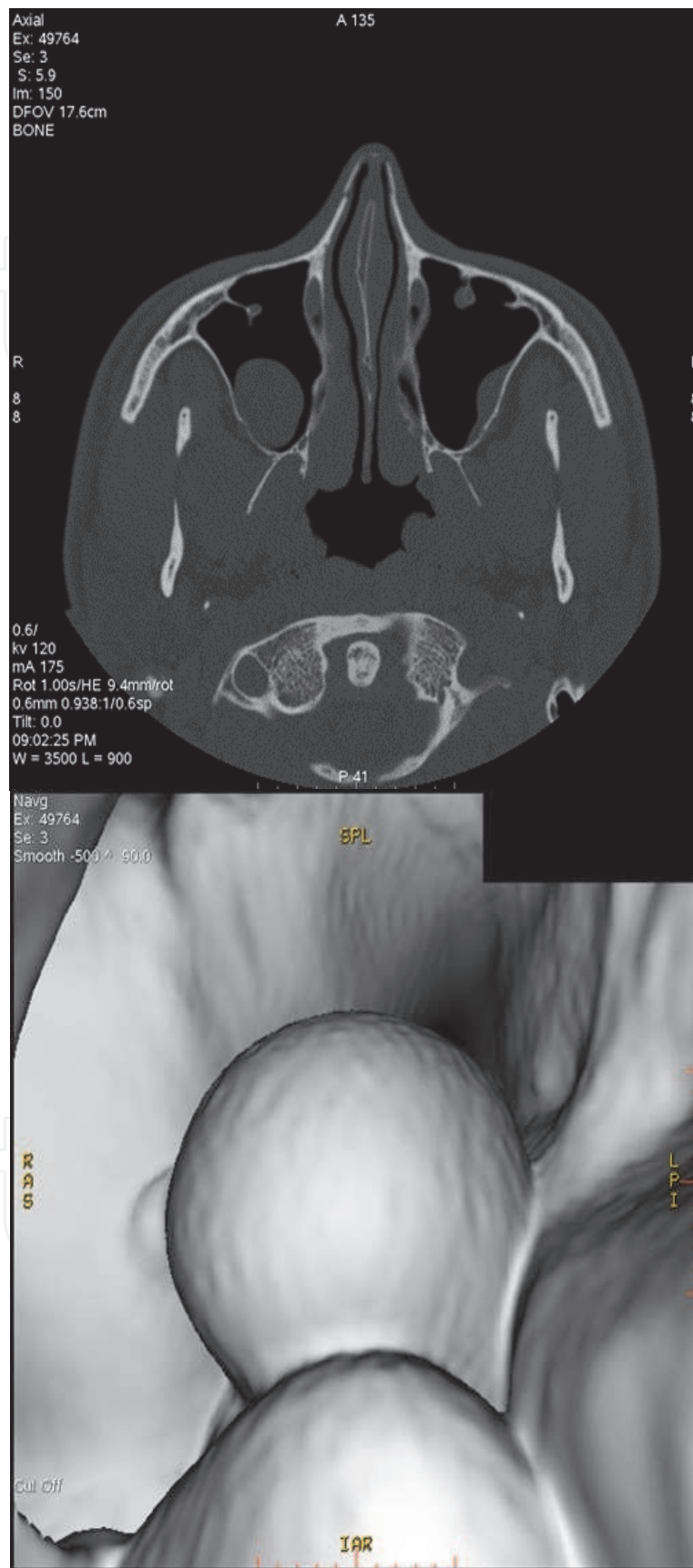


Fig. 3. Right maxillary sinus cyst; original figure.

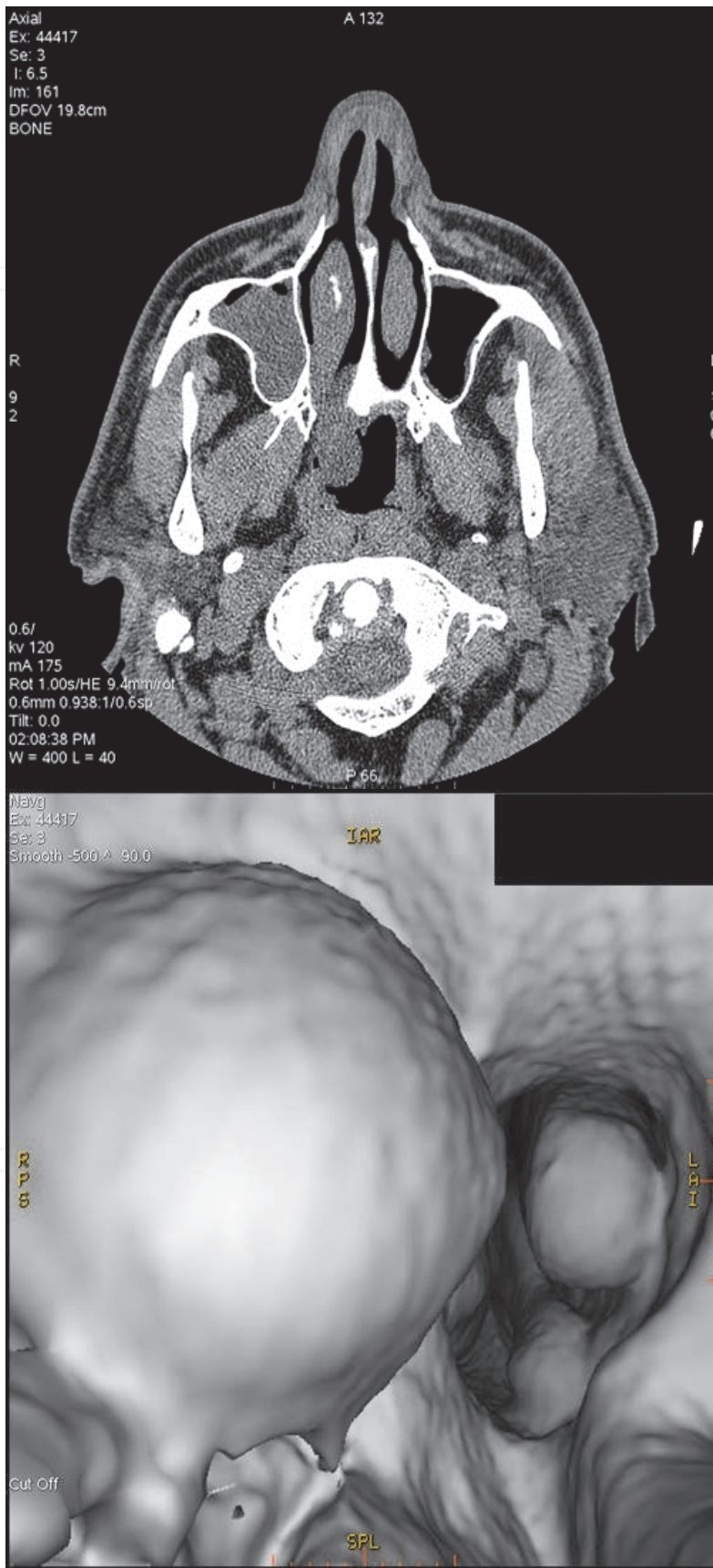


Fig. 4. Right choanal polyp; original figure.



VE remains an imaging technology and unlike conventional rhinoscopy there is no opportunity for the otolaryngologist to simultaneously culture, lavage or biopsy pathology (Greess et al., 2000). Table 1 outlines the advantages and disadvantages of VE. Overall, the advanced visualization inherent in VE makes it an excellent complement to flexible or rigid clinic endoscopy.

Advantages	Disadvantages
Visualize areas inaccessible by nasal endoscopy (ostia, paranasal cavities)	Cannot appreciate quality of the mucosa
Antro- and retro-grade views, 360° analysis	Learning curve
Traverse painful stenotic areas	No density measurements
No additional morbidity (no special CT, no IV contrast/aerolized medication/local trauma/discomfort or complications)	Cannot culture, lavage or biopsy pathology

Table 1. Advantages and Disadvantages of virtual endoscopy

Unlike fiber-optic rhinoscopy, there is no additional morbidity with VE beyond that associated with a routine non-contrast CT. No particular CT specifications are required and any patient that can undergo a CT sinus can have VE completed using the same image dataset. For the Radiologist, VE can offer the unique advantages of superior visualization described above without additional imaging of the patient or a considerable amount of additional image processing. For communication amongst colleagues, VE can serve as an additional tool to CT for subjects on whom the Otolaryngologist has not performed rhinoscopy. If care is being provided in a remote area where there is limited or no access to fiberoptic rhinoscopy or for discussing a patient case across two or more centers, VE can increase communication amongst treating physicians.

There are limitations to the use of VE in both Otolaryngology and Radiology. As with other advances in medical technology there is a learning curve with the introduction of a new modality (Chin et al., 2007). Once the user is familiar with VE software, however, navigation of the virtual endoscope is instantaneous. Specific limitations of VE arise in evaluating mucosal surfaces and secretions. For the Otolaryngologist, it is difficult to appreciate the quality and colour of the mucosal lining, prohibiting a differentiation of erythema or leukoplakia. Radiologically, mucous in the nasal cavity can be mistaken for a false soft tissue density; however, this is a similar pitfall in conventional two-dimensional CT (Anand et al., 2009).

### 3.2 Pre-operative and intra-operative planning

As a preoperative tool in surgical planning VE holds widespread potential. Prior to undertaking either open or endoscopic sinus surgery, the operative approach can be mapped out with the virtual endoscope. The influence of removing or partially altering surgical landmarks can be evaluated from the direction of anticipated view during surgery,

as well as from several perspectives adjacent to the anatomic landmark to evaluate the functional impact of the intended surgical step. This could assist in making both endoscopic and open nasal surgery even safer and minimally invasive by assisting in preservation of vital functional structures. A step-by-step anatomic prosection can be formulated with VE for each individual case, allowing the surgeon to plan out an entire procedure in the preoperative setting. This is a great assist for both active surgeons and in simulation-based teaching for trainees; the latter is an advantage that will be explored in detail later in this chapter. Several institutions have already begun using VE as a preoperative tool, and its use has been described in combination with multiplanar imaging, to preoperatively decide safe surgical entrance points for paranasal sinus mucocoeles (Nakasato et al, 2000). The advantage of being able to traverse stenotic segments inaccessible by conventional rhinoscopy increases the utility of VE in advanced skull base surgery. Visualization and thorough preoperative localization of critical structures such as the carotid and optic canal within the sphenoid, frontal sinus recess, anterior and posterior ethmoid arteries, fovea ethmoidalis and cribriform plate at the skull base increases operative safety in endoscopic and open skull base approaches. Intra-operatively, VE can be used as a navigational aid with image-guided applications to identify complex anatomy. The surgeon can herein use VE in real-time for intraoperative decision making to help direct the surgery, increase efficiency, localize detailed landmarks and importantly reduce the complication rate of advanced sinonasal surgery.

### 3.3 Anatomical correlation

To date several reports have evaluated the capability of VE to identify nasal cavity and paranasal sinus landmarks and a high level of agreement has been seen between volume rendering virtual three-dimensional imaging methods and conventional fiber-optic rhinoscopy (Di Rienzo et al., 2003; Han et al., 2000). Reports also demonstrate considerable agreement among VE and intra-operative findings in the vast majority of patients (Bisdas et al., 2004). We completed a preliminary evaluation of our VE interpretation experience and compared this to operative identification of landmarks in yet unpublished data. In a retrospective series, VE of 25 patients undergoing CT imaging of the paranasal sinuses for chronic nasal symptoms was compared to operative fiberoptic endoscopy findings. None of the patients were given aerosolized nasal decongestant prior to their CT imaging. Nineteen anatomic landmarks relevant in the mucociliary clearance of paranasal sinus secretions were objectively evaluated to be either not, partially or very well identified and scored with a 0, 1, or 2 out of 2 respectively (Table 2).

VE outperformed operative findings in visualizing hard to access areas such as the superior turbinate, superior meatus, choanae, nasopharynx, sphenoid and sphenothomoidal recess. VE also identified more clearly structures of the osteomeatal complex, namely the maxillary sinus ostium, uncinat process, and infundibulum, where most often pathology is localized in chronic sinonasal disease. Operative endoscopy better identified the middle and inferior meati and turbinates, as similarly described by Han et al. (2003). Surgeons are able to dissect away diseased mucosa or suction secretions to gain entry into a meatus, a feat not feasible with VE. Operative endoscopy also better visualized the ethmoid air cells, frontoethmoidal recess and frontal sinus, areas routinely addressed in dissection during endoscopic sinus surgery.

	VE			FOE		
	0	1	2	0	1	2
Septum	0	0	25(100%)	0	1	25(96.2%)
Nasal cavity	1(4.0%)	2(8.0%)	22(88.0%)	3(12.0%)	3(12.0%)	19(76.0%)
Infer Turbinate*	0	2(8.3%)	22(91.7%)	0	1(4.2%)	23(95.8%)
Mid Turbinate*	6(25.0%)	2(8.3%)	16(66.7%)	1(4.8%)	2(9.5%)	18(85.7%)
Super Turbinate	13(52.0%)	0	12(48.0%)	25(100%)	0	0
Infer Meatus*	1(4.2%)	2(8.3%)	21(87.5%)	0	1(4.2%)	23(95.8%)
Mid Meatus*	4(16.7%)	3(12.5%)	17(70.8%)	1(4.8%)	1(4.8%)	19(90.4%)
Super Meatus	10(40.0%)	0	15(60.0%)	25(100%)	0	0
Choanae	2(8.0%)	1(4.0%)	22(88.0%)	2(8.0%)	2(8.0%)	21(84.0%)
Nasopharynx	1(4.0%)	0	24(96.0%)	3(12.0%)	3(12.0%)	19(76.0%)
Uncinate process	9(37.5%)	7(29.2%)	8(33.3%)	0	20(83.3%)	4(16.7%)
Infundibulum	9(37.5%)	10(41.7%)	5(20.8%)	0	20(83.3%)	4(16.7%)
Max sinus ostium	8(32.0%)	4(16.0%)	12(48.0%)	0	21(84.0%)	4(16.0%)
Maxillary Sinus	3(12.0%)	6(23.1%)	17(68.0%)	0	19(76.0%)	6(24.0%)
Frontal Sinus*	8(32.0%)	6(24.0%)	11(44.0%)	2(8.0%)	10(40.0%)	13(52.0%)
Sphenoid Sinus	7(28.0%)	6(24.0%)	12(48.0%)	1(4.0%)	16(64.0%)	8(32.0%)
Ethmoid cells*	6(24.0%)	9(36.0%)	10(40.0%)	0	13(52.0%)	12(48.0%)
FER*	8(32.0%)	6(24.0%)	11(44.0%)	2(8.0%)	10(40.0%)	13(52.0%)
SER	8(32.0%)	5(20.0%)	12(48.0%)	1(4.0%)	16(64.0%)	8(32.0%)

FER: frontoethmoidal recess; SER: sphenoidoethmoidal recess; \*Only 24 were observed as opposed to 25 as these structures were surgically removed in the past.

Table 2. Total number and percentages of scores for each anatomical landmark observed by virtual endoscopy (VE) and by fiberoptic operative endoscopy (FOE).

#### 4. Virtual Endoscopy in resident and trainee education

Apart from clinical uses for the Otolaryngologist, virtual endoscopy also has potential applications in resident training. In the past, resident education in most surgical disciplines has been heavily based on the apprenticeship model, where trainees learned various procedures through clinical encounters. This fact is particularly still prevalent in endoscopic sinus surgery, where technical expertise is gained mainly from practice on real patients. However, the intricate anatomy of the nasal cavity and paranasal sinuses, as well as the numerous surrounding vital structures, create the potential for significant morbidity of endoscopic sinus surgery in inexperienced hands.

In the past decade, there has been an emergence of novel teaching modalities, such as simulation training and virtual reality. Numerous authors in the past have reported improved resident performance after simulation and virtual reality training (Grantcharov et al., 2005; Seymour et al., 2002). More recently, VE has become an innovative educational method for training residents. In terms of Gastroenterology, improvement in technical accuracy and time needed to reach technical competency has been shown for colonoscopies after virtual endoscopy training (Ferlitsch et al., 2010). Improved trainee performance with surgical simulation training in endoscopic sinus surgery has been demonstrated, although there is a lack of data with virtual endoscopy. Edmond published his work with an endoscopic sinus surgical simulator as a training device for Otolaryngology residents and suggested a positive impact in performance in certain procedures such as anterior ethmoidectomies and also increased surgical confidence (Edmond, 2002). Similar response to simulation in endoscopic sinus surgery was demonstrated by Glaser with his work with medical students, who praised the ability for simulation training to help with 3D visualization and understanding of nasal anatomy (Glaser et al., 2006). There is a lack of data on the use of the virtual endoscope in Otolaryngology training, which we hope will be addressed as VE becomes more popular amongst endoscopic sinus surgeons.

In our institution, similar to many programs, endoscopic sinus surgery is typically performed by senior residents, starting in the upper years of residency. The use of VE would allow exposure for younger junior residents to explore and properly understand the anatomy early in their training, potentially improving their ultimate performance and safety on real patients. It is common knowledge within the discipline of Otolaryngology, furthermore, that the anatomy of the paranasal sinuses is a challenge to truly comprehend. A realistic virtual portrayal of the anatomy can strengthen the comprehension of natural pathways of mucociliary clearance as well as rhinoscopy and operative assessment. As mentioned previously, users are not restricted to spaces defined by mucosal surfaces in the nasal cavity as they are during real endoscopy. They are able to permeate through mucosal and bony structures and therefore learn the complex anatomical relationships. The literature has shown on numerous occasions that an operator can better appreciate spatial relationships in a three-dimensional model than in a series of two-dimensional images (Greess et al., 2000; Remy-Jardin et al., 1998).

VE provides many advantages over surgical experience for early training. It is non-invasive, thus there is no compromise in patient care. The same approaches and technical exercises can be performed multiple times or variant approaches can be designed and practiced. A resident can thus attempt to discover numerous pathways to a certain anatomical structure, such as a specific meatus or the maxillary, sphenoid or frontal sinus ostia. VE also provides crucial information to the location of surrounding anatomical structures. This will provide teaching faculty with pre-operative knowledge of what procedures are safe to be performed by resident trainees at varying levels of experience, thus objectifying procedure delegation.

## 5. Future directions

Three-dimensional rendering of helical CT images has modified the way Otolaryngologists and Radiologists approach the investigation of tubular anatomical structures. It is evident

that VE of the paranasal sinuses provides surgeons with a new tool for both pre-operative and intra-operative planning, as well as a teaching modality for residents. The limitations of VE are in its ability to assess mucosal surfaces and secretions. In particular, current VE processing does not allow adequate differentiation of color and density, thus mucus or other secretions can be mistaken for a false soft tissue density. The differentiation between erythema and leukoplakia also can not be addressed by VE as opposed to direct visualization of color by conventional rhinoscopy. Moreover, VE is currently not able to identify tissue densities with imaging. Ultimately understanding from density measurements the nature of individual structures will allow improved identification of critical landmarks and pathologic anomalies possibly without conventional invasive rhinoscopy. Further research and innovation of VE technology will likely address this issue in the future. Finally, prospective trials in its use in training can objectively explore the role of this innovation in resident education.

## 6. Conclusion

As we enter a new decade, we are fortunate to constantly being challenged by novel diagnostic and therapeutic modalities to enhance patient care. VE has the potential to improve pre-operative diagnosis of pathologies, intra-operative patient management, post-operative follow-up, as well as trainee education. In this chapter, we have explored this relatively new technology, with an overview of its numerous utilities in clinical practice and residency training. VE has already been implemented routinely in certain centers for imaging of the colon and bronchial tree. It is our belief that VE will continue to progress as a technology and will certainly be an essential armamentarium of Otolaryngologists in the near future.

## 7. References


- Anand SM, Frenkiel S, Le BQH, Glikstein R. Virtual Endoscopy: Our Next Major Investigative Modality? *J Otolaryngol Head Neck Surg.* 2009 Dec;38(6):642-5.
- Bisdas S, Verink M, Burmeister HP, et al. Three-dimensional visualization of the nasal cavity and paranasal sinuses: clinical results of a standardized approach using multislice helical computed tomography. *J Comput Assist Tomogr* 2004; 28(5):661-669.
- Chin JL, Luke PP, Pautler SE. Initial experience with robotic-assisted laparoscopic radical prostatectomy in the Canadian health care system. *Can Urol Assoc J* 2007; 1(2):97-101.
- Di Rienzo L, Coen Tirelli G, Turchio P, et al. Comparison of virtual and conventional endoscopy of nose and paranasal sinuses. *Ann Otol Rhinol Laryngol* 2003; 112:139-142.
- Edmond, C. V. Impact of the Endoscopic Sinus Surgical Simulator on Operating Room Performance. *The Laryngoscope* 2002;112:1148-1158.
- Ferlitsch A, Schoefl R, Puespoek A, Miehsler W, Schoeniger-Hekele M, Hofer H, Gangl A, Homoncik M. Effect of virtual endoscopy simulator training on performance of

- upper gastrointestinal endoscopy in patients: a randomized controlled trial. *Endoscopy* 2010;42(12):1049-56.
- Gilani S, Norbash AM, Ringl H, et al. Virtual endoscopy of the paranasal sinuses using perspective volume rendered helical sinus computed tomography. *Laryngoscope* 1997;107:25-9
- Glaser AY, Hall CB, Uribe S JI, Fried MP. Medical students' attitudes toward the use of an endoscopic sinus surgery simulator as a training tool. *Am J Rhinol* 2006;2:177-9.
- Grantcharov, TP, Kristiansen, VB, Bendix, J, Bardram, L, Rosenberg, J, Funch-Jensen, P. Randomized clinical trial of virtual reality simulation for laparoscopic skills training. *Br J Surg* 2005;91(2): 146-150.
- Greess H, Nomayr A, Tomandl B, et al. 2D and 3D visualization of head and neck tumours from spiral-CT data. *European Journal of Radiology* 2000; 33:170-177.
- Han P, Pirsig W, Ilgen F, et al. Virtual endoscopy of the nasal cavity in comparison with fiberoptic endoscopy. *Eur Arch Otolaryngol* 2000; 257:578-583.
- Kettenbach, J., Birkfellner, W., Rogalla, P. (2008). *Virtual Endoscopy of the Paranasal Sinuses*, In: *Image Processing in Radiology*, Neri, E., Caramella, D., Bartolozzi, C., (151-171), Springer Berlin Heidelberg, 978-3-540-49830-8, Berlin Heidelberg.
- Nakasato T, Katoh K, Ehara S, et al. Virtual CT Endoscopy in Determining Safe Surgical Entrance Points in Paranasal mucoceles. *J Comput Assist Tomogr* 2000; 24(3):486-492.
- Ossoff RH, Reinisch L. Computer-assisted surgical techniques: a vision for the future of otolaryngology, head and neck surgery. *J Otolaryngol* 1994; 23(5):354-359.
- Pineau BC, Paskett ED, Chen GJ, et al. Virtual colonoscopy using oral contrast compared with colonoscopy for the detection of patients with colorectal polyps. *Gastroenterology* 2003; 125(2):304-10.
- Remy-Jardin M, Artaud D, Fribourg M, et al. Volume rendering of the tracheobronchial tree: clinical evaluation of bronchographic images. *Radiology* 1998;208:761-70.
- Rice, DH, Schaefer, SD. (2004). Introduction, In: *Endoscopic paranasal sinus surgery*, Rice, DH, Schaefer, SD. (XV), Lippincott Williams & Wilkins, 0-7817-4077-0, Philadelphia.
- Rogalla P, Nischwitz A, Gottschalk S, et al. Virtual endoscopy of the nose and paranasal sinuses. *Eur Radiol* 1998; 8(6): 946-950.
- Rogalla, P. (2000). *Virtual Endoscopy of the Nose and Paranasal Sinuses*, In: *Virtual endoscopy and related 3D techniques*, Rogalla, P., Terwisscha van Scheltinga, J., Hamm, B., (17-38), Springer, 3-540-65157-8, Berlin Heidelberg New York.
- Rubin GD, Beaulieu CF, Argiro V, et al. Perspective volume rendering of CT and MR images: applications for endoscopic imaging. *Radiology* 1996; 199(2):321-330.
- Seymour, NE, Gallagher, AG, Roman, SA, O'Brien, MK, Bansal, VK, Andersen, DK, Satava, RM. Virtual Reality Training Improves Operating Room Performance. Results of a Randomized, Double-Blinded Study. *Ann Surg* 2002; 236(4):458-464.

- Vining DJ, Liu K, Choplin RH, et al. Virtual bronchoscopy: Relationships of virtual reality endobronchial simulations to actual bronchoscopic findings. *Chest* 1996; 109(2):549-553.
- Wood BJ, Razavi P. Virtual Endoscopy: A Promising New Technology. *Am Fam Physician* 2002;66:107-12.

IntechOpen

IntechOpen



## **Advances in Endoscopic Surgery**

Edited by Prof. Cornel Iancu

ISBN 978-953-307-717-8

Hard cover, 444 pages

**Publisher** InTech

**Published online** 25, November, 2011

**Published in print edition** November, 2011

Surgeons from various domains have become fascinated by endoscopy with its very low complications rates, high diagnostic yields and the possibility to perform a large variety of therapeutic procedures. Therefore during the last 30 years, the number and diversity of surgical endoscopic procedures has advanced with many new methods for both diagnoses and treatment, and these achievements are presented in this book. Contributing to the development of endoscopic surgery from all over the world, this is a modern, educational, and engrossing publication precisely presenting the most recent development in the field. New technologies are described in detail and all aspects of both standard and advanced endoscopic maneuvers applied in gastroenterology, urogynecology, otorhinolaryngology, pediatrics and neurology are presented. The intended audience for this book includes surgeons from various specialities, radiologists, internists, and subspecialists.

### **How to reference**

In order to correctly reference this scholarly work, feel free to copy and paste the following:

Sumeet Anand, Rickul Varshney and Saul Frenkiel (2011). Virtual Endoscopy of the Nasal Cavity and the Paranasal Sinuses, *Advances in Endoscopic Surgery*, Prof. Cornel Iancu (Ed.), ISBN: 978-953-307-717-8, InTech, Available from: <http://www.intechopen.com/books/advances-in-endoscopic-surgery/virtual-endoscopy-of-the-nasal-cavity-and-the-paranasal-sinuses>

**INTECH**  
open science | open minds

### **InTech Europe**

University Campus STeP Ri  
Slavka Krautzeka 83/A  
51000 Rijeka, Croatia  
Phone: +385 (51) 770 447  
Fax: +385 (51) 686 166  
[www.intechopen.com](http://www.intechopen.com)

### **InTech China**

Unit 405, Office Block, Hotel Equatorial Shanghai  
No.65, Yan An Road (West), Shanghai, 200040, China  
中国上海市延安西路65号上海国际贵都大饭店办公楼405单元  
Phone: +86-21-62489820  
Fax: +86-21-62489821



© 2011 The Author(s). Licensee IntechOpen. This is an open access article distributed under the terms of the [Creative Commons Attribution 3.0 License](#), which permits unrestricted use, distribution, and reproduction in any medium, provided the original work is properly cited.

IntechOpen

IntechOpen