

We are IntechOpen, the world's leading publisher of Open Access books Built by scientists, for scientists

4,800

Open access books available

122,000

International authors and editors

135M

Downloads

Our authors are among the

154

Countries delivered to

TOP 1%

most cited scientists

12.2%

Contributors from top 500 universities



WEB OF SCIENCE™

Selection of our books indexed in the Book Citation Index
in Web of Science™ Core Collection (BKCI)

Interested in publishing with us?
Contact book.department@intechopen.com

Numbers displayed above are based on latest data collected.

For more information visit www.intechopen.com



Sialendoscopy: Endoscopic Approach to Benign Salivary Gland Diseases

Meghan Wilson, Kyle McMullen
and Rohan R. Walvekar*

*Department of Otolaryngology Head & Neck Surgery,
Louisiana State, University Health Science Center,
New Orleans, Louisiana
USA*

1. Introduction

Sialadenitis, or recurrent salivary gland infection associated with pain and swelling of the major salivary glands, is a common presentation to emergency rooms and outpatient clinics. One of the most frequent causes of sialadenitis is obstruction in the salivary ductal system. Salivary calculi affect 1.2% of the population and account for 60-70% of salivary duct obstruction (Nahlieli 2004; Kim 2007; Bomeli 2009; Nahlieli 2006). Additional causes of obstruction to salivary flow include strictures in 25-25%, inflammation (5-10%) and other rare pathologies such as foreign bodies (1%)

Conservative treatment is the first line of therapy that includes treatment with antibiotics, salivary stimulants or sialogogues, and anti-inflammatory agents. However, conservative therapy fails in up to 40% of people with sialadenitis; in which case the recommended treatment is excision of the involved salivary gland. There are several important nerves that are in close proximity to the major salivary glands. The facial nerve, motor to facial muscles, runs through the parotid glandular system. Similarly, the submandibular gland is associated with the lingual nerve that is sensory to the anterior two thirds of the oral tongue; marginal mandibular nerve that allows movement of the angle of the mouth; and the hypoglossal nerve, motor to the tongue. Surgical excision of the gland carries numerous risks include but are not limited to paresis or palsy of the facial nerve, lingual nerve, and hypoglossal nerve. Other complications include Frey syndrome (gustatory sweating), sialoceles, salivary fistula, xerostomia, numbness in the distribution of the greater auricular nerve, infection, and hemorrhage. Consequently, although surgical resection in experienced hands is safe, it's often not desired due to the associated surgical risk and external scar in the neck associated with it.

In 1988, salivary duct endoscopes were introduced. Since their introduction, sialendoscopes have undergone technical refinements that have been instrumental in permitting clear and high definition visualization and manipulation of the salivary ductal system. Today, salivary duct endoscopy or "Sialendoscopy" allows the minimally invasive endoscopic visualization of major salivary gland ductal system and endoscopic interventions to treat chronic sialadenitis with or without sialolithiasis.

As in many other surgical areas, the advent of sialendoscopy has added additional options to the diagnosis and management of non-neoplastic salivary pathology. Initially, sialendoscopy was created for diagnostic evaluation of the salivary glands and ductal system as well as treatment of obstruction through the removal of sialoliths or dilation of strictures. Nahlieli et al, in their study in 2004¹ described successful endoscopic treatment of recurrent parotitis and juvenile recurrent parotitis. The scope of sialendoscopy was further expanded to treat radioactive iodine sialadenitis (Kim 2007; Bomeli 2009; Nhlieli 2006) and sialadenitis induced by autoimmune diseases (Schacham 2011). Today, sialendoscopy is regarded as an acceptable and often preferred diagnostic and treatment tool for chronic sialadenitis and non-neoplastic obstruction of the salivary ductal system.

2. Indications and contraindication

Current evidence has validated sialendoscopy for the treatment of non-neoplastic disorders of the salivary glands, including sialolithiasis. Sialolithiasis is one of the most common non-neoplastic disorders of the major salivary glands and a major cause of sialadenitis and unilateral diffuse swelling of the major salivary glands (Marchal F, Dulguerov P. 2003; Nahlieli O. 2006). In general, stones less than 4 mm in the submandibular gland and less than 3 mm in the parotid gland are amenable to endoscopic removal. Intermediate size stones between 5-7 mm may need further fragmentation either using a Holmium laser or lithotripsy prior to endoscopic extraction. In general stones larger than 8 mm require a combined approach technique for stone removal (Karavidas K, Nahlieli O, Fritsch N, et al. 2010). The combined approach technique is a technique that uses the sialendoscope for stone localization and either an intra-oral or an external approach for removal of large submandibular or parotid gland stones, respectively (Bodner L. 2002; Lustmann J, Regev E, Melamed Y. 1990; Marchal F. 2007; Raif J, Vardi M, Nahlieli O, et al. 2006; Seldin HM, Seldin SD, Rakower W. 1953; Walvekar RR, Bomeli SR, Carrau RL, et al. 2009).

Sialendoscopy indications include diagnostic evaluation of recurrent or chronic sialadenitis, including unexplained swelling of the major salivary glands associated with meals, ductal stenosis, and intra-ductal masses (Nahlieli O. 2006; Walvekar RR, Razfar A, Carrau RL, et al. 2008). The authors of limited series have also suggested benefit in patients with radioiodine-induced sialadenitis (Kim JW, Han GS, Lee SH et al. 2007; Bomeli SR, Schaitkin B, Carrau RL, et al. 2009; Nahlieli O and Nazarian Y. Sialadenitis 2006). Recent studies and the authors' experience suggest benefit in children with recurrent sialadenitis (Nahlieli O, Shacham R, Shlesinger M, et al. 2004; Jabbour N, Tibesar R, Lander T, et al. 2010; Martins-Carvalho C, Plouin-Gaudon I, Quenin S, et al. 2010; Faure F, Querin S, Dulguerov P, et al. 2007) and also in patients who have recurrent sialadenitis from autoimmune processes such as Sjogren's syndrome or Systemic Lupus Erythematosus (Shacham R, Puterman MB, Ohana N, et al. 2011).

The only absolute contraindication is acute sialadenitis. The use of the rigid dilator system and/or a semi-rigid endoscope during an acute episode increases the chance of ductal trauma and irrigation as well as ductal injury could increase the potential spread of infection in the head and neck soft tissues. Sialendoscopy can be challenging in patients with microstomia or trismus. These could be considered as relative contraindications for the procedure.

2.1 Sialendoscopy: Technique

Sialendoscopy may be performed in the clinic setting with local anesthesia or in the operating room with sedation or general anesthesia. The decision of where to perform the procedure is physician and/or patient preferences. The basic work up for sialendoscopy is summarized in **Table 1**.

History	Symptoms
	Number of infections
	Previous treatments
	History of external beam radiation therapy
	History of Radioactive iodine treatment
Physical Examination	Full Head and Neck examination
	Bimanual palpation of glands
	Examine and note location of papilla
	Note any anatomical limitations (trismus, small oral commissure, temporomandibular joint pathology, etc.)
Imaging	Computed Tomography Scan (CT)
	Ultrasound
	Magnetic Resonance Imaging Scan (MRI)

Table 1. Preoperative Evaluation

2.1.1 Basic workup

Workup of all salivary disorders begins with history of present disease. Important questions to ask include symptoms, number of infections, previous treatments, and previous testing or other studies. Questions regarding history of external beam radiation or radioactive iodine therapy are important as well to understand possible etiologies of salivary disease.

Examination should first include a complete head and neck exam. Bimanual palpation of the salivary gland should be performed to examine for any masses or palpable stones, noting any asymmetry. Examine the papilla and its location. Assess the patency and saliva flow and quality of the saliva from the papilla. It is important to make notes regarding the papilla in the chart to aid in identification when ready to perform sialendoscopy; pictorial illustrations are particularly helpful. In addition, the surgeon must evaluate access to the oral cavity by paying close attention to the size of the oral commissure (e.g., microstomia), size of tongue, ability to open the mouth (e.g., preoperative trismus), and pathology of temporomandibular joints

Laboratory and imaging studies ordered will depend on the patient's symptoms and physical exam findings. Frequently used imaging studies include ultrasonography, computed tomography (CT), and magnetic resonance imaging (MRI), (**Figures 1 and 2**). The authors' preference for diagnosis and surgical planning is CT scan with and without contrast.

2.1.2 Instrumentation

The basic instrumentation includes a specialized dilator system that permits gradual serial dilation of the salivary duct papilla from the lowest No.0000 dilator to a maximum of No.8,

(Figure 3). The sialendoscopes most frequently used are the “all-in-one” interventional sialendoscopes, which can range from 1.1mm to 1.6 mm in diameter, (Figure 4). The sialendoscopes have an optic channel that transmits the image using fiberoptic channels, and an irrigation channel allows a continuous irrigation to be performed to maintain duct patency for endoscopic visualization of the salivary duct lumen and to allow working space for surgical intervention. A working channel is used to introduce instruments for intervention. The 1.1 and 1.3 mm sialendoscopes permit introduction of 0.4 mm stone wire baskets (Figure 5 A-C) and a hand-held micro burr to break stones. The 1.6 mm sialendoscope permits the use of 0.6 mm stone wire basket and a cup forceps in addition.

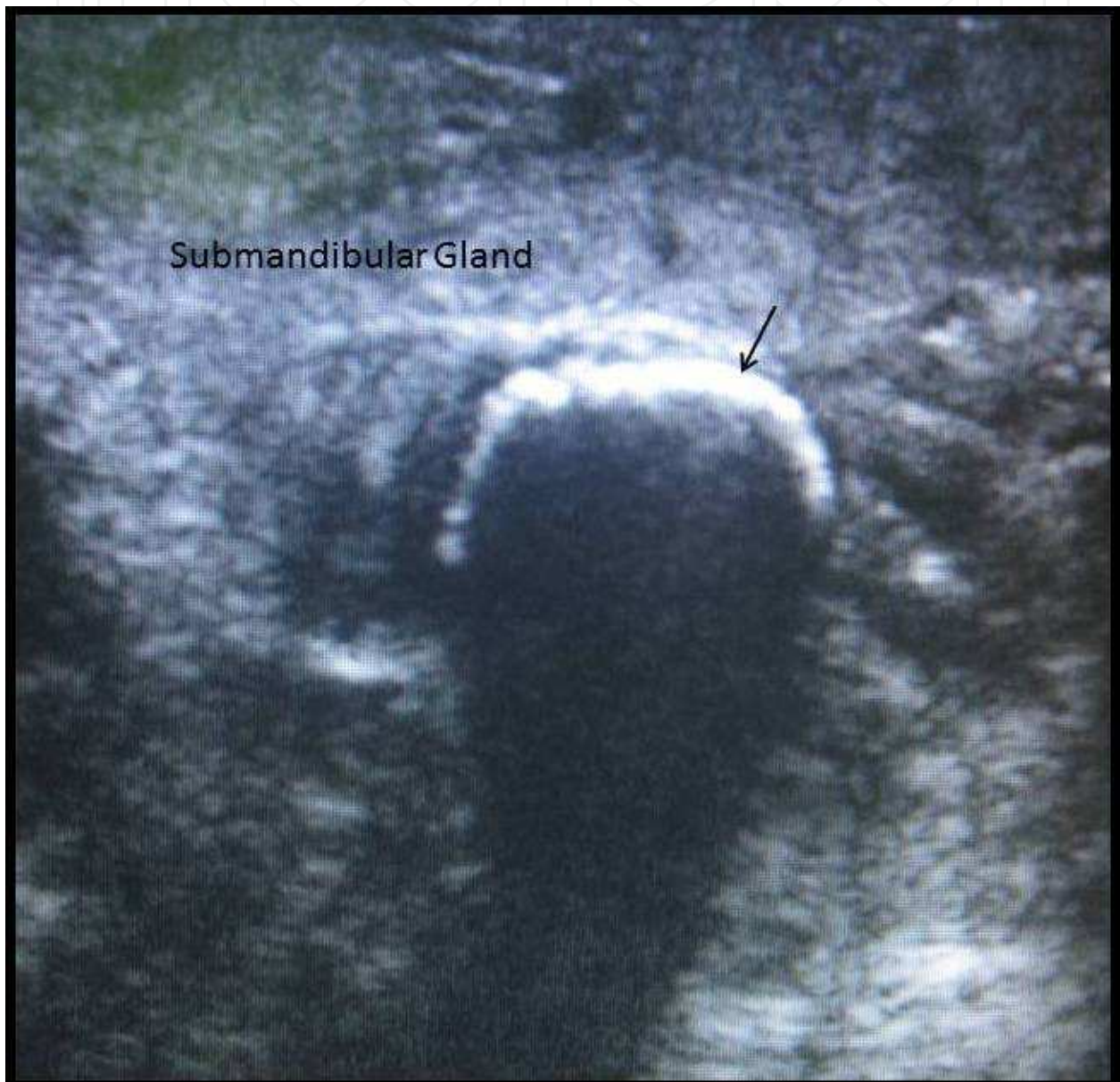


Fig. 1. Ultrasonography image of large submandibular stone. The stone appears as a hyperechoic rim while throwing a shadow that is a pathognomic finding of a salivary stone visualized via ultrasound, (black arrow points to the stone).

Holmium laser fibers can be used as well through the interventional channels for intraductal laser fragmentation of stones, (**Figure 6**). Another important tool for sialendoscopy is the conical dilator that permits gradual dilation of the duct and allows one to transition from a smaller dilator to the next size, (**Figure 7**).

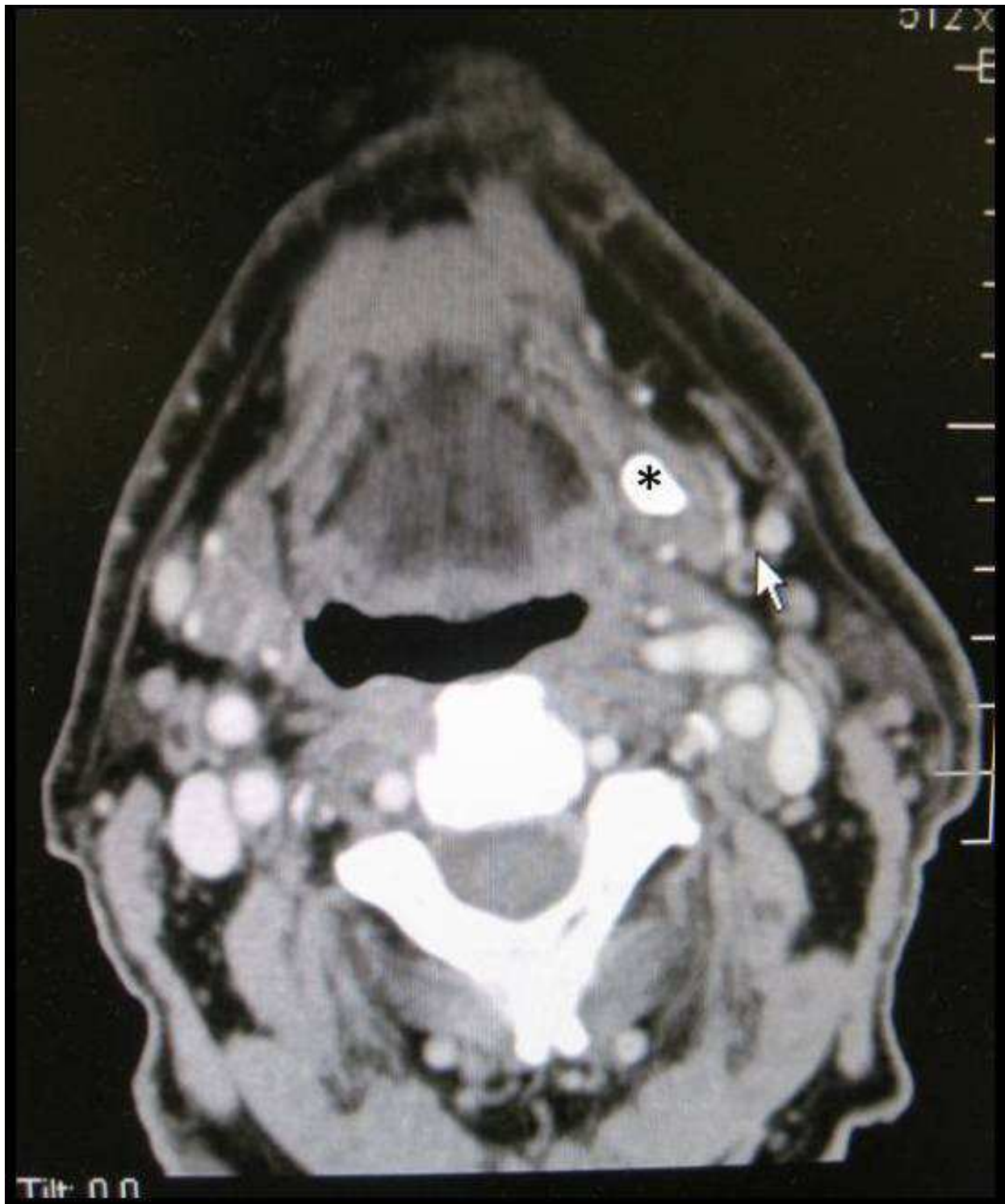

Fig. 2. An contrast enhanced axial CT scan showing a large irregular left submandibular stone in the hilum, (the asterisk denotes the salivary stone).

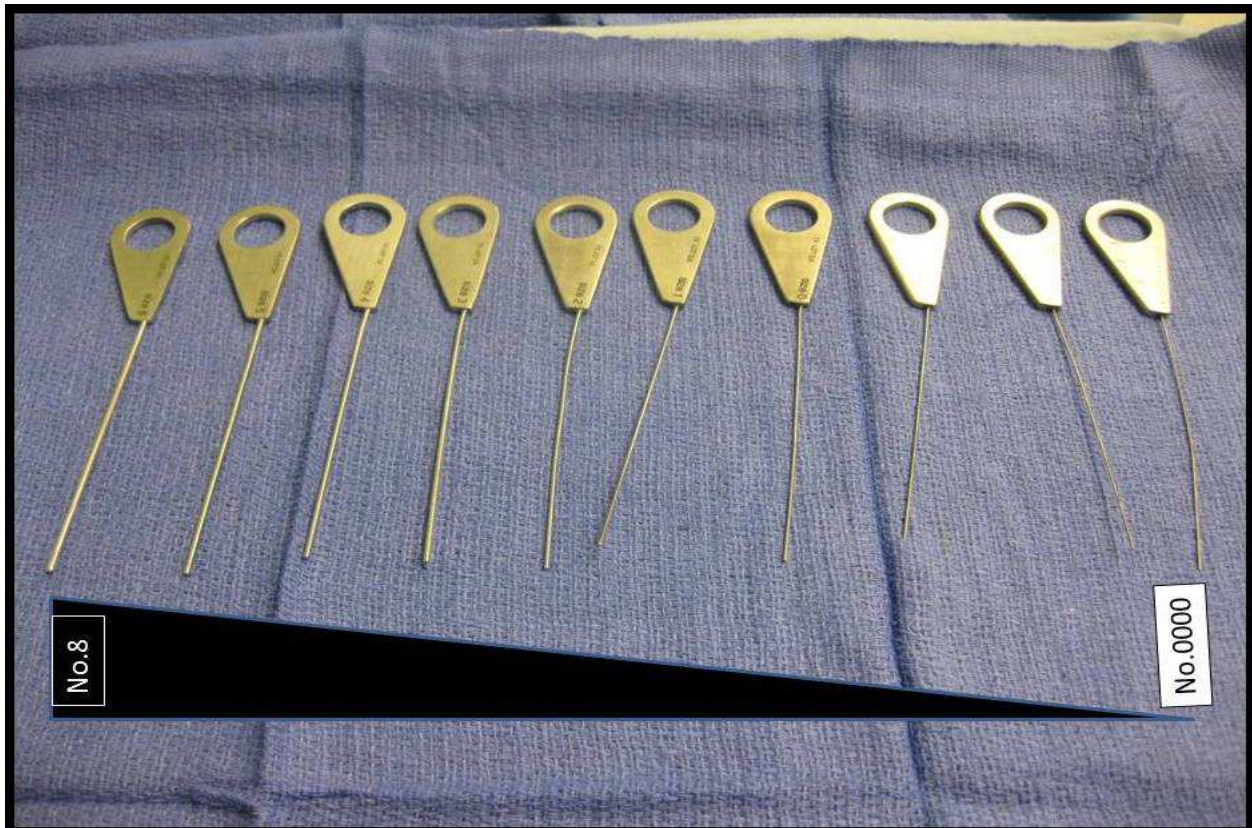

Fig. 3. Marchal Dilator System

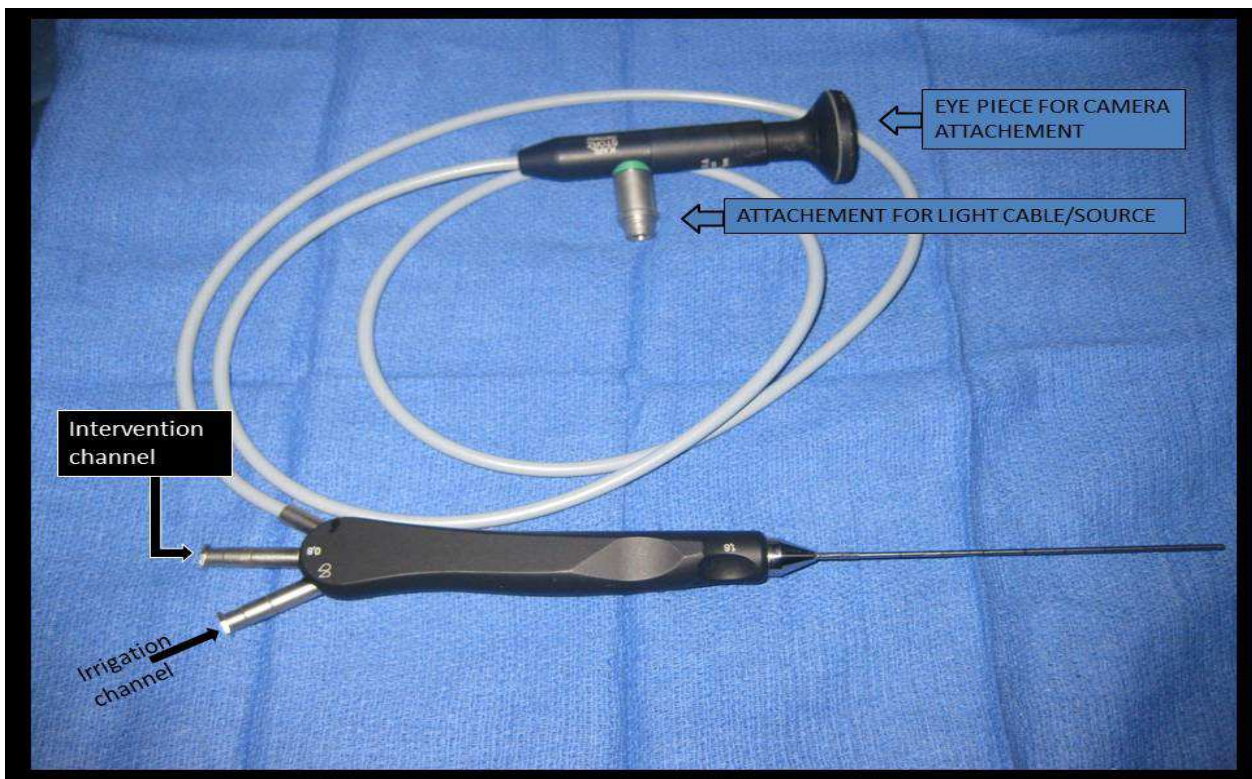

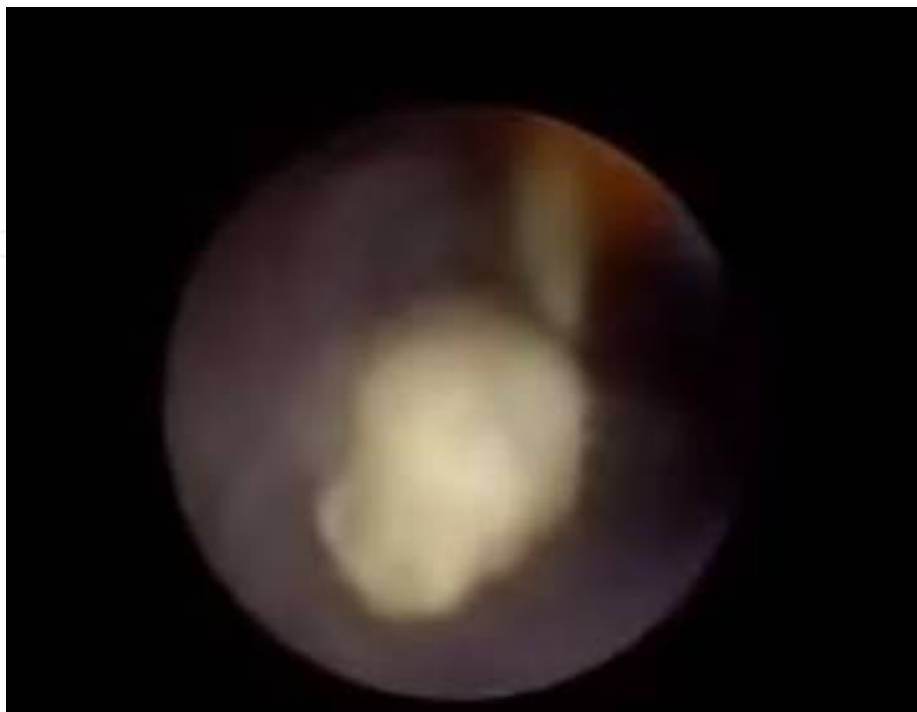


Fig. 4. 1.6 mm Erlangen "All-In-One" Sialendoscope

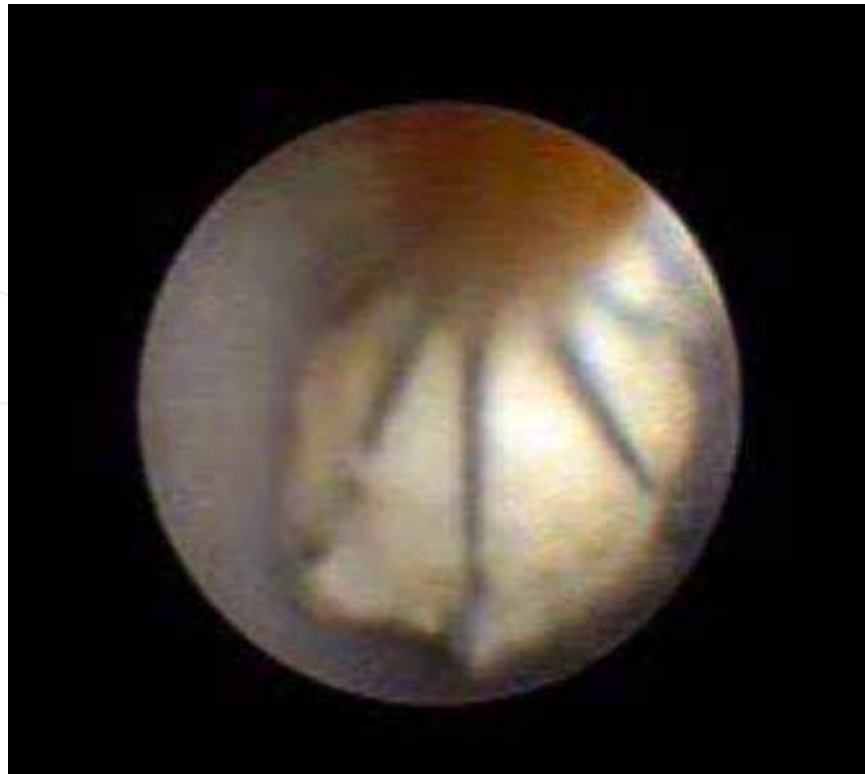Salivary duct stents or cannulae can usually left in place following the procedure to decrease the risk of scarring and papilla stenosis, (**Figure 8**)



A)



B)



C)

Fig. 5. A) 0.4 mm stone wire basket. B) A free floating submandibular duct stone. C) The wire basket can be inserted through the interventional port of the sialendoscope and used for trapping the stone for endoscopic removal

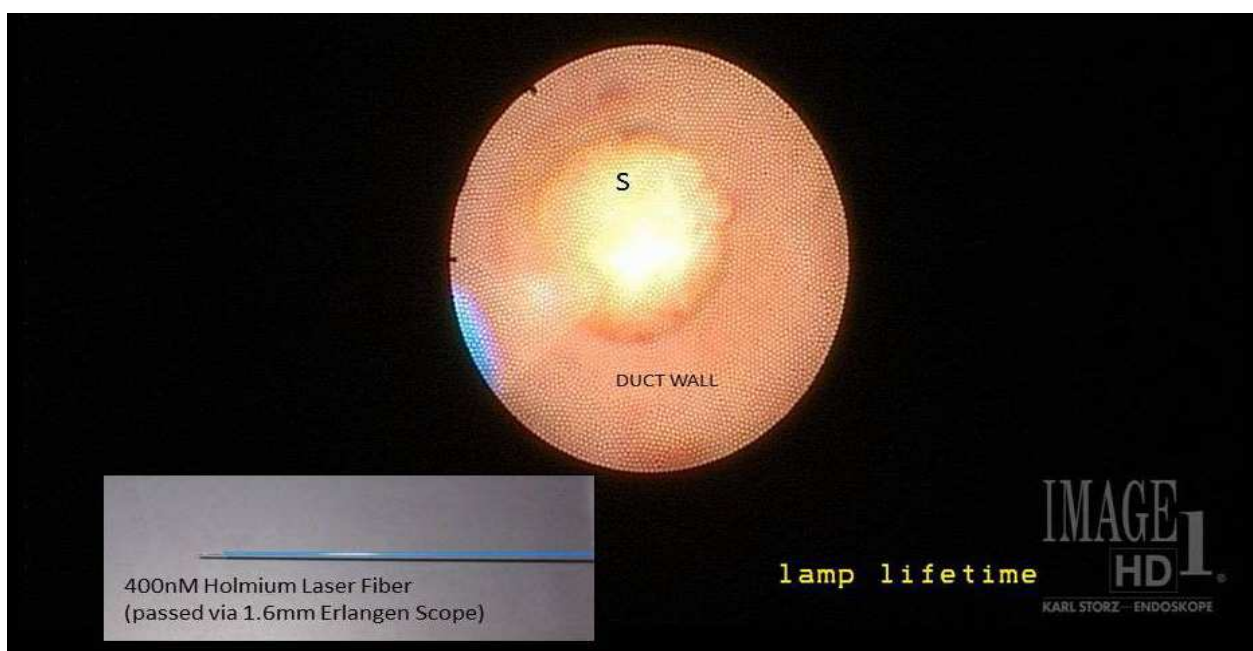


Fig. 6. A Holmium laser fiber being used for intra-ductal laser fulguration of an impacted 6mm submandibular stone (S). Inset shows the tip of the 400 nM Holmium laser fiber that can be passed via the interventional channel of the 1.6 mm Erlangen Sialendoscope.




Fig. 7. Conical Dilator

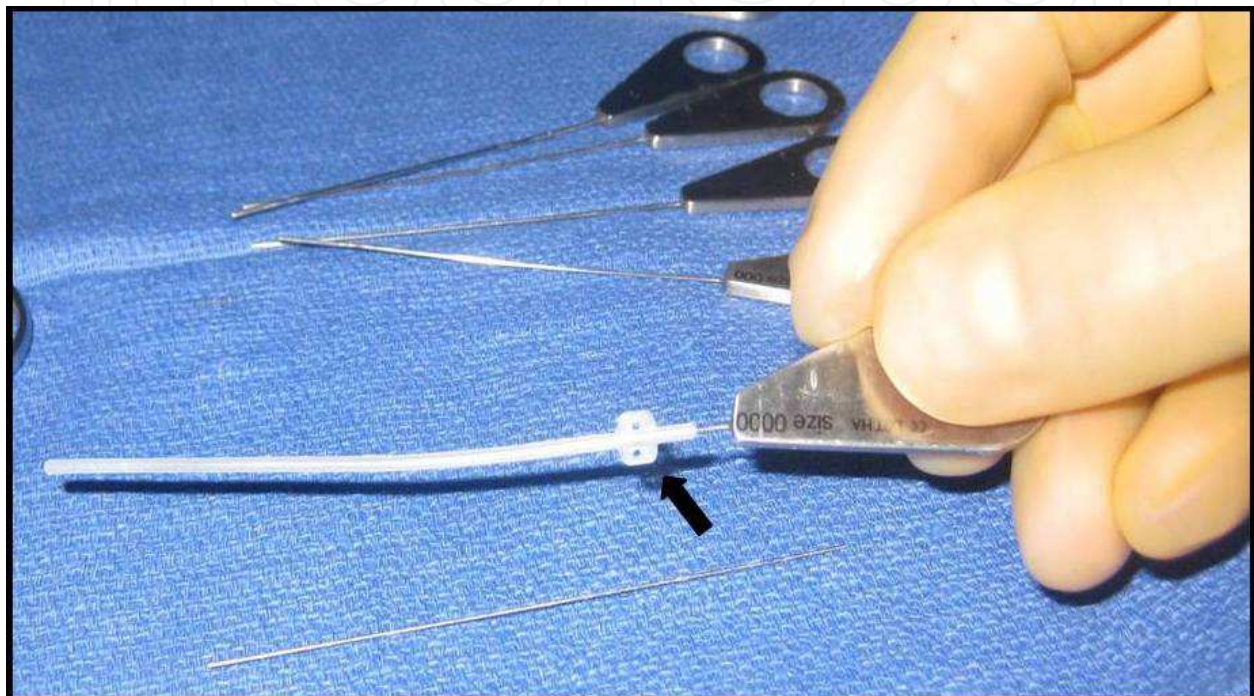


Fig. 8. The Schaitkin Salivary Canula (Hood Laboratories, Pembroke, MA) can be inserted over a No.0000 Marchal dilator to prevent subsequent stenosis of the duct or papilla. Black arrow points to distal end of stent that projects out of the papilla. Two holes on either side of the flange of the stent facilitate securing the stent to the floor of mouth or buccal mucosa via non-absorbable stitches.

2.1.3 Operative technique

Operative technique can be divided into two main components:

1. Access to the salivary duct i.e. dilation of the papilla
2. Endoscopy with or without intervention.

Management of papilla is the rate-limiting step of the procedure. Care must be taken to dilate the papilla. Poor handling of the papilla can lead to papillary stenosis in the future that can lead to obstructive sialadenitis. In addition, perforation of the duct (minor or major ductal tear) and creation of a false passage are potential complications of papilla dilation that add morbidity to the procedure and also are reasons for sialendoscopy failure.

Identification of the papilla can be aided by using an operating microscope or surgical loupes. The author recommends the use of at least surgical loupes to identify and dilate the papilla. In office localization and documentation of the location of the papilla with imaging

is very helpful in intra-operative identification of the papilla. Massage of the gland may also assist in localizing the papilla by denoting the point of saliva flow. After identification of the papilla, serial dilation of the papilla is then performed using the Marchal dilator system, (Figure 3). Injection of local anesthetic around the papilla often helps the process of serial dilation by making the ductal opening more prominent and by stiffening the surrounding tissues to facilitate serial cannulation of the duct. In this procedure, salivary probes of increasing diameter, beginning with the smallest (No. 0000), are sequentially introduced into the duct. Dilation up to No.3 or No.4 is adequate to allow introduction of a sialendoscope of 1.3mm diameter. For the introduction of larger endoscopes (1.6mm), dilation up to No.6 probe is necessary (Marchal F. 2003). Other techniques used to dilate the papilla or facilitate the identification of the papilla are the Seldinger's technique that uses a series of bougies of increasing diameter that are inserted over a guide wire that is placed in the salivary duct (Figure 9), the placement of a papillotomy or an incision at the entry point of the salivary duct to facilitate entry into the it, and use of Methylene blue to identify the duct orifice (Marchal F. 2003; Geisthoff UW. 2009; Papadaki ME, Kaban L, Kwolek C, et al. 2007; Iwai T, Matsui Y, Yamagishi M, et al. 2009; Luers JC, Vent J, Beutner D. 2008).




Fig. 9. Bougies of increasing diameter used in the Seldinger's technique of salivary duct dilation.

Nahlieli et al have suggested performing a papillotomy to allow introduction of the scope (Nahlieli O. 2006). However, in the authors' experience, a papillotomy prevents the creation

of a mucosal seal around the endoscope, resulting in leakage of the irrigation, consequently preventing maximum dilation of the duct through hydraulic pressure. The authors reserve the use of a papillotomy for one of two scenarios: difficult cases in which standard dilation or the Seldinger's technique fails and if necessary for the delivery of larger stones at the conclusion of a procedure.

2.1.4 Endoscopy with or without intervention

Despite its apparent simplicity, sialendoscopy is a technically challenging procedure that requires organized and sequential learning (Marchal F. 2003). Once this is acquired, the success rates for diagnostic as well as interventional sialendoscopy can be more than 85% (Marchal F, Dulguerov P. 2003; Nahlieli O. 2006; Marchal F. 2003).

Sialendoscopy allows visualization of the entire ductal system with ability to navigate the scope into primary, secondary and at time tertiary branching systems, (**Figure 10**). With respect to diagnostic sialendoscopy, Marchal and Dulguerov reported a 98% success rate (Marchal F, Dulguerov P. 2003), whereas (Nahlieli O, Baruchin AM. 1999) reported a success rate of 96% in their case series. Though diagnostic sialendoscopy is possible in most patients, failure to pass the scope along the entire ductal system may result from ductal stenosis, inflammation, or because of the presence of an acute masseteric bend of the parotid duct, making navigation with the scope difficult.

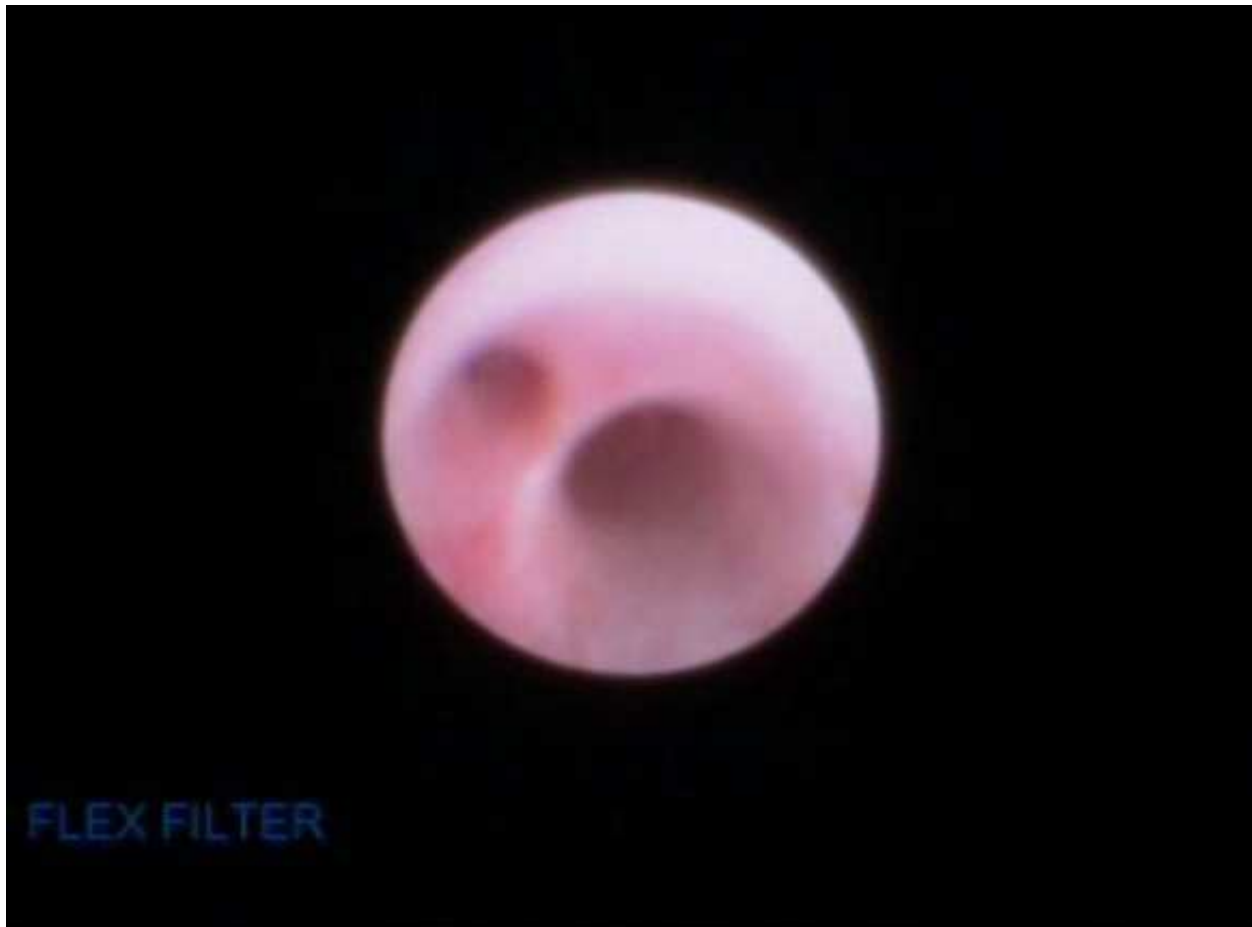


Fig. 10. Intraoperative view of the ductal lumen showing branching ductal system.

In the interventional setting, stone removal is the most common indication for sialendoscopy. Success rates for endoscopic stone removal without adjuvant lithotripsy with forceps or laser fragmentation range from 74-89% in several case series (Marchal F, Dulguerov P. 2003; Nahlieli O. 2006; Marchal F. 2007; Walvekar RR, Razfar A, Carrau RL, et al. 2008; Bowen MA, Tausin M, Kluka, EA, et al. 2010; Nahlieli O, Nakar LH, Nazarian Y, et al. 2008; Walvekar RR, Carrau RL, Schaitkin B. 2009). Nahlieli et al reported a success rate of 86% and 89%, respectively, for endoscopic parotid and submandibular sialolithotomy in 736 cases of sialolithiasis (Nahlieli O. 2006). However, their success rate for endoscopic sialolithotomy was 80% in an earlier series of 3 years experience, during which they reported a total of 32 cases of sialolithiasis with 4 failures (Nahlieli O, Baruchin AM. 1999). Stones larger than 3mm in the parotid gland and 4mm in the submandibular gland have a lower success rate for removal (Marchal F, Dulguerov P. 2003). Laser fragmentation and lithotripsy are useful for removal of intermediate-size stones (up to 6 or 7 mm). External lithotripsy can be performed prior to sialendoscopy to fragment the stones into smaller fragments that can be more readily removed with wire baskets or forceps. External lithotripsy for the management of salivary stone is not currently FDA approved in the United States. Consequently, the authors have not incorporated this into their practice. Laser stone fragmentation and intra-ductal lithotripsy have been described. The Holmium has been used for stone fragmentation (Papadaki ME, McCain JP, Kim K, et al. 2008). For larger stones or stones that cannot be accessed endoscopically, a combined approach technique is required, (Figure 11). The use of the da Vinci robot has been described to assist in the

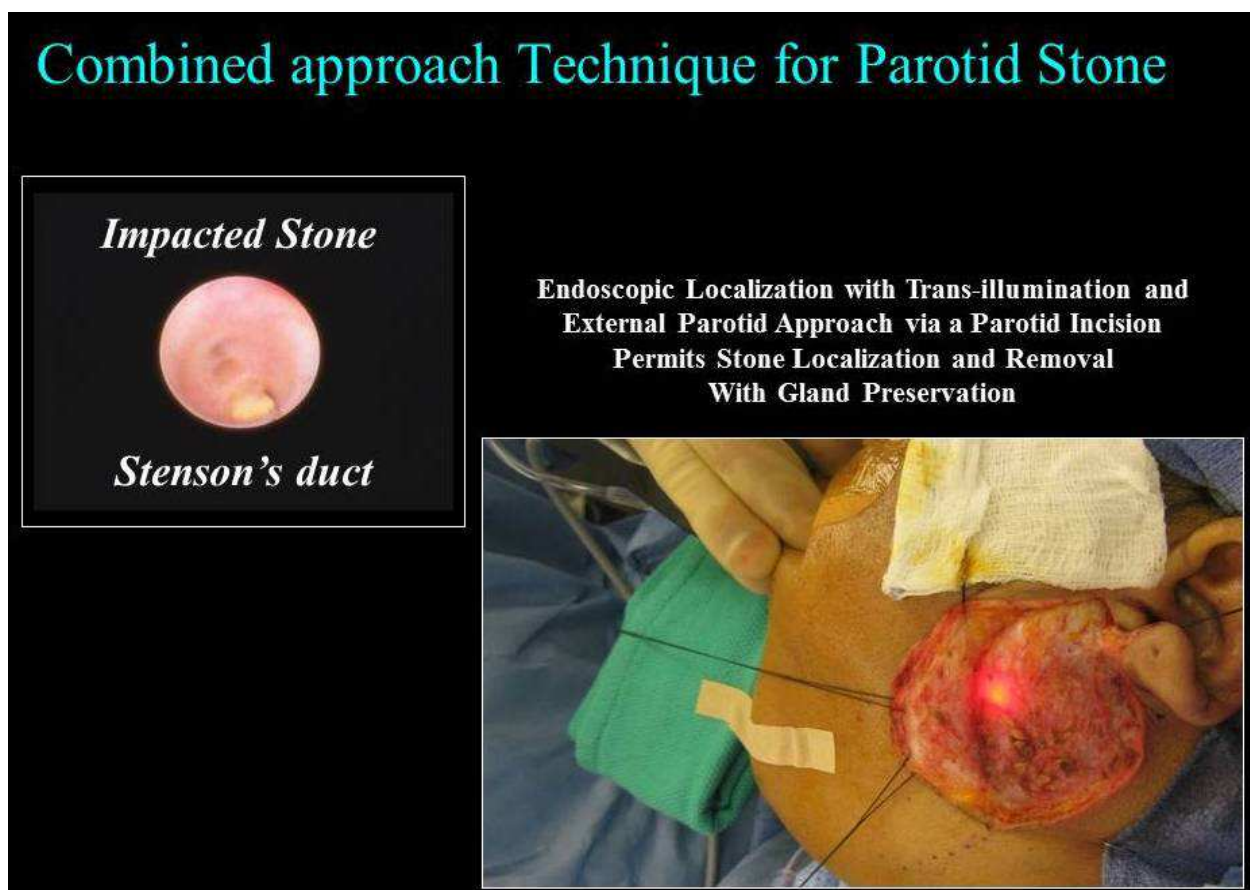

Fig. 11. Combined Approach Technique for Parotid Stones via an External Approach.

management of large hilar and intra-glandular submandibular salivary stones are traditionally difficult to access via a transoral route, (**Figure 12**)(Walvekar RR, Tyler PD, Tammareddi N, et al. 2011).

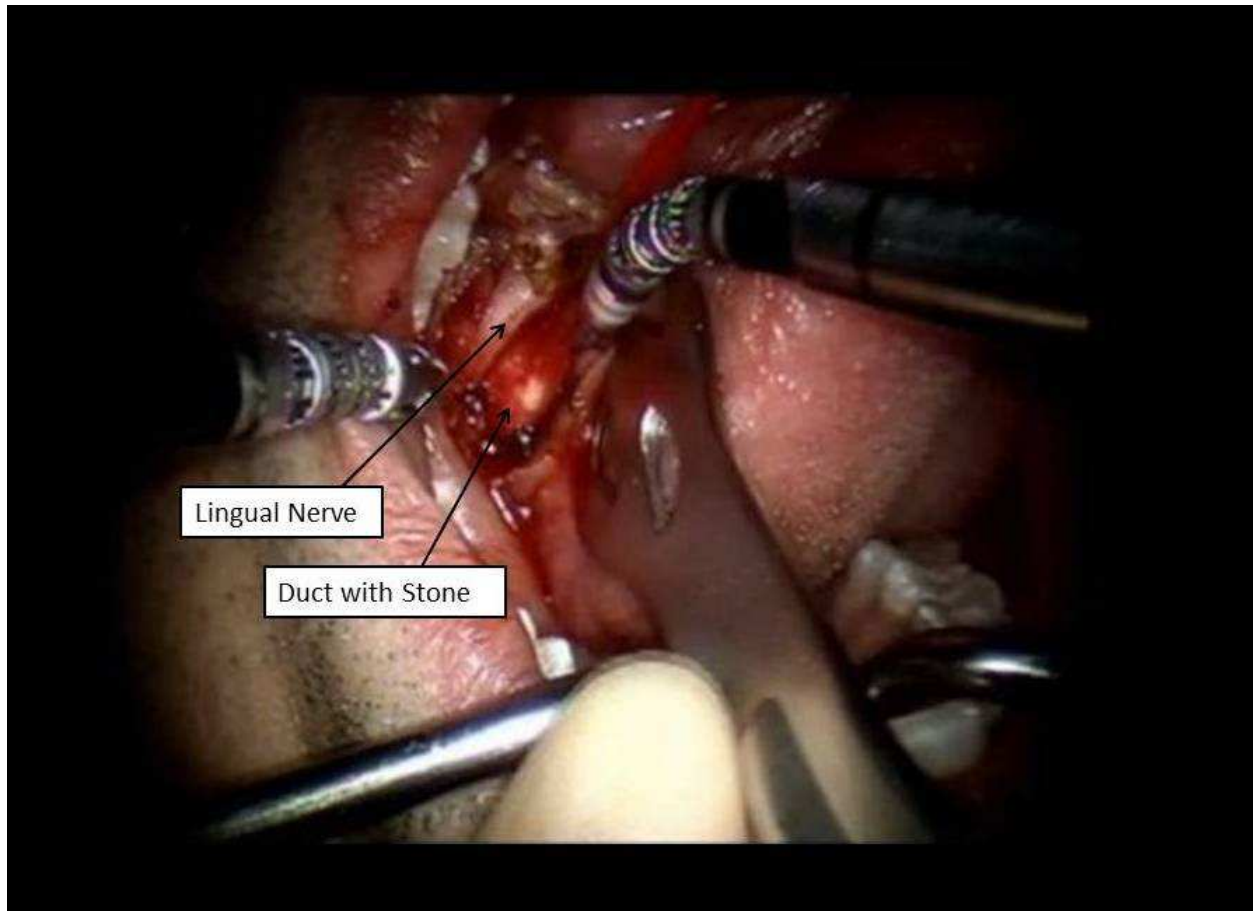


Fig. 12. Combined Approach Technique (Robot-Assisted) for Submandibular Stones via a Transoral Approach. Right submandibular stone is exposed with identification and dissection of the lingual nerve with excellent visualization via the da Vinci robotic system.

Radioactive iodine (RAI) treatment can induce sialadenitis with inflammation and consequently stenosis of the ductal system (Kim JW, Han GS, Lee SH et al. 2007; Bomeli SR, Schaitkin B, Carrau RL, et al. 2009; Nahlieli O and Nazarian Y. 2006). This occurs because the salivary glands in addition to the thyroid gland concentrate iodine. Up to 60% of patients treated with RAI can develop chronic sialadenitis (Kim JW, Han GS, Lee SH et al. 2007; Bomeli SR, Schaitkin B, Carrau RL, et al. 2009; Nahlieli O and Nazarian Y. 2006). Sialendoscopy has shown to be effective in the treatment of this disorder. Bomeli et al. (Bomeli SR, Schaitkin B, Carrau RL, et al. 2009) studied radioactive iodine induced sialadenitis in 12 patients. 37 glands were studied in these 12 patients. Mucous plugs were found in 44% of glands; strictures had developed in 30%. Therapeutic maneuvers involve flushing the gland to expel mucous plugs, dilation of stenotic areas with an endoscopic balloon dilator, or , intra-ductal instillation of steroids during the procedure. Sialendoscopy was able to be performed in 84% of patients and 75% of patients had resolution of symptoms following the procedure. Overall success rates for resolution of symptoms range

between 50 and 100%. Failure is most commonly due to severe ductal stenosis (Kim JW, Han GS, Lee SH et al. 2007; Bomeli SR, Schaitkin B, Carrau RL, et al. 2009; Nahlieli O and Nazarian Y. 2006).

Juvenile recurrent sialadenitis most frequently affects the parotid gland. The etiology is unknown. Sialendoscopy can be used as both a diagnostic tool and treatment (Nahlieli O, Shacham R, Shlesinger M, et al. 2004; Jabbour N, Tibesar R, Lander T, et al. 2010; Martins-Carvalho C, Plouin-Gaudon I, Quenin S, et al. 2010; Faure F, Querin S, Dulguerov P, et al. 2007). Sialendoscopy with irrigation of the duct with or without injection steroids has been shown to be effective in treating this condition. Characteristic findings are seen on sialendoscopy originally include whitish appearance of the duct and lack of vascular markings seen on the ductal wall. Shacham et al. (Shacham R, Droma EB, London D, et al. 2009) studied 70 children with recurrent sialadenitis. In 56 of the children, symptoms were eliminated after one procedure; only 5 children required a repeat procedure.

3. Complications

Major complication rates are low with sialendoscopy. Gland swelling post-operatively is expected and usually resolves in approximately 24-48 hours. This is particularly important to consider in submandibular procedures, as swelling could cause airway compromise (Iwai T, Matsui Y, Yamagishi M, et al. 2009). Consequently, when performing bilateral submandibular gland procedures, it is important to examine the gland and oral cavity after completing one side and determine whether it is safe for the patient to proceed with the contralateral gland.

One of the more serious iatrogenic complications is avulsion of the duct. This complication can be prevented by avoiding excessive traction on the stone while it is engaged in the wire basket. If duct avulsion or a major ductal tear occurs, subsequent gland excision could be necessary (Walvekar RR, Razfar A, Carrau RL, et al. 2008).

Lingual nerve paresthesias can occur in up to 15% of patients undergoing transoral combined procedures in the immediate post-operative period and resolves with time (Walvekar RR, Razfar A, Carrau RL, et al. 2008; Bowen MA, Tauzin M, Kluka, EA, et al. 2010; Nahlieli O. 2009). The development of a post-operative stricture has been reported (Bowen MA, Tauzin M, Kluka, EA, et al. 2010; Nahlieli O. 2009). Taking care not to cause trauma to the duct or papilla during the procedure minimizes the risk of this complication. In addition, in the event the duct is traumatized or a papillotomy is required, placement of a salivary stent for up to 2 weeks can help prevention of subsequent ductal or papillary stenosis. Salivary fistulas, sialoceles, minor ductal tears, development traumatic ranulas, minor bleeding, and infection have been reported (Nahlieli O. 2006; Walvekar RR, Razfar A, Carrau RL, et al. 2008; Bowen MA, Tauzin M, Kluka, EA, et al. 2010) (4,21,31). Other complications may include inability to retrieve the stone and failure of the procedure due to ductal stenosis or an acute masseteric bend (Nahlieli O. 2006; Walvekar RR, Razfar A, Carrau RL, et al. 2008; Bowen MA, Tauzin M, Kluka, EA, et al. 2010; Nahlieli O. 2009).

4. Future directions and conclusions

Diagnostic and interventional sialendoscopy are safe and effective options for treating non-neoplastic disorders of the major salivary glands. Sialendoscopy is technically challenging and requires sequential learning in which success rates appear to be proportional to the surgeon's level of experience Marchal F, Dulguerov P. (2003). The authors recommend that

future sialendoscopist's should familiarize themselves with the anatomy and physiology of the salivary glands and floor of the mouth. They should be competent in taking care of any potential complication and should be comfortable with major salivary gland resections if required. Sialendoscopy training via hands-on courses and case observations should be pursued prior to initiating a sialendoscopy practice


5. Further resources for sialendoscopy-related information

1. www.salivaryendoscopy.net
2. <http://emedicine.medscape.com/article/1520153-overview>
3. Marchal F. Sialendoscopy. In: E Myers, Ed. Salivary Gland Disorders. Berlin, Germany: Springer; 2007:127-48.
4. Marchal F, Dulguerov P. Sialolithiasis management: the state of the art. Arch Otolaryngol Head Neck Surg. Sep 2003;129(9):951-6.
5. Marchal F. Sialendoscopy: The Endoscopic Approach to Salivary Gland Ductal Pathologies. Tuttlingen, Germany: Endo Publishing; 2003.
6. Koch M, Zenk J, Iro H. Algorithms for treatment of salivary gland obstructions. Otolaryngol Clin North Am. 2009.

6. References

- [1] Nahlieli O, Shacham R, Shlesinger M, et al.(2004). Juvenile recurrent parotitis: a new method of diagnosis and treatment. *Pediatrics*; Vol. 144,No. 1, (Jul 2004),pp. 9-12.
- [2] Kim JW, Han GS, Lee SH et al.(2007). Sialendoscopic treatment for radioiodine induced sialadenitis. *Laryngoscope* Vol. 117, No. 1, (Jan 2007), pp. 133-136.
- [3] Bomeli SR, Schaitkin B, Carrau RL, et al. (2009), Interventional sialendoscopy for treatment of radioiodine-induced sialadenitis. *Laryngoscope*, Vol 119, No.5 ,(May 2009), pp. 864-867.
- [4] Nahlieli O and Nazarian Y. Sialadenitis following radioiodine therapy - a new diagnostic and treatment modality. *Oral Dis*, 2006;12:476-479.
- [5] Shacham R, Puterman MB, Ohana N, et al. (2011) Endoscopic treatment of salivary glands affected by autoimmune diseases. *J Oral Maxillofac Surg*, Vol. 69, No. 2 (Feb 2011), pp.476-481.
- [6] Marchal F, Dulguerov P. (2003) Sialolithiasis management: the state of the art. *Arch Otolaryngol Head Neck Surg*, Vol. 129, No. 9 (Sept 2003), pp. 951-956.
- [7] Nahlieli O. (2006) Sialendoscopy: a new approach to salivary gland obstructive pathology. *J Am Dent Assoc*, Vol. 137, No. 10, (Oct 2006), pp. :1394-1400.
- [8] Karavidas K, Nahlieli O, Fritsch N, et al.(2010) Minimal surgery for parotid stones: a 7-year endoscopic experience. *In J Oral Maxillofac Surg*, Vol. 39, No. 1, (Jan 2010), pp. 1-4.
- [9] Bodner L. (2002) Giant salivary gland calculi: diagnostic imaging and surgical management. *Oral Surg Oral Med Oral Pathol Oral Radiol Endo.* Vol. 94, No. 2, (Sep 2002), pp. 320-233.
- [10] Lustmann J, Regev E, Melamed Y. (1990) Sialolithiasis. A survey on 245 patients and a review of the literature. *Int J Oral Maxillofac Surg*, Vol. 19, No. 3, (Jun 1990), pp. 135-138.
- [11] Marchal F. (2007) A combined endoscopic and external approach for extraction of large stones with preservation of parotid and submandibular glands. *Laryngoscope*, Vol. 117, No. 2 (Feb 2007), pp. 373-377.
- [12] Raif J, Vardi M, Nahlieli O, et al. (2006) An Er:YAG laser endoscopic fiber delivery system for lithotripsy of salivary stones. *Lasers Surg Med*, Jul 2006;38(6):580-587.

- [13] Seldin HM, Seldin SD, Rakower W. (1953) Conservative surgery for the removal of salivary calculi. *Oral Surg Oral Med Oral Pathol*, Vol 6, No. 5, (May 1953), pp. 579-587.
- [14] Walvekar RR, Bomeli SR, Carrau RL, et al. (2009) Combined approach technique for the management of large salivary stones. *Laryngoscope*. Vol. 119, No. 6, (Jun 2009), pp.1125-1129.
- [15] Walvekar RR, Razfar A, Carrau RL, et al. (2008) Sialendoscopy and associated complications: a preliminary experience. *Laryngoscope*. Vol. 118, No. 5, (May 2008), pp. 776-779.
- [16] Jabbour N, Tibesar R, Lander T, et al. (2010) Sialendoscopy in Children. *Int J Pediatr Otorhinolaryngol*, Vol 74, No. 4, (Apr. 2010), pp. 347-350.
- [17] Martins-Carvalho C, Plouin-Gaudon I, Quenin S, et al. (2010) Pediatric Sialendoscopy: a 5-year experience at a single institution. *Arch Otolaryngol Head Neck Surg*, Vol 136, No. 1, (Jan 2010)pp. 33-36.
- [18] Faure F, Querin S, Dulguerov P, et al. (2007) Pediatric salivary gland obstructive swelling: sialendoscopic approach. *Laryngoscope*, Vol 117, No. 8 (Aug 2007), pp. 1363-1367.
- [19] Marchal F. Sialendoscopy: The *Endoscopic Approach to Salivary Gland Ductal Pathologies*. Tuttlingen, Germany: Endo-Publishing; 2003.
- [20] Geisthoff UW. (2009) Technology of sialendoscopy. *Otolaryngol Clin North Am* Vol. 42, No. 6, (Dec 2009), pp. 1001-1028.
- [21] Papadaki ME, Kaban L, Kwolek C, et al. (2007) Arterial stents for access and protection of the parotid and submandibular ducts during sialoendoscopy. *J Oral Maxillofac Surg* Vol 65, No. 9 (Sept 2007), pp. 1865-1868.
- [22] Iwai T, Matsui Y, Yamagishi M, et al. (2009) Simple technique for dilatation of the papilla in sialoendoscopy. *J Oral Maxillofac Surg*, Vol. 67, No. 3, (Mar 2009) pp. 681-2.
- [23] Luers JC, Vent J, Beutner D. (2008) Methylene blue for easy and safe detection of salivary duct papilla in sialendoscopy. *Otolaryngol Head Neck Surg* Vol. 139, No. 3 (Sept 2008), pp. 466-467.
- [24] Nahlieli O, Baruchin AM. (1999) Endoscopic technique for the diagnosis and treatment of obstructive salivary gland diseases. *J Oral Maxillofac Surg*. Vol. 25, No. 12, (Dec 1999), pp. 1394-401; discussion 1401-1402.
- [25] Bowen MA, Tuzin M, Kluka, EA, et al. (2010) Diagnostic and interventional sialendoscopy: a preliminary experience. *Laryngoscope*, Vol. 121, No. 2 (Feb 2010), pp. 299-303.
- [26] Nahlieli O, Nakar LH, Nazarian Y, et al. (2008) Sialoendoscopy: a new approach to salivary gland obstructive pathology. *J Am Dent Assoc*, Vol. 137, No. 10, (Oct 2008), pp. 1394-1400.
- [27] Walvekar RR, Carrau RL, Schaitkin B. (2009) Sialendoscopy: Minimally invasive approach to the salivary ductal system. *Operative Techniques in Otolaryngology*. Vol. 20, No. 2, (Jun 2009), pp. 131-135.
- [28] Papadaki ME, McCain JP, Kim K, et al. Interventional sialoendoscopy: Early Clinical Results. *J Oral Maxillofac Surg*, Vol. 66, No. 5, (May 2008), pp. 954-962.
- [29] Walvekar RR, Tyler PD, Tammareddi N, et al. Robotic-assisted Transoral removal of a submandibular Megalith. *Laryngoscope* Vol. 131, No. 3, (Mar 2011), pp. 534-7.
- [30] Shacham R, Droma EB, London D, et al. Long-term experience with endoscopic diagnosis and treatment of juvenile recurrent parotitis. *J Oral Maxillofac Surg*, Vol. 67, No. 1, (Jan 2009), pp. 162-167.
- [31] Nahlieli O. Advanced Sialoendoscopy Techniques, Rare Findings and Complications. *Otolaryngol Clin North Am*. Vol. 42, No. 6, (Dec 2009), pp. 1053-1072.



Advances in Endoscopic Surgery

Edited by Prof. Cornel Iancu

ISBN 978-953-307-717-8

Hard cover, 444 pages

Publisher InTech

Published online 25, November, 2011

Published in print edition November, 2011

Surgeons from various domains have become fascinated by endoscopy with its very low complications rates, high diagnostic yields and the possibility to perform a large variety of therapeutic procedures. Therefore during the last 30 years, the number and diversity of surgical endoscopic procedures has advanced with many new methods for both diagnoses and treatment, and these achievements are presented in this book. Contributing to the development of endoscopic surgery from all over the world, this is a modern, educational, and engrossing publication precisely presenting the most recent development in the field. New technologies are described in detail and all aspects of both standard and advanced endoscopic maneuvers applied in gastroenterology, urogynecology, otorhinolaryngology, pediatrics and neurology are presented. The intended audience for this book includes surgeons from various specialities, radiologists, internists, and subspecialists.

How to reference

In order to correctly reference this scholarly work, feel free to copy and paste the following:

Meghan Wilson, Kyle McMullen and Rohan R. Walvekar (2011). Sialendoscopy: Endoscopic Approach to Benign Salivary Gland Diseases, *Advances in Endoscopic Surgery*, Prof. Cornel Iancu (Ed.), ISBN: 978-953-307-717-8, InTech, Available from: <http://www.intechopen.com/books/advances-in-endoscopic-surgery/sialendoscopy-endoscopic-approach-to-benign-salivary-gland-diseases>

INTECH
open science | open minds

InTech Europe

University Campus STeP Ri
Slavka Krautzeka 83/A
51000 Rijeka, Croatia
Phone: +385 (51) 770 447
Fax: +385 (51) 686 166
www.intechopen.com

InTech China

Unit 405, Office Block, Hotel Equatorial Shanghai
No.65, Yan An Road (West), Shanghai, 200040, China
中国上海市延安西路65号上海国际贵都大饭店办公楼405单元
Phone: +86-21-62489820
Fax: +86-21-62489821

© 2011 The Author(s). Licensee IntechOpen. This is an open access article distributed under the terms of the [Creative Commons Attribution 3.0 License](#), which permits unrestricted use, distribution, and reproduction in any medium, provided the original work is properly cited.

IntechOpen

IntechOpen