

We are IntechOpen, the world's leading publisher of Open Access books Built by scientists, for scientists

4,800

Open access books available

122,000

International authors and editors

135M

Downloads

Our authors are among the

154

Countries delivered to

TOP 1%

most cited scientists

12.2%

Contributors from top 500 universities

**WEB OF SCIENCE™**Selection of our books indexed in the Book Citation Index
in Web of Science™ Core Collection (BKCI)

Interested in publishing with us?
Contact book.department@intechopen.com

Numbers displayed above are based on latest data collected.

For more information visit www.intechopen.com

Endoscopic Surgery of Maxillary Sinuses in Oral Surgery and Implantology

Miroslav Andrić

*University of Belgrade, Faculty of Dentistry
Serbia*

1. Introduction

Due to the close anatomical relationship of the maxillary sinuses to the dentoalveolar complex, surgical procedures involving these anatomical structures represent a part of a everyday practice in oral surgery and implantology. Those interventions are directed mainly towards the treatment of odontogenic infections of the sinuses as well as surgical treatment of oroantral fistulae and odontogenic cysts and tumors of the upper jaw invading the antrum. Traditional approach under such circumstances is a Caldwell-Luc type of surgery, comprising osteotomy of the anterior sinus wall and creation of artificial opening of the sinus into the inferior nasal meatus. Although high success rates are reported, this kind of surgery may result in significant long-term complications, such as sclerosis of the antral walls, collapse of the sinus and creation of the postoperative cysts of maxilla (Nemec et al., 2009).

Also, widespread use of dental implants resulted in development of numerous techniques of alveolar bone augmentation in order to provide adequate amount of bone for implant placement. Many of those techniques involve the maxillary sinuses. However, complications of dental implant placement and augmentation procedures may include injuries to the maxillary sinuses, infections of the sinuses and displacement of augmentation material or implants themselves into the sinus. Again, the primary treatment of those complications includes surgery of the sinus, most commonly a Caldwell-Luc procedure.

Recent technological advances in field of endoscopy resulted in substantial improvement in techniques of endoscope-controlled surgery of nose and paranasal sinuses. Those techniques proved to be very useful in this area of complex anatomy and limited access to the surgical field. In particular, endoscopic surgery of the maxillary sinuses is widespread and has a long track of good results in ENT surgery. This is especially true for functional endoscopic sinus surgery (FESS). This technique, proved to be safe and effective for treatment of both chronic rhino-sinusitis and nasal polyposis (Chiu & Kennedy, 2004), nowadays is widely accepted as a standard of care for patients who require surgical treatment of chronic rhino-sinusitis.

In contrast to this, surgical treatment of odontogenic diseases of the maxillary sinus still predominantly comprises traditional surgical techniques. Recently, several studies reported results of FESS for treatment of odontogenic sinusitis. Also, new techniques of endoscope-assisted surgery of odontogenic cysts and tumors were described. Finally, endoscope-

controlled sinus augmentation and endoscopic treatment of implant-related complications involving the maxillary sinuses were reported in the literature.

Therefore, the aim of this article was to describe clinical problems encountered in this field, to briefly discuss indications for the surgery and to analyze available treatment options and criteria for selection of optimal treatment modality. Also, a literature review will present available data on endoscopic surgery for treatment of odontogenic diseases of the maxillary sinuses, as well as for sinus augmentation procedures and treatment of implant-related complications affecting the maxillary sinuses. Finally, the level of current scientific evidence on these issues will be evaluated.

2. Odontogenic maxillary sinusitis

Apart from more common rhinogenic sinusitis, some cases of maxillary sinus infections are related to odontogenic sources. This entity, designated as odontogenic maxillary sinusitis (OMS) accounts for approximately 10-12% of all cases of maxillary sinusitis (Mehra & Murad, 2004).

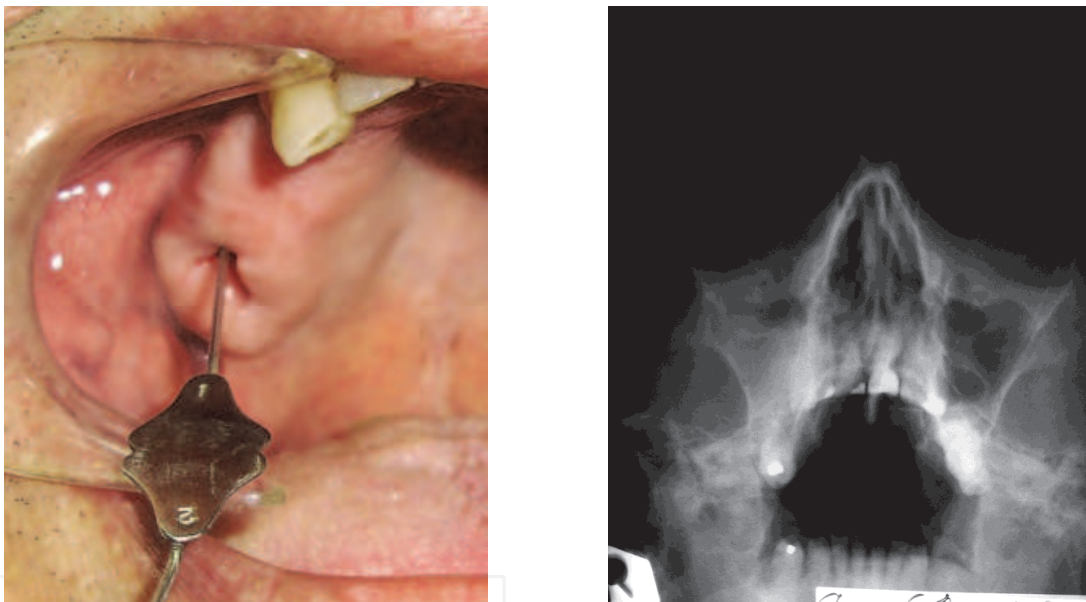

Fig. 1. a. Clinical photograph of a right oroantral fistula. A probe is inserted through the fistula into the sinus. b. Waters' view of the same patient indicating acute maxillary sinusitis.

The most common cause of OMS are oroantral fistulae (OAF) (Figures 1a and 1b) which are defined as pathological communications between the oral cavity and the maxillary sinus (Brook, 2006). Usually, they result from unsuccessful healing of Schneiderian membrane perforations that occur during tooth extractions and other surgical procedures involving alveolar processes of the upper jaw. In contrast to oroantral communications, which occasionally may heal spontaneously, most cases of OAF and subsequent maxillary sinusitis will require some kind of surgical treatment. This treatment varies from simple fistula closure by local flap to endoscopically assisted surgery of the maxillary sinus.

Besides oroantral fistulae, other common causes of OMS are chronic periapical or periodontal odontogenic infections, odontogenic cysts of the maxilla and iatrogenic factors, including placement of dental implants, sinus augmentations and intra-antral foreign bodies

(Brook, 2006; Zimble et al., 1998) (Figure 2). What is common for all these conditions is that disruption of the sinus membrane results in creation of a pathway through which oral microorganisms invade the antrum, resulting in sinus inflammation.

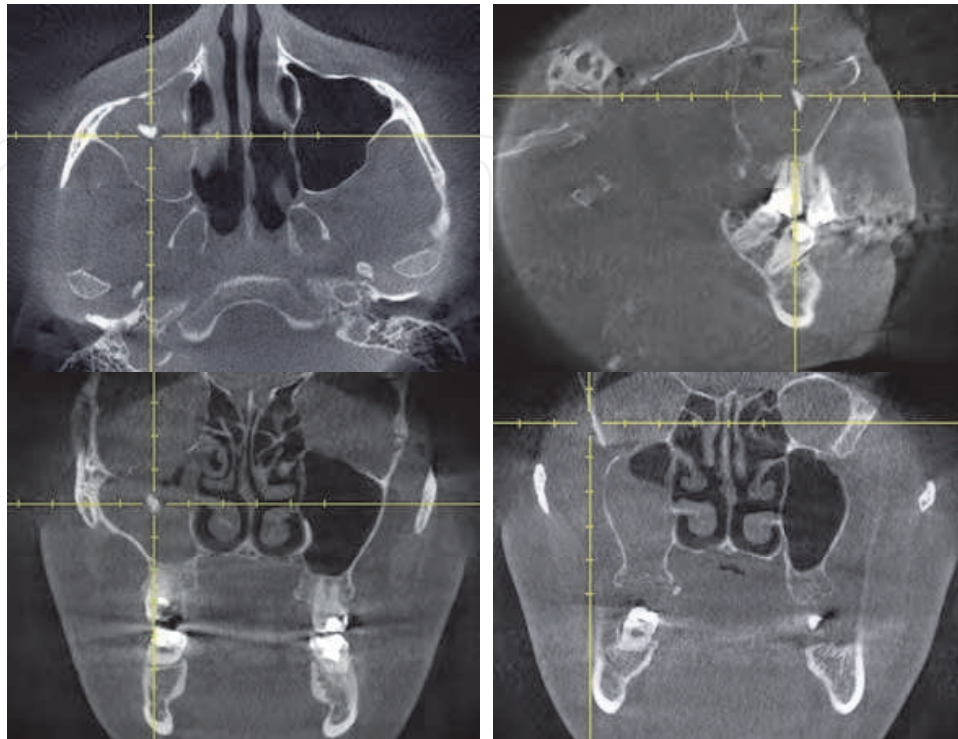


Fig. 2. Cone-beam CT of a patient with OAF and a root tip pushed into the sinus. Such situation is usually followed by pronounced inflammatory reaction.

Traditionally, OMS is treated by a Caldwell-Luc type of surgery (Güven, 1998) or by conservative procedures, including antibiotics and sinus irrigation, followed by surgical treatment of odontogenic source of infection (Dolanmaz et al., 2004). Caldwell-Luc operation is criticized as aggressive surgery with relatively high incidence of complications (De Freitas & Lucente, 1988; Ikeda et al., 1996). Most important of all, efficacy of inferior meatal antrostomy, typically performed in this kind of surgery, is doubtful, as the mucociliary clearance remains directed toward the natural sinus ostium in the middle meatus (Kennedy & Shaalan, 1989). Car & Juretić (1998) and Al-Belasy (2004), showed that inferior meatal antrostomy might be avoided, at least in some patients. Nevertheless, opening of the sinus on its anterior wall has to be performed, which results in permanent defect of anterior maxilla, sclerosis of the antral walls and collapse of the sinus cavity (Nemec et al., 2009). This kind of defect could complicate future prosthetic rehabilitation of these patients, regarding possible use of dental implants.

3. Functional endoscopic sinus surgery for treatment of odontogenic sinusitis

Principles of functional endoscopic sinus surgery (FESS) are based on actual understanding of sinus physiology, particularly regarding mucociliary clearance of the sinus. If effective drainage of the maxillary sinus is to be established, the optimal location to do so is at the

level of the natural sinus ostium, in the middle nasal meatus. Therefore, FESS is directed towards establishment and preservation of osteomeatal complex patency. It aims to restore sinus ventilation and reestablish mucociliary clearance, which in turn results in resolution of sinus disease and maintenance of healthy sinus mucosa (Stammberger, 1986; Kennedy, 1985). It was demonstrated that such therapeutical approach is a viable option for treatment of both maxillary sinusitis and other inflammatory conditions affecting this anatomical structure (Busaba & Kieff, 2002). In contrast to rhino-sinusitis, most cases of OMS are still treated by a Caldwell-Luc type of surgery. However, several studies were published, reporting results of FESS for treatment of chronic odontogenic sinusitis (Lopatin et al., 2002; Costa et al., 2007; Andric et al., 2010; Albu & Baciut, 2010; Hajjioannou et al., 2010), which will be discussed in details later in this chapter.

3.1 Surgical technique

Endoscopic surgery of the maxillary sinuses is most commonly based on usage of rigid endoscopes, usually of 4.0 mm diameter. These endoscopes, providing different angles of vision, from 0 to 120 degrees, allow for good visualization of all parts of the osteomeatal complex, sinus ostium and sinus itself. Also, a set of specially designed surgical instruments includes different biting and grasping forceps, cutting knives and microdebriders.

This kind of surgery is usually done with patient under the general anesthesia. If possible, carefully controlled hypotension is useful to minimize bleeding during the procedure (Eberhart et al., 2007) since it was shown that pronounced intraoperative bleeding correlates with higher failure rates in endoscopic sinus surgery (Albu & Baciut, 2010). Also, infiltration of surgical field with local anesthetic solution containing epinephrine is very helpful for this purpose.

Procedures starts with careful medial dislocation of the middle turbinate which allows good visualization of the middle nasal meatus, uncinate process and ethmoidal bulla. Uncinate process is cut by a sickle-knife in a direction parallel to its upper edge and removed by grasping forceps (Figures 3a, 3b and 3c).

After that, natural sinus ostium is identified and subsequently enlarged in a postero-inferior direction. Ostium is enlarged to the size that should allow access to the sinus with appropriate instruments and also effective drainage of the sinus after the surgery (Figure 4). At this point care must be taken, as extremely anterior enlargement of the ostium might result in an injury to the nasolacrimal duct. Through this enlarged ostium it is possible to inspect entire maxillary sinus, particularly when angled-view endoscopes are used (Figure 5). Also, using long curved antrum forceps and suction tips, most of intra-antral pathology and foreign bodies can be removed by this approach too.

What is specific for odontogenic sinusitis is that most of mucosal inflammation, as well as majority of foreign bodies of dental origin, are located in the alveolar recess of the sinus. Depending on local anatomy and position of sinus ostium, access to this part of the sinus might be difficult, even when large middle meatal antrostomy is performed. Still, in cases with OAF it is possible to reach alveolar recess through the fistula itself. Beside this, additional small puncture of the sinus in canine fossa, with an endoscope introduced through it, can provide better visualization of this part of the sinus. However, in most of the cases, angled view endoscopes will ensure good visual control in the entire sinus, even through middle meatal antrostomy.

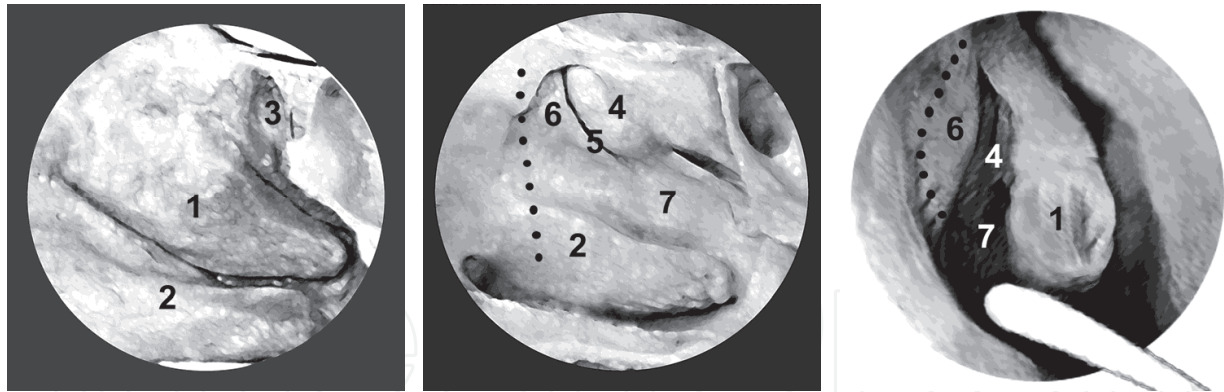


Fig. 3. Schematic presentation of the right lateral nasal wall. a. Middle turbinate (1), inferior turbinate (2) and spheno-ethmoidal recess (3) are seen. b. Upon removal of the middle turbinate, middle nasal meatus (7) is visible. Semilunar hiatus (5) is bounded by ethmoidal bulla (4) and uncinete process (6). Aperture of the maxillary sinus can not be seen, as it is located behind these structures. Dotted line illustrates path of the nasolacrimal duct. c. The same anatomic structures as seen through a 0° endoscope. Middle turbinate (1) is dislocated medially by a Freer elevator. Dotted line represents line of resection of the uncinete process (6). Previously published in ref: Andric et al, 2010.

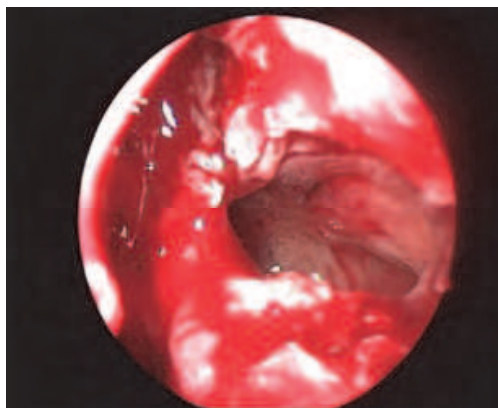


Fig. 4. A view of the enlarged natural ostium of the left maxillary sinus (0° endoscope). Previously published in ref: Andric et al, 2010.

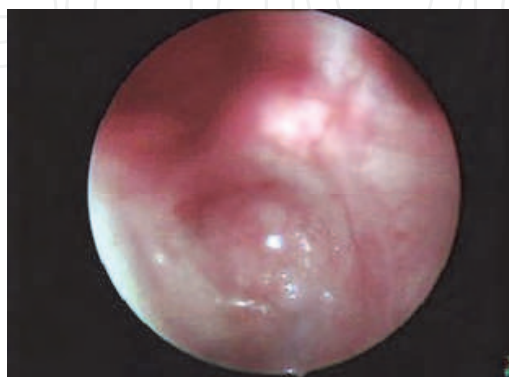


Fig. 5. A view of the alveolar recess of the maxillary sinus through the enlarged ostium (70° endoscope). Previously published in ref: Andric et al, 2010.

The most important advantage of FESS, compared to other treatment options for odontogenic sinusitis, is a possibility to surgically treat inflammation of other paranasal sinuses as well, in particular that of anterior ethmoidal cells. Residual inflammation in this area is one of common causes of failure in treatment of odontogenic sinusitis. Therefore, if necessary, removal of ethmoidal bulla and opening of the anterior ethmoidal cells may be performed too (Figures 6a and 6b).

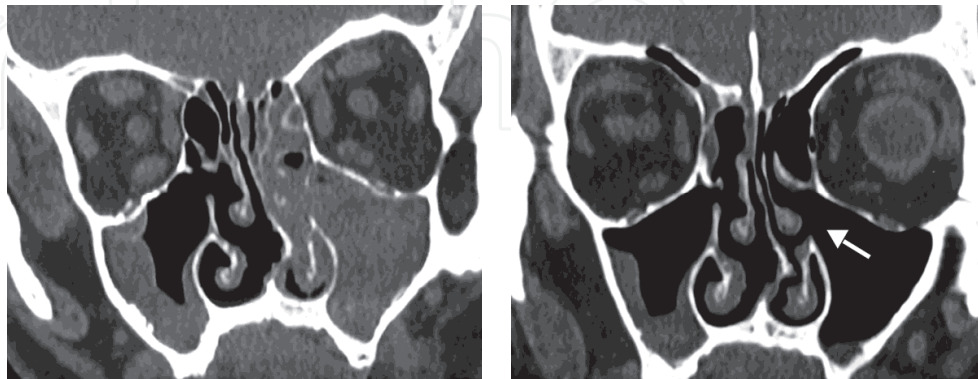


Fig. 6. a. Coronal CT scan of odontogenic sinusitis demonstrating pronounced inflammation of left maxillary sinus and anterior ethmoidal cells. b. Six months postoperatively reduction in extent of sinus inflammation, as well as resection of the uncinete process (arrow) are clearly visible. Previously published in ref: Andric et al, 2010.

Finally, successful treatment of odontogenic sinusitis is based on efficient elimination of odontogenic source of infection. Therefore, closure of oroantral fistula (if present) and extraction of causative teeth should be performed in the same surgical act.

3.2 Literature data

Recently, several authors reported results of FESS for treatment of chronic odontogenic sinusitis (Lopatin et al., 2002; Costa et al., 2007; Andric et al., 2010; Albu & Baciut, 2010; Hajjioannou et al., 2010). Although there were some technical differences, all studies have reported essentially the same surgical procedure, comprising middle meatal antrostomy, access to the maxillary sinus through enlarged natural sinus ostium and endonasal approach for removal of intra-antral foreign bodies, such are root tips and dental implants. The most important results of these studies are summarized in table 1.

Lopatin (Lopatin et al., 2002) was the first who reported 70 cases of odontogenic sinusitis treated by endoscopic sinus surgery. Apart from 39 cases with OAF, he presented 10 cases with odontogenic cysts and 6 with fungal balls in the sinuses. Also, he presented 21 cases with foreign bodies inside the sinus. Surgical technique included usage of microdebrider, resection of the uncinete process and removal of ethmoidal bulla. Removal of foreign bodies was accomplished by curved suction tip through enlarged sinus ostium. Authors commented on difficulty in reaching alveolar recess of the sinus through middle meatal antrostomy. In initial cases they used additional puncture in canine fossa, and later on, access to alveolar recess was established through OAF itself. Out of 70 cases, after the follow-up period of up to three years, there were 4 failures. In 3 patients recurrence of OAF was noticed and in one patient stenosis of antrostomy resulted in recurrent sinusitis. Besides facial edema and nasal discharge, which were described as less pronounced compared to Caldwell-Luc procedure, no other complications were reported.

	Total cases (n)	Cases with OAF (n)	OAF recurrence n (%)	Revision surgery n (%)	Follow up period	Overall success rate n/all cases (%)
<i>Lopatin et al., 2002</i>	70	39	3 (8%)	3 (4%)	1 – 3 yr	66 / 70 (95%)
<i>Costa et al., 2007</i>	17	5	No	No	6 mo – 2 yr	17 / 17 (100%)
<i>Andric et al., 2010</i>	14	14	No	No	6 mo – 2 yr	14 / 14 (100%)
<i>Albu & Baicut, 2010</i>	104	30	4 (13%)	9 (9%)	Min. 6 mo	95 / 104 (91%)
<i>Hajjioannou et al., 2010</i>	4	4	No	No	6 mo – 3 yr	4 / 4 (100%)

Table 1. Results of clinical studies on FESS for treatment of odontogenic sinusitis. Mo – months, Yr – years. Previously published in ref: Andric, 2010.

Costa (Costa et al., 2007) presented 17 cases of OMS, including 5 OAF, 7 cases with odontogenic cysts, 2 cases of sinusitis related to placement of dental implants and 3 patients with root-canal sealing materials pushed into the sinus. Again, microdebrider was used and access to alveolar recess was obtained through OAF. In cases with odontogenic cysts, a bone window in the anterior sinus wall was created for removal of the cyst, while middle meatal antrostomy was performed to enhance resolution of corresponding sinus inflammation. After a 2-years follow up period, good long - term results (defined as absence of sinusitis symptoms and healing of OAF) were obtained in all cases. In one case nasal synechiae were observed postoperatively, which was corrected under the local anesthesia.

Another retrospective study (Andric et al., 2010) reported results of FESS in 14 patients with OAF and corresponding OMS. Similarly to previous studies, middle meatal antrostomy was performed by resection of the uncinate process, and most of instrumentation inside the sinus was accomplished through the enlarged sinus ostium, including removal of intra-antral foreign bodies. Closure of OAF was achieved by Rehrmann's buccal advancement flap or buccal fat pad. During the follow up period of up to two years, clinical examination and control CT scans showed good results in all cases. No significant complications were reported.

The only prospective study on this issue included 104 patients with OMS and 307 with rhinogenic sinusitis (Albu & Baciut, 2010). It is of interest that no statistically significant differences in failure rates was noted comparing these two groups of patients (7% in odontogenic *vs.* 9% in rhinogenic group). Still, somewhat higher failures rates (13%) were noticed in cases with OAF. Surgical technique was similar to other studies, including puncture of the sinus in the canine fossa for better visualization of the alveolar recess. Again, there were not significant intraoperative and postoperative complications.

Finally, in a case series from Hajjioannou, four cases of odontogenic sinusitis with OAF were successfully treated by endoscopic sinus surgery and fistula closure by synthetic

surgical glue and buccal advancement flap (Hajjioannou et al., 2010). Also, retrospective analysis of 27 cases of odontogenic sinusitis revealed that most common causes of this condition were complications of dental implants placement and tooth extraction. Treatment included transnasal endoscopic sinus surgery in 19 (70.4%) patients, Caldwell-Luc operation in two (7.4%) patients and only antibiotics in 4 (14.8%) cases. During the follow-up period of two to six months, no recurrences were recorded (Lee, KC. & Lee, SJ., 2010).

In summary, all these studies reported essentially the same surgical procedure, applying principles of FESS for treatment of rhinogenic sinusitis in patients with OMS. In all cases middle meatal antrostomy was performed which presents substantial difference to Caldwell-Luc procedure. It is interesting that most of the surgeons, at least in some cases, used additional puncture of the sinus in canine fossa, creating better access to the alveolar recess of the sinus. This is very specific for treatment of odontogenic sinusitis in which most of the intra-antral pathology is located in the lower third of the sinus. Still, it was also demonstrated that access to this part of the maxillary sinus can be achieved through oroantral fistula, if present.

It is important that practically no significant intraoperative or postoperative complications occurred in any case. Although endoscopic sinus surgery might result in broad range of major and minor complications (McMains, 2008), rare occurrence of complications in the treatment of odontogenic maxillary sinusitis might be related to the relatively limited extent of endo-nasal surgery, compared to the treatment of rhinosinusitis and nasal polyps.

Although all studies presented very good short to mid-term results (follow up period lasted up to three years), there is a lack of objective measures of improvement in patients' condition after the surgery. All studies reported lack of symptoms and subjective patients' perception of improvement as outcome measures. In one study (Andric et al., 2010) control CT scans were performed, but without attempt to use some scoring system of CT findings in sinusitis. The only result which can be objectively validated is recurrence rate of OAF. It ranged from 0 to 13% which is similar or somewhat higher comparing to Caldwell-Luc procedure (Guven, 1998; Yilmaz et al., 2003). Still, it has to be addressed that closure of OAF is a delicate procedure, requiring vast experience specific to this kind of surgery. Although it is a common procedure for oral and maxillofacial surgeons, some of otorhinolaryngologists rarely perform this intervention. In fact, in a study with highest recurrence rate reported (Albu & Baciut, 2010), authors were able to demonstrate "learning curve" since three recurrences occurred in the first 15 cases and only one in remaining patients.

Finally, it can be concluded that use of FESS for treatment of OMS is clinically well documented procedure with good results and low incidence of complications. Still, from the scientific point of view, the main shortcoming of all these studies is that results of FESS are not compared with results of some traditional treatment options for odontogenic sinusitis, such is Caldwell-Luc procedure. Therefore, prospective and randomized studies are needed to establish efficacy of this kind of treatment, as well to provide criteria for individual selection of most suitable treatment of odontogenic sinusitis.

4. Endoscopic surgery for treatment of odontogenic cysts and tumors

The most common odontogenic cysts and tumors involving the upper jaw include periapical and dentigerous cysts, keratocystic odontogenic tumors (previously known as odontogenic keratocysts) and ameloblastomas. Their expansive growth within the upper jaw might result in destruction of the bony walls of the sinus and subsequent sinus infection (Figure 7).

Clinical course of these lesions tends to be relatively asymptomatic and it is not uncommon that symptoms of maxillary sinusitis are among the first signs indicating the presence of an odontogenic cyst or tumor.

Selection of the most appropriate surgical treatment is based on histological type of the lesion, but also having in mind its size and relationship to the neighboring anatomical structures, including maxillary sinuses. Inflammatory periapical and residual cysts, as well as dentigerous cysts are effectively treated by simple enucleation and extraction or endodontic treatment of the causative tooth. On the other hand, keratocystic odontogenic tumors (KCOT) and ameloblastomas require more aggressive type of surgery due to infiltrative growth and high recurrence rates. Still, while most of ameloblastomas of the upper jaw are treated by partial maxillectomy, surgical options for KCOT include decompression followed by complete enucleation, enucleation in combination with Carnoy solution or cryosurgery and, finally, resection of the involved jaw (Ghali & Connor, 2003).

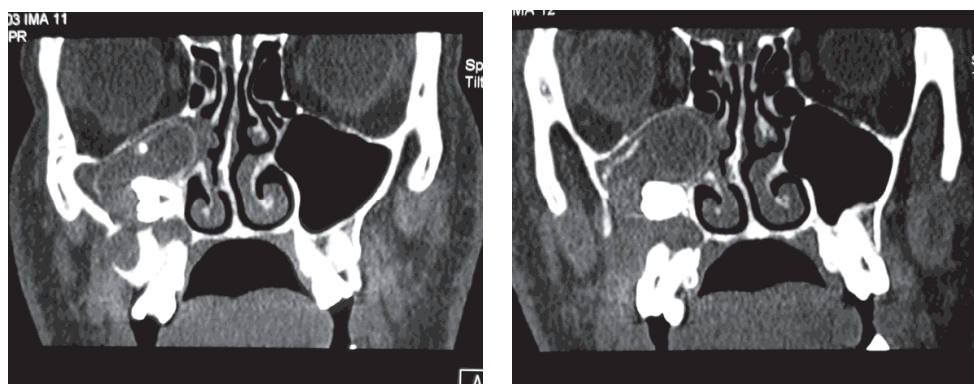


Fig. 7. Coronal CT scan of keratocystic odontogenic tumor of the right maxilla invading the maxillary sinus and resulting in secondary inflammation of antral mucosa.

In cases of odontogenic cysts or tumors occupying the sinus, common surgical approach includes removal of the lesion by a Caldwell-Luc type of surgery. Still, while such procedure results in permanent defect of anterior maxilla, visualization of the postero-inferior part of the upper jaw (which is a common site of occurrence of odontogenic lesions) might be difficult even when large antrostomy in the canine fossa is performed. Endoscope-assisted surgery for those lesions has a potential to provide better overview of the surgical field and still to allow less aggressive surgical approach.

Few articles were published describing techniques of endoscope-assisted removal of odontogenic cysts from the maxillary sinus. Cedin (Cedin et al., 2005) presented 4 cases of periapical cysts with oroantral fistulae, occupying alveolar recess of the sinus. Surgical technique comprised combined approach through canine fossa and inferior meatal antrostomy, cystectomy under the endoscopic control and closure of oroantral fistula by local flaps. Successful closure of OAF was obtained in all cases and there were no recurrences during the 2-years follow-up period.

In a case-series including 10 periapical and 3 dentigerous cysts (Seno et al., 2009), after partial resection of anterior portion of the inferior turbinate, inferior meatal antrostomy was performed to gain access to the alveolar recess and to allow removal of the cyst. Interestingly, although authors stated that in five cases of periapical cysts only partial resection of the cystic wall was performed, in a follow-up period ranging from 11 to 72

months no recurrences were noted. Also, several case reports were published, describing similar surgical techniques (Micozkadioglu & Erkan, 2007; Lamb et al., 2009; Di Pasquale & Shermetaro, 2006; Hasbini et al., 2001; Christmas et al., 2008).

It is interesting that in these studies access to the sinus was obtained through inferior nasal meatus, which reflects difficulties in reaching inferior portion of the maxillary sinus through middle meatal antrostomy. Such difficulties are best described in an article from Lamb and coworkers (Lamb et al., 2009), who reported that attempt to remove odontogenic cyst and the tooth from the sinus through middle meatal antrostomy was unsuccessful, so conversion to Caldwell-Luc approach had to be performed. On the other hand, several authors reported successful removal of dentigerous cysts through middle meatal antrostomy (Di Pasquale & Shermetaro, 2006; Hasbini et al., 2001; Christmas et al., 2008). As an alternative technique, Costa (Costa et al., 2007) used intraoral approach for removal of the cyst and middle meatal antrostomy was performed to treat corresponding sinusitis.

At this point, it seems reasonable to use inferior meatal antrostomy for removal of cysts from the sinus, if patency of natural sinus ostium is preserved. If not, widening of the natural sinus ostium, according to FESS principles, should enhance resolution of sinus inflammation. However, there is some concern that simultaneous persistence of more than one opening of the sinus might actually decrease its drainage, due to "circular flow" phenomenon (Coleman & Duncavage, 1996). Still, in a prospective study including 72 patients with severe maxillary sinusitis (as determined by Lund-Mackay CT score), combined inferior and middle meatal antrostomy shown superior results in reduction of sinus inflammation, compared to middle meatal antrostomy alone (Albu et al., 2011).

Regarding odontogenic tumors, several cases of endoscopic surgery for treatment of ameloblastomas of the upper jaw were reported (London & Schlosser, 2002; Bray et al., 2007; Leong et al., 2010). Although in most of them entire tumor was removed by an endoscopic approach, a technique of combined maxillectomy and endoscopic ethmoidectomy was described, too (Bray et al., 2007).

Also, few cases of fibro-osseous lesions involving ethmoidal region were presented (Akao et al 2003, Cansiz et al 2004, Lopatin and Kapitanov 2005). In all of them transnasal endoscopic approach was used with variable success, since in one case only reduction of tumor was achieved which required additional surgery for complete removal of the lesion (Akao et al, 2003).

At this point it has to be noted that follow up periods for cases of odontogenic tumors were variable in these reports, which rises the question of possible recurrences. While an average time for diagnosis of ameloblastoma recurrence is approximately 5 years, late recurrences are well documented in the literature (Carlson & Marx, 2006). Therefore, long term follow-up, as well as prospective studies comparing endoscopic and traditional surgical techniques for removal of odontogenic tumors are needed.

5. Endoscopic sinus surgery and dental implant treatment

An increasing number of dental implants is placed in posterior parts of the upper jaw. Although advances in surgical techniques and implant design resulted in high success rates, complications are still encountered, many of them involving maxillary sinuses. Such complications include creation of oroantral fistulae, sinus infections and displacement of implants or grafting material into the sinus. Also, in unfavorable anatomical situations, sinus augmentation procedures are needed prior or simultaneously to implant placement.

Recently, endoscopic techniques were described, both for treatment of sinus related complications of dental implants and for sinus augmentation.

5.1 Endoscopic surgery for treatment of implant-related complications

Occasionally, displacement of implants into the sinus may occur, either during implant insertion or during functional loading period. Although some of cases may remain asymptomatic, such situation usually results in inflammation of the corresponding sinus, obviously requiring some kind of treatment. Even in asymptomatic cases, removal of displaced implant should not be postponed, since it may result in migration of implant into distant spaces, such are nasal cavity (Kitamura, 2007), sphenoid sinus (Felisati et al., 2007), orbit (Griffa et al., 2010) or even anterior cranial fossa (Cascone et al., 2010).

Once the diagnosis has been made, surgical procedure for implant removal may include opening of the anterior sinus wall *via* Caldwell-Luc approach, or endoscopic sinus surgery. In available literature, two endoscopic techniques for removal of implants were described, creating access to the sinus through canine fossa or through middle meatal antrostomy.

Nakamura (Nakamura et al., 2004) reported endoscopic removal of displaced implant through a 10 x 10 mm window in the anterior sinus wall, using urological retrieval basket. Similar technique was described by Varol and colleagues in a series of 3 cases, except that curved hemostat was used for implant removal (Varol et al., 2006). Also, it was shown that endoscopic removal of implant from the sinus can be successfully combined with simultaneous sinus lift procedure (Ucer, 2009), facilitating future placement of a new implant. What is common for all these reports is that essentially conventional approach through canine fossa was used, but due to the use of endoscopes much smaller opening of the sinus wall had to be performed, compared to traditional Caldwell-Luc procedure.

Another possibility is to remove the implant by transnasal approach, usually through middle meatal antrostomy (Ramotar et al., 2010; Lubbe 2008). Such approach is particularly indicated if concomitant sinusitis is present, since it provides both an opportunity to remove displaced implant and to improve ventilation and drainage of affected sinus (Kim et al., 2007). Still, actual position of an implant has to be determined when decision regarding access through canine fossa or middle meatal antrostomy is to be made. In a case report from El Charkawi et al. (2005), it was shown that when an implant was in a more anterior and medial position in the maxillary sinus, transnasal access was unsuccessful so a Caldwell-Luc approach had to be used. Besides this, a clinician should have in mind that position of an implant within the sinus might change in a short period of time, so once appropriate radiographs are taken, surgery should not be delayed.

In a retrospective multi-center report of 27 patients with implants displaced into the sinus, Chiapasco proposed a treatment protocol based on presence of sinusitis and oroantral communication (OAC). In 17 patients who didn't have signs of sinusitis and in whom patency of the sinus ostium was preserved, intraoral approach through canine fossa was used for retrieval of implant and closure of OAC. In 6 patients who presented with maxillary sinusitis and obstruction of the sinus ostium, but without OAC, treatment consisted of partial uncinectomy, middle meatal antrostomy and removal of implant through enlarged ostium. Finally in 4 cases with sinusitis, ostium obstruction and oroantral communication, operative procedure comprised combined FESS and intraoral approach for closure of OAC by buccal advancement flap (Chiapasco et al., 2009).

It seems that in cases of sinus related complications in implantology, several factors have to be considered before the decision regarding the most suitable treatment option can be made. Chronic sinusitis with obstruction of the sinus ostium probably should be treated by FESS, and middle meatal antrostomy can be used for removal of foreign bodies, including implants and grafting material, as well. In situations with no or minimal signs of sinusitis and with preserved patency of the ostium, access via canine fossa is simple and effective for retrieval of displaced implants. When such an intervention is performed under the endoscopic control, it is possible to create significantly smaller bony window in the sinus wall, which should provide uneventful healing of the defect, without long-term effect on the corresponding sinus health. Finally, in a study from Aimeti and colleagues, it was shown that inferior meatal antrostomy and insertion of nasosinus tube might be useful in treatment of sinus lift complications (Aimeti et al, 2001).

5.2 Endoscopic surgery for sinus augmentation procedures

Reduction in height of residual alveolar ridge of posterior maxilla might be the result of either increased pneumatization of the upper jaw or pronounced resorption of alveolar process following tooth extraction. Whatever is the reason, such situation must be resolved before placement of implants is considered. Regarding this, several sinus augmentation techniques are used, comprising crestal or lateral approach to the sinus. Although these techniques are well established, use of endoscopes has a potential to further improve results of this procedures.

A prospective study on osteotome sinus floor elevation under the endoscopic control was published in 2002 (Nkenke et al., 2002). In 14 patients a total of 22 implants were placed and the endoscopes with view angles of 70, 90 and 120 degrees were inserted through the canine fossa. After sinus floor elevation with appropriate osteotomes, β -tricalcium phosphate or autogenous bone from the retromolar region were used for sinus augmentation. At a second stage surgery, 6 months after the implant placement, follow-up sinusoscopy was performed. Out of 22 implant sites, perforation on sinus membrane was noted in one case, which was immediately repaired by periosteal patch. In all patients postoperative course was uneventful, without signs of sinusitis. However, at a second stage surgery mobility of 2 implants was noted (in a same patient who had sinus perforation) and implants were removed, while control sinusoscopy revealed migration of grafting material into the sinus. Also, in one patient polyposis of antral mucosa was noted in control endoscopy, but the implants were stable and the patient was free of symptoms, so no further treatment was performed. Authors commented on complexity of procedure and extended length of surgery (average time of surgery was 67 minutes), so they concluded that such approach is more of scientific than clinical interest.

Berengo and colleagues reported results of endoscopic controlled osteotome sinus floor elevation in 8 patients in whom 16 Osseotite implants were placed (Berengo et al., 2004). Endoscopes were introduced through a 4 mm diameter opening in the canine fossa and BioOss® particles were used for sinus augmentation. Lacerations of sinus membrane with minimal displacement of grafting material were noted in 2 cases. Authors commented on pattern of sinus membrane distension and concluded that it is possible that mucosal lacerations are more likely to occur when detachment of sinus membrane is confined to the small area around the implant site in contrast to situations when mucosa is elevated on the broader base. It is important that after a 14 months follow-up period all implants were

considered to be successful, including two cases in whom membrane lacerations had occurred. Also, no signs of sinusitis were noted in these cases.

Apart from endoscope-controlled osteotome sinus lift procedure, a technique of minimally invasive lateral-window sinus augmentation was described by Engelke and colleagues (Engelke & Deckwer, 1997; Engelke et al., 2003). Basically, surgical technique comprised only a small 5 mm-diameter osteotomy at the lateral sinus wall, through which elevation of sinus membrane and placement of augmentation material was performed under the control of a 2,7 mm-diameter endoscope. A total of 118 sinus augmentations were performed in 83 patients and 211 implants were placed, most of them simultaneously with augmentation procedure. Perforation of sinus membrane was noted in 28 cases, which were repaired immediately using polyglactine mesh except of 1 case with large perforation, who required second surgical intervention. Postoperatively, one case of wound dehiscence was noted, resulting in creation of oroantral fistula and concomitant sinusitis. Out of 211 implants, 11 implants were lost, most of them before the prosthetic loading (Engelke et al., 2003). Same author (Engelke & Capobianco, 2005) described technique of flapless sinus augmentation and simultaneous implant placement using three-dimensional surgical template. Twenty one implants were placed in six patients using this approach. One case of sinus perforation was noted and out of 21 implants one failure occurred during the healing period.

Based on pertinent literature, it seems that endoscope-controlled sinus augmentation yields similarly good results compared to conventional approach. However, need for expensive equipment and prolonged time of surgery are the factors that have to be considered when discussing this issue. Also, regarding minimally invasive lateral window augmentation, prospective study comparing this technique to the traditional surgical procedure will be necessary before its clinical use can be recommended.

6. Conclusion

Functional endoscopic sinus surgery for treatment of odontogenic sinusitis seems as a safe and predictable treatment option. Although scientific evidence is low (since there are not any studies comparing FESS to other treatment possibilities), this is a clinically well documented procedure with low incidence of complications. Also, it has to be noted that criteria for selection of optimal treatment modality for specific clinical situations are not established. Regarding this, FESS might be particularly indicated in cases of odontogenic sinusitis with severe ethmoidal inflammation and/or obstruction of sinus ostium. On the other hand, if patency of osteomeatal complex is preserved, which is not a rarity with odontogenic sinusitis, it is questionable if middle meatal antrostomy is of any benefit for the patient. Still, available scientific data are not sufficient to answer these questions.

In contrast to odontogenic sinusitis, endoscopic surgery for odontogenic cysts and tumors is documented only in limited case series reports, so at this moment it is difficult to discuss possible advantages and shortcomings of such procedures. However, it is clear that endoscope-assisted removal of these lesions should provide better visualization of the surgical field which is very important for prevention of recurrences. Until more scientific data are available, traditional treatment options with endoscopic control of poorly visualized regions (such is postero-inferior part of the sinus) can be recommended.

Also, regarding treatment of implant-related complications involving the maxillary sinus, endoscopic surgery has a potential to provide effective treatment of those cases, similarly to treatment of odontogenic sinusitis of non-implant etiology. On the other hand, endoscopic

sinus augmentation needs scientific evidence of superiority to conventional techniques before it can be introduced into clinical practice.

7. Acknowledgment

This work was supported by grant no. 175021 from The Ministry of science of Republic of Serbia.

8. References

- Aimetti, M., Romagnoli, R., Ricci, G. & Massei, G. (2001). Maxillary sinus elevation: the effect of macrolacerations and microlacerations of the sinus membrane as determined by endoscopy. *The International journal of periodontics & restorative dentistry*, Vol.21, No.6, (December 2001), pp. 581-589, ISSN 0198-7569
- Akao, I., Ohashi, T., Imokawa, H., Otsuka, T., Taguchi, Y. & Takagi, M. (2003). Cementifying fibroma in the ethmoidal sinus extending to the anterior cranial base in an 11-year-old girl: a case report. *Auris Nasus Larynx*, Vol.30, Suppl.1, (15 February 2003), pp. 123-126, ISSN 0385-8146
- Al-Belasy, FA. (2004). Inferior meatal antrostomy: is it necessary after radical sinus surgery through the Caldwell-Luc approach? *Journal of oral and maxillofacial surgery : official journal of the American Association of Oral and Maxillofacial Surgeons* Vol.62, No.5, (May 2004), pp. 559-562, ISSN 0278-2391
- Albu, S. & Bacut, M. (2010). Failures in endoscopic surgery of the maxillary sinus. *Otolaryngology--head and neck surgery: official journal of American Academy of Otolaryngology-Head and Neck Surgery*, Vol.142, No.2, (February 2010), pp. 196-201, ISSN 0194-5998
- Albu, S., Gocea, A. & Necula, S. (2011). Simultaneous inferior and middle meatus antrostomies in the treatment of the severely diseased maxillary sinus. *American journal of rhinology & allergy*. Vol.25, No.2, (March/April 2011), pp. e80-e85(6), ISSN 1945-8924
- Andric, M. (2010). Endoscopic surgery of the maxillary sinuses in oral and maxillofacial surgery practice: a literature review. *Hellenic Archives of Oral & Maxillofacial Surgery*, Vol.2, No.2, (August 2010), pp. 57-68, ISSN 1108-829 X
- Andric, M., Saranovic, V., Drazic, R., Brkovic, B. & Todorovic L. (2010). Functional endoscopic sinus surgery as an adjunctive treatment for closure of oroantral fistulae: a retrospective analysis. *Oral surgery, oral medicine, oral pathology, oral radiology, and endodontics*, Vol.109, No.4, (April 2010), pp. 510-516. ISSN 1079-2104
- Berengo, M., Sivoilella, S., Majzoub, Z. & Cordioli, G. (2004). Endoscopic evaluation of the bone-added osteotome sinus floor elevation procedure. *International journal of oral and maxillofacial surgery*, Vol.33, No.2, (March 2004), pp. 189-194, ISSN 0901-5027
- Bray, D., Michael, A., Falconer, DT & Kaddour, HS. (2007). Ameloblastoma: a rare nasal polyp. *The Journal of laryngology and otology*, Vol.121, No.1, (January 2007), pp. 72-75, ISSN 0022-2151
- Brook I. (2006). Sinusitis of odontogenic origin. *Otolaryngology--head and neck surgery: official journal of American Academy of Otolaryngology-Head and Neck Surgery*, Vol.135, No.3, (September 2006), pp. 349-355, ISSN 0194-5998


- Busaba, NY. & Kieff, D. (2002). Endoscopic sinus surgery for inflammatory maxillary sinus disease. *Laryngoscope*, Vol.112, No.8, (August 2002), pp. 1378-1383. ISSN 0023-852X
- Cansiz, H., Tuskan, K., Karaman, E. & DervisoÄYlu, S. (2004). Endoscope assisted removal of cementoossifying fibroma in the paranasal sinuses in a five-year-old girl. *International journal of pediatric otorhinolaryngology*, Vol.68, No.4, (April 2004), pp. 489-493, ISSN 0165-5876
- Car, M. & Juretić, M. (1998) Treatment of oroantral communications after tooth extraction. Is drainage into the nose necessary or not? *Acta oto-laryngologica*, Vol.118, No.6, (November 1998), pp. 844-846. ISSN 0001-6489
- Carlson, ER. & Marx, RE. (2006). The ameloblastoma: primary, curative surgical management. *Journal of oral and maxillofacial surgery: official journal of the American Association of Oral and Maxillofacial Surgeons*, Vol.64, No.3, (March 2006), pp. 484-494, ISSN 0278-2391
- Cascone P., Ungari, C., Filiaci, F., Gabriele, G. & Ramieri, V. (2010). A dental implant in the anterior cranial fossae. *International journal of oral and maxillofacial surgery*, Vol.39, No.1, (January 2010), pp. 92-93, ISSN 0901-5027
- Chiapasco, M., Felisati, G., Maccari, A., Borloni, R., Gatti, F. & Di Leo, F. (2009). The management of complications following displacement of oral implants in the paranasal sinuses: a multicenter clinical report and proposed treatment protocols. *International journal of oral and maxillofacial surgery*, Vol.38, No.12, (December 2009), pp. 1273-1278, ISSN 0901-5027
- Chiu, AG. & Kennedy, DW. (2004) Surgical management of chronic rhinosinusitis and nasal polyposis: a review of the evidence. *Current allergy and asthma reports*, Vol.4, No.6, (November 2004), pp. 486-489, ISSN 1529-7322
- Christmas DA, Mirante JP, Yanagisawa E. (2008). Endoscopic view of a maxillary dentigerous cyst. *Ear, nose, & throat journal*, Vol.87, No.6, (June 2008), pp. 316, ISSN 0145-5613
- Coleman, JR Jr. & Duncavage, JA. (1996). Extended middle meatal antrostomy: the treatment of circular flow. *Laryngoscope*, 1996; Vol.106, No.10, (October 1996), pp. 1214-1217, ISSN 0023-852X
- Costa, F., Emanuelli, E., Robiony, M., Zerman, N., Polini, F. & Politi, M. (2007). Endoscopic surgical treatment of chronic maxillary sinusitis of dental origin. *Journal of oral and maxillofacial surgery: official journal of the American Association of Oral and Maxillofacial Surgeons*, Vol.65, No.2, (February 2007), pp. 223-228. ISSN 0278-2391
- DeFreitas, J. & Lucente, FE. (1988). The Caldwell-Luc procedure: institutional review of 670 cases: 1975-1985. *Laryngoscope*, Vol.98, No.12, (December 1988), pp. 1297-1300, ISSN 0023-852X
- Di Pasquale, P. & Shermetaro, C. (2006). Endoscopic removal of a dentigerous cyst producing unilateral maxillary sinus opacification on computed tomography. *Ear, nose, & throat journal*, Vol.85, No.11, (November 2006), pp. 747-748, ISSN 0145-5613
- Dolanmaz, D., Tuz, H., Bayraktar, S., Metin, M., Erdem, E. & Baykul, T. (2004). Use of pedicled buccal fat pad in the closure of oroantral communication: analysis of 75 cases. *Quintessence international*, Vol. 35, No.3, (March 2004), pp. 241-246, ISSN 0033-6572
- Eberhart, LH., Kussin, A., Arndt, C., Lange, H., Folz, BJ., Werner, JA., Wulf H. & Kill, C. (2007). Effect of a balanced anaesthetic technique using desflurane and remifentanyl

- on surgical conditions during microscopic and endoscopic sinus surgery. *Rhinology*, Vol.45, No.1, (March 2007), pp. 72-78, ISSN 0300-0729
- El Charkawi, HG., El Askary, AS & Ragab, A (2005). Endoscopic removal of an implant from the maxillary sinus: a case report. *Implant dentistry*, Vol.14, No.1, (March 2005), pp. 30-35, ISSN 1056-6163
- Engelke, W. & Capobianco, M. (2005). Flapless sinus floor augmentation using endoscopy combined with CT scan-designed surgical templates: method and report of 6 consecutive cases. *The International journal of oral & maxillofacial implants*, Vol.20, No.6, (November - December 2005), pp. 891-897, ISSN 0882-2786
- Engelke, W. & Deckwer, I. (1997). Endoscopically controlled sinus floor augmentation. A preliminary report. *Clinical oral implants research*, Vol.8, No.6, (December 1997), pp. 527-531, ISSN 0905-7161
- Engelke, W., Schwarzwäller, W., Behnsen, A. & Jacobs, HG. (2003). Subantoscopic laterobasal sinus floor augmentation (SALSA): an up-to-5-year clinical study. *The International journal of oral & maxillofacial implants*, Vol.18, No.1, (January - February 2003), pp. 135-143, ISSN 0882-2786
- Felisati, G., Lozza, P., Chiapasco, M. & Borloni, R. (2007). Endoscopic removal of an unusual foreign body in the sphenoid sinus: an oral implant. *Clinical oral implants research*, 2007; Vol.18, No.6, (December 2007), pp. 776-780, ISSN 0905-7161
- Ghali, GE. & Connor, MS. (2003). Surgical management of the odontogenic keratocyst. *Oral and maxillofacial surgery clinics of North America*, Vol.15, No.3, (August 2003), pp. 383-392. ISSN 1042-3699
- Griffa A., Viterbo, S. & Boffano, P. (2010). Endoscopic-assisted removal of an intraorbital dislocated dental implant. *Clinical oral implants research*, Vol.21, No.7, (July 2010), pp. 778-780, ISSN 0905-7161
- Güven O. (1998). A clinical study on oroantral fistulae. *Journal of cranio-maxillofacial surgery*, Vol.26, No.4, (August 1998), pp. 267-271, ISSN 1010-5182
- Hajjiioannou, J., Koudounarakis, E., Alexopoulos, K., Kotsani, A. & Kyrmizakis, DE. (2010). Maxillary sinusitis of dental origin due to oroantral fistula, treated by endoscopic sinus surgery and primary fistula closure. *The Journal of laryngology and otology*, Vol.124, No.9, (September 2010), pp. 986-989, ISSN 0022-2151
- Hasbini, AS., Hadi, U. & Ghafari, J. (2001). Endoscopic removal of an ectopic third molar obstructing the osteomeatal complex. *Ear, nose, & throat journal*, Vol.80, No.9, (September 2001), pp. 667-670. ISSN 0145-5613
- Ikeda, K., Hirano, K., Oshima, T., Shimomura, A., Suzuki, H., Sunose, H., Kondo, Y. & Takasaka, T. (1996). Comparison of complications between endoscopic sinus surgery and Caldwell-Luc operation. *The Tohoku journal of experimental medicine*, Vol.180, No.1, (September 1996), pp. 27-31, ISSN 0040-8727
- Kennedy, DW. & Shaalan, H. (1989). Reevaluation of maxillary sinus surgery: experimental study in rabbits. *The Annals of otology, rhinology, and laryngology*, Vol.98, No.11, (November 1989), pp. 901-906, ISSN 0003-489
- Kennedy, DW. (1985). Functional endoscopic sinus surgery: technique. *Archives of otolaryngology*, Vol.111, No.10, (October 1985), pp. 643-649. ISSN 0003-9977
- Kim, JW., Lee, CH., Kwon, TK. & Kim, DK. (2007). Endoscopic removal of a dental implant through a middle meatal antrostomy. *The British journal of oral & maxillofacial surgery*, Vol.45, No.5, (July 2007), pp. 408-409, ISSN 0266-4356

- Kitamura A. (2007). Removal of a migrated dental implant from a maxillary sinus by transnasal endoscopy. *The British journal of oral & maxillofacial surgery*, Vol.45, No.5, (July 2007), pp. 410-411, ISSN 0266-4356
- Lamb, JF., Husein, OF. & Spiess, AC. (2009). Ectopic molar in the maxillary sinus precipitating a mucocele: a case report and literature review. *Ear, nose, & throat journal*, Vol.88, No.8, (August 2009), pp. E6-E11, ISSN 0145-5613
- Lee, KC. & Lee, SJ. (2010). Clinical Features and Treatments of Odontogenic Sinusitis, *Yonsei Medical Journal*, Vol.51, No.6, (November 2010), pp. 932-937. ISSN 0513-5796
- Leong, SC., Karkos, PD., Krajacevic, J., Islam, R. & Kent, SE. (2010). Ameloblastoma of the sinonasal tract: A case report. *Ear, nose, & throat journal*, Vol.89, No.2, (February 2010), pp. 70-71, ISSN 0145-5613
- London, SD., Schlosser, RJ. & Gross, CW. (2002). Endoscopic management of benign sinonasal tumors: a decade of experience. *American journal of rhinology*, Vol.16, No.4, (July - August 2002), pp. 221-227, ISSN 1050-6586
- Lopatin, AS. & Kapitanov, DN. (2005). Endonasal removal of a large ethmoidal cementoblastoma. *Rhinology*, Vol.43, No.2, (June 2005), pp. 156-158, ISSN 0300-0729
- Lopatin, AS., Sysolyatin, SP., Sysolyatin, PG. & Melnikov, MN. (2002). Chronic maxillary sinusitis of dental origin: is external surgical approach mandatory? *Laryngoscope*, Vol.112, No.6, (June 2002), pp. 1056-1059, ISSN 0023-852X
- Lubbe, DE., Aniruth, S., Peck, T. & Liebenberg, S. (2008). Endoscopic transnasal removal of migrated dental implants. *British dental journal*, Vol.204, No.8, (April 26th, 2008), pp. 435-436, ISSN 0007-0610
- McMains, KC. (2008). Safety in endoscopic sinus surgery. *Current opinion in otolaryngology & head and neck surgery*, Vol.16, No.3, (June 2008), pp. 247-251. ISSN 1068-9508
- Mehra, P. & Murad, H. (2004). Maxillary sinus disease of odontogenic origin. *Otolaryngologic clinics of North America*, Vol.37, No.2, (April 2004), pp. 347-364, ISSN 030-6665
- Micozkadioglu, SD & Erkan, AN. (2007). Endoscopic removal of a maxillary dentigerous cyst. *B-ENT*, Vol.3, No.4, pp.213-216. ISSN 1781-782X
- Nakamura, N., Mitsuyasu, T. & Ohishi, M. (2004). Endoscopic removal of a dental implant displaced into the maxillary sinus: technical note. *International journal of oral and maxillofacial surgery*, Vol.33, No.2, (March 2004), pp. 195-197, ISSN 0901-5027
- Nemec, SF., Peloschek, P., Koelblinger, C., Mehra, S., Krestan, CR. & Czerny, C. (2009). Sinonasal imaging after Caldwell-Luc surgery: MDCT findings of an abandoned procedure in times of functional endoscopic sinus surgery. *European Journal of Radiology*, Vol.70, No.1, (April 2009), pp. 31-34, ISSN 0720-048X
- Nkenke, E., Schlegel, A., Schultze-Mosgau, S., Neukam, FW. & Wiltfang, J. (2002). The endoscopically controlled osteotome sinus floor elevation: a preliminary prospective study. *The International journal of oral & maxillofacial implants*, Vol.17, No.4, (July - August 2002), pp. 557-566, ISSN 0882-2786
- Ramotar, H., Jaberoo, MC., Koo Ng, NK., Pulido, MA. & Saleh, HA. (2010). Image-guided, endoscopic removal of migrated titanium dental implants from maxillary sinus: two cases. *The Journal of laryngology and otology*, Vol.124, No.4, (April 2010), pp. 433-436, ISSN 0022-2151
- Stammler, H. (1986). Endoscopic endonasal surgery--concepts in treatment of recurring rhinosinusitis. Part II. Surgical technique. *Otolaryngology--head and neck surgery*:

- official journal of American Academy of Otolaryngology-Head and Neck Surgery*, Vol.94, No.2, (February 1986), pp. 147-156. ISSN 0194-5998
- Ucer, TC. (2009). A modified transantral endoscopic technique for the removal of a displaced dental implant from the maxillary sinus followed by simultaneous sinus grafting. *The International journal of oral & maxillofacial implants*, Vol.24, No.5, (September - October 2009), pp. 947-951, ISSN 0882-2786
- Varol, A., Türker, N., Göker, K. & Basa, S. (2006). Endoscopic retrieval of dental implants from the maxillary sinus. *The International journal of oral & maxillofacial implants*, Vol.21, No.5, (September - October 2006), pp. 801-804. ISSN 0882-2786
- Yilmaz, T., Suslu, AE. & Gursel, B. (2003). Treatment of oroantral fistula: experience with 27 cases. *American journal of otolaryngology*, Vol.24, No.4, (July - August 2003), pp. 221-223. ISSN 0196-0709
- Zimble, MS., Lebowitz, RA., Glickman, R., Brecht, LE. & Jacobs, JB. (1998). Antral augmentation, osseointegration, and sinusitis: the otolaryngologist's perspective. *American journal of rhinology*, Vol.12, No.5, (September - October 1998) , pp. 311-316, ISSN 1050-6586

IntechOpen



Advances in Endoscopic Surgery

Edited by Prof. Cornel Iancu

ISBN 978-953-307-717-8

Hard cover, 444 pages

Publisher InTech

Published online 25, November, 2011

Published in print edition November, 2011

Surgeons from various domains have become fascinated by endoscopy with its very low complications rates, high diagnostic yields and the possibility to perform a large variety of therapeutic procedures. Therefore during the last 30 years, the number and diversity of surgical endoscopic procedures has advanced with many new methods for both diagnoses and treatment, and these achievements are presented in this book. Contributing to the development of endoscopic surgery from all over the world, this is a modern, educational, and engrossing publication precisely presenting the most recent development in the field. New technologies are described in detail and all aspects of both standard and advanced endoscopic maneuvers applied in gastroenterology, urogynecology, otorhinolaryngology, pediatrics and neurology are presented. The intended audience for this book includes surgeons from various specialities, radiologists, internists, and subspecialists.

How to reference

In order to correctly reference this scholarly work, feel free to copy and paste the following:

Miroslav Andrić (2011). Endoscopic Surgery of Maxillary Sinuses in Oral Surgery and Implantology, *Advances in Endoscopic Surgery*, Prof. Cornel Iancu (Ed.), ISBN: 978-953-307-717-8, InTech, Available from: <http://www.intechopen.com/books/advances-in-endoscopic-surgery/endoscopic-surgery-of-maxillary-sinuses-in-oral-surgery-and-implantology>

INTECH
open science | open minds

InTech Europe

University Campus STeP Ri
Slavka Krautzeka 83/A
51000 Rijeka, Croatia
Phone: +385 (51) 770 447
Fax: +385 (51) 686 166
www.intechopen.com

InTech China

Unit 405, Office Block, Hotel Equatorial Shanghai
No.65, Yan An Road (West), Shanghai, 200040, China
中国上海市延安西路65号上海国际贵都大饭店办公楼405单元
Phone: +86-21-62489820
Fax: +86-21-62489821

© 2011 The Author(s). Licensee IntechOpen. This is an open access article distributed under the terms of the [Creative Commons Attribution 3.0 License](#), which permits unrestricted use, distribution, and reproduction in any medium, provided the original work is properly cited.

IntechOpen

IntechOpen