

# We are IntechOpen, the world's leading publisher of Open Access books Built by scientists, for scientists

## 4,800

Open access books available

## 122,000

International authors and editors

## 135M

Downloads

Our authors are among the

## 154

Countries delivered to

## TOP 1%

most cited scientists

## 12.2%

Contributors from top 500 universities

**WEB OF SCIENCE™**Selection of our books indexed in the Book Citation Index  
in Web of Science™ Core Collection (BKCI)

Interested in publishing with us?  
Contact [book.department@intechopen.com](mailto:book.department@intechopen.com)

Numbers displayed above are based on latest data collected.  
For more information visit [www.intechopen.com](http://www.intechopen.com)



# Novel Phenotypes in Bicuspid Aortic Valve Disease

Evaldas Girdauskas<sup>1</sup>, Michael A. Borger<sup>2</sup> and Thomas Kuntze<sup>1</sup>

<sup>1</sup>Zentralklinik Bad Berka

<sup>2</sup>Heart Centre Leipzig, University Leipzig  
Germany

## 1. Introduction

Bicuspid aortic valve (BAV) is the most common congenital abnormality of the human heart, affecting approximately 1-2% of the general population (Williams, 2006). It is widely accepted that BAV is a very heterogeneous disease and that the different phenotypes of BAV disease may be caused by unique pathogenetic mechanisms. Because the heterogeneous nature of BAV disease has been recognized by many researchers, attempts have been made to stratify the most common anatomic-clinical forms.

The clinically observed linkage between specific BAV morphology and the associated lesions of the proximal aorta has recently led to several phenotypic classifications which incorporate both valve and proximal aortic anatomy. These different BAV phenotypes may be caused by unique pathogenetic mechanisms and may require different therapeutic approaches. The clarification of this phenomenon will undoubtedly affect the individual treatment strategy of BAV disease.

In the face of these novel findings, this chapter deals with recent controversies in BAV disease.

## 2. Phenotypes in BAV disease

The recently identified BAV phenotypes incorporate specific aortic valve anatomy (or a predominant type of aortic valve dysfunction) and concomitant lesions of the proximal aorta. To begin with, these empirical observations were based on the surgical and echocardiographic findings of an association between specific BAV disease and concomitant lesions of aortic root, ascending aorta, or both. Configuration of the proximal aorta is undoubtedly different in patients with BAV stenosis versus BAV insufficiency. Moreover, there are apparently distinct forms of proximal aortic lesions in patients with fusion of right coronary and left coronary cusps versus fusion of right coronary and non-coronary cusps in BAV disease.

These specific associations of BAV anatomy and proximal aortic disease have been analyzed by a large number of *in vitro*, rheological and biomolecular investigations. These novel BAV phenotypes and the corresponding fundamental research articles will be addressed in detail in the following paragraphs.

## 2.1 BAV stenosis versus BAV insufficiency

The strong correlation between specific aortic dilatation patterns and the functional status of BAV (i.e., BAV stenosis versus insufficiency) has been demonstrated by some investigators based on the empirical analysis of clinical data. In particular, the presence of BAV stenosis is typically associated with asymmetrical dilatation of the mid-ascending aorta and a nearly normal aortic root diameter (Cotrufo & Della Corte, 2009). In contrast, aortic root dilatation is more often associated with a concomitant or consequent BAV insufficiency (i.e., root dilatation phenotype).

Different pathogenetic mechanisms have been proposed for those two apparently different BAV phenotypes (Cotrufo & Della Corte, 2009). Importantly, significant differences in the expression and spatial distribution of extracellular matrix (ECM) proteins have been found between these two subgroups of BAV disease (i.e., aortic valve stenosis versus insufficiency). Both BAV phenotypes have been linked to the specific patient's characteristics and will be discussed in detail.

### 2.1.1 BAV stenosis with an asymmetric mid-ascending aortic dilatation

This most common anatomical-clinical BAV phenotype includes stenosis of the BAV, an unaffected or only mildly dilated aortic root, and an asymmetric dilatation of the mid-ascending aorta, starting from the sinotubular junction and involving mostly the convexity (i.e., the greater curvature) of the vessel (Fig. 1). The association between BAV stenosis and asymmetric mid-ascending aortic dilatation has been proposed to be pathogenetic (Della Corte *et al.*, 2007).

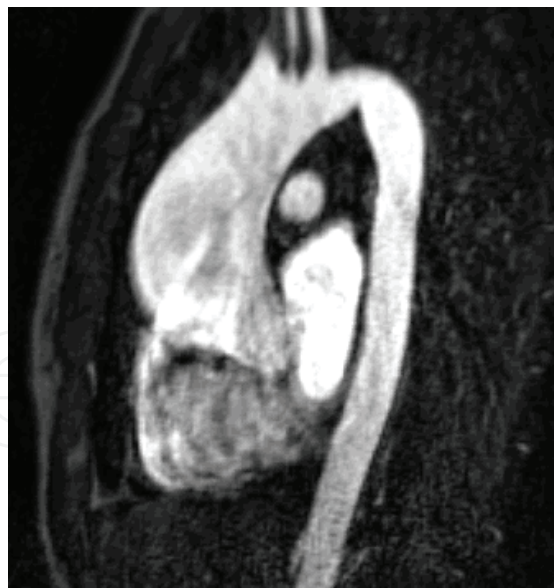

Fig. 1. Magnetic resonance imaging demonstrating an asymmetric mid-ascending aortic aneurysm in a patient with BAV stenosis

It has been proved that stenosis of the BAV, which is geometrically asymmetrical, produces an eccentric turbulent transvalvular blood flow that results in asymmetrical wall stress distribution in the ascending aorta (Fig. 2) (Robicsek *et al.*, 2004). It has been hypothesized that this uneven wall stress distribution may be important in promoting early localized

aortic wall changes, which may lead subsequently to an asymmetric ascending aortic dilatation. These flow-dependant changes in the microstructure of the vessel wall are known as a *flow-induced vascular remodeling* (Lehoux *et al.*, 2002).

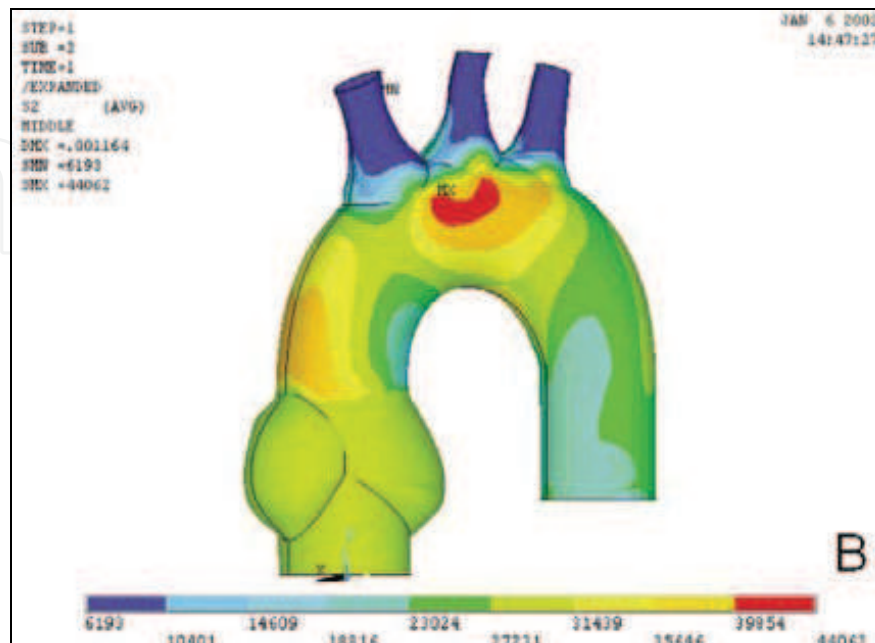


Fig. 2. Stress patterns in the proximal aorta in the setting of an eccentric BAV. The red and yellowish brown segments of the proximal aorta are the most stressed by the eccentric transvalvular blood flow; the blue segments are the least stressed (published in *Annals of Thoracic Surgery* 2004; 77:177-185)

According to these data, this pathogenetically linked anatomical-clinical BAV phenotype (i.e., BAV stenosis with an asymmetric mid-ascending aortic dilatation) may represent the predominantly hemodynamically triggered form of BAV aortopathy. In compliance with these findings, some most recent *in vitro* and *in vivo* studies provide further evidence of the hemodynamic nature of this BAV phenotype.

#### 2.1.1.1 Correlation between BAV stenosis and the extent of mid-ascending aortic dilatation

Given the marked heterogeneity of BAV disease and the co-existence of different clinical-anatomical phenotypes, the data on the correlation between the type of BAV dysfunction and the extent of proximal aortic dilatation are very controversial. However, when the analysis has been focused on the mid-ascending aortic dilatation form alone, a strong correlation has been found between the degree of BAV stenosis and the extent of ascending aortic dilatation at maximum diameter (Della Corte *et al.*, 2007).

Similar findings have been recently reported by some other investigators (Davies *et al.*, 2007). These authors were able to clearly demonstrate a strong association between the presence of aortic valve stenosis and all adverse aortic events in the BAV subgroup. Moreover, a significant correlation has been demonstrated most recently between the degree of eccentricity of the systolic transvalvular flow through the BAV and the severity of the proximal aortic dilatation in the pediatric BAV subpopulation (i.e., the larger the angle of misdirected blood flow with the aortic axis, the larger the proximal aortic diameter) (den

Reijer *et al.*, 2010). These correlations were most significant at the more distal level of the ascending aorta, where aortic wall stress is expectedly highest.

These results favour the hemodynamic hypothesis of BAV-associated aortopathy (i.e. abnormal blood flow patterns induced by BAV stenosis are directly involved in the development of ascending aortic dilatation).

### 2.1.1.2 Functioning of the “clinically normal” BAV

There is emerging evidence that the “clinically normal” BAV (i.e., one without a quantitatively detectable transvalvular pressure gradient by continuous-wave Doppler methods of grading) is morphologically stenotic and is associated with an abnormal eccentric systolic transvalvular flow, which results in asymmetrical wall stress distribution in the ascending aorta (Robicsek *et al.*, 2004).

This has been recently demonstrated in a sophisticated mathematical analysis, using a dynamic three-dimensional (3D) finite element model of the bicuspid aortic root (Conti *et al.*, 2010). These investigators were able to convincingly demonstrate that the mere fusion of the two aortic valve cusps restricts the opening motion of the conjoined cusp, which causes subclinical BAV stenosis. Moreover, the longitudinal stress at the convexity of the ascending aorta has been found to be increased by 36% in BAV versus the tricuspid aortic valve (TAV) aortic root finite element model.

The *in vitro* data have been supported most recently by an *in vivo* analysis of systolic transvalvular flow in BAV patients using sophisticated four-dimensional magnetic resonance imaging (MRI) (Hope *et al.*, 2010). The authors of this study demonstrated convincingly a nested helical systolic flow pattern in the proximal aorta in patients with BAV, including those without ascending aortic dilatation or significant BAV stenosis (Fig. 3). These abnormal systolic transvalvular flow patterns were shown to be different and unique for the two most common cusp fusion types in patients with BAV.

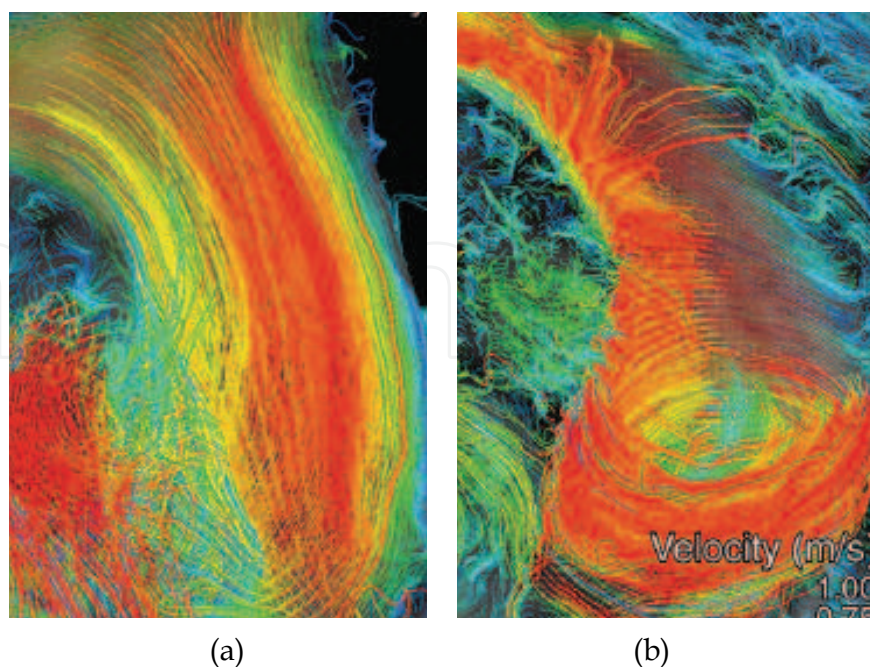


Fig. 3. Systolic transvalvular flow patterns in the proximal aorta in a patient with TAV (a) and BAV (b) (published in *Radiology* 2010; 77:177-185)

All above-mentioned studies clearly indicate that the eccentric opening of “clinically normal” BAV is enough to generate significant flow disturbances downstream (e.g., turbulence, vortices, nested helical flow patterns, asymmetrically arranged flow), which may induce permanent mechanical stimuli to the ascending aortic wall, and, subsequently, asymmetric aortic dilation.

### 2.1.1.3 Asymmetric pattern of aortopathy in BAV disease

The concept of asymmetry in ascending aortic disease was first introduced by Cotrufo *et al.* (2001). This was based on the empirical macroscopic surgical observations of asymmetric ascending aortic aneurysms propagating from the right anterolateral aortic wall (i.e., convexity or a greater curvature).

The enlargement of the tubular mid-ascending aorta in patients with BAV disease has a typical asymmetric configuration at the convexity of the vessel, as shown in the retrospective analysis of aortic angiograms (Bauer *et al.*, 2006). Moreover, the distance between the aortic valve level and the level of the maximal ascending aortic diameter was found to be greater in BAV patients versus TAV patients.

The asymmetric pattern of the ascending aortic wall alterations has been confirmed by a series of consecutive histological and biomolecular investigations by Cotrufo *et al.* (2005). Consecutive studies have shown an asymmetric spatial pattern of extracellular matrix (ECM) protein expression and smooth muscle cell (SMC) changes in the convexity versus the concavity of the dilated ascending aorta in BAV patients (Cotrufo *et al.*, 2005; Della Corte *et al.*, 2006, 2008). Moreover, this asymmetric pattern of microstructural aortic wall changes has been found in non-dilated aortas in the setting of BAV stenosis.

This proven asymmetry of BAV aortopathy, which may be interpreted as a result of aortic wall stress-induced vascular remodeling, lends more credence to the hemodynamic nature of BAV stenosis-associated aortopathy.

In conclusion, the identified predominant anatomical-clinical BAV phenotype of BAV stenosis with an asymmetric mid-ascending aortic dilatation may include those patients in whom the hemodynamic factors play a determinant role.

### 2.1.2 BAV insufficiency with a dilatation of aortic root (root dilatation phenotype)

There is a relatively small subset of BAV patients (10-15%), who present with the predominant aortic root dilatation at the level of aortic annulus and the sinuses of Valsalva. This form of proximal aortic dilatation is commonly associated with a varying degree of concomitant or consequent aortic valve insufficiency. This relatively rare clinical-anatomical form of BAV disease has been described in the literature as a “root dilatation phenotype” (Della Corte *et al.*, 2007) (Fig. 4).

The prevalence of the root phenotype does not increase with age (it occurs primarily in the young BAV population) and shows a strong predilection for the male gender. It has been hypothesized, that this phenotype may be subtended by a less flow-dependent mechanism of aortic wall failure than is asymmetric mid-ascending aortic dilatation, and that it may coexist with every possible degree of aortic valve dysfunction. It has also been proposed that the root dilatation phenotype may be a purely genetic form of BAV disease and a completely different disease from BAV stenosis and asymmetric mid-ascending aortic dilatation (Cotrufo & Della Corte, 2009).

A subgroup of young male BAV patients with the predominant aortic dilatation at the level of the aortic root that occurred independently of age, body size, and aortic valve function has been also prospectively identified in an echocardiographic study (Nistri *et al.*, 1999). The authors of this report hypothesized that there may be a subgroup of BAV patients who are affected by the congenital weakness of the aortic wall structure that causes premature aortic root dilatation, independent of any hemodynamic perturbations.

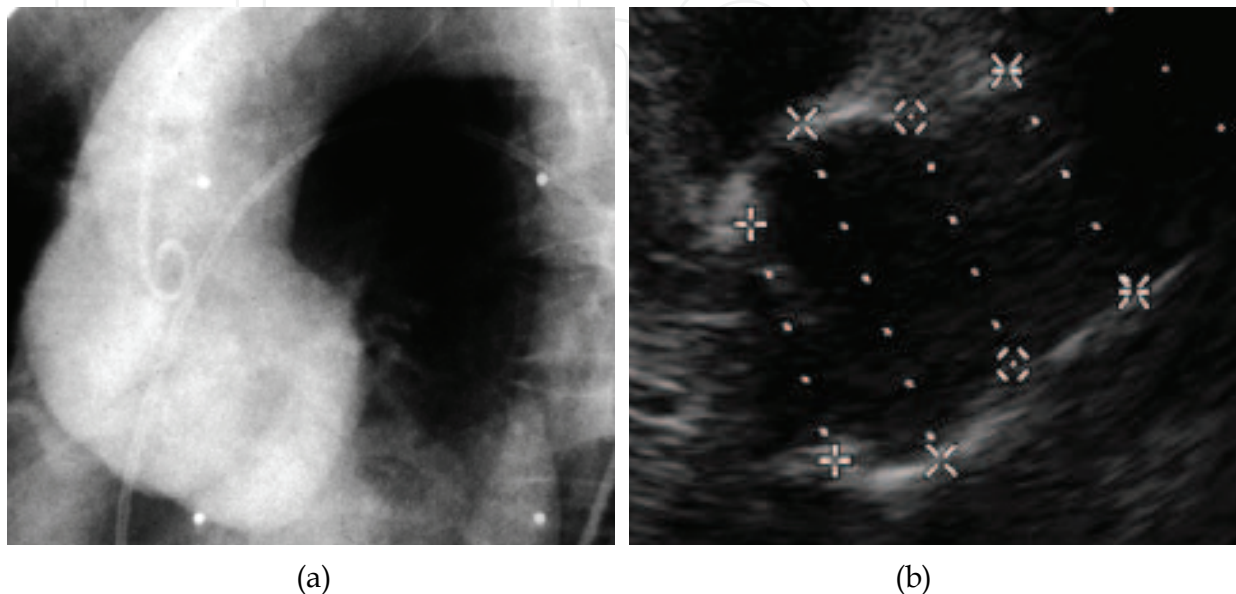


Fig. 4. Images of aortic angiography (a) and transthoracic echocardiography (b) in BAV patient with a “root phenotype”

Although the genetic nature of the root dilatation phenotype has been postulated by all the above-mentioned studies, no specific gene defect responsible for this type of BAV disease has been ever identified. Moreover, there is a notable paucity of clinical and biomolecular data on the BAV subgroup with a “root phenotype”.

Nonetheless, some important indices of the genetic origin of this clinical-anatomical form of BAV disease may be identified in the recent literature and will be discussed in detail as follows.

#### 2.1.2.1 Evidence of the genetic nature of the root dilatation phenotype

A recent study by Loscalzo *et al.* (2007) analyzed a small number of selected families with a high prevalence of BAV disease and familial thoracic aortic aneurysms (TAA). Based on the genetic analysis of thirteen affected families, the authors concluded that BAV and familial thoracic aortic aneurysms are variably penetrant independent manifestations of a single gene defect which may be associated with a wide spectrum of left outflow tract disorders.

However, only fifteen family members of the analyzed probands (13%) had BAV in this study and only ten of them (9%) had a concomitant thoracic aortic aneurysm (i.e., the study included only a small subgroup of patients with a combined BAV/TAA phenotype). Moreover, three patients in the BAV/TAA subgroup had a significant aortic valve dysfunction (i.e., moderate or greater valve insufficiency or stenosis). Therefore, conclusions should be only cautiously drawn from such a limited number of affected patients.

The recently published echocardiographic study by Biner *et al.* (2009) focused on aortopathy in first-degree relatives of BAV patients. Unfortunately, this study included only a small proportion of first-degree relatives of BAV patients (i.e., 48 relatives of 54 BAV patients) and compared them with a highly selective control group (i.e., 45 healthy individuals without structural heart disease, who were included during a study period of 4 years). Irrespective of those methodological flaws, this study has demonstrated a high prevalence of mild aortic root dilatation, which was associated with abnormal elastic properties of proximal aorta in the first-degree relatives of BAV patients. Notably, this series included predominantly BAV patients with aortic dilatation at the level of aortic annulus and sinuses of Valsalva (i.e., the root dilatation phenotype of BAV disease).

We reported most recently on a patient with familial BAV disease and the root dilatation phenotype, who was operated on for proximal aortic aneurysm (Girdauskas *et al.*, 2011a). The surgery was complicated by intraoperative aortic dissection. Multi-generational genetic analysis was performed thereafter and revealed a mutation in the transforming growth factor-beta receptor type II (TGFBR2) gene in our patient and her father.

Some specific features were indicative of a genetic origin of the BAV-associated aortopathy in this patient. The strong family history of BAV disease associated with the root dilatation phenotype, the marked fragility of the aortic wall (which led to the intraoperative aortic dissection), and the histological pattern of symmetric medial degeneration (i.e., cystic medial necrosis) were indices of a Marfan-syndrome-like connective tissue disorder.

BAV has been previously described to be an associated feature of an uncommon connective tissue disorder known as Loeys-Dietz syndrome, which is characterized by progressive aortic dilatation and the triad of hypertelorism, cleft palate or bifid uvula, and craniosynostosis. However, no predictive clinical signs of this syndrome were found in the affected family in our case.

Mutations in the TGFBR1 and TGFBR2 genes have been recently demonstrated to result in a wide spectrum of Marfan syndrome-related genetic disorders (e.g., Loeys-Dietz syndrome, and familial thoracic aortic aneurysms and dissections). However, thus far, mutations in the TGFBR1 and TGFBR2 genes have not been found in patients with BAV disease (Arrington *et al.*, 2008; Loscalzo *et al.*, 2007). The possible explanation for this finding may be the heterogeneous nature of BAV disease (i.e., genetic analysis in these studies was not focused on BAV patients with the root dilatation phenotype).

Because there are no targeted genetic studies or detailed surgical reports that have focused on the root dilatation phenotype of BAV disease, the true incidence of TGFBR mutations in BAV disease is not known.

In conclusion, the above discussed data suggest that the proximal aortic dilatation associated with BAV stenosis versus that associated with BAV insufficiency should be considered as different diseases that are possibly amenable to different therapeutic approaches. The heterogeneous nature of BAV disease and the above-discussed pathogenetic insights should be considered when advocating novel surgical treatment guidelines for BAV-associated aortopathy (Guntheroth, 2008).

The widespread belief that BAV disease is a congenital disorder of vascular connective tissue has led to more aggressive treatment recommendations of the proximal aorta in BAV patients, approaching the aortic management recommendations for patients with Marfan syndrome. However, given the heterogeneity of the complex and multifaceted BAV disease,



there is an urgent need for diagnostic tools to reliably distinguish the more from the less “malignant” phenotypes of BAV disease (Girdauskas *et al.*, 2011b).

In the view of above-presented data, it would seem unjustified to extend the surgical procedure to the sinuses of Valsalva in BAV patients with aortic valve stenosis and asymmetric mid-ascending aortic dilatation. In contrast, the relatively small proportion of young male BAV patients with the root dilatation phenotype may benefit from the more radical and aggressive surgical treatment strategy.

## 2.2 Different cusps fusion patterns in BAV disease

There are two most common patterns of cusp fusion in BAV disease (Fig. 5): the most commonly seen fusion of the left and right coronary cusps, occurs in 70-85% of cases, and union of the right and non-coronary cusps, occurs in the remaining 15-30% of BAV cases. A more detailed classification system of all BAV morphologic variants has been presented by Sievers & Schmidtke (2007).

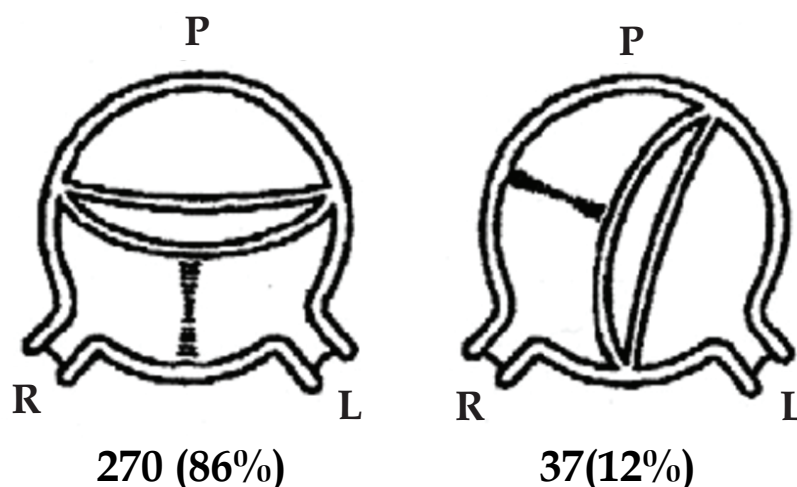


Fig. 5. Schema of morphologic BAV classification (published in *Mayo Clinic Proceedings* 1999; 74:14-26)

There is emerging evidence from the recent literature that the different cusp fusion patterns in BAV disease are associated with specific lesions of the proximal aorta. The histopathological grading of the of aortic wall changes in patients who underwent surgery for BAV disease demonstrated a more severe degree of wall degeneration in the ascending aorta in patients with fusion of the left coronary and right coronary cusps versus fusion of the right coronary and non-coronary cusps (Russo *et al.*, 2007). The prevalence of fibrosis, cystic medial necrosis, elastic fragmentation, and inflammation has been shown to be significantly higher in patients with fusion of the left coronary and right coronary cusps.

Moreover, BAV patients with fusion of the left coronary and right coronary cusps were significantly younger at the time of surgery and had a significantly larger aortic root diameter versus BAV patients with fusion of the right coronary and non-coronary cusps.

The investigators of this study concluded that the presence of more severe histopathological changes at a younger age, and a significantly larger aortic root diameter in BAV patients with fusion of the left coronary and right coronary cusps, may be predictive of a more accelerated and “malignant” BAV phenotype (Russo *et al.*, 2007).

A comparative echocardiographic evaluation of BAV patients with different aortic valve cusp fusion patterns brought comparable findings: fusion of the left coronary and right coronary cusps was associated with a larger aortic root diameter and a smaller aortic arch, than was fusion of the right coronary and non-coronary cusps (Schaefer *et al.*, 2007). Moreover, fusion of the left coronary and right coronary cusps correlated with a higher aortic stiffness index and lower distensibility at the level of the aortic root.

The authors hypothesized that the differences in the spatial propagation of blood flow through the BAVs with fusion of the left coronary and right coronary cusps versus fusion of the right coronary and non-coronary cusps may lead to an inhomogeneous distribution of shear stress and, consequently, to differential alterations of the proximal aortic wall.

The same authors advocated, in their subsequent retrospective analysis (Schaefer *et al.*, 2008), an integrated phenotypic classification of BAV disease that includes both the cusp fusion pattern and the proximal aortic shape. Three different proximal aortic shapes in BAV disease were identified (Fig. 6).

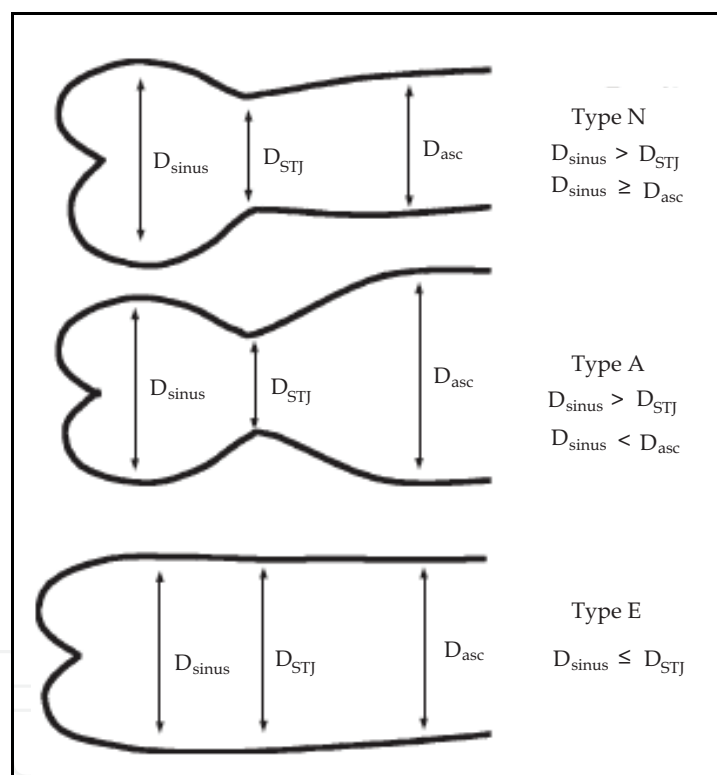


Fig. 6. Proximal aortic shapes in BAV disease (published in *Heart* 2008; 94:1634-1638)

Schaefer *et al.* arrived at very similar findings: fusion of the left coronary and right coronary cusps was associated with normal aortic shape (Type N) but a larger diameter of the aortic annulus and sinuses of Valsalva. In contrast, fusion of the right coronary and non-coronary cusps resulted in ascending aortic dilatation (Type A) and larger aortic arch dimensions. This phenotypic classification has been proposed as a clinical and a research tool in order to precisely define BAV subgroups based on the combination of cusp morphology and proximal aortic shape.

Another retrospective echocardiographic study demonstrated, analogously with Schaefer *et al.* (2007, 2008), that fusion of the right coronary and non-coronary cusps correlated with the

more rapid growth of ascending aortic diameter in the pediatric population (Holmes *et al.*, 2007).

The pathogenetic background for clinical observation of the specific aortic shapes in BAV patients with different morphologic cusp fusion patterns has been elucidated in detailed *in vivo* rheological studies using sophisticated 4D magnetic resonance imaging (Hope *et al.*, 2010). Hope *et al.* analyzed most recently the transvalvular systolic flow patterns in BAVs and demonstrated a markedly abnormal helical flow in patients with BAV, including those without ascending aortic dilatation or aortic valve stenosis. This suggests that the abnormal systolic flow pattern is not secondary to a dilated aorta or to aortic valve stenosis, but that it may be implicated in the pathogenesis of BAV-associated aortopathy.

Interestingly, Hope *et al.*, (2010) were able to convincingly demonstrate in their study two different nested helical flow patterns that are unique for the two most common cusp fusion types in patients with BAV (i.e., fusion of the left coronary and right coronary cusps versus fusion of the right coronary and non-coronary cusps).

The most common fusion pattern of the left coronary and right coronary cusps was associated with a right-anteriorly directed eccentric systolic flow jet, with a resulting marked peripheral skewing towards the convexity of the proximal aorta (Fig. 7a). A left-handed nested systolic helical flow, which was observed specifically in patients with fusion of the right coronary and non-coronary cusps, was associated with a left-posteriorly directed eccentric flow jet (Fig. 7b).

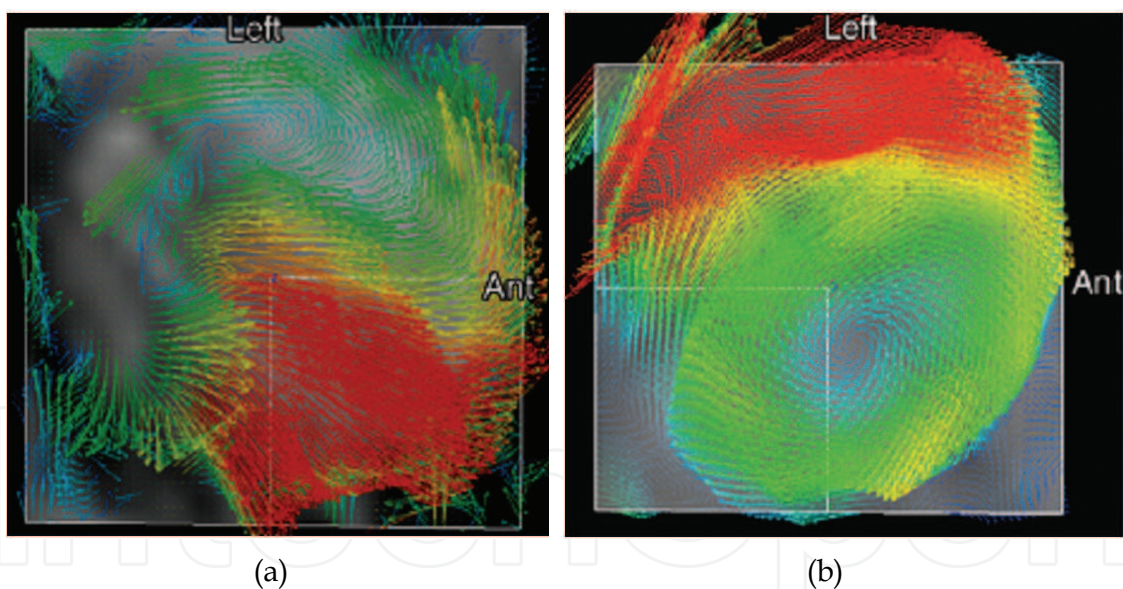


Fig. 7. Different eccentric transvalvular flow patterns in the proximal aorta in a patient with BAV and fusion of the left coronary and right coronary cusps (a) and in a patient with BAV and fusion of the right coronary and non-coronary cusps (b) (published in *Radiology* 2010; 77:177-185)

Most importantly, Hope *et al.* (2010) convincingly showed that different morphologic patterns of aortic valve cusp fusion in patients with BAV result in the specific orientation of systolic flow jets in the proximal aorta. As a logical consequence of this, it may be assumed that the direction of eccentric systolic flow would be crucial in determining the specific pattern of segmental aortic aneurysm formation in patients with a BAV. Specifically, fusion

of the left coronary and right coronary cusps, which generates a right-anterior eccentric flow jet, may be linked to asymmetric dilatation of the mid-ascending tubular aorta. Fusion of the right coronary and non-coronary cusps, which produces a left-posteriorly directed eccentric flow jet, might explain the increased aortic arch dimensions in this subgroup of BAV patients.

Nonetheless, the above-mentioned rheological studies are not able to sufficiently answer all relevant questions concerning the pathogenesis of BAV aortopathy. The paucity of data on the “root dilatation phenotype” precludes any reasonable explanation for the larger aortic root dimensions in BAV patients with fusion of the left coronary and right coronary cusps. Asymmetric involvement of the aortic root (i.e., sinuses of Valsalva) in BAV patients has not been systematically addressed and, accordingly, there are no specific data on aortic root morphology in BAV patients with the “root dilatation phenotype”. Additional in-depth studies are required, especially those that correlate the data of rheological studies with the results of detailed histological/ biomolecular analyses from the proximal aorta in BAV patients.

In summary, those detailed rheological data provide a unique hemodynamic insight into the different clinically observed phenotypes of BAV disease. This pathogenetic background should be considered when advocating treatment guidelines for BAV-associated aortopathy.

### 2.3 Clustering of patients with BAV aortopathy

Some efforts have been made to cluster BAV patients according to the anatomical pattern of proximal aortic dilatation and to propose “individualized” degrees of aortic replacement for these subgroups (Fazel *et al.*, 2008). Hierarchic cluster analysis was proposed by Fazel *et al.* to stratify BAV patients into four distinct patterns of proximal aortic involvement.

Based on four identified dilatation patterns of the proximal aorta, Itoh *et al.* (2010) argue that a custom-tailored approach to aortic resection is reasonable in patients with BAV and should involve the aortic arch in the majority of cases (i.e., in 73% BAV patients undergoing surgery) (Itoh *et al.*, 2010). All these surgical considerations are limited by the theoretical assumption that all patients with BAV have an underlying connective tissue disorder and that aneurismal aortic dilation is not a consequence of the co-existent hemodynamic abnormalities.

There are some major limitations of the study by Fazel *et al.* (2008), which should be stressed when considering such aggressive treatment guidelines for the dilated proximal aorta in the setting of a BAV. As discussed in the previous subparagraphs, there is a growing amount of evidence supporting the notion that hemodynamic factors are involved in the genesis of aortopathy in patients with BAV disease. Therefore, BAV morphology (i.e., different aortic valve cusps fusion patterns) and BAV function (i.e., BAV stenosis versus BAV insufficiency) should undoubtedly be considered when trying to better discriminate between specific subgroups of BAV disease (Della Corte & Cotrufo, 2008).

Interestingly, Fazel *et al.* (2008) found the highest prevalence of right coronary and non-coronary cusp fusion and the highest mean grade of aortic valve insufficiency in the cluster of BAV patients with dilatation of the tubular ascending aorta and aortic arch. These findings correlate appropriately with the data from the rheological and echocardiographic studies by Hope *et al.*, (2010), and Schaefer *et al.*, (2008). Moreover, the retrospective study by Fazel *et al.*, (2008) included only a selected (i.e., non-consecutive) cohort of BAV patients, for whom thoracic aortic imaging data were available for analysis.

Fazel *et al.*, (2008) acknowledged in the discussion of their manuscript that there are no follow-up data to support the hypothesis that such an aggressive aortic replacement strategy results in decreased postoperative morbidity and mortality over the long term. The progression rate of aortic arch aneurysms over years after surgery is currently unknown and the 1.9 mm/year growth rate that Fazel *et al.* (2008) cited refers to the mid-ascending aortic tract.

Moreover, the aforementioned study lacks an accurate comparison of the study population with a matched TAV group, as already stressed in the invited commentary by Della Corte & Cotrufo (2008). Therefore, it is unclear whether the observed proximal aortic dilation patterns are unique to the BAV setting.

In summary, the presented novel treatment recommendations for the identified BAV clusters may not be drawn from purely observational studies, which include only a limited number of selective BAV patients and do not respect the hemodynamic background of different BAV phenotypes.

### 3. Conclusion

The clinically observed linkage between specific BAV morphology and the associated lesions of the proximal aorta has recently led to several phenotypic classifications which incorporate both aortic valve and proximal aortic anatomy. These novel BAV phenotypes and the fundamental research contributions have been addressed in detail in this chapter.

The predominant anatomical-clinical BAV phenotype of BAV stenosis with an asymmetric mid-ascending aortic dilatation may include those patients in whom the hemodynamic factors play the determinant role. The root dilatation phenotype may be subtended by a less flow-dependent mechanism of aortic wall failure and may be a purely genetic form of BAV disease. This is clearly a completely different disease from BAV stenosis and asymmetric mid-ascending aortic dilatation.

The evidence suggests that the proximal aortic dilatation associated with BAV stenosis versus that with BAV insufficiency should be considered as different diseases that may be amenable to specific therapeutic approaches. According to discussed in this chapter, it seems not justified to extend the surgical procedure to the sinuses of Valsalva in BAV patients with aortic valve stenosis and asymmetric mid-ascending aortic dilatation. In contrast, a relatively small proportion of young male BAV patients with the root dilatation phenotype should probably be treated more radically.

There is emerging evidence from the recent literature that different cusp fusion patterns in BAV disease are associated with specific lesions of the proximal aorta. The presence of more severe aortic histopathological changes at a younger age, and a significantly larger aortic root diameter in BAV patients with fusion of the left coronary and right coronary cusps may be predictive of a more accelerated and “malignant” BAV phenotype.

It has been convincingly demonstrated that fusion of the left coronary and right coronary cusps generates a right-anterior eccentric flow jet, which may hemodynamically explain the resulting asymmetric dilatation of the mid-ascending tubular aorta. Fusion of the right coronary and non-coronary cusps, which produces a left-posteriorly directed eccentric flow jet, might explain the increased aortic arch dimensions in this subgroup of BAV patients. However, the paucity of data on the “root dilatation phenotype” precludes any reasonable hemodynamic explanation for the larger aortic root dimensions in BAV patients with fusion

of the left coronary and right coronary cusps. The aortic root (i.e., sinuses of Valsalva) has not been systematically addressed in BAV patients and, accordingly, there are no specific data on aortic root morphology in BAV patients with the “root dilatation phenotype”. Additional in-depth studies are required, especially those that correlate the data of rheological studies with the results of detailed histological/ biomolecular analyses from the proximal aorta in BAV patients.

The pathogenetic background of different BAV phenotypes should be considered when advocating treatment guidelines for BAV-associated aortopathy. Data from recent studies requires a reevaluation of the overwhelming support of the genetic nature of BAV aortopathy, and they oblige us to acknowledge that hemodynamic factors are significantly involved in the development of this disease process. Given the described heterogeneity of BAV disease, additional studies are under way to more precisely describe which hypothesis is the “correct” one for explaining the apparently different phenotypes of BAV disease.

From a clinical standpoint, there is an urgent need for diagnostic tools to reliably distinguish the more from the less “malignant” phenotypes of BAV disease. The combination of protein assays (i.e., metalloproteinase 2 plasma levels) and magnetic resonance imaging tests (i.e., quantitative measurement of the angle of the misdirected blood flow) has been most recently proposed as a future diagnostic tool for clinical risk stratification of different BAV phenotypes (den Reijer *et al.*, 2010). Prospective multicenter studies will be needed to prove the predictive value of this novel concept. The identification of a BAV phenotype representing the more “malignant” form of BAV disease, which would be amenable to the more aggressive surgical strategy, still requires special future research efforts.

In conclusion, in the face of most recent *in vitro* and *in vivo* findings on BAV disease, we found it necessary to address the issue of phenotypes in BAV disease. We feel that a critical review of this clinical problem is crucial, because the different BAV phenotypes may be caused by unique pathogenetic mechanisms and may be amenable to different therapeutic approaches. Such observations are not simply theoretical in nature: they significantly affect our surgical approach to the proximal aorta in patients with this common clinical entity of BAV disease.

#### 4. References

- Arrington, C.; Sower, T.; Chuckwuk, N.; Stevens, J.; Leppert, M.; Yetman, A. & Bowles, N. (2008). Absence of TGFBR1 and TGFBR2 mutations in patients with bicuspid aortic valve and aortic dilatation. *American Journal of Cardiology*, Vol. 102, No. 5, (September 2008), pp. 629-631, ISSN 0002-9149
- Bauer, M.; Gliach, V.; Siniawski, H. & Hetzer, R. (2006). Configuration of the ascending aorta in patients with bicuspid and tricuspid aortic valve disease undergoing aortic valve replacement with or without reduction aortoplasty. *Journal of Heart Valve Disease*, Vol. 15, No. 5, (September 2006), pp. 594-600, ISSN 0966-8519
- Biner, S.; Rafique, A.; Ray, I.; Cuk, O.; Siegel, R. & Tolstrup, K. (2009). Aortopathy is prevalent in relatives of bicuspid aortic valve patients. *Journal of the American College of Cardiology*, Vol. 53, No. 24, (June 2009), pp. 2288-2295, ISSN 0735-1097
- Conti, C.; Della Corte, A.; Votta, E.; Del Viscovo, L.; Bancone, C.; De Santo, L. & Redaelli, A. (2010). Biomechanical implications of the congenital bicuspid aortic valve: a finite

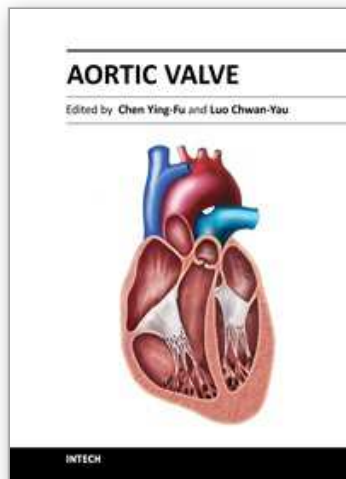
- element study of aortic root function from in vivo data. *Journal of Thoracic and Cardiovascular Surgery*, Vol. 140, No. 4, (October 2010), pp. 890-896, ISSN 0022-5223
- Cotrufo, M.; Della Corte, A. (2009). The association of bicuspid aortic valve disease with asymmetric dilatation of the tubular ascending aorta: identification of a definite syndrome. *Journal of Cardiovascular Medicine*, Vol. 10, No. 4, (April 2009), pp. 291-297, ISSN 1558-2027
- Cotrufo, M.; De Santo, L.; Esposito, S.; Renzulli, A.; Della Corte, A.; De Feo, M.; Marra, C. & Agozzino, L. (2001). Asymmetric medial degeneration of the intrapericardial aorta in aortic valve disease. *International Journal of Cardiology*, Vol.81, No.1, (November 2001), pp. 37-41, ISSN 0167-5273
- Cotrufo, M.; Della Corte, A.; De Santo, L.; Quarto, C.; De Feo, M.; Romano, G.; Amarelli, C.; Scardone, M.; Di Meglio, F.; Guerra, G.; Scarano, M.; Vitale, S.; Castaldo, C. & Montagnani, S. (2005). Different patterns of extracellular matrix protein expression in the convexity and the concavity of the dilated aorta with bicuspid aortic valve: preliminary results. *Journal of Thoracic and Cardiovascular Surgery*, Vol. 130, No. 2, (August 2005), pp. 504-511, ISSN 0022-5223
- Davies, R.; Kaple, R.; Mandapati, D.; Gallo, A.; Botta, D.; Elefteriades, J. & Coady, M. (2007). Natural history of ascending aortic aneurysms in the setting of an unreplaced bicuspid aortic valve. *Annals of Thoracic Surgery*, Vol. 83, No. 4, (April 2007), pp. 1338-1344, ISSN 0003-4975
- Della Corte, A.; De Santo, L.; Montagnani, S.; Quarto, C.; Romano, G.; Amarelli, C.; Scardone, M.; De Feo, M.; Cotrufo, M. & Caianiello, G. (2006). Spatial patterns of matrix protein expression in dilated ascending aorta with aortic regurgitation: congenital bicuspid valve versus Marfan's syndrome. *Journal of Heart Valve Disease*, Vol. 15, No. 1, (January 2006), pp. 20-27, ISSN 0966-8519
- Della Corte, A.; Bancone, C.; Quarto, C.; Dialetto, G.; Covino, F.; Scardone, M.; Caianiello, G. & Cotrufo, M. (2007). Predictors of ascending aortic dilatation with bicuspid aortic valve: a wide spectrum of disease expression. *European Journal of Cardiothoracic Surgery*, Vol. 31, No. 3, (March 2007), pp. 397-404, ISSN 1010-7940
- Della Corte, A.; Quarto, C.; Bancone, C.; Castaldo, C.; Di Meglio, F.; Nurzynska, D.; De Santo, L.; De Feo, M.; Scardone, M.; Montagnani, S. & Cotrufo, M. (2008). Spatiotemporal patterns of smooth muscle cell changes in ascending aortic dilatation with bicuspid and tricuspid aortic valve stenosis: focus on cell-matrix signalling. *Journal of Thoracic and Cardiovascular Surgery*, Vol. 135, No. 1, (January 2008), pp. 8-18, ISSN 0022-5223
- Della Corte, A. & Cotrufo, M. (2008). Bicuspid aortopathy or bicuspid aortopathies? The risk of generalizing. *Journal of Thoracic and Cardiovascular Surgery*, Vol. 136, No. 6, (December 2008) pp. 1604, ISSN 0022-5223
- den Reijer, P.; Sallee 3<sup>rd</sup>, D.; van der Velden, P.; Zaaijer, E.; Parks, W.; Ramamurthy, S.; Robbie, T.; Donati, G.; Lamphier, C.; Beekman, R. & Brummer, M. (2010). Hemodynamic predictors of aortic dilatation in bicuspid aortic valve by velocity-encoded cardiovascular magnetic resonance. *Journal of Cardiovascular Magnetic Resonance*, Vol. 12, No. 1, (January 2010), pp. 4-17, ISSN 1097-6647.
- Fazel, S.; Mallidi, H.; Lee, R.; Sheehan, M.; Liang, D.; Fleischmann, D.; Herfkens, R.; Mitchell, R. & Miller, DC. (2008). The aortopathy of bicuspid aortic valve disease has

- distinctive patterns and usually involves the transverse aortic arch. *Journal of Thoracic and Cardiovascular Surgery*, Vol. 135, No. 4, (April 2008), pp. 901-907, ISSN 0022-5223
- Girdauskas, E.; Schulz, S.; Borger, M.; Mierzwa, M. & Kuntze, T. (2011). Transforming growth factor-beta receptor type II mutation in a patient with bicuspid aortic valve disease and intraoperative aortic dissection. *Annals of Thoracic Surgery*, (in press), doi:10.1016/j.athoracsur.2010.12.060
- Girdauskas, E.; Borger, M.; Secknus, M.; Girdauskas, G. & Kuntze, T. (2011). Is aortopathy in bicuspid aortic valve disease a congenital defect or a result of abnormal hemodynamics? A critical reappraisal of a one-sided argument. *European Journal of Cardiothoracic Surgery*, (February 2011), doi:10.1016/j.ejcts.2011.01.001
- Guntheroth, W. (2008). A critical review of the ACC/AHA practice guidelines on bicuspid aortic valve with dilated ascending aorta. *American Journal of Cardiology*, Vol. 102, No. 1, (July 2008), pp. 107-110. ISSN 0002-9149
- Itoh, A.; Fischbein, M.; Arata, K. & Miller, DC. (2010). „Peninsula-style“ transverse aortic arch replacement in patients with bicuspid aortic valves. *Annals of Thoracic Surgery*, Vol. 90, No. 4, (October 2010), pp. 1369-1371, ISSN 0003-4975
- Holmes, K.; Lehmann, C.; Dalal, D.; Nasir, K.; Dietz, H.; Ravekes, W.; Thompson, W. & Spevak, P. (2007). Progressive dilation of the ascending aorta in children with isolated bicuspid aortic valve. *American Journal of Cardiology*, Vol. 99, No. 7, (April 2007), pp. 978-983, ISSN 0002-9149
- Hope, M.; Hope, T.; Meadows, A.; Ordovas, K.; Urbania, T.; Alley, M. & Higgins, C. (2010). Bicuspid aortic valve: four-dimensional MR evaluation of ascending aortic systolic flow pattern. *Radiology*, Vol.255, No.1, (April 2010), pp. 53-61, ISSN 0033-8419
- Hope, M.; Hope, T.; Meadows, A.; Ordovas, K.; Urbania, T.; Alley, M. & Higgins, C. (2010). Bicuspid aortic valve: four-dimensional MR evaluation of ascending aortic systolic flow patterns. *Radiology*, Vol. 255, No. 1, (April 2010), pp. 53-61, ISSN 0033-8419
- Lehoux, S.; Tronc, F. & Tedgui, A. (2002). Mechanisms of blood flow-induced vascular enlargement. *Biorheology*, Vol. 39, No. 3-4, (January 2002), pp. 319-324, ISSN 0006-355X
- Loscalzo, M.; Goh, D.; Loeys, B.; Kent, K.; Spevak, P. & Dietz, H. (2007). Familial thoracic aortic dilation and bicommissural aortic valve: a prospective analysis of natural history and inheritance. *American Journal of Medical Genetics Part A*, Vol. 143A, No. 17, (September 2007), pp. 1960-1967, ISSN 1552-4825
- Nistri, S.; Sorbo, M.; Marin, M.; Palisi, M.; Scognamiglio, R. & Thiene, G. (1999). Aortic root dilatation in young men with normally functioning bicuspid aortic valves. *Heart*, Vol. 82, No. 1, (July 1999), pp. 19-22, ISSN 1355-6037
- Robicsek, F.; Thubrikar, M.; Cook, J. & Fowler, B. (2004). The congenitally bicuspid aortic valve: how does it function? Why does it fail? *Annals of Thoracic Surgery*, Vol. 77, No. 1, (January 2004), pp. 177-185, ISSN 0003-4975
- Russo, C.; Cannata, A.; Lanfranconi, M.; Vitali, E.; Garatti, A. & Bonacina, E. (2007). Is aortic wall degeneration related to bicuspid aortic valve anatomy in patients with valvular disease? *Journal of Thoracic and Cardiovascular Surgery*, Vol. 136, No. 4, (October 2008), pp. 937-942, ISSN 0022-5223



- Schaefer, B.; Lewin, M.; Stout, K.; Byers, P. & Otto, C. (2007). Usefulness of bicuspid aortic valve phenotype to predict elastic properties of the ascending aorta. *American Journal of Cardiology*, Vol. 99, No. 5, March 2007), pp. 686-690, ISSN 0002-9149
- Schaefer, B.; Lewin, M.; Stout, K.; Gill, E.; Prueitt, A.; Byers, P. & Otto, C (2008). The bicuspid aortic valve: an integrated phenotypic classification of leaflet morphology and aortic root shape. *Heart*, Vol. 94, No. 12, (December 2008), pp. 1634-1638, ISSN 1355-6037
- Sievers, H. & Schmidtke C (2007). A classification system for the bicuspid aortic valve from 304 surgical specimens. *Journal of Thoracic and Cardiovascular Surgery*, Vol. 133, No. 5, (May 2007), pp. 1226-1233, ISSN 0022-5223
- Williams, DS. (2006). Bicuspid aortic valve. *Journal of Insurance Medicine*, Vol. 38, No. 1, pp. 72-74, ISSN 0743-6661

IntechOpen



## **Aortic Valve**

Edited by Prof. Chen Ying-Fu

ISBN 978-953-307-561-7

Hard cover, 350 pages

**Publisher** InTech

**Published online** 09, December, 2011

**Published in print edition** December, 2011

Much has evolved in the field of aortic valve disease because of the increase in knowledge in the last decade, especially in the area of its management. This book "Aortic Valve" is comprised of 18 chapters covering basic science, general consideration of aortic valve disease, infective endocarditis, aortic sclerosis and aortic stenosis, bioprosthetic valve, transcatheter aortic valve implantation and a special section on congenital anomalies of the aortic valve. We hope this book will be particularly useful to cardiologists and cardiovascular surgeons and trainees. We also believe that this book will be a valuable resource for radiologists, pathologists, cardiovascular anesthesiologists, and other healthcare professionals who have a special interest in treating patients with aortic valve disease. We are certain that information in this book will help to provide virtually most new areas of aortic valve disease that will be employed in the current era.

### **How to reference**

In order to correctly reference this scholarly work, feel free to copy and paste the following:

Evaldas Girdauskas, Michael A. Borger and Thomas Kuntze (2011). Novel Phenotypes in Bicuspid Aortic Valve Disease, Aortic Valve, Prof. Chen Ying-Fu (Ed.), ISBN: 978-953-307-561-7, InTech, Available from: <http://www.intechopen.com/books/aortic-valve/novel-phenotypes-in-bicuspid-aortic-valve-disease>

**INTECH**  
open science | open minds

### **InTech Europe**

University Campus STeP Ri  
Slavka Krautzeka 83/A  
51000 Rijeka, Croatia  
Phone: +385 (51) 770 447  
Fax: +385 (51) 686 166  
[www.intechopen.com](http://www.intechopen.com)

### **InTech China**

Unit 405, Office Block, Hotel Equatorial Shanghai  
No.65, Yan An Road (West), Shanghai, 200040, China  
中国上海市延安西路65号上海国际贵都大饭店办公楼405单元  
Phone: +86-21-62489820  
Fax: +86-21-62489821

© 2011 The Author(s). Licensee IntechOpen. This is an open access article distributed under the terms of the [Creative Commons Attribution 3.0 License](#), which permits unrestricted use, distribution, and reproduction in any medium, provided the original work is properly cited.

IntechOpen

IntechOpen