

We are IntechOpen, the world's leading publisher of Open Access books Built by scientists, for scientists

4,800

Open access books available

122,000

International authors and editors

135M

Downloads

Our authors are among the

154

Countries delivered to

TOP 1%

most cited scientists

12.2%

Contributors from top 500 universities



WEB OF SCIENCE™

Selection of our books indexed in the Book Citation Index
in Web of Science™ Core Collection (BKCI)

Interested in publishing with us?
Contact book.department@intechopen.com

Numbers displayed above are based on latest data collected.

For more information visit www.intechopen.com



Adrenal Cortex Tumors and Hyperplasias

Duarte Pignatelli^{1,2,3}

¹Endocrinology, Hospital S. João, Porto

²Faculty of Medicine of the University of Porto

³IPATIMUP, University of Porto

Portugal

1. Introduction

The adrenal cortex tumors include both malignant adrenal cortex cancers (ACC) and benign masses (ACT) that can be either secreting, of one of the hormones normally produced in the adrenal cortex (Cushing's syndrome if the hypersecretion is of cortisol or Conn's syndrome if it is aldosterone) or non-secretory (Incidentalomas).

The outer part of the adrenal glands, the adrenal cortex, is responsible for regulating important body functions including blood sugar levels, body water and salt levels, and consequently blood pressure and kidney functions, the immune system, the inflammatory response, the physiological response to stress, and, finally, sexual and reproductive functions.

The three different parts of the adrenal cortex, *zona glomerulosa*, *zona fasciculata* and *zona reticularis*, are responsible for producing different hormones namely mineralocorticoids, glucocorticoids, and androgens (and eventually also estrogens). The *glomerulosa* secretes aldosterone, and gives rise to Primary Aldosteronism (PA)/Hyperaldosteronism that can result either from an adenoma (Conn's syndrome) or from bilateral hyperplasia (BAH). The *fasciculata* secretes cortisol and adenomas that produce this hormone are associated to a distinct syndrome called Cushing's syndrome. Finally the adrenal cortex *reticularis* zone is supposed to produce adrenal androgens (namely dehydroepiandrosterone - DHEA and dehydroepiandrosterone sulfate - DHEA-s) that can in turn be either converted into testosterone or aromatized to estrogen in peripheral organs like the adipose tissue. In spite of the fact that normally this peripheral conversion is more important than the local production, there are adrenal cortex tumors that can produce testosterone directly, the Androgen-secreting tumors as well as adrenocortical carcinomas expressing aromatase and producing estrogens, the Estrogen-secreting tumors.

The majority of adrenocortical tumors (ACT) are benign and silent (non-secreting adenomas or incidentalomas) since they do not ever result in hormone secretion. Its true incidence is still unknown because it is probable that many of these cases still go undiagnosed. However, it is estimated that they are present in at least 3% of the adult population (especially over 50 years of age) (National Institutes of Health, 2002; Grumbach et al., 2003). Most of these tumors are discovered incidentally due to the widespread availability of imaging studies for intra-abdominal diseases. This is the reason why they are designated as Incidentalomas.

In summary, only a minority of the adrenocortical benign tumors (about 15%) are hormone-secreting adenomas, responsible for Cushing's syndrome, primary aldosteronism (Conn's syndrome) or even sometimes virilization.

Adrenocortical carcinoma is a rare, highly malignant tumor usually associated with a poor prognosis which may occur either in children or adults. This is a malignancy with an heterogeneous presentation and despite probably still underestimated it has an expected incidence of about 1-2 cases per 1 million population per year (Wajchenberg et al., 2000; Dackiw et al., 2001; Kebebew et al., 2006). Although the adrenocortical carcinomas may occur and develop at any age, two different disease peaks were identified, one before the age of five and the other in the fifth decade of life (Wajchenberg et al., 2000; Ng & Libertino, 2003).

2. Adrenal cortex cancer

The evaluation and categorization of adrenocortical neoplasms remain among the most challenging areas in adrenal pathology (Lau & Weiss, 2009), since the pathological diagnosis of ACC, which is based on gross and microscopic criteria, is still full of areas of subjectivity. Moreover, in the absence of the gold standards that constitute the appearance of metastases, local invasion or recurrence, the diagnosis of malignancy may represent a great difficulty for both clinicians and pathologists.

Several multiparametric systems have been developed to assess this malignancy (Aubert, 2005). Among them, the Weiss system (Weiss, 1984), first introduced 25 years ago, and based on nine microscopic criteria, appears to be the most employed scoring methodology, because of its simplicity and reliability.

This system provides specific guidelines for differentiating adrenocortical adenoma from adrenocortical carcinoma and is considered the standard for determining malignancy in tumors of the adrenal cortex. However, considerable advances in the understanding of the pathology of adrenocortical neoplasias have occurred since delineation of the Weiss system, offering alternative approaches in the contemporary assessment of adrenocortical tumors (Lau & Weiss, 2009). In a recent study based on whole genome gene analysis the authors proposed a molecular assay for the classification and prognosis of adrenocortical tumors (Giordano et al., 2009). There were many genetic expression differences between ACC and ACT and normal adrenals. There were in fact 879 genes over expressed and 1011 under expressed in ACC that could differentiate ACC from ACT and normal adrenals. The most significant ones were related to cell proliferation, as would be expected. But the reality is that such systems are still very expensive and add very little to the diagnostic power of the morphological analyses. Therefore, in most adrenocortical tumors, the morphological approach considering the probability of malignancy in adrenal masses > 6 cm and that of being benign in tumors < 4 cm, together with the postoperative assessment by the Weiss system, brings sufficient elements to establish the differential diagnosis between a benign and a malignant tumor (Tissier, 2010).

The Weiss system, which, as previously was said, is currently the most popular scoring system, combines nine morphological parameters, of which three are structural ("dark" cytoplasm, diffuse architecture, necrosis), three are cytological (atypia, mitotic count, atypical mitotic figures) and three are related to invasion (of sinusoids, veins and tumor capsule) (Volante et al., 2008). The nine histological criteria are:

- High nuclear grade (grades 3 or 4) (High Nuclear/Cytoplasm ratio; marked variation of nuclear characteristics; giant cells with hyperchromatic nuclei; visible nucleoli)
 1. Small roundish nuclei; without nucleoli
 2. Larger nuclei, more irregular in shape and with visible nucleoli (at 400x magnification)
 3. Irregular nuclei, with larger size, with visible nucleoli (at 100x)
 4. enormous cells with polylobulated nuclei
 - Mitoses (>5 per 50 HPF vs. <6)
 - Abnormal mitoses (absent vs. present)
 - Clear cells ($\leq 25\%$ vs. $> 25\%$)
 - Diffuse architecture ($> 33\%$ vs. $\leq 33\%$ of the area) (cells unorganized in trabecular or alveolar structures)
 - Necrosis (present vs. absent)
 - Venous invasion (present vs. absent)
 - Sinusoidal invasion (present vs. absent)
 - Capsular invasion (present vs. absent)
1. Nuclear grade: nuclear grade III and IV based on criteria of Fuhrman (Fuhrman et al., 1982).
 2. Mitotic rate: greater than 5/50 HPF (x400 objective). According to Weiss, "mitosis was evaluated by counting 10 random high-power-fields in the area of the greatest numbers of mitotic figures on the five slides with greatest number of mitoses. If less than five slides were available for a case, a correspondingly greater number of fields per slide were used to make fifty high power-fields."
 3. Atypical mitotic figures: "mitosis was regarded as atypical when it definitely showed an abnormal distribution of chromosomes or an excessive number of mitotic spindles."
 4. Cytoplasm: presence of $\leq 25\%$ "clear or vacuolated cells resembling the normal *zona fasciculata*."
 5. Diffuse architecture: diffuse architecture was present "if greater than one-third of the tumor formed patternless sheets of cells." Trabecular, columnar, alveolar or nesting organizations were regarded as non-diffuse patterns.
 6. Necrosis: necrosis was "regarded as present when occurring in at least confluent nests of cells."
 7. Venous invasion: Weiss defined a vein as an "endothelial-lined vessel with smooth muscle as a component of the wall."
 8. Sinusoid invasion: a sinusoid was defined as "endothelial-lined vessel in the adrenal gland with little supportive tissues." Only sinusoids located within the tumor were considered.
 9. Invasion of tumor capsule: "invasion of the capsule was accepted as present when nests or cords of tumor extended into or through the capsule, with a corresponding stroma reaction."

Fig. 1. Weiss classification

Tumors are classified as malignant when they meet 4 or more of these histological criteria. However, it must be stated that there are still some difficulties and subjectivity in the application of this system. Also, whether the presence of 3 criteria represents malignancy, is still controversial (Aubert et al., 2005). But, despite the referred limitations and subjectivity the Weiss classification is still the most reliable and most used criteria system.

Other markers not included in the Weiss scores are now perfectly identified as being associated with the risk of recurrence and lower survival. Ki67 expression $\geq 10\%$ for instance is associated with much less chances of survival at 5 years. The same can be said about a high expression of SF-1. The immuno-histochemistry of these two factors is now routine in most pathology labs. (Fassnacht et al., 2011; Sbiera et al., 2010; Terzolo et al., 2001)

2.1 Adrenal cortex cancer pathogenesis

Molecular studies support the fact that uncontrolled cell proliferation is probably the most important factor in the development of cancers and ACC is no exception. ACC consist of monoclonal populations of cells (Beuschlein et al., 1994) while for instance adrenocortical macronodular hyperplasias are usually polyclonal. It is a basic rule that the mutations that give rise to cancer development are deletions of tumor suppressor genes or amplifications of oncogenes. The increase in cell proliferation induced by growth factors like the IGFs, bFGF or TGF $\beta 1$ (Feige et al., 1991; Mesiano et al., 1991; Mesiano et al., 1993) leads to the development of polyclonal tumors but also renders the cells more susceptible to mutations in tumor suppressor genes or in oncogenes and if these mutations give those cells a genetic advantage, cancer development may ensue. Genomic instability is the basis of gross chromosomal alterations and aneuploidy (Giordano et al., 2009).

Most cases of adrenocortical cancers appear to be sporadic and only a small percentage of patients present ACC as a component of one of the known hereditary cancer syndromes, such as the Li-Fraumeni's syndrome, the Beckwith-Wiedemann syndrome or the Multiple Endocrine Neoplasia type 1 (Koch et al., 2002; Sidhu et al., 2004; Libé & Bertherat, 2005; Kjellman et al., 1999; Schulte et al., 2000; Heppner et al., 1999).

One important difference between these two forms of adrenocortical carcinomas (either sporadic or part of an hereditary syndrome) is the current degree of knowledge about its tumorigenesis (Soon et al., 2008). For sporadic adrenocortical malignant tumors the molecular mechanisms underlying its development are still far from completely understood (Sidhu et al, 2002). One hypothesis refers the possible evolution of adrenocortical cancers from adrenal adenomas (Bernard et al., 2003); however long-term follow-up data of incidentally discovered adrenal neoplasms do not support that hypothesis (Barzon et al., 2003; Bernini et al., 2005).

The study and investigation of the pathophysiology of ACC is not only crucial for the understanding of these malignant tumors but also for the development of more sensitive means of diagnosis and better ways of treatment. And despite the fact that knowledge of these tumors has greatly evolved in the last decades, the understanding of the genes and pathways underlying the development of adrenal cortex cancers has been slow. Many genes and pathways are thought to play an important role in their development but frequently their biological plausibility is still missing.

Hereditary tumor syndrome	Gene (<i>locus</i>)	Prevalence of ACT
Li-Fraumeni syndrome (LFS)	<i>TP53</i> (17p13), <i>HIC-1</i> (17p13), <i>hCHK2</i> (22q12.1)	ACC 3%-4%
Beckwith-Wiedemann syndrome (BWS)	<i>IGF-II</i> , <i>H19</i> , <i>CDKN1C</i> (<i>p57kip2</i>), <i>KCNQ1</i> (11p15)	ACC 5%
Multiple Endocrine Neoplasia 1 (MEN-1)	<i>Menin gene</i> (11q13)	ACT 25-50%; ACC rare
Congenital Adrenal Hyperplasia (CAH)	Mostly <i>CYP21B</i> (6p21.3)	ACT in up to 82%; ACC (rare) vs Hyperplasia (usual)

- In LFS there is a germline mutation of the tumor suppressor gene TP53 in more than 70% of the families. Tumors associated with this syndrome include breast carcinoma; soft tissue sarcoma; brain tumors; osteosarcoma; leukemia and ACC. Mutations in Checkpoint Kinase 2 gene (*hCHK2*) encoding a kinase that phosphorylates TP53 were identified in some of these tumors but not in ACC (Libé & Bertherat, 2005).
- In BWS there is, on the contrary, deregulation of the imprinted *IGF-II* locus at 11p15. The *IGF-II* gene is maternally imprinted and so it's expressed only from the paternal allele. *H19* and *p57kip2* are paternally imprinted. In cases of paternal isodisomy, *IGF-II* is over-expressed and *H19* and *p57kip2* are under-expressed! BWS is a syndrome of "overgrowth" that includes many tumors like the renal' Wilms tumor, ACC, neuroblastoma and hepatoblastoma (Libé & Bertherat, 2005).
- In MEN-1 the germline mutation is in the *Menin* gene (90% of the families). This gene is also a tumor suppressor gene and it is located in chromosome 11 (11q13). LOH at 11q13 exist in more than 90% of ACC (Kjellman et al., 1999; Schulte et al., 2000; Heppner et al., 1999)

Adapted from Soon P. et al., (2008). Molecular markers and the pathogenesis of adrenocortical cancer. *The Oncologist* 13: 548-561

Table 1. Hereditary tumor syndromes, responsible genes and associated ACT prevalence

In **sporadic ACC** it has been reported that hyper-expression of the insulin-like growth factor II (**IGF-II**) is observed in the vast majority of cases (Bouille et al., 1998; Gicquel et al., 1994; Gicquel et al., 1997; Gicquel et al., 2001; Ilvesmaki et al., 1993). Together with the increase of this growth factor there is also an increased expression of its receptor (*IGF-IR*) in most ACC (Weber et al., 1997). The over-expression of *IGF-II* is probably related to adrenal cancer cell proliferation, through the *IGF-I* receptor (Fottner et al., 2001 and Logié et al., 1999).

The *IGF-II* overexpression is the result of changes at the 11p15 locus (Gicquel et al., 1994; Gicquel et al., 1997). LOH at 11p15 is much more frequent in ACC (78,5%) than in ACT (9,5%) (Gicquel et al., 2001). It is associated with a higher risk of tumor recurrence, and correlates with Weiss score. Thus, according to Gicquel and colleagues, 11p15 alterations could be used as a biological marker for confirming ACC malignancy after surgical removal of the tumor (Gicquel et al., 2001).

The 11p15 region is organized in a telomeric domain containing the IGF-II gene and H19 and a centromeric domain including the CDKN1C (p57kip2) (DeChiara et al., 1991; Hao et al., 1993; Lee et al., 1995; Matsuoka et al., 1995). Genetic and epigenetic changes in the imprinted 11p15 region resulting in low p57kip2 and H19 and elevated IGF2 mRNA expression levels have been reported in sporadic ACCs (Gicquel et al., 1994; Gicquel et al., 1997). The IGF-II system, in the adrenal gland, is responsible for growth-promoting and differentiating functions during the fetal period (Mesiano et al., 1993), but its role has been largely documented in adrenocortical malignant tumors, also in adult patients (Gicquel et al., 2001). In fact, several studies have been successful in showing the strong overexpression of IGF-II in malignant adrenocortical tumors (in approximately 90% of the cases) (Bouille et al., 1998; Gicquel et al., 1994; Gicquel et al., 1997; Gicquel et al., 2001; Ilvesmaki et al., 1993a).

Inactivating mutations of the **TP53 gene** located at the 17p13 locus are another genetic alteration that is frequently encountered in ACC. TP53 is one of the most relevant tumor suppressor genes, frequently mutated in human cancers. The TP53 mutations are thought to happen late in the evolution of sporadic malignant adrenocortical tumors. Mutations in the exons 5-8 are found more frequently in ACC than in ACT (Hollstein et al., 1991; Reincke et al., 1994). The germline mutations in TP53 have been observed in 50-80% of children diagnosed with sporadic ACC (Libé & Bertherat, 2005; Wagner et al., 1994; Varley et al., 1999). In southern Brazil where the prevalence of ACC in children is 10 times greater than in the rest of the world, there is a particular mutation at exon 10 of TP53 (Arginine 337 Histidine) in most of the cases (Ribeiro et al., 2001; Latronico et al., 2001).

Considering TP 53 gene mutations in sporadic ACC in adults, its frequency has been reported in different proportions in diverse studies ranging from 25% to 70%. (Ohgaki et al., 1993; Reincke et al., 1994; Barzon et al., 2001; Lin et al., 1994) Loss of Heterozygosity (LOH) at 17p13 was reported in 95% of ACC and only in 30% of ACT (Gicquel et al., 2001) and therefore this can also be used as a marker of malignancy.

Other reported molecular studies have suggested that genetic alterations of the **Wnt signaling pathway** may also be associated with the development of adrenocortical tumors. In fact the activation of the Wnt signaling pathway is the most prevalent defect in adrenocortical tumorigenesis particularly due to the fact that it is not only present in malignant lesions but in benign adrenocortical adenomas as well (Tissier et al., 2005).

The Wnt family includes a group of growth factors involved in developmental and homeostatic processes. Some regulatory genes in this pathway (including the down regulators of β -catenin, GSK3, Axin and APC, and β -catenin itself) can be mutated in primary human cancers (Polakis et al., 2000). In all of them the common denominator is the activation of gene transcription by β -catenin (via the transcription factors TCF and LEF).

β -catenin has a dual function in the cell: cell-adhesion (conjugated with E-cadherin) and transcriptional regulation. When the regulators of β -catenin are down-regulated the transcriptional function is increased and the adhesion is reduced and both of these alterations lead to the progression of malignancies (Brembeck et al., 2006).

Genetic alterations in the Wnt pathway conducting to β -catenin accumulation in the cytoplasm have been correlated with the pathogenesis of different types of cancer

(Gordon & Nusse, 2006). Curiously, in adrenocortical tumors, the accumulation of β -catenin has been found in both benign and malignant situations although with a slightly higher prevalence in adrenal cortex cancer (Tissier et al., 2005). It is a fact that β -catenin mutations are the most frequent genetic defects reported in adrenocortical adenomas and in these benign ACT it is mostly the non-secretory adenomas that have these mutations (Tissier et al., 2005). According to that study, abnormal cytoplasmic and/or nuclear accumulation of β -catenin was found in 38% of the adrenocortical adenomas (ACA) and in 77% of the ACC, but mutations in the β -catenin gene were found with similar frequencies of in both ACA and ACC (27% *vs.* 31%) (Tissier et al., 2005). These somewhat opposite results suggest that other components of the Wnt signaling pathway, such as the adenomatous polyposis coli (APC) or axin, may be contributing to the pathogenesis of ACC (Tissier et al., 2005).

2.2 Adrenal cortex cancer – Diagnosis and clinical presentation

Adrenocortical tumors can be classified as functional, when their hormonal secretions result in clinical consequences, or nonfunctional tumors, when they do not secrete hormones in a sufficient level to produce clinical consequences. About 50 to 60% of the adrenocortical carcinomas are functional, therefore, associated with hormonal secretion (Ng & Libertino, 2003; Allolio & Fassnacht, 2006). The most frequent presentation among adults is the Cushing's syndrome alone (45%) or the association of Cushing's syndrome with a virilization syndrome, with over-production of both glucocorticoids and androgens (25%) (Ng & Libertino, 2003; Wajchenberg et al., 2000). Other forms of functional tumors include the virilization syndrome alone and the feminization syndrome. Thus, signs and symptoms of adrenocortical tumors may vary significantly according to their origin and depending on the type of hormones that are released. Cortisol excess can be associated to symptoms such as centripetal obesity, protein wasting with skin thinning and striae, muscle atrophy (myopathy), osteoporosis, psychiatric disturbances, impaired defense against infections, diabetes, hypertension and gonadal dysfunction in men and women. In the case of aggressive malignant ACC weight loss may be observed. Androgen over-secretion is associated with various manifestations in women like hirsutism, menstrual abnormalities, infertility and eventually virilization, while excess of estrogen, although not so common, can present as gynecomastia in men. It is most important to characterize the adrenocortical carcinoma's secretory profile in order to establish its origin and better guide its treatment and follow-up (Libé et al., 2007).

Due to the elevated possibility of non-specific symptoms, both symptomatic and apparently asymptomatic patients should be evaluated.

According to the European Network for the Study of Adrenal Tumors (ENSAT), both should be studied with the following laboratory tests to determine the secretory activity of the tumor (Fassnacht & Allolio, 2009):

- fasting blood glucose and HbA1c;
- serum potassium;
- adrenal androgens (DHEA-s, androstenedione, testosterone, 17-OH progesterone);
- serum estradiol in men and postmenopausal women;
- cortisol and adrenocorticotrophic hormone (ACTH) both fasting and around midnight (in the serum or in the saliva);

- fasting serum cortisol at 8 AM following a 1 mg dose of dexamethasone on the previous day at bedtime;
- 24-hour urinary free cortisol.

After careful hormonal assessment, imaging studies, by means of computerized tomography (CT), magnetic resonance imaging (MRI) or 18 F-fluorodeoxyglucose positron emission tomography (FDG-PET), are the next essential exams both to localize and delimitate the tumor and to distinguish benign adenomas from adrenocortical carcinomas (Boland et al., 1998; Hamrahian et al., 2005; Szolaret et al., 2005; Caoili et al., 2002; Groussin et al., 2009; Minn et al., 2004; Metser et al., 2006; Wajchenberg et al., 2000). Despite sometimes being considered a controversial position, several studies have shown that the size and the appearance of the tumor remains one of the best indicators of malignancy (most molecular studies add only a little to the accuracy of malignancy identification by the mere determination of tumor size). In a study from the National Italian Study Group on Adrenal Tumors including 887 patients with adrenal incidentalomas, adrenocortical carcinomas were significantly associated with mass size, with 90% being more than 4 cm in diameter when discovered (Angeli et al., 1997). According to a study by Sturgeon and colleagues at the University of California (San Francisco) including 457 ACC cases, a size of ≥ 4 cm makes the likelihood of malignancy double (to 10%) while in tumors ≥ 8 cm it gets more than ninefold higher (47%) (Sturgeon et al., 2006).

However, because of the growing evidence of adrenocortical cancers diagnosed with a diameter between 4 and 6 cm (Sturgeon et al., 2006; Grumbach et al., 2003; Herrera et al., 1991; Mantero et al., 2000) and since it seems evident that during their early stages of development, carcinomas have to be small, it becomes clear that surgical intervention would be most beneficial the smaller and more localized the tumor would be.

Overall, prognosis does improve for patients with smaller adrenocortical tumors at the time of diagnosis. In a retrospective review of 62 ACC cases (Henley et al., 1983) patients with stages I to III lesions who underwent curative resections had significantly longer survival rates. In another study done by Fassnacht and colleagues, the five year survival significantly improved (82% *vs* 18%) for patients with smaller tumors (stages I and II, confined to the adrenal gland) *vs.* metastatic disease, stage IV (Fassnacht et al., 2009).

As general rules, one could say that the prognosis is better in the case of young children, in smaller and localized tumors specially if nonfunctioning and in which a complete resection can be achieved.

Despite the importance of evaluating an adrenal mass size and appearance, this should not be the only parameter guiding diagnosis and posterior treatment, since radiographic features are often of strong predictive value (Dunnick et al., 1996). MRI and CT images may in fact be useful in helping to define what will be the histological type of the adrenal tumor:

On unenhanced CT scanning, the measurements of Hounsfield units (HU) are of great value in differentiating malignant from benign adrenocortical tumors. The Hounsfield scale is a semi-quantitative method of measuring x-ray attenuation. Despite the fact that around 30% of adenomas do not contain large amounts of lipid, being indistinguishable from non-adenomas, adrenal masses with < 10 HU on unenhanced CT are almost certainly benign tumors (Grumbach et al., 2003). Therefore, this seems to be the consensus

cut-off for distinguishing adrenocortical carcinomas from benign adrenal tumors, according to several studies (Boland et al., 1998; Hamrahian et al., 2005). However, in those cases of benign tumors with poor intracytoplasmic lipid concentration a better discrimination can be obtained by searching for a delayed contrast clearance in contrast-enhanced CT. In this case, tumors measuring $> 10\text{HU}$ in a unenhanced CT, that show a contrast washout of less than 50% after 10- to 15-min of contrast-enhanced CT and also a delayed attenuation of more than 35HU, are suspicious for malignancy (Szolar et al., 2005; Caoili et al., 2002).

The use of MRI for differentiating benign and malignant adrenocortical tumors is equally effective to CT scan. But since MRI is more expensive and less standardized, CT scan remains the primary adrenal imaging procedure,

The utilization of the PET scanning with fluorodeoxyglucose (FDG) has been successful in identifying unilateral adrenal tumors with higher suspicion for malignancy, due to the greater reported uptake of FDG by malignant tumors compared to the benign adrenocortical tumors (Groussin et al., 2009; Maurea et al. 2001; Minn et al., 2004). The use of integrated PET-CT can further improve the capacity to distinguish between malignant and benign tumors by increasing the quality of the image. This improvement is also due to the combination of CT attenuation measurements with the intensity of FDG uptake, as described by the standardized uptake value (SUV) for the adrenal lesion (Metser et al., 2006; Caoili et al., 2007).

In what concerns **fine-needle aspiration biopsy** (FNA) one must stress that usually it is not successful in distinguishing between malignant and benign tumors and there are doubts about the risk of disseminating a carcinoma through the abdominal cavity; it can however be of some utility in differentiating an adrenal tumor from a metastasis to the adrenal and in evaluating staging for a known cancer (Jhala et al., 2004; Kocijancic et al., 2004).

2.3 Adrenal cortex cancer staging

The first staging system published by the World Health Organization (WHO) dates from in 2004 (DeLellis, 2004), and was based on different staging systems, such as the Sullivan modification of the Macfarlane system (Sullivan, 1978). The AJCC (American Joint Committee on Cancer)/UICC (International Union Against Cancer) developed a TNM staging system with the same definitions for the first time in 2009, being published on the AJCC/UICC Cancer Staging Manual, Seventh Edition. A simplified classification system was recently proposed by the European network ENSAT in which stage III includes cases with lymph nodes metastasis, infiltration of surrounding tissues and venous tumor thrombosis and stage IV only cases with distant metastases (Fassnacht et al., 2009).

Tumor clinical staging is most dependent of clinical examination and radiographic imaging in order to evaluate the size of the primary tumor and the extent of local and distant disease. Since disease-free and overall survival rates seem to be strongly related with tumor staging, resection of the primary tumor and examination of local extension of the disease and regional lymph nodes involvement should be performed for a better pathologic tumor staging.

The following table describes the AJCC/UICC anatomic stages and prognostic groups:

Stage	T	N	M	Description
Stage I	T1	N0	M0	Tumor 5 cm or less in greatest dimension, no extra-adrenal invasion.
Stage II	T2	N0	M0	Tumor greater than 5 cm, no extra-adrenal invasion.
Stage III	T1	N1	M0	Tumor 5 cm or less in greatest dimension, no extra-adrenal invasion but with metastasis in regional lymph node(s).
	T2	N1	M0	Tumor greater than 5 cm, no extra-adrenal invasion but with metastasis in regional lymph node(s).
	T3	N0	M0	Tumor of any size with local invasion, but not invading adjacent organs*.
Stage IV	T3	N1	M0	Tumor of any size with local invasion, but not invading adjacent organs* plus metastasis in regional lymph node(s).
	T4	N0	M0	Tumor of any size with invasion of adjacent organs*.
	T4	N1	M0	Tumor of any size with invasion of adjacent organs* plus metastasis in regional lymph node(s).
	Any T	Any N	M1	Tumor of any size and with or without invasion of adjacent organs and lymph nodes, but with distant metastases.

Adapted from Edge, SB., Byrd, DR., Compton, CC., Fritz, AG., Greene, FL., Trotti, A. (Eds.). (2010). AJCC Cancer Staging Manual, 7th Ed. Springer, Chicago.

*Adjacent organs include kidney, diaphragm, great vessels, pancreas, spleen and liver.

Table 2. AJCC/UICC anatomic stages and prognostic groups

2.4 Adrenal cortex cancer treatment

For being a very rare and aggressive carcinoma the prognosis for patients with adrenocortical cancer is poor, also due to usually not being diagnosed in the early stages of the disease (Ng & Libertino, 2003; Harrison et al., 1999). Its rarity is one of the main reasons for the lack of robust clinical studies on the most efficacious treatments (Decker et al., 1991; Bukowski et al., 1993; Khan et al., 2000). Several studies and clinical trials, however, have shown that this trend in prognosis is changing and in fact patients with this type of carcinoma are living longer as progresses are being made in its treatment (Berruti et al., 2005; Adam et al., 2006; Allolio et al., 2004; Terzolo et al., 2007; van Ditzhuijsen et al., 2007; Fassnacht et al., 2011).

Currently, the only potentially curative treatment for adrenal cortex carcinomas is total resection of the tumor at the time of initial evaluation (Allolio et al., 2006; Dackiw et al., 2001). However, in a study of Haak and colleagues with 96 patients, the overall five-year survival rate after total resection was only 49% (Haak et al., 1994). This happens probably due to the presence of hidden micrometastases that will only become apparent some months to years later (Allolio & Fassnacht, 2006; Stojadinovic et al., 2002). In fact, many patients may develop distant metastases two or more years after the diagnosis date (Abiven et al., 2006).

Therefore, surgery in these patients must be as extensive as possible, with lymphadenectomy associated. One should be very careful to avoid capsular damage and the spill of malignant cells that may result in the development of metastasis (Terzolo et al., 2007; van Ditzhuijsen et al., 2007). Nowadays, open adrenalectomy is the most consensual operation type, since laparoscopy is associated with greater risk of malignant cells spread and therefore higher risk of recurrence or dissemination (Schteingart et al., 2005; Gonzalez et al., 2005; Cobb et al., 2005). Studies have also shown that whenever total resection is not possible, maximal debulking is associated with a decrease in excess of hormone production and with better overall survival when compared with non-surgical treatments (Ng & Libertino, 2003; Luton, et al., 1990).

Whenever surgery is not feasible or is unable to completely remove the tumor, mitotane (Lysodren), an adrenocorticolytic drug, was shown to be effective, either as a primary therapy or as an adjuvant therapy (Henley et al., 1983; Dackiw et al., 2001; Berruti et al., 2005; Terzolo et al., 2007; Luton et al 1990; Hahner & Fassnacht, 2005). Mitotane has a specific effect on adrenal cells resulting in their lysis (Hahner & Fassnacht, 2005).

As a primary treatment for unresectable tumors, mitotane is especially beneficial in improvement of symptoms associated with hypercortisolism. However this benefit tends to last for short periods of time, and is associated to inconsistent survival rates (Henley et al., 1983; Baudin et al., 2001).

In what concerns the adjuvant use of mitotane therapy, its benefits have been questioned mainly due to the lack of data from controlled clinical trials and even from large prospective studies with consistent assessments of dosing and tumor variability (Kendrick et al., 2001; Kopf et al., 2001). Despite the lack of robust data, several retrospective analyses have reported higher recurrence-free survival when compared to control groups and tumor regression rates of around 30% also being associated with a better control of hormone excess (Allolio & Fassnacht, 2006; Terzolo et al., 2007). Treatment with mitotane has especially good results in patients previously submitted to tumor resection, who begun therapy right after surgery and who are submitted to regular monitoring of mitotane plasma levels (Daffara et al., 2008).

When considering recurrent or advanced adrenocortical cancer, aggressive resection of local or distant disease is still considered to be an effective therapy method capable of increasing overall survival (Schteingart et al., 1982; Meyer et al., 2004). However, in these cases the use of cytotoxic drugs such as mitotane alone or in combination with other chemotherapeutic agents has to be utilized (Allolio & Fassnacht, 2006).

Mitotane is recommended even in patients with unresectable advanced disease, since several studies have reported the effectiveness of this drug in producing objective improvements in the majority of treated patients, despite its low impact on survival. Moreover, it has been demonstrated that cytotoxic activity of chemotherapeutic agents is increased when combined with mitotane in human adrenal carcinoma cells in vitro (Bukowski et al., 1993; Abraham et al., 2002). Despite the modest results found in the few prospective trials published until now, the combination of mitotane with different chemotherapeutic regimens resulted in overall response rates varying between 14 to 49% (Berruti et al., 2005; Khan et al., 2000; Abraham et al., 2002; Bonacci et al., 1998).

Other regimens of chemotherapy without mitotane have been also evaluated in a few clinical trials but showed modest response rates, revealing the need for the development of more and better drugs and well-designed prospective trials (Schlumberger et al., 1988; Quinkler et al., 2008; Khan et al., 2004).

One must be conscious that progresses in this cancer treatment are limited and slow. More clinical trials and large prospective studies are necessary to better support physicians' choices of treatment. An example of those trials was the recently concluded "First International Randomized trial in locally advanced and Metastatic Adrenocortical Carcinoma Treatment" (FIRM-ACT), an international clinical study comparing the efficacy of etoposide, doxorubicin and cisplatin (EDP) plus mitotane versus streptozotocin plus mitotane in patients with metastatic adrenocortical cancer. This sufficiently large prospective study gave support to the use of the first therapeutic combination (EDP+mitotane) in these conditions (Fassnacht et al., 2011).

The use of radiation therapy or radiofrequency ablation are the least studied hypothesis. They are mainly beneficial in patients with unresectable local tumors with local symptoms or symptomatic metastasis (Scheingart et al., 2005; Polat et al., 2009; Magee et al., 1987). Their impact in patients' survival is still unknown and needs further investigation (Wood et al., 2003; Mayo-Smith et al., 2004).

In the future one may expect that the understanding of the specific molecular alterations in these malignant cells can identify suitable therapeutical targets that may significantly improve the prognosis for these patients.

3. Primary hyperaldosteronism/Conn's syndrome

The synthesis of aldosterone by the adrenal glands occurs in the *zona glomerulosa*. The major conditions for the production of this hormone such as the low concentration of 17-alpha-hydroxylase and the ability to add an hydroxyl group at the 18-carbon position and its subsequent oxidation to an aldehyde, only occur in the *zona glomerulosa* and this processing is mediated by a single multifunctional cytochrome P450 - CYP11B2 or Aldo Synthase (White et al., 1987; White, 1994; Ulick et al., 1992; Holland & Carr, 1993).

The aldosterone-producing adenoma was first described by Conn in 1954 (Conn, 1955; Young, 2007a), who also established for the first time the relationship between adrenal aldosterone-producing tumors, hypertension, and hypokalemia (Gittler & Fajans, 1995). In addition to the aldosterone-producing adenoma (APA), other subtypes of primary aldosteronism (PA) have been described over the subsequent four decades (Conn, 1955; Conn, 1964; Gittler & Fajans, 1995; Young, 2007a; Stowasser, 2009). The most common is the bilateral idiopathic hyperaldosteronism (IHA) which represent approximately 70% of all PA cases (while APA, approximately 30%). Other forms include unilateral hyperplasia or primary adrenal hyperplasia (caused by hyperplasia of the *zona glomerulosa* of only one adrenal gland), familial hyperaldosteronism type I (glucocorticoid-remediable aldosteronism - GRA) caused by the existence of an hybrid gene composed of the CYP11B1 promoter and CYP11B2 gene in which aldosterone is produced in response to ACTH and hence responds to glucocorticoid mediated suppression of ACTH, familial hyperaldosteronism type II (the familial occurrence of aldosterone-producing adenoma or bilateral idiopathic hyperplasia or both), and also the familial or sporadic occurrence of APA due to a mutation in the gene of the K⁺ channel (KCNJ5) (Choi et al., 2011).

Finally, in spite of being very rare, pure aldosterone-producing adrenocortical carcinomas and ectopic aldosterone-secreting tumors (e.g. neoplasms in the ovary or kidney) may also occur.

The screening of PA is done by the demonstration of an elevated aldosterone level (> 15 ng/dl) together with the suppression of Plasma Renin Activity (PRA), translated in an

increased Aldosterone (*in ng/dl*)/PRA (*in ng/ml/h*) ratio above 20 or 40 (accordingly to the desired sensitivity).

Then a confirmatory test is needed and this can be done by one of the following tests:

- fludrocortisone suppression test
- oral salt load
- saline infusion test
- Captopril test

Since these tumors are generally very small, CT scan has a low sensitivity to localize them, and the fact that in people above 40 to 50 years of age, the prevalence of incidentalomas is high makes its specificity also decrease. Therefore the gold standard for a correct diagnosis of APA is Adrenal Venous Sampling in spite of the fact that it is an invasive method with a good success rate only in the hands of experienced radiologists.

During the past two decades it has become increasingly recognized that primary aldosteronism is much more common than previously thought. It is currently acknowledged that primary aldosteronism accounts for up to 5–10% of hypertensive patients, correlating with the severity of hypertension and going up to 20% in cases of resistant hypertension (i.e. one that does not respond to 3-drug-regimen).

The clinical features of PA are mostly determined by the renal actions of aldosterone. Its diagnosis is more frequently made in patients who are in the third to sixth decades of life, with resistant hypertension, accompanied by marked hypokalemia, possibly muscle weakness and cramping, headaches, palpitations, polydipsia, polyuria, nocturia, or a combination of these. There is, however, generally a characteristic lack of edema!

Hypokalemia, once the most important “screening” method for PA is observed less and less frequently both due to the sodium restriction that most doctors recommend to their patients with high blood pressure and also to the higher prevalence of BAH *vs* APA observed in the more recent series.

Patients' elevated blood pressure is a major clinical finding in PA (Mattsson & Young, 2006; Young, 2007a). However, PA is rarely associated with malignant hypertension (Zarifis et al., 1996). In a study of Blumenfeld and colleagues, the mean blood pressure was 184/112 mmHg in patients with an adrenal adenoma and 161/105 mmHg in patients diagnosed with bilateral hyperplasia (Blumenfeld et al., 1994). One important and special feature associated with PA hypertension is the failure to achieve the goal blood pressure (BP) despite a complete adherence to a multi-drug regimen of treatment.

It was also clearly demonstrated that aldosterone excess has direct adverse cardiovascular consequences that go well beyond the risks associated with this type of hypertension (Stowasser, 2009). Aldosterone is responsible for the development of myocardial fibrosis aggravating the prognosis post myocardial infarct (MI) and in congestive heart failure (CHF).

Cardiovascular risk factors seem to be more severe with PA, since when matched for age, blood pressure and the duration of hypertension, these patients have greater left ventricular mass measurements when compared to patients with other types of hypertension, including essential hypertension, pheochromocytoma, and Cushing's syndrome (Milliez et al., 2005; Tanabe et al., 1997). Also, in a case-control study of 124 patients with PA and 465 patients with essential hypertension, matched for age, sex, and systolic and diastolic blood pressure, it was found that patients presenting with either APA or bilateral hyperplasia had a significantly higher rate of cardiovascular events (e.g. stroke, atrial fibrillation and myocardial infarction) than the matched essential hypertension patients (Milliez et al., 2005).

Furthermore, some particular renal effects may be also experienced by PA patients, independently of their systemic hypertension. Several reports have shown that glomerular filtration rate (GFR) and urinary albumin excretion may be increased in these patients; however these changes appear to be largely reversible after appropriate treatment. Adrenalectomy increased the serum creatinine and decreased the mean GFR. Treatment with spironolactone resulted in a similar decline in GFR. Thus, surgical cure or mineralocorticoid receptor blockade reverse the hyperfiltration state and unmask the underlying renal insufficiency (Stowasser, 2009).

One final point to be stressed in relation to PA is that generally APA should be treated surgically while bilateral adrenal hyperplasias are better treated medically with mineralocorticoid inhibition by means of spironolactone, eplerenone or amiloride. Nevertheless, even APAs, specially the small ones, may also be treated appropriately with these drugs and hence, the choice should always be given to the patients.

4. Androgen-secreting adrenal cortex tumors

Androgen-secreting adrenal cortex tumors are rare tumors, accounting for only 0.2% of the causes of androgen excess (Azziz et al., 2004; Carmina et al., 2006). Androgen over-secretion results in the development of androgenic features in affected women, with the development of hirsutism, androgenic alopecia, acne, ovulatory dysfunction, and, if the oversecretion is extreme or prolonged, even virilization may ensue (Wajchenberg et al., 2000; Azziz et al., 2004).

Despite the fact that benign androgen-secreting adrenal tumors have been described, the finding of androgen secretion by an ACT is considered to be highly suggestive of malignancy. The presence of a virilizing adrenocortical carcinoma can be suggested by very high testosterone levels and the failure of androgen suppression in response to glucocorticoid administration (Kaltsas et al., 2003; Waggoner et al., 1999; Derksen et al., 1994). In a report of 21 women with androgen-secreting tumors, serum testosterone levels were 2.6-fold higher in the women with malignant tumors (n=10) than in women with benign tumors (n=11) (Moreno et al., 2004).

Benign cortisol-secreting adenomas can also produce small amounts of androgens, but the serum androgen levels are usually not elevated (Kamenicky et al., 2007).

Considering its elevated probability of malignancy it is of great importance to identify patients with this type of rare carcinomas among women with androgen excess, due to its life-threatening potential (Wajchenberg et al., 2000). Despite several authors having considered that a clinical presentation with rapidly progressive virilization was sufficient to identify patients requiring a more extensive investigation (Kettel, 1989), it is consensual that some androgen-secreting adrenocortical tumors may produce only moderate levels of androgens and have a rather indolent presentation (Rosenfield, 2005; Kaltsas et al., 2003).

It should also be noticed that androgen-secreting tumors in men same as estrogen secreting tumors in women, may not result in clinically significant syndromes, and both can be erroneously considered as non-functioning, delaying their treatment. If one doesn't apply an extensive analytical protocol to nonfunctioning adrenocortical tumors, only the development of mass effects or the occurrence of metastases would lead to their recognition as malignant.

5. Estrogen-secreting adrenal cortex tumors

Estrogen-secreting adrenal cortex tumors correspond to a very rare type of tumors characterized by the over-production of estrogens (estrone or estradiol). The over-secretion of these hormones may cause precocious puberty with very early menarche in girls and more often sex-reversal characteristics in men (feminizing symptoms) (Advani et al., 2010). The feminizing symptoms, such as the characteristic gynecomastia, are associated with the expression of the cytochrome P450 aromatase (aromatase) in adrenocortical cells. Normally, aromatase catalyses the conversion of C19 steroids into estrogens in tissues such as the ovarian follicles' granulosa layer and the adipose tissue, whereas normal adrenal tissues have no detectable aromatase activity (Watanabe & Nakajin, 2004).

6. Cushing's syndrome

The Cushing's syndrome was first described by Harvey Cushing in 1932, and can be caused by several mechanisms associated with increased levels of cortisol in the blood. The diagnosis of Cushing's syndrome is determined through biochemical tests, since the presence of suggestive symptoms and signs are not enough to sustain it. In fact none of its symptoms is pathognomonic and most of them are non-specific such as obesity, hypertension and increased cardiovascular risk, menstrual irregularity and infertility, osteoporosis and glucose intolerance. It can also cause some form of psychological distress, going from impaired quality of life to depression and even psychosis. It should always be borne in mind, however, that if left untreated, Cushing's syndrome has a 5 fold excess mortality.

The high levels of cortisol in the blood can be caused not only by adrenocortical tumors but also by adrenocorticotrophic hormone (ACTH) or corticotropin-releasing hormone (CRH) hyperproduction, as well as by the excessive intake of glucocorticoid drugs. This is even one of the most frequent causes of Cushing's syndrome (Iatrogenic Cushing's). In the study of a Cushing's syndrome case these situations need to be excluded (Weber SL., 1997; Hughes et al., 1996; Quddusi et al., 1998). Moreover, special attention is also required for other disorders causing hypercortisolism-related symptoms and sometimes also exhibiting mild to moderate elevations of plasma cortisol, known as pseudo-Cushing's syndrome. The pseudo-Cushing's syndromes may include:

- Patients who are physically stressed (e.g. severe bacterial infections) (Liddle, 1960);
- Patients with severe obesity, especially visceral obesity or polycystic ovary syndrome (Liddle, 1960);
- Patients with psychological stress (major depressive disorder and severe melancholic syndromes) (Gold et al., 1986);
- Rarely, also patients with chronic alcoholism (Kirkman & Nelson, 1988).

The difficulties normally met in Cushing's syndrome diagnostic process are well translated by the fact that patients normally express some signs and symptoms of the syndrome, 2 years before a confirmation of diagnosis can be reached. After raising the suspicion by the observation of a patient with central (truncal) obesity plus hypertension, in many cases accompanied by a typical cushingoid facies (round, plethoric face), the most specific signs are the presence of thin skin, easy bruising and proximal myopathy. However, to avoid mistakes in diagnosing Cushing's syndrome due to all of the different conditions that might imitate its signs and symptoms, initial diagnostic tests for hypercortisolism must be highly

sensitive. According to the evidence-based 2008 Endocrine Society Clinical Guidelines the *first-line tests* for this syndrome should be the late night salivary cortisol, the 24h urinary cortisol, or the low-dose dexamethasone suppression test (either the 1 mg, overnight or the 2mg/day, 48h dexamethasone suppression tests). To establish the diagnosis of Cushing's syndrome the following criteria should be met (Nieman et al., 2008):

- At least two of the first-line tests must be abnormal and conservative criteria should be used to interpret it to maximize sensitivity; for instance, in a patient with a symptomatic Cushing's syndrome, the cortisol cutoff level to be considered as un-suppressed after the Dexamethasone test should be $>1.8 \mu\text{g/dl}$ (while in the case of incidentalomas studied to exclude subclinical Cushing's syndrome, specificity should be the main criterion and so the cutoff level should be $>5 \mu\text{g/dl}$).
- Urinary and salivary cortisol measurements should be obtained at least twice;
- The urinary cortisol excretion should be unequivocally increased (threefold above the upper limit of normal for the assay), or the diagnosis of Cushing's syndrome is uncertain and other tests should be performed;
- The patient should undergo additional evaluation if the test results are discordant or only slightly abnormal;
- If test results are normal, the patient does not have Cushing's syndrome unless it is extremely mild or cyclic. Additional evaluations are not suggested unless symptoms progress or cyclic Cushing's syndrome is suspected.

Cushing's syndrome is rare (it has an incidence of up to 3:1.000.000 persons per year) (Lindholm et al., 2001). It's also an intriguing condition both because of its complex diagnostic protocol and the demand for a correct treatment to avoid its devastating complications that can even conduct to death if left untreated. After diagnosing the hypercortisolism, it is important to determine its cause (Table 3) to better chose the appropriate treatment. It is a disease whose patients should be sent to a major hospital where multidisciplinary and well experienced teams will be available.

Diagnosis	Percentage of Patients (%)
ACTH-dependent Cushing's syndrome	
Cushing's disease	68
Ectopic ACTH syndrome	12
Ectopic CRH syndrome	< 1
ACTH-independent Cushing's syndrome	
Adrenal adenoma	10
Adrenal carcinoma	8
Micronodular hyperplasia	1
Macronodular hyperplasia	< 1
Pseudo-Cushing's syndrome	
Major depressive disorder	1
Alcoholism	< 1

Table 3. Frequency of causes of Cushing's syndrome

One of the most important, and therefore the initial, phase of determining Cushing's syndrome's etiology is to determine if the hypercortisolism is ACTH-dependent or ACTH independent. The ACTH-dependent hypercortisolism is normally due to a pituitary (or less frequently non-pituitary) ACTH secreting tumor, while ACTH-independent hypercortisolism is usually due to an adrenal tumor or hyperplasia. The preferred test is naturally the measurement of plasma ACTH. Usually a low plasma ACTH concentration of <5 pg/mL (1.1 pmol/L) in a hypercortisolemic patient is evidence of ACTH-independent disease (Invitti et al., 1999), while if the plasma ACTH concentration is above 15 pg/mL (3.3 pmol/L) it can be assumed that cortisol secretion is ACTH-dependent. Despite values between 5 and 15 pg/mL (1.1 to 3.3 pmol/L) being less definitive they normally indicate the hypercortisolism is ACTH-dependent. However, it is recommendable to perform a CRH stimulation test in these patients to confirm that hypothesis.

In the presence of an ACTH-independent Cushing's syndrome, it is important to proceed with a thin-section CT imaging of the adrenal glands, to determine its cause. When CT imaging suggests a suspicious lesion (for instance with large size) further investigation will be required to distinguish between the malignant ACC and benign ACT. The presence of bilateral disease on the other hand implies the distinction between, for instance, a bilateral tumor and bilateral macronodular adrenal hyperplasia.

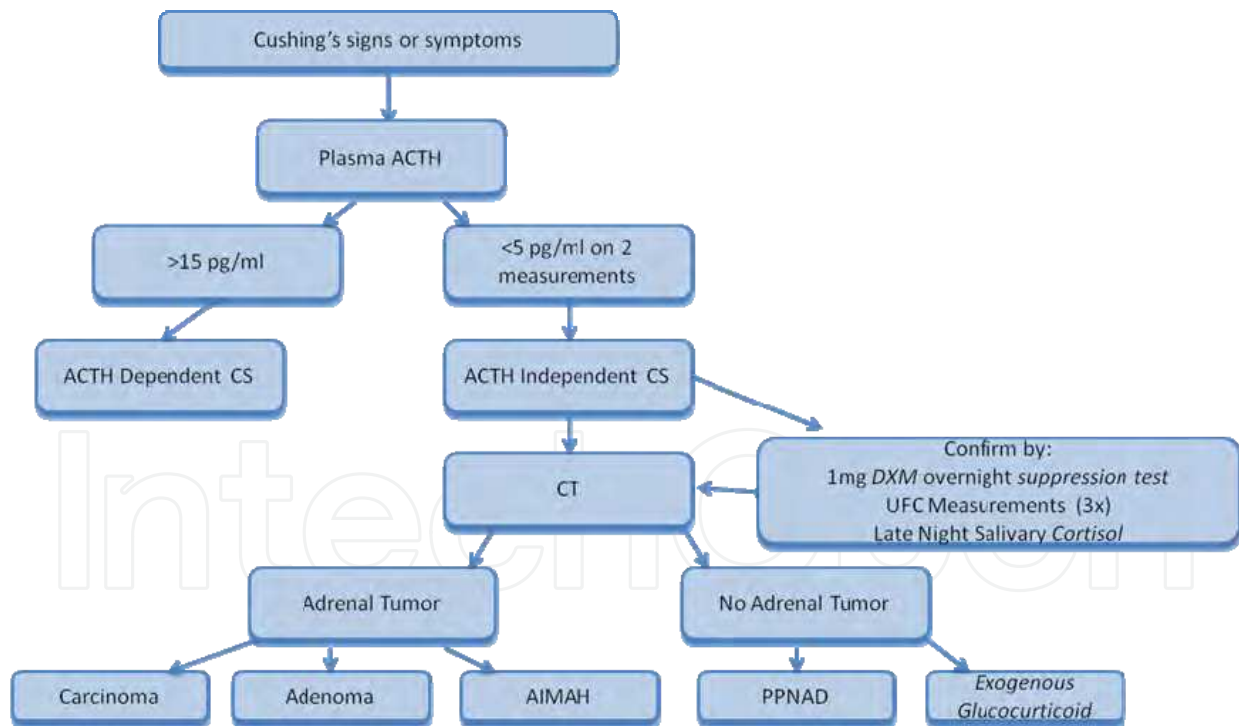


Fig. 2. Cushing syndrome

Unilateral adenomas causing Cushing's syndrome should be surgically removed as they imply a very significant increase in morbidity and mortality, which is due to cardiovascular diseases or infections.

For the great majority of ACTH-dependent Cushing's syndrome patients, the cause of the hypercortisolism is a pituitary corticotroph adenoma (Cushing's disease). Even so,

patients with ACTH-dependent disease should undergo non-invasive tests such as the high-dose dexamethasone suppression test and the CRH stimulation test, to confirm the presence of Cushing's disease. It is also important to exclude extrapituitary (ectopic) sources of ACTH.

7. Subclinical Cushing's syndrome

The "subclinical" Cushing's syndrome (SCS) refers to autonomous cortisol production that is insufficient to generate the typical, clinically recognizable, combination of symptoms. The prevalence of overt Cushing's syndrome caused by an adrenal adenoma in the general population is lower than the prevalence of subclinical Cushing's syndrome in patients with clinically non-functioning adrenal adenoma (Ross, 1994).

Patients with SCS have an adrenal mass usually detected incidentally (an incidentaloma) and normally do not show any of the clinical manifestation of the Cushing's syndrome (Terzolo et al., 2005a). Still, they have some endocrine alterations that allows their recognition (Urinary free cortisol $> 70 \mu\text{g} / 24\text{h}$; serum cortisol levels after a dexamethasone suppression test $> 5 \mu\text{g}/\text{dl}$; morning ACTH levels $< 10 \text{pg}/\text{ml}$). According to the Italian National survey on 1,004 adrenal incidentalomas (Mantero et al., 2000), of which 92 were classified as SCS, the hormonal evaluation showed low baseline secretion of ACTH in 79% of the SCS patients, lack of suppressibility of cortisol secretion after 1 mg dexamethasone in 73%, supra-normal 24-hour urinary cortisol excretion in 75% or disturbed cortisol circadian rhythm in 43%. Subclinical Cushing's syndrome is the most commonly detected abnormality in patients with adrenal incidentalomas.

Most patients with SCS may show one or more of the clinical manifestation of cortisol over-secretion, such as arterial hypertension, obesity or diabetes (Terzolo et al., 2000; Angeli & Terzolo, 2002). The association between a clinically silent adrenal adenoma and some of clinical manifestations of the metabolic syndrome has been studied and is considered well proven. In a retrospective study done by Terzolo and colleagues (Terzolo et al., 2005b), of 210 such patients, 53.8% had hypertension, 21.4% were obese and 22.4% had hyperglycemia.

8. Incidentalomas

An adrenal incidentaloma is a mass lesion, usually with 1cm or more in diameter, discovered incidentally by radiologic examination (Young, 2007b). In recent years these incidentally discovered adrenal masses have been found with increasing frequency due to the widespread use of imaging techniques of the abdomen and their prevalence is estimated to be around 4% in the general population (Bovio et al., 2006). Several studies have been published concerning the prevalence of adrenal incidentalomas. In a series of 739 autopsies, Hedeland and colleagues (Hedeland et al., 1968) reported the presence of adrenal masses in 9% of normotensive patients versus 12% in patients with hypertension. In another review including 25 studies (Kloos et al., 1995), the calculated prevalence of adrenal incidentaloma was of 6%. The prevalence of adrenal adenomas increases with age from 0.2% in a patient between 20 and 29 years of age to 7% in a patient over 70 years of age (Young, 2007; Kloos et al., 1995). It is noteworthy that they are rare under the age of 40.

Despite the fact that the majority of adrenal incidentalomas are clinically non-hypersecreting and benign adrenocortical adenomas (Mansmann et al., 2004), frequently, incidentalomas' series include cases that are cortisol secreting adrenocortical adenomas (5 to 9%) (Mantero et al., 2000; Young 2007) or pheochromocytomas (3 to 5%) (Young, 2007; Cawood et al., 2009). Of these pheochromocytomas, 50% are normotensive (Motta Ramirez et al., 2005). Incidentalomas can also be adrenocortical carcinomas and metastatic carcinomas. In a group of 2005 patients with adrenal incidentalomas, almost 5% were adrenocortical carcinomas and 2.5% corresponded to other primary carcinomas' metastases (Young, 2000).

The approach to the evaluation and management of adrenal incidentalomas usually begins with taking patients' clinical history and performing a physical examination, testing for signs or symptoms of adrenal hyperfunction or malignant disease, and performing a complete hormonal evaluation (Young, 2007; Kudva et al., 2003; Terzolo et al., 2005).

The probability to find a primary adrenal carcinoma in these cases has to be considered as rare, in spite of being dependant on the size of the tumor (above 4 cm the probability of an incidentaloma being malignant is 24% (Angeli et al., 1997); however, due to the importance of such a situation the initial major concern in evaluating an adrenal incidentaloma is the possibility of malignancy, followed by the evaluation of the possibility of metastatic cancer. In fact, one should also remember that several types of carcinomas may metastasize to the adrenal glands (e.g. lung, kidney, colon, breast, pancreas, liver and stomach).

Adrenal incidentalomas are bilateral in 10-to 15% of the cases. In these cases the etiology will be one of the following: metastases; congenital adrenal hyperplasia; bilateral adenomas, bilateral adrenocortical macronodular hyperplasia; bilateral pheochromocytomas; hemorrhage, lymphoma; infectious or infiltrative diseases.

As a main conclusion we would like to stress that it is of crucial importance to evaluate all patients with adrenal incidentalomas for the possibility of either subclinical hormonal hyper-function, including SCS and pheochromocytoma, as well as cancer. Table 4 describes major evaluations and clinical features for differential diagnosis of adrenal incidentalomas.

9. Pediatric adrenal cortex tumors

The presence and diagnosis of adrenal cortex tumors in children is rare and may occur sporadically or as a component of certain hereditary tumour syndromes, such as the Li-Fraumeni syndrome, the multiple endocrine neoplasia-1 (MEN1), the Beckwith-Wiedemann syndrome, the Carney complex, and even in some rare cases of congenital adrenal hyperplasia. Its incidence is around 1 to 3 in 10.000.000 except in the southern regions of Brazil where it reaches 1 to 3 :1.000.000 (Agrons et al., 1999; Ribeiro et al., 2000, Wasserman et al., 2011).).

In southern Brazil, these carcinomas are frequently associated with a particular mutation of TP53 (namely Arg337His) (Ribeiro et al., 1990).

Clinical and biological characteristics of adrenocortical tumours are different from those observed in other paediatric carcinomas. About 65% of them are diagnosed in children younger than 5 years of age (Ribeiro et al., 1990). This age distribution has been demonstrated in several reports, including a study of Zerbini and colleagues, with 32 pediatric patients with adrenocortical neoplasms, in which the age at diagnosis ranged from 6 months to 19 years (median age, 5 years), with a predominant number of patients being 5 years of age and younger (Zerbini et al., 1992). In another study of Lefebvre and colleagues, with 42 children with adrenocortical neoplasms, two-thirds were younger than 5 years of age (Lefebvre et al., 1983).

Diagnosis	Suggestive Clinical Features	Imaging Characteristics
Adrenocortical Adenoma	May have symptoms related to excess glucocorticoid, mineralocorticoid, androgen, or estrogen secretion	<ul style="list-style-type: none"> • Round or oval, with smooth margins • Homogeneous • Rare tumor calcification, necrosis or hemorrhage • Small, usually ≤ 3 cm in diameter • Usually solitary, unilateral • CT unenhanced attenuation values ≤ 10 HU (25% may have low lipid content and hence have attenuation values $>10\%$) • Not highly vascular • Isointense in relation to liver on T1- and T2-weighted images in MRI • No delay in contrast medium washout (ten minutes after administration of contrast, an absolute contrast medium washout of 50 % or more)
Adrenocortical carcinoma	Mass effect symptoms, symptoms related to excess glucocorticoid, mineralocorticoid, androgen, or estrogen secretion. The size ($>4/6$ cm) and the evolution are the most important signs to raise the suspicion	<ul style="list-style-type: none"> • Irregular shape • Inhomogeneous density because of central areas of low attenuation due to tumor necrosis • Common tumor calcification • Diameter usually >4 cm • Unilateral location • High unenhanced CT attenuation values (>20 HU) • Inhomogeneous enhancement on CT with intravenous contrast • Delay in contrast medium washout (ten minutes after administration of contrast, an absolute contrast medium washout of less than 50 %) • Hypo-intensity compared with liver on T-1 weighted MRI and high to intermediate signal intensity on T-2 weighted MRI • High standardized uptake value (SUV) on FDG-PET-CT study • Evidence of local invasion or metastases.

Diagnosis	Suggestive Clinical Features	Imaging Characteristics
Pheochromocytoma	Hypertension, Paroxysmal Symptoms (e.g. palpitation, diaphoresis, headache, pallor, tremor). Half of the cases will remain undiagnosed! Plasma metanephrines and 24h urine metanephrines are the initial screening tests	<ul style="list-style-type: none"> • Round or oval, with clear margins • Heterogeneous, with cystic areas • Usually large • Usually solitary, unilateral • High unenhanced CT attenuation values (>10 HU) (usually >25) • Usually vascular • Delay in contrast medium washout (ten minutes after administration of contrast, an absolute contrast medium washout of less than 50 percent) but may be normal, mimicking the adenomas • Markedly hyper intense in relation to the liver on T2-weighted images, in MRI • Chemical-shift imaging: Pheos and ACC don't lose signal intensity on out-of phase images in comparison with in-phase ones, whereas adenomas do • Hemorrhage and cystic areas common
Metastatic Cancer	Cancer-specific signs. The identification of a primary extra-adrenal cancer favors this possibility	<ul style="list-style-type: none"> • Irregular shape and inhomogeneous nature • Tendency to be bilateral • High unenhanced CT attenuation values (>20 HU) and enhancement with intravenous contrast on CT • Delay in contrast medium washout (ten minutes after administration of contrast, an absolute contrast medium washout of less than 50 percent) • Isointense or slightly less intense than the liver on T-1 weighted MRI and high to intermediate signal intensity on T-2 weighted MRI (representing an increased water content)

Adapted from Young WF, Jr. Clinical practice. The incidentally discovered adrenal mass. N Engl J Med 2007a; 356: 601-10

Table 4. Clinical features and imaging characteristics of adrenal incidentalomas

About half of the adrenocortical tumours in children have predisposing constitutional genetic factors, and are usually associated with the Li-Fraumeni syndrome or the Beckwith-Wiedemann syndrome (Li & Fraumeni, 1969a; Wiedemann, 1983; Lynch et al., 1978).

The Li-Fraumeni syndrome is a cancer-predisposing syndrome that includes breast cancer, brain carcinoma, sarcomas, leukaemia and adrenocortical carcinoma (Li & Fraumeni, 1969a; Lynch et al., 1978). This syndrome is a rare autosomal dominant condition associated with germline mutations of the tumour suppressor gene TP53 on the chromosome 17 (17p13) (Li & Fraumeni, 1969b; Li et al., 1998;). The patient and the affected family members may develop different types of tumours (Birch, 1994; Srivastava et al., 1990; Sandrini et al., 1997; Hisada et al., 1998).

On the other side the Beckwith-Wiedemann syndrome, associated with abnormalities involving chromosome 11p15, and defined as a growth disorder is sometimes referred to as the EMG [exomphalos-macroglossia-gigantism] syndrome. This syndrome is associated with an increased risk of benign and malignant tumors of multiple organs (Fraumeni & Miller et al., 1967; Wiedemann, 1983), particularly the Wilms tumor of the kidneys and adrenocortical carcinoma (Lack, 1997).

The incidence of adrenocortical carcinomas in children is higher in girls. These pediatric carcinomas are hormone secreting tumors more frequently than in adults (90% vs 50%) (Michalkiewicz et al., 2004; Patil et al., 2002; Bonfig et al., 2003). The classic endocrine syndromes (namely the virilising and the Cushing's syndromes) represent the most common presentations of adrenocortical carcinomas in this age group (Wilkins, 1948 and Ribeiro et al., 2000).

However in spite of being pathologically malignant these carcinomas have a much better prognosis, with many of them becoming cured by the first surgical intervention (Michalkiewicz et al., 2004; Sutter et al., 2006; Wieneke et al., 2003; 27: Sabbaga et al., 1993)

10. ACTH-independent adrenal cortex hyperplasias

ACTH-independent hypercortisolism is always of adrenocortical origin and an adrenocortical adenoma or carcinoma are by far its most common aetiologies (in up to 95% of patients). The remaining cases will be adrenocortical hyperplasias.

Even in these cases it's important to distinguish adrenocorticotropin (ACTH)-dependent forms like Cushing's disease or CAH (due to 21-hydroxylase deficiency) from ACTH-independent ones as a primary step in the differential diagnosis of Cushing's syndrome due to adrenocortical bilateral hyperplasias (Doppman et al., 2000).

Among the adrenal causes of Cushing's syndrome about 10-15% are due to bilateral adrenal lesions that include micronodular (particularly its most common variant the *Primary Pigmented Nodular Adrenocortical Disease - PPNAD*) and macronodular adrenal hyperplasias (*ACTH-Independent Macronodular Adrenocortical Hyperplasia - AIMAH*) and, more rarely, bilateral adenomas or carcinomas (Christopoulos et al., 2005; Stratakis & Boikos, 2007).

The hyperplasias can be sporadic or familial as is the case of PPNAD that can occur isolated or as part of an autosomal dominant disease including other tumors, endocrine and non-endocrine, called the Carney Complex.

Many adrenal cortex hyperplasia cases are thought to be the consequence of genetic changes in several key components of the cyclic AMP (cAMP) pathway (Libé & Betherat, 2005; Groussin et al., 2002a; Stratakis et al., 2007). Activating germline mutations of the ACTH receptor (MC2R) gene, making it display high levels of basal activity, have been reported

(Swords et al., 2002). The same occurred with GNAS activating mutations resulting in constitutive activation of the cAMP pathway that were shown to cause ACTH-independent macronodular adrenocortical hyperplasia (AIMAH) in McCune-Albright syndrome (Weinstein, 1991). On the other hand PRKAR1A-inactivating mutations resulting in a permanent activation of PKA may be associated to the development of PPNAD either isolated or as part of the Carney complex (Kirschner et al., 2000; Groussin et al., 2002b). More recently, inactivating mutations of the phosphodiesterase 11A gene, a gene coding for an enzyme that normally regulates cyclic nucleotide levels was reported both in cases of PPNAD and other bilateral hyperplasias (e.g. macronodular) (Libé et al., 2008).

11. ACTH-independent macronodular hyperplasias

The ACTH-independent macronodular adrenocortical hyperplasias (AIMAH) constitute a rare condition that consists of multiple bilateral adrenocortical macronodules causing a striking enlargement of the adrenal glands (Doppman et al., 1991; Malchoff et al., 1989; Swain et al., 1998). The great majority of AIMAH cases is sporadic. AIMAH is responsible for less than 1% of all the endogenous cases of Cushing's syndrome (Christopoulos et al., 2005). Usually patients present in the fifth and sixth decades of life, a significantly latter age of onset compared to other cortisol producing adenomas (Swain et al., 1998).

11.1 AIMAH pathogenesis

Increased cortisol levels in AIMAH result from the fact that hormones other than ACTH become able to activate cortisol secretion through receptors aberrantly located in the adrenal cortex cells and coupled to cAMP activation. Hormones like GIP, catecholamines, vasopressin, serotonin, LH among others can activate PKA signaling, via cAMP production, leading to a situation of Cushing's syndrome.

In fact a great number of patients with AIMAH have that ectopic expression of and/or increased responsiveness to one of several possible receptors like the gastric inhibitory polypeptide (GIP) receptors (food-dependent hypercortisolism) (Resnik et al., 1992; N'diaye et al., 1998), vasopressin receptors (Horiba et al., 1995), the β -adrenergic receptors (Lacroix et al., 1997), the LH receptors, the serotonin receptors, the leptin receptors and angiotensin II receptors (Lacroix et al., 1997; Lacroix et al., 2001; Lacroix et al., 1992).

In the example of GIP-activated-cortisol-production, k cells from the duodenum and small intestine release, after food ingestion, a gastro-intestinal hormone named GIP (Gastric Inhibiting Peptide or Glucose-dependent Insulinotropic Peptide) in physiological concentrations (Lacroix et al., 2001). The expression of GIP receptors in the cells of the *zona fasciculata*, where they normally don't exist, can then be activated by the GIP secreted in response to meals, causing what is known as "food-dependent" cortisol production. The presence of this receptor can be confirmed *in vivo* by clinical testing or by adrenal imaging following the injection of [123 I]-GIP (Lacroix et al., 1992).

To date, more than 30 cases were reported where the adrenal hormonal hypersecretion was associated to GIP stimulation. In the majority of cases patients presented with AIMAH (Lacroix et al., 2004; Groussin et al., 2002c). Besides that, other receptors were identified, some ectopically expressed and some being eutopic but showing an over-expression in the adrenocortical cells, as being the cause of cases of AIMAH and recently also demonstrated in cases of unilateral adenomas (Lacroix, 2009).

The majority of cases of AIMAH is sporadic. Some cases however are familial and in most an autosomal dominant hereditary has been described (Lacroix, 2009). Nevertheless, the

genetic cause for these cases hasn't yet been identified. In addition to those familiar reports, AIMAH has been described in MEN-1 with a frequency between 6% (Burgess et al., 1996) and 21% (Skogseid et al., 1992), and in rare cases of Gs alpha subunit mutations (Weinstein et al., 1991; Fragoso et al., 2003) or activating mutations of the ACTH receptor (MC2R) (Swords et al., 2002):

- **Gs alpha-subunit mutations** – an activating mutation in the gene of the Gsa subunit of G-protein coupled receptors (stimulatory guanine nucleotide-binding protein, Gs) leads to constitutive activation of cAMP. These mutations may be responsible not only for increased production of cortisol but also for increased proliferation and consequently the formation of adrenal nodules (Weinstein et al., 1991; Fragoso et al., 2003).
- **MEN1** – In patients with multiple endocrine neoplasia syndrome type 1 (MEN1) caused by mutations in the tumor suppressor gene *menin*, together with the more frequent endocrine tumors that are characteristic of the syndrome, adrenocortical adenomas or macronodular bilateral hyperplasias may also occur (Burgess et al., 1996; Skogseid et al., 1992).
- **Other genes** – There were some rare reports of activating mutations of the ACTH receptor (MC2R) gene in adrenal tumors and AIMAH (Swords et al., 2002). Moreover, AIMAH has also been reported in patients with: familial polyposis coli and a mutation in the adenomatous polyposis coli (APC) gene (Kartheuser et al., 1999); in patients with mutations in the fumarate hydratase gene (FH) (Matyakhina et al., 2005) on chromosome 1 (1q42.3-43); and in patients with germline mutations in phosphodiesterase 11A isoform 4 gene (PDE11A) (Libé et al., 2008) located on chromosome 2 (2q31-35).

11.2 AIMAH diagnosis and clinical presentation

Usually AIMAH cases can be discovered after an incidental radiological finding or following the investigation of an adrenal hypersecretion syndrome and can be distinguished from ACTH-dependent macronodular hyperplasia by a suppressed plasma ACTH (<5 pg/mL *vs.* ≥15 pg/mL).

The most common laboratory findings associated with AIMAH are the following:

- Increased serum and urinary cortisol and undetectable plasma ACTH in the basal state (Doppman et al., 2000; Swain et al., 1998; Kirschner et al., 1964; Bourdeau et al., 2001, Lieberman et al., 1994).
- As in any cause of adrenal cortisol hypersecretion, dexamethasone suppression test fails to suppress cortisol production (Christopoulos et al., 2005).

An exception to this general pattern occurs in patients with GIP-dependent Cushing's syndrome in whom cortisol hypersecretion occurs in response to meals and serum cortisol may be low in the fasting state (Resnik et al., 1992; Lacroix et al., 1992).

- Steroid hormone synthesis is relatively inefficient in AIMAH as a consequence of decreased steroidogenic enzymatic activity resulting frequently in elevated 17-hydroxyprogesterone levels after stimulation with ACTH (Bourdeau et al., 2001).
- Serum 18-hydroxycorticosterone, corticosterone and estrone may cause hypertension or feminization in the patients in whom they are increased (Wada et al., 2002).

The diagnosis of AIMAH is usually suspected after typical imaging studies, which can be variable. At the computed tomography (CT) the adrenal glands in patients with AIMAH are greatly enlarged with multiple macronodules up to 5 cm in diameter. These adrenals' weight may vary between 24 to 500g (Doppman et al., 2000; Malchoff et al., 1989).

The asymmetric appearance of the adrenal macronodules in AIMAH has been described (Liebermann et al., 1994; Lacroix et al., 2001) and also, according to a study including patients with surgically proven AIMAH, adrenal masses measuring up to 5 cm of soft tissue density can distort and obscure the adrenal glands (Doppman et al., 1991). This may conduct to the erroneous diagnosis of a unilateral adenoma.

Therefore, other clinical and molecular features must be used in diagnosing AIMAH.

One important suggestion consist of evaluating **all** patients with AIMAH and clinical and sub-clinical Cushing's syndrome for the presence of aberrant receptors, that are very frequently present in AIMAH (Lacroix et al., 2001; Mircescu et al., 2000).

In this scenario, tests that modulate the levels of ligands for those receptors may be useful determining cortisol and other steroid changes. These tests include physiological tests, such as upright posture and mixed meals, and pharmacological tests including gonadotropin-releasing hormone, thyrotropin-releasing hormone, vasopressin, glucagon and metoclopramide (Lacroix et al., 2001; Mircescu et al., 2000). Cortisol increases $\geq 25\%$ are considered as significant, provided there is no increase in ACTH. If necessary, these tests should be carried out under Dexamethasone suppression. Responses between 25% and 49% are considered partial responses and if $\geq 50\%$ complete responses. Any positive change should prompt the continuation of the study to identify all the receptors that may be involved (Lacroix et al., 2001)

The importance of identifying these aberrant receptors is the possibility to have specific therapeutical weapons that may permit avoiding bilateral adrenalectomy:

RECEPTOR	IN VIVO SCREENING	MEDICAL TREATMENT
GIP	Mixed meal (Food-dependent Cushing) Stimulation by GIP infusion	Octreotide GIPR antagonist
Vasopressin	Upright posture Inhibition by water load Stimulation by saline infusion Administration of Arginine Vasopressin Administration of DDAVP (- =V1R; + =V2R)	Vasopressin receptor antagonist DDAVP antagonist (V2)
B-adrenergic	Upright posture Stimulation by insulin-induced hypoglycemia Isoproterenol infusion Propranolol suppression	B-blocker (Propranolol)
LH/βHCG	GnRH test hCG Recombinant LH Pregnancy or Menopausal related cortisol elevation Sometimes also androgen secreting	Long acting GnRH agonist GnRH antagonist
5HT-4	Administration of 5HT-4 agonists Metoclopramide/Cisapride/Tegaserod test	5HT-4 receptor antagonist
Angiotensin	Upright posture Angiotensin infusion (?) Angiotensin antagonist	Angiotensin receptor antagonist

(Adapted from Lacroix et al., 2009 ACTH independent macronodular hyperplasia. Best Practice and Research Clinical Endocrinology and Metabolism. Vol 23. Pp 245-259)

Table 5. Receptors involved in AIMAH, in vivo screening tests and possible medical treatments

12. ACTH-independent micronodular hyperplasias

ACTH-independent micronodular hyperplasias are characterized by the presence of multiple cortical micronodules, with less than 1 cm in diameter (Louiset et al., 2010). These micronodular hyperplasias can be divided in two different subtypes, depending on the presence or absence of nodular pigment and internodular atrophy. The most common and predominant type of ACTH-independent micronodular adrenal hyperplasia is the primary pigmented nodular adrenocortical disease (PPNAD), characterized by multiple pigmented micronodules usually surrounded by internodular cortical atrophy. The pigmented nodules are observed in the zone between the cortex and the medulla and the cells have hybrid characteristics between cortical and medullar (for instance the high expression of synaptophysin). The pigment has been identified as lipofuscin (Louiset et al., 2010).

PPNAD is one of the possible causes of Cushing's syndrome. However, it must be stressed that it is a rare disease representing less than 1% of the cases of Cushing's syndrome. It may be sporadic or familial, and in this case it's one of the components of the Carney complex (Carney & Young, 1992; Stratakis et al., 2001).

12.1 ACTH-independent micronodular hyperplasia- pathogenesis

A few genes were already identified as causal for the development of ACTH-independent micronodular hyperplasia:

- **PRKAR1A** - Most patients with PPNAD, especially when the disease is a component of Carney complex, have germline-inactivating mutations of the PRKAR1A [protein kinase A (PKA) regulatory subunit type 1 α] gene (Kirschner et al., 2000; Groussin et al., 2002a; Groussin et al., 2002b). These mutations code for a truncated protein that is not produced, and the loss of this protein leads to an increased activation of protein kinase A (PKA) by cyclic AMP (Nadella & Kirschner, 2005). In several different studies of patients with PPNAD associated with Carney complex, 65-82% had PRKAR1A mutations (Groussin et al., 2002; Veugelers et al., 2004; Bertherat et al 2009).
- **Phosphodiesterase 11A (PDE11A)** - PDE11A is a dual-specificity PDE with affinity both to cAMP and cGMP, expressed in several endocrine tissues (D'Andrea et al., 2005). Decreased expression of PDE11A has been correlated to increased adrenocortical levels of cAMP and cAMP-responsive element (CREB) phosphorylation presumably being the cause of adrenal hyperplasia. Besides having been identified in PPNAD and non-pigmented micronodular bilateral adrenocortical hyperplasias, in a study of Libé and colleagues, the PDE11A missense germline variants were also found in 18.8% of adrenocortical tumors (adrenocortical carcinomas, adenomas and bilateral macronodular adrenal hyperplasias) (Libé et al., 2008).
- **Other genes** - PDE8B gene mutations have also been described in patients with PPNAD or nonpigmented variants of the disease (Horvath et al., 2008).

Moreover, in addition to germline PRKAR1A mutations, somatic beta-catenin mutations have been found in the larger nodules of patients with PPNAD, suggesting that secondary events in the Wnt/beta-catenin signaling pathway can contribute to tumorigenesis in PPNAD (Tadjine et al., 2008; Gaujoux et al., 2008).

12.2 ACTH-independent micronodular hyperplasia – Diagnosis and clinical presentation

Most commonly patients with PPNAD present signs and symptoms of hypercortisolism such as weight gain, obesity, hypertension, and menstrual cycle disorders. However, in many of them these symptoms are subtle and slowly progressive. Besides, sometimes the cortisol hypersecretion can be cyclical rendering these cases difficult to diagnose. On the other hand, there are several characteristics that are unique to this type of micronodular hyperplasia (Carney & Young, 1992; Larsen et al., 1986; Stratakis et al., 2001).

- The majority of patients with PPNAD are diagnosed at a young age, usually before turning 30 years, and many cases occur in patients under 15 years of age.
- Another hallmark is the paradoxical cortisol response to Dexamethasone suppression test, meaning that cortisol raises in response to dexamethasone instead of being reduced (Stratakis et al., 1999).
- At surgery the characteristic pigmentation can be observed.
- Most of the nodules found in these patients are less than 4 mm, and reasonably well demarcated from the adjacent atrophic cortex.

As already mentioned, in some patients with this pathology the development of hypercortisolism symptoms can be cyclic and irregular what causes some typical Cushing's syndrome symptoms to be variable or discrete, therefore complicating its diagnosis. On the other hand, in patients with PPNAD, due to the presence of elevated cortisol levels, osteoporosis and avascular hip necrosis have been reported (Ruder et al., 1974; Carney & Young, 1992).

12.3 Carney complex

PPNAD occurs as part of Carney complex in more than 60% of the cases (Bertherat et al., 2009).

This syndrome is an autosomal dominant form of multiple neoplasia. The main signs that characterize this condition are the presence of spotty skin pigmentation (lentiginosis), the presence of endocrine tumors, including PPNAD (the most common endocrine finding in Carney's complex), testicular large cell calcifying Sertoli cells tumors, GH secreting pituitary adenomas and thyroid adenomas and carcinomas, and non-endocrine tumors, including atrial myxomas, cutaneous myxomas, breast ductal adenomas, psammomatous melanotic schwannomas, and osteochondromyxomas (Stratakis et al., 2001; Carney et al., 1985; Stratakis et al., 1997). Cushing's syndrome caused by PPNAD occurs in many of the cases of Carney Complex. However, if one considers also the subclinical cases of Cushing's syndrome, the percentage will surely be higher (Bertherat et al., 2009; Stratakis et al., 2001).

Three genetic loci were associated with the Carney Complex: 2p16, 17q22-24 and 17p12-13. More than 70% Carney Complex cases have a PRKAR1A mutation (Bertherat et al., 2009).

For being a heterogeneous disease that can present with different signs and symptoms, its diagnosis is usually difficult (Carson et al., 1988; Gunther et al., 2004), especially if it shows unusual clinical manifestations and if it is not present in other family members.

The most important steps for its diagnosis can be the same as for the diagnosis of Cushing's syndrome. Therefore initial phases must include confirming hypercortisolism, determining whether the hypercortisolism is ACTH-dependent or ACTH-independent, and whether there is paradoxical response to Dexamethasone suppression test. Then it will be necessary

to identify the cause of that hypercortisolism. When investigating family members of patients affected by PPNAD or other forms of micronodular disease, the dexamethasone suppression tests should be used to identify subclinical adrenal disease, since for these patients, even subtle changes of cortisol secretion should be considered abnormal (plasma cortisol $>1.8 \mu\text{g/dL}$ [50 nmol/L] following Liddle's test). ACTH suppression is also significant in this context. After that, the computerized tomography of the adrenals will help to distinguish unilateral from bilateral nodular disease or hyperplasia and so it must be performed next (Rockal et al., 2004). It must be stressed however that the adrenals are not very enlarged and so the interpretation of the images can be difficult (Bertherat et al., 2009). Treatment of PPNAD is often bilateral adrenalectomy, sometimes in two surgical timings years-apart, related to the fact that the development of this bilateral disease is frequently asymmetrical.

13. References

- Abiven, G., Coste, J., Groussin, L., Anract, P., Tissier, F., Legmann, P., Dousset, B., Bertagna, X. & Bertherat, J. (2006). Clinical and biological features in the prognosis of adrenocortical cancer: poor outcome of cortisol-secreting tumors in a series of 202 consecutive patients. *J Clin Endocrinol Metab*, Vol. 91, pp. (2650-5), ISSN.
- Abraham, J., Bakke, S., Rutt, A., Meadows, B., Merino, M., Alexander, R., Schrupp, D., Bartlett, D., Choyke, P., Robey, R., Hung, E., Steinberg, SM., Bates, S. & Fojo, T. (2002). A phase II trial of combination chemotherapy and surgical resection for the treatment of metastatic adrenocortical carcinoma: continuous infusion doxorubicin, vincristine, and etoposide with daily mitotane as a P-glycoprotein antagonist. *Cancer*, Vol. 94, pp. (2333-43), ISSN.
- Adam, R., Chiche, L., Aloia, T., Elias, D., Salmon, R., Rivoire, M., Jaeck, D., Saric, J., Le Treut, YP., Belghiti, J., Mantion, G. & Mentha, G., Association Française de Chirurgie. (2006). Hepatic resection for noncolorectal nonendocrine liver metastases: analysis of 1,452 patients and development of a prognostic model. *Ann Surg*, Vol. 244, No. 4, pp. (524-35), ISSN.
- Advani, A., Johnson, SJ., Nicol, MR., Papacleovoulou, G., Evans, DB., Vaikkakara, S., Mason, JL. & Quinton, R. (2010). Adult-onset hypogonadotropic hypogonadism caused by aberrant expression of aromatase in an adrenocortical adenocarcinoma. *Endocr J*, Vol. 57, No. 7, pp. (651-6), ISSN.
- Agrons, GA., Lonergan, GJ., Dickey, GE. & Perez-Monte, JE. (1999). Adrenocortical neoplasms in children: radiologic-pathologic correlation. *Radiographics*, Vol. 19, No. 4, pp. (989-1008), ISSN.
- Allolio, B. & Fassnacht, M. (2006). Clinical review: Adrenocortical carcinoma: clinical update. *J Clin Endocrinol Metab*, Vol. 91, pp. (2027-37), ISSN.
- Allolio, B., Hahner, S., Weismann, D. & Fassnacht, M. (2004). Management of adrenocortical carcinoma. *Clin Endocrinol (Oxf)*, Vol. 60, pp. (273-87), ISSN.
- Angeli, A., Osella, G., Ali, A. & Terzolo, M. (1997). Adrenal incidentaloma: an overview of clinical and epidemiological data from the National Italian Study Group. *Horm Res*, Vol. 47, pp. (279-83), ISSN.
- Angeli, A. & Terzolo, M. (2002). Adrenal incidentaloma – a modern disease with old complications. *J Clin Endocrinol Metab*, Vol. 87, pp. (4869-71), ISSN.

- Aubert, S., Buob, D., Leroy, X., Devos, P., Carnaille, B., Do Cao, C., Wemeau, JL. & Leteurtre, E. (2005). Weiss system: a still in-use diagnostic tool for the assessment of adrenocortical malignancy. *Ann Pathol*, Vol. 25, No. 6, pp. (545-54), ISSN.
- Azziz, R., Sanchez, LA., Knochenhauer, ES., Moran, C., Lazenby, J., Stephens, KC., Taylor, K. & Boots, LR. (2004). Androgen excess in women: experience with over 1000 consecutive patients. *J Clin Endocrinol Metab*, Vol. 89, pp. (453-62), ISSN.
- Barzon, L., Chilosi, M., Fallo, F., Martignoni, G., Montagna, L., Palù, G. & Boscaro, M. (2001). Molecular analysis of CDKN1C and TP53 in sporadic adrenal tumors. *Eur J Endocrinol*, Vol. 145, pp. (207-12), ISSN.
- Barzon, L., Sonino, N., Fallo, F., Palu, G. & Boscaro M. (2003). Prevalence and natural history of adrenal incidentalomas. *Eur J Endocrinol*, Vol. 149, pp. (273-85), ISSN.
- Baudin, E., Pellegriti, G., Bonnay, M., Penfornis, A., Laplanche, A., Vassal, G. & Schlumberger, M. (2001). Impact of monitoring plasma 1,1-dichlorodiphenildichloroethane (o,p'DDD) levels on the treatment of patients with adrenocortical carcinoma. *Cancer*, Vol. 92, pp. (1385-92), ISSN.
- Bernard, MH., Sidhu, S., Berger, N., Peix, JL., Marsh, DJ., Robinson, BG., Gaston, V., Le Bouc, Y. & Gicquel, C. (2003). A case report in favor of a multistep adrenocortical tumorigenesis. *J Clin Endocrinol Metab*, Vol. 88, pp. (998-1001), ISSN.
- Bernini, GP., Moretti, A., Oriandini, C., Bardini, M., Taurino, C. & Salvetti, A. (2005). Long-term morphological and hormonal follow-up in a single unit on 115 patients with adrenal incidentalomas. *Br J Cancer*, Vol. 92, pp. (1104 - 9), ISSN.
- Berruti, A., Terzolo, M., Sperone, P., Pia, A., Casa, SD., Gross, DJ., Carnaghi, C., Casali, P., Porpiglia, F., Mantero, F., Reimondo, G., Angeli, A. & Dogliotti, L. (2005). Etoposide, doxorubicin and cisplatin plus mitotane in the treatment of advanced adrenocortical carcinoma: a large prospective phase II trial. *Endocr Relat Cancer*, Vol. 12, pp. (657-66), ISSN.
- Bertherat, J., Horvath, A., Groussin, L., Grabar, S., Boikos, S., Cazabat, L., Libe, R., René-Corail, F., Stergiopoulos, S., Bourdeau, I., Bei, T., Clauser, E., Calender, A., Kirschner, LS., Bertagna, X., Carney, JA. & Stratakis, CA. (2009). Mutations in regulatory subunit type 1A of cyclic adenosine 5'-monophosphate-dependent protein kinase (PRKAR1A): phenotype analysis in 353 patients and 80 different genotypes. *J Clin Endocrinol Metab*, Vol. 94, No. 6, pp. (2085-91), ISSN.
- Beuschlein, F., Reincke, M., Karl, M., Travis, WD., Jaurisch-Hancke, C., Abdelhamid, S., Chrousos, GP. & Allolio, B. (1994). Clonal composition of human adrenocortical neoplasms. *Cancer Research*, Vol. 54, pp. (4927-32), ISSN.
- Birch, JM. (1994). Li-Fraumeni syndrome. *Eur J Cancer*, Vol. 30A, pp. (1935-41), ISSN.
- Blumenfeld, JD., Sealey, JE., Schluskel, Y., Vaughan, ED., Sos, TA., Atlas, SA., Muller, FB., Acevedo, R., Ulick, S. & Laragh, JH. (1994). Diagnosis and treatment of primary hyperaldosteronism. *Ann Intern Med*, Vol. 121, pp. (877-85), ISSN.
- Boland, GW., Lee, MJ., Gazelle, GS., Halpern, EF., McNicholas, MM. & Mueller, PR. (1998). Characterization of adrenal masses using unenhanced CT: an analysis of the CT literature. *AJR Am J Roentgenol*, Vol.171, pp. (201-4), ISSN.
- Bonacci, R., Gigliotti, A., Baudin, E., Wion-Barbot, N., Emy, P., Bonnay, M., Cailleux, AF., Nakib, I. & Schlumberger, M. Réseau Comète. (1998). Cytotoxic therapy with etoposide and cisplatin in advanced adrenocortical carcinoma. *Br J Cancer*, Vol. 78, pp. (546-9), ISSN.

- Bonfig, W., Bittmann, I., Bechtold, S., Kammer, B., Noelle, V., Arleth, S., Raile, K. & Schwarz, HP. (2003). Virilising adrenocortical tumours in children. *Eur J Pediatr*, Vol. 162, No. 9, pp. (623-8), ISSN.
- Boulle, N., Logié, A., Gicquel, C., Perin, L. & Le Bouc, Y. (1998). Increased levels of insulin-like growth factor II (IGF-II) and IGF-binding protein-2 are associated with malignancy in sporadic adrenocortical tumors. *J Clin Endocrinol Metab*, Vol. 83, No. 5, pp. (1713-20), ISSN.
- Bourdeau, I., D'Amour, P., Hamet, P., Boutin, JM. & Lacroix, A. (2001). Aberrant membrane hormone receptors in incidentally discovered bilateral macronodular adrenal hyperplasia with subclinical Cushing's syndrome. *J Clin Endocrinol Metab*, Vol. 86, pp. (5534-40), ISSN.
- Bovio, S., Cataldi, A., Reimondo, G., Sperone, P., Novello, S., Berruti, A., Borasio, P., Fava, C., Dogliotti, L., Scagliotti, GV., Angeli, A. & Terzolo, M. (2006). Prevalence of adrenal incidentaloma in a contemporary computerized tomography series. *J Endocrinol Invest*, Vol. 29, pp. (298-302), ISSN.
- Brembeck, FH., Rosário, M. & Birchmeier, W. (2006). Balancing cell adhesion and Wnt signaling, the key role of beta-catenin. *Curr Opin Genet Dev*, Vol. 16, No. 1, pp. (51-9), ISSN.
- Bukowski, RM., Wolfe, M., Levine, HS., Crawford, DE., Stephens, RL., Gaynor, E. & Harker, WG. (1993). Phase II trial of mitotane and cisplatin in patients with adrenal carcinoma: a Southwest Oncology Group study. *J Clin Oncol*, Vol. 11, No. 1, pp. (161-5), ISSN.
- Burgess, JR., Harle, RA., Tucker, P., Parameswaran, V., Davies, P., Greenaway, TM. & Shepherd, JJ. (1996). Adrenal lesions in a large kindred with multiple endocrine neoplasia type 1. *Arch Surg*, Vol. 131, No. 7, pp. (699-702), ISSN.
- Caoili, EM., Korobkin, M., Brown, RK., Mackie, G. & Shulkin, BL. (2007). Differentiating adrenal adenomas from nonadenomas using (18)F-FDG PET/CT: quantitative and qualitative evaluation. *Acad Radiol*, Vol. 14, No. 4, pp. (468-75), ISSN.
- Caoili, EM., Korobkin, M., Francis, IR., Cohan, RH., Platt, JF., Dunnick, NR. & Raghupathi, KI. (2002). Adrenal masses: characterization with combined unenhanced and delayed enhanced CT. *Radiology*, Vol. 222, No. 3, pp. (629-33), ISSN.
- Carmina, E., Rosato, F., Janni, A., Rizzo, M. & Longo, RA. (2006). Extensive clinical experience: relative prevalence of different androgen excess disorders in 950 women referred because of clinical hyperandrogenism. *J Clin Endocrinol Metab*, Vol. 9, pp. (12-6), ISSN.
- Carney, JA., Gordon, H., Carpenter, PC., Shenoy, BV. & Go, VL.. (1985). The complex of myxomas, spotty pigmentation, and endocrine overactivity. *Medicine (Baltimore)*, Vol. 64, No. 4, pp. (270-83), ISSN.
- Carney, JA. & Young, WF Jr. (1992). Primary pigmented nodular adrenocortical disease and its associated conditions. *Endocrinologist*, Vol. 2, pp. (6), ISSN.
- Carson, DJ., Sloan, JM., Cleland, J., Russell, CF., Atkinson, AB. & Sheridan, B. (1988). Cyclical Cushing's syndrome presenting as short stature in a boy with recurrent atrial myxomas and freckled skin pigmentation. *Clin Endocrinol (Oxf)*, Vol. 28, No. 2, pp. (173-80), ISSN.
- Cawood, TJ., Hunt, PJ., O'Shea, D., Cole, D. & Soule, S. (2009). Recommended evaluation of adrenal incidentalomas is costly, has high false-positive rates and confers a risk of

- fatal cancer that is similar to the risk of the adrenal lesion becoming malignant; time for a rethink? *Eur J Endocrinol*, Vol. 161, No. 4, pp. (513-27), ISSN.
- Choi, M., Scholl, UI., Yue, P., Björklund, P., Zhao, B., Nelson-Williams, C., Ji, W., Cho, Y., Patel, A., Men, CJ., Lolis, E., Wisgerhof, MV., Geller, DS., Mane, S., Hellman, P., Westin, G., Åkerström, G., Wang, W., Carling, T. & Lifton, RP. (2011). K⁺ channel mutations in adrenal aldosterone-producing adenomas and hereditary hypertension. *Science*, Vol. 331, No. 6018, pp. (768-72), ISSN.
- Christopoulos, S., Bourdeau, I. & Lacroix, A. (2005). Clinical and subclinical ACTH-independent macronodular adrenal hyperplasia and aberrant hormone receptors. *Horm Res*, Vol. 64, pp. (119-31), ISSN.
- Cobb, WS., Kercher, KW., Sing, RF. & Heniford, BT. (2005). Laparoscopic adrenalectomy for malignancy. *Am J Surg*, Vol. 189, pp. (405-11), ISSN.
- Conn JW. (1964). Plasma renin activity in primary aldosteronism. Importance in differential diagnosis and in research of essential hypertension. *J Am Med Ass*, Vol. 190, pp. (222-5), ISSN.
- Conn, JW. (1955). Presidential address. Part I. Painting the background. Part II. Primary aldosteronism, a new clinical syndrome. *J Lab Clin Med*, Vol. 45, pp. (3-17), ISSN.
- Dackiw, AP., Lee, JE., Gagel, RF. & Evans, DB. (2001). Adrenal cortical carcinoma. *World J Surg*, Vol. 25, pp. (914-26), ISSN.
- Daffara, F., De Francia, S., Reimondo, G., Zaggia, B., Aroasio, E., Porpiglia, F., Volante, M., Termine, A., Di Carlo, F., Dogliotti, L., Angeli, A., Berruti, A. & Terzolo, M. (2008). Prospective evaluation of mitotane toxicity in adrenocortical cancer patients treated adjuvantly. *Endocr Relat Cancer*, Vol. 15, No. 4, pp. (1043-53), ISSN.
- D'Andrea, MR., Qiu, Y., Haynes-Johnson, D., Bhattacharjee, S., Kraft, P. & Lundeen, S. (2005). Expression of PDE11A in normal and malignant human tissues. *J Histochem Cytochem*, Vol. 53, No. 7, pp. (895-903), ISSN.
- DeChiara, TM., Robertson, EJ. & Efstratiadis A. (1991). Parental imprinting of the mouse insulin-like growth factor II gene. *Cell*, Vol. 64, pp. (849-59), ISSN.
- Decker, RA., Elson, P., Hogan, TF., Citrin, DL., Westring, DW., Banerjee, TK., Gilchrist, KW. & Horton, J. (1991). Eastern Cooperative Oncology Group study 1879: mitotane and adriamycin in patients with advanced adrenocortical carcinoma. *Surgery*, Vol. 110, No. 6, pp. (1006-13), ISSN.
- DeLellis, RA., Lloyd, RV., Heitz, PU. & Eng, C. (2004). *Pathology and Genetics of Tumours of Endocrine Organs*, World Health Organization, ISBN, Lyon, France.
- Derksen, J., Nagesser, SK., Meinders, AE., Haak, HR. & van de Velde, CJ. (1994). Identification of virilizing adrenal tumors in hirsute women. *N Engl J Med*, Vol. 331, pp. (968-73), ISSN.
- Doppman, JL., Chrousos, GP., Papanicolaou, DA., Stratakis, CA., Alexander, HR. & Nieman, LK. (2000). Adrenocorticotropin-independent macronodular adrenal hyperplasia: an uncommon cause of primary adrenal hypercortisolism. *Radiology*, Vol. 216, No. 3, pp. (797-802), ISSN.
- Doppman, JL., Nieman, LK., Travis, WD., Miller, DL., Cutler, GB Jr., Chrousos, GP. & Norton, JA. (1991). CT and MR imaging of massive macronodular adrenocortical disease: a rare cause of autonomous primary adrenal hypercortisolism. *J Comput Assist Tomogr*, Vol. 15, No. 5, pp. (773-9), ISSN.

- Dunnick, NR., Korobkin, M. & Francis, I. (1996). Adrenal radiology: distinguishing benign from malignant adrenal masses. *AJR Am J Roentgenol*, Vol. 167, pp. (861-7), ISSN.
- Edge, SB., Byrd, DR., Compton, CC., Fritz, AG., Greene, FL., Trotti, A. (Eds.). (2010). *AJCC Cancer Staging Manual*, 7th Ed. Springer, Chicago.
- Fassnacht, M. & Allolio, B. (2009). Clinical management of adrenocortical carcinoma. *Best Pract Res Clin Endocrinol Metab*, Vol. 23, No. 2, pp. (273-89); ISSN.
- Fassnacht, M., Johanssen, S., Quinkler, M., Bucszy, P., Willenberg, HS., Beuschlein, F., Terzolo, M., Mueller, HH., Hahner, S. & Allolio, B., German Adrenocortical Carcinoma Registry Group, European Network for the Study of Adrenal Tumors. (2009). Limited prognostic value of the 2004 International Union Against Cancer staging classification for adrenocortical carcinoma: proposal for a Revised TNM Classification. *Cancer*, Vol. 115, No. 2, pp. (243-50), ISSN.
- Fassnacht, M., Libé R, Kroiss M, Allolio B. (2011). Adrenocortical carcinoma: a clinician's update. *Nat Rev Endocrinol*. Vol. 7, No 6, pp. (323-35).
- Feige, JJ., Cochet, C., Savona, C., Shi, DL., Keramidas, M., Defaye, G. & Chambaz, EM. (1991). Transforming growth factor beta 1: an autocrine regulator of adrenocortical steroid genesis. *Endocr Res*, Vol. 17, pp. (267-79), ISSN.
- Fottner, C., Hoeflich, A., Wolf, E. & Weber, MM. (2004). Role of the insulin-like growth factor system in adrenocortical growth control and carcinogenesis. *Horm Metab Res*, Vol. 36, pp. (397-405), ISSN.
- Fragoso, MC., Domenice, S., Latronico, AC., Martin, RM., Pereira, MA., Zerbini, MC., Lucon, AM. & Mendonca, BB. (2003). Cushing's syndrome secondary to adrenocorticotropin-independent macronodular adrenocortical hyperplasia due to activating mutations of GNAS1 gene. *J Clin Endocrinol Metab*, Vol. 88, No. 5, pp. (2147), ISSN.
- Fraumeni, JF Jr. & Miller, RW. (1967). Adrenocortical neoplasms with hemihypertrophy, brain tumors, and other disorders. *J Pediatr*, Vol. 70, pp. (129-38) ISSN.
- Fuhrman, SA., Lasky, LC. & Limas, C. (1982). Prognostic significance of morphologic parameters in renal cell carcinoma. *Am J Surg Pathol*, Vol. 6, No. 7, pp. (655-63), ISSN.
- Gaujoux, S., Tissier, F., Groussin, L., Libé, R., Ragazzon, B., Launay, P., Audebourg, A., Dousset, B., Bertagna, X. & Bertherat, J. (2008). Wnt/beta-catenin and 3',5'-cyclic adenosine 5'-monophosphate/protein kinase A signaling pathways alterations and somatic beta-catenin gene mutations in the progression of adrenocortical tumors. *J Clin Endocrinol Metab*, Vol. 93, No. 10, pp. (4135-40), ISSN.
- Gicquel, C., Bertagna, X., Gaston, V., Coste, J., Louvel, A., Baudin, E., Bertherat, J., Chapuis, Y., Duclos, JM., Schlumberger, M., Plouin, PF., Luton, JP. & Le Bouc, Y. (2001). Molecular markers and long-term recurrences in a large cohort of patients with sporadic adrenocortical tumors. *Cancer Res*, Vol. 61, No. 18, pp. (6762-7), ISSN.
- Gicquel, C., Bertagna, X., Schneid, H., Francillard-Leblond, M., Luton, JP., Girard, F. & Le Bouc, Y. (1994). Rearrangements at the 11p15 locus and overexpression of insulin-like growth factor-II gene in sporadic adrenocortical tumors. *J Clin Endocrinol Metab*, Vol. 78, No. 6, pp. (1444-53), ISSN.
- Gicquel, C., Raffin-Sanson, ML., Gaston, V., Bertagna, X., Plouin, PF., Schlumberger, M., Louvel, A., Luton, JP. & Le Bouc, Y. (1997). Structural and functional abnormalities at 11p15 are associated with the malignant phenotype in sporadic adrenocortical

- tumors: Study on a series of 82 tumors. *J Clin Endocrinol Metab*, Vol. 82, No. 8, pp. (2559-65), ISSN.
- Giordano, TJ., Kuick, R., Else, T., Gauger, PG., Vinco, M., Bauersfeld, J., Sanders, D., Thomas, DG., Doherty, G. & Hammer, G. (2009). Molecular classification and prognostication of adrenocortical tumors by transcriptome profiling. *Clin Cancer Res*, Vol. 15, No. 2, pp. (668-76), ISSN.
- Gittler, RD. & Fajans, SS. (1995). Primary aldosteronism (Conn's syndrome). *J Clin Endocrinol Metab*, Vol. 80, pp. (3438-41), ISSN.
- Gold, PW., Loriaux, DL., Roy, A., Kling, MA., Calabrese, JR., Kellner, CH., Nieman, LK., Post, RM., Pickar, D. & Gallucci, W. (1986). Responses to corticotropin-releasing hormone in the hypercortisolism of depression and Cushing's disease. Pathophysiologic and diagnostic implications. *N Engl J Med*, Vol. 314, No. 21, pp. (1329-35), ISSN.
- Gonzalez, RJ., Shapiro, S., Sarlis, N., Vassilopoulou-Sellin, R., Perrier, ND., Evans, DB. & Lee, JE. (2005). Laparoscopic resection of adrenal cortical carcinoma: a cautionary note. *Surgery*, Vol. 138, No. 6, pp. (1078-85), ISSN.
- Gordon, MD. & Nusse, R (2006). Wnt signaling: Multiple pathways, multiple receptors, and multiple transcription factors. *J Biol Chem*, Vol. 281, pp. (22429-33), ISSN.
- Groussin, L., Jullian, E., Perlemoine, K., Louvel, A., Leheup, B., Luton, JP., Bertagna, X. & Bertherat, J. (2002a). Mutations of the PRKAR1A gene in Cushing's syndrome due to sporadic primary pigmented nodular adrenocortical disease. *J Clin Endocrinol Metab*, Vol. 87, No. 9, pp. (4324-9), ISSN.
- Groussin, L., Kirschner, LS., Vincent-Dejean, C., Perlemoine, K., Jullian, E., Delemer, B., Zacharieva, S., Pignatelli, D., Carney, JA., Luton, JP., Bertagna, X., Stratakis, CA. & Bertherat, J. (2002b). Molecular analysis of the cyclic AMP-dependent protein kinaseA (PKA) regulatory subunit1A (PRKAR1A) gene in patients with Carney complex and primary pigmented nodular adrenocortical disease (PPNAD) reveals novel mutations and clues for pathophysiology: augmented PKA signaling is associated with adrenal tumorigenesis in PPNAD. *Am J Hum Genet*, Vol. 71, No. 6, pp. (1433-42), ISSN.
- Groussin, L., Perlemoine, K., Contesse, V., Lefebvre, H., Tabarin, A., Thieblot, P., Schlienger, JL., Luton, JP., Bertagna, X. & Bertherat, J. (2002c). The ectopic expression of the gastric inhibitory polypeptide receptor is frequent in adrenocorticotropin-independent bilateral macronodular adrenal hyperplasia, but rare in unilateral tumors. *J Clin Endocrinol Metab*, Vol. 87, No. 5, pp. (1980-5), ISSN.
- Groussin, L., Bonardel, G., Silvéra, S., Tissier, F., Coste, J., Abiven, G., Libé, R., Bienvenu, M., Alberini, JL., Salenave, S., Bouchard, P., Bertherat, J., Dousset, B., Legmann, P., Richard, B., Foehrenbach, H., Bertagna, X. & Tenenbaum, F. (2009). 18F-Fluorodeoxyglucose positron emission tomography for the diagnosis of adrenocortical tumors: a prospective study in 77 operated patients. *J Clin Endocrinol Metab*, Vol. 94, No. 5, pp. (1713-22), ISSN.
- Grumbach, MM., Biller, BM., Braunstein, GD., Campbell, KK., Carney, JA., Godley, PA., Harris, EL., Lee, JK., Oertel, YC., Posner, MC., Schlechte, JA. & Wieand, HS. (2003). Management of the clinically inapparent adrenal mass ("incidentaloma"). *Ann Intern Med*, Vol. 138, No. 5, pp. (424-9), ISSN.

- Gunther, DF., Bourdeau, I., Matyakhina, L., Cassarino, D., Kleiner, DE., Griffin, K., Courkoutsakis, N., Abu-Asab, M., Tsokos, M., Keil, M., Carney, JA. & Stratakis, CA. (2004). Cyclical Cushing syndrome presenting in infancy: an early form of primary pigmented nodular adrenocortical disease, or a new entity? *J Clin Endocrinol Metab*, Vol. 89, no. 7, pp. (3173-82), ISSN.
- Haak HR, Hermans J, van de Velde CJ, Lentjes EG, Goslings BM, Fleuren GJ, Krans HM. Optimal treatment of adrenocortical carcinoma with mitotane: results in a consecutive series of 96 patients. *Br J Cancer*. 1994 May;69(5):947-51
- Hahner, S. & Fassnacht, M. (2005). Mitotane for adrenocortical carcinoma treatment. *Curr Opin Investig Drugs*, Vol. 6, pp. (386-94), ISSN.
- Hamrahian, AH., Ioachimescu, AG., Remer, EM., Motta-Ramirez, G., Bogabathina, H., Levin, HS., Reddy, S., Gill, IS., Siperstein, A. & Bravo, EL. (2005). Clinical utility of noncontrast computed tomography attenuation value (hounsfield units) to differentiate adrenal adenomas/hyperplasias from nonadenomas: Cleveland Clinic experience. *J Clin Endocrinol Metab*, Vol. 90, No. 2, pp. (871-7), ISSN.
- Harrison, LE., Gaudin, PB. & Brennan, MF. (1999). Pathologic features of prognostic significance for adrenocortical carcinoma after curative resection. *Arch Surg*, Vol. 134, pp. (181-5), ISSN.
- Hedeland, H., Ostberg, G. & Hökfelt, B. (1968). On the prevalence of adrenocortical adenomas in an autopsy material in relation to hypertension and diabetes. *Acta Med Scand*, Vol. 184, pp. (211-4), ISSN.
- Henley, DJ., van Heerden, JA., Grant, CS., Carney, JA. & Carpenter, PC. (1983). Adrenal cortical carcinoma--a continuing challenge. *Surgery*, Vol. 94, No. 6, pp. (926-31), ISSN.
- Heppner, C., Reincke, M., Agarwal, SK., Mora, P., Allolio, B., Burns, AL., Spiegel, AM. & Marx, SJ. (1999). MEN1 gene analysis in sporadic adrenocortical neoplasms. *J Clin Endocrinol Metab*, Vol. 84, No. 1, pp. (216-9), ISSN.
- Herrera, MF., Grant, CS., van Heerden, JA., Sheedy, PF. & Ilstrup, DM. (1991). Incidentally discovered adrenal tumors: an institutional perspective. *Surgery*, Vol. 110, No. 6, pp. (1014-21), ISSN.
- Hisada, M., Garber, JE., Fung, CY., Fraumeni, Jr JF. & Li, FP. (1998). Multiple primary cancers in families with Li-Fraumeni syndrome. *J Natl Cancer Inst*, Vol. 90, pp. (606-11), ISSN.
- Holland, OB. & Carr, B. (1993). Modulation of aldosterone synthase messenger ribonucleic acid levels by dietary sodium and potassium and by adrenocorticotropin. *Endocrinology*, Vol. 132, pp. (2666-73), ISSN.
- Hollstein, M., Sidransky, D., Vogelstein, B. & Harris, CC. (1991). p53 mutations in human cancers. *Science*, Vol. 253, No. 5015, pp. (49-53), ISSN.
- Horiba, N., Suda, T., Aiba, M., Naruse, M., Nomura, K., Imamura, M. & Demura, H. (1995). Lysine vasopressin stimulation of cortisol secretion in patients with adrenocorticotropin-independent macronodular adrenal hyperplasia. *J Clin Endocrinol Metab*, Vol. 80, No. 8, pp. (2336-41), ISSN.
- Horvath, A., Mericq, V. & Stratakis, CA. (2008). Mutation in PDE8B, a cyclic AMP-specific phosphodiesterase in adrenal hyperplasia. *N Engl J Med*, Vol. 358, pp. (750-2), ISSN.

- Hughes, JM., Hichens, M., Booze, GW. & Thorner, MO. (1986). Cushing's syndrome from the therapeutic use of intramuscular dexamethasone acetate. *Arch Intern Med*, Vol. 146, pp. (1848-9), ISSN.
- Ilvesmaki, V., Kahri, AL., Miettinen, PJ. & Voutilainen, R. (1993). Insulin-like growth factors (IGFs) and their receptors in adrenal tumors: high IGF-II expression in functional adrenocortical carcinomas. *J Clin Endocrinol Metab*, Vol. 77, No. 3, pp. (852-8), ISSN.
- Invitti, C., Pecori Giraldi, F., de Martin, M. & Cavagnini, F. (1999). Diagnosis and management of Cushing's syndrome: results of an Italian multicentre study. Study Group of the Italian Society of Endocrinology on the Pathophysiology of the Hypothalamic-Pituitary-Adrenal Axis. *J Clin Endocrinol Metab*, Vol. 84, pp. (440-8), ISSN.
- Jhala, NC., Jhala, D., Eloubeidi, MA., Chhieng, DC., Crowe, DR., Roberson, J. & Eltoun, I. (2004). Endoscopic ultrasound-guided fine-needle aspiration biopsy of the adrenal glands: analysis of 24 patients. *Cancer*, Vol. 102, No. 5, pp. (308-14), ISSN.
- Kaltsas, GA., Isidori, AM., Kola, BP., Skelly, RH., Chew, SL., Jenkins, PJ., Monson, JP., Grossman, AB. & Besser, GM. (2003). The value of the low-dose dexamethasone suppression test in the differential diagnosis of hyperandrogenism in women. *J Clin Endocrinol Metab*, Vol. 88, No. 6, pp. (2634-43), ISSN.
- Kamenicky, P., Houdoin, L., Ferlicot, S., Salenave, S., Brailly, S., Droupy, S., Meduri, G., Sasano, H., Suzuki, T., Young, J. & Chanson, P. (2007). Benign cortisol-secreting adrenocortical adenomas produce small amounts of androgens. *Clin Endocrinol (Oxf)*, Vol. 66, No. 6, pp. (778-88), ISSN.
- Kartheuser, A., Walon, C., West, S., Breukel, C., Detry, R., Gribomont, AC., Hamzehloei, T., Hoang, P., Maiter, D., Pringot, J., Rahier, J., Khan, PM., Curtis, A., Burn, J., Fodde, R. & Verellen-Dumoulin, C. (1999). Familial adenomatous polyposis associated with multiple adrenal adenomas in a patient with a rare 3' APC mutation. *J Med Genet*, Vol. 36, No. 1, pp. (65-7), ISSN.
- Kebebew, E., Reiff, E., Duh, QY., Clark, OH. & McMillan, A. (2006) Extent of disease at presentation and outcome, for adrenocortical carcinoma: have we made progress? *World J Surgery*, Vol. 30, No. 5, pp. (872-8), ISSN.
- Kendrick, ML., Lloyd, R., Erickson, L., Farley, DR., Grant, CS., Thompson, GB., Rowland, C., Young, WF Jr. & van Heerden, JA. (2001). Adrenocortical carcinoma: surgical progress or status quo? *Arch Surg*, Vol. 136, No. 5, pp. (543-9), ISSN.
- Kettel, LM. (1989). Management of hirsutism. *Drug Ther Bull*, Vol. 27, pp. (49-51), ISSN.
- Khan, TS., Imam, H., Juhlin, C., Skogseid, B., Gröndal, S., Tibblin, S., Wilander, E., Oberg, K. & Eriksson, B. (2000). Streptozocin and o,p'DDD in the treatment of adrenocortical cancer patients: long-term survival in its adjuvant use. *Ann Oncol*, Vol. 11, No. 10, pp. (1281-7), ISSN.
- Khan, TS., Sundin, A., Juhlin, C., Wilander, E., Oberg, K. & Eriksson, B. (2004). Vincristine, cisplatin, teniposide, and cyclophosphamide combination in the treatment of recurrent or metastatic adrenocortical cancer. *Med Oncol*, Vol. 21, No. 2, pp. (167-77), ISSN.
- Kirkman, S. & Nelson, DH. (1988). Alcohol-induced pseudo-Cushing's disease: a study of prevalence with review of the literature. *Metabolism*, Vol. 37, pp. (390-4), ISSN.
- Kirschner, LS., Carney, JA., Pack, SD., Taymans, SE., Giatzakis, C., Cho, YS., Cho-Chung, YS. & Stratakis, CA. (2000). Mutations of the gene encoding the protein kinase A type I-

- a regulatory subunit in patients with the Carney complex. *Nat Genet*, Vol. 26, No. 1, pp. (89-92), ISSN.
- Kirschner MA, Powell RD Jr, Lipsett MB (1964). Cushing's syndrome: nodular cortical hyperplasia of adrenal glands with clinical and pathological features suggesting adrenocortical tumor. *J Clin Endocrinol Metab*. Vol.24, pp (947-55).
- Kjellman, M., Roshani, L., Teh, BT., Kallioniemi, OP., Höög, A., Gray, S., Farnebo, LO., Holst, M., Bäckdahl, M. & Larsson, C. (1999). Genotyping of adrenocortical tumors: very frequent deletions of the MEN1 locus in 11q13 and of a 1-centimorgan region in 2p16. *J Clin Endocrinol Metab*, Vol. 84. No. 2, pp. (730-5), ISSN.
- Kloos, RT., Gross, MD., Francis, IR., Korobkin, M. & Shapiro, B. (1995). Incidentally discovered adrenal masses. *Endocr Rev*, Vol. 16, pp. (460-484), ISSN.
- Koch, CA., Pacak, K. & Chrousos, GP. (2002). The molecular pathogenesis of hereditary and sporadic adrenocortical and adrenomedullary tumors. *J Clin Endocrinol Metab*, Vol. 87, pp. (5367-84), ISSN.
- Kocijancic, K., Kocijancic, I. & Guna, F. (2004). Role of sonographically guided fine-needle aspiration biopsy of adrenal masses in patients with lung cancer. *J Clin Ultrasound*, Vol. 32, pp. (12-6), ISSN.
- Kopf, D., Goretzki, PE. & Lehnert, H. (2001). Clinical management of malignant adrenal tumors. *J Cancer Res Clin Oncol*, Vol. 127, pp. (143-55), ISSN.
- Korobkin, M., Francis, IR., Kloos, RT. & Dunnick, NR. (1996). The incidental adrenal mass. *Radiol Clin North Am*, Vol. 34, pp. (1037-54), ISSN.
- Kudva, YC., Sawka, AM. & Young, WF. (2003). The laboratory diagnosis of adrenal pheochromocytoma: the Mayo Clinic experience. *J Clin Endocrinol Metab*, Vol. 88, pp. (4533-9), ISSN.
- Lack, LEE. (1997). *Atlas of tumor pathology*, Armed Forces Institute of Pathology, ISBN, Washington, DC.
- Lacroix, A., Bolte, E., Tremblay, J., Dupré, J., Poitras, P., Fournier, H., Garon, J., Garrel, D., Bayard, F., Taillefer, R., Flanagan & RJ. & Hamet, P.(1992). Gastric inhibitory polypeptide-dependent cortisol hypersecretion – a new cause of Cushing's syndrome. *N Engl J Med*, Vol. 327, No. 14, pp. (974-80), ISSN.
- Lacroix, A., Tremblay, J., Rousseau, G., Bouvier, M. & Hamet, P. (1997). Propranolol therapy for ectopic b-adrenergic receptors in adrenal Cushing's syndrome. *N Engl J Med*, Vol. 337, pp. (429-34), ISSN.
- Lacroix, A., N'diaye, N., Tremblay, J. & Hamet, P. (2001). Ectopic and abnormal hormone receptors in adrenal Cushing's syndrome. *Endocr Rev*, Vol. 22, pp. (75-110), ISSN.
- Lacroix, A., Baldacchino, V., Bourdeau, I., Hamet, P. & Tremblay, J. (2004). Cushing's syndrome variants secondary to aberrant hormone receptors. *Trends Endocrinol Metab*, Vol. 15, pp. (375-82), ISSN.
- Lacroix A. (2009). ACTH-independent macronodular hyperplasia. *Best Practice and Research Clinical Endocrinology and Metabolism*, Vol. 23, pp. (245-259), ISSN.
- Larsen, JL., Cathey, WJ. & Odell, WD. (1986). Primary adrenocortical nodular dysplasia, a distinct subtype of Cushing's syndrome. Case report and review of the literature. *Am J Med*, Vol. 80, pp. (976-84), ISSN.
- Latronico, AC., Pinto, EM., Domenice, S., Fragoso, MC., Martin, RM., Zerbini, MC., Lucon, AM. & Mendonca, BB. (2001). An inherited mutation outside the highly conserved DNA-binding domain of the p53 tumor suppressor protein in children and adults

- with sporadic adrenocortical tumors. *J Clin Endocrinol Metab*, Vol. 86, No. 10, pp. (4970-3), ISSN.
- Lau, SK. & Weiss, LM. (2009). The Weiss system for evaluating adrenocortical neoplasms: 25 years later. *Hum Pathol*, Vol. 40, No. 6, pp. (757-68), ISSN.
- Lee, MH., Reynisdottir, I. & Massague, J. (1995). Cloning of p57kip2, a cyclindependent kinase inhibitor with unique domain structure and tissue distribution. *Genes Dev*, Vol. 9, pp. (639-49), ISSN.
- Lefevre, M., Gerard-Marchant, R., Gubler, JP., Chaussain, JL. & Lemerle, J. (1983). *Adrenal and endocrine tumors in children*, Nijhoff, ISBN, Boston.
- Li, FP. & Fraumeni, JF Jr. (1969a). Soft-tissue sarcomas, breast cancer, and other neoplasms: a familial syndrome? *Ann Intern Med*, Vol. 71, pp. (747-52), ISSN.
- Li, FP. & Fraumeni, Jr JF. (1969b). Rhabdomyosarcoma in children: epidemiologic study and identification of a familial cancer syndrome. *J Natl Cancer Inst*, Vol. 43, pp. (1365-73), ISSN.
- Li, FP., Fraumeni, Jr JF., Mulvihill, JJ., Blattner, WA., Dreyfus, MG., Tucker, MA. & Miller, RW. (1998). A cancer family syndrome in twenty-four kindreds. *Cancer Res*, Vol. 48, pp. (5358-62), ISSN.
- Libé, R. & Bertherat, J. (2005). Molecular genetics of adrenocortical tumours, from familial to sporadic diseases. *Eur J Endocrinol*, Vol. 153, pp. (477-87), ISSN.
- Libé, R., Fratticci, A. & Bertherat, J. (2007). Adrenocortical cancer: pathophysiology and Clinical management. *Endocr Relat Cancer*, Vol. 14, pp. (13-28), ISSN.
- Libé, R., Fratticci, A., Coste, J., Tissier, F., Horvath, A., Ragazzon, B., Rene-Corail, F., Groussin, L., Bertagna, X., Raffin-Sanson, ML., Stratakis, CA. & Bertherat, J. (2008). Phosphodiesterase 11A (PDE11A) and genetic predisposition to adrenocortical tumors. *Clin Cancer Res*, Vol. 14, No. 12, pp. (4016-24), ISSN.
- Liddle, GW. (1960). Tests of pituitary-adrenal suppressibility in the diagnosis of Cushing's syndrome. *J Clin Endocrinol Metab*, Vol. 20, pp. (1539-60), ISSN.
- Lieberman, SA., Eccleshall, TR. & Feldman, D. (1994). ACTH-independent massive bilateral adrenal disease (AIMBAD): A subtype of Cushing's syndrome with major diagnostic and therapeutic implications. *Eur J Endocrinol*, Vol. 131, pp. (67-73), ISSN.
- Lin, SR., Lee, YJ. & Tsai, JH. (1994). Mutations of the p53 gene in human functional adrenal neoplasms. *J Clin Endocrinol Metab*, Vol. 78, No. 2, pp. (483-91), ISSN.
- Lindholm J, Juul S, Jorgensen JO, Astrup J, Bjerre P, Feldt-Rasmussen U, Hagen C, Jorgensen J, Kosteljanetz M, Kristensen L, Laurberg P, Schmidt K, Weeke J. (2001). Incidence and late prognosis of Cushing's syndrome: a population based study. *J Clin Endocrinol Metab* 86: 117-123
- Logie, A., Boulle, N., Gaston, V., Perin, L., Boudou, P., Le Bouc, Y. & Gicquel, C. (1999). Autocrine role of IGF-II in proliferation of human adrenocortical carcinoma NCI H295R cell line. *J Mol Endocrinol*, Vol. 23, pp. (23-32), ISSN.
- Louisset, E., Gobet, F., Libé, R., Horvath, A., Renouf, S., Cariou, J., Rothenbuhler, A., Bertherat, J., Clauser, E., Grise, P., Stratakis, CA., Kuhn, JM. & Lefebvre, H. (2010). ACTH-independent Cushing's syndrome with bilateral micronodular adrenal hyperplasia and ectopic adrenocortical adenoma. *J Clin Endocrinol Metab*, Vol. 95, No. 1, pp. (18-24), ISSN

- Luton, JP., Cerdas, S., Billaud, L., Thomas, G., Guilhaume, B., Bertagna, X., Laudat, MH., Louvel, A., Chapuis, Y., Blondeau, P., Bonnin, A. & Bricaire, H. (1990). Clinical features of adrenocortical carcinoma, prognostic factors, and the effect of mitotane therapy. *N Engl J Med*, Vol. 322, No. 17, pp. (1195-201), ISSN.
- Lynch, HT., Mulcahy, GM., Harris, RE., Guirgis, HA. & Lynch, JF. (1978). Genetic and pathologic findings in kindred with hereditary sarcoma, breast cancer, brain tumors, leukemia, lung, laryngeal, and adrenal cortical carcinoma. *Cancer*, Vol. 41, pp. (2055-64), ISSN.
- Magee, BJ., Gattamaneni, HR. & Pearson, D. (1987). Adrenal cortical carcinoma: survival after radiotherapy. *Clin Radiol*, Vol. 38, pp. (587-8), ISSN.
- Malchoff, CD., Rosa, J., DeBold, CR., Kozol, RA., Ramsby, GR., Page, DL., Malchoff, DM. & Orth, DN. (1989). Adrenocorticotropin-independent bilateral macronodular adrenal hyperplasia: an unusual cause of Cushing syndrome. *J Clin Endocrinol Metab*, Vol. 68, No. 4, pp. (855-60), ISSN.
- Mansmann, G., Lau, J., Balk, E., Rothberg, M., Miyachi, Y. & Bornstein, SR. (2004). The clinically inapparent adrenal mass: update in diagnosis and management. *Endocr Rev*, Vol. 25, pp. (309-40), ISSN.
- Mantero, F., Terzolo, M., Arnaldi, G., Osella, G., Masini, AM., Ali, A., Giovagnetti, M., Opocher, G. & Angeli, A. (2000). A survey on adrenal incidentaloma in Italy. Study Group on Adrenal Tumors of the Italian Society of Endocrinology. *J Clin Endocrinol Metab*, Vol. 85, No. 2, pp. (637-44), ISSN.
- Matsuoka, S., Edwards, MC., Bai, C., Parker, S., Zhang, P., Baldini, A., Harper, JW. & Elledge, SJ. (1995). P57kip2, a structurally distinct member of the p21CIP1 Cdk inhibitor family, is a candidate tumor suppressor gene. *Genes Dev*, Vol. 9, No. 6, pp. (650-62), ISSN.
- Mattsson, C. & Young, WF Jr. (2006). Primary aldosteronism: diagnostic and treatment strategies. *Nat Clin Pract Nephrol*, Vol. 2, pp. (198), ISSN.
- Matyakhina, L., Freedman, RJ., Bourdeau, I., Wei, MH., Stergiopoulos, SG., Chidakel, A., Walther, M., Abu-Asab, M., Tsokos, M., Keil, M., Toro, J., Linehan, WM. & Stratakis, CA. (2005). Hereditary leiomyomatosis associated with bilateral, massive, macronodular adrenocortical disease and atypical cushing syndrome: a clinical and molecular genetic investigation. *J Clin Endocrinol Metab*, Vol. 90, No. 6, pp. (3773-9), ISSN.
- Maurea, S., Klain, M., Mainolfi, C., Ziviello, M. & Salvatore, M. (2001). The diagnostic role of radionuclide imaging in evaluation of patients with nonhypersecreting adrenal masses. *J Nucl Med*, Vol. 42, No. 6, pp. (884-92), ISSN.
- Mayo-Smith, WW. & Dupuy, DE. (2004). Adrenal neoplasms: CT-guided radiofrequency ablation--preliminary results. *Radiology*, Vol. 231, pp. (225-30), ISSN.
- Mesiano, S., Mellon, SH., Gospodarowicz, D., Di Blasio, AM. & Jaffe, RB. (1991). Basic fibroblast growth factor expression is regulated by corticotropin in the human fetal adrenal: a model for adrenal growth regulation. *PNAS*, Vol. 88, pp. (5428-32), ISSN.
- Mesiano, S., Mellon, SH. & Jaffe, RB. (1993). Mitogenic action, regulation, and localization of insulin-like growth factors in the human fetal adrenal gland. *J Clin Endocrinol Metab*, Vol. 76, pp. (968-76), ISSN.

- Metser, U., Miller, E., Lerman, H., Lievshitz, G., Avital, S. & Even-Sapir, E. (2006). 18F-FDG PET/CT in the evaluation of adrenal masses. *J Nucl Med*, Vol. 47, No. 1, pp. (32-7), ISSN.
- Meyer, A., Niemann, U. & Behrend, M. (2004). Experience with the surgical treatment of adrenal cortical carcinoma. *Eur J Surg Oncol*, Vol. 30, pp. (444-9), ISSN.
- Michalkiewicz, E., Sandrini, R., Figueiredo, B., Miranda, EC., Caran, E., Oliveira-Filho, AG., Marques, R., Pianovski, MA., Lacerda, L., Cristofani, LM., Jenkins, J., Rodriguez-Galindo, C. & Ribeiro, RC. (2004). Clinical and outcome characteristics of children with adrenocortical tumors: a report from the International Pediatric Adrenocortical Tumor Registry. *J Clin Oncol*, Vol. 22, No. 5, pp. (838-45), ISSN.
- Milliez, P., Girerd, X., Plouin, PF., Blacher, J., Safar, ME. & Mourad, JJ. (2005). Evidence for an increased rate of cardiovascular events in patients with primary aldosteronism. *J Am Coll Cardiol*, Vol. 45, pp. (1243-8), ISSN.
- Minn, H., Salonen, A., Friberg, J., Roivainen, A., Viljanen, T., Långsjö, J., Salmi, J., Välimäki, M., Nägren, K. & Nuutila, P. (2004). Imaging of adrenal incidentalomas with PET using (11)C-metomidate and (18)F-FDG. *J Nucl Med*, Vol. 45, No. 6, pp. (972-9), ISSN.
- Mircescu, H., Jilwan, J., N'Diaye, N., Bourdeau, I., Tremblay, J., Hamet, P. & Lacroix, A. (2000). Are ectopic or abnormal membrane hormone receptors frequently present in adrenal Cushing's syndrome? *J Clin Endocrinol Metab*, Vol. 85, No. 10, pp. (3531-6), ISSN.
- Moreno, S., Montoya, G., Armstrong, J., Leteurtre, E., Aubert, S., Vantyghem, MC., Dewailly, D., Wemeau, JL. & Proye, C. (2004). Profile and outcome of pure androgen-secreting adrenal tumors in women: experience of 21 cases. *Surgery*, Vol. 136, No. 6, pp. (1192-8), ISSN.
- Motta Ramirez, G., Remer, E., Herts, B., Gill, I. & Hamrahian, A. (2005). Comparison of CT findings in symptomatic and incidentally discovered pheochromocytomas. *Am J Roentgenol*, Vol. 185, pp. (684-688), ISSN.
- N'diaye, N., Tremblay, J., Hamet, P., de Herder, WW. & Lacroix, A. (1998). Adrenocortical overexpression of gastric inhibitory polypeptide receptor underlies food-dependent Cushing's syndrome. *J Clin Endocrinol Metab*, Vol. 83, pp. (2781-5), ISSN.
- Nadella, KS. & Kirschner, LS. (2005). Disruption of Protein Kinase A regulation causes immortalization and dysregulation of D-type cyclins. *Cancer Res*, Vol. 65, pp. (10307-15), ISSN.
- National Institutes of Health. (2002). NIH state-of-the-science statement on management of the clinically inapparent adrenal mass ("incidentaloma"). *NIH Consensus State-of-the-Science Statements*, Vol. 19, pp. (1-25), ISSN.
- Ng, L. & Libertino, JM. (2003). Adrenocortical carcinoma: diagnosis, evaluation and treatment. *J Urol*, Vol. 169, pp. (5-11), ISSN.
- Nieman, L., Biller, B., Findling, J., Newell-Price, J., Savage, M., Stewart, P. & Montori, VM. (2008). The diagnosis of Cushing's syndrome: an Endocrine Society Clinical Practice guideline. *J Clin Endocrinol Metab*, Vol. 93, No. 5, pp. (1526-40), ISSN.
- Ohgaki, H., Kleihues, P. & Heitz, PU. (1993). P53 mutations in sporadic adrenocortical tumors. *Intern J Cancer*, Vol. 54, pp. (408-10), ISSN.
- Patil, KK., Ransley, PG., McCullagh, M., Malone, M. & Spitz, L. (2002). Functioning adrenocortical neoplasms in children. *BJU Int*, Vol. 89, No. 6, pp. (562-5), ISSN.


- Polakis, P. Wnt signaling and cancer. *Genes Dev*, Vol. 14, No. 15, pp. (1837-51), ISSN.
- Polat, B., Fassnacht, M., Pfreundner, L., Guckenberger, M., Bratengeier, K., Johanssen, S., Kenn, W., Hahner, S., Allolio, B. & Flentje, M. (2009). Radiotherapy in adrenocortical carcinoma. *Cancer*, Vol. 115, No. 13, pp. (2816-23), ISSN.
- Quddusi, S., Browne, P., Toivola, B. & Hirsch, IB. Cushing syndrome due to surreptitious glucocorticoid administration. *Arch Intern Med*, Vol. 158, pp. (294-6), ISSN.
- Quinkler, M., Hahner, S., Wortmann, S., Johanssen, S., Adam, P., Ritter, C., Strasburger, C., Allolio, B. & Fassnacht, M. (2008). Treatment of advanced adrenocortical carcinoma with erlotinib plus gemcitabine. *J Clin Endocrinol Metab*, Vol. 93, No. 6, pp. (2057-62), ISSN.
- Reincke, M., Karl, M., Travis, WH., Mastorakos, G., Allolio, B., Linehan, HM. & Chrousos, GP. (1994). P53 mutations in human adrenocortical neoplasms: Immunohistochemical and molecular studies. *J Clin Endocrinol Metab*, Vol. 78, No. 3, pp. (790-4), ISSN.
- Resnik, Y., Allali Zerah, V., Chayvilalle, JA., Leroyer, R., Leymarie, P., Travert, G., Lebrethon, MC., Budi, I., Balliere, AM. & Mahoudeau, J. (1992). Food-dependent Cushing's syndrome mediated by aberrant adrenal sensitivity to gastric inhibitory polypeptide. *N Engl J Med*, Vol. 327, No. 14, pp. (981-6), ISSN.
- Ribeiro, RC., Sandrini Neto, RS., Schell, MJ., Lacerda, L., Sambaio, GA. & Cat, I. (1990). Adrenocortical carcinoma in children: A study of 40 cases. *J Clin Oncol*, Vol. 8, pp. (67-74), ISSN.
- Ribeiro, RC., Michalkiewicz, EL., Figueiredo, BC., DeLacerda, L., Sandrini, F., Pianovsky, MD., Sampaio, G. & Sandrini, R. (2000). Adrenocortical tumors in children. *Braz J Med Biol Res*, Vol. 33, No. 10, pp. (1225-34), ISSN.
- Ribeiro, RC., Sandrini, F., Figueiredo, B., Zambetti, GP., Michalkiewicz, E., Lafferty, AR., DeLacerda, L., Rabin, M., Cadwell, C., Sampaio, G., Cat, I., Stratakis, CA. & Sandrini, R. (2001). An inherited p53 mutation that contributes in a tissue-specific manner to pediatric adrenal cortical carcinoma. *Proc Natl Acad Sci U S A*, Vol. 98, No. 16, pp. (9330-5), ISSN.
- Rockall, AG., Babar, SA., Sohaib, SA., Isidori, AM., Diaz-Cano, S., Monson, JP., Grossman, AB. & Reznick, RH. (2004). CT and MR imaging of the adrenal glands in ACTH-independent Cushing syndrome. *Radiographics*, Vol. 24, No. 2, pp. (435-52), ISSN.
- Rosenfield, RL. Clinical practice. Hirsutism. *N Engl J Med*, Vol. 353, pp. (2578-88), ISSN.
- Ross, NS. (1994). Epidemiology of Cushing's syndrome and subclinical disease. *Endocrinol Metab Clin North Am*, Vol. 23, pp (539-46), ISSN.
- Ruder, HJ., Loriaux, DL. & Lipsett, MB. (1974). Severe osteopenia in young adults associated with Cushing's syndrome due to micronodular adrenal disease. *J Clin Endocrinol Metab*, Vol. 39, pp. (1138-47), ISSN.
- Sabbaga, CC., Avilla, SG., Schulz, C., Garbers, JC. & Blucher, D. (1993). Adrenocortical carcinoma in children: clinical aspects and prognosis. *J Pediatr Surg*, Vol. 28, No. 6, pp. (841-3), ISSN.
- Sandrini, R., Ribeiro, R. & DeLacerda, L. (1997). Extensive personal experience: childhood adrenocortical tumors. *J Clin Endocrinol Metab*, Vol. 82, pp. (2027-31), ISSN.
- Sbiera S, Schull S, Assie G, Voelker HU, Kraus L, Beyer M, Ragazzon B, Beuschlein F, Willenberg HS, Hahner S, Saeger W, Bertherat J, Allolio B, Fassnacht M. (2010).

- High diagnostic and prognostic value of steroidogenic factor-1 expression in adrenal tumors. *J Clin Endocrinol Metab*. Vol. 95, No. 10, pp. (161-71).
- Schlumberger, M., Ostronoff, M., Bellaiche, M., Rougier, P., Droz, JP. & Parmentier, C. (1988). 5-Fluorouracil, doxorubicin, and cisplatin regimen in adrenal cortical carcinoma. *Cancer*, Vol. 61, No. 8, pp. (1492-4), ISSN.
- Schteingart, DE., Motazed, A., Noonan, RA. & Thompson, NW. (1982). Treatment of adrenal carcinomas. *Arch Surg*, Vol. 117, pp. (1142-6), ISSN.
- Schteingart, DE., Doherty, GM., Gauger, PG., Giordano, TJ., Hammer, GD., Korobkin, M. & Worden, FP. (2005). Management of patients with adrenal cancer: recommendations of an international consensus conference. *Endocr Relat Cancer*, Vol. 12, No. 3, pp. (667-80), ISSN.
- Schulte, KM., Mengel, M., Heinze, M., Simon, D., Scheuring, S., Köhler, K. & Röher, HD. (2000). Complete sequencing and messenger ribonucleic acid expression analysis of the MEN I gene in adrenal cancer. *J Clin Endocrinol Metab*, Vol. 85, No. 1, pp. (441-8), ISSN.
- Sidhu, S., Marsh, DJ., Theodosopoulos, G., Philips, J., Bambach, CP., Campbell, P., Magarey, CJ., Russell, CF., Schulte, KM., Röher, HD., Delbridge, L. & Robinson, BG. (2002). Comparative genomic hybridization analysis of adrenocortical tumors. *J Clin Endocrinol Metab*, Vol. 87, No. 7, pp. (3467-74), ISSN.
- Sidhu, S., Sywak, M., Robinson, B. & Delbridge, L. (2004). Adrenocortical cancer: recent clinical and molecular advances. *Curr Opin Oncol*, Vol. 16, pp. (13-8), ISSN.
- Skogseid, B., Larsson, C., Lindgren, PG., Kvanta, E., Rastad, J., Theodorsson, E., Wide, L., Wilander, E. & Oberg, K. (1992). Clinical and genetic features of adrenocortical lesions in multiple endocrine neoplasia type 1. *J Clin Endocrinol Metab*, Vol. 75, No. 1, pp. (76-81), ISSN.
- Soon, P., McDonald, K., Robinson, B. & Sidhu, S. (2008). Molecular markers and the pathogenesis of adrenocortical cancer. *Oncologist*, Vol. 13, pp. (548-61), ISSN.
- Srivastava, S., Zou, ZQ., Pirollo, K., Blattner, W. & Chang, EH. (1990). Germ-line transmission of a mutated p53 gene in a cancer-prone family with Li-Fraumeni syndrome. *Nature*, Vol. 348, pp. (747-9), ISSN.
- Stojadinovic, A., Ghossein, RA., Hoos, A., Nissan, A., Marshall, D., Dudas, M., Cordon-Cardo, C., Jaques, DP. & Brennan, MF. (2002). Adrenocortical carcinoma: clinical, morphologic, and molecular characterization. *J Clin Oncol*, Vol. 20, No. 4, pp. (941-50), ISSN.
- Stowasser, M. (2009). Update in primary aldosteronism. *J Clin Endocrinol Metab*, Vol. 94, No. 10, pp. (3623-30), ISSN.
- Stratakis, CA., Courcoutsakis, NA., Abati, A., Filie, A., Doppman, JL., Carney, JA. & Shawker, T. (1997). Thyroid gland abnormalities in patients with the syndrome of spotty skin pigmentation, myxomas, endocrine overactivity, and schwannomas (Carney complex). *J Clin Endocrinol Metab*, Vol. 82, No. 7, pp. (2037-43), ISSN.
- Stratakis CA, Sarlis N, Kirschner LS, Carney JA, Doppman JL, Nieman LK, Chrousos GP, Papanicolaou DA. (1999) Paradoxical response to dexamethasone in the diagnosis of primary pigmented nodular adrenocortical disease. *Ann Intern Med*. Vol. 131(8), pp (585-91).

- Stratakis, CA., Kirschner, LS. & Carney, JA. (2001). Clinical and molecular features of the Carney complex: diagnostic criteria and recommendations for patient evaluation. *J Clin Endocrinol Metab*, Vol. 86, pp. (4041-6), ISSN.
- Stratakis, CA. & Boikos, SA. (2007). Genetics of adrenal tumors associated with Cushing's syndrome: a new classification for bilateral adrenocortical hyperplasias. *Nat Clin Pract Endocrinol Metab*, Vol. 3, pp. (748-57), ISSN.
- Sturgeon C, Shen WT, Clark OH, Duh QY, Kebebew E. (2006). Risk assessment in 457 adrenal cortical carcinomas: how much does tumor size predict the likelihood of malignancy? *J Am Coll Surg*. Vol. 202(3), pp (423-30).
- Sullivan, M., Boileau, M. & Hodges, CV. (1978). Adrenal cortical carcinoma. *J Urol*, Vol. 120, pp. (660-5), ISSN.
- Sutter, JA. & Grimberg, A. (2006). Adrenocortical tumors and hyperplasias in childhood: etiology, genetics, clinical presentation and therapy. *Pediatr Endocrinol Rev*, Vol. 4, No. 1, pp. (32-9), ISSN.
- Swain, JM., Grant, CS., Schlinkert, RT., Thompson, GB., vanHeerden, JA., Lloyd, RV. & Young, WF. (1998). Corticotropin-independent macronodular adrenal hyperplasia: a clinicopathologic correlation. *Arch Surg*, Vol. 133, No. 5, pp. (541-6), ISSN.
- Swords, FM., Baig, A., Malchoff, DM., Malchoff, CD., Thorner, MO., King, PJ., Hunyady, L. & Clark, AJ. (2002). Impaired desensitization of a mutant adrenocorticotropin receptor associated with apparent constitutive activity. *Mol Endocrinol*, Vol. 16, No. 12, pp. (2746-53), ISSN.
- Szolar, DH., Korobkin, M., Reittner, P., Berghold, A., Bauernhofer, T., Trummer, H., Schoellnast, H., Preidler, KW. & Samonigg, H. (2005). Adrenocortical carcinomas and adrenal pheochromocytomas: mass and enhancement loss evaluation at delayed contrast-enhanced CT. *Radiology*, Vol. 234, No. 2, pp. (479-85), ISSN.
- Tadjine, M., Lampron, A., Ouadi, L., Horvath, A., Stratakis, CA. & Bourdeau, I. (2008). Detection of somatic beta-catenin mutations in primary pigmented nodular adrenocortical disease (PPNAD). *Clin Endocrinol (Oxf)*, Vol. 69, No. 3, pp. (367-73), ISSN.
- Tanabe, A., Naruse, M., Naruse, K., Hase, M., Yoshimoto, T., Tanaka, M., Seki, T., Demura, R. & Demura, H. (1997). Left ventricular hypertrophy is more prominent in patients with primary aldosteronism than in patients with other types of secondary hypertension. *Hypertens Res*, Vol. 20, No. 2, pp. (85-90), ISSN.
- Terzolo, M., Osella, G., Ali, A. & Angeli, A. (2000). Adrenal incidentalomas. In: De Herder WW (ed). *Functional and Morphological Imaging of the Endocrine System*. Boston: Kluwer Academic Publishers, Vol. 7, pp. (191-211), ISSN.
- Terzolo M, Boccuzzi A, Bovio S, Cappia S, De Giuli P, Ali A, Paccotti P, Porpiglia F, Fontana D, Angeli A. (2001). Immunohistochemical assessment of Ki-67 in the differential diagnosis of adrenocortical tumors. *Urology*. Vol. 57(1), pp (176-82).
- Terzolo, M., Bovio, S., Reimondo, G., Pia, A., Osella, G., Borretta, G. & Angeli, A. (2005a). Subclinical Cushing's syndrome in adrenal incidentalomas. *Endocrinol Metab Clin North Am*, Vol. 34, No. 2, pp. (423-39), ISSN.
- Terzolo, M., Bovio, S., Pia, A., Conton, PA., Reimondo, G., Dall'Asta, C., Bemporad, D., Angeli, A., Opocher, G., Mannelli, M., Ambrosi, B. & Mantero, F. (2005b). Midnight serum cortisol as a marker of increased cardiovascular risk in patients with a clinically inapparent adrenal adenoma. *Eur J Endocrinol*, Vol. 153, No. 2, pp. (307-15), ISSN.

- Terzolo, M., Angeli, A., Fassnacht, M., Daffara, F., Tauchmanova, L., Conton, PA., Rossetto, R., Buci, L., Sperone, P., Grossrubatscher, E., Reimondo, G., Bollito, E., Papotti, M., Saeger, W., Hahner, S., Koschker, AC., Arvat, E., Ambrosi, B., Loli, P., Lombardi, G., Mannelli, M., Bruzzi, P., Mantero, F., Allolio, B., Dogliotti, L. & Berruti, A. (2007). Adjuvant mitotane treatment for adrenocortical carcinoma. *N Engl J Med*, Vol. 356, No. 23, pp. (2372-80), ISSN.
- Tissier, F., Cavard, C., Groussin, L., Perlemoine, K., Fumey, G., Hagneré, AM., René-Corail, F., Jullian, E., Gicquel, C., Bertagna, X., Vacher-Lavenu, MC., Perret, C. & Bertherat, J. (2005). Mutations of beta-catenin in adrenocortical tumors: Activation of the Wnt signaling pathway is a frequent event in both benign and malignant adrenocortical tumors. *Cancer Res*, Vol. 65, No. 17, pp. (7622-7), ISSN.
- Tissier, F. (2010). Classification of adrenal cortical tumors: what limits for the pathological approach? *Best Pract Res Clin Endocrinol Metab*, Vol. 24, No. 6, pp. (877-85), ISSN.
- Ulick, S., Wang, JZ. & Morton, DH. (1992). The biochemical phenotypes of two inborn errors in the biosynthesis of aldosterone. *J Clin Endocrinol Metab*, Vol. 74, pp. (1415-20), ISSN.
- van Ditzhuijsen, CI., van de Weijer, R. & Haak, HR. (2007). Adrenocortical carcinoma. *Neth J Med*, Vol. 65, No. 2, pp. (55-60), ISSN.
- Varley, JM., McGown, G., Thorncroft, M., James, LA., Margison, GP., Forster, G., Evans, DG., Harris, M., Kelsey, AM. & Birch, JM. (1999). Are there low-penetrance TP53 Alleles? Evidence from childhood adrenocortical tumors. *Am J Hum Genet*, Vol. 65, No. 4, pp. (995-1006), ISSN.
- Veugelers, M., Wilkes, D., Burton, K., McDermott, DA., Song, Y., Goldstein, MM., La Perle, K., Vaughan, CJ., O'Hagan, A., Bennett, KR., Meyer, BJ., Legius, E., Karttunen, M., Norio, R., Kaariainen, H., Lavyne, M., Neau, JP., Richter, G., Kirali, K., Farnsworth, A., Stapleton, K., Morelli, P., Takanashi, Y., Bamforth, JS., Eitelberger, F., Noszian, I., Manfroi, W., Powers, J., Mochizuki, Y., Imai, T., Ko, GT., Driscoll, DA., Goldmuntz, E., Edelberg, JM., Collins, A., Eccles, D., Irvine, AD., McKnight, GS. & Basson, CT. (2004). Comparative PRKAR1A genotype-phenotype analyses in humans with Carney complex and PRKAR1a haploinsufficient mice. *Proc Natl Acad Sci U S A*, Vol. 101, No.39, pp. (14222-7), ISSN.
- Volante, M., Buttigliero, C., Greco, E., Berruti, A. & Papotti, M. (2008). Pathological and molecular features of adrenocortical carcinoma: an update. *J Clin Pathol*, Vol. 61, No. 7, pp. (787-93), ISSN.
- Wada, S., Kitahama, S., Togashi, A., Inoue, K., Iitaka, M. & Katayama, S. (2002). Preclinical Cushing's syndrome due to ACTH-independent bilateral macronodular adrenocortical hyperplasia with excessive secretion of 18-hydroxydeoxycorticosterone and corticosterone. *Intern Med*, Vol. 41, No. 4, pp. (304-8), ISSN.
- Waggoner, W., Boots, LR. & Azziz, R. (1999). Total testosterone and DHEAS levels as predictors of androgen-secreting neoplasms: a populational study. *Gynecological Endocrinology*, Vol. 13, pp. (394-400), ISSN.
- Wagner, J., Portwine, C., Rabin, K., Leclerc, JM., Narod, SA. & Malkin, D. (1994). High frequency of germline p53 mutations in childhood adrenocortical cancer. *J Natl Cancer Inst*, Vol. 86, No. 22, pp. (1707-10), ISSN.
- Wajchenberg, BL., Albergaria Pereira, MA., Medonca, BB., Latronico, AC., Campos Carneiro, P., Alves, VA., Zerbini, MC., Liberman, B., Carlos Gomes, G. & Kirschner,

- MA. (2000). Adrenocortical carcinoma: clinical and laboratory observations. *Cancer*, Vol. 88, No. 4, pp. (711-36), ISSN.
- Wasserman JD, Zambetti GP, Malkin D. (2011) Towards an understanding of the role of p53 in adrenocortical carcinogenesis. *Mol Cell Endocrinol*. Sep 10. [Epub ahead of print]
- Watanabe, M. & Nakajin, S. (2004). Forskolin up-regulates aromatase (CYP19) activity and gene transcripts in the human adrenocortical carcinoma cell line H295R. *J Endocrinol*, Vol. 180, No. 1, pp. (125-33), ISSN.
- Weber MM., Auernhammer CJ., Kiess W., and Engelhardt D. (1997) Insulin-like growth factor receptors in normal and tumorous adult human adrenocortical glands. *European Journal of Endocrinology* Vol. 136 pp. (296-303).
- Weber, SL. (1997). Cushing's syndrome attributable to topical use of lotrisone. *Endocr Pract*, Vol. 3, pp. (140-4), ISSN.
- Weinstein, LS., Shenker, A., Gejman, PV., Merino, MJ., Friedman, E. & Spiegel, AM. (1991). Activating mutations of the stimulatory G protein in the McCune-Albright syndrome. *N Engl J Med*, Vol. 325, pp. (1688-95), ISSN.
- Weiss, LM. (1984). Comparative histologic study of 43 metastasizing and nonmetastasizing adrenocortical tumors. *Am J Surg Pathol*, Vol. 8, pp. (163-9), ISSN.
- White, PC., New, MI. & Dupont, B. (1987). Congenital adrenal hyperplasia. *N Engl J Med*, Vol. 316, pp. (1519-24), ISSN.
- White, PC. (1994). Disorders of aldosterone biosynthesis and action. *N Engl J Med*, Vol. 331, pp. (250-8), ISSN.
- Wiedemann, HR. (1983). Tumours and hemihypertrophy associated with Wiedemann-Beckwith syndrome. *Eur J Pediatr*, Vol. 141, pp. (29), ISSN.
- Wieneke, JA., Thompson, LD. & Heffess, CS. (2003). Adrenocortical neoplasms in the pediatric population: a clinicopathologic and immunophenotypic analysis of 83 patients. *Am J Surg Pathol*, Vol. 27, No. 7, pp. (867-81), ISSN.
- Wilkins, L. (1948). A feminizing adrenal tumor causing gynecomastia in a boy of five years contrasted with a virilizing tumor in a five-year-old girl: classification of seventy cases of adrenal tumor in children according to their hormonal manifestations and a review of eleven cases of feminizing adrenal tumor in adults. *J Clin Endocrinol Metab*, Vol. 8, pp. (111-32), ISSN.
- Wood, BJ., Abraham, J., Hvizda, JL., Alexander, HR. & Fojo, T. (2003). Radiofrequency ablation of adrenal tumors and adrenocortical carcinoma metastases. *Cancer*, Vol. 97, pp. (554-60), ISSN.
- Young, WF. (2000). Management approaches to adrenal incidentalomas: a view from Rochester, Minnesota. *Endocrinol Metab Clin North Am*. Vol. 29, pp (159-85).
- Young, WF. (2007a). Primary aldosteronism: renaissance of a syndrome. *Clin Endocrinol (Oxf)*, Vol. 66, No. 5, pp. (607-18), ISSN.
- Young, WF. (2007b). The incidentally discovered adrenal mass. *N Engl J Med*, Vol. 356, pp. (601-10), ISSN.
- Zarifis, J., Lip, GY., Leatherdale, B. & Beevers, G. (1996). Malignant hypertension in association with primary aldosteronism. *Blood Press*, Vol. 5, pp. (250-4), ISSN.
- Zerbini, CA., Kozakewich, HP., Weinberg, DS., Mundt, DJ., Edwards, JAI. & Lack, EE. (1992). Adrenocortical neoplasms in childhood and adolescence: analysis of prognostic factors including DNA content. *Endocr Pathol*, Vol. 3, pp. (116-28), ISSN.



Contemporary Aspects of Endocrinology

Edited by Dr. Evanthia Diamanti-Kandarakis

ISBN 978-953-307-357-6

Hard cover, 454 pages

Publisher InTech

Published online 30, November, 2011

Published in print edition November, 2011

This book aims to provide readers with a general as well as an advanced overview of the key trends in endocrine disorders. While covering a variety of topics ranging from thyroid carcinogenesis and pituitary adenomas to adrenal tumors and metabolic bone disease, this book also focuses on more specific issues not yet fully elucidated (e.g. the molecular pathways involved in thyrotropin beta gene regulation or monogenic phosphate balance disorders). Readers of different fields and background will have the opportunity to update their knowledge and more importantly to clarify areas of uncertainty and controversies in several topics of endocrine disorders.

How to reference

In order to correctly reference this scholarly work, feel free to copy and paste the following:

Duarte Pignatelli (2011). Adrenal Cortex Tumors and Hyperplasias, Contemporary Aspects of Endocrinology, Dr. Evanthia Diamanti-Kandarakis (Ed.), ISBN: 978-953-307-357-6, InTech, Available from: <http://www.intechopen.com/books/contemporary-aspects-of-endocrinology/adrenal-cortex-tumors-and-hyperplasias>

INTECH
open science | open minds

InTech Europe

University Campus STeP Ri
Slavka Krautzeka 83/A
51000 Rijeka, Croatia
Phone: +385 (51) 770 447
Fax: +385 (51) 686 166
www.intechopen.com

InTech China

Unit 405, Office Block, Hotel Equatorial Shanghai
No.65, Yan An Road (West), Shanghai, 200040, China
中国上海市延安西路65号上海国际贵都大饭店办公楼405单元
Phone: +86-21-62489820
Fax: +86-21-62489821

© 2011 The Author(s). Licensee IntechOpen. This is an open access article distributed under the terms of the [Creative Commons Attribution 3.0 License](#), which permits unrestricted use, distribution, and reproduction in any medium, provided the original work is properly cited.

IntechOpen

IntechOpen