

We are IntechOpen, the world's leading publisher of Open Access books Built by scientists, for scientists

4,800

Open access books available

122,000

International authors and editors

135M

Downloads

Our authors are among the

154

Countries delivered to

TOP 1%

most cited scientists

12.2%

Contributors from top 500 universities



WEB OF SCIENCE™

Selection of our books indexed in the Book Citation Index
in Web of Science™ Core Collection (BKCI)

Interested in publishing with us?
Contact book.department@intechopen.com

Numbers displayed above are based on latest data collected.

For more information visit www.intechopen.com



Endoscopy in Paediatric Inflammatory Bowel Disease (IBD)

Marco Gasparetto and Graziella Guariso

*Department of Paediatrics,
Unit of Gastroenterology, Hepatology,
Digestive Endoscopy and Care of the Liver Transplanted Child,
University of Padua,
Italy*

1. Introduction

Endoscopic investigation has become more and more important for diagnosis, follow-up and management of Inflammatory Bowel Disease (IBD) affected patients in the last decades [1].

In fact it allows us to evaluate the grade and extension of bowel inflammation, thus the severity of disease, its prognosis, and the response to therapy as well as the possible indication to a surgical intervention [1]. An endoscopic treatment of several complications (i.e. stenosis) also represents a useful possibility being available.

Moreover, the advent of techniques such as capsule and both single and double-balloon-assisted enteroscopy is revolutionizing small-bowel imaging and has major implications for diagnosis, classification, therapeutic decision making and outcomes in the management of IBD [2].

The last available Consensus document reached by a group of international experts in the fields of endoscopy and IBD at a meeting held in Brussels (organised jointly by the European Crohn's and Colitis Organisation ECCO and the Organisation Mondiale d'Endoscopie Digestive OMED) dates back to 12-13th December 2008 [2]. The statements included in this document with the relative levels of evidence and grades of recommendation will be reported as a referral along the chapter.

Endoscopy is able to differentiate Crohn's Disease (CD) and Ulcerative Colitis (UC) in 89% of cases. Essentially it is nowadays the most efficacious and diffused technique to evaluate CD localisation and activity at the level of terminal ileum and colon; its accuracy for results are therefore significantly superior with respect to bowel enema [1].

An immediate diagnosis with excellent accuracy is obtainable when endoscopy is associated to the histological examination of biopsy samples [3].

The endoscopic procedure for paediatric patients with IBD differs significantly from the modalities in use for adults, especially in regards of the use of sedation-analgesia, and the number and localisation of the mucosal biopsies effectuated and the regular inclusion of terminal ileum intubation within a complete investigation. [4-6].

In the paediatric age, assistance with anesthesia allows one to perform a complete endoscopic examination with visualisation of terminal ileum in 90% of cases [3].

Limitations of endoscopy are however the impossibility to completely evaluate the small bowel, just the first 2-3 loops of small-bowel and the last 20-30 cm of terminal ileum, as well as the necessity of profound sedation-analgesia in the paediatric age [3].

The endoscopic evaluation of mucosal healing is important to identify the efficacy of a specific therapeutic regimen: a significant correlation has been observed, for instance, among administration of new drugs such as anti TNF $-\alpha$ (infliximab, natalizumab and adalimumab), azathioprine and methotrexate, clinical improvement and disappearance of endoscopic lesions; mucosal healing has not been shown, but instead to be predictive for response to orally administered corticosteroids [1].

Determinant is the role of endoscopy for the prediction of a possible post-surgical relapse (endoscopic relapse is reported in 60- 70% of cases at 6- 12 months whereas a clinical relapse is observed in 50% of cases at 3 years follow-up for Crohn's disease); for those patients with an endoscopic remission, a significant reduction of hospitalization and surgical intervention has also been observed [1].

2. Upper gastrointestinal tract endoscopy: General aspects

The presence of symptoms related to the upper gastrointestinal tract such as dysphagia, odinophagia, nausea and/or vomit, oral ulcers, represents a typical indication to an upper-tract endoscopy in the phases of diagnosis and staging of IBD [4-5].

It should also be noted that even in the absence of symptoms, the upper gastrointestinal tract involvement appears more and more frequently present at the endoscopic and histological evaluation of patients with CD. The importance of taking biopsies at this level has to be considered, even with an endoscopically normal mucosa [4-5].

'Small-bowel endoscopy' is defined as any endoluminal examination of the small bowel, including capsule endoscopy, push enteroscopy and balloon- or other device-assisted endoscopy [2].

A gastroscope with a diameter of 9 mm is used for children weighing more than 15 Kg and a probe with a diameter of 8 mm is used for body weights between 5 and 15 Kg. A diameter of 5-7 mm is used for newborns weighing 2.5-4 Kg whereas a probe with a diameter of 5-6 mm is used for newborn weighing less than 2.5 Kg [7-8].

The endoscopic lesions that are typically observed in oesophagus include erythema, ulcerations, strictures and mucosal bridges. The histological finding of non caseating granulomata in oesophagus is observed in 20-30% of patients [4-5].

At the gastric and duodenal levels, typical endoscopic lesions include ulcerations (which can be linear, curve-shaped, diffuse, superficial or aphthous), nodularities, cobble-stone mucosa, bowel wall rigidity and luminal strictures [4-5].

A focal antral gastritis, negative for *Helicobacter Pylori*, has been observed in 84% of CD affected patients.

UC was not traditionally associated to an extension involving more than colon and ileum.

However, inflammatory lesions at the level of the upper gastrointestinal tract have recently been frequently observed also in UC patients (up to 70%) [4-5].

3. Ileum – colonoscopy: General aspects

A video – colonoscope with adulthood-dimensioned size can be used for patients aged from 3-4 years and/or with body weight of at least 12-15 Kg [4-5-8]. This colonoscope for adults is

more rigid and diminishes the risk of loops formation; it requires, however, a peculiar attention of the operator for the risk of perforations, mainly for smaller children. Moreover its larger diameter can determine limitations in manoeuvrability in the more restricted lumen of the child.

A colonoscope with a diameter of 11.1-11.7 mm is therefore more indicated for the whole pediatric age [7-8].

Before any colonoscopy, it's good practice to perform a digital anal exploration and, subsequently, a rectal exploration in order to detect any possible lesion being localized at the lower segments; the retroversion of the colonoscope is also important for this purpose [4-5].

An adequate lubrication allows an easier transit through into the rectum, which can also be helped by the guide of the index finger of the operator [4-5].

As for inflation, CO₂ can represent an alternative to air since it is more rapidly absorbed thus produces minor discomfort, as well as a minor theoretical risk of perforation [4-5].

The patient is usually placed in lateral security position [4-5].

If during the procedure a difficulty in overcoming the splenic flexure is observed, the patient can be replaced in the supine position as well as on the opposite side. An assistant located on the left of the operator exercises an abdominal pressure in order to check and prevent any loop formation at the sigma or transverse colon. A moderate air inflation is preferable in the Sigma to avoid that an excessive volume increases any risk of loop formation [4-5].

When the operator needs to increase the penetration pressure of the instrument, a loop formation may have been produced [4-5].

The length of the colonoscope at the splenic flexure in the absence of loops is of 40 cm for older children whereas it can decrease to 20-25 cm in children aged 3-4 years old. At the hepatic flexure, instead, it is of 60 cm in the absence of loops for the older children and 40 cm for 3-4 year old children. At the cecum, the length from the anus is about 80 cm for the older children and 40-60 cm for the younger ones. The ileum-cecal valve is localized at about 1-4 cm distally in respect to the appendix orifice and opens perpendicularly to the colon axis [4-5].

In order to prevent any tension of the bowel wall, the aspiration of the air inside the cecum is suggested before ileum intubation. Ileum intubation allows its evaluation up to 40 cm. At this level, therapeutic dilations of the terminal ileum can be effectuated through a perendoscopic balloon [4-5].

Biopsic samples should be performed on each area, including segments of apparently normal mucosa [4-5].

4. Morphology of lesions

Typical endoscopic lesions in CD are [3-5] (Fig. 1-4):

- aphthous ulcerations (generally multiple, focal, with small diameter and surrounded by normal erythematous mucosa)
- mucosal nodularities
- mucosal aspect of cobblestone (resulting from interception of long ulcerative lesions and large tortuous ones including areas of thickened mucosa within)
- flattening of ileal mucosa
- pseudomembranous formations

- mucosal bridges
- stenosis (mild to severe, more frequently localized at the Bauhin valve) [1][3].

Inflammatory pseudopolyps are less frequent in CD with respect to UC [3].

According to the mucosal and phenotypical characteristics at onset, CD is classified into inflammatory, stenosing and fistulizing.

Since CD can potentially involve the whole gastrointestinal tract, the intubation of ileum and upper gastrointestinal endoscopy are always indicated for a complete stadiation of the disease.

At the level of the strictures, the intestinal mucosa usually appears actively inflamed, frequently ulcerated and bleeding.

In the fistulizing CD phenotype, the internal orifice of the fistula can be observed on the bowel wall, generally in correspondance of inflamed areas.

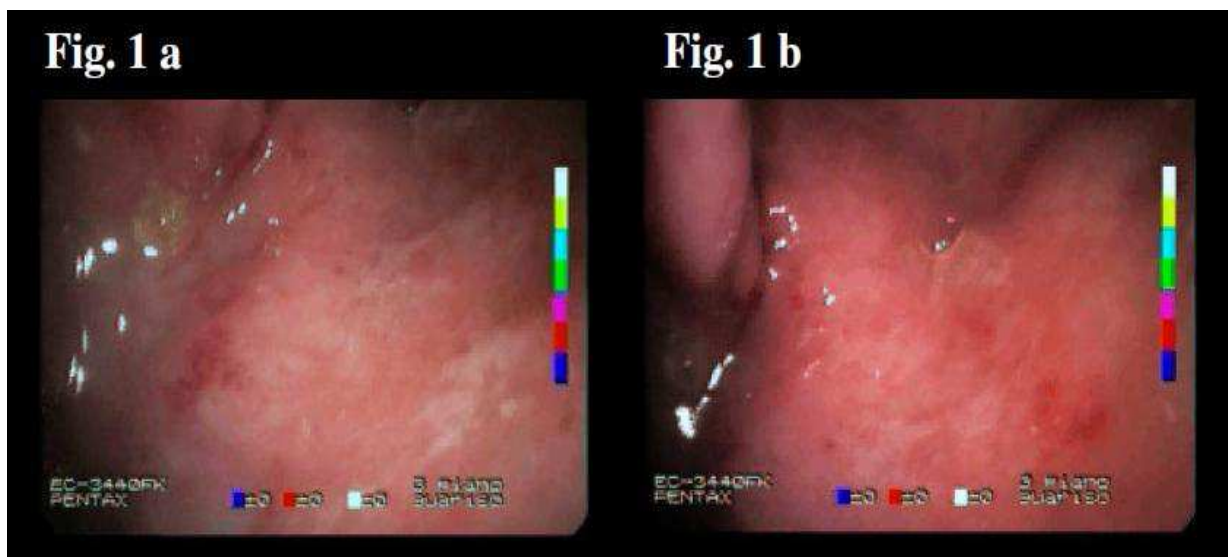


Fig. 1. Gastric mucosa with focal aphthous ulcerations (a) surrounded by erythematous mucosa (b) in Crohn's Disease

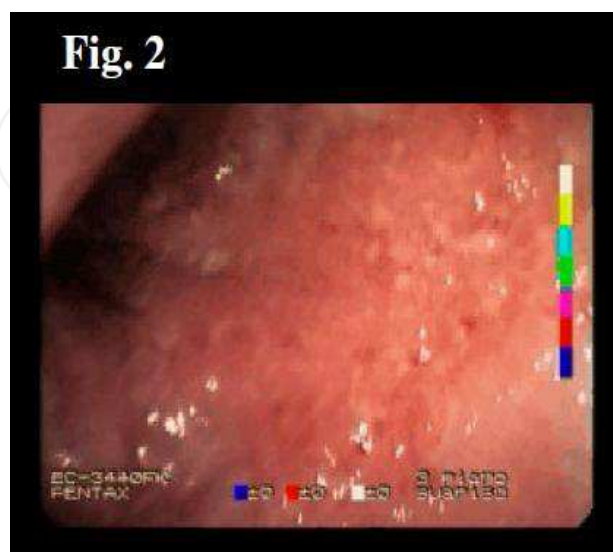


Fig. 2. Gastric mucosal nodularities and cobblestone pattern in Crohn's Disease

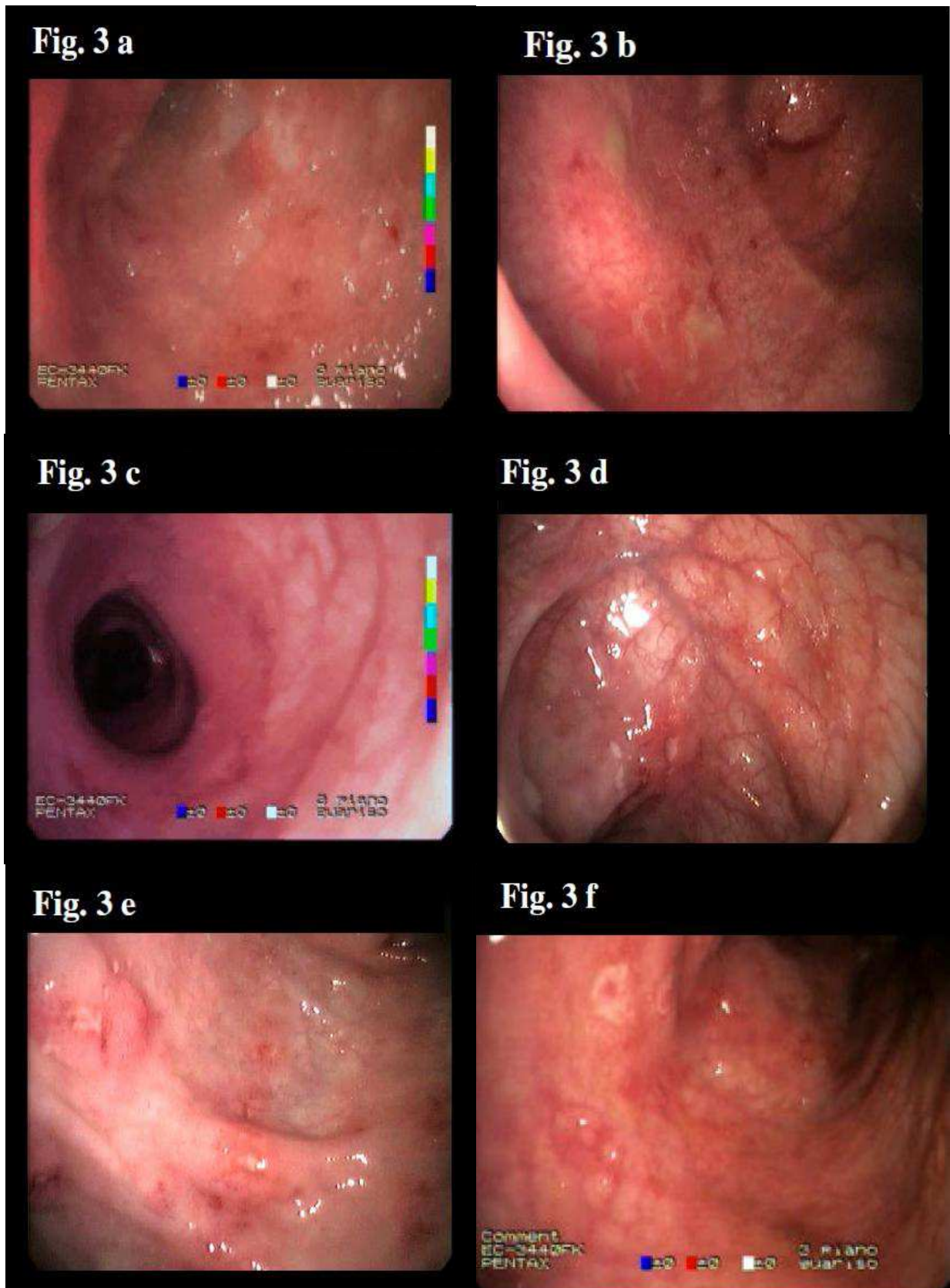


Fig. 3. Colonic mucosa with focal aphthous ulcerations (a-b) surrounded by erythematous mucosa (c-d-e-f) in Crohn's Disease

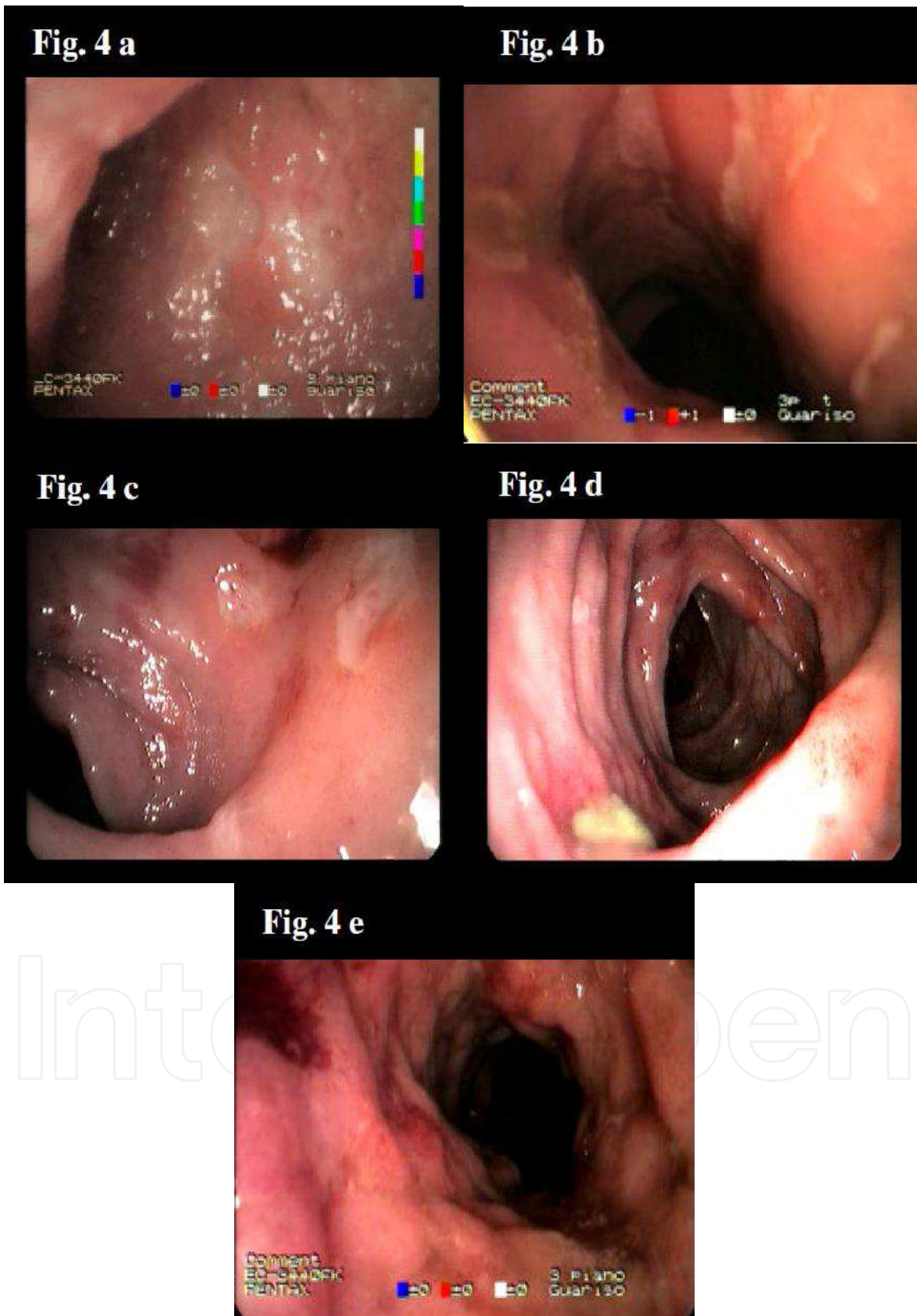


Fig. 4. Colonic mucosa with extensive deep ulcerations (a, b, c, d) and cobblestone pattern (e) in Crohn's Disease

The histological findings which are more characteristic of CD are: trans-mural inflammation with infiltration and fibrosis; dilatation and sclerosis of lymphatic vessels; lymphatic aggregates; the typical non - caseating granulomata. Other possible findings include excess of histiocytes, giant perinucleated cells (Langhan's like), mucous gland cells hyperplasia, focal criptitis, pseudopyloric metaplasia of colocytes and decrease of inflammation grade from the upper to the lower colon [9].

Even though the macroscopic and hystological characteristics are frequently discriminating for UC and MC, in those cases in which a differential diagnosis cannot be set, the disease is identified as Unclassified IBD, presenting intermediate characteristics between CD and UC. Infective colitis can also present a macroscopic pattern being similar to that of IBD [3].

For this reason, multiple biopsies should always be suggested at each segment for diagnosis [3].

In UC the inflammatory process is limited to mucosa and submucosa and it spreads for continuity from rectum to the whole colon [3].

Instead in CD inflammation is trans-mural and "patchy" lesions can be found throughout the whole gastrointestinal tract; an involvement of adjacent lymphonodes and mesenter as well as the formation of fistula and abscesses can be observed [3].

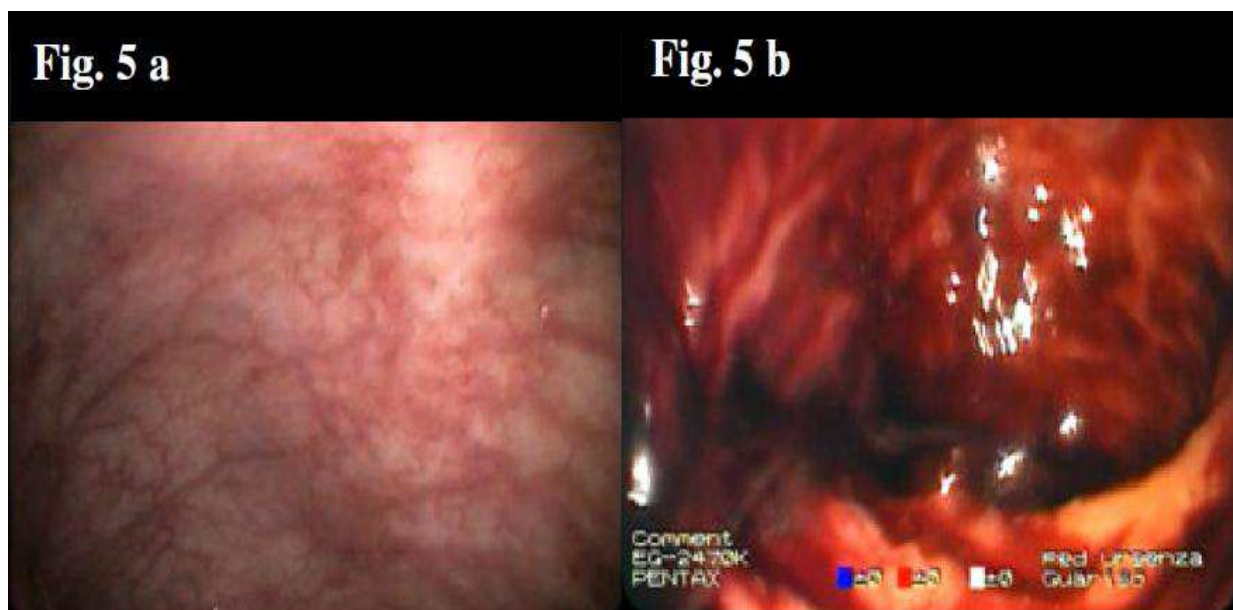


Fig. 5. Colonic erythematous mucosa with crispness (a) and mucosal bleeding (b) in Ulcerative Colitis

Endoscopic characteristics in UC [3-5] (Fig. 5):

- loss of vascularization
- diffuse hyperemia
- edema
- mucosal crispness and/or bleeding at the contact of the endoscope
- mucous - suppurative secretion
- diffuse erosions covered by fibrine

Other possible findings:

- ulcerations of variable diameter and number, surrounded by actively inflamed and potentially bleeding mucosa

- aphthous ulcerations
- inflammatory pseudopolyps, generally parietal, consequence of the regeneration of previously ulcerated areas
- mucosal granularity
- nodules with erosions above
- loss of colonic haustrae with aspect of “rigid tube”
- backwash ileitis: ileal extension of lesions in pancolitis
- patchy colitis
- relative rectal sparing

Baron and Mayo scores are the two principle indexes for the endoscopic grading of UC [3].

As regards the major histological alterations in UC, they are distorted with the disappearance of mucous glandular architecture and inflammatory infiltration of the crypts. They also have a villi-like profile of the mucosal surface, a high grade alteration of the mucosal architecture, Paneth cells metaplasia and a decrease of the inflammation and mucosal alteration grade from the upper to the lower colonic tract are seen [9].

5. Contraindications to endoscopic procedure

Absolute: toxic megacolon, suspect of intestinal perforation, shock [3]

Relative: hyperacute situations with associated risk of severe complications such as perforation and abundant bleeding.

The risk of complications is equal to 0.3% per procedure and decreases to 0.05% in the absence of polypectomy [4].

Conservative therapy is used in cases of asymptomatic perforations or in localized peritonitis, in the absence of signs and symptoms of sepsis. In any more severe situations, the operating approach consists in the resection of the intestinal segment and anastomosis [4-5].

Splenic rupture is a very rare complication, that manifests with hypovolemia, pain at the shoulder or abdominal pain appearing within 24 hours after the performance of ileum-colonoscopy.

Equally rare is also pancreatitis caused by the rupture of the pancreas within the procedure [4-5].

6. SES – CD score for Crohn’s Disease

Being mucosal healing a fundamental end-point for treatment of CD, the necessity to define a simple score for the endoscopic activity of disease has emerged in the last few years [1].

Such a score results from the addition of single evaluations: ulcer’s dimension, extension of the ulcerated surface, presence and severity of stricture [1].

From the validation studies, SES – CD comes out to be simple, reproducible and easy to be used for CD; a strong relation among the score value, the clinical parameters of the disease (pCDAI) and blood levels of CRP have been identified [1].

The correlation between SES –CD and pCDAI is statistically significant, despite the limitation due to the fact that many extra intestinal manifestations are clinically manifested but are not necessarily accompanied by any mucosal involvement [1].

Other possible limitations of SES-CD are the presence of fistulas (for the evaluation of which endoscopy does not represent the best diagnostic tool), underestimation of strictures (due to the functional nature of the classification being used; what is considered is, in fact, the

capacity of the endoscope to overcome the stricturing tract) and overestimation of non-specific lesions (at this level the endoscopic experience of the operator is determinant) [1].

The addition prefigures the evaluation of 5 pre-determined ileum-colonic segments: ileum (explorable portion), right colon (comprehending the ileum-cecal valve, cecum, ascendant colon, hepatic flexure), transverse colon, left colon (comprehending descendant colon, sigma, rectum-sigmoid junction), rectum. For each segment, the evaluation of four endoscopic variables is prefigured: presence of ulcers, extension of ulcerated surface, extension of the surface with lesions, presence of stenosis. For each variable, a score ranging from 0 to 3 is assigned to each segment [1].

The classification of the ulcers for the SES-CD addition is based on their dimensions; therefore the extension of the ulcerated segment is evaluated attributing a score of 3 to those cases with a surface involvement exceeding 30%: such a proportion of extension is thus considered as the most severe pattern, since a major extension has no additional effect on the severity of symptoms [1].

The classification of strictures for SES-CD is both descriptive and functional; in fact it is based on the capacity of the endoscope to overcome a segmental luminal narrowing [1].

7. Further diagnostic applications of the endoscopic examination

Device-assisted enteroscopy (DAE) is a generic term for endoluminal examination of the small bowel by any endoscopic technique that includes assisted progression (e. g. by a balloon, overtube, or other stiffening device) [2]. DAE can be used to diagnose Crohn's disease, because histological corroboration is available.

A fundamental endoscopic application in the follow-up of IBD affected patients is the endoscopic surveillance for any dysplasia (a high-grade dysplasia evolve to invasive carcinoma in 33-100% of cases) [1]. As reported by the American Gastroenterology Society guidelines, the risk of neoplasia increases in cases of a long lasting disease with early onset, severe extension of disease, familiarity for cancer of colon-rectum, presence of backwash ileitis and history of sclerosing cholangitis [3]. Furthermore carcinogenesis correlates with the activity of inflammation [4-5].

Aiming to the surveillance and early diagnosis of any arising neoplasia, the ideal number of biopsies to be taken during an endoscopic examination is 2-4 every 10 cm (and on 4 quadrants). For the paediatric age, such a surveillance schedule is indicated for cases with disease duration > 8 years [4].

Techniques like chromoendoscopy and AFI (auto-florescence imaging) increase from 2 to 5 times the sensitivity for the identification of any neoplastic lesion; on the contrary no significant advantages have been observed with NBI (narrow binding imaging) technique, with respect to traditional endoscopy [1].

An endoscopic examination is recommended, after 2-3 months since the beginning of treatment in patients with a new diagnosis, in order to evaluate the efficacy of the ongoing therapy to get mucosal healing.

Another major role of the endoscopic examination involves those patients with IBD that undergo a surgical intervention with confectioning of ileal-pouch [3][10]. A post-surgical pouchitis is- in fact- common: it can be mild to severe and generally does not involve the last ileal oxbow (23-46% of cases at 10-11 years of age). A surveillance of the macro- and microscopic inflammation is possible through scheduled post-operative controls.

The *push enteroscopy*, per os or laparoscopic, is an evolving technique which is useful for diagnostic evaluation of the small bowel [4-5]. It consists in an endoluminal examination of the proximal jejunum using a long, flexible endoscope [2]. At present, endoscopes with length up to 230 cm, diameter of 10 mm and deflexion grades up to 160-180° are used. Per os, it is possible to reach a length of 120-180 cm beyond Treitz ligament; with laparoscopic assistance, also the terminal ileum is reached.

Push enteroscopy allows tissue sampling, polypectomy, and treatment of bleeding lesions [2].

In recent years, balloon-assisted endoscopic techniques have largely replaced push enteroscopy in examination of the small bowel.

More recently, advanced endoscopic techniques of *balloon-assisted* and *spiral enteroscopy* have allowed direct tissue sampling for histopathology and therapeutic procedures in the small bowel. However the role of these investigations in the diagnosis and management of IBD is unclear [2][3].

Balloon-assisted enteroscopy (BAE) is a generic term for endoluminal examination of the small bowel by any endoscopic technique that includes balloon-assisted progression [2].

Single-balloon enteroscopy (SBE) is defined as endoluminal examination of the small bowel using a single-balloon endoscope [2].

Double-balloon enteroscopy (DBE) is defined as endoluminal examination of the small bowel using a double-balloon endoscope [2]. DBE, first described by Yamamoto and colleagues in 2001, allows deep (even complete) intubation of the small bowel by pleating the bowel onto a long, flexible endoscope fitted with an overtube [2].

DBE needs to be performed under deep sedation or general anesthesia which allows the execution of biopsies as well as of therapeutical procedures such as emostasis and dilatations [4]. The DBE system consists in a video-enteroscope (length of 200 cm, diameter of 8.5 mm), with overtube and elevate resolution. On the overtube as well as on the extremity of the instrument, two balloons are placed; these can be inflated and deflated with air, throughout a pressure-regulated control system (P max 45 mmHg). Both are deflated at the beginning of the procedure. Once duodenum is reached, the balloon on the overtube is inflated to stabilize the tube which is pushed foreword as much as possible. Subsequently, the balloon on the enteroscope is inflated while the one on the overtube is deflated, so that the overtube can be pushed foreword to the tip of the instrument. By repeating the procedure with the same order, the instrument progressively advances visualizing the entire small bowel.

DBE is particularly useful for patients with obscure gastrointestinal bleeding as well as for those with suspicion of CD but with negative ileoscopy and imaging. It allows us to identify early lesions like aphthae, erosions and small ulcers. Large portions of the small bowel can be visualized directly; oral and anal routes, alone or in combination, are used to achieve complete small-bowel examination [2].

Endosonography uses a colonoscope with frontal vision and with a transducer (emitting sound waves with a frequency of 7.5 Hz) placed on the rigid extremity or being introduced through the operative tube. A fluid of interface is necessary and can be obtained through filling the balloon with water as well as in the intestinal segment to be examined [4]. In the paediatric age, indications to this technique can include suspicion of neoplasia (early identification of adenoma), evaluation of the extension and depth of lesions (in particular perirectal and pericolonic abscesses), strictures, fistula and anastomosis [4-5].

Characteristic findings of IBD from endosonography are bowel wall thickening with loss of the normal structure, which is secondary to progressive inflammation. Although the

differentiation between CD (with transparietal involvement) and UC may be set through echoendoscopy, UC in phase of activity can in certain cases manifest with findings which are referable to CD [4-5].

Other useful parameters which can be evaluated through echoendoscopic doppler are velocity of maximal flux in the superior mesenteric artery and the increase in transparietal vascularisation [4-5].

The high magnification endoscopy (HMCC) allows a magnification of up to 100 times. The images obtained close in on the histological findings both for the segments of normal mucosa and for those with clearly evident lesions; it is not possible, however, to identify those mild mucosal alterations, which are on the contrary recognizable at histology [4]. This technique is particularly useful for the execution of targeted biopsies and can be taken into consideration also for the surveillance of the development of neoplasia in IBD affected patients.

Confocal Laser Endomicroscopy (CLE) is a technology developed in the last 5 years which focalises on a single point of a laser illumination at a low power [4-5]. The distal extremity of the endoscope contains a channel for air and water, two guide lights, an operating channel with diameter 2.8 mm and an auxiliary channel for water. The sodium-fluorescein administered i.v. at the beginning of the procedure is used as a mean of contrast. Cellular and subcellular microscopic images are obtained. This technique allows the execution of targeted biopsies in IBD affected patients, reducing the number of bioptic samples to be taken [4-5].

Intraoperative enteroscopy (IOE) is defined as an endoluminal examination of the small bowel during abdominal surgery with manual external assistance for endoscope progression. By definition, IOE is an exploration of the small intestine with an endoscope (gastroscope, colonoscope, pediatric colonoscope, or enteroscope) during a surgical procedure [2].

Spiral enteroscopy is a recently developed technique. An enteroscope, introduced orally, is passed through a single-use overtube, which has helical spirals at its distal end and rotates independently from the enteroscope. The enteroscope can be locked in the overtube allowing the option of spiral enteroscopy, or unlocked and advanced through the overtube [2].

8. Operative endoscopy

Beside diagnostic endoscopy, operative endoscopy also has a determinant role in the practical management of IBD affected patients [3].

In particular, CD patients have an elevated risk of relapses in the sites of surgical anastomosis where strictures can appear [3]. At this level, pneumatic endoscopic dilatations (balloons of 12-18 mm with pressures of 25-50 psi are used) as well as the placement of coated stents are techniques of important efficacy for the rechanneling of severe strictures (early efficacy in 86% of cases; late efficacy in 55% of cases) [1].

Before the advent of pneumatic perendoscopic dilators, patients with significant strictures necessary underwent a surgical intervention of resection of intestinal segments, with a risk of short bowel syndrome [3].

The response to operative endoscopy techniques has been demonstrated significantly higher, observing a minor risk of surgical intervention in those cases with extension of the stricture being ≤ 4 cm [1]. A recent study by Stienecker K [11], examined 31 strictures in a group of CD affected patients: in 30 of them balloon dilatation was successful in a single

endoscopic session, so that eventually the strictures could be passed easily with the standard colonoscope. Sufficient dilatation was not possible in one patient with a long stricture of the ileum involving the Bauhin valve and an additional stricture of the ileum which were 15 cm apart. This patient therefore required surgery. Available follow-up was in the range of 54-118 months (mean 81). The relapse rate over this period was 46%, but 64% of relapsing strictures could be successfully dilated again. Only in four patients was surgery required during this follow-up period. These initial results support endoscopic balloon dilatation, especially for short strictures in Crohn's disease, perforation a rare complication. In the long-term, the relapse rate is probably higher than after surgery, but usually a second endoscopic treatment can be performed successfully, leading to a considerable success rate of the endoscopic procedure. The overall technical success rate, defined as achieving an endoscopically passable residual stricture, is between 70% and 90 %, independent of the balloon's diameter having being used.

Indications to endoscopic dilatation of the strictures are [3]:

- severe strictures, with proximal bowel dilatation
- length of stenosis being < 2-3 cm
- endoscopic accessibility
- CD in remission or with low inflammatory activity

The dilatation is effectuated under deep sedation by insertion of the dilator across the stenosis and by inflation of the associated balloon with water and gastrographin in order to render it radio-opaque, therefore subjected to control [3]. Once the targeted diameter is reached, the balloon remains in loco for 1-2 minutes. An endoscopic control is usually performed one month later, in order to evaluate the diameter at the level of the precedent stenosis: if it is normal, a following endoscopic control is performed after 6 months whereas if the luminal diameter remains lower than 50% of the normal size, a new dilatation is programmed. The procedure should always be performed in a secure setting, in order to prevent the arousal of any complications [3].

The principle limitations to the use of endoscopy in paediatric age are mainly determined by the dimensions of the instrument [1].

Other frequently used endoscopic applications are: intra-operative ileoscopy (for the study of ileum during laparotomy), the removal of videocapsule (in cases when it is retained into the small bowel) and mucosal marking with china blue (to consent a major accuracy of the histological analysis) [1].

9. Small bowel capsule endoscopy (SBCE)

"Small-bowel capsule endoscopy (SBCE)" or "video capsule endoscopy" is a method of endoluminal examination of the small bowel using a wireless capsule shaped tool which is usually swallowed and then propelled through the gastrointestinal tract by gut motility.

Until a decade ago, mucosal visualization of the small bowel was limited to the reach of the push enteroscope as well as of the invasive and expensive intraoperative enteroscopy [2].

Even though push-enteroscopy has allowed us to access the visualization of the proximal jejunum extending the diagnostic potentialities of EGDS, it incidentally results in a relatively invasive technique [12]. Even more invasive is intra-operatory enteroscopy which in effect requires laparotomy and laparoscopy. Double-balloon enteroscopy allows a visualization of the entire bowel without necessity of surgical access, but requires a long time for manipulation.

Before the advent of video capsule endoscopy, the small bowel remained a “black box”, being almost inaccessible to the paediatric endoscopists.

The advent of small-bowel capsule endoscopy (SBCE) allowed for the first time direct visualisation of the entire small bowel, albeit without the ability for tissue sampling [2].

This new technique has actually revolutionised the field of enteroscopy, offering a method for the complete evaluation of the small bowel. It is a non invasive technique, secure both for the paediatric and the adult patient, that overcomes the limitations of barium contrasted enteroscopy (low specificity for initial inflammatory lesions) and of ileum-colonoscopy (which can at its best evaluate the terminal ileum) [13].

The lens with extremely short focus (1 mm) allows a very high precision of image, without requiring inflation with air and with a resolution of 0.1 mm [14].

A recent meta-analysis demonstrated the accuracy of video capsule endoscopy for the evaluation of the small bowel to be significantly superior to the one of enteroscopy and ileum-colonoscopy (63% vs 23% and 46% respectively); such a superiority is observed also with respect of other traditional techniques of imaging (i.e. TAC). Furthermore SBCE, can be useful for diagnosis of diseases involving the right colon [13].

This technique is therefore efficacious for the identification of superficial lesions which are not radiologically visible and the localisation of which can not be explored through endoscopy.

It is important for the study of the small bowel diseases (particularly for CD and U-IBD) in which the localisation at the small bowel can represent the unique site of disease, with consequent difficulty for a correct diagnosis [12].

The 2008 ECCO and OMED Consensus Statement [2] indicated that ileocolonoscopy must be performed prior to SBCE for the diagnosis of Crohn’s disease. Small-bowel cross-sectional imaging should generally precede SBCE. The choice of radiographic imaging depends on local availability and expertise.

SBCE should be performed in children or adolescents with a high suspicion of Crohn’s disease, when conventional endoscopy and small-bowel imaging are normal.

Younger children, under 9 years in particular, cannot generally assume and swallow the capsule. Determinants are the dimensions of the child, in terms of compatibility between capsular dimensions and the oesophageal sphincters, pylorus and ileum-cecal valve. It is important to ascertain the swallowing capacity of the child through simulations, i.e. vitaminic capsules with comparable dimensions, before performing SBCE. A valid alternative is the insertion of the capsule (length 25,3 mm, diameter 11 mm, weight 3.7 g) directly in the duodenum, using a dedicated device to perform the insertion [12-13].

This technique is particularly efficacious for the identification of paediatric patients with suspicion of Crohn’s disease manifesting a protein-losing enteropathy and/or growth deficit, gastro-duodenal bleeding, malabsorption, chronic abdominal pain, chronic diarrhoea, anorexia, anemia, hypoalbuminemia, positive serology for ASCA (being negative or poorly significant the other exams of the diagnostic flow-chart i.e. EGDS, ileum-colonoscopy, abdominal radiography); in these cases, moreover, capular endoscopy results economic as a test to be performed as a first-line indication [11] [14].

Other applications of SBCE comprehend [2][14][15]:

- Non invasive evaluation of the small bowel in patients with diagnosed CD but manifesting unexplained signs and symptoms (i.e. anemia)
- Assessment of postoperative recurrence of Crohn’s disease (SBCE should only be considered if ileocolonoscopy is contraindicated or unsuccessful)

- The discrimination between CD and UC in patients with U-IBD (video capsule endoscopy allows a diagnostic redefinition in 29-40% of patients with diagnosis of IBD-U)
- Evaluation of mucosal healing after treatment

The photographic objective, with angle of vision of 140°, permits an adequate visualization of the small bowel – considering the relative small diameter [12]. A complete evaluation of the gastrointestinal segments with major diameters, such as stomach and colon is in stead not possible.

Inside the capsule a coloured miniaturized camera, a battery and a transmission device are placed. Two images per second are acquired and sent, in form of radio waves, to 8 detection electrodes being placed on the abdominal surface of the patient and, from them, to an external recorder. The film on a monitor is then analyzed by the specialist. The duration of the test is of about 8 hours.

An adequate intestinal preparation to be effectuated the day before through assumption of iso-osmolar solutions at a dosage of 25-30 ml/Kg is recommended. It is in fact critically important for a good visualization of the small bowel mucosa [14]. Oral preparations of sodium-phosphate or poliethylenglicole (PEG) are used.

The administration of prokinetics may reduce transit times, increasing the complete evaluation of the small bowel. Randomized studies are nevertheless necessary to confirm their efficacy [14].

Patients should fast for at least 8 hours before the procedure and can start consuming liquids 1-2 hours after its begun; they can have light meals 2 hours after the ingestion of the capsule [14].

By the way, there is no available evidence to support a particular bowel preparation for SBCE in the subset of patients with suspected Crohn's disease [2]. The technique was approved by the American FDA in 2001 for adults and in 2003 for patients aging 10 to 18 years and presents a very low risk of complications. It can be performed for outpatients and does not expose to ionizing radiations, as it happens with the more common radiological techniques such as small bowel enema and abdominal TAC [8]. Also, small bowel lesions identified through capsular endoscopy are observed in 13% of normal asymptomatic adults, so they are not sufficient for a diagnosis of IBD. More importantly similar lesions are, identified in patients affected by Celiac Disease, allergic-infective-ischemic-rheumatic-autoimmune enteropathy, in immunodeficiencies and in NSAD enteropathy [14-15].

Video capsule endoscopy is the most efficacious test for diagnosis of patients with symptomatic "occult" CD but it is unspecific and does not allow itself the differential diagnosis among the above-mentioned patterns [14].

In summary, as it is stated in the 2008 ECCO and OMED Consensus, SBCE is able to identify mucosal lesions compatible with Crohn's disease in some patients in whom conventional endoscopic and small-bowel radiographic imaging modalities have been non diagnostic. As with other imaging modalities, a diagnosis of Crohn's disease should not be based on the appearances at capsule endoscopy alone. A normal capsule endoscopy has a high negative predictive value for active small-bowel Crohn's disease [2].

Principle limitations of SBCE [2]:

- Difficulties in swallowing of the younger child (Diameter 25.3 mm)
- Poor quality of the intestinal preparation
- Poor standardization of diagnostic reports
- Elevate costs

- A specificity of lesions (10% of patients can present IBD like lesions)
- Risk of capsule retention (5% of CD affected patients)

Principal contraindications to capsular endoscopy are suspected or known obstructions of the gastrointestinal tract because of an increased risk of retention of the capsule (incidence of 0,75 -5%), recent surgical interventions and patients with pace-maker [14][16].

Causes of obstruction and consequent retention of the capsule can be primitive lesions of IBD, drug induced lesions (es. NSAD), radiation induced lesions and neoplastic lesions (mainly in the young adults with a longer follow-up) [14].

In the majority of cases, retentions are temporary and asymptomatic [14].

In order to minimize the risk of capsule retention, an accurate anamnesis and clinical examination are fundamental. Any symptom possibly related to obstruction has to be identified, even though in most cases the capsule retention results asymptomatic [14].

Since the preliminary performance of enteroscopy for the evaluation of any possible stenosis does not exclude afterwards a capsule retention, the "patency capsule" appears, in stead, a more useful opportunity. It is made of lactose and barium, and begins to break up after the thirtieth hour: if its passage does not determine complications (the patient eliminates the capsule unbroken or the radio-frequencies emitted give out within thirty hours), then the video capsule endoscopy can be safely performed [14][16].

Extremely rare side effects of the patency capsule are abdominal pain and occasional temporary episodes of bowel occlusion.

When the capsule is actually retained, an orally administered corticosteroid therapy generally permits the progression of the capsule through the stricture [14].

The incidence of capsule retention among patients with suspected CD is of 10% whereas it is of 4-7% among those with diagnosis of CD [14].

In summary, as reported in the 2008 ECCO and OMED Consensus Statement [2]:

- In patients with suspected Crohn's disease the risk of small-bowel capsule retention is low and comparable to that when the indication for SBCE is bleeding.
- In patients with an established diagnosis of Crohn's disease the risk of small-bowel capsule retention is increased, particularly in those with known intestinal stenosis. It is essential to attempt to exclude small-bowel strictures by a thorough clinical history and radiographic imaging before SBCE [2]. However, normal radiographic studies cannot entirely exclude the potential for small-bowel capsule retention [2].

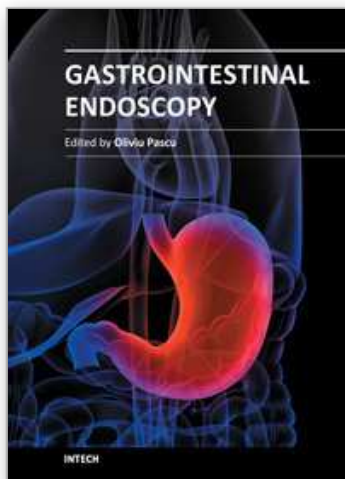
A patency (biodegradable, 'dummy') capsule to reduce the risk of retention should be considered, or DAE, if strictures are identified [2].

Passage of an intact patency capsule predicts safe transit of a small-bowel capsule of identical or lesser size. A patency capsule may itself cause obstruction at tight strictures, but this is usually transient. A retained small-bowel capsule can often be retrieved by DAE [2].

10. References

- [1] Daperno M, D'Haens G, Van Assche G, Baert F, Bulois P, Maunoury V, Sostegni R, Rocca R, Pera A, Gevers A, Mary JY, Colombel JF, Rutgeerts P: Development and validation of a new, simplified endoscopic activity score for Crohn's disease: the SES -CD. *Gastrointestinal Endoscopy* 2004; 60: 505-12.
- [2] Bourreille A et al. Role of small-bowel endoscopy in IBD: international OMED-ECCO consensus. *Endoscopy* 2009; 41: 618-637

- [3] De Angelis GL, Bizzarri B, De Angelis N, Borrelli O: The endoscopic diagnosis. In: SIGENP Consensus Statement (Italian Society of Gastroenterology Hepatology and Nutrition): Inflammatory Bowel Disease in the paediatric age. Eds Area Pediatrica Publ Milan Italy 2008, pp 23-26.
- [4] Venkatesh K, Thomson M. Endoscopic Modalities in Pediatric Inflammatory Bowel Disease. In: Pediatric Inflammatory Bowel Diseases. Mamula P, Markowitz JE, Baldassano RN eds Springer Publ New York 2008, pp 211-35.
- [5] Venkatesh K, Thomson M. Endoscopic Modalities in Pediatric Inflammatory Bowel Disease. In: Pediatric Inflammatory Bowel Diseases. Perspectives and Consequences. Walker-Smith JA, Lebenthal E, Branski D eds Karger Publ Basel Switzerland 2009, pp 100-122.
- [6] Guariso G, Gasparetto M, Visonà Dalla Pozza L, D'Incà R, Zancan L, Sturniolo G, Brotto F, Facchin P. Inflammatory bowel disease developing in paediatric and adult age. *J Pediatr Gastroenterol Nutr.* 2010 Dec;51(6):698-707.
- [7] Boyle JT. Esophagogastroduodenoscopy in the pediatric patient. In: Gastroenterologic Endoscopy. Sivak MV eds Saunders Company Publ, Philadelphia, London, Toronto, Montreal, Sydney, Tokyo, 2000, pp 783-98.
- [8] Mougnot JF, Bontems P, Cadranel S. Endoscopic Equipment. In: Pediatric Gastrointestinal Endoscopy. Textbook and Atlas. Winter SH, Murphy MS, Mougnot JF, Cadranel S eds BC Decker Inc Publ Hamilton Ontario 2006, pp 6-33.
- [9] Girardin M, Seidman EG. Video Capsule Endoscopy in Pediatric Inflammatory Bowel Disease. In: Pediatric Inflammatory Bowel Diseases. Mamula P, Markowitz JE, Baldassano RN eds Springer Publ New York 2008, pp 275-87.
- [10] Miele E: Pouchitis. In: SIGENP Consensus Statement (Italian Society of Gastroenterology Hepatology and Nutrition): Inflammatory Bowel Disease in the paediatric age. Eds Area Pediatrica Publ Milan Italy 2008, pp 27-30.
- [11] Stienecker K, Gleichmann D, Neumayer U, Joachim Glaser H, Tonus Long V. Term results of endoscopic balloon dilatation of lower gastrointestinal tract strictures in Crohn's disease: a prospective study. *World J Gastroenterol* 2009 June 7; 15(21): 2623-2627.
- [12] De Angelis GL, Bizzarri B, Vincenti F: Video capsule endoscopy. In: SIGENP Consensus Statement (Italian Society of Gastroenterology Hepatology and Nutrition): Inflammatory Bowel Disease in the paediatric age. Eds Area Pediatrica Publ Milan Italy 2008, pp 25-27.
- [13] Seidman SG, Dirks MH: Wireless Capsule Endoscopy in IBD: State of The Art and Image of the Future. *Journal of Pediatric Gastroenterology and Nutrition* 2006; 43, suppl. 2.
- [14] Mescoli C, Ruge M. Histology in Inflammatory Bowel Disease. In: SIGENP Consensus Statement (Italian Society of Gastroenterology Hepatology and Nutrition): Inflammatory Bowel Disease in the paediatric age. Eds Area Pediatrica Publ Milan Italy 2008, pp 37-41.
- [15] Dirks MH, Costea F, Sant'Anna, Peretti N, Seidman EG: Videocapsule Endoscopy in Pediatric Crohn's Disease: a 4 -year experience. *Journal of Pediatric Gastroenterology and Nutrition* 2006; 43, suppl. 2.
- [16] Role of the Wireless Capsule Endoscopy in Diagnosis of Undetermined Colitis and Suspect IBD in Paediatric Patients. *Journal of Pediatric Gastroenterology and Nutrition* 2006; 43, suppl. 2.



Gastrointestinal Endoscopy

Edited by Prof. Oliviu Pascu

ISBN 978-953-307-385-9

Hard cover, 272 pages

Publisher InTech

Published online 19, July, 2011

Published in print edition July, 2011

Endoscopy has had a major impact in the development of modern gastroenterology. By using different data it provided a better understanding of pathogenic mechanisms, described new entities and changed diagnostic and therapeutic strategies. Meanwhile, taking advantage of many technical advances, endoscopy has had a developed spectacularly. Video-endoscopes, magnification, confocal and narrow-band imaging endoscopes, endoscopic ultrasounds and enteroscopes emerged. Moreover, endoscopy has surpassed its function as an examination tool and it became a rapid and efficient therapeutic tool of low invasiveness. InTech Open Access Publisher selected several known names from all continents and countries with different levels of development. Multiple specific points of view, with respect to different origins of the authors were presented together with various topics regarding diagnostic or therapeutic endoscopy. This book represents a valuable tool for formation and continuous medical education in endoscopy considering the performances or technical possibilities in different parts of the world.

How to reference

In order to correctly reference this scholarly work, feel free to copy and paste the following:

Marco Gasparetto and Graziella Guariso (2011). Endoscopy in Paediatric Inflammatory Bowel Disease (IBD), Gastrointestinal Endoscopy, Prof. Oliviu Pascu (Ed.), ISBN: 978-953-307-385-9, InTech, Available from: <http://www.intechopen.com/books/gastrointestinal-endoscopy/endoscopy-in-paediatric-inflammatory-bowel-disease-ibd->

INTECH
open science | open minds

InTech Europe

University Campus STeP Ri
Slavka Krautzeka 83/A
51000 Rijeka, Croatia
Phone: +385 (51) 770 447
Fax: +385 (51) 686 166
www.intechopen.com

InTech China

Unit 405, Office Block, Hotel Equatorial Shanghai
No.65, Yan An Road (West), Shanghai, 200040, China
中国上海市延安西路65号上海国际贵都大饭店办公楼405单元
Phone: +86-21-62489820
Fax: +86-21-62489821

© 2011 The Author(s). Licensee IntechOpen. This is an open access article distributed under the terms of the [Creative Commons Attribution 3.0 License](#), which permits unrestricted use, distribution, and reproduction in any medium, provided the original work is properly cited.

IntechOpen

IntechOpen