

We are IntechOpen, the world's leading publisher of Open Access books Built by scientists, for scientists

4,800

Open access books available

122,000

International authors and editors

135M

Downloads

Our authors are among the

154

Countries delivered to

TOP 1%

most cited scientists

12.2%

Contributors from top 500 universities



WEB OF SCIENCE™

Selection of our books indexed in the Book Citation Index
in Web of Science™ Core Collection (BKCI)

Interested in publishing with us?
Contact book.department@intechopen.com

Numbers displayed above are based on latest data collected.

For more information visit www.intechopen.com



Adrenal Imaging Methods: Comparison of Mean CT Attenuation, CT Histogram Analysis and Chemical Shift Magnetic Resonance Imaging for Adrenal Mass Characterization and Review of the Literature

Ahmet Mesrur Halefoglu

*Sisli Etfal Training and Research Hospital Radiology Department, Sisli, Istanbul
Turkey*

1. Introduction

Adrenal masses are commonly incidentally discovered on abdominal computed tomography (CT), occurring in up to 5 % of patients (1). Most of these adrenal masses turn out to be adenomas. In a patient with a known history of primary extra-adrenal neoplasm especially lung carcinoma, diagnosis or exclusion of an adrenal metastasis is mandatory. Because it requires appropriate therapy of the primary tumor in metastasis cases and imaging follow-up is a suitable strategy for adenomas. The presence of intracellular lipid in adenomas has been proven to be useful for distinguishing these lesions from nonadenomas.

In the routine work-flow, a 10 Hounsfield unit (HU) attenuation value is used as a threshold for the diagnosis adrenal adenomas on unenhanced CT examinations (2). Although it is regarded as a very useful method in many adenoma cases, it in fact has limited value because approximately 29 % of these adenomas have an attenuation value of more than 10 HU due to their poor lipid content and therefore can be classified as indeterminate masses (3).

The delayed contrast-enhanced CT attenuation or washout CT method has been shown to be very sensitive for adrenal mass characterization. It makes the distinction between adenoma and metastases on the basis of physiological temporal differences in the enhancement and exit iodinated contrast from the adrenal lesion. Adrenal adenomas show a percentage enhancement washout of at least 60 % or greater or a relative percentage washout of 50 % on delayed contrast-enhanced CT (4). Although it is regarded as a very sensitive diagnostic method, also holds some disadvantages. In a busy clinical practice, monitoring every CT scan performed is not feasible. Hence a separate patient visit may be needed after an indeterminate finding on an unenhanced CT scan. The patients are also subjected to multiphasic scanning and injection of intravenous contrast material. There has also been a recently heightened concern about radiation relating to use of CT with adrenal washout CT, including 3 passes through the upper abdomen. Even though complications are infrequent, risks related to IV contrast material remain. Certainly, one can agree that a test avoiding

both radiation and intravenous contrast would have better patient acceptance. An additional work-flow related issue is the need to obtain a delayed scan at 15 minutes following contrast material administration.

The other method for diagnosis of an adenoma is percutaneous biopsy. But due to its invasive nature and inherent risk, it should be considered as a last procedure when all other noninvasive methods were inconclusive.

Mean CT attenuation method which is widely used in clinical practice results in averaging of tissue density over the CT pixels. Tissue heterogeneity therefore may result in inadequate information being obtained about densities that present a smaller volume from a region of interest (ROI) where the mean CT attenuation is measured.

Recently the use of CT histogram analysis to evaluate adrenal masses has been proposed by Bae et al (5). CT histogram analysis provides objective insight into the varying CT densities and the number of pixels with these densities and therefore is more likely to be sensitive for lipid detection, represented as pixels with negative attenuation, particularly in lipid poor adenomas, which are likely to have a mean CT attenuation of more than 10 HU. This technique has the advantage of involving no additional tests, radiation or repeat trips to the hospital by the patient if an adenoma is confirmed. Obviously, if the CT histogram analysis is indeterminate, other imaging tests such as adrenal washout CT will be necessary and will require an additional patient visit.

Magnetic resonance imaging (MRI) using in-phase and opposed-phase images, known as chemical-shift MRI, has been proposed as an effective alternative to CT for characterization of adrenal masses. (6, 7). Quantitative analysis of the signal intensity of adrenal lesions compared with that of the liver, fat, muscle and image background was subsequently shown to improve characterization of adrenal masses compared with qualitative analysis of signal intensity variations. (6, 7, 8).

The purpose of this chapter is to discuss mean attenuation method using 10 HU threshold value on unenhanced CT, CT histogram analysis method both on unenhanced and contrast enhanced CT and chemical shift MRI method using quantitative analysis with adrenal to spleen chemical shift ratio and adrenal signal intensity index formulas based on our recently published prospective research studies. We also reviewed the literature in terms of comparing our results in order to lightening this topic.

2. Materials and methods

Both of these studies were approved by our hospital's institutional research ethics board and informed consents were obtained from all patients. These studies were performed between March 2007 and November 2008. During this period, patients who exhibited adrenal masses on either CT or MRI examinations were routinely detected in the daily work-flow and then evaluated as to whether or not they were appropriate for our studies. The inclusion criterion was mass size, where a 1- cm cut-off value was used in order to eliminate possible partial volume effects. Adrenal cysts, adrenal masses that contain large amount of macroscopic fat visible to the naked eye with a high probability of myelolipomas were also excluded from the study. Adrenal masses that contained large necrotic, calcified, cystic and hemorrhagic areas were also not included.

Patients with adrenal masses showing consistency with the inclusion criterion were prospectively evaluated with the mean attenuation method using 10 HU threshold value on unenhanced CT images and CT histogram analysis method on unenhanced and contrast

enhanced CT images in the first study. CT histogram analysis method on unenhanced CT images and chemical-shift MRI using in-phase and opposed-phase gradient-echo images were compared in the second study. All of the patients who had adrenal masses were evaluated by at least two experienced abdominal radiologists.

In the first study, 94 patients (46 males, 48 females, age range : 30-79 years) with 113 adrenal masses were included. These adrenal masses ranged from 1.07 to 8.02 cm in a diameter with a mean average of 3.03 ± 1.91 cm. These masses consisted of 66 adenomas, 45 metastases and 2 pheochromocytomas. Nine patients had bilateral adenomas and 10 patients had bilateral metastases.

In the second study, 93 patients (45 males, 48 females, mean age : 56.7 ± 11.4 years , age range 22-85 years) with 109 adrenal masses were included. The mass size ranged from 1.52 cm to 13.22 cm in a diameter with a mean of 3.02 ± 1.83 cm. These masses were 67 adenomas, 42 metastases. Nine patients had bilateral adenomas and 7 patients had bilateral metastases.

In both studies, final diagnoses of these adrenal masses were based on available clinical, imaging and pathological data. The first reference standard for the diagnosis of an adenoma was established on the basis of stable mass size for at least 6 months during imaging follow-up. If the mass conformed with this criterion, we regarded it as benign. In our first study, 34 of 66 adenomas and in the second study 39 of 67 adenomas had previous imaging studies and showed no interval change during this time period, and therefore were regarded as benign masses. In the first study two patients and in the second study only one patient were subjected to a biopsy procedure which revealed lipid- poor adenomas. In the remaining 30 patients of the first group and 27 patients of the second group who did not have a previous imaging study, an adrenal washout study was performed in order to have a reference standard for the adenoma diagnosis. This required at least a 60 % absolute percentage enhancement washout on delayed contrast enhanced images. Absolute enhancement washout (AEW) was calculated as follows :

$$AEW = \frac{\text{Enhanced attenuation value} - \text{Unenhanced attenuation value}}{\text{Enhanced attenuation value} - \text{Delayed enhanced value}}$$

In the 45 and 42 metastases in our research studies respectively, the following reference standards were used : pathological data obtained either by biopsy or during operation, rapid growth of a mass or identification of a new mass in less than 6 months in a patient with a known primary malignant tumor, or regression in the size of the mass subsequent chemotherapy. In the 45 metastases ; the diagnoses were based on biopsy in 5 patients, operation results in 2 patients, reduction of mass size following chemotherapy in 2 patients, increase of mass size during follow up in 31 patients and identification of a new mass in 5 patients. In the second group consisting of 42 metastases, the reference standards were biopsy in 5 patients, reduction of mass size following chemotherapy in 2 patients, increase of mass size during follow up in 32 patients and identification of a new mass in 3 patients.

In the first group the primary malignant tumors were lung carcinoma in 26 patients, cervix carcinoma in 1 patient, testis carcinoma in 4 patients, gastric carcinoma in 2 patients, colon carcinoma in 3 patients, breast carcinoma in 1 patient, Hodgkin lymphoma in 1 patient, neuroendocrine tumor in 1 patient, larynx carcinoma in 1 patient, renal cell carcinoma in 1

patient, bladder carcinoma in 1 patient, and malignant melanoma in 3 patients. In the second group, lung carcinoma in 23 patients, unknown primary tumor in 4 patients, malignant melanoma in 2 patients, gastric carcinoma in 2 patients, colon carcinoma in 2 patients, testicular carcinoma in 2 patients, breast carcinoma in 1 patient, Hodgkin lymphoma in 1 patient, neuroendocrine tumor in 1 patient, larynx carcinoma in 1 patient, renal cell carcinoma in 1 patient, cervix carcinoma in 1 patient and metastatic sarcoma in 1 patient.

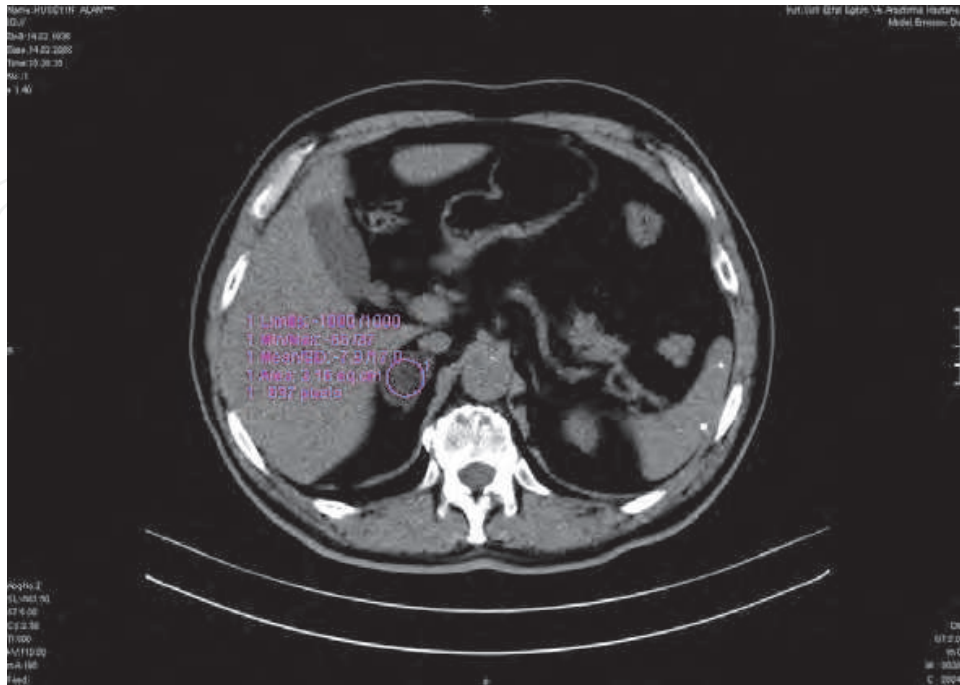
In the two pheochromocytoma cases included in the first study, the reference standards were the clinical, laboratory and MRI findings. These patients had hypertension attacks, showed elevated urine normetanephrine and vanillylmandelic acid levels and exhibited characteristic MRI findings for these tumors.

3. CT technique

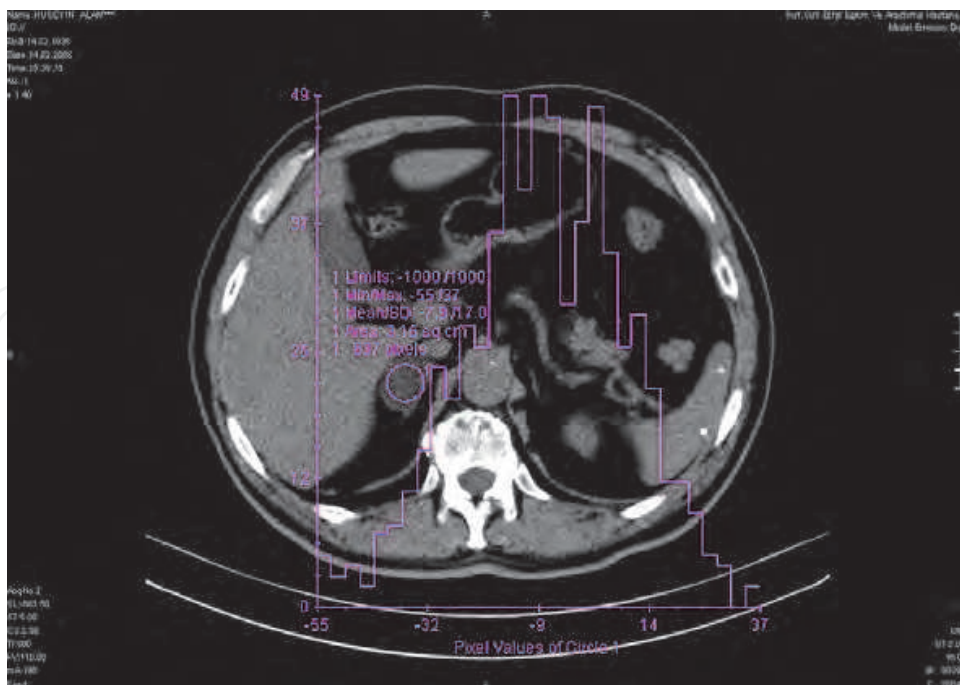
All CT examinations were performed either by using a dual-detector row helical CT scanner (Somatom Emotion Duo / Emotion 6, Siemens Medical Systems, Erlangen, Germany) or a multi-detector row helical CT scanner (Somatom Sensation 16, Siemens Medical Systems, Erlangen, Germany). We performed both unenhanced and contrast-enhanced CT examinations for all of the patients with the following imaging parameters : 10 mm collimation and 5 mm reconstructed section thickness for dual-detector row CT scanner and 5 mm collimation and 5 mm section thickness for multi-detector row CT scanner, no overlap reconstruction and 130 kVp for each scanner, 1 : 1 pitch for both dual-detector row scanner and multi-detector row scanner, 180 mA for dual-detector row scanner and 135-160 mA for multi-detector row scanner. The images were reconstructed with a standard soft-tissue-kernel algorithm. Contrast-enhanced CT images were obtained following 150 mL of contrast material (Ultravist 370, Schering, Germany) administration by using a power injector at a rate of 2-4 mL / sec. Adrenal washout CT protocol included unenhanced CT and following the two-phase contrast-enhanced CT in which images were obtained at 60 seconds (early contrast-enhanced) and 15 minutes (delayed contrast-enhanced) following bolus contrast material injection.

4. CT histogram analysis

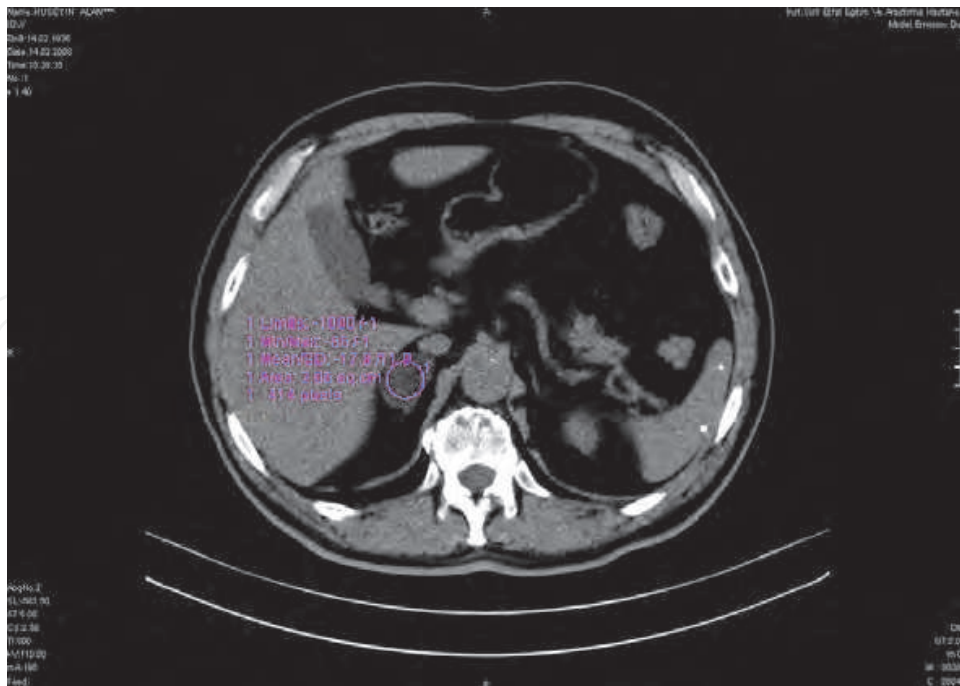
CT histogram measurements were performed on a postprocessing Workstation (Magic View 1000, Siemens Medical Solutions). A commercially available software (CT Perfusion, Siemens Medical Systems) was used to obtain the histograms. For each adrenal mass, the image showing the maximal cross-sectional area was chosen. The long-axis and short-axis diameters of the mass were measured on that image. A circular ROI was placed on the adrenal mass to include as much as the mass possible but avoiding the outermost portion of edges to prevent partial volume effects. If possible, approximately two thirds of the mass was measured. The mean attenuation over the ROI was recorded. A CT histogram was obtained from the ROI using software application on the workstation. A graph of the number of pixels on the y-axis versus the pixel attenuation on the x-axis was obtained from the ROI (Figure 1). Histogram analysis included recording the total number of pixels, number of negative pixels (pixels with attenuation less than 0 HU), and the resultant percentage of negative pixels in each ROI.



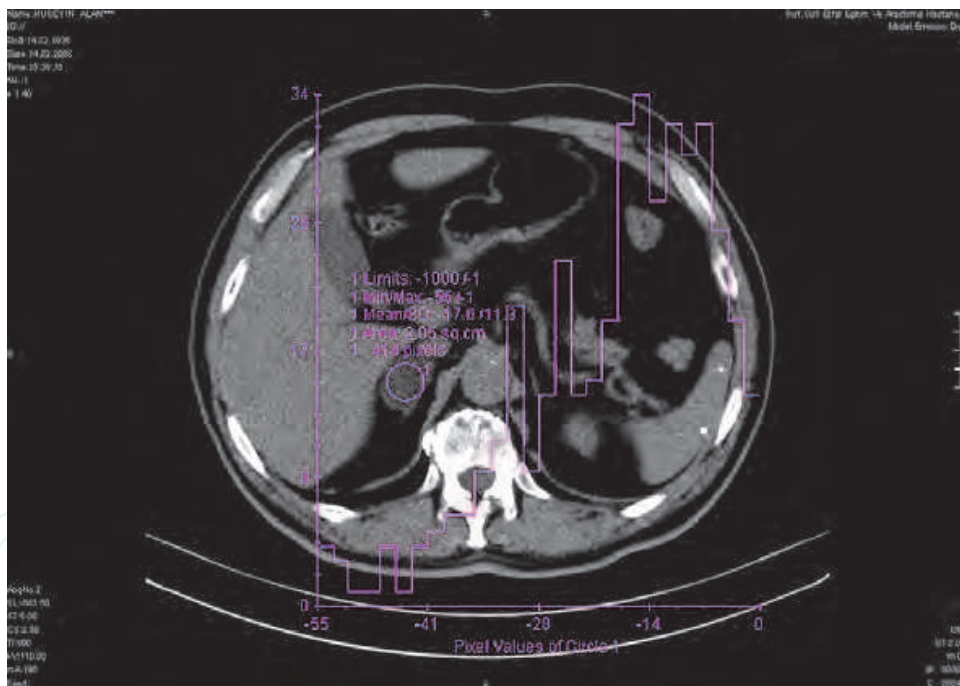
(a)



(b)



(c)



(d)

- (a) Unenhanced CT scan using ROI demonstrates 637 pixels with a mean attenuation of -7.9 HU. The upper and lower limits of pixel attenuation are $+1000$ and -1000 , respectively.
- (b) Corresponding histogram analysis shows pixel attenuation ranging from -55 to 37 HU.
- (c) Unenhanced CT scan using ROI shows that the mass containing 414 negative pixels. The upper and lower limits of pixel attenuation are -1 and -1000 , respectively.
- (d) Corresponding histogram analysis reveals that 65 % of the mass contains negative pixels.

Fig. 1. 72 year-old man with a right adrenal adenoma

5. Data analysis

The percentage of negative pixels were calculated from the total number of pixels and the number of negative pixels in each ROI. The percentage of adrenal masses showing a mean attenuation value of 10 HU or less were calculated for unenhanced and contrast-enhanced CT images of adenomas, metastases and pheochromocytomas. Also percentage of adrenal masses that show a mean attenuation value of more than 10 HU were calculated for unenhanced and enhanced CT images of all adrenal masses. We also investigated the percentage of each type of adrenal mass in terms of containing any negative pixel and at the threshold values of 5 % and 10 % negative pixel on both unenhanced and contrast-enhanced CT images. All the reviews and calculations were performed by at least two experienced abdominal radiologists and final results were achieved by a consensus for each evaluation.

6. MR technique

MR examination was performed by means of a 1.5 tesla superconducting magnet (Signa, GE Medical Systems, Milwaukee, Wisconsin, USA). In all cases, a torso multi-channel phased-array coil was used. All patients underwent axial breath-hold dual-echo T1-weighted 2D spoiled gradient-echo in- and opposed-phase imaging using the following parameters ; TR : 175 msec., TE : 4.4 (in-phase) / 2.2 (opposed-phase) msec., 80° flip angle, 256 x 160 matrix, 48 cm field of view, 0.60 phase FOV, 0.75 Nex, 6 mm slice thickness, 1.5 mm interslice gap, and 62.5 kHz bandwidth.

7. MR evaluation

Two experienced abdominal radiologists performed the quantitative MR measurements by reaching a consensus. An ellipsoid ROI was placed on the center of the adrenal mass and spleen on both in-phase and opposed-phase MR images to obtain signal intensity values. ROIs were placed on each adrenal mass covering as much as the mass possible while avoiding to contain the outermost portions in order to eliminate chemical shift artifact. We calculated the adrenal-to-spleen chemical shift ratio and adrenal signal intensity index for each adrenal mass. The adrenal-to-spleen chemical shift ratio was calculated as the adrenal mass-to-spleen signal intensity ratio on the opposed-phase images divided by the adrenal mass-to-spleen signal intensity ratio on the in-phase images. The signal intensity index was calculated as the adrenal mass signal intensity on the in-phase images minus the adrenal mass signal intensity on the opposed-phase images divided by the adrenal mass signal intensity on the in-phase images multiplied by 100.

8. Results for first research

Adrenal adenomas at unenhanced CT

The mean attenuation of 66 adenomas at unenhanced CT ranged from - 83.1 to 48.8 HU (mean : 0.5 HU \pm 18.1). Of the 66 adenomas, 51 (77.3 %) had a mean attenuation value of \leq 10 HU and 15 (22.7 %) showed a mean attenuation value of more than 10 HU. All of these adenomas contained negative pixels on unenhanced CT. Overall, the percentage of negative pixels for adenomas on unenhanced CT ranged from 0-96 %, with a mean value of 50.4 \pm

30.2. The number of adenomas when we used a negative pixel percentage threshold of 10 % was 60 (90.9 %) (Figure 1). There was no adenoma containing negative pixel between % 5 and 10 %. We found only 6 adenomas containing less than 5 % negative pixel among which two cases were diagnosed as lipid poor adenomas following biopsy, two cases showed no interval change in size during follow-up and the remaining two cases demonstrated more than 60 % absolute percentage enhancement washout. An increase in the percentage of negative pixels was correlated with a decrease in mean attenuation ($p < 0.001$). We obtained a 90.9 % sensitivity for 10 % negative pixel percentage threshold compared to 77.2 % sensitivity for ≤ 10 HU mean attenuation threshold value for unenhanced CT. Both methods resulted in a 100 % specificity for the diagnosis of adenoma (Figure 2).

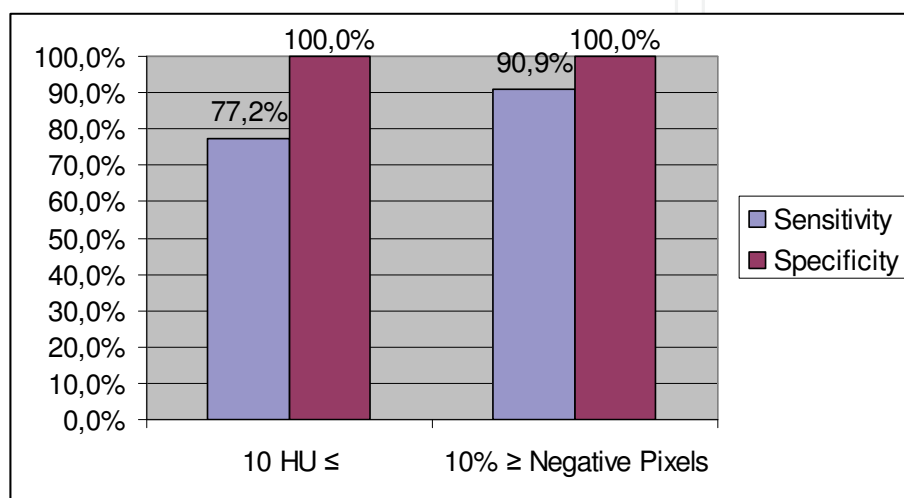
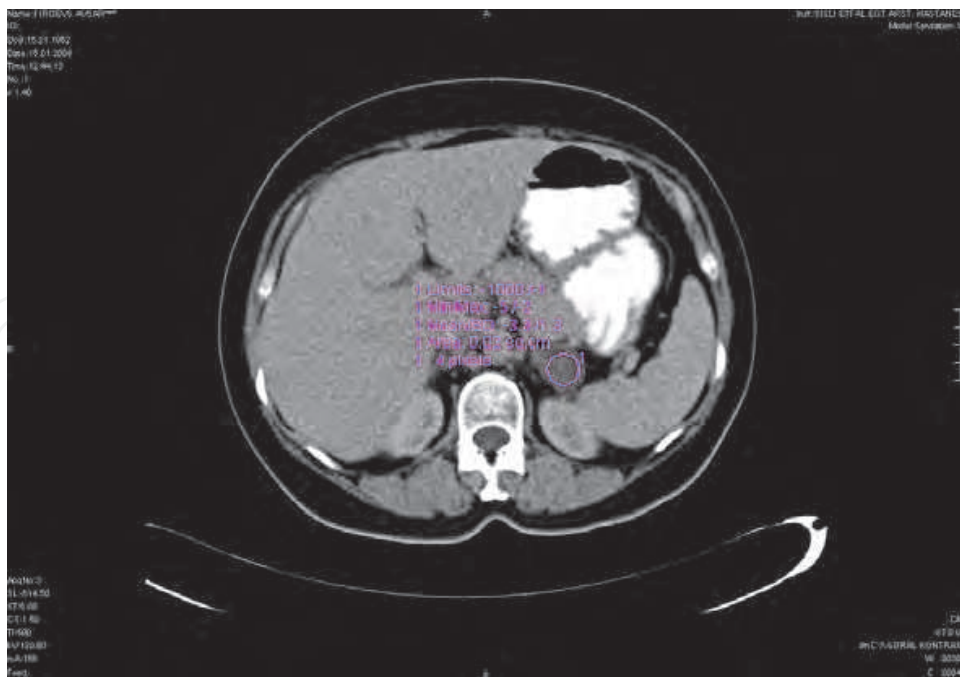


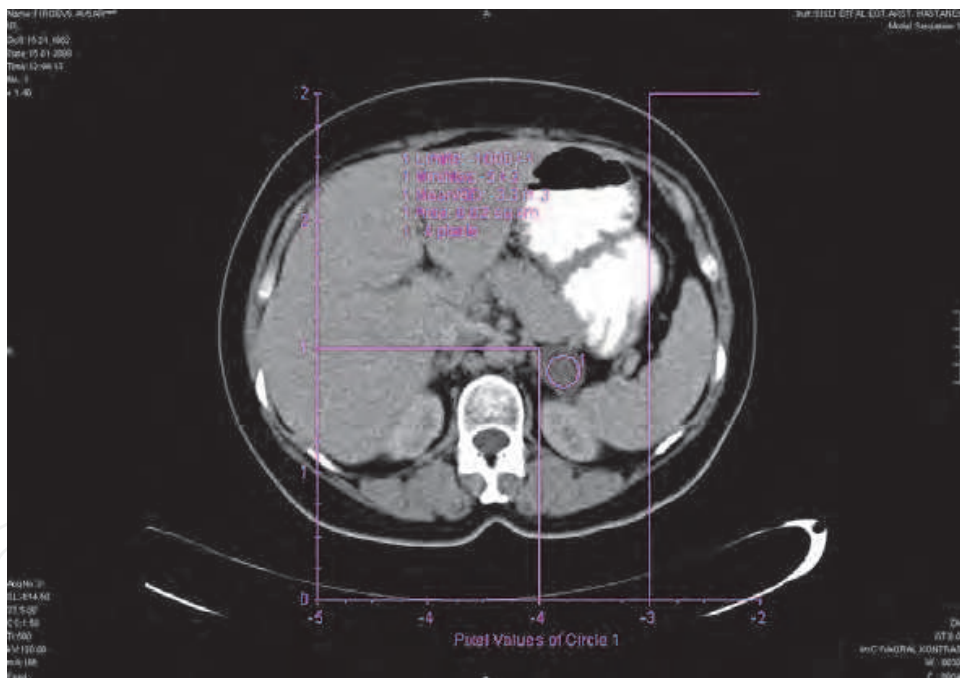
Fig. 2. Bar chart comparing sensitivity values of CT histogram analysis method to mean attenuation method at a threshold of 10 % negative pixel on unenhanced CT.

Adrenal adenomas at contrast-enhanced CT

The mean attenuation of 66 adenomas at contrast-enhanced CT ranged from 0.5 to 97.3 HU (mean : $32.5 \text{ HU} \pm 19.8$). Of the 66 adenomas at contrast-enhanced CT, 58 (87.9 %) showed a mean attenuation value of more than 10 HU and only 8 (12.1 %) had a mean attenuation value of ≤ 10 HU. The lowest percentage of negative pixels regarding these adenomas with a mean attenuation value of ≤ 10 HU, was 25 % (mean attenuation of this mass was 8.7 HU). 45 in 66 adenomas (68.2 %) which demonstrated negative pixels at contrast-enhanced CT (Figure 3). All of the 8 adenomas with a mean attenuation value of ≤ 10 HU contained negative pixels and the percentage range of negative pixels was between 25-47 % (mean : 34.4 ± 6.6 HU). 37 of the 58 adenomas (63.8 %) with a mean attenuation value of more than 10 HU had negative pixels and the percentage range of negative pixels was between 1-35 % (mean : 8.0 ± 9.2 HU). The overall percentage range of negative pixels for adenomas at contrast-enhanced CT was 0-47 % with a mean value of 12.7 ± 13.4 . The highest mean attenuation value of an adenoma containing negative pixels (0.14 %) was found to be as 62.2 HU at contrast-enhanced CT. only found 6 adenomas (9.1 %) containing between 5-10 % negative pixel on contrast-enhanced CT. 20 adenomas (30.3 %) had negative pixels less than 5 %. But when we used a more than 10 % negative pixel threshold 19 adenomas (28.8 %) were detected. Increase in the percentage of negative pixels was again correlated well with a decrease in mean attenuation ($p < 0.001$). We obtained a 37.9 % sensitivity for 5



(c)



(d)

(a) Contrast- enhanced CT scan using ROI demonstrates 481 pixels with a mean attenuation of 25.3 HU. The upper and lower limits of pixel attenuation are + 1000 and - 1000, respectively.

(b) Corresponding histogram analysis shows pixel attenuation ranging from - 5 to 56 HU.

(c) Contrast- enhanced CT scan using ROI shows that the mass containing 4 negative pixels. The upper and lower limits of pixel attenuation are - 1 and - 1000, respectively.

(d) Corresponding histogram analysis reveals approximately 1 % of the mass contains negative pixels on contrast- enhanced CT.

Fig. 3. 46 year-old woman with a left adrenal adenoma.

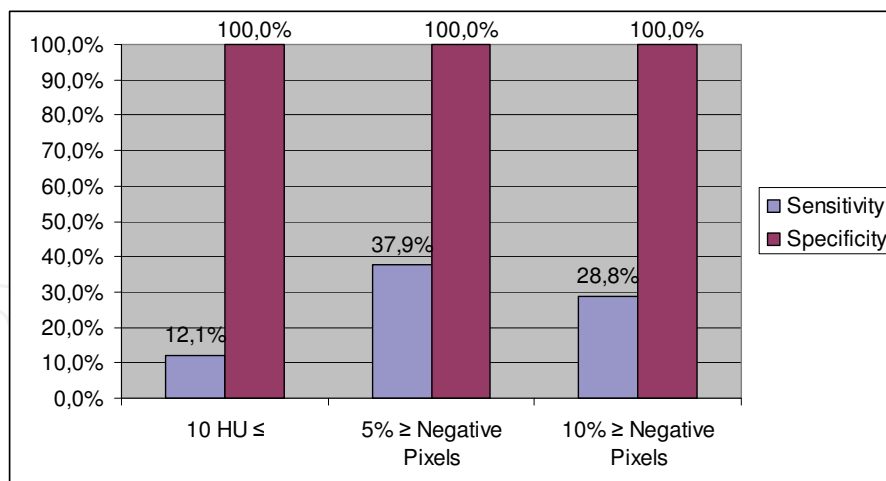


Fig. 4. Bar chart comparing sensitivity values of CT histogram analysis method to mean attenuation method at thresholds of 5 % and 10 % negative pixels on contrast-enhanced CT.

% negative pixel threshold and 28.8 % sensitivity for 10 % negative pixel threshold compared to 12.1 % sensitivity for ≤ 10 HU mean attenuation threshold value for contrast-enhanced CT. Both methods yielded a 100 % specificity for the diagnosis of adenoma (Figure 4). If we use a mean attenuation threshold value of ≤ 30 HU, our sensitivity increases to 51.5 % while 100 % specificity is being maintained. But with a more increase of mean attenuation threshold value of ≤ 40 HU, although a 75.7 % sensitivity is achieved, our specificity decreases to 90 %.

Adrenal adenomas at unenhanced and contrast-enhanced CT

All of the 66 adrenal adenomas demonstrated an increase in mean attenuation values (mean increase : 26.6 ± 20.3) and a decrease in the percentage of negative pixels (mean decrease : 24.5 ± 22.4) following contrast media administration. Although 51 of 66 (77.3 %) adenomas had a mean attenuation of ≤ 10 HU on unenhanced CT images, only 8 of the adenomas (12.1 %) demonstrated a mean attenuation value of ≤ 10 HU on contrast-enhanced images. While all 66 of the adenomas (100 %) had negative pixels on unenhanced CT images, only 45 adenomas (68.2 %) persisted to show negative pixels on contrast-enhanced CT images (Table 1).

Adrenal metastases at unenhanced CT

The mean attenuation of 45 metastases on unenhanced CT ranged from 23.2 to 44.5 HU (mean : $33.8 \text{ HU} \pm 5.3$). None of the adrenal metastases had a mean attenuation value of ≤ 10 HU on unenhanced CT images (Figure 5). Of the 45 metastases 21 (46.6 %) contained negative pixels. The mean percentage of negative pixels was found to be 0-3 % on unenhanced CT images (Table 2).

Adrenal metastases at contrast-enhanced CT

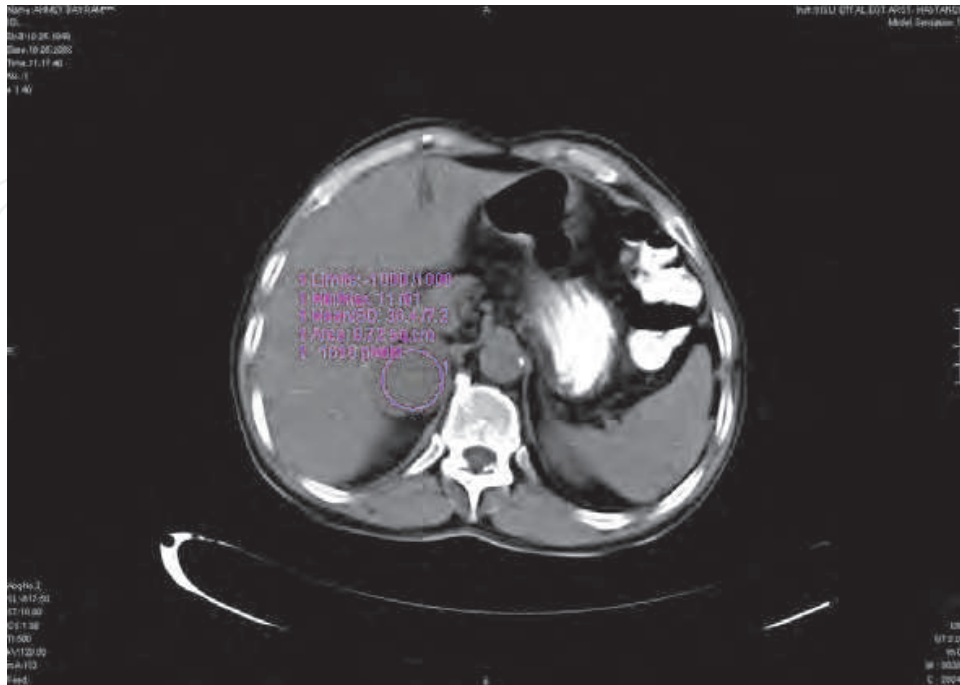
The mean attenuation of 45 metastases on contrast-enhanced CT ranged from 31.5 to 83.2 HU (mean : $53.3 \text{ HU} \pm 12.9$). None of the adrenal metastases had a mean attenuation value of ≤ 10 HU on contrast-enhanced CT images (Figure 5). Of the 45 metastases only 7 (15.5 %) contained negative pixels. The percentage of negative pixels was 0-1 % for these metastases (Table 2).

Histogram Analysis	Adrenal Adenomas	
	Unenhanced CT (66 adenomas)	Enhanced CT (66 adenomas)
Atenuation (HU)		
Average \pm SD	0,5 \pm 18,1	32,5 \pm 19,8
Range	-83,1 to 48,8	0,5 to 97,3
Negative Pixels %		
Average \pm SD	50,4 \pm 30,2	12,7 \pm 13,4
Range	0 - 96	0 - 47
Number of Cases with Negative Pixels	66 (100%)	45 (68,1%)
Negative Pixels more than 5%	60 (90,9%)	25 (37,8%)
Negative Pixels more than 10%	60 (90,9%)	19 (28,7%)
Average Atenuation \leq 10 HU	51 (77,2%)	8 (12,1%)
Negative Pixels more than 5%	51	8
Negative Pixels more than 10%	51	8
Average Atenuation 10-20 HU	7 (10,6%)	10(15,1%)
Negative Pixels more than 5%	7	8
Negative Pixels more than 10%	7	8
Average Atenuation \geq 20 HU	8 (12,1%)	48 (72,7%)
Negative Pixels more than 5%	2	9
Negative Pixels more than 10%	2	4

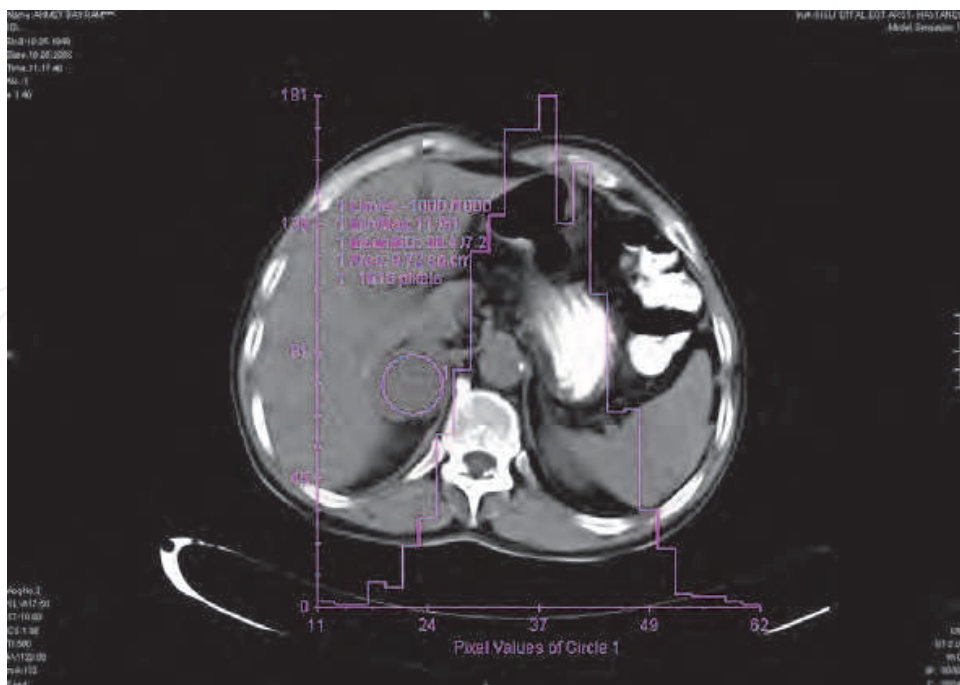
Table 1. Histogram analysis results for adrenal adenomas with unenhanced and enhanced CT.

Histogram Analysis	Adrenal Metastases	
	Unenhanced CT (45 metastases)	Enhanced CT (45 metastases)
Atenuation (HU)		
Average \pm SD	33,8 \pm 5,3	53,3 \pm 12,9
Range	23,2 - 44,5	31,5 - 83,2
Negative Pixel %		
Average \pm SD	0,4 \pm 0,8	0
Range	0 - 3	0
Number of Cases with Negative Pixels	21(46,6%)	7 (15,5%)
Negative Pixels more than 5%	0	0
Negative Pixels more than 10%	0	0
Average Atenuation \leq 10 HU	0	0
Number of Cases with Negative Pixels	0	0

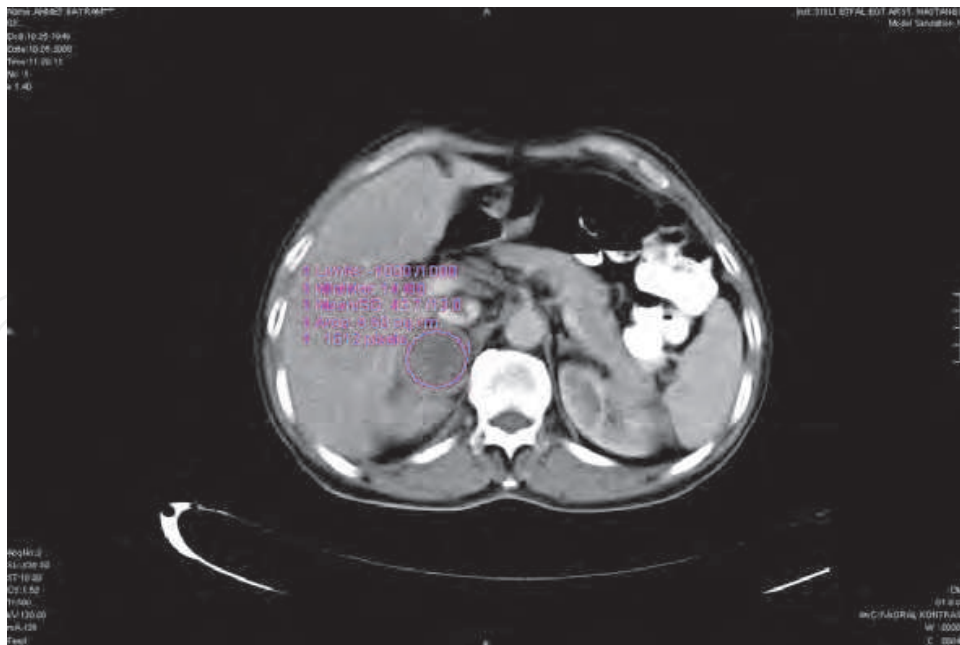
Table 2. Histogram analysis results for metastases with unenhanced and enhanced CT.



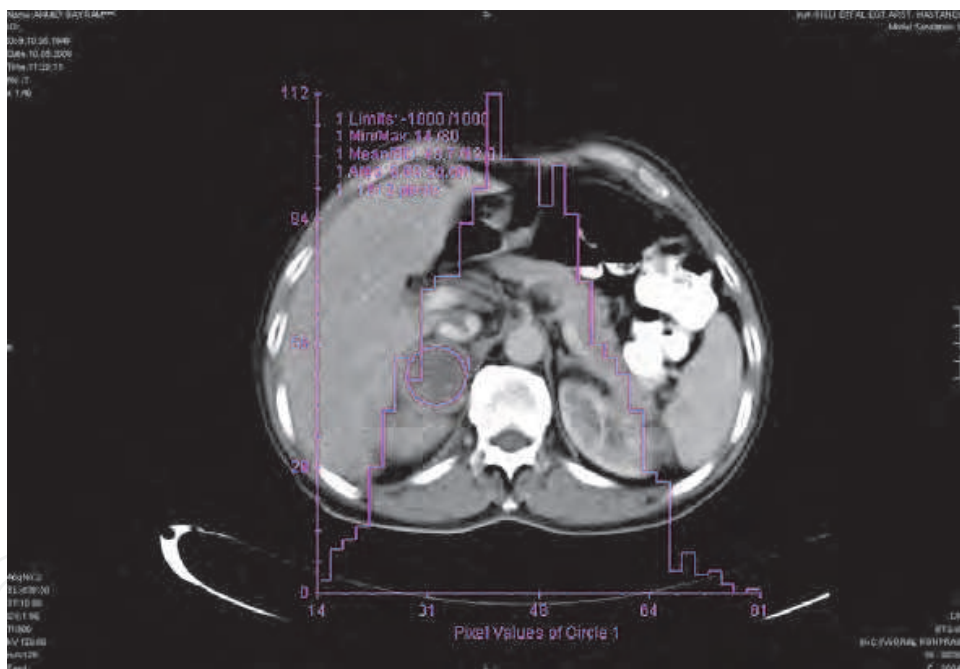
(a)



(b)



(c)



(d)

(a) Unenhanced CT scan using ROI demonstrates 1616 pixels with a mean attenuation of 36.4 HU. The upper and lower limits of pixel attenuation are + 1000 and - 1000, respectively.

(b) Corresponding histogram analysis shows pixel attenuation ranging from 11 to 61 HU without any negative pixels.

(c) Contrast- enhanced CT scan using ROI demonstrates 1612 pixels with a mean attenuation increases to 43.7 HU. The upper and lower limits of pixel attenuation are + 1000 and - 1000, respectively.

(d) Corresponding histogram analysis shows pixel attenuation range increases to 14 - 80 HU.

Fig. 5. 59 year-old man with a right adrenal metastasis who had a history of primary lung carcinoma.

Pheochromocytomas at unenhanced CT

The mean attenuation of 2 pheochromocytomas on unenhanced CT ranged from 38.1 to 39.3 HU (mean : 38.7 HU \pm 0.6). None of the pheochromocytomas had a mean attenuation value of \leq 10 HU on unenhanced CT images. Both of these pheochromocytomas had negative pixels.

Pheochromocytomas at contrast-enhanced CT

The mean attenuation of 2 pheochromocytomas on contrast-enhanced CT ranged from 38.6 to 55.9 HU (mean : 47.3 HU \pm 8.7). None of the pheochromocytomas had a mean attenuation value of \leq 10 HU on contrast-enhanced CT images. Both of these pheochromocytomas persisted to contain negative pixels on contrast-enhanced CT images (Figure 6).

Thus a mean attenuation threshold value of \leq 10 HU and 5 % and 10 % negative pixel threshold values obtained with CT histogram analysis method yielded a 100 % specificity for the diagnosis of adrenal adenoma on both unenhanced and contrast-enhanced CT images. Our sensitivity values of unenhanced CT were found to be 77.2 % for \leq 10 HU mean attenuation threshold value and 90.9 % for 10 % negative pixel threshold value. But at contrast-enhanced CT, our sensitivities decreased to 12.1 % for \leq 10 HU mean attenuation value with 37.9 % for 5 % negative pixel and 28.8 % for 10 % negative pixel threshold values, respectively.

9. Results for second research

The mean CT attenuation of 67 adenomas at unenhanced CT ranged from - 83.1 to 40.8 HU (mean : - 0.2 HU \pm 17.5). Of the 67 adenomas, 53 (79.1 %) had a mean attenuation value of \leq 10 HU and 14 (20.9 %) showed a mean attenuation value of more than 10 HU. The mean attenuation of 42 metastases on unenhanced CT ranged from 20.7 to 44.5 HU (mean : 34.3 HU \pm 5.1). None of the adrenal metastases had a mean attenuation value of \leq 10 HU on unenhanced CT images. All of the adenomas contained negative pixels on unenhanced CT. Overall, the percentage of negative pixels for adenomas on unenhanced CT ranged from 0-96 %, with a mean value of 51.2 \pm 29.9. Of the 42 metastases, 21(50 %) contained negative pixels on unenhanced CT. The percentage of negative pixels for metastases was found to be between 0-3 %, with a mean value of 0.5 \pm 0.8 on unenhanced CT images (Table 3). When we used a more than 10 % negative pixel threshold, 61 out of 67 adenomas could be detected (Figure 7). However, none of the metastases demonstrated negative pixels reaching out to that level (Figure 8). 6 out of 67 adenomas demonstrated less than 10 % negative pixel with CT histogram analysis method resulting in indeterminate masses. Therefore CT histogram analysis method using a 10 % negative pixel threshold on unenhanced CT yielded a 91 % sensitivity and a 100 % specificity for the diagnosis of adenoma (Figure 9).

An increase in the percentage of negative pixels was correlated well with a decrease in mean attenuation ($p < 0.001$).

65 out of 67 adenomas demonstrated an adrenal-to-spleen chemical shift ratio of less than 0.71 and a signal intensity index of greater than 16.5 % (Figure 10). However, two adenomas in this group showed an adrenal-to-spleen chemical shift ratio of more than 0.71 and also had a signal intensity index of less than 16.5 %. Both of these adenomas were also classified in the indeterminate group containing less than 10 % negative pixel with CT histogram analysis method. One of these adenomas was diagnosed with imaging follow-up which

revealed no interval change in size during more than two years and the other one was subjected to a biopsy procedure and diagnosed as lipid-poor adenoma. On the other hand, although two adenomas could not be determined with both CT histogram analysis and chemical shift MRI methods, the 4 adenomas which were classified as indeterminate by CT histogram analysis method, MRI was able to characterize these masses. These 4 adenomas, in spite of containing less than 10 % negative pixel with CT histogram analysis method, exhibited a less than 0.71 chemical shift ratio and demonstrated a more than 16.5 % signal intensity index by MRI (Table 4). Hence, we characterized these masses as adenomas by chemical shift MRI. For these 4 adenomas, we used adrenal washout study (n = 2) and imaging follow-up (n = 2) as reference standards.

Histogram Analysis	Unenhanced CT	
	67 adrenal adenomas	42 adrenal metastases
Attenuation (HU)		
Average \pm SD	-0,2 \pm 17,5	34,3 \pm 5,1
Range	-83,1 to 40,8	20,7 to 44,5
Negative Pixels %		
Average \pm SD	51,2 \pm 29,9	0,5 \pm 0,8
Range	0 - 96	0 - 3
Number of Cases with Negative Pixels	67 (100%)	21(50%)
Negative Pixels more than 5%	61 (91%)	0
Negative Pixels more than 10%	61 (91%)	0

Table 3. a. Histogram analysis on unenhanced CT results for adrenal adenomas and metastases.

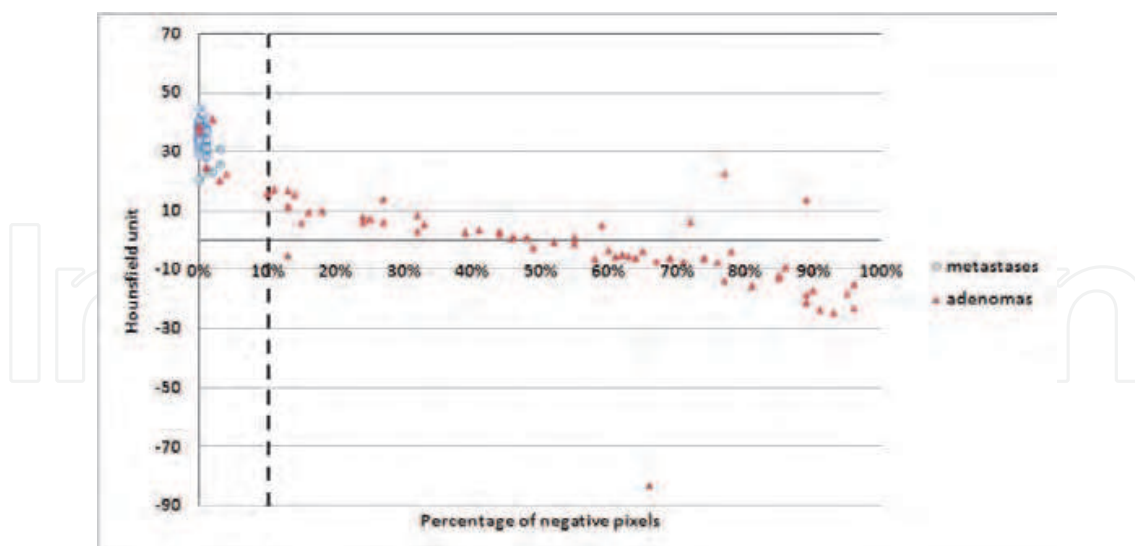
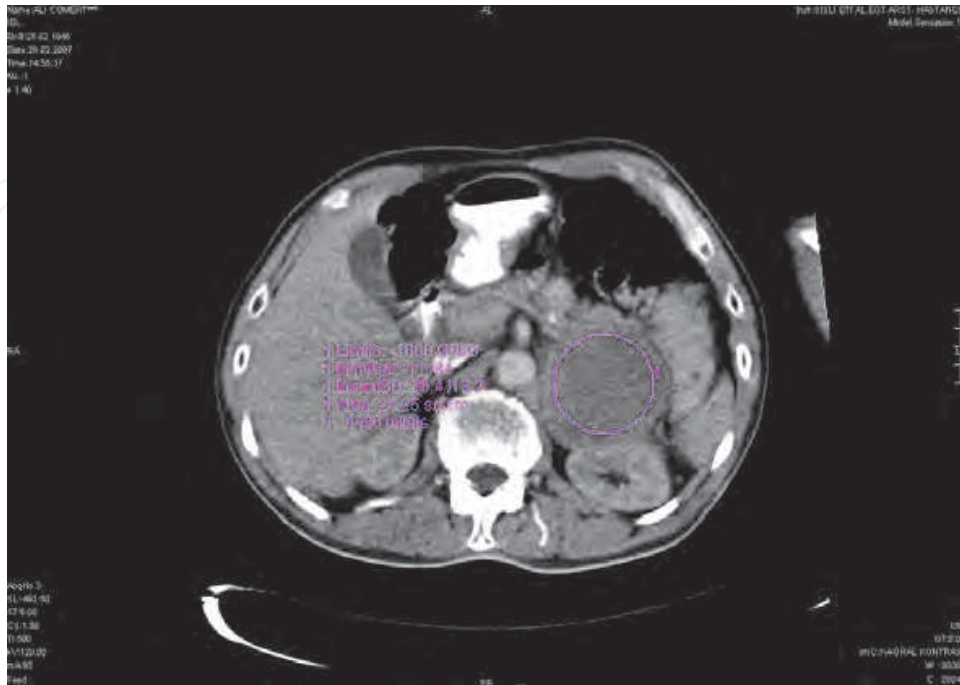
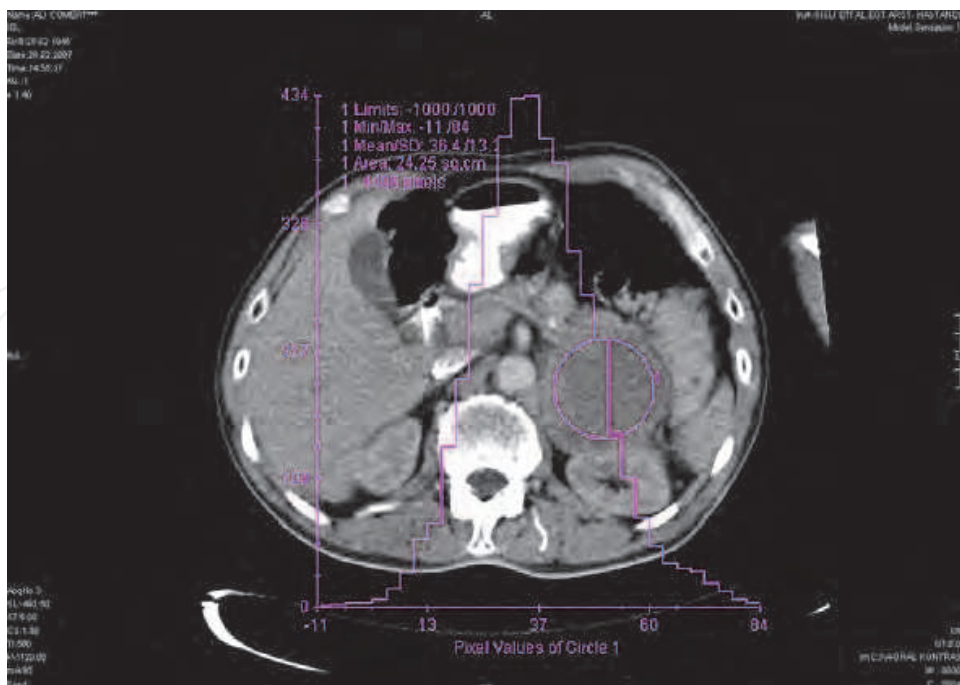


Table 3. b. Scatterplot illustrates correlation between mean CT attenuation and negative pixel percentage of adenomas and metastases. Note that all of the metastases demonstrate less than 10 % negative pixels on this graph.

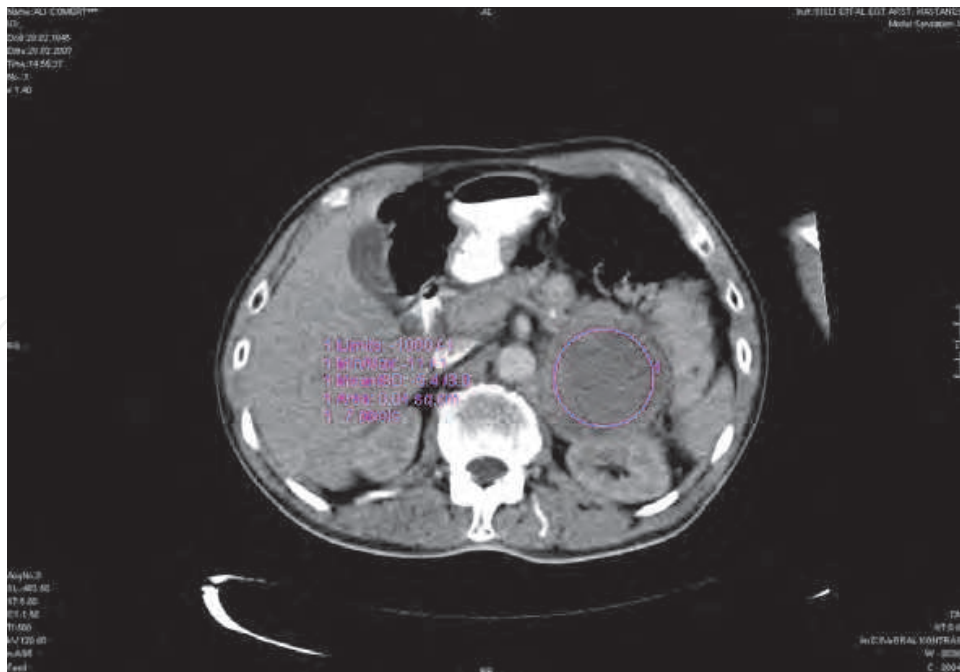
42 out of 42 metastases showed an adrenal-to-spleen chemical shift ratio of more than 0.71 and 39 out of 42 of them demonstrated an adrenal-to-spleen signal intensity index of less



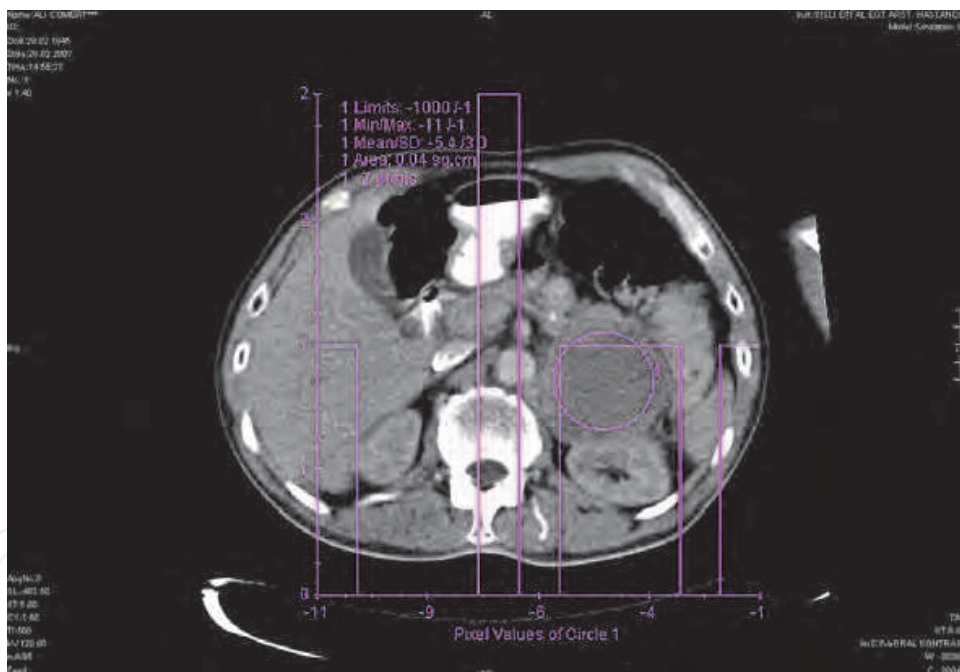
(a)



(b)



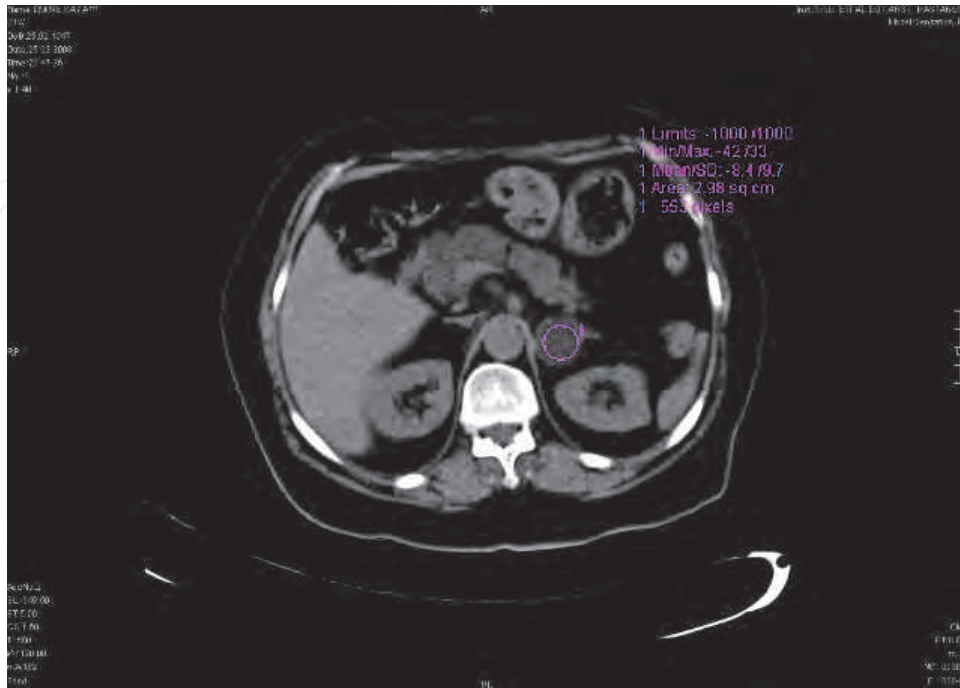
(c)



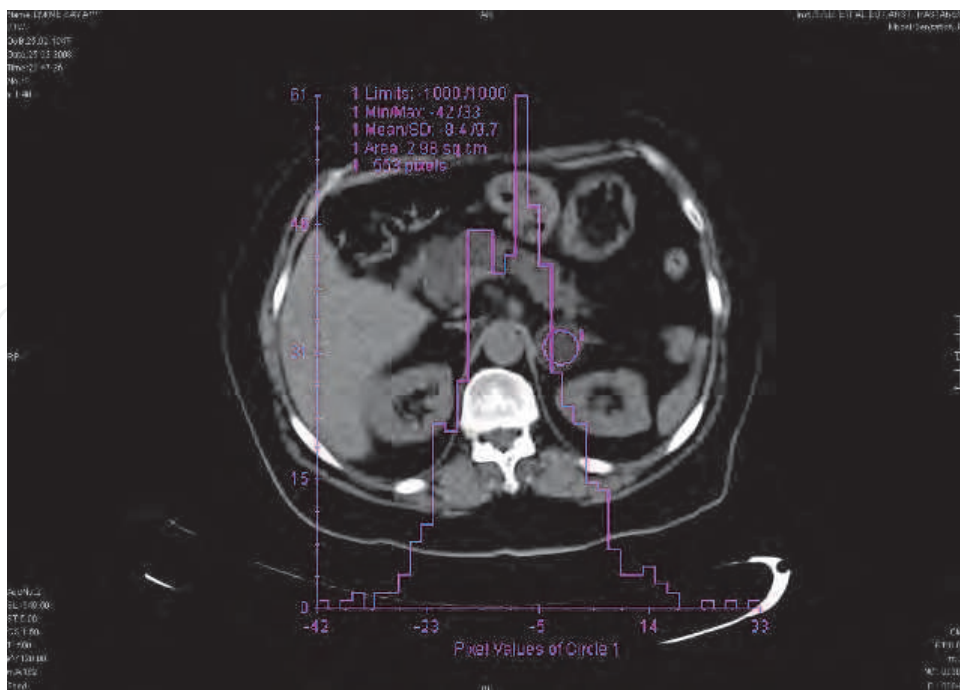
(d)

- (a) Contrast- enhanced CT scan using ROI demonstrates 4496 pixels with a mean attenuation of 36.4 HU. The upper and lower limits of pixel attenuation are + 1000 and - 1000, respectively.
- (b) Corresponding histogram analysis shows pixel attenuation ranging from - 11 to 84 HU.
- (c) Contrast- enhanced CT scan using ROI shows that the mass containing 7 negative pixels. The upper and lower limits of pixel attenuation are - 1 and - 1000, respectively.
- (d) Corresponding histogram analysis reveals approximately 0.15 % of the mass contains negative pixels on contrast- enhanced CT.

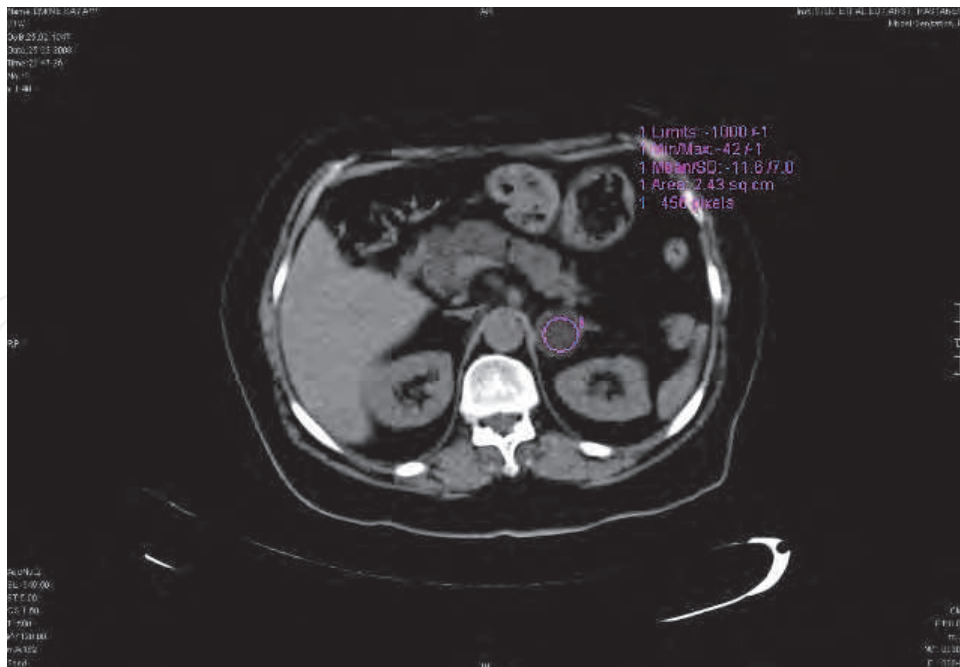
Fig. 6. 63 year-old man with a left adrenal pheochromocytoma



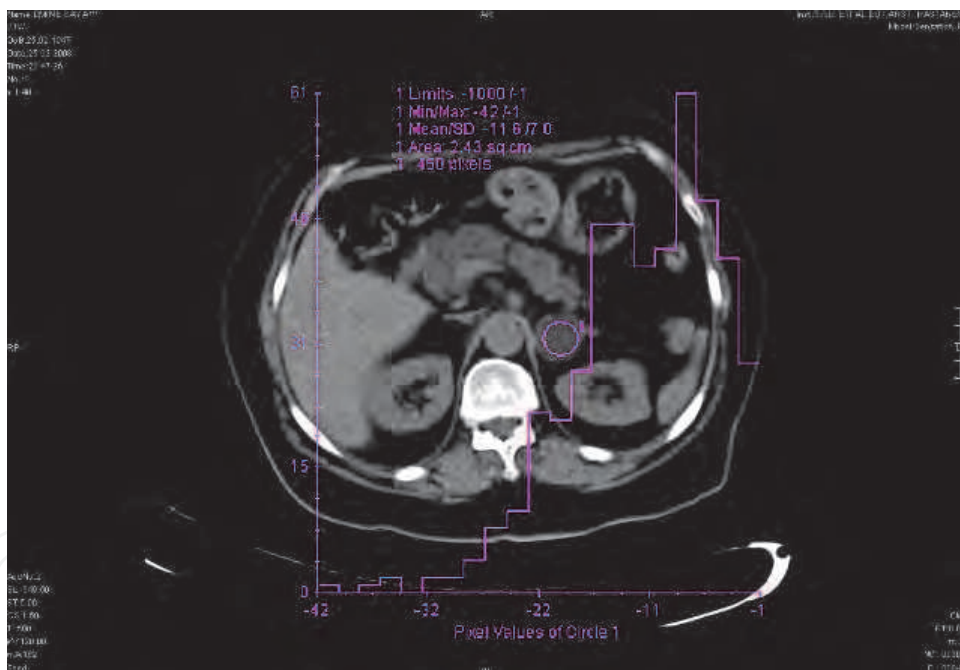
(a)



(b)



(c)



(d)

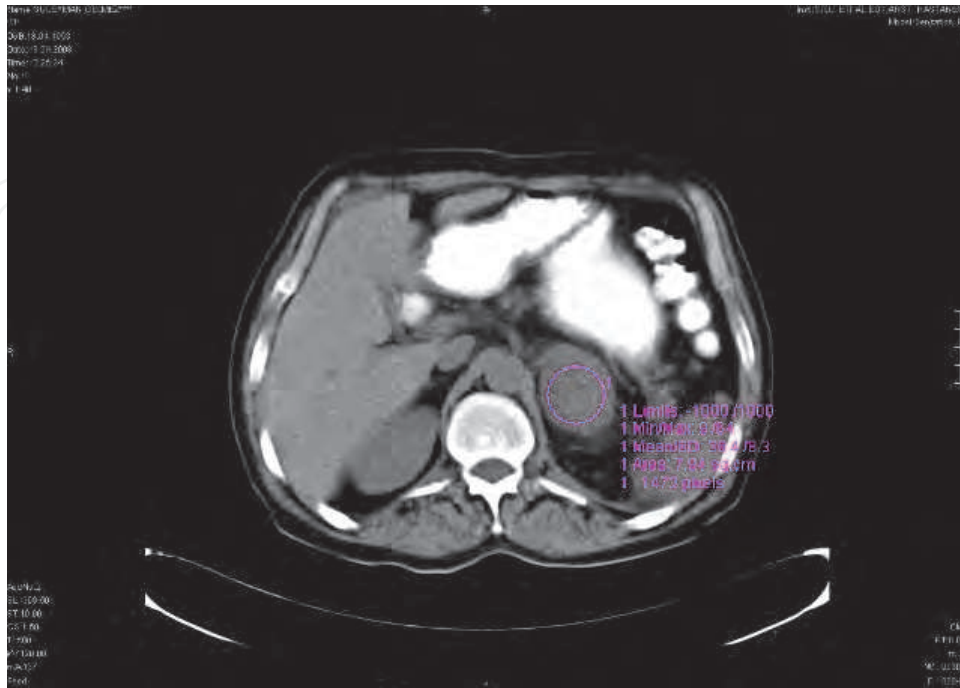
(a) Unenhanced CT scan applying ROI reveals 553 pixels and demonstrates a mean attenuation of -8.4 HU. The upper and lower limits of pixel attenuation are $+1000$ and -1000 , respectively.

(b) Corresponding histogram analysis shows pixel attenuation ranging from -42 to 33 HU.

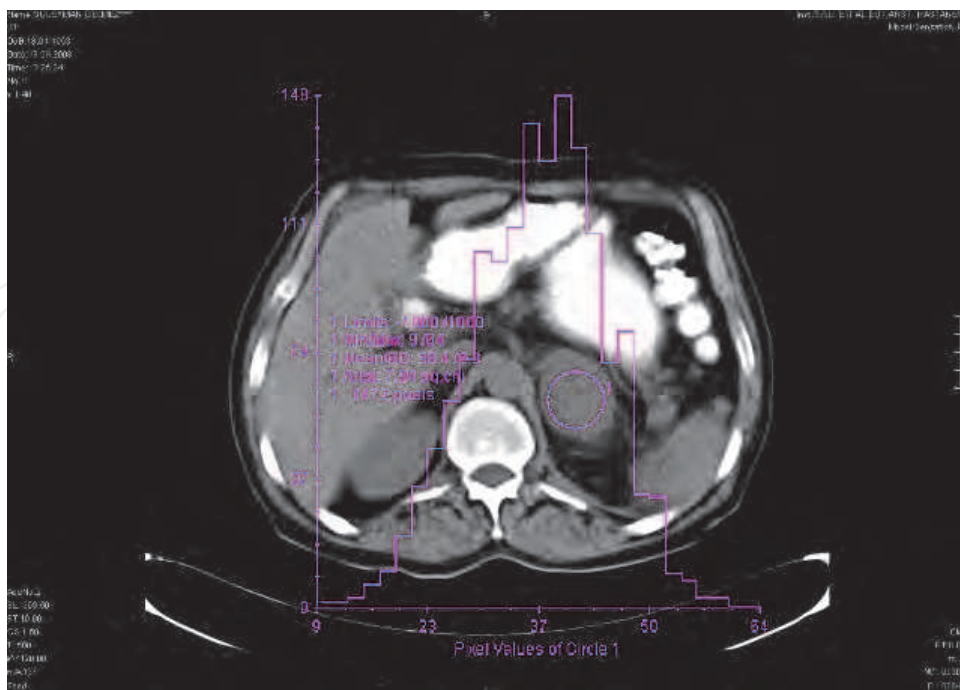
(c) Unenhanced CT scan applying ROI reveals that the incidentaloma containing 450 negative pixels. The upper and lower limits of pixel attenuation are -1 and -1000 , respectively.

(d) Corresponding histogram analysis shows that incidentaloma contains 81% negative pixels and therefore can be regarded as adenoma.

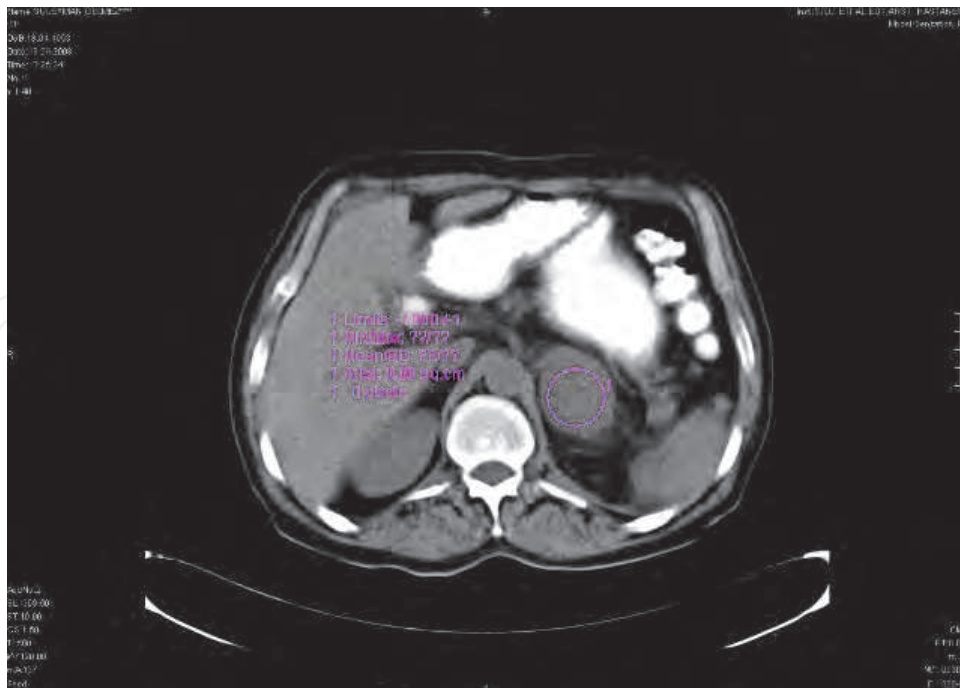
Fig. 7. 61 year-old woman with a left adrenal incidentaloma



(a)



(b)



(c)

(a) Unenhanced CT scan applying ROI reveals 1472 pixels and demonstrates a mean attenuation of 36.4 HU. The upper and lower limits of pixel attenuation are + 1000 and - 1000, respectively.

(b) Corresponding histogram analysis shows pixel attenuation ranging from 9 to 64 HU without any negative pixels.

(c) Unenhanced CT scan applying ROI reveals that the mass contains no negative pixels and therefore can be regarded as metastasis. The upper and lower limits of pixel attenuation are - 1 and - 1000, respectively.

Fig. 8. 55 year-old man with known testicular carcinoma history presenting with a left adrenal mass

Gender	Age	Mean Attenuation (HU)	Number of Pixels	Number of Negative Pixels	Percentage of Negative Pixels (%)	SI Index	SI Ratio	Clinical Presentation	Referans Standard
M	50	38.4	684	1	0	0	0.99	Incidentaloma	Biopsy
F	24	36.7	516	0	0	8.9	0.84	Incidentaloma	Imaging follow-up
F	67	40.8	125	2	2	61	0.38	Incidentaloma	Washout study
F	51	22.3	216	8	4	31.5	0.66	Breast cancer	Washout Study
F	53	24.5	1226	17	1	45.2	0.53	Hypertension	Imaging follow-up
F	65	20.2	177	6	3	81.6	0.18	Incidentaloma	Imaging follow-up

Table 4. Indeterminate masses with CT histogram analysis (n = 6) and both CT istogram analysis and chemical shift MRI (n = 2).

GENDER	AGE	SI INDEX (%)	CS RATIO	PRIMER TUMOR
Male	78	22.6	0.72	Lung cancer
Female	79	18.6	0.87	Insulinoma
Male	37	17.2	0.76	Lung cancer

Table 5. Metastases showing more than 16.5 % signal intensity index leading to false-positive adenoma results.

than 16.5 % (Figure 11). Three metastases, even though they had a chemical shift ratio of more than 0.71, demonstrated a signal intensity index of greater than 16.5 % leading to false positive cases for adenoma diagnosis (Table 5).

When we used an adrenal-to-spleen chemical shift ratio of less than 0.71 and an adrenal-to-spleen signal intensity index of more than 16.5 % formulas, a 97 % sensitivity was obtained for both methods. However, although a 100 % specificity value was achieved for chemical shift ratio, this dropped to 93 % for signal intensity index in adenoma diagnosis (Figure 9).

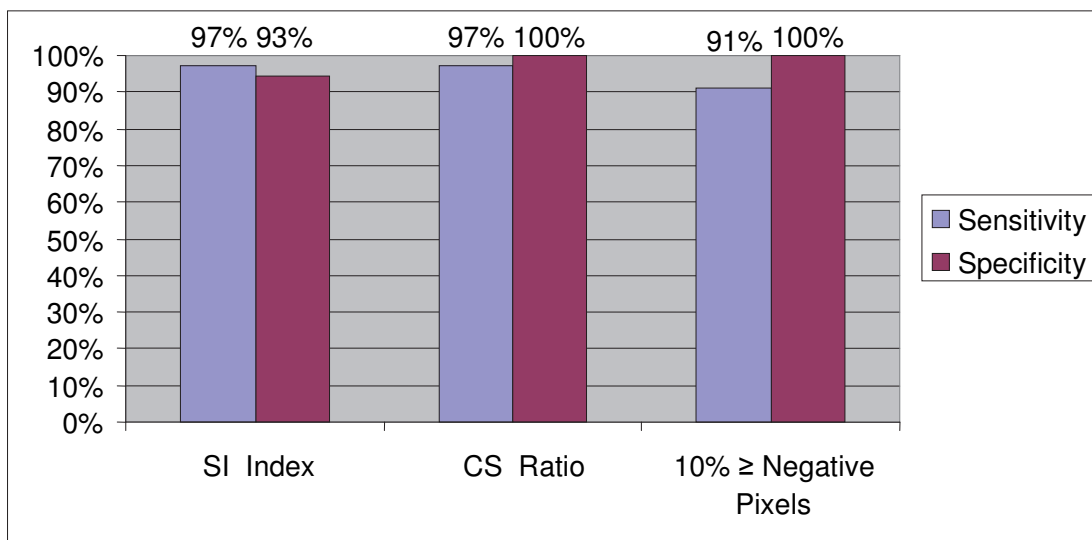
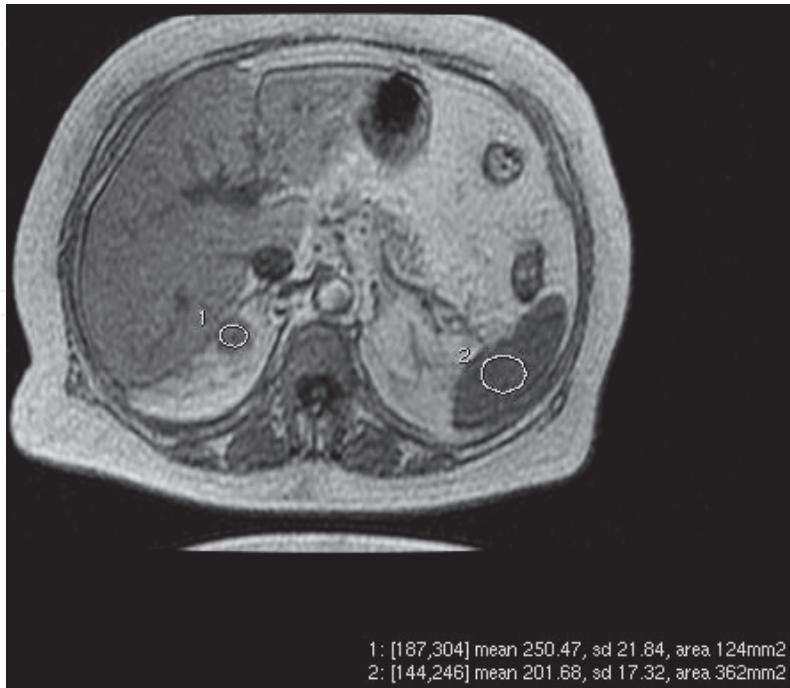


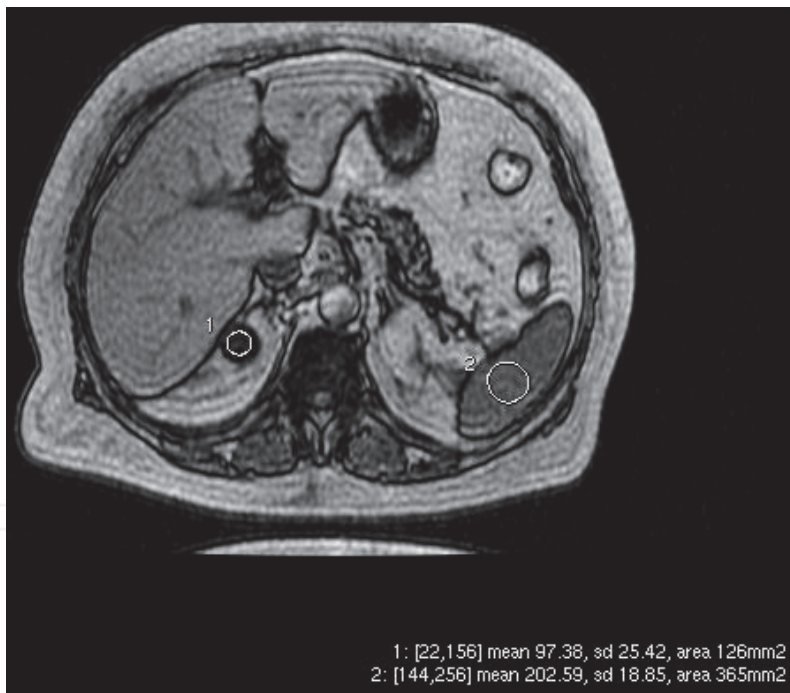
Fig. 9. Bar chart comparing sensitivity values of SI index and CS ratio formulas of chemical shift MRI to % 10 negative pixel threshold of CT histogram analysis on unenhanced CT for adenoma diagnosis.

10. Discussion

The currently used 10 HU threshold mean attenuation method is proved to be useful for differentiating adenomas from metastases at unenhanced CT and has a 71 % sensitivity for diagnosis of adrenal adenomas (3). However, this method is not sensitive in the differentiation of adenomas from nonadenomas at contrast enhanced CT because there is too much overlap in the mean attenuation between two groups (2, 9). Unfortunately, the majority of clinical CT examinations performed in daily routine practice are contrast enhanced. In this case, especially with cancer patients in whom characterization of adrenal masses is important in terms of prognosis and management, this leads to a difficult problem. In the absence of previous comparative CT scans or unenhanced CT studies, patients may be required to undergo an unenhanced CT scan or MRI for further characterization of these adrenal masses.



(a)

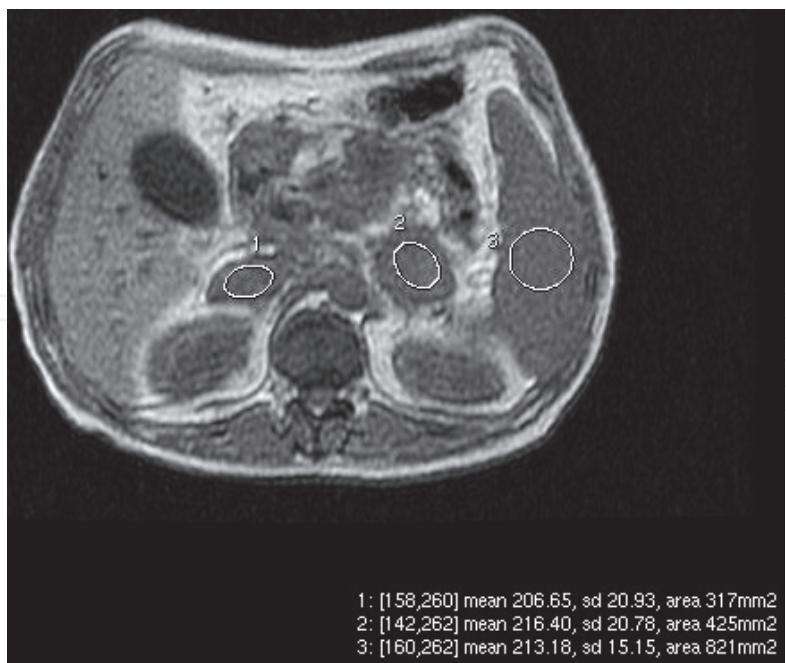


(b)

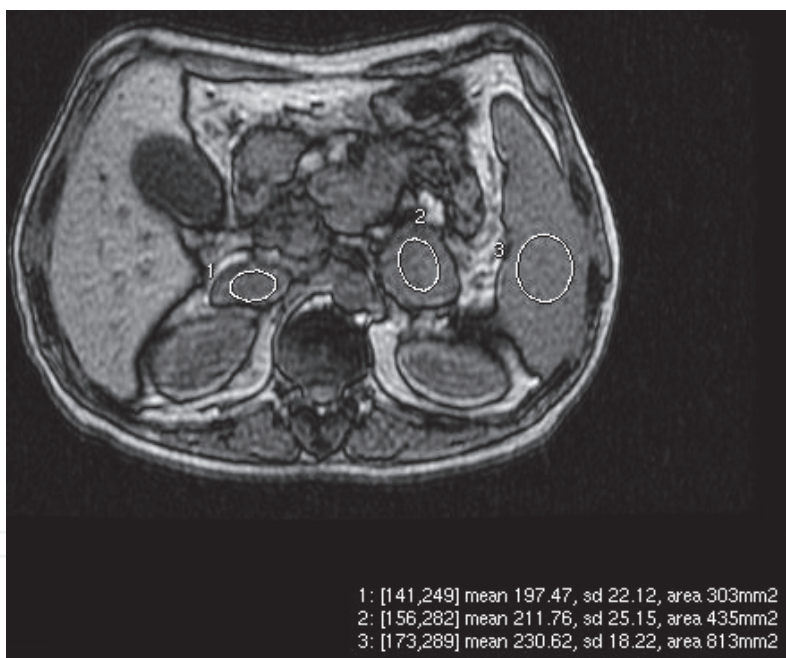
(a) Axial in-phase gradient-echo MR image shows a right adrenal mass demonstrating slight hyperintensity compared to spleen.

(b) Axial opposed-phase gradient-echo MR image demonstrates that the mass showing obvious signal intensity loss with respect to spleen. For this mass adrenal-to-spleen chemical shift ratio and adrenal-to-spleen signal intensity index were calculated as 0.34 and 61 % respectively and

Fig. 10. 72 year-old woman who has a colon carcinoma history presenting with a right adrenal mass



(a)



(b)

(a) Axial in-phase gradient-echo MR image reveals bilateral adrenal masses showing isointense signal intensity with spleen on this image.

(b) Axial opposed-phase gradient-echo MR image showing that these masses demonstrating no signal intensity loss with respect to spleen. For the right adrenal mass adrenal-to-spleen chemical shift ratio and adrenal-to-spleen signal intensity index were calculated as 0.88 and 4.3 % and for the left adrenal mass these values were found as 0.90 and 2.3 %, respectively. Given the results, these masses were regarded as bilateral metastases.

Fig. 11. 46 year-old man with a known history of lung carcinoma having bilateral adrenal masses

On the other hand, despite the fact that the currently used 10 HU threshold mean attenuation method on unenhanced CT is useful, this method may result in a categorization of approximately 29 % of adenomas as being indeterminate (3). In this situation, further investigations such as MRI, adrenal washout study or biopsy may be necessary for the definite characterization of the adrenal mass (10). Currently, there is little doubt that, adrenal washout CT has excellent diagnostic performance for the characterization of adrenal nodules of more than 10 HU on unenhanced CT (4, 10). However, adrenal washout CT has some disadvantages such as the need of multiphasic scanning, resulting in a small amount of added radiation burden, and the use of IV contrast material. Biopsy is an invasive procedure and MRI requires an additional visit with extra burden on the resources.

Bae et al (5) described a histogram analysis method with the goal of improving sensitivity in distinguishing between adenomas and metastases on standard contrast enhanced studies. The histogram analysis method uses a ROI within the adrenal mass and determines if pixels measuring less than 0 HU are present.

CT histogram analysis is a potentially interesting concept that, if successful, is a simple postprocessing technique that does not need additional patient visits, multiphasic scanning, intravenous contrast, or additional imaging investigations.

Bae et al (5) concluded that sensitivity in the diagnosis of an adenoma at contrast-enhanced CT was higher when used CT histogram analysis method compared with the mean attenuation value method. In this study, although only 10.9 % (20 out of 184) of adenomas had a mean attenuation value of ≤ 10 HU on contrast-enhanced CT images, 52.7 % (97 out of 184) of them could be diagnosed by the presence of negative pixels using the CT histogram analysis method. In their series, none of the metastases had a mean attenuation value of ≤ 10 HU or contained negative pixels. Despite the absence of negative pixels in their metastases group they were not sure that the presence of any negative pixel could be regarded as a 100 % specific evidence for the diagnosis of an adrenal adenoma. Therefore they recommended using a 10 % negative pixel threshold as an appropriate criterion for diagnosis of adenomas due to the lowest percentage of negative pixels in their adenoma group which measured less than 10 HU on contrast-enhanced CT images that was detected as 9.8 %. In their study, using 5 % and 10 % negative pixel threshold values, they obtained sensitivities of 35.9 % and 27.7 % respectively, and even with these more stringent criteria that they used for the CT histogram analysis method, the results could be regarded as much better than the 10.9 % sensitivity value they obtained with the 10 HU mean attenuation threshold method. However, if anyone should use more than a 10 % negative pixel threshold value for the diagnosis of adenoma, this increase would result in a decrease of test sensitivity and may obviate the histogram analysis method to be used as a clinically useful adjunct to the mean attenuation method.

Jhaveri et al (11) pointed out that by using a CT histogram-derived threshold of more than 10 % negative pixel, adenomas can be diagnosed with a 100 % specificity on unenhanced CT. In spite of this perfect specificity value they achieved, the sensitivity was compromised and yielded a modest value of 46 %. Negative pixels were present in 25 out of 28 adenomas and the mean negative pixel percentage was found to be 9.8 % for adenomas. In their series, unlike Bae et al's, 9 out of 11 nonadenomas also demonstrated negative pixels and the mean negative pixel percentage was found as 5.7 % for the nonadenoma group. However by

using a more than 10 % negative pixel threshold value, although 13 out of 28 adenomas were detected, none of the nonadenomas were consistent with this criterion. Based on this finding, they could not find a statistically significant relationship for diagnosing an adenoma by the simple presence of negative pixels in a mass and for this reason they did not recommend using the mere presence of negative pixels as a sufficient criterion for the diagnosis of an adenoma.

Remer et al (12) in their retrospective study, included 187 patients with 204 adrenal masses to evaluate CT histogram analysis method in distinguishing adenomas from nonadenomas based on their pathology results. In this study, the interpreters found that 72 out of 76 and 63 out of 72 adenomas, respectively, with attenuation values of more than 10 HU contained negative pixels on unenhanced CT images. On contrast-enhanced CT images, none of the adenomas had a mean attenuation value of ≤ 10 HU, but 24 and 28, respectively, persisted to contain negative pixels. Negative pixels were detected on both unenhanced and contrast-enhanced CT images of the nonadenoma group including metastases, pheochromocytomas and adrenocortical carcinomas. However, none of the nonadenoma group showed an attenuation value of ≤ 10 HU on both unenhanced and contrast-enhanced CT images. Using a 10 % negative pixel threshold value to diagnose an adenoma, an approximately 88 % specificity and 71 % sensitivity was obtained on unenhanced CT images. But on contrast-enhanced CT images even a better specificity of 99 % was obtained, where sensitivity dropped to 12 %. This sensitivity level was similar to that obtained by Bae et al (5) on contrast-enhanced CT images. Due to this unacceptable low sensitivity value obtained, they concluded that despite the perfect specificity value achieved, CT histogram analysis using 10 % negative pixel threshold value on contrast-enhanced CT images has limited clinical usefulness for the diagnosis of an adenoma.

Boland et al (3) in their meta-analysis of 10 reported studies used unenhanced CT to characterize adrenal masses. They concluded that an increase in the 10 HU mean attenuation threshold value yielded more overlapping between adenomas and metastases. Consequently, although the diagnostic sensitivity of an adenoma increases, specificity drops. Similarly, as with Bae et al (5), the same trend can be observed in our study, too. When we used more than 10 HU threshold value for contrast-enhanced CT images, our sensitivity values substantially increased while specificity values decreased.

Jhaveri et al (13) recently published a study in which a 24 lipid-poor adenoma population was evaluated by CT histogram analysis method using more than 5 % negative pixel threshold value on unenhanced images. They obtained a sensitivity of about 91 % with a specificity of 100 % when compared with adrenal washout CT sensitivity and specificity of 100 % each. When they used a 10 % negative pixel threshold value, the sensitivity was still at a good level of 70 %, while maintaining a specificity of 100 % compared with adrenal washout CT at sensitivity and specificity of 100 %.

In a recently published study by Ho LM et al (14), the authors stated that by applying a 10 % negative pixel threshold, sensitivity increases in the diagnosis of adenoma from 68 % to 84 %, when the standard mean CT attenuation value of ≤ 10 HU was used, while maintaining a 100 % specificity. They concluded that a CT histogram analysis using a 10 % negative pixel threshold can be used to characterize some adenomas that would otherwise be considered as indeterminate by mean CT attenuation alone and consequently may help decrease

referrals for additional imaging or biopsy of adrenal masses, particularly in patients with a known primary malignancy. They stated that the application of a threshold of 5 % negative pixels slightly increases sensitivity for the diagnosis of an adenoma compared to using a threshold of 10 % negative pixels ; however, the advantage of this higher sensitivity is compromised by decreased specificity. In an oncological patient population, decreasing specificity would lead to more metastases since they may be misclassified as benign adenomas which consequently could result in understaging of the primary tumor. They therefore recommended the application of a threshold of 10 % negative pixels for CT histogram analysis.

In our study, we obtained a 77.2 % sensitivity for ≤ 10 HU mean attenuation threshold value and a much better sensitivity of 90.9 % for 10 % negative pixel threshold value with CT histogram analysis method on unenhanced CT images. Both methods gave a 100 % specificity for the diagnosis of an adenoma. But at contrast-enhanced CT, our sensitivity substantially decreased to 12.1 % for ≤ 10 HU mean attenuation value. We obtained a sensitivity of 37.9 % for 5 % negative pixel threshold and a 28.8 % sensitivity for 10 % negative pixel threshold, respectively. For both methods, again a 100 % specificity was maintained on contrast-enhanced CT images. Our results suggest that a CT histogram analysis method using a 10 % negative pixel threshold performed on unenhanced CT images is superior to ≤ 10 HU mean attenuation threshold method and results in good sensitivity while maintaining perfect specificity for the diagnosis of an adenoma. But on contrast-enhanced images, in similarity with most of the studies we mentioned before, although a 100 % specificity was maintained, sensitivity values dramatically decreased to unacceptable levels for both 5 % and 10 % negative pixel threshold values, pointing to CT histogram analysis method as a less clinical useful adjunct on contrast-enhanced CT.

The sensitivity for diagnosing an adenoma using a CT histogram-derived threshold of more than 10 % negative pixel decreased as the unenhanced CT attenuation increased. The demonstration of a statistically significant relationship between increasing the percentage of negative pixels and decreasing mean CT attenuation supported this relationship. This relationship is consistent with the fact that adenomas having abundant lipid have lower CT attenuation and therefore are likely to have a higher percentage of negative pixels.

In our study, adrenal masses demonstrated an increase in mean attenuation and a decrease in the percentage of negative pixels on contrast-enhanced CT images compared to unenhanced CT images. This can be seen in many other studies and was attributed to the pseudoenhancement effect that has been described for renal cysts (15, 16). This phenomenon may cause a decrease in the percentage of negative pixels in adenomas on contrast-enhanced CT images as a result of artifactual enhancement of lipid tissue related to enhancing adjacent nonlipid tissue.

Clinical applications of CT histogram analysis and chemical shift MRI for the diagnosis of adrenal adenomas are based on the different lipid contents of benign and malignant adrenal masses. In fact, adenomas have higher lipid contents than metastases which account for their low attenuation on unenhanced CT and signal intensity loss on opposed-phased MR images. But whether a high correlation between CT histogram analysis and chemical shift MRI measurements exists is yet unclear, because a comparison of these

techniques in the same cohort of patients has been previously published in only a few of the studies in the literature (11, 17).

In general radiology practice, qualitative visual assessment is a commonly used method to characterize adrenal adenomas without measuring signal intensity on chemical shift images. Mayo-Smith et al. (18) compared a qualitative assessment of adrenal masses with the adrenal-to-spleen chemical shift ratio and reported that there was no significant difference in terms of mass characterization. However, Israel et al. (17) found that there was a discrepancy in 15 out of 42 (36 %) adrenal masses between qualitative and quantitative analyses and stated that qualitative analysis should be regarded as less sensitive than quantitative analysis in adenoma diagnosis. The results of this study can be indicated that qualitative analysis should be regarded as less sensitive than quantitative analysis in terms of adrenal mass characterization on MRI and therefore it is a necessity to obtain quantitative measurements of adrenal masses. In our study, we did not use qualitative visual assessment for adrenal mass characterization on opposed-phase images.

In our study, using an adrenal-to-spleen chemical shift ratio of less than 0.71 and an adrenal signal intensity index of greater than 16.5 % formulas on chemical shift MRI, we were able to diagnose 65 out of 67 (97 %) adenomas. 2 out of 67 adenomas could not be determined by MRI, but were also characterized as indeterminate by CT histogram analysis method due to containing less than 10 % negative pixels. But in 4 masses that were regarded as indeterminate by CT histogram, we were able to diagnose them as adenomas using chemical shift MRI formulas. Regarding metastases, none of them demonstrated a more than 10 % negative pixel by CT histogram analysis method. On the other hand, although 42 out of 42 metastases (100 %) exhibited an adrenal-to-spleen chemical shift ratio of more than 0.71, 39 out of 42 metastases (93 %) had an adrenal signal intensity index of less than 16.5 % leading to three false positive results and a subsequent decrease in specificity for adenoma diagnosis. Therefore we can state that although there was a high correlation between these two methods, chemical shift MRI using quantitative analysis was found to be more sensitive than CT histogram analysis method, because it enables us to discriminate more adenomas that would otherwise be regarded as indeterminate on CT. For metastases, CT histogram analysis and MRI using chemical shift ratio formula diagnosed all cases and was found superior to the signal intensity index formula.

Jhaveri et al. (11) compared CT histogram analysis method using 10 % negative pixel threshold on unenhanced CT and chemical shift MRI using a threshold of 20 % signal intensity drop in 39 adrenal masses that were indeterminate on CT. While CT histogram analysis using a more than 10 % negative pixel threshold yielded a 46 % sensitivity and 100 % specificity for adenoma diagnosis, MRI using a threshold of 20 % signal intensity drop increased sensitivity to a 71 % level, while maintaining 100 % specificity. Using MRI, the observers were able to characterize 7 more adrenal masses as adenomas whereas they were regarded as indeterminate by CT histogram analysis, similar to our study. They concluded that CT histogram analysis with a threshold of 10 % negative pixel increases sensitivity for adenoma diagnosis compared to mean CT attenuation alone. But chemical shift MRI with a threshold of 20 % signal intensity drop is more sensitive than CT histogram analysis for adenoma diagnosis.

In a similar study performed by Israel et al. (17), 42 adrenal masses were evaluated by both unenhanced CT and chemical shift MRI for further characterization. A lipid-rich adenoma was diagnosed if a mass showed equal or less than 10 HU mean attenuation value on unenhanced CT, had an adrenal-to-spleen chemical shift ratio of less than 0.71 and exhibited an adrenal signal intensity index of more than 16.5 %. 28 out of 42 (67 %) adrenal masses fulfilled all of the preceding criteria and therefore were diagnosed as benign masses. Although 8 out of 42 (19 %) adrenal masses had a more than 10 HU mean attenuation value on unenhanced CT images, demonstrated an adrenal-to-spleen chemical shift ratio of less than 0.71 and a signal intensity index of more than 16.5 %, they were unchanged in size at follow-up imaging and were regarded as benign masses. Chemical shift MRI was able to characterize 8 out of 13 (62 %) adrenal adenomas that exhibited more than 10 HU mean attenuation value resulting in indeterminate masses on unenhanced CT images.

Outwater et al. (19) in their study investigated whether a correlation exists between mean attenuation value on unenhanced CT and chemical shift MRI using adrenal-to-spleen chemical shift ratio of 0.71 threshold in 49 adrenal masses. They reported that these measurements are highly correlated and support that both techniques rely on the lipid content within the adrenal lesions. But in this relatively small sample-sized study, they found no clear evidence as to which method used was more accurate to characterize adrenal masses.

In a study performed by Mayo-Smith et al. (18), a slightly higher adrenal-to-spleen chemical shift ratio of 0.75 was applied and all of the metastases were correctly identified. But with this threshold value, 5 out of 28 adenomas were misclassified. In this study similar to ours, both adrenal-to-spleen chemical shift ratio and adrenal signal intensity index formulas were used and it was mentioned that adrenal-to-spleen chemical shift ratio is a better quantitative test for discriminating adenomas from metastases. Conversely, Fujiyoshi et al. (20) reported that adrenal signal intensity index using a threshold value between 11.2 % - 16.5 %, resulted in 100 % accuracy and should be accepted as the best quantitative test for discriminating benign from malignant adrenal masses. They claimed that adrenal-to-spleen ratio, adrenal-to-muscle ratio and adrenal-to-liver ratio formulas demonstrated considerable overlap between benign and malignant adrenal tumors. Park et al. (21) compared delayed enhanced CT and chemical shift MRI for evaluating 43 lipid-poor adenomas. In this study, similar to the prior one, they revealed that adrenal signal intensity index exhibited a higher diagnostic accuracy than did adrenal-to-spleen chemical shift ratio.

In our study, as with the above, when we compared adrenal-to-spleen chemical shift ratio and adrenal signal intensity index formulas, we could not encounter any discrepancy between these two formulas in adenoma diagnosis. All of the adenomas, except for two cases, showed a less than 0.71 chemical shift ratio and had a more than 16.5 % signal intensity index. For these two adenomas, while a more than 0.71 chemical shift ratio was calculated, they also exhibited a less than 16.5 % signal intensity index. But regarding metastases, although all of them showed a more than 0.71 chemical shift ratio, 3 of them exhibited a signal intensity index of more than 16.5 % resulting in false positive adenoma cases. Hence, similar to Mayo Smith et al. (18), we can state that adrenal-to-spleen chemical shift ratio formula can be regarded as a better quantitative test for discriminating adenomas from metastases.

CT histogram analysis is influenced by variations in CT image quality and noise levels. CT image quality is affected by a number of other factors such as patient and technical properties which, as with other previous studies, were not standardized completely in this study. These factors include patient body habitus, breathing motion artifact, size and location of ROI, kilovolt peak and miliampere second values, slice collimation, section thickness, reconstruction kernel, IV contrast media injection rate, and scan delay. Other factors that could impact image noise include differences in CT scanner technology (Both dual and multi-detector row CT scanners were used in this study). Noisy pixels may simulate false-positive percentage negative pixels. The higher current reduces image noise and improves image quality, which is critical for thin-section extended-length studies, especially of large patients (22). This could reduce the number of spuriously negative pixels. However, thinner slice thickness may lead to noisier images. Therefore, thin slices or sharp kernels may be inappropriate for CT histogram analysis because of excessive image noise. Bae et al (5) recommended that CT images should be reconstructed with a smooth soft-tissue-kernel typically used for abdominal CT rather than a sharp lung or bone algorithm, which is usually noisier, prior to application of histogram analysis. Because image noise is inversely related to the square root of the tube current (23), CT images should be acquired with standard miliamper-second and peak kilovoltage used for the abdomen rather than with a low-dose technique (5, 23).

In spite of their several limitations, our studies carry the importance of being prospective in nature whereas many of the previous studies in the literature have been performed retrospectively and therefore carry a potential for subject-selection bias. Due to the prospective nature of the studies, we were able to standardize most of the imaging parameters such as slice thickness, collimation, bandwidth, coil type etc. An important limitation of our studies are that we used pathological data as a reference standard only in a small percentage of patients. This is partly due to daily practice where CT or MRI is used for characterizing adrenal adenomas and these patients seldom undergo biopsy or surgery for definitive diagnosis. Another limitation of both studies are the lack of long-term follow-up and although we used a minimum of 6 months follow-up time as a reference standard, there is a possibility that some adrenal metastases may have long doubling times leading to a confusion. In the literature although some authors have used a minimum 1 year follow-up (24, 25), many of the leading authors have agreed that 6 months follow-up time is sufficient as a reference standard for adenoma diagnosis (4, 18, 19, 26). Finally, in our studies we obtained high specificity values reaching out to 100 % level and this should be viewed with some scepticism.

11. Conclusion

In conclusion, our first study suggests that CT histogram analysis using a 10 % negative pixel threshold has a higher sensitivity than ≤ 10 HU mean attenuation threshold method to discriminate adenomas from nonadenomas on unenhanced CT while a 100 % specificity has been achieved for both methods. Therefore CT histogram analysis method has a promising potential in the diagnosis of adenoma and can replace the mean attenuation method. But with contrast-enhanced CT, although 100 % specificity is being maintained for both methods, sensitivities significantly decrease. Although better sensitivities are

obtained with CT histogram analysis using 5 % and 10 % negative pixel threshold values compared to the mean attenuation method, this poor sensitivity levels would limit its clinical usefulness.

In our second study that comparing of CT histogram analysis using a 10 % negative pixel threshold on unenhanced CT with chemical shift MRI using adrenal-to-spleen chemical shift ratio and adrenal signal intensity index formulas demonstrate high correlation for adenoma diagnosis. Although CT histogram analysis and adrenal-to-spleen chemical shift ratio formula have perfect specificity values, adrenal signal intensity index formula has a relatively lower specificity. In the second study, we found that adrenal-to-spleen chemical shift ratio is superior to the other two methods in the diagnosis of adenoma. Hence we can state that chemical shift MRI using the quantitative method has a higher sensitivity than the histogram analysis method and may help further characterization of some adrenal masses which are regarded as indeterminate on CT histogram analysis.

12. References


- [1] Korobkin M. 2000. CT characterization of adrenal masses : the time has come. *Radiology* 217 : 629-632.
- [2] Lee MJ, Hahn PF, Papanicolaou N, Egglin TK, Saini S, Mueller PR, Simeone JF. 1991. Benign and malignant adrenal masses : CT distinction with attenuation coefficients, size and observer analysis. *Radiology* 179 : 415-418.
- [3] Boland GW, Lee MJ, Gazelle GS, Halpern EF, Mc-Nicholas MM, Mueller PR. 1998. Characterization of adrenal masses using unenhanced CT : an analysis of the CT literature. *AJR Am J Roentgenol* 171 : 201-204.
- [4] Pena CS, Boland GW, Hahn PF, Lee MJ, Mueller PR. 2000. Characterization of indeterminate (lipid poor) adrenal masses : use of washout characteristics at contrast enhanced CT. *Radiology* 217 : 798-802.
- [5] Bae KT, Fuangtharnthip P, Prasad SR, Joe BN, Heiken JP. 2003. Adrenal masses : CT characterization with histogram analysis method. *Radiology* 228 : 735-742.
- [6] Mayo-Smith WW, Boland GW, Noto RB, Lee M. 2001. State-of-the-art of adrenal imaging. *RadioGraphics* 21 : 995-1012.
- [7] Slapa RZ, Jakubowski W, Januszewics A, Kasperlik-Zaluska AA, Dabrowska E, Fijuth J, Feltynowski T, Tarnawski R, Krolicki L. 2000. Discriminatory power of MRI for differentiation of adrenal non-adenomas vs. adenomas evaluated by means of ROC analysis : can biopsy be obviated ? *Eur Radiol* 10 : 95-104.
- [8] Heinz Peer G, Honigschnabl S, Schneider B, Niederle B, Kaserer K, Lechner G. 1999. Characterization of adrenal masses using MR imaging with histopathologic correlation. *AJR Am J Roentgenol* 173 : 15-22.
- [9] Korobkin M, Brodeur FJ, Yutzy GG, Francis IR, Quint LE, Dunnick NR, Kazerooni EA. 1996. Differentiation of adrenal adenomas from nonadenomas using CT attenuation values. *AJR Am J Roentgenol* 166 : 531-536.
- [10] Al-Hawary MM, Francis IR, Korobkin M. 2005. Non-invasive evaluation of the incidentally detected indeterminate adrenal mass. *Best Pract Res Clin Endocrinol Metab* 19 : 277-292.

- [11] Jhaveri KS, Wong F, Ghai S, Haider MA. 2006. Comparison of CT histogram analysis and chemical shift MRI in the characterization of indeterminate adrenal nodules. *AJR Am J Roentgenol* 187 : 1303-1308.
- [12] Remer EM, Motta-Ramirez GA, Shepardson LB, Hamrahan AH, Herts BR. 2006. CT histogram analysis in pathologically proven adrenal masses. *AJR Am J Roentgenol* 187 : 191-196.
- [13] Jhaveri KS, Lad SV, Haider MA. 2007. Computed tomographic histogram analysis in the diagnosis of lipid poor adenomas : comparison to adrenal washout computed tomography. *J Comput Assist Tomogr* 31 : 513-518.
- [14] Ho LM, Paulson EK, Brady MJ, Wong TZ, Schindera ST. 2008. Lipid-poor adenomas on unenhanced CT : Does histogram analysis increase sensitivity compared with a mean attenuation threshold method ? *AJR Am J Roentgenol* 191 : 234-238.
- [15] Coulam CH, Sheafor DH, Leder DA, Paulson EK, DeLong DM, Nelson RC. 2000. Evaluation of pseudoenhancement of renal cysts during contrast-enhanced CT. *AJR Am J Roentgenol* 174 : 493-498.
- [16] Bae KT, Heiken JP, Siegel CL, Bennett HF. 2000. Renal cysts : is attenuation artifactually increased on contrast-enhanced CT images ? *Radiology* 216 : 792-796.
- [17] Israel GM, Korobkin M, Wang C, Hecht EN, Krinsky GA. 2004. Comparison of unenhanced CT and chemical shift MRI in evaluating lipid-rich adrenal adenomas. *AJR Am J Roentgenol* 183 : 215-219.
- [18] Mayo-Smith WM, Lee MJ, McNicholas MM, Hahn PF, Boland GW, Saini S. 1995. Characterization of adrenal masses (< 5 cm) by use of chemical shift MR imaging : observer performance versus quantitative measures. *AJR Am J Roentgenol* 165 : 91-95.
- [19] Outwater EK, Siegelman ES, Huang AB, Birnbaum BA. 1996. Adrenal masses : correlation between CT attenuation value and chemical shift ratio at MR imaging with in-phase and opposed-phase sequences. *Radiology* 200 : 749-752.
- [20] Fujiyoshi F, Nakajo M, Fukukura Y, Tsuchimochi S. 2003. Characterization of adrenal tumors by chemical shift fast low-angle shot MR imaging : comparison of four methods of quantitative evaluation. *AJR Am J Roentgenol* 180 : 1649-1657.
- [21] Park BK, Kim CK, Kim B, Lee JH. 2007. Comparison of delayed enhanced CT and chemical shift MR for evaluating hyperattenuating incidental adrenal masses. *Radiology* 243 : 760-765.
- [22] Rydberg J, Buckwalter KA, Caldemeyer KS, Phillips MD, Conces DJ Jr, Aisen AM, Persohn SA, Kopecky KK. 2000. Multisection CT : scanning techniques and clinical applications. *RadioGraphics* 20 : 1787-1806.
- [23] Birnbaum BA, Hindman N, Lee J, Babb JS. 2007. Multidetector row CT attenuation measurements: assessment of intra- and interscanner variability with an anthropomorphic body CT phantom. *Radiology* 242 : 109-119.
- [24] Outwater EK, Siegelman ES, Radecki PD, Piccoli CW, Mitchell DG. 1995. Distinction between benign and malignant adrenal masses : value of T 1 weighted chemical-shift MR imaging. *AJR Am J Roentgenol* 165 : 579-583.
- [25] Szolar DH, Kammerhuber FH. 1998. Adrenal adenomas and nonadenomas : assessment of washout at delayed contrast-enhanced CT. *Radiology* 207 : 369-375.

- [26] Caoili EM, Korobkin M, Francis IR, Cohan RH, Platt JF, Dunnick NR, Raghupathi KI. 2002. Adrenal masses : characterization with combined unenhanced and delayed enhanced CT. *Radiology* 222 : 629-633.

IntechOpen

IntechOpen



Computed Tomography - Special Applications

Edited by Dr. Luca Saba

ISBN 978-953-307-723-9

Hard cover, 318 pages

Publisher InTech

Published online 21, November, 2011

Published in print edition November, 2011

CT has evolved into an indispensable imaging method in clinical routine. The first generation of CT scanners developed in the 1970s and numerous innovations have improved the utility and application field of the CT, such as the introduction of helical systems that allowed the development of the "volumetric CT" concept. Recently interesting technical, anthropomorphic, forensic and archeological as well as paleontological applications of computed tomography have been developed. These applications further strengthen the method as a generic diagnostic tool for non destructive material testing and three dimensional visualization beyond its medical use.

How to reference

In order to correctly reference this scholarly work, feel free to copy and paste the following:

Ahmet Mesrur Halefoglu (2011). Adrenal Imaging Methods: Comparison of Mean CT Attenuation, CT Histogram Analysis and Chemical Shift Magnetic Resonance Imaging for Adrenal Mass Characterization and Review of the Literature, Computed Tomography - Special Applications, Dr. Luca Saba (Ed.), ISBN: 978-953-307-723-9, InTech, Available from: <http://www.intechopen.com/books/computed-tomography-special-applications/adrenal-imaging-methods-comparison-of-mean-ct-attenuation-ct-histogram-analysis-and-chemical-shift-m>

INTECH
open science | open minds

InTech Europe

University Campus STeP Ri
Slavka Krautzeka 83/A
51000 Rijeka, Croatia
Phone: +385 (51) 770 447
Fax: +385 (51) 686 166
www.intechopen.com

InTech China

Unit 405, Office Block, Hotel Equatorial Shanghai
No.65, Yan An Road (West), Shanghai, 200040, China
中国上海市延安西路65号上海国际贵都大饭店办公楼405单元
Phone: +86-21-62489820
Fax: +86-21-62489821

© 2011 The Author(s). Licensee IntechOpen. This is an open access article distributed under the terms of the [Creative Commons Attribution 3.0 License](#), which permits unrestricted use, distribution, and reproduction in any medium, provided the original work is properly cited.

IntechOpen

IntechOpen