

# We are IntechOpen, the world's leading publisher of Open Access books Built by scientists, for scientists

**4,800**

Open access books available

**122,000**

International authors and editors

**135M**

Downloads

Our authors are among the

**154**

Countries delivered to

**TOP 1%**

most cited scientists

**12.2%**

Contributors from top 500 universities



**WEB OF SCIENCE™**

Selection of our books indexed in the Book Citation Index  
in Web of Science™ Core Collection (BKCI)

Interested in publishing with us?  
Contact [book.department@intechopen.com](mailto:book.department@intechopen.com)

Numbers displayed above are based on latest data collected.

For more information visit [www.intechopen.com](http://www.intechopen.com)



# Estimated Specific Gravity with Quantitative CT Scan in Traumatic Brain Injury

Vincent Degos, Thomas Lescot and Louis Puybasset  
*Neuro-ICU Unit, Department of Anesthesiology and Critical Care  
Groupe Hospitalier Pitié-Salpêtrière, APHP, Université Pierre et Marie Curie, Paris  
France*

## 1. Introduction

An uncontrolled increase in intracranial pressure (ICP), often due to cerebral oedema, is the most common cause of death in traumatic brain injury (TBI) patients. Different types of oedema coexist in TBI patients: vasogenic oedema and cytotoxic oedema. Vasogenic oedema occurs with the extravasation of fluid into the extracellular space following blood brain barrier (BBB) disruption. Cytotoxic oedema results from a shift of water from the extracellular compartment into the intracellular compartment due in part to alterations in normal ionic gradients. The description of the localisation, and the knowledge of the chronology, the determinants, and the kinetics of the BBB disruption are necessary to adapt therapeutic strategy.

Although nuclear magnetic resonance is not advisable during the acute phase of human TBI, especially in unstable TBI patients, this imaging is one of the most accurate for the study of brain oedema. Diffusion-weighted imaging provides a useful and non-invasive method for visualizing and quantifying diffusion of water in the brain associated with oedema. Apparent diffusion coefficients (ADC) can be calculated and used to assess the magnitude of water diffusion in tissues. For example, a high ADC value indicates more freely diffusible water which is considered as a marker of vasogenic oedema. On the other hand, cytotoxic oedema restricts water movement and results in decreased signal intensities in the ADC map. In a rat model of diffuse TBI, an early increase in ADC values during the first 60 minutes was observed, followed by a decrease in ADC values reaching a minimum at one week [1]. This result suggests a biphasic oedema formation following diffuse TBI without contusion, with a rapid and short disruption of the BBB during the first hour post injury, leading to an early formation of vasogenic edema. Contrary to the non-contused areas, there are numerous arguments in favour of a profound and prolonged alteration of the BBB in traumatic areas of contusion appearing on CT [2-7]. Several methods have been used to study oedema formation and the BBB changes following animal and human TBI, however its underlying mechanisms are still not well understood. For these reasons, it might be interesting to investigate a new and more accessible technique to study the oedema formation at the acute phase of human TBI, particularly to compare the non-contused and the contused areas and to follow the BBB state in these areas with time.

Computed Tomography (CT) scan, the iconographic gold standard to describe acute brain lesions, is widespread and accessible. CT scan image acquisitions are prompt and reproducible with high quality. With specific software, volume, weight and an estimation of specific gravity (eSG) can be quantified from CT DICOM image and can be used to study different anatomic areas at different periods after injury. The goal of this review is to describe the use of quantitative CT scan results in non-contused and contused areas in TBI patients.

## 2. Quantitative computed tomography

Since its development in the 1970's, CT scan has become the radiological examination of choice in the acute assessment of patients with acute brain lesions and especially TBI. CT maps the way in which different tissues attenuate or absorb the beam of X-ray. A crucial point is that the radiological attenuation is linearly correlated with the physical density in the range of human tissue densities [8, 9]. For example, blood clot has relatively little water content and absorbs X-rays more than the normal brain. It is displayed as hyperdense area. On the other hand, ischemia and liquid collection are displayed in dark areas because there is an increase in water content.

BrainView, a recent software package developed for Windows workstations, provides semi-automatic tools for brain analysis and quantification from DICOM images obtained from cerebral CT scan. For each exam, BrainView inputs series of continuous axial scans of the brain. It then automatically excludes extracranial compartments on each section (**Figure 1**).

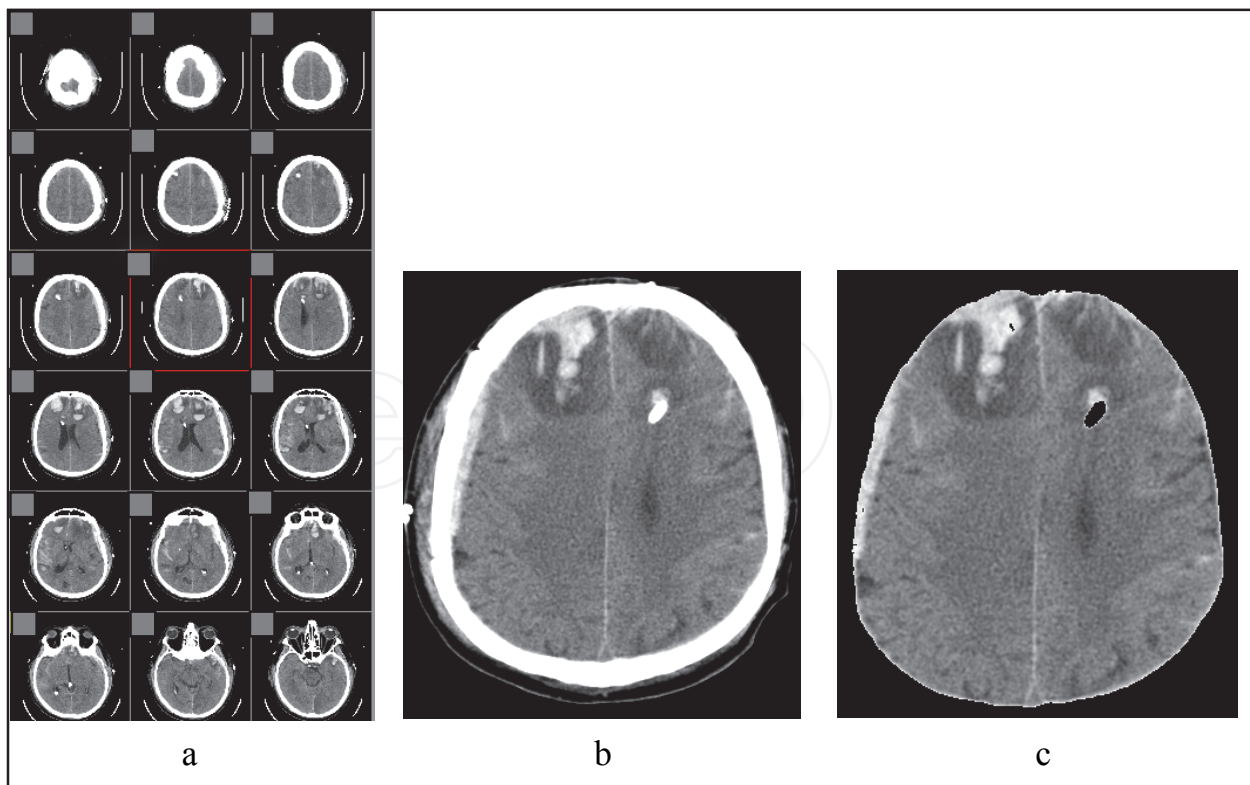


Fig. 1. Brainview software working window. CT DICOM image imports (a, b), automatic exclusion of extracranial compartments (c).

Interactive slice-by-slice segmentation allows the user to select different anatomical territories indexed throughout the whole sequence. The software is an upgrade of Lungview, another software previously developed by the same institution (Institut National des Télécommunications) and used for lung and heart weight, volume and density analysis by our group [10-12]. For each compartment of a known number of voxels, the volume, weight and eSG are computed using the following equations:

1. Volume of the voxel = surface x section thickness.
2. Weight of the voxel =  $(1 + CT / 1000) \times$  Volume of the voxel where CT is the attenuation coefficient (expressed in Hounsfield Unit).
3. Volume of the compartment = number of voxels x volume of the voxel.
4. Weight of the compartment = summation of the weight of each individual voxel included in the compartment.
5. Estimated specific gravity (eSG) of the compartment = Weight of the compartment / Volume of the compartment. The eSG is expressed as a physical density in g/mL.

Brainview technology was first validated *ex vivo*. We measured the specific gravity of different solutes by determining the weight of one liter of these solutes (Figure 2). The eSG of the same solutes was then computed using BrainView. The two values were linearly correlated especially in the range of densities in human brain tissue [13]. Using the correlation between the specific density and the radiological attenuation, Brainview allowed

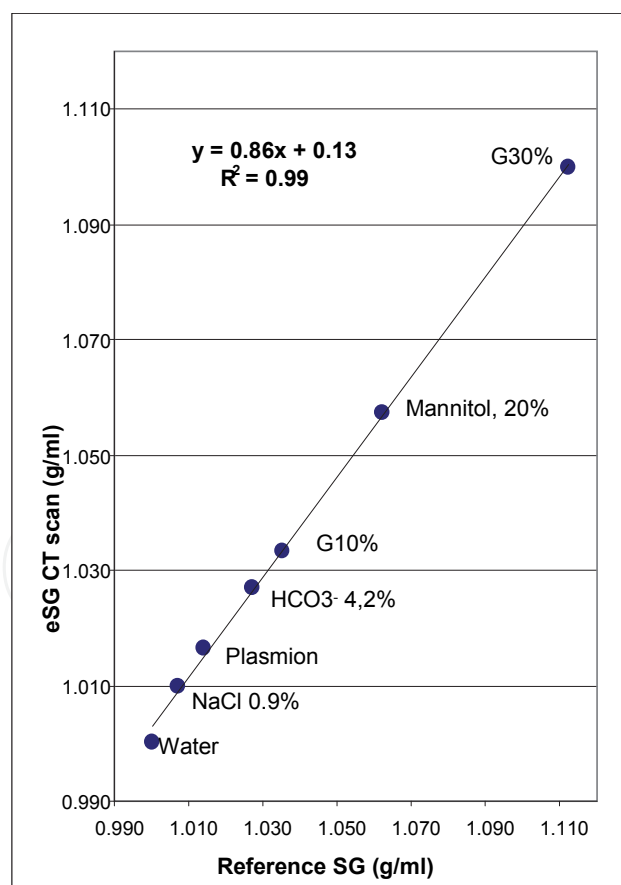


Fig. 2. Comparison of the specific gravity (SG) of the different solutes measured by the electronic scale method (weight/volume) and the estimated specific gravity (eSG) with quantitative CT scan [13].

us to assess the weight, volume and eSG of different anatomical parts of the brain (the two hemispheres, the cerebellum, the brainstem and the intraventricular and subarachnoid cerebrospinal fluid, the white and grey matters, contused and non-contused hemispheric areas). The technology also allows the comparison of different populations (TBI patients, subarachnoid haemorrhage patients, controls) or the same population at different periods (first hours after injury, CT controls at 1 week, before or after a treatment etc.).

In theory, eSG measurement is a good reflection of the density variations. When studying the consequence of BBB disruption in TBI, a complete disruption of the BBB with leakage of water, electrolytes, proteins and cells would increase the brain eSG since the added volume (exsudat) has a density greater than the brain. However, a partial disruption of the BBB with leakage of water and electrolytes would decrease the density since the added volume (transudat) has a density lower than the brain (**Figure 3**).

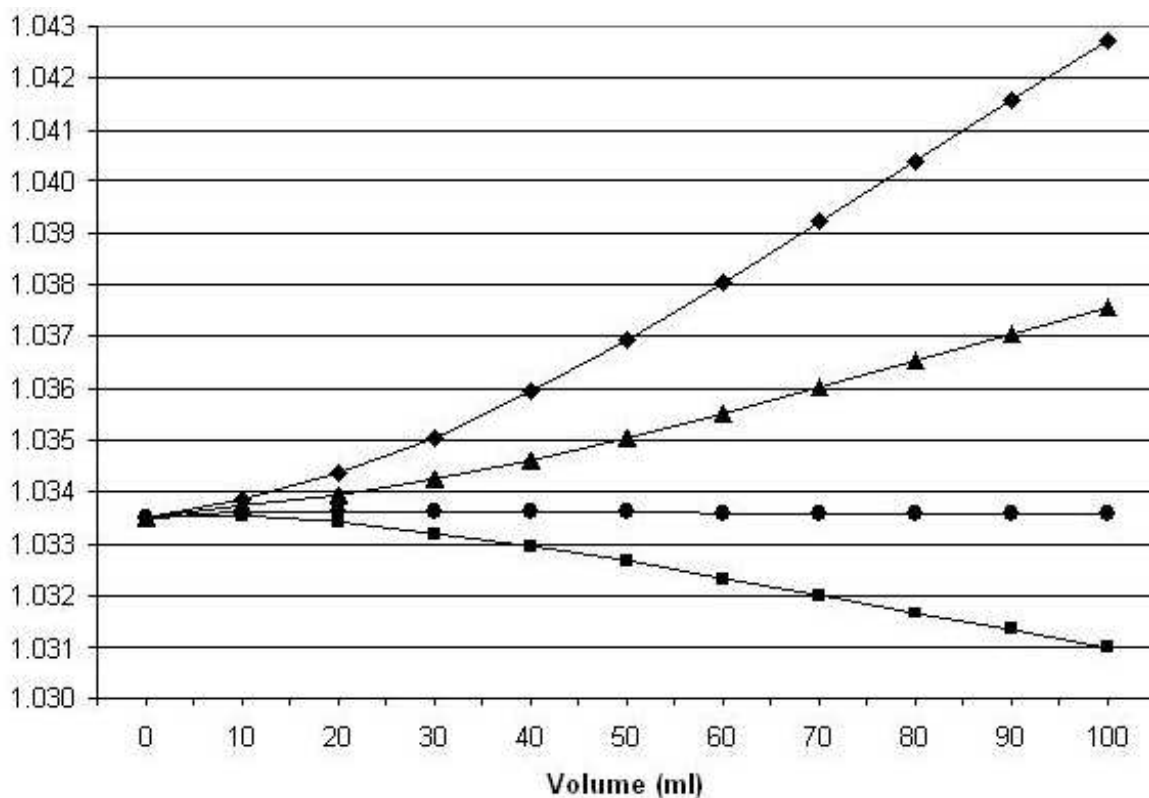


Fig. 3. Computation of the resulting specific gravity after adding a given volume (x axis) of a solute with a density of 1.026 g/mL (square), 1.0335 (round), 1.045 (triangle) and 1.060 (diamond) in hemispheres having a volume of 1041 mL, a weight of 1076 g and a SG of 1.0335 g/mL (mean values of controls). 1.026 g/mL is the density of plasma. 1.060 g/mL is the density of blood. 1.045 g/mL is the density of a solute explaining an increase in the hemispheric volume of 85 mL combined with a raise in SG from 1.0335 up to 1.0367 g/mL (mean value of controls and TBI patients [13]).

### 3. Quantative CT study of non-contused hemispheric areas

Using the methodology of Brainview, weight, volume and eSG of the brain were measured in 15 TBI patients, 3±2 days after the trauma and in 15 controls. For similar age and overall

intracranial volume, TBI patients had an overall brain weight 82g heavier, and hemispheres weight 91g heavier, than controls [13]. Volume of intraventricular and subarachnoid CSF was reduced in TBI patients. In this first series of measurements in 15 TBI patients, eSG of hemispheres, brainstem and cerebellum was significantly higher in TBI patients as compared to controls (all  $P < 0.0001$ ). The increase in eSG was statistically similar in these three anatomical compartments, and in white and grey matter. Furthermore, there was no correlation between the hemispheric eSG and age, natremia at computed tomography time, presence of a traumatic subarachnoid hemorrhage, or presence of intraparenchymal blood [13].

To confirm these results, a second study was performed in a larger cohort of 120 severe TBI patients. The measurement of eSG from the initial CT scan performed in the first 5 hours after trauma was also increased. eSG increase was present in the overall intracranial content and in the non-contused hemispheric areas [14]. The follow up changes in eSG of the overall intracranial content showed that it takes more than ten days to return to a normal value of eSG (**Figure 4**). The same cohort was divided into two groups according to the initial eSG of the non-contused hemispheric areas. The normal specific gravity (NSG) group was defined as patients having an eSG less than 1.96 SD above controls. In the increased specific gravity (ISG) group, patients had an eSG higher than 1.96 SD above controls. Patients in the ISG group had a lower Glasgow coma scale (GCS) and more often had a mydriasis at the scene of the accident, more frequently received osmotherapy in the initial phase, more frequently had an extra-ventricular drainage implanted for ICP monitoring and CSF drainage, more frequently received barbiturates as a second line therapy and more frequently had a CT classified in the third category of the Marshall score. In this cohort, the initial GCS, the velocity, the occurrence of mydriasis at the scene and the use of osmotherapy were

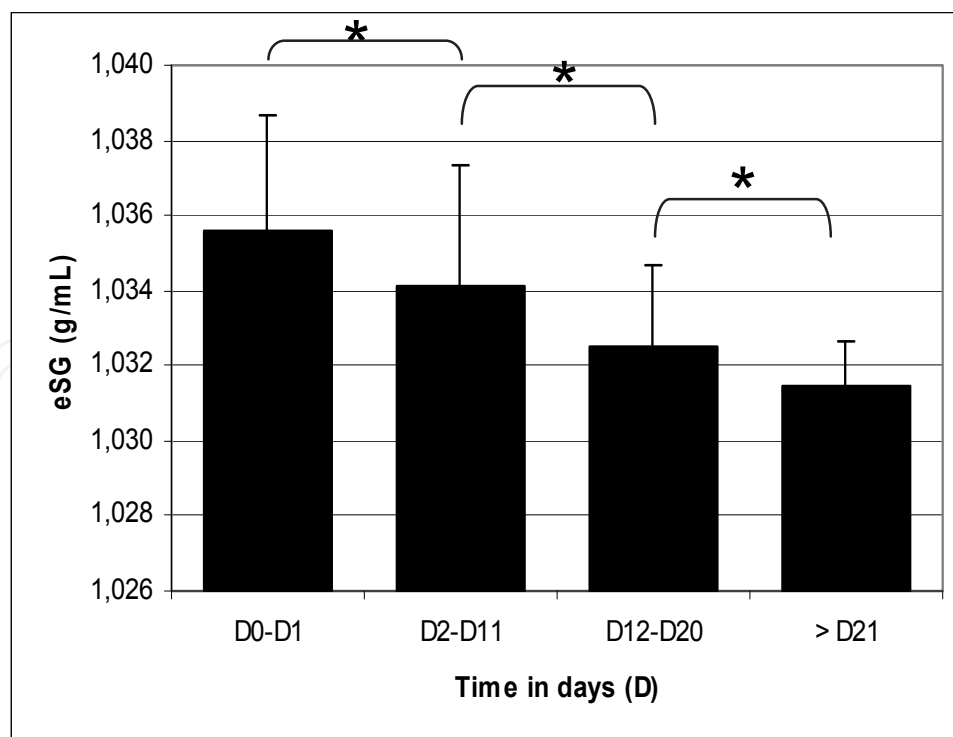


Fig. 4. Follow-up changes in estimated specific gravity (eSG) of the overall intracranial content (n=15) [14].



predictors of outcome at ICU discharge and at one year. eSG of the overall intracranial content or of the non-contused areas were also predictors of outcome (**Table 1**). This study indicated also that eSG was strongly correlated with the intensity of therapeutics to maintain ICP below 20 mmHg. To understand the relationship between eSG and brain swelling, we compared eSG values of TBI patients and high grade subarachnoid haemorrhage (SAH) patients with a similar severity of brain swelling. The increase of eSG was only highlighted in the TBI group [15]; it was not observed in the high grade SAH group. In a fourth study, we compared eSG value of the non-contused hemispheric areas before and after an hypertonic saline bolus administration, and we observed an increase of eSG associated with a decrease in the volume, corresponding to a correct permeability of the BBB in these areas [16].

	ICU discharge		1 yr	
	GOS 1-3 (n = 46)	GOS 4-5 (n = 74)	GOS 1-3 (n = 37)	GOS 4-5 (n = 83)
Age (yr)	37 ± 15	33 ± 14	39 ± 15	33 ± 14
Initial GCS	6 ± 3	8 ± 3†	6 ± 3	8 ± 3†
SAPS 2	50 ± 11	40 ± 9†	51 ± 12	41 ± 10†
Mechanisms				
Assault	6 (13)	5 (7)	6 (16)	5 (6)
Fall	13 (28)	20 (27)	10 (27)	23 (28)
MVA	22 (48)	38 (51)	16 (43)	44 (53)
Pedestrian	5 (11)	11 (15)	5 (14)	11 (13)
Velocity				
Low	15 (32)	7 (10)*	14 (38)	8 (10)†
Mydriasis on scene				
Yes	21 (46)	17 (23)*	17 (46)	21 (25)*
Use of osmotherapy on scene				
Yes	24 (52)	17 (23)*	19 (51)	24 (29)*
eSG overall intracranial content	1.0352 ± 0.0034	1.0338 ± 0.0026*	1.0348 ± 0.0032	1.0341 ± 0.0029
eSG noncontused areas	1.0355 ± 0.0033	1.0340 ± 0.0027*	1.0351 ± 0.0032	1.0343 ± 0.0029

Table 1. Predicting factors of outcome at Intensive Care Unit (ICU) and 1 year later in patients with severe TBI. GOS: Glasgow outcome scale; SAPS: simplified acute physiological score; MVA: motor vehicle accident; \* p<0.01; † p<0.001 [14].

#### 4. Quantitative CT study of contused hemispheric areas

In TBI, osmotherapy such as hypertonic saline has been shown to decrease ICP; therefore it is used in an emergency to control ICP augmentation. From a theoretical point of view, it can be expected that hypertonic saline is effective only in the areas of the brain where the BBB is still functional after trauma. As there seem to be BBB alterations in contusion areas, the patient population that is most likely to respond to hypertonic saline needs to be further defined. A prospective study was designed to evaluate, using quantitative CT scan, the regional effects of hypertonic saline on contused and non-contused brain tissue after TBI [16]. Global and regional brain volumes, weights and eSGs were compared with Brainview before and after hypertonic saline bolus administration in a prospective series of 14 patients 3±2 days after severe TBI. Hypertonic saline presented opposite effects on non-contused and contused hemispheric areas (**Figure 5**). Hypertonic saline decreased the volume of the non-contused hemispheric tissue by 14 ± 9 mL while increasing the eSG by 0.029 ± 0.027 %. The volume of the contused tissue ranged from 3 mL to 157 mL (50 ± 55 mL). Hypertonic saline increased the volume of contused hemispheric tissue by 6 ± 4 mL without any concomitant change in density. The increase of the contusion's volume with hypertonic saline injection

was significantly related to baseline contusion volume expressed in percentage ( $r^2= 0.62, P = 0.01$ , **Figure 6**). Hypertonic saline consistently decreased the weight of the non-contused areas while increasing the eSG, indicating a decrease in water content and, consequently, a functional BBB. On the other hand, hypertonic saline always increased the weight of the contused area. By using quantitative CT scan, this study was able to describe in human TBI the BBB permeability selectively in contused and non-contused areas. The BBB is still permeable in the contused areas 3 days after TBI, and thus hypertonic saline should be given with caution in TBI patients with large contusions after the immediate resuscitation period while the patient is in the ICU.

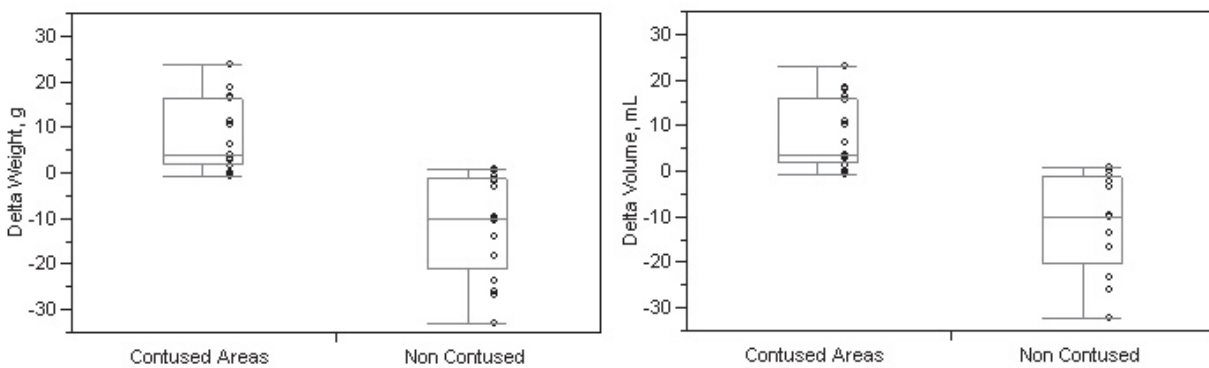


Fig. 5. Mean effect of hypertonic saline on the weight and volume of contused and non-contused areas. The box plots summarize the distribution (25th and 75th quartiles). The line across the middle of the box identifies the median sample value. The whiskers extend from the ends from the sides of the box to the outermost data point that falls within the distances computed [16].

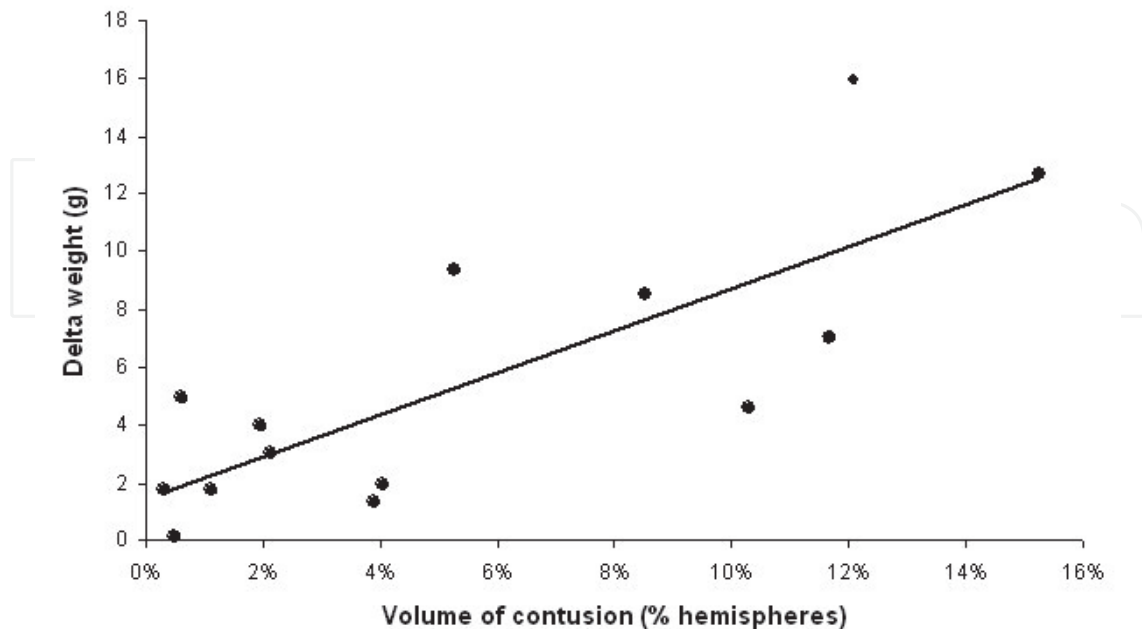


Fig. 6. Change in the weight of contusion according to its initial volume assessed in percentage of the hemispheres [16].



## 5. Interpretation of estimated specific gravity variations

As quantitative brain CT studies have shown, contused and non-contused hemispheric areas show opposite behaviour concerning eSG variation. In the non-contused areas, a large part of the TBI patients presented an early increase of eSG (5 hours after trauma). This increased eSG in TBI was diffuse, present in the white and grey matters, and required more than 10 days to become normal. The value of eSG was also correlated with the therapeutic intensity level in ICU and the outcome at ICU discharge. Contrary to the contused hemispheric areas, the BBB of the non-contused areas was sufficiently semi-permeable to lead to decreased water content after osmotherapy.

The observation of increased eSG in patients with TBI is in opposition with some experimental literature. Studies performed in murine models of head trauma report a decrease in eSG with a rise in the cerebral water content [17, 18]. However, and as in our three different studies [14-16], Bullock et al. observed an increased SG with severe TBI in the same proportion [19]. In another human TBI study, specific gravity determined on small pieces of subcortical tissue using a graduated specific-gravity column was also increased [20].

In our studies, eSG increase was concomitant to a gain of weight. One might argue that the increased eSG could be due exclusively to hyperemia caused by vascular dilation. However, there are some strong experimental [21] and human data against this hypothesis. Recently, Marmarou et al demonstrated, using MRI, that brain oedema is the major fluid component contributing to traumatic brain swelling following TBI in humans [22]. These authors observed a reduction in cerebral blood volume in proportion to cerebral blood flow following severe brain injury. As shown on the abacus presented in **Figure 3**, since blood has an eSG of 1.060 g/mL [23], theoretically an increase in cerebral blood volume of 45 mL would be necessary to increase hemispheric eSG from the mean value of controls to the mean value of TBI patients. Considering that normal cerebral blood volume is about 5% of the overall intracranial volume, this would mean a 65 % increase in cerebral blood volume. Together, the mean change of hemispheric volume that we observed was 85 mL, a value much higher than what could be explained by the change in cerebral blood volume alone.

Another hypothesis to explain eSG increase could be the presence of traumatic macro-haemorrhagic lesions. We first reported that the eSG value was increased in the white matter, excluding the subarachnoid space and thus subarachnoid haemorrhage [13]. Also, eSG values of the total intracranial content and of the non-contused hemispheric areas were similarly elevated [14], a finding that argues against a major role for visible macro-hemorrhagic lesions in eSG elevation.

The last hypothesis to explain eSG increase is the very early BBB disruption already described in different experimental models of TBI [24, 25]. There are many experimental arguments showing that the BBB disruption is early and brief. Time window studies indicate that the barrier seals within a few hours following severe head injury [26]. In the experimental model of Barzo et al, permeability of the BBB returned to control values as soon as 30 min after the head trauma [1]. Tanno et al also observed a pronounced abnormal permeability to IgG and horseradish peroxidase occurring within the first hour after injury that was widespread throughout both hemispheres after a lateral, fluid percussive brain injury in the rat [27]. In that study, maximal permeability occurred at 1 hr after injury. This was confirmed by Baldwin et al [2]. In humans, this early, transient and diffuse opening of the BBB might be directly or indirectly involved in the increase of eSG. Theoretically, a leak of plasma decreases the overall hemispheric eSG since the SG of plasma (between 1.0245

and 1.0285 g/mL) is lower than that of the brain. According to **Figure 3**, the volume added in hemispheres of TBI patients should have a mean density of 1.045 g/mL to explain eSG increase. This value cannot be explained by plasma leakage alone and must also involve cells. Thus, it can be hypothesized that BBB opening occurs immediately after TBI in some patients, leading to extravasation of cells and proteins into the extracellular space. This extravasation could also be associated with leucocyte infiltration and microglia proliferation already described in TBI [27]. Immune cells' proliferation increase tissue specific gravity and they also correlate with brain injuries severity, exacerbating the oedema and leading to prolonged ICP elevation and to higher treatment intensity. Thus, eSG may reflect the early BBB disruption and consequences specifically associated with TBI [15] and may explain why it is correlated with TBI outcome.

Regarding the contused areas, experimental data suggest that BBB remains open for a prolonged period of time after trauma [2, 3]. Our quantitative CT scan study of contused areas suggested that this is true in human TBI, since hypertonic saline consistently increased the weight and volume of contused areas. In the experiment performed by Tanno and al, at 24 hr after injury, abnormal permeability was restricted to the impact site and this area remained permeable up to 72 hr after trauma [28]. Experimentally, Beaumont et al demonstrated using an intravenous bolus of Gd-DTPA with serial T1 MR images that BBB permeability was the greatest in the site of contusion [29]. Gd-DTPA accumulation was greatly enhanced by secondary insult such as hypoxia and hypotension. **Figure 7** represents an illustration of BBB regional and chronological modifications and CT scan observation after TBI in contused and non-contused areas.

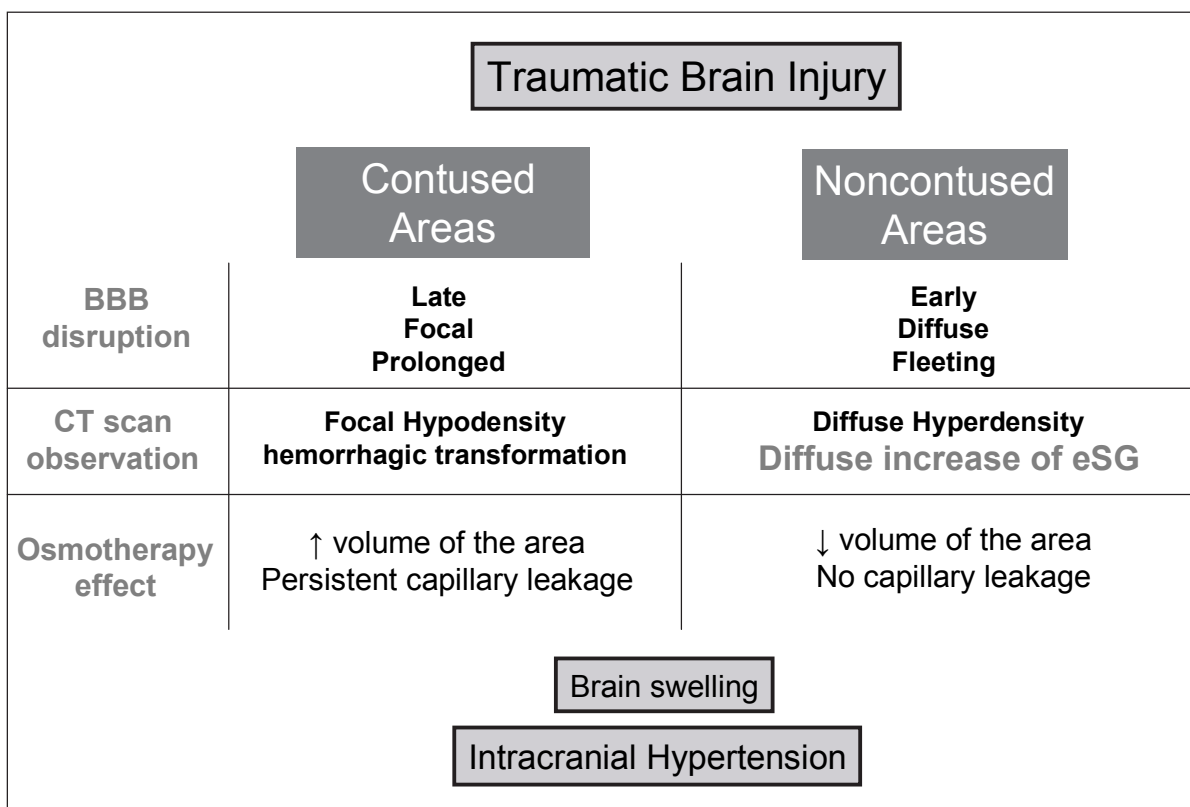


Fig. 7. Illustration of BBB modification after TBI in contused and non-contused areas

## 6. Conclusion

Quantitative CT scan is validated for brain imaging and may help to better characterize the regional differences (contused and non-contused areas) in TBI and the BBB disruption time-course. These studies argue for a distinction between the contused and non-contused area and also for a consideration of the change of the lesions over time.

The clinical usefulness of the automatic determination of eSG in human TBI to characterize the BBB state or to establish outcome information's will have to be addressed in a large prospective study.

## 7. Acknowledgement

This study was supported by the non-profit organizations "Fondation des Gueules Cassées" and the Société Française d'Anesthésie Réanimation Paris, France. None of the authors have any conflicts of interest regarding this work.

## 8. References


- [1] Barzo P, Marmarou A, Fatouros P, Corwin F, Dunbar J.(1996) Magnetic resonance imaging-monitored acute blood-brain barrier changes in experimental traumatic brain injury. *J Neurosurg*;85(6):1113-1121.
- [2] Baldwin SA, Fugaccia I, Brown DR, Brown LV, Scheff SW.(1996) Blood-brain barrier breach following cortical contusion in the rat. *J Neurosurg*;85(3):476-481.
- [3] McLaughlin MR, Marion DW.(1996) Cerebral blood flow and vasoresponsivity within and around cerebral contusions. *J Neurosurg*;85(5):871-876.
- [4] Daneyemez M.(1999) Microangiographic changes following cerebral contusion in rats. *Neuroscience*;92(2):783-790.
- [5] Furuya Y, Hlatky R, Valadka AB, Diaz P, Robertson CS.(2003) Comparison of cerebral blood flow in computed tomographic hypodense areas of the brain in head-injured patients. *Neurosurgery*;52(2):340-345; discussion 345-346.
- [6] Hoelper BM, Soldner F, Chone L, Wallenfang T.(2000) Effect of intracerebral lesions detected in early MRI on outcome after acute brain injury. *Acta Neurochir Suppl*;76:265-267.
- [7] von Oettingen G, Bergholt B, Gyldensted C, Astrup J.(2002) Blood flow and ischemia within traumatic cerebral contusions. *Neurosurgery*;50(4):781-788; discussion 788-790.
- [8] Phelps ME, Gado MH, Hoffman EJ.(1975) Correlation of effective atomic number and electron density with attenuation coefficients measured with polychromatic x rays. *Radiology*;117(3 Pt 1):585-588.
- [9] Mull RT.(1984) Mass estimates by computed tomography: Physical density from CT numbers. *Am J Radiol*;143:1101-1104.
- [10] Puybasset L, Cluzel P, Gusman P, et al.(2000) Regional distribution of gas and tissue in acute respiratory distress syndrome. I. Consequences for lung morphology. CT Scan ARDS Study Group. *Intensive Care Med*;26(7):857-869.
- [11] Rouby JJ, Puybasset L, Cluzel P, et al.(2000) Regional distribution of gas and tissue in acute respiratory distress syndrome. II. Physiological correlations and definition of

- an ARDS Severity Score. CT Scan ARDS Study Group. *Intensive Care Med*;26(8):1046-1056.
- [12] Rouby JJ, Puybasset L, Nieszkowska A, Lu Q.(2003) Acute respiratory distress syndrome: lessons from computed tomography of the whole lung. *Crit Care Med*;31(4 Suppl):S285-295.
- [13] Lescot T, Bonnet MP, Zouaoui A, et al.(2005) A quantitative computed tomography assessment of brain weight, volume, and specific gravity in severe head trauma. *Intensive Care Med*;31(8):1042-1050.
- [14] Degos V, Lescot T, Zouaoui A, et al.(2006) Computed tomography-estimated specific gravity of noncontused brain areas as a marker of severity in human traumatic brain injury. *Anesth Analg*;103(5):1229-1236.
- [15] Degos V, Pereira AR, Lescot T, et al.(2008) Does brain swelling increase estimated specific gravity? *Neurocrit Care*;9(3):338-343.
- [16] Lescot T, Degos V, Zouaoui A, et al.(2006) Opposed effects of hypertonic saline on contusions and noncontused brain tissue in patients with severe traumatic brain injury. *Crit Care Med*;34(12):3029-3033.
- [17] Gardenfors A, Nilsson F, Skagerberg G, Ungerstedt U, Nordstrom CH.(2002) Cerebral physiological and biochemical changes during vasogenic brain oedema induced by intrathecal injection of bacterial lipopolysaccharides in piglets. *Acta Neurochir (Wien)*;144(6):601-608; discussion 608-609.
- [18] Talmor D, Roytblat L, Artru AA, et al.(1998) Phenylephrine-induced hypertension does not improve outcome after closed head trauma in rats. *Anesth Analg*;87(3):574-578.
- [19] Bullock R, Smith R, Favier J, du Trevou M, Blake G.(1985) Brain specific gravity and CT scan density measurements after human head injury. *J Neurosurg*;63(1):64-68.
- [20] Nath F, Galbraith S.(1986) The effect of mannitol on cerebral white matter water content. *J Neurosurg*;65(1):41-43.
- [21] Kita H, Marmarou A.(1994) The cause of acute brain swelling after the closed head injury in rats. *Acta Neurochir Suppl (Wien)*;60:452-455.
- [22] Marmarou A, Portella G, Barzo P, et al.(2000) Distinguishing between cellular and vasogenic edema in head injured patients with focal lesions using magnetic resonance imaging. *Acta Neurochir Suppl*;76:349-351.
- [23] Blacque-Belair A, Mathieu de Fossey B, Fourestier M. *Dictionnaire des constantes biologiques et physiques*. In. 4th edition ed. Paris: Maloine; 1965.
- [24] Habgood MD, Bye N, Dziegielewska KM, et al.(2007) Changes in blood-brain barrier permeability to large and small molecules following traumatic brain injury in mice. *Eur J Neurosci*;25(1):231-238.
- [25] Chen Y, Constantini S, Trembovler V, Weinstock M, Shohami E.(1996) An experimental model of closed head injury in mice: pathophysiology, histopathology, and cognitive deficits. *J Neurotrauma*;13(10):557-568.
- [26] van den Brink WA, Santos BO, Marmarou A, Avezaat CJ.(1994) Quantitative analysis of blood-brain barrier damage in two models of experimental head injury in the rat. *Acta Neurochir Suppl (Wien)*;60:456-458.
- [27] Israelsson C, Wang Y, Kylberg A, Pick CG, Hoffer BJ, Ebendal T: Closed head injury in a mouse model results in molecular changes indicating inflammatory responses. *J Neurotrauma* 2009; 26: 1307-14

- [28] Tanno H, Nockels RP, Pitts LH, Noble LJ.(1992) Breakdown of the blood-brain barrier after fluid percussive brain injury in the rat. Part 1: Distribution and time course of protein extravasation. *J Neurotrauma*;9(1):21-32.
- [29] Beaumont A, Marmarou A, Fatouros P, Corwin F.(2002) Secondary insults worsen blood brain barrier dysfunction assessed by MRI in cerebral contusion. *Acta Neurochir Suppl*;81:217-219.

IntechOpen

IntechOpen



## **Computed Tomography - Special Applications**

Edited by Dr. Luca Saba

ISBN 978-953-307-723-9

Hard cover, 318 pages

**Publisher** InTech

**Published online** 21, November, 2011

**Published in print edition** November, 2011

CT has evolved into an indispensable imaging method in clinical routine. The first generation of CT scanners developed in the 1970s and numerous innovations have improved the utility and application field of the CT, such as the introduction of helical systems that allowed the development of the "volumetric CT" concept. Recently interesting technical, anthropomorphic, forensic and archeological as well as paleontological applications of computed tomography have been developed. These applications further strengthen the method as a generic diagnostic tool for non destructive material testing and three dimensional visualization beyond its medical use.

### **How to reference**

In order to correctly reference this scholarly work, feel free to copy and paste the following:

Vincent Degos, Thomas Lescot and Louis Puybasset (2011). Estimated Specific Gravity with Quantitative CT Scan in Traumatic Brain Injury, *Computed Tomography - Special Applications*, Dr. Luca Saba (Ed.), ISBN: 978-953-307-723-9, InTech, Available from: <http://www.intechopen.com/books/computed-tomography-special-applications/estimated-specific-gravity-with-quantitative-ct-scan-in-traumatic-brain-injury>

**INTECH**  
open science | open minds

### **InTech Europe**

University Campus STeP Ri  
Slavka Krautzeka 83/A  
51000 Rijeka, Croatia  
Phone: +385 (51) 770 447  
Fax: +385 (51) 686 166  
[www.intechopen.com](http://www.intechopen.com)

### **InTech China**

Unit 405, Office Block, Hotel Equatorial Shanghai  
No.65, Yan An Road (West), Shanghai, 200040, China  
中国上海市延安西路65号上海国际贵都大饭店办公楼405单元  
Phone: +86-21-62489820  
Fax: +86-21-62489821



© 2011 The Author(s). Licensee IntechOpen. This is an open access article distributed under the terms of the [Creative Commons Attribution 3.0 License](#), which permits unrestricted use, distribution, and reproduction in any medium, provided the original work is properly cited.

IntechOpen

IntechOpen