

# We are IntechOpen, the world's leading publisher of Open Access books Built by scientists, for scientists

**4,800**

Open access books available

**122,000**

International authors and editors

**135M**

Downloads

Our authors are among the

**154**

Countries delivered to

**TOP 1%**

most cited scientists

**12.2%**

Contributors from top 500 universities



**WEB OF SCIENCE™**

Selection of our books indexed in the Book Citation Index  
in Web of Science™ Core Collection (BKCI)

Interested in publishing with us?  
Contact [book.department@intechopen.com](mailto:book.department@intechopen.com)

Numbers displayed above are based on latest data collected.

For more information visit [www.intechopen.com](http://www.intechopen.com)



## Complex Posterior Urethral Stricture

Ying-Long Sa and Yue-Min Xu

*Department of Urology, Sixth People's Hospital, Urethral Reconstruction Center,  
Jiaotong University of Shanghai, Shanghai 200233,  
China*

### 1. Introduction

Majority of posterior urethral stricture results from pelvic fracture, straddle injuries, or crush injuries. The management of traumatic posterior urethral strictures remains one of the most difficult tasks in urologic practice. In developed countries, agricultural activities have reduced over time and the number of accidents with pelvic fracture due to tractors tipping over has markedly decreased. Work site accidents have also markedly decreased due to the effective prevention of these kinds of accidents, and pedestrian, bicycle, and motorcycle accidents have diminished due to the increased using of cars. But patient conditions are so different from those present in developing countries, such as Egypt, India, Nepal, and China. In those countries, agricultural activities are still quite prevalent, the prevention of accidents on the work site has not dramatically lessened, and bicycles and motorcycles are the most popularly vehicles (1). Moreover, the emergency treatment of patients with PFUDDs in developing and developed countries is quite different. In Italy, emergency treatment for PFUDD was often provided by a urologist in 92.7% of cases, while in india emergency it is done by a general surgeon in 70.1% of cases. Since the majority of those patients have been treated using incorrect maneuvers in some developing country, iatrogenic damage to the urethra may be added (2). In our country, as China is large population, vast territory and uneven development of medical standards, many iatrogenic injurys were caused by inappropriate treatment, complex posterior strictures are not uncommon. Our center received nearly 200 complex posterior urethral strictures every year from all over the country. Hence, this chapter focuses on the management of traumatic posterior urethral injuries typically sustained in association with pelvic fracture.

Complex posterior urethral strictures continue to represent a genuine challenge and they pose one of the most difficult management problems in urology, which represents 5% of all urethral strictures. It is characterized by a stricture gap exceeding 3cm, previous failed repair, associated perineal fistulas, rectourethral fistulas, periurethral cavities, false passages or an open bladder neck. Destruction or rupture of the posterior urethra is caused mainly by forces that occur during traumatic pelvic fracture. This trauma results in partial or complete rupture of the urethra. A complete rupture often results in destruction of the posterior urethra and may damage the sphincteric structures, while always damaging the neurovascular bundles, which results in impotence and incontinence. Due to prior repeated surgery, patients with complex strictures are often found significant scar tissue formation of the urethra. The problems arise from a lack of the healthy elastic tissue needed to reconstruct the urethra.

## 2. Assessment

There are a number of different imaging techniques that may be used in imaging the male urethra. The most widespread methods include retrograde urethrography (RUG) and voiding cystourethrography (VCUG). However, other modalities, such as ultrasound, magnetic resonance imaging (MRI), and computed tomography, have been used as adjuncts. Accurate diagnosis of stricture presence, number, location, and length is of paramount importance in planning appropriate treatment. Although RUG and VCUG are often sufficient for this purpose, ultrasound, CT urethrography and MRI can be useful in certain situations, such as the evaluation of spongiofibrosis, rectourethral fistulas and the periurethral tissues.

### 2.1 Anatomy and symptoms in complex posterior urethral strictures

The posterior urethra consists of a distal membranous segment which, as it traverses the muscular urogenital diaphragm, becomes the narrowest portion of the normal urethra. For a long time, conventional urologic wisdom was that urethral rupture in men occurs at the prostatomembranous junction by a shearing force that avulses the prostatic apex from the urogenital diaphragm. Recent studies suggest that this traditional belief may be a misconception. The urethral sphincter extends from the bladder neck to the perineal membrane (diaphragma urogenitale). The muscular lining and surrounding of the membranous urethra are directly continuous with similar muscle fibers of the prostatic urethra and end abruptly at the perineal membrane. Hence, the weakness may lie in the bulbomembranous junction rather than the prostatomembranous junction at which the posterior urethra is liable to rupture (Fig. 1). More proximally, the prostatic urethra can be seen extending from the bladder neck to the membranous segment. A small longitudinally oriented mound of smooth muscle, the verumontanum, is present along the dorsal aspect of the prostatic urethra and can be seen as a filling defect during fluoroscopic studies. Its distal end marks the proximal aspect of the membranous urethra (3).

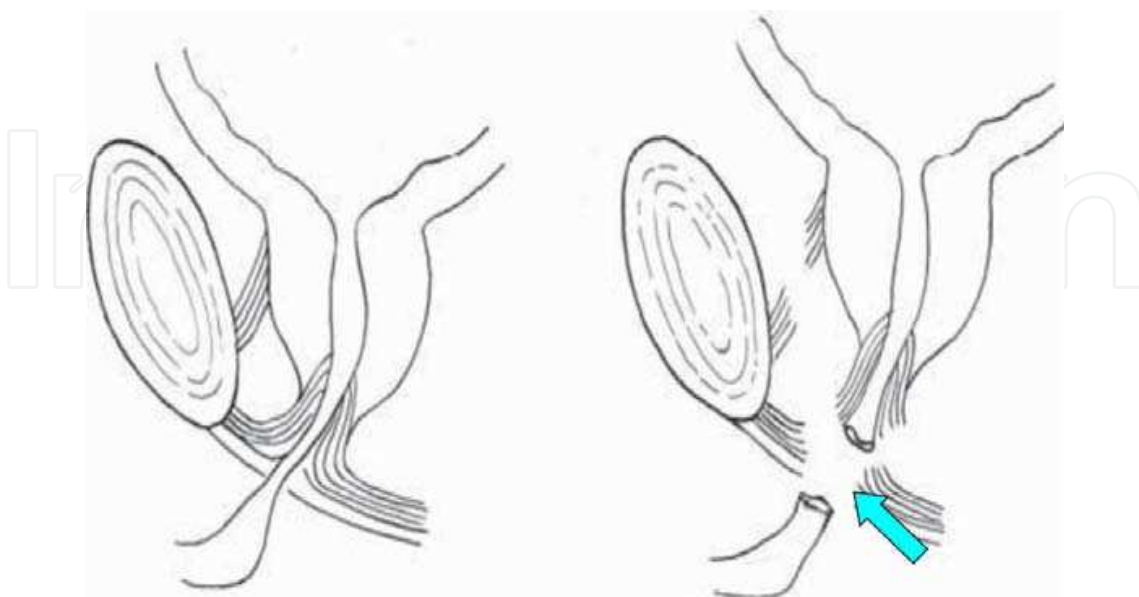


Fig. 1. Bulbomembranous junction (blue arrow), which is the most weakness site in the urethra

Although dysuria is the main symptom in patients with urethral stricture, other special phenomenon can still be noticed in those with complex urethral stricture. In patients with urethrorectal fistula, the most common symptoms are watery stools, urinary incontinence, irritative voiding complaints, and pneumaturia and fecaluria (Fig. 2).

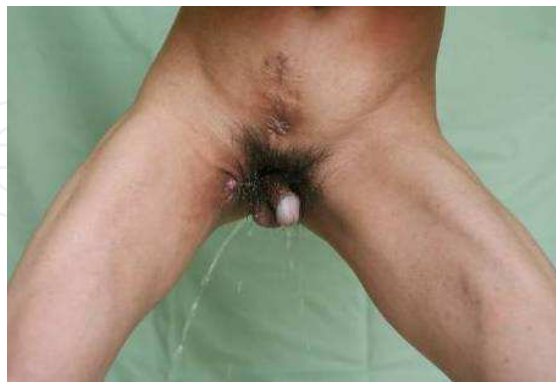

Fig. 2. The main presenting symptom in all cases was urinary leakage through the anus

## 2.2 Retrograde urethrography and voiding cystourethrography

RUG and VCUG are the most commonly used techniques for male urethral imaging. They are readily available and can be safely and relatively quickly performed. The information they provide is usually sufficient to direct patient care. Serious complications are rare, and the procedure is usually well tolerated by patients.

Useful anatomic landmarks to identify the membranous urethra are the inferior margins of the obturator foramina (Fig. 3). It is particularly important to identify the exact location of the membranous urethra, as this is where the urogenital diaphragm and external sphincter are located. In the trauma setting, injury to the external sphincter may affect urinary continence. Although the posterior urethra is opacified during most examinations, its distention is usually poor after contrast passes through the relatively narrow membranous urethra. To improve visualization of the posterior urethra, the patient can be instructed to void during the examination, distending the posterior segment.

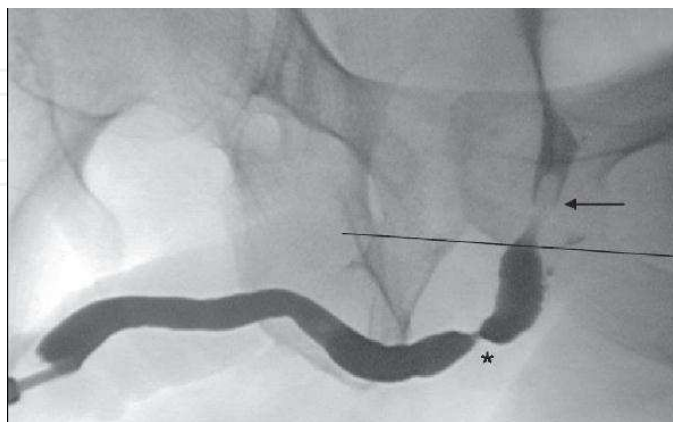


Fig. 3. Bony landmark beneath the inferior margin of the obturator foramina intersects the bulbomembranous junction of the urethra. Arrow head showed a filling defect (verumontanum) in the posterior urethra whose distal end extent to the proximal end of membranous urethra

The VCUG often is performed in conjunction with retrograde urethrography and is especially useful in assessing the posterior urethra. In contrast to the RUG, opening of the bladder neck and distention of the posterior urethra are achieved during VCUG (4).

To perform a VCUG, the bladder is filled with contrast either through the urethra in a retrograde fashion, an indwelling Foley catheter, or a suprapubic catheter. The patient is positioned in much the same way as during a RUG, and instructed to void into a canister. This is more easily accomplished if the fluoroscopy table is tilted upwards so that the patient is in a standing position. Images of the urethra are then obtained during voiding.

It is common to see an apparently long gap between the distal limit of a complete obliteration on ascending (retrograde) urethrogram and the bladder neck on a cystogram (through a suprapubic catheter) (Fig. 4a, b). This doesn't mean that the stricture extends all the way up to the bladder neck, only that the detrusor is unable to contract and open the bladder neck and so allow contrast down to the upper end of the obliteration.

Of course, those technique might be the most common approach for evaluating urethrorectal fistulas (Fig. 5).

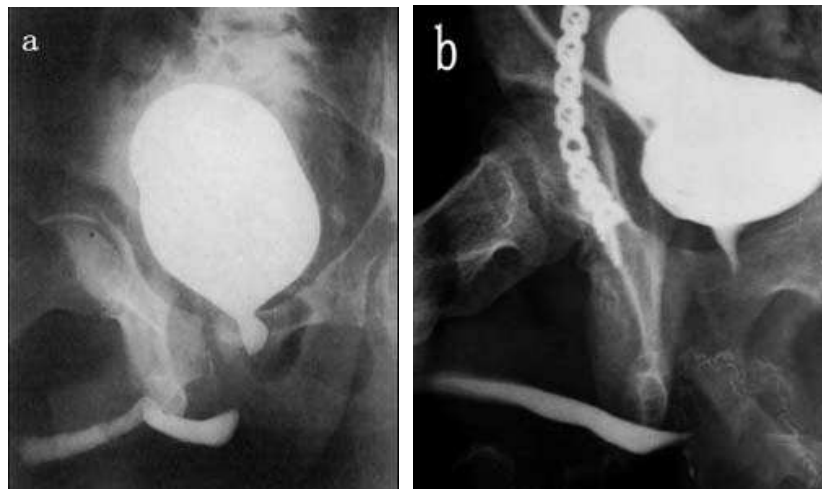


Fig. 4. a,b Combined ascending urethrogram and micturating cystogram helps to define the proximal and distal limits of the stricture

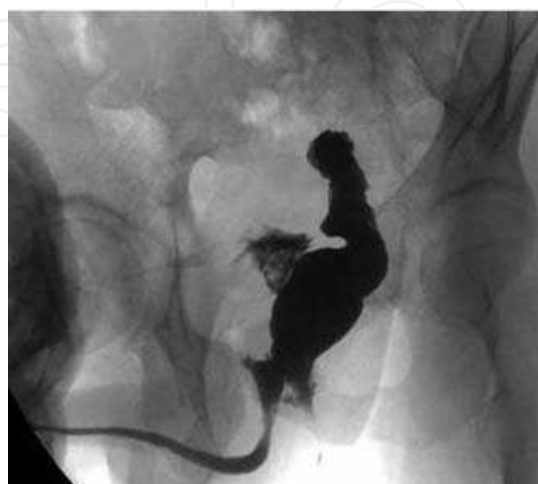


Fig. 5. the preoperative urethrogram showed a connection between urethra and rectum



### 2.3 Sonourethrography

A less frequently used method of imaging the urethra is sonourethrography, which was introduced in the mid-1980s. It is an accurate tool for the diagnosis and characterization of strictures, particularly of the bulbar urethra. Although less frequently performed, transperineal scans may be obtained to image the posterior urethra (Fig. 6).

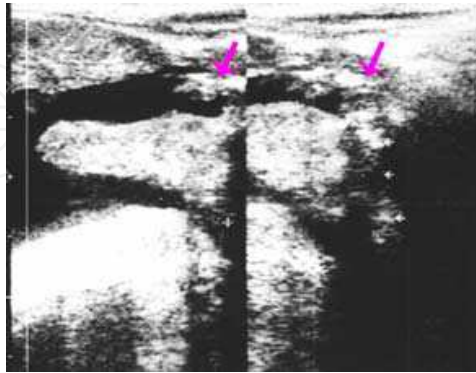


Fig. 6. the site of the posterior urethra stricture from transperineal scans (red arrow)

The advantage of sonourethrography lies in its ability to determine stricture length, especially in the bulbar urethra, with a high degree of accuracy. Because the probe can be oriented along the course of the urethra, there are fewer tendencies to foreshorten the length of a stricture than with RUG. As fibrosis develops, the urethra becomes less distensible compared with the surrounding normal tissues. Areas of periurethral fibrosis appear as hyperechogenicity of the tissues of the spongiosa surrounding the urethra (5). Therefore, sonourethrography may provide information about the soft tissues surrounding the urethra including the degree of spongiofibrosis surrounding the stenotic portions of the lumen (6). The disadvantages of sonourethrography include its limited availability, cost, limited evaluation of the posterior urethra, and the high level of technical expertise necessary to be able to perform and interpret the exam.

### 2.4 Magnetic resonance imaging

MRI is infrequently used in the evaluation of the male urethra. In general, the sagittally oriented images are most useful for evaluation the status of urethra. A phased array coil is placed over the perineum, and a small field of view is used. It is not widely available and is an expensive and technically difficult examination to perform. In most cases, little information is gained beyond that provided by other conventional imaging methods. However, MRI can provide useful information in certain clinical situations, particularly in evaluation the situation of posterior urethral trauma and periurethral soft tissues (Fig. 7). The information about the location of the prostate gland and pelvic hematoma may be obtained as well (7,8).

### 2.5 Voiding CT urethrography

Recently, performing 3-D retrograde CT urethrograms became possible because of the technical developments in multislice CT technology (9). These images allow visualization of the urethra from any angle, without interference caused by the surrounding structures. In urethral stricture disease, the advantage of this technique is becoming more important, especially in documenting the posterior urethra which is located behind bony structures, allowing better visualization of the pathology and better preoperative planning (Fig. 8).

Looking at the 3-D reconstructions of the urethra (or other organs) is almost like performing exploratory.

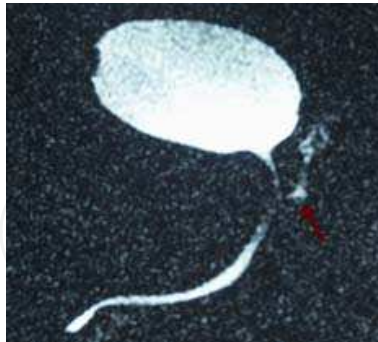

Fig. 7. Sagittal images for evaluation of the posterior urethral stricture and surround tissue

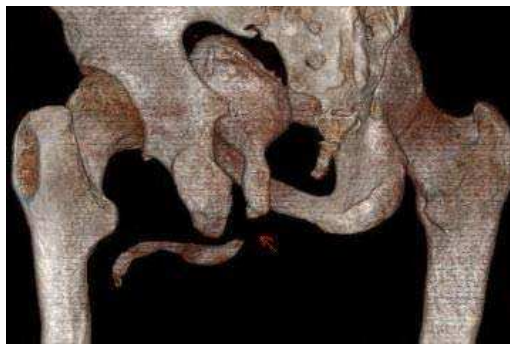

Fig. 8. shows on CTCUG the bladder neck and the proximal part of the prostatic urethra were visualized, the distraction defect (arrow) is about 3cm which was confirmed by the operative finding

CTCUG is also typically fairly sensitive and specific qualitatively for diagnosing a urethrorectal fistula. According to the 3D image obtained from CTCUG, more details about the fistula could be got. It might be the better choice for patients suffered with PFUDDs associated with urethrorectal fistula than other procedures (Fig. 9).

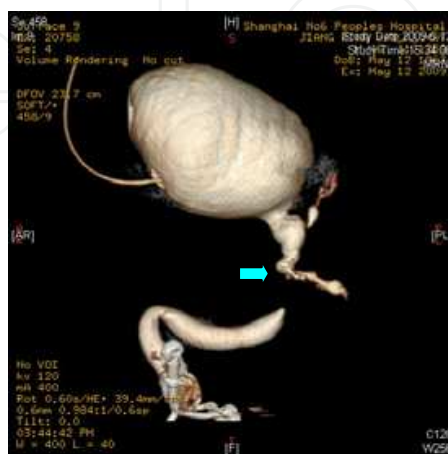


Fig. 9. CTCUG showed a PUDD and urethrorectal fistulas, the defects length is about 4cm, the blue arrow indicate the urethrorectal fistulas

## 2.6 Urethroscopy

A flexible cystoscopy may be helpful in determining the details of an apparently obstructed or incompetent bladder neck and indeed might be helpful in the overall assessment of the urethra on either side of the obstruction. The 7.5Fr flexible cystoscopy was used to perform urethroscopy under lidocaine jelly 2% intraurethral anesthesia. A flexible cystoscopy is advanced through the urethra until the stricture was encountered (Fig. 10a). Then flexible cystoscopy via a suprapubic cystostomy tract was utilized to locate the proximal segment of a complete traumatic disruption (Fig. 10b). Urethral calculi were identified proximal to the stricture only during urethroscopy (Fig. 10c). The ability to negotiate the stricture visually can provide important information regarding length, density, location in relation to the external sphincter, and any associated pathology before treatment is undertaken. Staging of the stricture adequately in these settings may provide more accurate, and more real-time information than RUG, improving the urologist's ability to select definitive therapy for the patient (10).

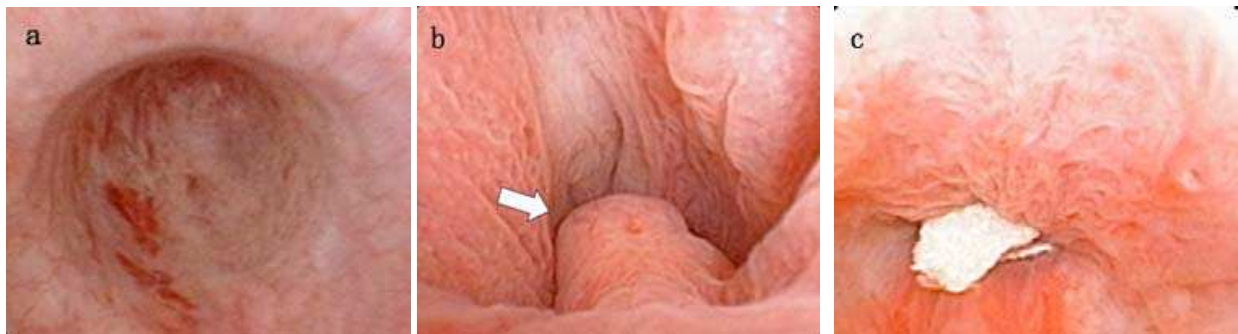


Fig. 10. The image of flexible cystoscopy. a) The obliterative view from the antegrade cystoscopy; b) The obliterative view from the bladder neck, the verumontanum (arrow); c) Calculus can be seen proximal to urethral stricture

Of course, it can be used to determine the degree of damage to the bladder as to capacity and compliance and the location of the fistula in relation to the ureteral orifices and the bladder neck (Fig. 11).

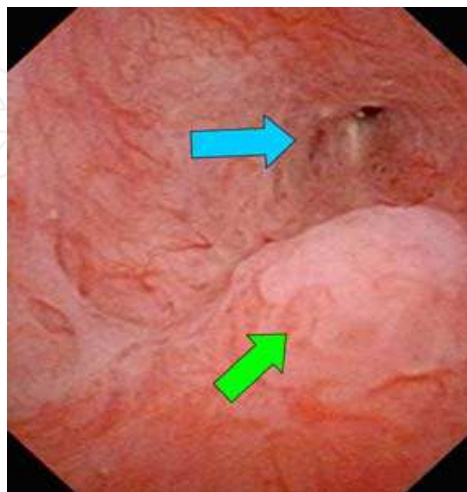


Fig. 11. From the bladder neck, the verumontanum (green arrow) and the urethrorectal fistula (blue arrow) can be seen through a flexible cystoscopy



### 3. Preparation

The patient is admitted on the day of surgery and requires no special preparation. It is sensible to know the patient's blood group, although blood transfusion is rarely necessary except in complicated cases. It is also sensible to have an up to date urine culture, although prophylactic antibiotics will almost always be given with the pre-medication or with the anesthesia. Since the sound will access to the suprapubic area in order to demonstrate the upper level of the obstruction by palpitation during the course of the procedure, a suprapubic drainage should be performed before surgery.

To patients with urethrorectal fistula, the function of the anal and external urethral sphincters, the presence of a concomitant urethral stricture or bladder neck contracture, the visible and palpable health of the tissue adjacent and near the fistula, and the size and location of the fistula should be determined preoperatively. The fecal and urinary proximal diversion should be performed and the patients nutritionally supplemented.

### 4. Procedure

#### 4.1 A simple perineal approach

The patient is positioned in standard lithotomy and prepped and draped to give access to the perineum, genitalia, and suprapubic region. A midline perineal skin incision that is bifurcated posteriorly to improve perineal access is made (Fig. 12a). The bulbo-spongiosus muscle is carefully resected to the bulbar urethra and the bulbar urethra is then separated from the perineal body proximally and from the fused corpora cavernosa more distally by division of the raphe that attaches the corpus spongiosum to the fused corpora on its ventral aspect (Fig. 12b). The site of the obliteration of the urethra is easily defined by passing a Foley catheter up the urethra until it can pass and at this site the urethra is transected (Fig. 13). Scarred tissue and unhealthy urothelium must be dissected off the transected bulbar urethra until the proximal cut end of the bulbar urethra is healthy (11). Occasionally, there is still a lumen through the site of the transection to the healthy posterior urethra above but this is rare. More commonly the posterior urethra above the site of the fibrosis and obliteration is best defined by passing a metal sound through the suprapubic catheter track to help identify the prostatic urethra by palpation through the scar tissue. The verumontanum

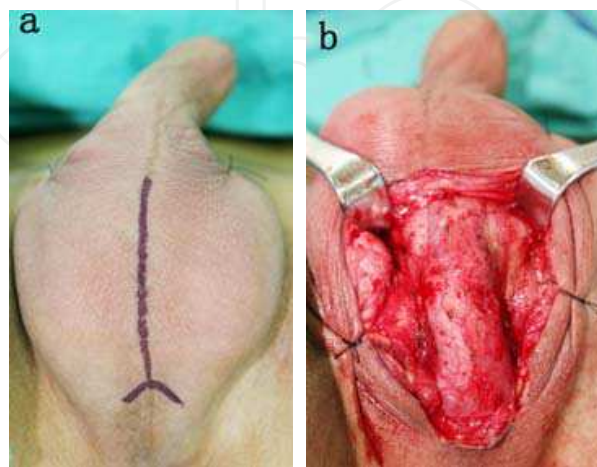


Fig. 12. a) the inverted Y shape incision line in the perineal; b) Exposure and mobilization of the bulbar urethra from within the bulbospongiosus muscle

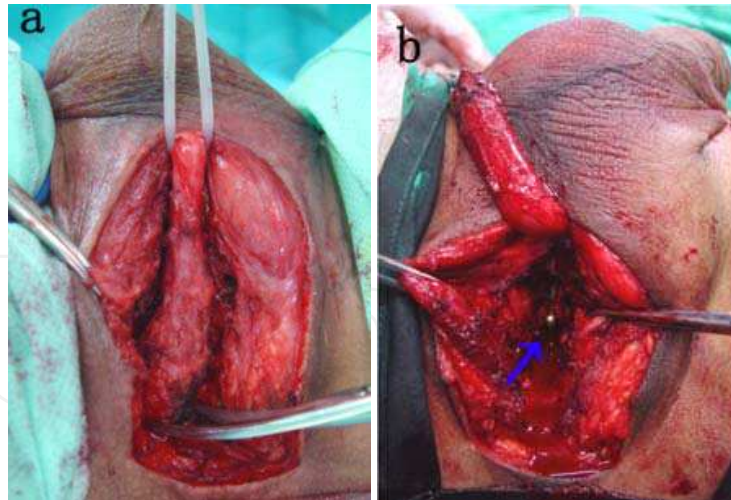


Fig. 13. a) The urethra is then transected through the site of obliteration to free it. b) The sound (blue arrow) indicate the distal end of posterior urethra after transected

is an important landmark for identifying the prostatic urethra and in case of any doubt cystoscopy was performed (12). It is usually then possible to cut through, strictly in the midline, onto the tip of the urethral sound to identify the prostatic urethra and then spatulate it open using six or eight 4/0 Vicryl sutures, which will subsequently be used for the anastomosis. We usually use eight Vicryl sutures at 1:2-, 4:5-, 7: 8-, 10 and 11-o'clock positions. We find that eight sutures is better than six sutures to create a watertight anastomosis. 10 or 12 sutures described by literatures are not suitable for complex posterior urethral cases. It is neither effective nor operational in most cases (Fig. 14).

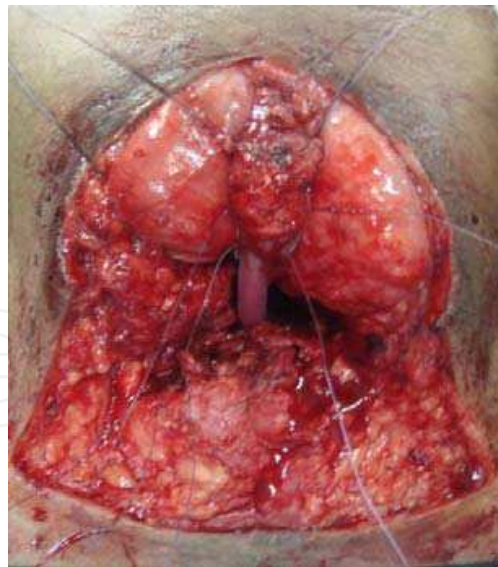


Fig. 14. Eight 4-O polyglactin sutures can then be placed through the full thickness of the proximal urethra at 1:2-, 4:5-, 7:8-, 10 and 11-o'clock positions

The emergency treatment of patients with PFUDD in developing countries is not currently codified and most of these patients have been treated using incorrect procedures that add iatrogenic damage to the trauma. Sometimes careless and repeated urethral dilatation leads to formation of a urethral false passage(s), resulting in infection and incontinence (Fig. 15).

For those patients with post-traumatic posterior urethral strictures compliance with urethral false passage, it also can be effectively treated by trans-perineal approach. It is important that the urethral false passage and the real urethra should be distinguished during surgery (13). When the catheterization procedure is carried out crudely, urethral false passage is likely to form and can be subsequently mistaken for the real urethra. In our country, emergency treatment was carried out at the local primary hospital and included catheterization. Most of patients were treated for urethral realignment and the posterior urethral scar tissue electrovaporization and electroresection procedure were performed. We discovered a lot of urethral false passage formation from bladder to urinary meatus (Fig. 16).

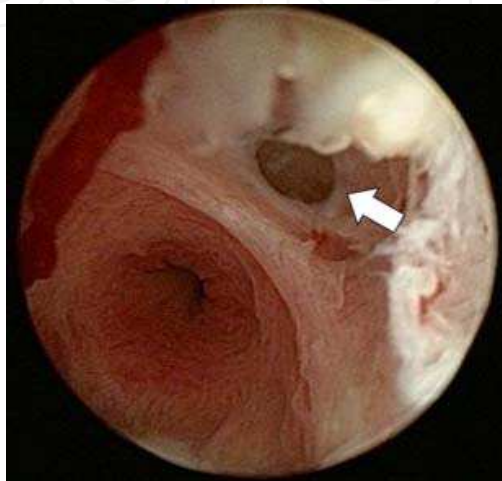


Fig. 15. Careless and repeated urethral dilatation leads to formation of a urethral false passage (arrow), a strictured area with a fibrous-appearing band

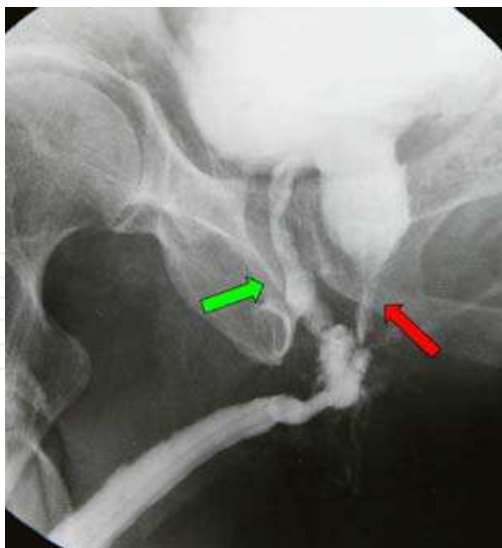


Fig. 16. Pre-operative urography for the patient. The passage marked with a green arrow is the false passage from bladder to urinary meatus. The passage marked with a red arrow is the real urethra

In the circumstances of suspectful a false passage, we usually open the bladder and then put the finger in to the bladder neck for identifying the right path or a flexible cystoscopy was



used to observe the verumontanum. At this point the verumontanum should be clearly visible within the posterior urethra, which is a useful point for distinguishing the urethra proper from a false passage. The false passage was resected and the stub was ligated. Meanwhile, we resected the scar tissue of the real urethra and undertook end-to-end anastomosis.

#### 4.2 A transperineal inferior pubectomy approach

More usually there is a longer defect and, therefore, some tension between the two ends when they are drawn together for anastomosis in this way. If this is the case, then a transperineal inferior pubectomy will be necessary to reduce the length of the defect and produce a tension-free anastomosis (14-16). This manoeuvre is mainly designed to reduce the natural curve of the bulbar urethra in order to achieve a tension-free anastomosis.

The first step is separation of the fused corpora cavernosa as they lie over the pubic symphysis such that the bulbar urethra comes to lie between them (Fig. 17). The corporal bodies are separated, beginning at the level of the crus and progressing distally along a relatively avascular midline plane for approximately 4 to 5 cm. Further distal separation is usually not possible due to the more intimate connection between the corporal bodies. This separation allows the urethra to lie between the separated corporal bodies, thereby shortening the distance to the anastomosis (17).

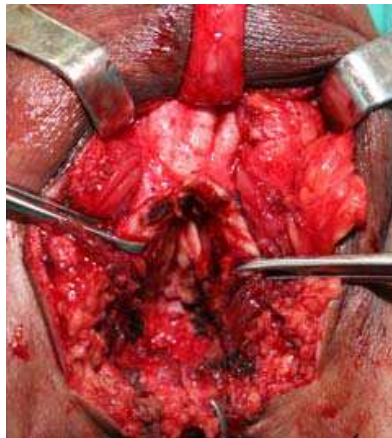


Fig. 17. Separation of the fused corpora cavernosa as they lie over the pubic symphysis

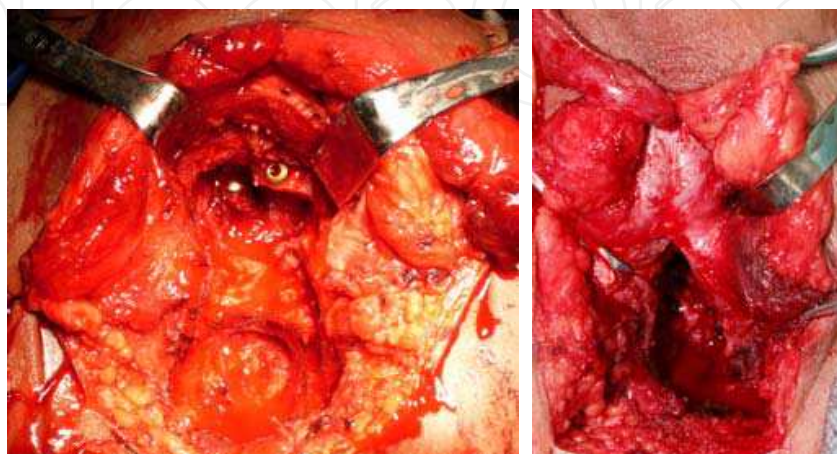


Fig. 18. Wedge resection of the inferior part of the pubic symphysis was done

The next step is removal of the inferior margin of the pubic symphysis (Fig. 18). If tension still exists, the dorsal penile vessels are displaced laterally or ligated and a wedge of bone is excised from the inferior aspect of the pubis using an osteotome and bone rongeurs, the wedge being large enough to allow the urethra be redirected cephalad to lie within the groove, resulting in an additional 1 to 2 cm of apparent urethral length. This maneuver also exposes the anteriorly displaced prostate, thereby facilitating the anastomosis.

The final maneuver is rerouting the urethra around the corporal body through a bony defect created by further pubectomy, shortening the distance to anastomosis by up to an additional 2 cm. For this maneuver one corporal body is circumferentially mobilized at or just proximal to the suspensory ligament. The dissection is carried out away from the surface of the corporal body to avoid injury to neurovascular structures (Fig. 19a). Care must be taken during opening of the dorsal aspect to avoid damage to the deep dorsal vein of the penis in the midline and, particularly, to the dorsal artery and nerve of the penis on either side. This maneuver does not cause significant penile torsion or chordee (Fig. 19b).

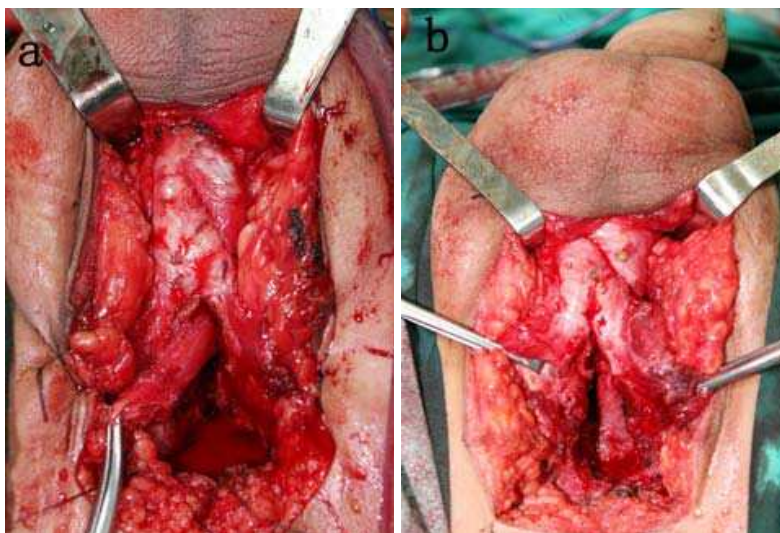


Fig. 19. a) reroute the distal end of urethra. b) the anastomosed urethra after reroute

By combining the two techniques, sectioning the cavernosa septum and chiseling off the lower margin of the pubis, the operative field could be clearly exposed and the path of the anastomotic urethra could be shortened. Then, the penile urethra can hide in the gap, which shortens the distance between the anterior and posterior urethra by about 2-3 cm. Therefore, tension-free anastomosis can be achieved, and postoperative penile shortening caused by excessive dissociation of the distal urethra can be prevented.

From 1990 to 2010, we have used this technique to treat nearly 2200 patients with complex posterior urethral strictures, ranging from 3.5 to 5.0 cm in length. Based on our experience, in cases of a high-lying prostate, the anastomosis may remain under tension. To address this, the proximal corporeal bodies can be separated at the level of the crus and dissected along the relatively avascular midline plane for about 4 to 5 cm. This technique can achieve about 1 to 2 cm of apparent urethral lengthening. We found it was not necessary to re-route the urethra around the corporeal body to provide additional length in those patients.

Having completed the anastomosis, a 16Fr or 18Fr silicone Foley urethral catheter is passed up into the bladder, and suprapubic catheter should be replaced as well. The wound is then closed in layers taking care to obliterate all the dead space as far as possible to reduce the



risk of hematoma formation. A wound drain should be left in place for 2 or 3 days to prevent the accumulation of any hematoma.

For treating the posterior urethral stricture associated with rectourethral fistulas, inferior pubectomy approach can be selected based on the complexity and etiology of the lesion (18,19). Young and Stone in 1917 first used a perineal exposure with a wide dissection, separating the rectum from the urethra and prostate, dividing the fistula after extensive rectal mobilization and performing rectal excision followed by a colocolic anastomosis. Goodwin et al modified this procedure in 1958 by using an anterior perineal space dissection, closing the defects and interposing a levator ani muscle successfully in patients with acquired rectourethral fistulas. Subsequent interest in the use of the interposition flaps has further enhanced the successful outcome of patients managed by the perineal approach and should be routinely employed in the complex cases where a wide separation is required and sufficiently large muscle flaps are interposed (20-22). The combined abdomino-perineal approach provides good exposure and was most suitable for refractory, complex, posterior, long-segment urethral strictures and large rectourethral fistulas located far from the anus. This technique may work well in cases where there is excessive perineal scar tissue or for patients for whom a prior perineal procedure was unsuccessful. However, we do not recommend this technique as the first-line approach in these patients, especially in pediatric cases. The transperineal-inferior pubic approach, which fully exposes the space behind the pubis and does not lead to pelvic instability, has a lower incidence of postoperative complications. Therefore, it may be appropriate as a first-line procedure in those patients (23).

The procedure is performed with the patient in a moderately dorsal lithotomy position utilizing an inverted 'U' shaped incision from mid-perineum to ischial tuberosities. A midline dissection above the external sphincter is maintained without a lateral or posterior extension separating the rectum, prostate, and subvesical surface up to the peritoneum. The dissection was done at the recto-urethral septum up to a level at least 3 cm above the fistula (Fig. 20). This type of dissection will prevent injury to the innervation of the rectum, anal sphincter, and penile corpora, thereby preserving potency and urinary continence, and should also be used in the smaller fistulas of surgical or traumatic origin. The fistula core was dissected to the rectum and excised (Fig. 21). These defects can be repaired by primary closure with direct approximation of the urethral side with one layer of interrupted 4-0 Monocryl (Fig. 22).

The key to success in this repair is interposition of a viable tissue flap between rectum and urethra. Here, we suggested using gracilis flap in this kind of operation. It has been widely used for the reconstruction of vaginal, vulvoperineal or inguinal defects to fill perineal skin defects created by a variety of surgical procedures, such as in the treatment of Paget's disease and penile and urethral cancer (24,25). The advantage of gracilis muscle is that the flap is close to the defect and good blood supply from the branches of the profunda femoralis artery. The complication rate after the muscle transposition is generally minimal.

The gracilis muscle was mobilized and released from its insertions (Fig. 23). The flap was rotated and the distal end was brought to the perineal area through a subcutaneous tunnel (Fig. 24). The muscle was laid between the rectum and the urethra and was fixed at least 3 cm above the fistula site (Fig. 25). All patients underwent fecal diversion, ileostomy or colostomy. Stomal closure was performed after voiding cystourethrography or evaluation under anesthesia and endoscopic demonstration of a healed fistula. Patient outcomes were assessed after surgical repair.

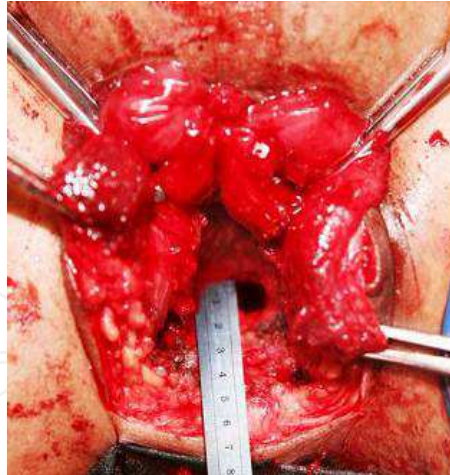


Fig. 20. The dissection is undertaken to divide the fistula tract and reach cephalad to noninflamed tissue

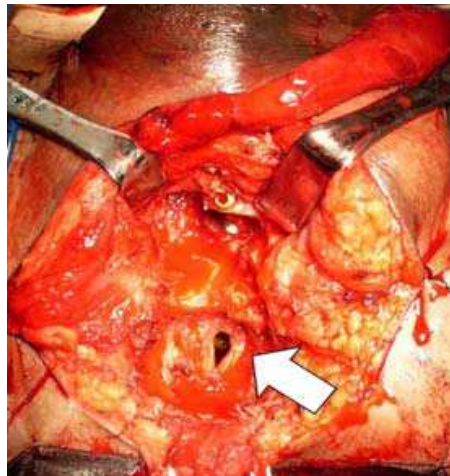


Fig. 21. Intra-operative view after perineal incision and dissection at the recto-urethral septum with a rectourethral fistula (arrow)

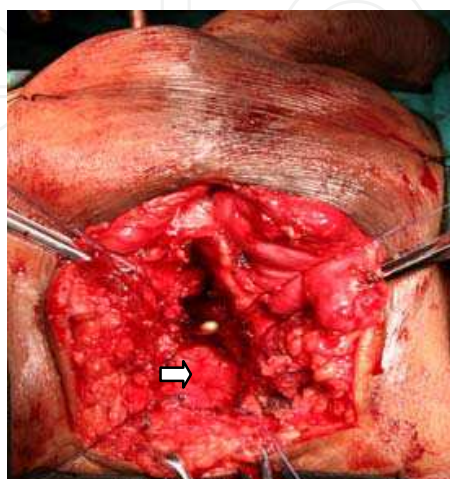


Fig. 22. Closure of the rectal portion of the fistula was performed (arrow)

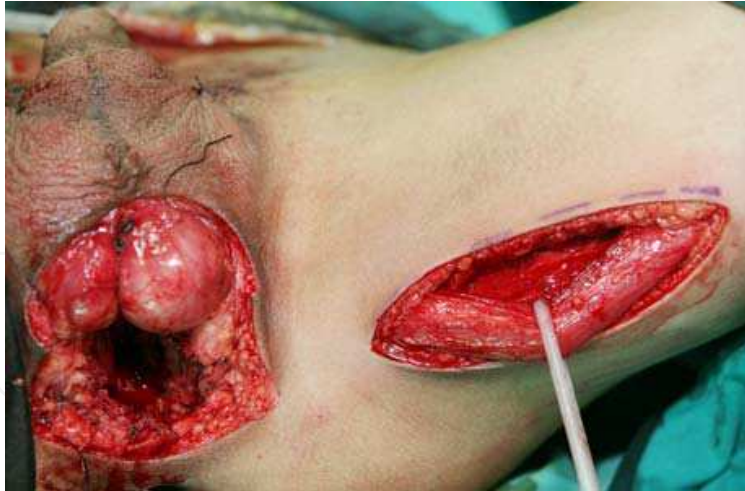


Fig. 23. Release and mobilisation of the gracilis muscle

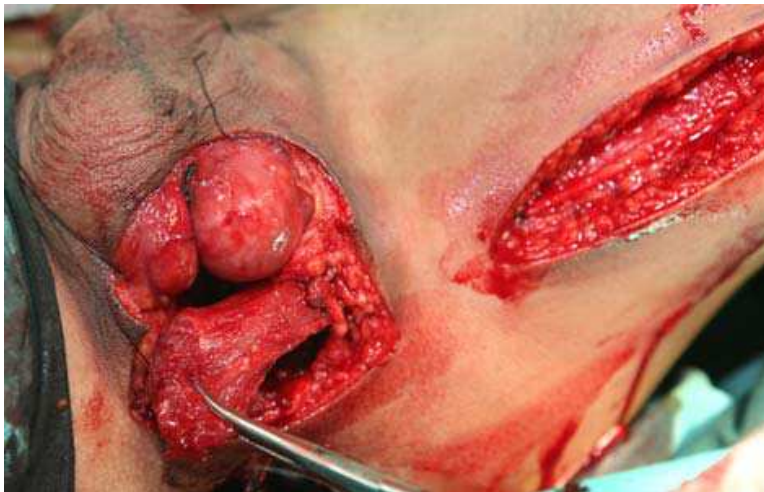


Fig. 24. The flap was rotated and the distal end was brought to the perineal area through a subcutaneous tunnel

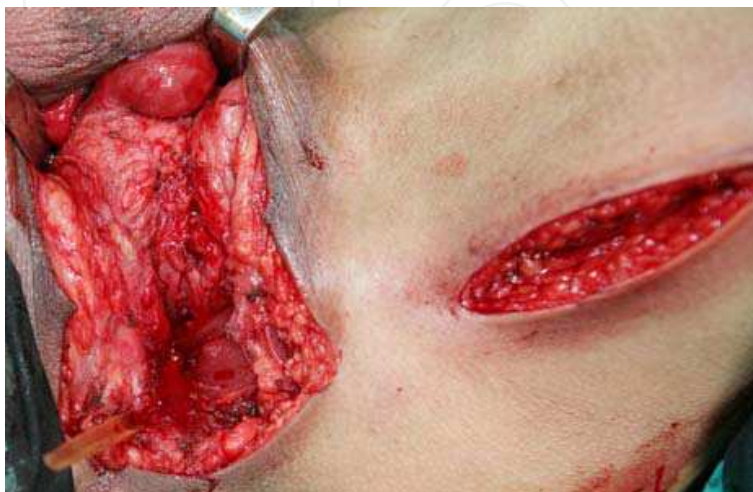

Fig. 25. Inset of the rotated flap between the rectum and the urethra



We emphasize the need for bowel diversion before attempting reconstruction. Moreover, important technical features include meticulous hemostasis, tension-free primary repair of the rectum after dissection and mobilization to a level of at least 3 cm above the fistula site and a tension-free transposition of the well-vascularized gracilis muscle. The results of our study have shown that recto-urethral fistula closure using the perineal approach with pedicle gracilis muscle interposition has a low morbidity and a high success rate. Nevertheless, the gracilis muscle interposition is an option for treatment of these complex fistulas (26).

#### **4.3 The combined transpubic- perineal approach**

The overwhelming majority of PFUDDs can be repaired successfully through the transperineal or inferior pubectomy approach as noted above, as defects as long as 10cm are amenable to repair. Only occasionally is it necessary to use a combined transpubic with perineal approach when there is a chronic periurethral cavity, bladder-neck injury, or some other coincidental problem which requires that approach or otherwise when the prostatic urethra is inaccessible from below, or in a severe bulbar crush injury leaving only the distal bulbar urethra intact or those patients who have failed a prior repair (16).

The combined transpubic- perineal approach involves both perineal and retropubic exposure of the urethra and prostate with removal of a segment of pubic bone to facilitate exposure. It was usually suggested in pediatric patients due to their narrow and deep pelvic outlet along with the abdominal location of bladder, which often makes a perineal approach suboptimal for adequate exposure (27,28). In some cases, their bladder neck might be non-functional either as a result of unrecognized or unrepaired injury at the time of pelvic fracture, prior resection or prostatectomy, or simply because of fixation in the periprostatic retropubic scar. In such cases, a transpubic- perineal approach has been suggested (17,29). Furthermore, the periurethral cavity formed from a liquefied pelvic hematoma can also be treated through this approach (30).

This approach was first performed by Pierce in 1962 and his approach allowed excellent visualization of the vesical neck, entire posterior urethra and the urogenital diaphragm. Waterhouse et al utilized this approach with a few modifications. He described excising an entire anterior wedge of pubis using a Gigli saw (31,32). Inferior wedge pubectomy will have been completed perineally, and this—combined with retropubic bone removal—will provide wide anterior access, which facilitates anastomosis and access to the pelvic floor to manage the complicating features that were the indication for this approach (33). We think that entire wedge pubectomy or inferior wedge pubectomy should be selected based on the complexity of local condition, such as surrounding scar tissue, the degree of exposure. Their technique combined exposing the periprostatic space by pubectomy followed by anterior urethral mobilization by a perineal approach (34,35).

In details, the patient was placed in standard lithotomy position. The thighs were abducted and the knees flexed providing access to the perineum. A midline subumbilical abdominal incision was made and carried well down to the root of the penis (Fig. 26a). The retropubic space and a plane must be developed between the symphysis and the underlying prostate and bladder. A Gigli saw is then passed on a right angle clamp from the retropubic space below the lower border of the pubic. The Gigli saw was pulled well laterally and the pubic was sawed through. A similar procedure was then performed on the other side and the wedge of the bone was removed approximately 2 cm on each side of the symphysis pubic (Fig. 26b,c). Identification of the proximal urethra beneath the fibrous tissue was done using a boogie passed through the bladder neck under direct vision or a finger can be used to help direct the retropubic dissection and avoid damage the bladder neck (36).

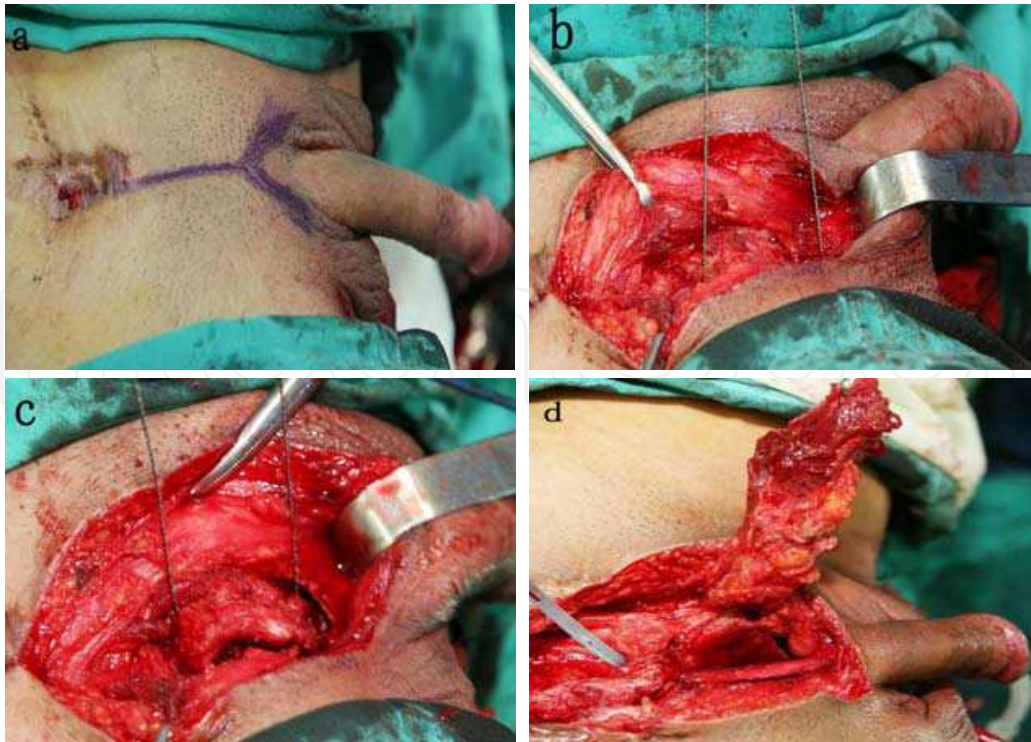


Fig. 26. Process of combined abdominal-perineal approach for urethroplasty was showed. a) a vertical midline incision was made and carried well down to the root of the penis b) a Gigli saw is then passed on a right angle clamp from the retropubic space c) a Gigli saw is then passed on a left angle clamp from the retropubic space. d) removal of a wedge of pubic bone and allowed a simultaneous perineal approach for distal urethral mobilization end-to-end urethroplasty was performed

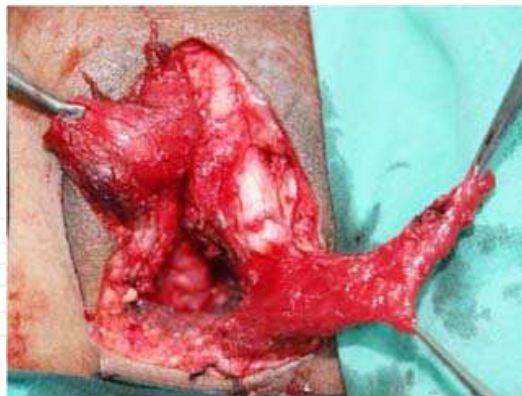

Fig. 27. The dartos muscle from the scrotum was used to supports urethral anastomosis

A midline perineal incision was also made to expose the anterior urethra. The distal urethra was mobilized distally up to glans and proximally up to triangular ligament and was transected at this level. The mobilized urethra was passed through an incision made in intercrural septum. End-to-end urethroplasty was performed over a 16Fr silicon catheter using six or eight interrupted 4-0 absorbable sutures (Fig. 26d). The dead space around the anastomosis needs to be obliterated by various methods including: mobilization of the cremaster fascia or dartos muscle from the scrotum; pedicled omentum; sliding a pedicled



gracilis muscle belly from the medial aspect of the thigh, or by vertical rectus abdominis muscle flap (Fig. 27). A surrapubic catheter was inserted through the bladder dome. Retropubic space suction drain was then placed.

## 5. Postoperative follow-up

A urethrogram with catheter should be arranged in each patients 2 weeks after operation. All patients should be followed up for 6 months or so later. And urinary flowmetry ,the ascending urethrogram, micturating cystogram will be repeated during the follow-up .

## 6. Complications

### 6.1 Failure of repair

The most common presentation of a recurrent stricture is that the patient runs into trouble within hours or days of having their postoperative catheter removed. This is because such problems are as a result of ischemia of the anastomosis because the blood supply is insufficient to sustain adequate vascularity of the anastomosis, fibrotic tissue was left behind. More commonly, tension anastomosis during operation may lead to the recurrence. If the procedure was performed technically competently then almost always the patients who show this early failure also have complete erectile dysfunction supporting the concept that this recurrent stricture is vasculogenic and ischaemic in origin. In such cases, the suprapubic catheter must be replaced and the patient must wait another three months and the procedure is repeated.

### 6.2 Erectile dysfunction and incontinence


In many patients with complex posterior strictures, stricture resection and bulboprostic anastomosis yielded good results of operation. Since those strictures are usually the result of severe pelvic trauma in which the urethra is disrupted from the pelvic floor, and during which neurovascular bundles are torn, 30%-50% of the patients already have erectile dysfunction prior to the bulboprostic anastomosis. Complication of erectile dysfunction is generally related to the original injury rather than the procedure itself. Our previous study showed that the neurogenic factors may be the principal etiology of organic impotence associated with urethral injury. The type of pelvic fracture, in particular fractures associated with the pubic diastasis, is particularly important. The location of stricture is also a risk factor for loss of potency (37,38). On the other hand, the erectile function will recovery in some patients within 6 months postoperatively, which is due to the decompression of erectile nerve bundles. Therefore, intimate following up after operation is absolutely necessary in those patient. Further treatment of impotence is only considered in those patients suffered with erectile dysfunction for a long period of time after the urethroplasty. There may also be postoperative incontinence due to surgery-related damage to the intrinsic sphincter organ when the bladder neck is incompetent, when the bladder neck is involved in the primary trauma. This complication can be avoided by a carefully assessment before surgery.

## 7. References

- [1] Barbagli G. History and evolution of transpubic urethroplasty: a lesson for young urologists in training. *Eur Urol* 2007; 52: 1290-1292

- [2] Kulkarni SB, Barbagli G, Kulkarni JS, Romano G, Lazzeri M. Posterior urethral stricture after pelvic fracture urethral distraction defects in developing and developed countries, and choice of surgical technique. *J Urol*. 2010; 183:1049-1054.
- [3] Pavlica P, Barozzi L, Menchi I. Imaging of male urethra. *Eur Radiol* 2003; 13:1583-1596.
- [4] Kawashima A, Sandler CM, Wasserman NF, LeRoy AJ, King BF Jr, Goldman SM. Imaging of urethral disease: a pictorial review. *Radiographics* 2004; 24 Suppl 1:S195-216.
- [5] Choudhary S, Singh P, Sundar E, Kumar S, Sahai A. A comparison of sonourethrography and retrograde urethrography in evaluation of anterior urethral strictures. *Clin Radiol* 2004; 59:736-742.
- [6] Mitterberger M, Christian G, Pinggera GM, Bartsch G, Strasser H, Pallwein L, et al. Gray scale and color Doppler sonography with extended field of view technique for the diagnostic evaluation of anterior urethral strictures. *J Urol* 2007; 177:992-996; discussion 997.
- [7] Gallentine ML, Morey AF. Imaging of the male urethra for stricture disease. *Urol Clin North Am* 2002; 29:361-372.
- [8] Ryu J, Kim B. MR imaging of the male and female urethra. *Radiographics* 2001; 21:1169-1185.
- [9] El-Kassaby AW, Osman T, Abdel-Aal A, Sadek M, Nayef N. Dynamic three-dimensional spiral computed tomographic cysto-urethrography: a novel technique for evaluating post-traumatic posterior urethral defects. *BJU Int*. 2003; 92:993-996
- [10] Figueroa JC, Hoening DM. Use of 7.5F flexible pediatric cystoscope in the staging and management of urethral stricture disease. *Jour Endourology*. 2004; 18:119-121.
- [11] Mundy AR. Anastomotic urethroplasty. *BJU Int* 2005; 96:921-944.
- [12] Mundy AR. Transperineal bulbo-prostatic anastomotic urethroplasty. *World J Urol* 1998; 16: 164-170.
- [13] Singla M, Jha MS, Muruganandam K, Srivastava A, Ansari MS, Mandhani A, et al. Posttraumatic posterior urethral strictures in children--management and intermediate-term follow-up in tertiary care center. *Urology* 2008, 72:540-543; discussion 543-544
- [14] Fu Q, Zhang J, Sa YL, Jin SB, Xu YM. Transperineal bulboprostatic anastomosis in patients with simple traumatic posterior urethral strictures: A retrospective study from a referral urethral center. *Urology*, 2009; 74(5):1132-6.
- [15] Fu Q, Xu YM, Zhang J, Jin SB, Sa YL. Use of anastomotic urethroplasty with partial pubectomy for posterior urethral obliteration injuries: 10 years experience. *World J Urol* 2009; 27:695-699.
- [16] Andrich, DE, Mundy AR. What is the Best Technique for Urethroplasty? *Eur Urol* 2008; 54:1031-1041
- [17] Webster GD, Guralnick ML. Reconstruction of posterior urethral disruption. *Urol Clin North Am* 2002; 29:429-441.
- [18] Zmora O, Potenti FM, Wexner SD, Pikarsky AJ, Efron JE, Noguerras JJ, et al. Gracilis muscle transposition for iatrogenic rectourethral fistula. *Ann Surg* 2003; 237:483-487.
- [19] Lane BR, Stein DE, Remzi FH, Strong SA, Fazio VW, Angermeier KW. Management of radiotherapy induced rectourethral fistula. *J Urol* 2006; 175:1382-1387; discussion 1387-1388.
- [20] Ulrich D, Roos J, Jakse G, Pallua N. Gracilis muscle interposition for the treatment of recto-urethral and rectovaginal fistulas: a retrospective analysis of 35 cases. *Journal of Plastic, Reconstructive & Aesthetic Surgery* 2009;62, 352-356.

- [21] Gupta G, Kumar S, Kekre NS, Gopalakrishnan G. Surgical management of rectourethral fistula. *Urology* 2008; 71:267-271.
- [22] Joshi HM, Vimalachandran D, Heath RM, Rooney PS. Management of iatrogenic rectourethral fistula by transanal rectal flap advancement. *Colorectal Dis* 2010.
- [23] Xu YM, Sa YL, Fu Q, Zhang J, Jin SB. Surgical Treatment of 31 Complex Traumatic Posterior Urethral Strictures Associated with Urethrorectal Fistulas. *Eur Urol* 2010; 57:514-520.
- [24] Rabau M, Zmora O, Tulchinsky H, Gur E, Goldman G. Recto-vaginal/urethral fistula: repair with gracilis muscle transposition. *Acta Chir Iugosl* 2006; 53:81-84.
- [25] Osawa S, Nishimura T, Akimoto M, Abe H, Hamasaki T, Kuroda S. Repair of a fistula between the bladder and the perineal skin by femoral gracilis flap interposition. *Int J Urol* 2001; 8:80-82.
- [26] Ulrich D, Roos J, Jakse G, Pallua N. Gracilis muscle interposition for the treatment of recto-urethral and rectovaginal fistulas: a retrospective analysis of 35 cases. *J Plast Reconstr Aesthet Surg* 2009; 62:352-356.
- [27] Kizer WS, Armenakas NA, Brandes SB, Cavalcanti AG, Santucci RA, Morey AF. Simplified reconstruction of posterior urethral disruption defects: limited role of supracrural rerouting. *J Urol* 2007; 177:1378-1381; discussion 1381-1382.
- [28] Zhang J, Xu YM, Qiao Y, Jin SB, Wu DL, Gu BJ. An evaluation of surgical approaches for posterior urethral distraction defects in boys. *J Urol* 2006; 176:292-295; discussion 295.
- [29] Iselin CE, Webster GD. The significance of the open bladder neck associated with pelvic fracture urethral distraction defects. *J Urol* 1999; 162:347-351.
- [30] Al-Rifaei MA, Zaghoul S, Al-Rifaei AM. Bulboprosthetic anastomotic urethroplasty with preservation of potency: anatomical study, operative approach and clinical results. *Scand J Urol Nephrol* 2005; 39:163-168.
- [31] Waterhouse K, Abrahams JI, Gruber H, Hackett RE, Patil UB, Peng BK. The transpubic approach to the lower urinary tract. *J Urol* 1973; 109: 486-490.
- [32] Turner-Warwick R. Complex traumatic posterior urethral strictures. *J Urol* 1977; 118: 564-574.
- [33] Pratap A, Agrawal CS, Tiwari A, Bhattarai BK, Pandit RK, Anchal N. Complex posterior urethral disruptions: management by combined abdominal transpubic perineal urethroplasty. *J Urol* 2006; 175: 1751-1754, discussion 1754.
- [34] Gupta NP, Mishra S, Dogra, PN, Yadav R, Seth A, Kumar R. Transpubic urethroplasty for complex posterior urethral strictures: A single center experience. *Urol Int* 2009; 83:22-26.
- [35] Koraitim MM. Transpubic urethroplasty revisited: total, superior, or inferior pubectomy? *Urology* 2010; 75:691-694.
- [36] Webster GD, MacDiarmid SA. Posterior urethral reconstruction. In: Webster GD, Kirby R, King L, Goldwasser B, editors. *Reconstructive urology*. Boston: Blackwell Scientific; 1993. Chapter 49.
- [37] Feng C, Xu YM, Yu JJ, Fei XF, Chen L. Risk factors for erectile dysfunction in patients with urethral strictures secondary to blunt trauma. *J Sex Med* 2008; 5:2656-2661.
- [38] Morey AF, McAninch JW. Reconstruction of posterior urethral disruption injuries: outcome analysis in 82 patients. *J Urol* 1997; 157:506-510.



## **Current Concepts of Urethroplasty**

Edited by Dr Ivo Donkov

ISBN 978-953-307-392-7

Hard cover, 152 pages

**Publisher** InTech

**Published online** 19, July, 2011

**Published in print edition** July, 2011

Urethral reconstructive surgery has always been a challenging part for urologist since the dawn of our speciality. In this book leading experts in lower urinary reconstructions from all over the world present their views and experience in that field, together with practical tips and tricks. The book is an excellent source of information for those who are already dealing with urethral surgery, and also an invaluable companion for urologists in training or those who want to dedicate themselves to this great sub-specialty. This book is an excellent reference guide and companion on the way to operating and consulting room, or when writing an article and reviewing the current practices. The abundance of methods and continuing development of new approaches to the problem prove the complexity of it.

### **How to reference**

In order to correctly reference this scholarly work, feel free to copy and paste the following:

Ying-Long Sa and Yue-Min Xu (2011). Complex Posterior Urethral Stricture, Current Concepts of Urethroplasty, Dr Ivo Donkov (Ed.), ISBN: 978-953-307-392-7, InTech, Available from:  
<http://www.intechopen.com/books/current-concepts-of-urethroplasty/complex-posterior-urethral-stricture>

**INTECH**  
open science | open minds

### **InTech Europe**

University Campus STeP Ri  
Slavka Krautzeka 83/A  
51000 Rijeka, Croatia  
Phone: +385 (51) 770 447  
Fax: +385 (51) 686 166  
[www.intechopen.com](http://www.intechopen.com)

### **InTech China**

Unit 405, Office Block, Hotel Equatorial Shanghai  
No.65, Yan An Road (West), Shanghai, 200040, China  
中国上海市延安西路65号上海国际贵都大饭店办公楼405单元  
Phone: +86-21-62489820  
Fax: +86-21-62489821

© 2011 The Author(s). Licensee IntechOpen. This is an open access article distributed under the terms of the [Creative Commons Attribution 3.0 License](#), which permits unrestricted use, distribution, and reproduction in any medium, provided the original work is properly cited.

IntechOpen

IntechOpen