

We are IntechOpen, the world's leading publisher of Open Access books Built by scientists, for scientists

4,800

Open access books available

122,000

International authors and editors

135M

Downloads

Our authors are among the

154

Countries delivered to

TOP 1%

most cited scientists

12.2%

Contributors from top 500 universities



WEB OF SCIENCE™

Selection of our books indexed in the Book Citation Index
in Web of Science™ Core Collection (BKCI)

Interested in publishing with us?
Contact book.department@intechopen.com

Numbers displayed above are based on latest data collected.

For more information visit www.intechopen.com



Versatility of Tubularized Incised Plate Urethroplasty in Management of Different Types of Hypspadias

Gamal Al-Saied

*Al-Azhar University, Cairo,
Egypt and King Abdul Aziz Specialist Hospital, Taif
Saudi Arabia*

1. Introduction

Hypospadias is one of the most common congenital anomalies occurring in approximately 1 of 200 to 1 of 300 live births.⁽¹⁾ Many operations have been described for repair of hypospadias. The introduction of Tubularized Incised-Plate (TIP) urethroplasty by Snodgrass in 1994 have resulted in a revolution in management of different types of hypospadias (distal and proximal either new cases or re-operative cases) as documented by many reports.⁽²⁻⁷⁾ The purpose of this review article is to emphasize that TIP urethroplasty with neourethral coverage using a vascularized pedicled flap of dartos fascia is versatile and simple operation with good functional and cosmetic outcome.

2. Surgical technique

Under complete a septic technique, a traction suture of 5-0 silk is placed in the glans to stabilize the penis during the procedure and help in demonstration of the abnormal curvature and redundant dorsal preputial skin. A circumscribing incision is made 2 mm proximal to the hypospadiac meatus, and the penis is degloved to the penoscrotal junction in cases with proximal meatus. In cases of hypoplastic urethra (the urethra devoid of corpus spongiosum), the meatus is preserved in all patients by a de-epithelialization of hypoplastic urethra. Artificial erection is conducted to verify the penile shaft without bending. If the penis is straight, TIP repair is continued; parallel longitudinal incisions are then made approximately 6 to 8 mm apart to separate the glans from the lateral margins of the plate and the glanular wings are mobilized to facilitate subsequent glans closure without tension. Then, the edges of the urethral plate are gently retracted laterally with fine forceps to delineate the midline which is deeply incised with tenotomy scissors from the hypospadiac meatus to the end of the plate, just below the tip of glans penis [Figure 1]. The incised urethral plate is tubularized without tension over a catheter of an appropriate size [6Fr or 8Fr], using two-layer 6/0 polyglactin sutures, (first layer is running sub-epithelial and second layer is interrupted sub-epithelial suture), [Figure 2]. The epithelium of the urethral plate is

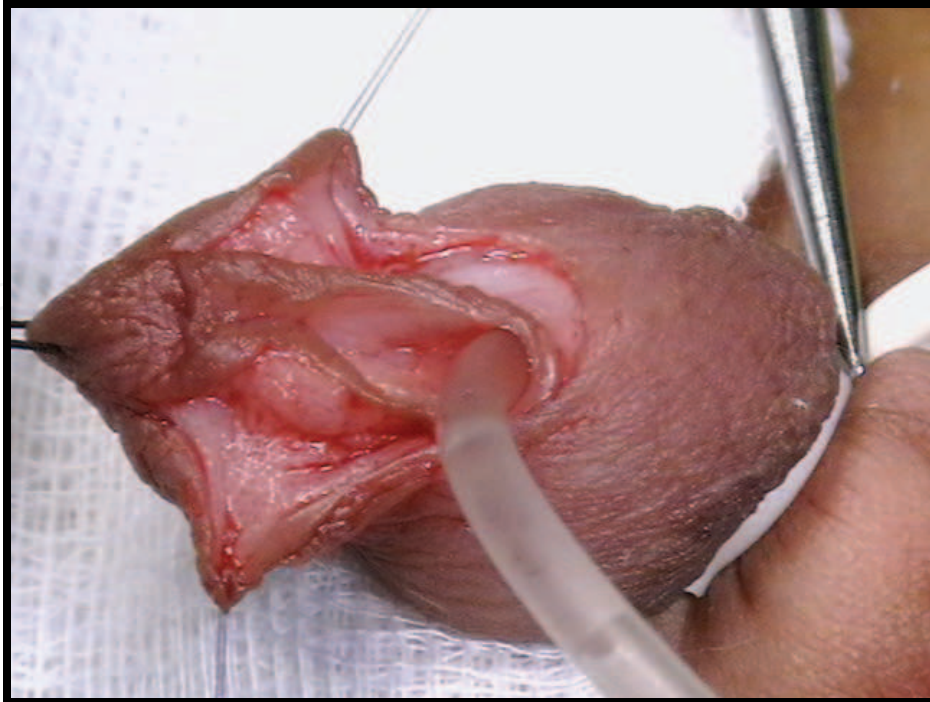

Fig. 1. A U-shaped skin incision is made surrounding the meatus and paramedian incisions are made bilaterally along the urethral plate. The urethral plate is incised sufficiently deeply in its midline from just below the tip of the glans to the regressed meatus

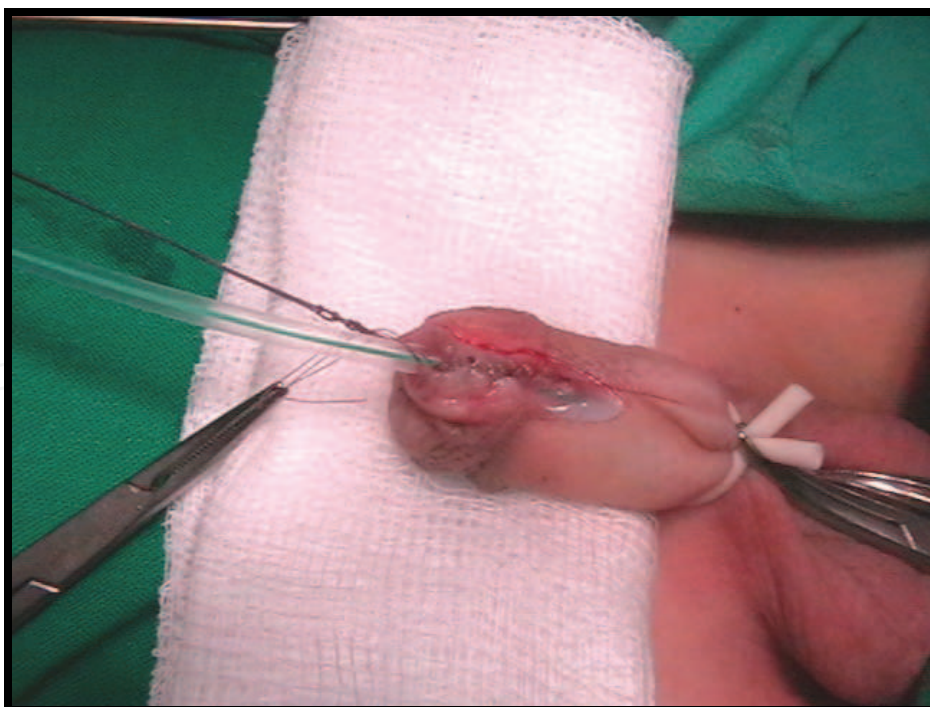


Fig. 2. The incised urethral plate (TIP) is tubularized without tension over a catheter of an appropriate size, using two-layer 6/0 polyglactin sutures (1st layer is running sub-epithelial and 2nd layer is interrupted sub-epithelial suture). Then the corpus spongiosum alongside the plate is sutured together over the neourethra with the "Y to I" technique

inverted toward the lumen to avoid fistula formation. Then, the corpus spongiosum alongside the plate is sutured together over the neourethra with the "Y to I" technique. In all cases, a vascularized dartos fascia flap harvested either from the prepuce or the penile shaft was used to cover the urethroplasty as a second layer. It is placed in such a manner as to cover the original suture line and sutured with periurethral tissue. Care must be taken to avoid rotation of the penis [Figure 3]. Then, the lateral glans wings are re-approximated over the neourethra using vertical mattress 6/0 polyglactin sutures [Figure 4].

If the curvature is less than 30 degree, dorsal plication of the corporal tissue in the midline is performed to preserve the urethral plate [Figure 5 and 6]. In case of severe chordee more than 30 degree, excision of the chordee followed by covering of the ventral raw area with preputial or penile shaft skin as a first stage. Then, after 6 months, the neo-urethra is fashioned from the healthy skin over a catheter of an appropriate size starting from the hypospadiac meatus and continued distally with incised urethral plate of the glans.

Then, Preputial skin is divided in midline and rotated on both sides of the shaft of the penis to cover the second layer of dartos fascia and sutured to the subglandular skin edge to cover the ventrum of the penis. In circumcised patients, penile ventral skin is approximated and sutured to cover the ventrum of the penis. Then, a straight catheter within the urethra was secured distally to the glans with the traction suture. The duration of the catheter indwelling ranges from 7 to 10 days according to the length of the neourethral. A compression dressing is applied and the first change of dressing is performed 48 hours after surgery to assess the viability of the repair and to detect the acute postoperative complications (bleeding, haematoma and oedema). Prophylactic IV antibiotic (3rd generation cephalosporin) started 30 minutes before induction of anesthesia and continued for 48 hours postoperatively. All patients were kept on regular follow up in outpatient clinic at the end of first, third and sixth month postoperatively.

3. Discussion

A technique to repair hypospadias with universal applicability in most variants would be appealing. The Snodgrass technique is a simple technical innovation that has revolutionized hypospadias surgery. Rich et al.,(1989) first described an incision in the urethral plate to obtain a cosmetically acceptable vertical slit-like meatus for the Mathieu repair.⁽⁸⁾ This was subsequently adopted for the entire length of the urethral plate as a complement to the Thiersch-Duplay urethroplasty for distal hypospadias reported by Snodgrass.⁽²⁻⁵⁾ The dorsal relaxing incision over the urethral plate results in a neourethra of more than 10 F ⁽²⁻⁵⁾ and does not seem to compromise the blood supply of urethral plate.⁽⁹⁻¹⁰⁾ It also results in re-epithelialization rather than fibrosis of the subcutaneous tissue which may later give rise to stricture of the neourethra.^(4,6,11) In 2001, Borer et al., found that the risk of fistula was reduced by using second layer to cover the suture line, and recommend this maneuver after TIP urethroplasty.⁽⁶⁾ In 2003, Samuel and Wilcox used a second layer of vascularized pedicle subcutaneous tissue harvested from the dorsal hooded prepuce provided cover for the urethroplasty to minimize the incidence of urethrocutaneous fistula.⁽⁷⁾ In 2003, Sozubir and Snodgrass mentioned that dartos pedicle flap obtained from the dorsal prepuce and shaft skin is used to cover the neourethra. In some patients with proximal hypospadias, the corpus spongiosum alongside the plate is sutured together over the neourethra with the "Y to I" technique before the dartos flap is applied.⁽¹²⁻¹³⁾

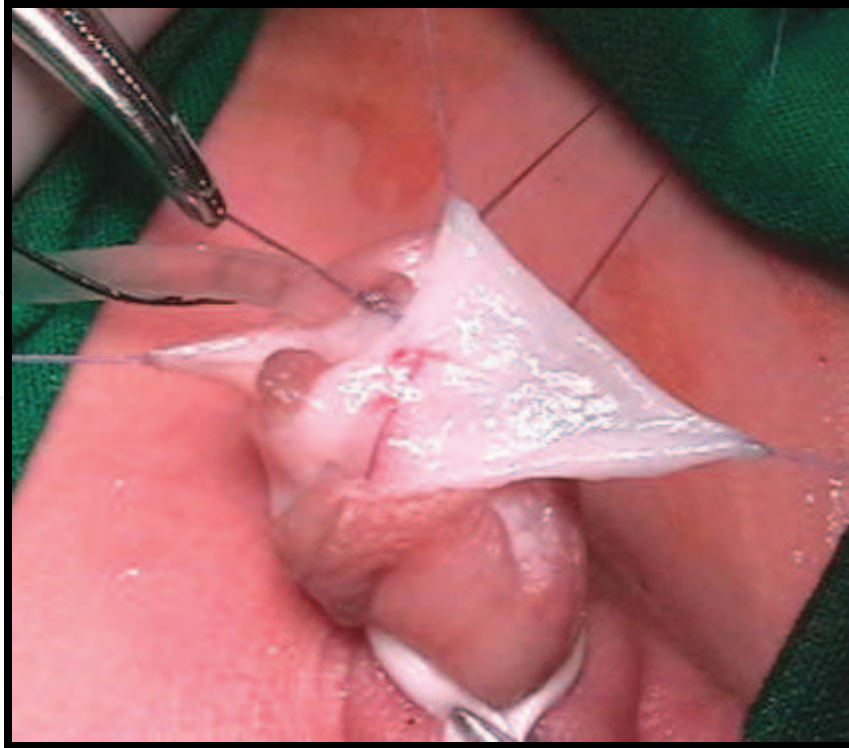


Fig. 3. A vascularized dartos fascia flap harvested from the prepuce is used to cover the neourethra as a second layer

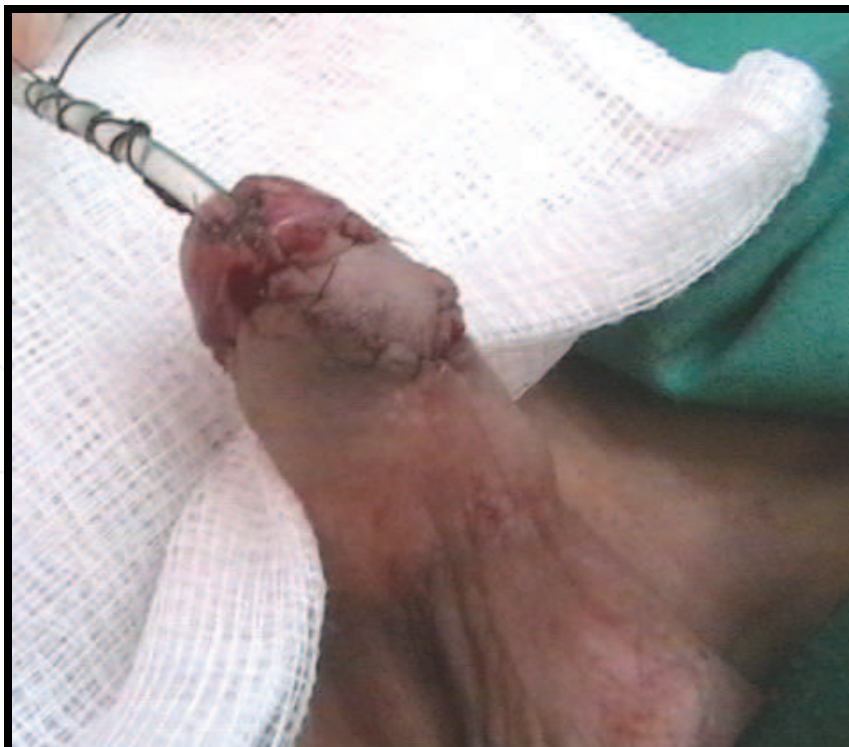

Fig. 4. After the lateral glans wings are reapproximated over the neourethra, the ventral aspect of the penis is covered with penile prepuce, which is sutured to the subglanular skin edge

In 2002, Elbakry concluded that post operative regular urethral calibration should be considered as an integral part of the TIP urethroplasty to prevent the neourethral and/or meatal stenosis with subsequent urethral fistula.⁽¹⁴⁾

In 2002 Lorenzo and Snodgrass concluded that dilatation of the neourethra is unnecessary after TIP urethroplasty and the calibration and uroflowmetry 6 months after surgery may be useful to detect subclinical obstruction. They attributed the meatal stenosis detected in other series (Elbakry 2002) to the technical error including failure to deeply incise the plate and/or tubularization of urethral plate too far distally.⁽¹⁵⁾

In our series, the urethrocutaneous fistula was seen in 6(4.14%) of 1^{ry}(new) cases and 5(16.67%) of 2^{ry} (previously failed repair) cases. Meatal stenosis, urethral stricture and meatal regression were observed in 17(9.71%), 5 (2.86%), and 10 (5.71%) respectively, in spite of the deep incision of urethral plate and tension free tubularization of urethral plate to a adequate length. All cases of urethral stricture and most cases of meatal stenosis responded well to regular urethral dilatation. Meatoplasty was performed in only 5 (2.85%) cases (1 of 1^{ry} cases and 4 of 2^{ry} cases). Secondary surgery for fistula repair was successful in all patients ⁽¹⁹⁾

In 2002 Snodgrass and Lorenzo concluded that TIP urethroplasty can be used for hypospadias reoperation, even when the urethral plate has been incised previously, but should be avoided when the urethral plate is obviously scarred or has been resected.⁽¹⁶⁾

TIP urethroplasty was used for hypospadias reoperation with successful results.⁽¹⁹⁾

Thin distal urethra devoid of spongiosum sometimes called 'hypoplastic urethra has been noticed in approximately one-fourth of patients undergoing urethroplasty.⁽¹⁷⁾ In our series, the hypoplastic urethra was observed in 25(17.24%) cases.⁽¹⁹⁾

Traditionally, the hypoplastic urethra is spatulated till the 'healthy' urethra with spongiosum cover is obtained and the urethroplasty is commenced. This step creates a more proximal hypospadias, thus increasing the chances of postoperative fistula.⁽¹⁸⁾

In our series, the urethral hypoplasia is preserved by its de-epithelialization. De-epithelialization starts ventrally and proximally at the normal penile skin below the hypospadiac meatus. At this site, dissection of subcutaneous tissue is facilitated by injection of few ml of normal saline using a fine needle (insulin needle) to achieve separation of adherent skin from the urethra and continues distally up to hypospadiac meatus. Then, the neourethra is reinforced by suturing the corpus spongiosum alongside the plate together over the neourethra with the "Y to I" technique before the dartos flap is applied with good functional and cosmetic outcome.⁽¹⁹⁾

In case of severe chordee more than 30 degree of 1^{ry} cases, or scarred urethral plate of 2^{ry} cases, the chordee or fibrosed urethral plate is excised and the ventral raw area is covered with either preputial or penile shaft skin as a first stage. Then, after 6 months, the neourethra is fashioned from the healthy skin over a catheter of an appropriate size, starting from the hypospadiac meatus and continued distally with incised urethral plate of the glans.⁽¹⁹⁾

In conclusion, the good functional and cosmetic outcome of TIP urethroplasty are attributed to; 1) tension free fashioning of the neo-urethra from the healthy urethral plate (non-scarred) over a catheter of an appropriate size, 2) using of two layers of 6/0 polyglactin sutures, (first layer is running sub-epithelial and second layer is interrupted sub-epithelial suture), with aid of magnification tools, 3) suturing of the corpus spongiosum alongside the plate together

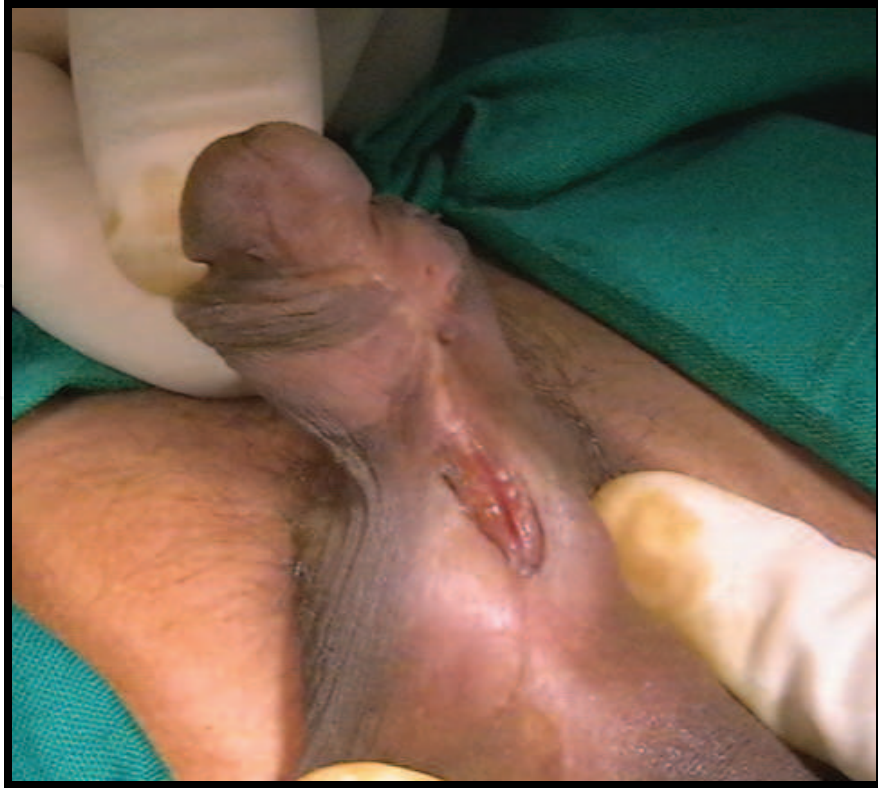

Fig. 5. Penoscrotal hypospadias with chordee less than 30 degree

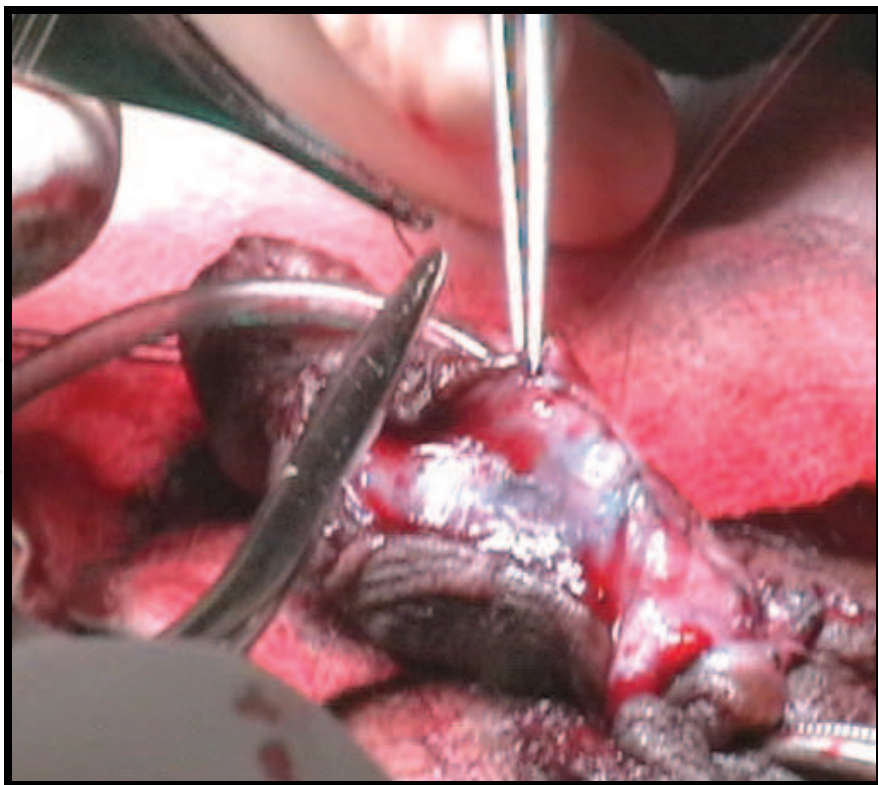


Fig. 6. Dorsal plication of the corporal tissue is done in the midline to preserve the urethral plate then, TIP urethroplasty is performed

over the neourethra with the “Y to I” technique, 4) and application of second layer of vascularized dartos pedicle flap harvested either from the dorsal prepuce or penile shaft skin in circumcised patients to cover the suture line after TIP urethroplasty.


4. References

- [1] Baskin LS, Colborn T, Himes K. Hypospadias and endocrine disruption: is there a connection? *Environ Health Perspect* 2001;109:1175-83.
- [2] Snodgrass W. Tubularized incised plate urethroplasty for distal hypospadias. *JL/ro/1994*; 151:464-5
- [3] Snodgrass W, Koyle M, Manzoni G, Horowitz R, Caldamone A, Ehrlich R. Tubularized Incised Plate hypospadias repair, results of a multicenter experience. *J Uro/1996*; 156:839-41
- [4] Snodgrass W, Koyle M, Manzoni G, Horowitz R, Caldamone A, Ehrlich R. Tubularized Incised Plate hypospadias repair for proximal hypospadias. *J Uro/1998*; 159:2129-31
- [5] Snodgrass W. Does Tubularized Incised Plate hypospadias repair create neourethra strictures?. *J Urol* 1999; 162:1159-61
- [6] Borer JG, Bauer SB, Peters CA, Diamond DA, Atala A, Cilento BG. Tubularized incised plate urethroplasty. Expanded use in proximal and repeat surgery for hypospadias. *J Urol* 2001; 165: 581 -5
- [7] Samuel M. and Wilcox DT. Tubularized incised-plate urethroplasty for distal and proximal hypospadias *BJU Int* 2003; 92: 783-785
- [8] Rich MA, Keating MA, Snyder HM III, Duckett JW. Hinging the urethral plate in hypospadias meatoplasty. *J Urol* 1989; 142:1551-3
- [9] Baskin LS, Erol A, Ying WL, Cunha GR. Anatomic studies of hypospadias. *J Uroi* 1998; 160: 1108-15
- [10] Erol A, Baskin LS, Li YW, Liu WH. Anatomical studies of the urethral plate: why preservation of the urethral plate is important in hypospadias repair. *BJU Int* 2000; 85: 728-34
- [11] Horasanii K, Perk C, Yesildere T. The effect of catheterization time on tissue regeneration after a deep urethral plate incision. *BJU int* 2000; 87:20
- [12] Sozubir S. and Snodgrass W.: A new algorithm for primary hypospadias repair based on tip urethroplasty. *J Pediatric Surg* 2003; 38:1157-1161
- [13] Yerkes EB, Adams MC, Miller DA, et al. Y-to-I wrap: Use of the distal spongiosum for hypospadias repair. *J Urol* 2000; 163:1536.
- [14] Elbakry A: further experience with Tubularized-incised urethral plate technique for hypospadias repair, 2002; *BJU Int* 89:291-294
- [15] Lorenzo A and Snodgrass W. Regular dilatation is unnecessary after Tubularized incised plate hypospadias repair. *BJU Int.* 2002; 89:94-97
- [16] Snodgrass W.T. and Lorenzo A.J. Tubularized incised-plate urethroplasty for hypospadias reoperation. 2002; *Br J Urol Int* 89:98-100.
- [17] Yang SS, Chen YT, Hsieh CH, Chen SC. Preservation of the thin distal urethra in hypospadias repair. *J Urol* 2000; 164:151-3.

- [18] Sarin YK, Manchanda V. Preservation of urethra devoid of corpus spongiosum in patients undergoing urethroplasty. *Indian J Urol* 2006; 22:326-8
- [19] Al-Saied G and Gamal A. Versatility of tubularized incised plate urethroplasty in the management of different types of hypospadias: 5-year experience. *Afr J Paediatr Surg* 2009; 6:88-92

IntechOpen

IntechOpen



Current Concepts of Urethroplasty

Edited by Dr Ivo Donkov

ISBN 978-953-307-392-7

Hard cover, 152 pages

Publisher InTech

Published online 19, July, 2011

Published in print edition July, 2011

Urethral reconstructive surgery has always been a challenging part for urologist since the dawn of our speciality. In this book leading experts in lower urinary reconstructions from all over the world present their views and experience in that field, together with practical tips and tricks. The book is an excellent source of information for those who are already dealing with urethral surgery, and also an invaluable companion for urologists in training or those who want to dedicate themselves to this great sub-specialty. This book is an excellent reference guide and companion on the way to operating and consulting room, or when writing an article and reviewing the current practices. The abundance of methods and continuing development of new approaches to the problem prove the complexity of it.

How to reference

In order to correctly reference this scholarly work, feel free to copy and paste the following:

Gamal Al-Saied (2011). Versatility of Tubularized Incised Plate Urethroplasty in Management of Different Types of Hypospadias, Current Concepts of Urethroplasty, Dr Ivo Donkov (Ed.), ISBN: 978-953-307-392-7, InTech, Available from: <http://www.intechopen.com/books/current-concepts-of-urethroplasty/versatility-of-tubularized-incised-plate-urethroplasty-in-management-of-different-types-of-hypospadias>

INTECH
open science | open minds

InTech Europe

University Campus STeP Ri
Slavka Krautzeka 83/A
51000 Rijeka, Croatia
Phone: +385 (51) 770 447
Fax: +385 (51) 686 166
www.intechopen.com

InTech China

Unit 405, Office Block, Hotel Equatorial Shanghai
No.65, Yan An Road (West), Shanghai, 200040, China
中国上海市延安西路65号上海国际贵都大饭店办公楼405单元
Phone: +86-21-62489820
Fax: +86-21-62489821

© 2011 The Author(s). Licensee IntechOpen. This is an open access article distributed under the terms of the [Creative Commons Attribution 3.0 License](#), which permits unrestricted use, distribution, and reproduction in any medium, provided the original work is properly cited.

IntechOpen

IntechOpen