

We are IntechOpen, the world's leading publisher of Open Access books Built by scientists, for scientists

4,800

Open access books available

122,000

International authors and editors

135M

Downloads

Our authors are among the

154

Countries delivered to

TOP 1%

most cited scientists

12.2%

Contributors from top 500 universities



WEB OF SCIENCE™

Selection of our books indexed in the Book Citation Index
in Web of Science™ Core Collection (BKCI)

Interested in publishing with us?
Contact book.department@intechopen.com

Numbers displayed above are based on latest data collected.

For more information visit www.intechopen.com



Drug-Induced Glaucoma (Glaucoma Secondary to Systemic Medications)

Eitan Z. Rath

*Department of Ophthalmology, Western Galilee – Nahariya Medical Center,
Israel*

1. Introduction

Glaucoma comprises a group of diseases that have in common a characteristic optic nerve and visual field damage and elevated intraocular pressure (IOP) is the main risk factor. The IOP depends on the balance between the formation and drainage of aqueous humor. The glaucoma can be classified into four main groups: open-angle (OAG), acute angle-closure (ACG), secondary and developmental glaucoma. The first two refer to the pathophysiology of the disease.

Drug-induced glaucoma is a form of secondary glaucoma induced by topical and systemic medications. The most common one is glucocorticoid OAG. Several drugs like antidepressants, anticoagulants, adrenergic antagonists, sulpham-based drugs and antiepileptic drugs have been reported to produce an acute ACG and especially in those with predisposed angle closure.

Bilateral simultaneous ACG is extremely a rare entity. Drug-induced uveal effusion causing secondary ACG have been reported¹⁻⁹ involving medications such as topiramate,^{2,4,6,9} trimethoprim¹ and venlafaxine.³ The mechanism of secondary OAG is usually the microscopic obstruction of the trabecular meshwork whereas ACG is induced by uveal effusion. The treatment of these two entities is similar to OAG and, it could be medically as well as surgical.

The differential diagnosis, prognosis and several future directions for research will be discussed.

Ophthalmologists should be aware of these types of glaucoma, which to my opinion are becoming more common in a busy glaucoma clinic.

2. Epidemiology

As shown that within the general population 5 to 6 % of the healthy subjects will develop marked elevation of IOP, 4 to 6 weeks after administration of topical dexamethasone or betamethasone eye drops.¹² These studies have also shown that these numbers are directly related to the frequency of the administration and duration of usage of this medication. Increasing usage is related to the increased risk for elevated IOP. At higher risk are patients with primary open-angle glaucoma, their first-degree relatives, diabetic patients, highly myopic individuals, and patients with connective tissue disease, specifically rheumatoid arthritis. In addition, patients with angle recession glaucoma are more susceptible to corticosteroid-induced glaucoma.

3. Mechanisms of IOP elevation in drug-induced glaucoma

3.1 Open-angle

Corticosteroid is a group of drugs that may produce IOP elevation by open-angle mechanism. Not all the patients taking steroid will develop this glaucoma. The risk factors include preexisting primary open-angle glaucoma, a family history of glaucoma, high myopia, diabetes mellitus and young age.¹³ It has been shown that 18-36% of the general population and 46-92% of patients with primary open-angle glaucoma respond to topical ocular administration of corticosteroids with an elevation of IOP, usually within 2-4 weeks after therapy has been instituted.

Topically applied eye drops and creams to the periorbital area and intravitreal injections are more likely to cause IOP elevation than intravenous, parenteral and inhaled forms. Since IOP elevation can be gradual and asymptomatic, patients on chronic corticosteroid therapy may remain undiagnosed, which can result in glaucomatous optic nerve damage. Steroid-induced IOP elevation typically occurs within a few weeks after commencing steroid therapy. In most cases, IOP returns spontaneously to the baseline within a few weeks to months upon discontinuing the steroid (steroid responders). In rare situations, the IOP remains high (steroid-induced glaucoma) that may require prolonged glaucoma medication or even surgery. This subject is discussed in details in the chapter on steroid-induced glaucoma.

3.2 Closed-angle

Some drugs have contraindications or adverse effects that are related to acute angle-closure glaucoma. These drugs will incite an attack in individuals with very narrow anterior chamber angles that are prone to occlusion, especially when the pupils are dilated. The classes of medications that have the potential to induce angle-closure are topical anticholinergic or sympathomimetic pupil dilating drops, tricyclic antidepressants, monoamine oxidase inhibitors, antihistamines, anti-Parkinson drugs, antipsychotic medications and antispasmodic agents.

Sulfonamide-containing medications may induce an ACG by a different mechanism, involving the anterior rotation of the ciliary-body. Typically, the angle-closure is bilateral and occurs within the first few doses. Patients with narrow or wide open angles are potentially susceptible to this rare and idiosyncratic reaction.

4. Pathophysiology of drug-induced glaucoma

4.1 Open-angle

The exact pathophysiology of steroid-induced glaucoma is unknown. It is known that steroid-induced IOP elevation is secondary to increased resistance to aqueous outflow. Some evidence shows that there could be an increased accumulation of glycosaminoglycans or increased production of trabecular meshwork-inducible glucocorticoid response (TIGR) protein, which could mechanically at microscopic level obstruct the aqueous outflow. Other evidence suggests that the corticosteroid-induced cytoskeletal changes could inhibit pinocytosis of aqueous humour or inhibit the clearing of glycosaminoglycans, resulting in the accumulation of this substance and blockage of the aqueous outflow.

4.2 Closed-angle

Aqueous humor is secreted by the ciliary body and circulates through the pupil to reach the anterior chamber angle. (Fig. 1) The pathophysiology of angle-closure glaucoma is usually

due to pupillary block, i.e. iris-lens contact at the pupillary border resulting from pupillary dilation.

People at risk for Angle Closure Glaucoma (ACG) are those with hypermetropia, microphthalmus and nanophthalmos. Medications have a direct or indirect effect, either in stimulating sympathetic or inhibiting parasympathetic activation causing pupillary dilation, which can precipitate an acute angle-closure in patients with occludable anterior chamber angles. These agents include adrenergic agonists (e.g. β 2-specific adrenergic agonists (e.g. salbutamol), non-catecholamine adrenergic agonists (e.g. amphetamine, dextroamphetamine, methamphetamine and phendimetrazine) and anticholinergics (e.g. tropicamide). Histamine H1receptor antagonists (antihistamines) and histamine H2 receptor antagonists (e.g. cimetidine and ranitidine) have weak anticholinergic adverse effects. Antidepressants such as fluoxetine, paroxetine, fluvoxamine and venlafaxine also have been associated with acute angle-closures, which is believed to be induced by either the anticholinergic adverse effects or the increased level of serotonin that cause mydriasis.

Sulfa-containing medications may result in acute angle-closures by a different mechanism. This involves the anterior rotation of the ciliary body with or without choroidal effusions, resulting in a shallow anterior chamber and blockage of the trabecular meshwork by the iris. Pupillary dilation and a preexisting shallow anterior chamber angle are not necessary. The exact reason for ciliary body swelling is unknown but it occurs in susceptible individuals. Topiramate is a sulfa-containing anticonvulsant. There were reports about patients on topiramate developing acute angle-closure. However, a pilot study was conducted in the Hong Kong Eye Hospital and the Prince of Wales Hospital recently, which showed that short-term use of topiramate, did not induce an asymptomatic angle narrowing. Therefore, it was suggested that topiramate induced secondary angle-closure glaucoma may be an all-or-none phenomenon.

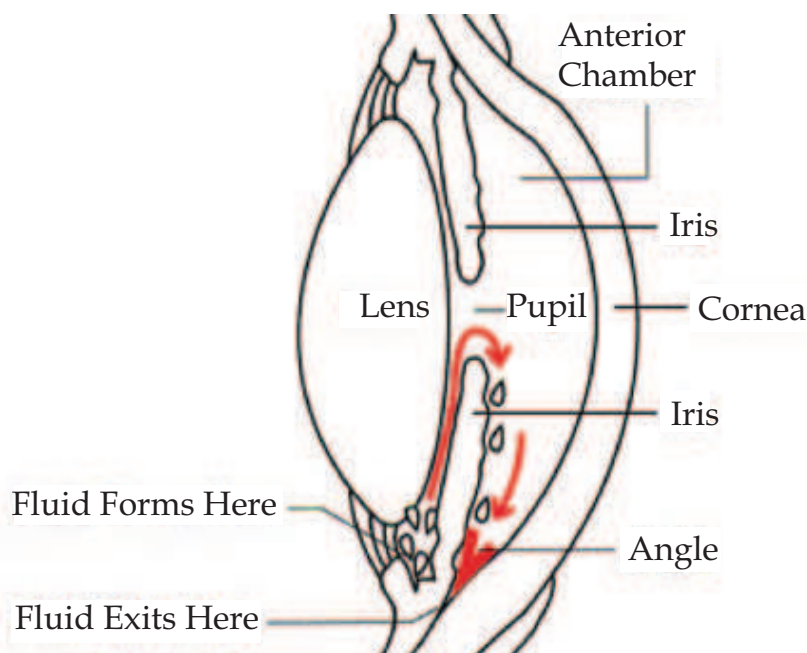


Fig. 1. Aqueous humor flow

Carbamazepine is also an anticonvulsive medication and a mood stabilizer and is primarily used in treating of epilepsy, bipolar disorders and trigeminal neuralgia.¹⁰ It stabilizes and

inactivates the sodium channel resulting in fewer active channels and fewer excited brain cells. It was only reported once as causing this disorder.⁸

We had two cases that developed simultaneously acute angle-closure glaucoma 4-6 weeks after intake of PO carbamazepine.

Case no. 1

A 58-year-old woman presented with a bilateral acute ACG. Her medical history included epilepsy treated with carbamazepine (Novartis Pharma BU (Novolog), Basel, Switzerland) 200 mg once a day for 4 weeks to stabilize her medical status. Eleven years earlier she underwent thyroidectomy due to hyperthyroidism.

The best-corrected visual acuity (BCVA) was 20/80 (with +3.75D) OD and 20/100 (with +4.25D) OS. The intraocular pressure (IOP) was 54 OD and 46mmHg OS. Both corneas were edematous and the anterior chambers were shallow. Gonioscopy revealed angle closure in both eyes and fixed, mid-dilated pupils. Ultrasound biomicroscopy (UBM) showed an anterior displaced crystalline lens with extensive irido-lenticular contact and peripheral anterior synechiae OU. The axial length was 21.35 mm OD and 21.30 mm OS. B-Scan ultrasound showed normal posterior segment OU.

The patient was treated systemically with PO acetazolamide 250mg, topical timolol maleate - dorzolamide HCl and brimonidine tartrate twice a day and the IOP decreased to 18mmHg OD and 16mmHg OS. Neodymium: Yttrium-Aluminum-Garnet (Nd: YAG) laser iridotomy was successfully performed OU. A week later, the BCVA improved to 20/80 OD and 20/60 OS, on ocular examination, patent iridotomies, mid dilated pupils with sphincter atrophy, mild nuclear sclerosis and normal optic discs were noted. The anterior chamber depth measured by Scheimpflug imaging (Pentacam®, Oculus Optikgerate GmbH, Wetzlar, Germany) was 1.54mm OD and 1.67mm OS and the volume was 90mm³ and 76mm³ respectively. The pachymetry was 572µm OD and 568µm. The visual fields 30-2 (Humphrey II® automatic perimeter, Allergan-Humphrey, San Leandro, CA) performed two months later showed inferior nasal step OU.

Case no. 2

A 53-year-old female was admitted due to high IOP simultaneously in both eyes. She was hypermetropic since childhood and had amblyopic OS. She suffered from epilepsy and had two attacks four and six weeks before being hospitalized for which she received PO carbamazepine 200mg/d for five weeks. A day before admission, she experienced severe bilateral ocular pain, vomiting and decrease in visual acuity OU.

Her BCVA was 20/40 with +5.50D OD and 20/100 with + 7.50D OS. The IOP was 54 mmHg OD and 49 mmHg OS. Both eyes had edematous cornea, very shallow anterior chamber, iris bombe and mid-dilated pupil that were not reacting to light. The anterior chamber had a narrow angle 360 degrees OU on UBM (Fig. 2). The posterior poles were normal. The patient was treated with topical pilocarpine 2% qid and PO acetazolamide 250mg bid.

The patient underwent Nd: YAG laser iridotomy OU. Three days later, the BCVA improved to 20/25 OD and 20/60 OS. The IOP decreased to 8mmHg OD and 6mmHg OS. The anterior chambers' depth was deepened and patent iridotomies, mild-dilated pupil, clear lens and posterior pole with normal optic discs were observed.

The mechanism of these agents causing bilateral AACG has been attributed to ciliochoroidal effusion, which causes forward rotation of the lens-iris diaphragm resulting in a secondary angle-closure and increased IOP. This medication and others can produce an excessive

amount of aqueous production as well as causing ciliary body edema. The common denominator to our patients was hypermetropia. Indeed, patients with short axial length, such as nanophthalmos and hyperopia have a tendency to develop thickened uvea, which can be aggravated by intraocular procedures such as cataract surgery resulting in acute ACG.¹¹

5. Non-steroidal agents associated with glaucoma

Unlike corticosteroid agents, the list of non-steroidal agents associated with glaucoma is wide and diverse (Table 1).¹⁴ The causes of glaucoma associated with these agents are also varied. The largest single cause of glaucoma in these patients appears to be an atropine-like effect, eliciting pupillary dilatation. This class of agents includes antipsychotics, antidepressants, monoamine oxidase (MAO) inhibitors, antihistamines, antiparkinsonian agents, antispasmodic agents, mydriatic agents, sympathetic agents, and botulinum toxin. The pupillary dilatation seen in these cases may be enough to precipitate an attack of angle-closure glaucoma in patients with narrow angles.

Concerning open-angle glaucoma, the causes of elevated IOP are much more varied, including the release of pigment during the pupillary dilation with subsequent obstruction of the trabecular meshwork, and a possible increase of inflow during pupillary dilation. As an alternative, some agents have been documented to produce an idiopathic swelling of the lens, associated with angle closure glaucoma. These agents include the antibiotics sulfa, quinine, and aspirin. Some agents directly obstruct the trabecular meshwork, such as the viscoelastic agents and silicone oil.

5.1 The role of psychotropic agents

Of the antipsychotic agents on the market today, only perphenazine (Trilafon®) and fluphenazine decanoate (Prolixin®) have been documented to cause glaucoma. In both instances these were attacks of angle-closure glaucoma. These episodes were felt to reflect the anticholinergic effect of these agents on the eyes.

5.2 The role of antidepressant agents

Amitriptyline (Elavil® and Amitril®) and imipramine (Tofranil®), which are antidepressant tricyclic agents, have been shown to produce attacks of an angle-closure glaucoma. Of the non-tricyclic drugs, fluoxetine (Prozac®) and mianserin hydrochloride (Bolvidon®)¹⁵ have been documented to be associated with attacks of angle-closure glaucoma.

5.3 The role of mood-altering agents, such as minor tranquilizers, sedatives, and stimulants

This is a rather diverse class of agents including sedatives such as diazepam (Valium®), morphine, barbiturates, and stimulants such as amphetamine and methylxanthines such as caffeine and theophylline. Diazepam has been reported to be taken by some patient having an attack of angle-closure glaucoma, in the literature there it is believed that this drug accentuate the anti cholinergic action on the eye in some rare cases with predisposed ACG . Barbiturates, morphine, para-aldehyde, meperidine, reserpine, and phenytoin have not been reported to produce an elevated IOP. The amphetamines have not been documented to produce an elevated IOP in any patient.

5.4 The role of antibiotics

Sulfa drugs

Agents that contain sulfa have been well documented to produce an idiosyncratic swelling of the lens associated with shallowing of the anterior chamber, retinal edema, and elevated IOP. These episodes do not involve the pupil and are not responding to cycloplegic agents. This observation has been confirmed by A-scan measurements of the eye during such an attack¹⁶.

Antipsychotropic agents

Phenothiazines

Perphenazine (Trilafon), fluphenazine decanoate (Prolixin)

Antidepressants

Tricyclic agents

Amitryptiline (Elavil), imipramine (Tofranil)

Nontricyclic agents

Fluoxetine (Prozac), mianserin HC1 (Bolvidin)

Monoamine oxidase (MAO) inhibitors

Phenylzine sulfate (Nardil)

Tranlycypromine sulfate (Parnate)

Antihistamines

Ethanolamines

Orphenadrine citrate (Norgesic)

Antiparkinsonian agents

Trihexyphenidyl HC1 (Artane)

Antispasmodic agents

Propantheline bromide (Pro-Banthine)

Dicydomine HC1 (Bentyl)

Antibiotics

Sulfa, quinine

Sympathomimetic agents

Epinephrine, ephedrine

Phenylephrine

Amphetamine

Hydroxyamphetamine

Mydriatic agents

All agents

Surgical agents

Viscoelastic agents, silicone oil

Botulin toxin

Cardiac agents

Disopyramide phosphate (Norpace)

Table 1. Non-steroidal agents

5.5 The role of antiparkinsonian agents

The anti-Parkinson agents act through two mechanisms: (1) Replenishing diminished stores of dopamine in the corpus striatum, and (2) Acting as a strong anticholinergic. Indeed, trihexyphenidyl

HCl (Artane)¹⁷ has been documented to precipitate angle-closure glaucoma. This finding is felt to reflect the anticholinergic effect of this agent.

5.6 The role of antispasmodic agents

These agents act to reduce both the gastrsecretion and the motility of the stomach. Their effect directly reflects their anticholinergic power. Although no attacks of angle-closure glaucoma are documented with these agents, propantheline bromide (Pro-Banthine®) and dicyclomine HCl (Bentyl®)¹⁸ have been documented to raise the IOP in patients with open-angle glaucoma probably because of their anticholinergic effect.

5.7 The role of anesthetic agents

General anesthesia has always entailed an increased risks to the patient, including the risk of elevated IOP and glaucoma. It has always been difficult to separate the various risk factors to the patient undergoing general anesthesia. The induction of general anesthesia itself may be associated with an elevated IOP from laryngeal spasm, coughing, and wheezing associated with endotracheal intubation. Specifically, succinylcholine, ketamine and chloral hydrate have been well documented to raise IOP. This effect is felt to be due to an increased extra-ocular muscle tone from these agents.¹⁹ The preoperative use of atropine, scopolamine, and ephedrine associated with attacks of angle-closure glaucoma following general anesthesia.

5.8 The role of antihistamines in inducing glaucoma

The antihistamines are a diverse group of agents that can be divided into two classes the H1 and the H2 antihistamines. The H1 antihistamines block the action of histamine on capillary permeability and vascular, bronchial, and other smooth muscles.²⁰ The H2 antihistamines block the effect of histamine on the smooth muscle in peripheral blood vessels and secretion of gastric acid. This group is important because of their anticholinergic effect of these agents. Although the anticholinergic action is mild, orphenadrine citrate (Norgesic®), an H1 antihistamine, has been documented to precipitate an attack of angle-closure glaucoma. It should also be noted that the H1 antihistamine promethazine HCl (Phenergan®) has been shown to produce an idiopathic swelling of the lens as documented with the sulfa agents. These agents exert only a weak response but should be approached with caution in the patient at risk for glaucoma.

5.9 The role of inhalation agents in inducing glaucoma

As mentioned above, a wide variety of agents are found as inhalation products, including sympathomimetic and parasympathomimetic agents. Salbutamol and ipratropium (used in combination for chronic obstructive airway) have also been documented to precipitate attacks of angle-closure glaucoma due to the anticholinergic effect of ipratropium in combination with the effect of salbutamol (a β_2 adreno receptor agonist) on increasing aqueous humor production.²¹ Therefore, these agents should be used with caution in patients at risk for such an attack of glaucoma.

5.10 The role of cardiac agents in inducing glaucoma

The traditional cardiac agents including digitalis and quinidine do not appear to have any effect on the IOP. However, disopyramide phosphate (Norpace®) does appear to have some anticholinergic activity and has indeed been documented to produce an attack of angle-closure glaucoma.²²

5.11 The role of botulinum toxin (Oculinum)

Botulinum toxin has become popular for the treatment of essential blepharo-spasm and extraocular muscle palsy; this injectable agent has been documented to produce an acute attack of angle closure glaucoma. The effect of this drug is on the ciliary ganglion, producing pupillarymydriasis.²³

5.12 The role of avastin and lucentis

A series of patients that developed sustained elevation of intraocular pressure (IOP) after intravitreal anti-VEGF injection for the treatment of neovascular age-related macular degeneration (AMD) is presented in numerous of recent publications²⁴ IOP reflects a balance between the rate that fluid flows into the eye and the rate that it exits the eye. If inflow increases or outflow decreases, then IOP will go up. Intravitreal injection of drugs, such as Lucentis (ranibizumab) or Avastin (bevacizumab), increases the amount of fluid within the eye, and hence will increase IOP. Normally, as the excess fluid gradually exits the eye over a period of time, the IOP returns to normal. However, there are a growing number of cases of patients undergoing Lucentis and Avastin therapy that develop elevation of IOP that does not return to normal.

In a recent study four out of 116 patients with AMD (3.45%) developed sustained elevated intraocular pressure (IOP) after multiple intravitreal injections of Avastin (1.5 mg/0.06 mL) and/or Lucentis (0.5 mg/0.05 mL). An analysis of 4 cases revealed: None of the patients had a previous diagnosis or family history of glaucoma/OHT. Two patients had both bevacizumab and ranibizumab injections. Two patients developed OHT after recent intravitreal ranibizumab and 2 patients after recent intravitreal Avastin injection. It appears that anti-VEGF drugs may, in some persons, lead to sustained elevation of IOP and possible glaucoma. It is not clear why this occurs, nor have any risk factors for this adverse effect, such as family history of glaucoma, been identified. Nor is it clear whether the IOP elevation is permanent, or whether IOP may return to normal after cessation of anti-VEGF injections. Glaucoma medications can lower IOP after it has been elevated by anti-VEGF drug use.

There are some publications²⁵ which describe the decrease of rubeosis iridis in patients with neo-vascular after intra- vitreal Avastin injection and can lead to decrease in IOP within 48 hours.

6. Treatment of drug-induced glaucoma

6.1 Medical: Open-angle

If the patient's underlying medical condition can tolerate discontinuation of corticosteroids, then its discontinuation will usually result in normalization of IOP. In case of topical corticosteroid drops, using a lower potency steroid medication, such as the phosphate forms of prednisolone and dexamethasone, loteprednol etabonate or fluorometholone should be considered. These drugs have a lesser chance to increase the IOP, but they are usually not as effective as others. Topical non-steroidal anti-inflammatory medications (e.g., diclofenac, ketorolac) are other alternatives do not cause IOP elevation, but they have only a limited

anti-inflammatory activity to treat the patient's underlying condition. In the occasional cases in which the patient's IOP does not normalize upon the cessation of the steroid or in those patients who must continue with treatment, topical anti-glaucoma medications are considered.

6.2 Medical: Closed-angle

If the etiology of closed angle glaucoma is sulfa containing medications, the increase in IOP generally will resolve upon discontinuing the agent. However, severe cases of sulfonamide-induced angle-closure (i.e. IOP >45 mm Hg) may not respond to discontinuing the offending agent. They may respond to intravenous mannitol. Other etiologies of drug-induced angle-closure are treated similar to primary acute angle-closure glaucoma with topical beta-blockers, prostaglandin analogues, cholinergic agonists and often oral acetazolamide.

6.3 Laser treatment

For open-angle steroid-induced glaucoma, selective laser trabeculoplasty or Argon laser trabeculoplasty (Fig. 3) can be applied in the absence of intraocular inflammation if the IOP is suboptimal with medication.

In closed-angle glaucoma, an Argon laser peripheral iridoplasty or YAG laser iridotomy may be performed to widen the angle and deepen the anterior chamber. Laser iridotomy can be performed to reverse pupillary block or to prevent further pupillary block. Laser Irididotomies can be performed as a preventive procedure in hypermetropic naophthalmic and microphthalmic eyes. Fig. 4 shows the effect of Argon laser laser iridotomy. When medical and laser therapy are ineffective in lowering the IOP to target pressure or the patient is intolerant to medical therapy, surgical therapy is indicated. Usually, trabeculectomy, a guarded filtration procedure, with or without intraoperative anti-metabolites, is the primary procedure. In cases of eyes with active neovascularization or inflammation, a glaucoma drainage implant may be used as the primary procedure.

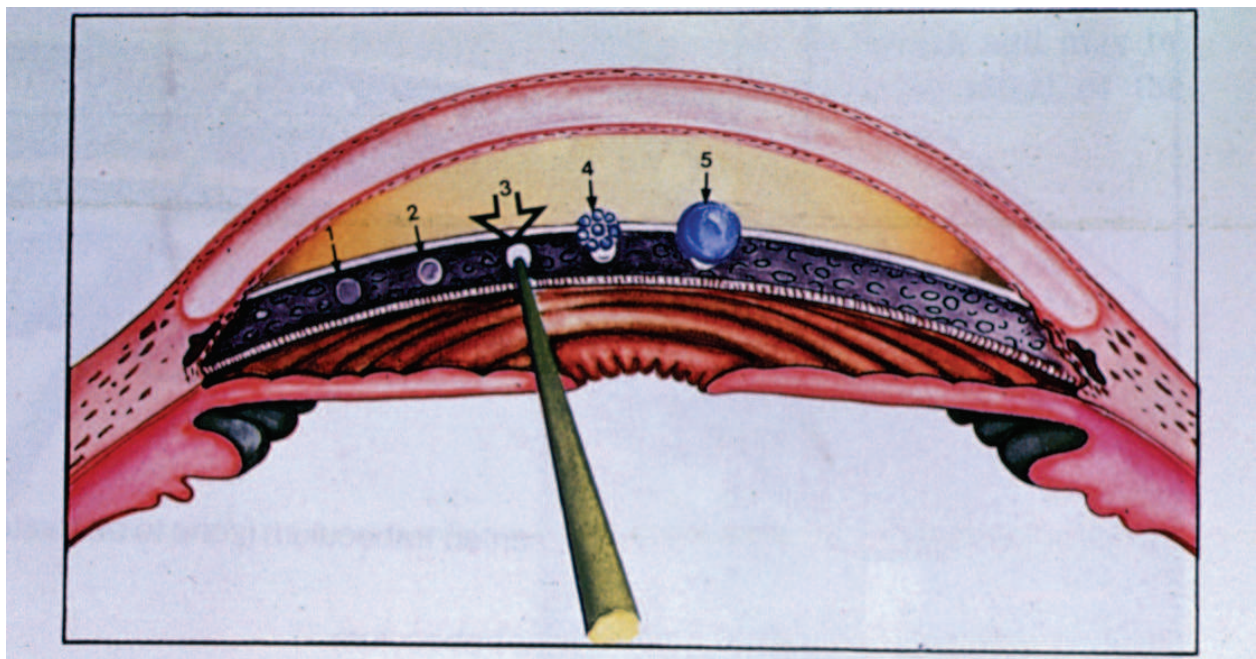


Fig. 2. ALT Argon Laser Trabeculoplasty

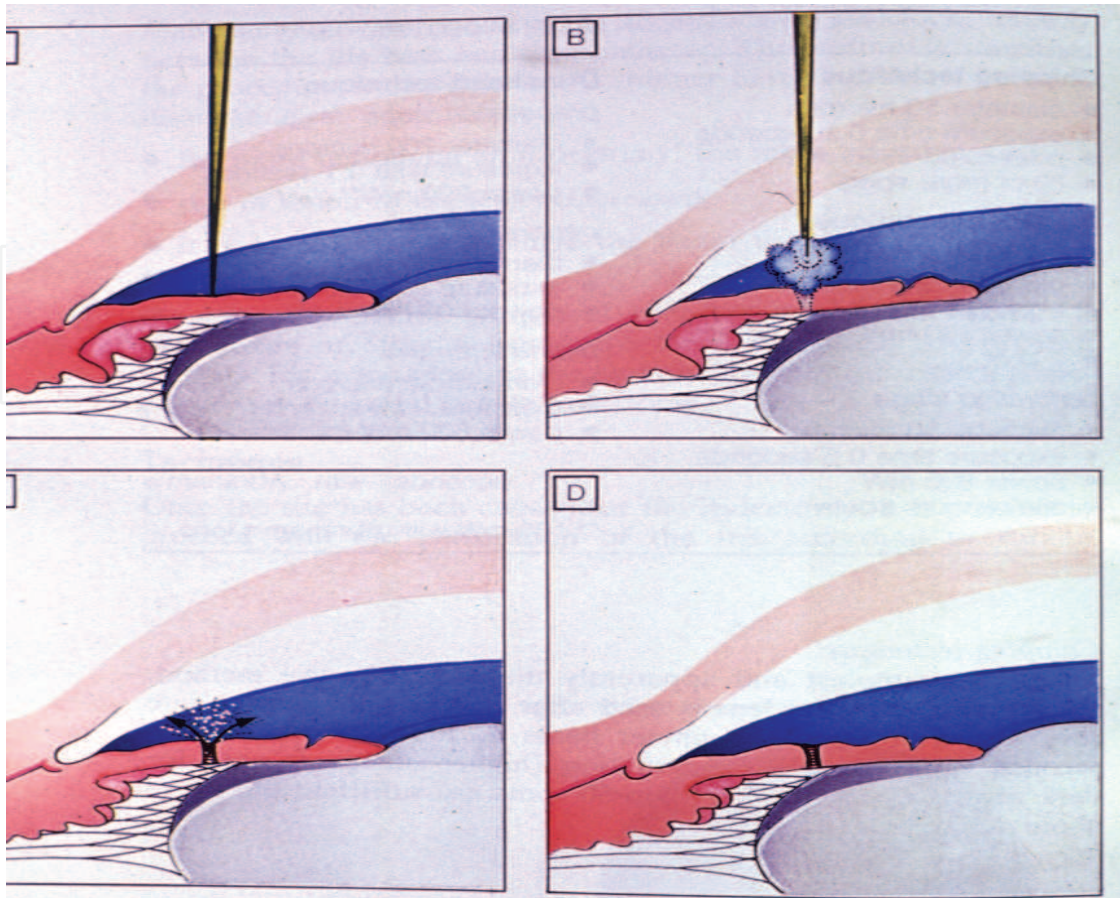


Fig. 3. LI Laser Iridotomy

6.4 Surgical: Closed-angle

Trabeculectomy can also be performed with similar indications as open-angle glaucoma. However, the surgery is more difficult since the anterior chamber is shallower and the cornea is usually hazier due to the acute IOP rise.

7. Prevention of drug induced glaucoma

7.1 Open-angle

Unnecessary prolonged use of corticosteroid should be avoided. Ophthalmic evaluation is recommended for patients treated with long-term steroids especially with risk factors such as family history of primary open-angle glaucoma.

7.2 Closed-angle

Prophylactic laser iridotomy may be performed in patients requiring frequent mydriasis such as frequent fundus examinations for diabetic retinopathy. Agents causing secondary angle-closure should be avoided in susceptible individuals as far as possible.

8. Conclusion

Drugs that cause or exacerbate open-angle glaucoma are mostly glucocorticoids. Several classes of drugs, including adrenergic agonists, cholinergics, anticholinergics, sulpha-based

drugs, selective serotonin reuptake inhibitors, tricyclic and tetracyclic antidepressants, anticoagulants and histamine H(1) and H(2) receptor antagonists, have been reported to induce or precipitate acute angle-closure glaucoma, especially in individuals predisposed with narrow angles of the anterior chamber. In some instances, bilateral simultaneous development of acute ACG occurs after carbamazepine and topiramate intake may occur especially in eyes with short axial length such as hypermetropia, microphthalmia and nanophthalmos. Clinicians should be mindful of the possibility of drug-induced glaucoma, whether or not the drug is listed as a contraindication and if in doubt, consult an ophthalmologist. Patients should visit an ophthalmologist routinely twice a year after the age of 40 and inform him about their different medications.

9. Acknowledgment


I acknowledge the support of Tradis Gat Ltd. in publication of this chapter.

10. References

- [1] Matz T, Abbott L. Bilateral acute angle-closure glaucoma. *Resident and Staff Physician* 2008; 54:3.
- [2] Kakaria V, Chalam, Tillis T, Farhana S, Brar SA. Acute bilateral simultaneous angle closure glaucoma Topiramate administration: a case report. *J Med Case Reports* 2008; 2:1.
- [3] GuMHP, Thiagalingam S, Ong P, Goldberg I. Bilateral acute angle closure caused by supraciliary effusion associated with Velafaxine intake. *MJA* 2005; 182:121-123.
- [4] Nemet A, Neshet R, Almog Y, Assia E. Bilateral acute angle closure glaucoma following Topiramate treatment. *Harefuah* 2002; 141:597-9.
- [5] Ates H.; Kay O., Lu K., Andac K. Bilateral angle closure glaucoma following general anesthesia: *International Ophthalmology* 1999; 23:129-30.
- [6] Singh SK, Thapa SS, Badhu BP. Topiramate induced bilateral angle-closure glaucoma. *Kathmandu University Medical Journal* 2007; 5:234-.
- [7] Lachkar Y, Bouassida W. Drug-induced acute angle closure glaucoma. *Curr Opin Ophthalmol* 2007; 18:129-33.
- [8] Chan KCY, Sachdev N, Wells AP. Bilateral acute angle closure secondary to uveal effusions associated with Flucloxacillin and Carbamazepine. *Br J Ophthalmol* 2008; 92:428-430.
- [9] Levy J, Yagev R, Petrova A, Lifshitz T. Topiramate - induced bilateral angle-closure glaucoma. *Can J Ophthalmol* 2006; 41:221-5.
- [10] Sean Sweetman (Ed.). Martindale-the complete drug reference, 36th edition, 471-477.
- [11] Brockhurst RJ. Nanophthalmos with uveal effusion: A new clinical entity. *Trans Am Ophthalmol Soc* 1974; 72:371-403.
- [12] Arnaly MF. Statistical attributes of the steroid hypertensive response in the clinically normal eye. I. the demonstration of three levels of response. *Invest Ophthalmol* 1965; 4:187.
- [13] Stewart RH, Kimbrough RL. Intraocular pressure response to topically administered fluorometholone. *Arch. Ophthalmol* 1979; 97:2139.
- [14] Mandelkom R. Drug induced Glaucoma, clinical pathway in glaucoma, in :Zimmerman and Kooner, New York: Thieme Medical Publishers inc. 2001 350-333

- [15] Kinek M. Glaucoma following the antidepressant mianserin. *Harefuah* 1990;118-699.
- [16] Hook SR, Holladay JL, Perager TC, Goosey JD. Transient myopia induced by sulphonamides. *Am J Ophthalmol* 1986; 101:495.
- [17] Friedman Z, Neuman E. Benzhexalol induced blindness in Parkinson's disease. *Br Med J* 1972; 1:605.
- [18] Mody MV, Keeney AH. Propantheline (probanthine) bromide in relation to normal and glaucomatous eyes: effects on intraocular tension and pupillary size. *JAMA* 1955; 159:1113.
- [19] Katz RI, Eakins KB. Mode of action of succinylcholine on intraocular pressure. *J Pharmacol Exp Ther* 1968; 162:1.
- [20] Bard L.A. Transient myopia associated with promethazine (phenergan) therapy: report of a case. *Am J Ophthalmol* 1964; 58:682?
- [21] Malawi JT, Rhobinson GM, Seneviratne H. Ipratropium bromide induced angle closure glaucoma (letter). *NZ Med J* 1982; 95:759.
- [22] Monica ML, Hesse RJ, Messerli FH. The effect of a calcium channel blocking agent on intraocular pressure. *AM J Ophthalmol* 1983; 96:814.
- [23] Kupfer C. Selective block of synaptic transmission in ciliary ganglion by type A botulinum toxin in Rabbits. *Proc Soc Exp Biol Med* 1958; 99:474.
- [24] Adelman RA, Zheng Q, Mayer HR. Persistent ocular hypertension following intravitreal bevacizumab and ranibizumab injections. *J Ocul Pharmacol Ther.* 2010 Feb; 26(1):105-10.
- [25] Milko E, Iliev, Diego Doming, Ute, Sebastin Wolf, Intravitreal Bevacizumab (Avastin®) in the Treatment of Neovascular Glaucoma. *AJO* Volume 142, Pages 1054-56, Dec. 2006.

IntechOpen



Glaucoma - Basic and Clinical Concepts

Edited by Dr Shimon Rumelt

ISBN 978-953-307-591-4

Hard cover, 590 pages

Publisher InTech

Published online 11, November, 2011

Published in print edition November, 2011

This book addresses the basic and clinical science of glaucomas, a group of diseases that affect the optic nerve and visual fields and is usually accompanied by increased intraocular pressure. The book incorporates the latest development as well as future perspectives in glaucoma, since it has expedited publication. It is aimed for specialists in glaucoma, researchers, general ophthalmologists and trainees to increase knowledge and encourage further progress in understanding and managing these complicated diseases.

How to reference

In order to correctly reference this scholarly work, feel free to copy and paste the following:

Eitan Z. Rath (2011). Drug-Induced Glaucoma (Glaucoma Secondary to Systemic Medications), Glaucoma - Basic and Clinical Concepts, Dr Shimon Rumelt (Ed.), ISBN: 978-953-307-591-4, InTech, Available from: <http://www.intechopen.com/books/glaucoma-basic-and-clinical-concepts/drug-induced-glaucoma-glaucoma-secondary-to-systemic-medications->

INTECH
open science | open minds

InTech Europe

University Campus STeP Ri
Slavka Krautzeka 83/A
51000 Rijeka, Croatia
Phone: +385 (51) 770 447
Fax: +385 (51) 686 166
www.intechopen.com

InTech China

Unit 405, Office Block, Hotel Equatorial Shanghai
No.65, Yan An Road (West), Shanghai, 200040, China
中国上海市延安西路65号上海国际贵都大饭店办公楼405单元
Phone: +86-21-62489820
Fax: +86-21-62489821

© 2011 The Author(s). Licensee IntechOpen. This is an open access article distributed under the terms of the [Creative Commons Attribution 3.0 License](#), which permits unrestricted use, distribution, and reproduction in any medium, provided the original work is properly cited.

IntechOpen

IntechOpen