

We are IntechOpen, the world's leading publisher of Open Access books Built by scientists, for scientists

4,800

Open access books available

122,000

International authors and editors

135M

Downloads

Our authors are among the

154

Countries delivered to

TOP 1%

most cited scientists

12.2%

Contributors from top 500 universities



WEB OF SCIENCE™

Selection of our books indexed in the Book Citation Index
in Web of Science™ Core Collection (BKCI)

Interested in publishing with us?
Contact book.department@intechopen.com

Numbers displayed above are based on latest data collected.

For more information visit www.intechopen.com



Novel Glaucoma Surgical Devices

Parul Ichhpujani¹ and Marlene R. Moster²

¹*Glaucoma Facility, Department of Ophthalmology,
Government Medical College and Hospital, Chandigarh,*

²*Anne and William Goldberg Glaucoma Service,
Wills Eye Institute, Philadelphia, PA,*

¹*India*

²*USA*

1. Introduction

An ideal glaucoma procedure is the one that is easy to perform, reproducible, with a low incidence of early postoperative hypotony, and long-term adequate IOP control. Furthermore, it should be minimally cataractogenic, allow rapid visual recovery and have the potential to be combined with phacoemulsification without one procedure potentially affecting the outcome of the other. Unfortunately, the quest for an ideal glaucoma procedure is on. The Landmarks in the course of surgical innovations for glaucoma management highlight the fact that we have come a long way.

Landmarks in the history of surgical innovations for glaucoma

- 1857 - Albrecht von Graefe: Surgical iridectomy "to reduce aqueous production" in glaucoma. Iridectomy helped many cases of angle closure, but not by the mechanism proposed.
- 1859 - Coccius: Iridectomy with iris inclusion
- 1876 - Argyll-Robertson: Scleral trephination
- 1878 - Louis De Wecker: Anterior sclerectomy
- 1903 - Bader and Lagrange: Iridosclerectomy
- 1905 - Heine: Cyclodialysis
- 1906 - Soren Holth: Iridenclesis
- 1909 - Elliot: Corneoscleral trephination
- 1924 - Preziosi: Electrocautery to create a full thickness fistula between the anterior chamber and the subconjunctival space.
- 1936 - Otto Barkan: Goniotomy for chronic glaucoma in adults.
- 1956 - Meyer-Schwickerath: Laser iridotomy with a xenon arc photocoagulator.
- 1958 - Harold Scheie: Modified Preziosi's procedure. Entered the eye with a knife and then used cautery to extend the scleral wound.
- 1968 - Cairns: Trabeculectomy. Removed a rectangular section of trabecular meshwork and deep cornea. He aimed to remove a block of the canal of Schlemm to get aqueous to flow freely into its cut ends.

- 1968 - Anthony Molteno: Glaucoma drainage device that directly shunted aqueous from the anterior chamber into a episcleral reservoir.
- 1976 - Theodore Krupin: First valved glaucoma drainage tube, at first without a reservoir.
- 1979 - James B. Wise and Stanton L. Witter: Argon laser "trabeculoplasty."
- 1982 - Robert Ritch: Iridoplasty for acute angle closure crisis unresponsive to medication.
- 1983 - Chen Wu Chen: Mitomycin C as an adjunctive in trabeculectomy.
- 1984 - 5-Fluorouracil was first reported in an animal model and in a pilot study in glaucoma filtering surgery.
- 2002 - ExPRESS miniature glaucoma shunt
- 2003 - Reay Brown and Mary Lynch: EYEPASS glaucoma shunt
- 2004 - George Baerveldt and Don Minckler: FDA approved, Trabectome microelectrocautery device
- 2004 - Richard Hill and Mory Ghareb: Trabecular micro-bypass stent, iStent. Undergoing FDA review
- 2005 - Deep light Gold shunt
- 2009 - Bruce Shields: Aquashunt
- 2009 - Transcend CyPass glaucoma implant

2. Trabeculectomy

Despite several available options, trabeculectomy – arguably is the most-performed glaucoma surgery till today. Although improved techniques and the adjunctive use of antimetabolites has enhanced long-term success as measured by intraocular pressure (IOP) control, trabeculectomy has a sizeable risk profile to glaucoma patients, over both the short and long term.

Blebitis, bleb related endophthalmitis, hypotony, overfiltration, bleb leaks, bleb fibrosis and encapsulation, bleb overhang, corneal endothelial cell loss, dellen, and aqueous misdirection are among the many risks associated post trabeculectomy. (Borisuth et al, 1999)

3. Drainage devices

Glaucoma drainage devices (GDD) were initially developed for use in complex glaucoma patients, many of whom had failed medical, laser, and prior surgical treatments. (Molteno, 1969; Krupin et al., 1976; Lloyd et al., 1994 & Coleman et al., 1995) Typically, these devices consist of a tube placed into the anterior chamber to allow for aqueous humor to flow posteriorly into an encapsulated filtration area typically 10–12 mm posterior to the limbus, into a reservoir sutured to the sclera.

Though complications associated with anterior bleb formation were avoided, GDD resulted in a high risk of hypotony and overfiltration, sometimes leading to suprachoroidal hemorrhage. As a result several measures for flow restriction and regulation were adopted, but despite all efforts complication profile of GDD is significant. Overfiltration, fibrosis, tube exposure, tube occlusion, tube retraction and diplopia to list a few potential complications. (Kupin et al., 1995; Ticho and Ophir, 1993 & Gedde et al., 2007)

Since neither trabeculectomy nor GDDs are without their fair share of complications, the quest for the development and advancement of glaucoma surgery to provide alternative means of shunting aqueous humor out of the anterior chamber is on.

Surgical procedures augmenting either conventional outflow pathway or uveoscleral outflow pathway have been developed. For conventional outflow enhancement, goniosurgical procedures (Epstein et al., 1985) and surgeries involving schlemm canal (both ab interno and ab externo) have recently emerged as successful surgical options.

Surgical approaches to augment suprachoroidal outflow have also been explored with cyclodialysis, suprachoroidal implants, seton devices, and most recently, an ab externo gold shunt placed in the suprachoroidal space. (Pinnas and Boniuk, 1969; Krejci, 1972; Ozdamar et al., 2003; Jordan et al., 2006)

Type	Glaucoma surgery
Non penetrating	Viscocanalostomy Deep sclerectomy Canaloplasty
Minimally penetrating	Ex-PRESS glaucoma filtration device Trabecular micro-bypass iStent Trabectome microelectrocautery Gold microshunt (GMS) device Eyepass implant
Penetrating	Trabeculectomy

Table 1. Types of glaucoma surgeries

This chapter, addresses the available knowledge for the novel drainage devices; devices which attempt to assist with flow regulation such as the Ex-PRESS mini-glaucoma shunt (Alcon Laboratories, Inc., Fort Worth, TX) (Wamsley et al., 2004), Schlemm's canal surgical procedures, including nonpenetrating canaloplasty surgery (Lewis et al., 2007), the Glaukos trabecular micro-bypass iStent (Nichamin, 2009) the Trabectome microelectrocautery device (Nguyen, 2008) and the suprachoroidal outflow gold microshunt device (GMS) (Melamed et al., 2009) (Table 1). Published data is limited as many of these devices are currently in investigation and undergoing clinical trials.

4. Minimally penetrating procedures

4.1 Ex-PRESS glaucoma filtration device

Ophthalmic surgery has evolved over the last several decades into sophisticated microsurgery involving continually smaller incisions. The Ex-PRESS shunt is on the forefront of this evolution toward smaller incision glaucoma filtration surgery. Since there is an added cost to using the Ex-PRESS rather than trabeculectomy, its place in the surgical management of glaucoma has not been clear so far.

Device

Ex-PRESS stands for "excessive pressure regulating shunt system".

The Ex-PRESS implant is a miniature unvalved glaucoma implant. It was originally developed by Optonol, Ltd. (Neve Ilan, Israel), as an alternative procedure to trabeculectomy

and to the other types of glaucoma filtering surgery for patients with open angle glaucoma (Nyska et al., 2003). Now, it is available as EX-PRESS Glaucoma Filtration Device (Alcon Laboratories, Inc., Fort Worth, TX).

The device is approximately 3 mm long, stainless steel tube (outer diameter 400 μm (27 gauge)) with a beveled, sharpened, rounded tip, a disc-like flange (<1 mm²) at the device proximal end, and a spur-like projection that prevents its extrusion. (Nyska et al., 2003; Geffen et al., 2010) The external flange and inner spur are angled to conform to the anatomy of the sclera, and the distance between them corresponds to the scleral thickness at the site of implantation.

The EX-PRESS® Glaucoma Filtration Device is preloaded on a specially designed disposable introducer, the EX-PRESS® Delivery System (EDS). The EDS is an inserter designed to maintain the correct orientation of the EX-PRESS® Glaucoma Filtration Device throughout the implantation procedure. The commercially available versions are: R-50, P-50 and P-200. (Table 2; Figure 1)

Characteristic	Ex PRESS R50	Ex PRESS P50	Ex PRESS P200
External body device	Round	Round	Round
Device length	2.96	2.64	2.64
Internal lumen size	50	50	200
Tip shape	Pointed	Pointed	Pointed
Backplate shape	Uniform	Vertical split	Vertical split
Preincision needle gauge	27G	25G	25G

Table 2. Comparative characteristics of the available models of Ex- PRESS implant

Indications

- Open Angle Glaucoma refractory to medical and laser treatment
- Open Angle Glaucoma with a failed filtration procedure
- Combined glaucoma and cataract procedure (Ex-PRESS may have the advantage of faster visual recovery compared with trabeculectomy)
- Aphakic glaucoma (As no iridectomy is required with the Ex-PRESS implantation, there is less risk of vitreous moving forward through a new iridectomy)
- Sturge-Weber syndrome and other situations as high hyperopia and nanophthalmos (Since chances of choroidal effusions following trabeculectomy are high in these subset of patients; Ex-PRESS implantation may offer a safer alternative because of its lower rate of prolonged postoperative hypotony)

Contraindications

The implantation of the EX-PRESS® Glaucoma Filtration Device is contraindicated if one or more of the following conditions exist:

- Presence of ocular disease such as uveitis, ocular infection, severe dry eye or severe blepharitis.
- Pre-existing ocular or systemic pathology that, in the opinion of the surgeon, is likely to cause postoperative complications following implantation of the device.
- Patient diagnosed with angle closure glaucoma.

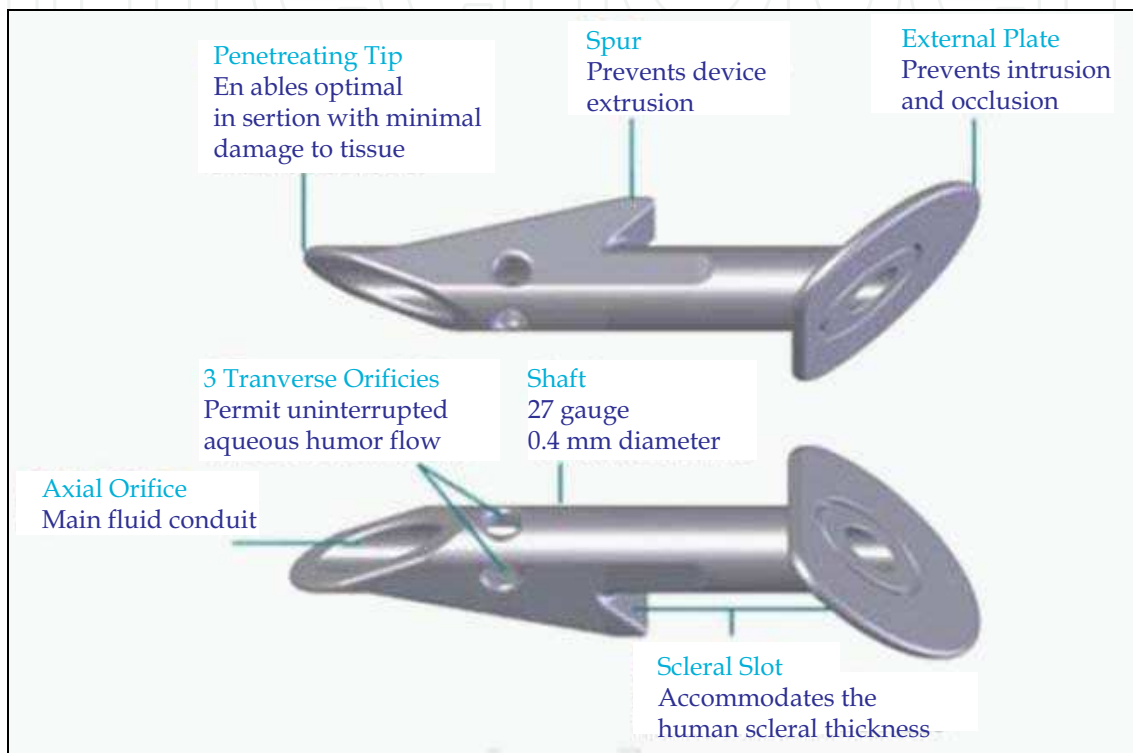


Fig. 1. R 50 Ex-PRESS device

Surgical procedure

Originally, the device was designed to be inserted at the limbus directly under the conjunctiva with formation of a subconjunctival bleb which served as a flow modulator. Poor conjunctival covering of the device, conjunctival erosions over the external flange and conjunctival scarring with subsequent decreased aqueous humour filtration, were some of the complications that were encountered because of direct subconjunctival implantation. (Kaplan Messa et al., 2002; Gandolfi et al., 2002; Traverso et al., 2005; Wamsley et al., 2004; Stewart et al., 2005; Rivier et al., 2007; Tavolato et al., 2006; Garg et al., 2005) Conjunctivoplasty or tube removal had to be performed to avoid secondary infection.

To overcome these complications, Dahan and Carmichael suggested implanting the device under a limbus based 50% deep scleral flap extending into clear cornea. (Dahan and Carmichael, 2005) This operation is similar to standard trabeculectomy without the need of an iridectomy or scleral removal.

This implant may also be used in deep sclerectomy to simplify the difficult dissection of Schlemm's canal and Trabeculo-Descemet's membrane.

4.2 Placement of device under a scleral flap

To place the Ex-PRESS filtration device, a conjunctival peritomy, limbal or fornix-based, is first created as in conventional trabeculectomy. Gentle cautery is applied to the sclera prior to creation of a scleral flap. The dimensions of the scleral flap may need to be slightly larger than the trabeculectomy flap and it should be initiated more posteriorly in order to ensure full coverage of the shunt plate.

Scleral spur is identified by a white, glistening band of fibers that crosses the bed of this section. The blue zone is a transition zone to the clear cornea. The surgeon should make sure that they implant the EX-PRESS device in the anterior chamber, just at the level of the scleral spur, but not too far posteriorly. It is important for the device to enter the eye exactly at the anterior aspect of the scleral spur and for it to remain at the iris plane so that it does not point downward towards the iris.

Once the scleral spur has been visualized, the anterior chamber should be filled with viscoelastic or air in the area of anticipated shunt entry. Rather than an ostium created by a punch, trephine, or scissors, a 25- or 27-gauge needle or a 400 μm wide blade is used to enter the anterior chamber at the level of the scleral spur, parallel to the iris, and the Ex-PRESS device is injected into this needle tract.

Complications

The Ex-PRESS device relies on nonphysiologic subconjunctival flow as its mechanism of IOP lowering. As a result, all of the issues that limit trabeculectomy and the complication profile associated with blebs accompany the Ex-PRESS shunt too, but to a much lesser extent.

Recently, external blockade of the tube has been reported as a possible device-related complication of Ex-PRESS implants, which can be visualized on a systematic gonioscopic examination. (Bagnis et al., 2011) It should be considered whenever IOP increases and a flat bleb is observed. Neodymium: Yttrium Argon Garnet (Nd:YAG) laser at the tip of the device is a viable therapeutic option to treat the external occlusion of Ex-PRESS devices, regardless the nature of the obstruction. Obstruction may also occur inside the lumen of the device where it may not be visualized by gonioscopy, at the point where the diameter constricts to 50 μm . Since this constriction point is close to the opening into the anterior chamber, Nd:YAG laser works in this scenario as well (Netland, 2011).

Corneal dislocation of the Ex-PRESS implant may occur and when associated with ocular hypertension, needs surgical treatment. (Vetrugno et al., 2011) Before considering a trabeculectomy, it could be valuable to attempt an implant reposition. Reopening of the conjunctiva and the scleral flap, excision of the corneal tissue covering the flange, and stitching the implant to the sclera with polypropylene suture has been tried with success.

The Magnetic Resonance Imaging (MRI) systems in clinical use today operate with magnetic fields ranging from 0.2 to 3.0 Tesla. To ascertain MRI compatibility, the Ex-PRESS glaucoma drainage device (316L stainless steel) has been examined for magnetic field interactions under standard 1.5, 3.0, and 4.7 T MRI scanning protocols. (Seibold et al., 2011) During induced torque testing, no displacement was noted under 1.5 and 3.0 T conditions, although a significant amount of displacement occurred in the 4.7 T environment. Increasing amounts of angular deflection were demonstrated at all three field strengths. So, it should be remembered that Ex-PRESS moves in the presence of high magnetic fields.

4.3 Scientific evidence so far

Ex-PRESS versus trabeculectomy

Maris et al in a retrospective comparative case series analysed data of 49 eyes with the Ex-PRESS and 47 eyes with a standard trabeculectomy. (Maris et al., 2007) The authors noted that although the mean IOP was significantly higher in the early postoperative period in the Ex-PRESS group compared with the trabeculectomy group, the reduction of IOP was similar in both groups after 3 months. The number of postoperative glaucoma medications in both groups was not significantly different. Kaplan-Meier survival curve analysis showed no significant difference in success between the two groups ($P = 0.594$). The success rate at an average of 11 months was 90% for the Ex-PRESS shunt compared with 92% for trabeculectomies at last follow up. Early postoperative hypotony and choroidal effusion were significantly more frequent after trabeculectomy than after Ex-PRESS implants under a scleral flap ($P < 0.001$). There was no difference between a limbal based or a fornix based approach with either procedure (trabeculectomy vs. Ex-PRESS shunt). After 3 months, the percentage decrease in IOP was similar for the groups, Ex-PRESS group (39.9 to 46.6%) and the trabeculectomy group (28.6 to 45.4%). For IOP control during the postoperative period, a significantly greater number of laser suture lysis procedures were performed in the Ex-PRESS group compared with the control group. The authors concluded that the Ex-PRESS implant under a scleral flap had similar IOP-lowering efficacy with a lower rate of early hypotony compared with trabeculectomy.

Ex-PRESS in previously operated eyes

Moster and co workers reported intermediate-term results of the Ex-PRESS implant (R-50 and T-50), under a scleral flap in previously operated eyes (cataract or failed glaucoma surgeries). (Lankaranian et al., 2010) To compare the outcome between patients who had previous trabeculectomy or cataract surgery the definition of success was IOP of 5-15mmHg. One hundred eyes of 100 patients were studied. The mean follow-up period was 27 ± 13.2 months (range: 12-66). Success was defined as complete if IOP was 5-21 mmHg without medication or surgical intervention, and qualified if IOP was within the same range with glaucoma medication. Success was complete in 60 (60%) and qualified in 24 (24%) eyes. The mean preoperative IOP of 27.7 ± 9.2 mm Hg (range, 14-52 mmHg) with 2.73 ± 1.1 drugs declined to 14.02 ± 5.1 mm Hg with 0.72 ± 1.06 drugs at the last follow up ($P < 0.0001$). The causes of failure were uncontrolled IOP (11%), bleb needling (4%), and persistent hypotony (1%). Bleb needling may induce an erratic wound healing response in some cases and lead to failure. The probability of success in the patients with previous cataract surgery and trabeculectomy at 3 years was 60.6% and 50.9%, respectively. Figure 2 shows Ex-PRESS implant in a case with previously failed trabeculectomy.

Ates and coworkers studied 15 eyes with postpenetrating keratoplasty glaucoma unresponsive to medical antiglaucomatous therapy in which Ex-PRESS mini glaucoma shunt implantation was done. (Ates et al., 2010)

IOP decreased from 41.46 mm Hg to 12.06 mm Hg over a mean follow-up of 12.2 months ($P < 0.001$).

IOP was below 21 mm Hg in 14 of 15 eyes (93.3%) with or without antiglaucomatous drugs. Complete success (IOP < 21 mm Hg without medication) rate was 86.6%. Average number of antiglaucomatous drug usage decreased from 3.20 (range: 2 to 4) preoperatively to 0.26 postoperatively (range: 0 to 3) ($P < 0.001$). In 93.3% of the cases, the decrease in IOP was 30%

or above postoperatively. After Ex-PRESS implantation, clear grafts remained clear while edematous grafts became clearer due to IOP decrease. Neither biomicroscopy nor pachymetry showed worsening of preoperatively opaque grafts.

Similarly, Vetrugno and colleagues also reported good results in vitrectomized patients who required glaucoma surgery for persistent ocular hypertension (Vetrugno et al., 2010).

Ex-PRESS with deep sclerectomy

Bissig and colleagues did a prospective, nonrandomized trial to study Deep Sclerectomy with the Ex-PRESS X-200 implant in 26 eyes. (Bissig et al., 2010) A posterior deep sclerectomy was dissected without opening the Schlemm's canal and an Ex-PRESS X-200 device was inserted under the scleral flap into the anterior chamber to drain aqueous humour into the intrascleral space. Eighty-five percent of patients achieved an IOP < 18 mmHg with or without medication and 69% without medication. Post-operative complications were hyphaema (15%), wound leak (15%), encysted blebs (54%) and bleb fibrosis in 8% of patients.

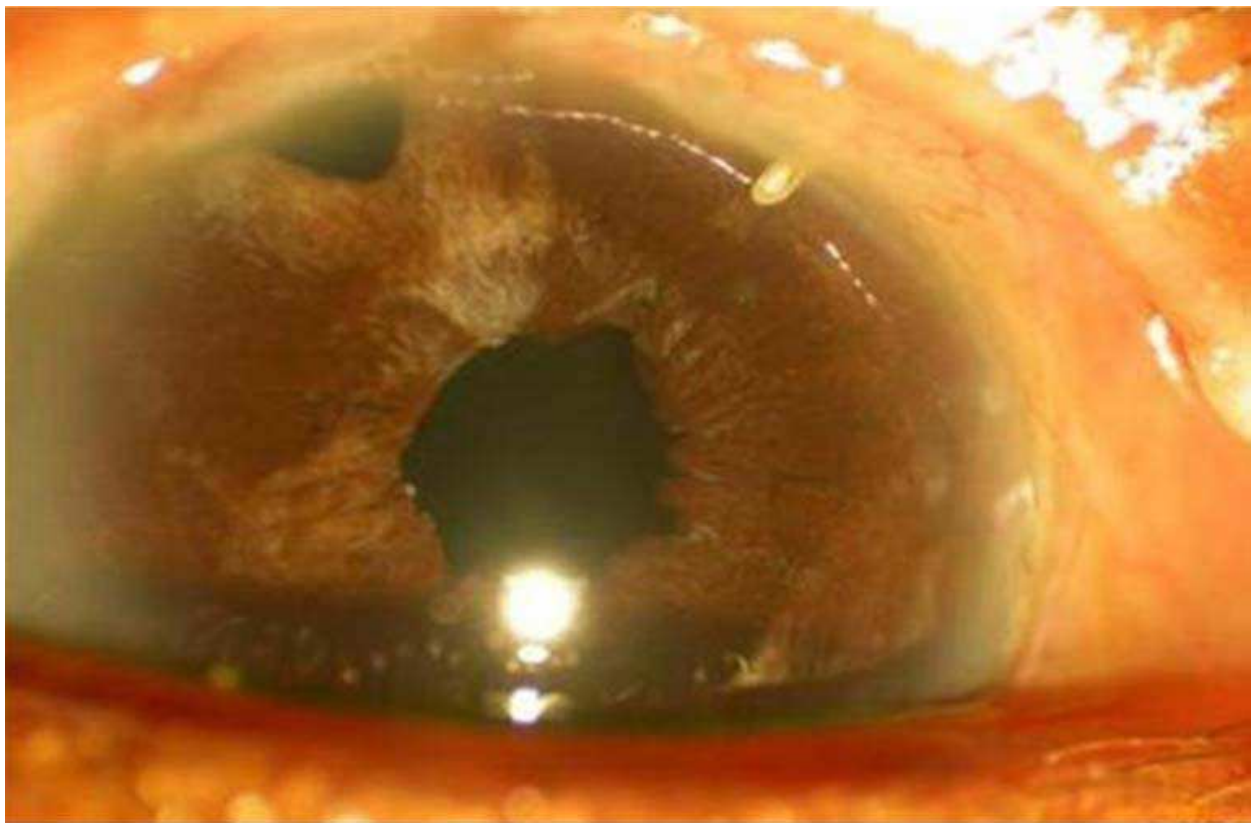


Fig. 2. Ex-PRESS in a previously failed glaucoma surgery

Gindroz and coworkers conducted a prospective study reporting on modified deep sclerectomy using the Ex-PRESS LR-50 in combined cataract and glaucoma surgery in 24 eyes. (Gindroz et al., 2011) Preoperative data had, IOP: 18.1 ± 5.3 mmHg, best-corrected visual acuity (BCVA): 0.6 ± 0.3 , and number of medications: 2.3 ± 1.1 . The IOP decreased by 25.4% at 24 months and by 27.0% at 48 months. At 24 months, 19 patients (86.3%) achieved a BCVA of 0.5 or better, and at 48 months the mean BCVA was 0.7 ± 0.3 . At the last visit, the mean number of medications reduced to 0.6 ± 0.8 ($P < 0.05$). The complete and qualified success rates were 45.6% and 85.2%. No conjunctival erosions over the Ex-PRESS LR-50 were noted.

Ex-PRESS with phacoemulsification

Kanner and co workers implanted Ex-PRESS device under a scleral flap either as a single procedure in 231 eyes of 200 patients or combined with cataract surgery in 114 eyes of 100 patients, for a total of 345 eyes in 300 patients who received the implant. (Kanner et al., 2009) They found that the Ex-PRESS implant under a scleral flap could lower IOP alone or in combination with cataract surgery. The most common device-related complication was blockage of the lumen of the implant, which was effectively treated with Nd:YAG laser treatment of the tube tip in the anterior chamber.

4.4 Place in surgical armamentarium

The advantages of this device as an adjunct to filtration surgery may be a lowered incidence of early postoperative hypotony and elimination of the need for a surgical iridectomy. The device is easily placed either temporally or nasally in an eye with prior scarring, as long as there are 2 to 3 clock hours of mobile conjunctiva available. There is often enough conjunctivae available between the side port vitrectomy scars to form a posterior bleb following a pars plana vitrectomy. Ex-PRESS requires less healthy tissue than for placement of a traditional drainage implant.

Since the resulting blebs are usually low and diffuse, there is little risk of developing dellen or bleb dysethesias, even when the surgery is located off to one side.

In eyes with prior failed trabeculectomies, Ex-PRESS can help to reestablish the aqueous flow without having to repeat the original procedure. The Ex-PRESS fits easily in the middle ground between a repeat trabeculectomy and a larger glaucoma drainage device like a Baerveldt, Molteno, or an Ahmed tube shunt.

Additionally, because of the technical familiarity of trabeculectomy, the learning curve for the incorporation of this device into filtering surgery is not a steep one, and it has shown to be effective when combined with phacoemulsification.

Initial doubts about the Ex-PRESS filtration device are decreasing with recent advances offering possibly a wider spectrum of indications while diminishing the potential complications.

5. Trabecular bypass devices

The site of abnormal outflow resistance within the meshwork is probably the juxtacanalicular tissue adjacent to Schlemm's canal, a layer of the meshwork approximately 10 μm thick. Removal or bypassing this thin layer of tissue should decrease the elevated IOP, without the need for creating a hole in the sclera and a filtration bleb.

Recent work has focused on using small tubes to bypass the meshwork, creating a direct route from the anterior chamber into Schlemm's canal. (Razeghinejad and Spaeth, 2011)

5.1 Trabecular micro-bypass iStent

Device

The iStent® trabecular micro-bypass stent (Glaukos Corp, Laguna Hills, California) is the first *ab-interno* micro bypass stent. It is a heparin-coated with Duraflo (Edwards Lifesciences, Irvine, CA), nonferromagnetic, surgical grade titanium (Ti6Al4V ELI) stent less than one mm in length and approximately 0.3 mm in height, with a snorkel length of 0.25 mm and a nominal snorkel bore diameter of 120 μm . It is about 1/5000 of the size of the Baerveldt

implant. (Samuelson et al., 2011) The iStent® is inserted through a small temporal clear corneal incision, bypassing the trabecular meshwork, and placed in Schlemm's canal at the lower nasal quadrant. The dimensions of the stent are customized for a natural fit and retention within the 270 μ canal space, with three retention arches to ensure secure placement.

Indications

- Mild-to-moderate primary open angle glaucoma
- Pigmentary glaucoma
- Pseudoexfoliative glaucoma, stand alone or in combination with cataract surgery.

Contraindications

- Presence of ocular disease such as uveitis, ocular infection
- Patients diagnosed with angle closure glaucoma

Surgical technique

The iStent® is preloaded in a single-use, light release force, sterile applicator (Figure 3) with a secure, rotatable grip to facilitate manipulation and placement into Schlemm's canal. Separate orientations of the stent are available for the right and left eye. iStent® implantation can be performed under topical anesthesia. Prior to implanting the iStent®, the angle anatomy and targeted stent site must be in clear view. The Swan-Jacob gonioprism is used to inspect the angle to ensure a good view at the nasal implant location. The iStent® is implanted through the same small, temporal, clear corneal incision used for phacoemulsification or a 1.5 mm incision when the stent is implanted as a stand-alone procedure. iStent is inserted in trabecular meshwork with “*Penetrate, lift and slide*” insertion technique.

For best possible angle visualization; iStent® insertion should be performed from the temporal side with the microscope magnified 12X and tilted towards the surgeon. The patient's head is tilted away from the surgeon.

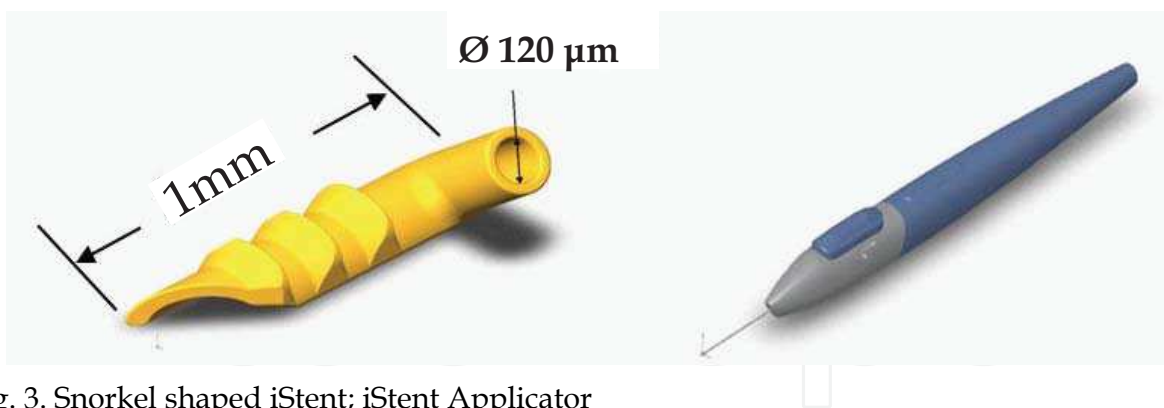


Fig. 3. Snorkel shaped iStent; iStent Applicator

Implantation is performed in the nasal position (3 to 4 o'clock for the right eye; 8 to 9 o'clock for the left eye) with the tip of the implant directed inferiorly. The tip of the stent should approach the trabecular meshwork at 15° angle to facilitate penetration of the tissue (Figure 4). Excessive resistance indicates that the approach is too perpendicular to the trabeculum. Once the stent is covered with meshwork it is released by pressing the applicator button. Only the proximal end of the stent remains visible in the anterior chamber. The iStent® is seated into position by gently tapping the side of the snorkel with the applicator tip. A small reflux of blood from the Schlemm's canal reflects correct positioning of the stent. Extraction of the viscoelastic material and hydration of the corneal incision conclude the procedure.

Proper stent placement is confirmed by flushing the anterior chamber of any refluxed blood, performing a high-magnification examination to confirm that the base of the implant is parallel with the circumferential axis of the Schlemm canal, and gently nudging the snorkel to confirm that the snorkel axis is parallel with the iris plane and that the base is well seated and fully through the trabecular meshwork.




Fig. 4. Technique of iStent implantation

Complications

The stent is small (1 mm) and hence it may sometimes be difficult to verify exact placement of the implant via gonioscopy, particularly in cases of corneal edema, peripheral anterior synechiae, or an uncooperative or anxious patient. In such cases there is a possibility of accidentally misplacing the iStent. Ichhpujani and coworkers carried out an in vitro study, in which they used a human cadaver eye, unsuitable for transplantation, as a model to visualize the position of the stent. (Ichhpujani et al., 2010) They reported that in cases where gonioscopy is not successful, UBM can aid in localization of the iStent, in both the anterior and posterior chambers, provided the probe is moved to provide a favorable signal, whereas AS-OCT is limited to detection of stents in the anterior chamber alone and B-scan is of no value.

A theoretical problem with bypass of the meshwork is blood reflux from Schlemm's canal into the anterior chamber via the tube, creating a microhyphema. Any activity that raises episcleral venous pressure higher than IOP, such as prolonged bending with the head down or vigorous Valsalva maneuver, would be most likely to cause this problem. Since such maneuvers also increase IOP by increasing the choroidal blood volume, this would counter the elevated episcleral venous pressure. This may explain why microhyphemas have not been reported till date with an iStent.

5.2 Scientific evidence so far

US iStent Study group assessed the safety and efficacy of the iStent in combination with cataract surgery in subjects with mild to moderate open-angle glaucoma. (Samuelson et al., 2011) A total of 240 eyes with mild to moderate open-angle glaucoma with IOP \leq 24 mmHg controlled on 1 to 3 medications were randomized to undergo cataract surgery with iStent implantation (treatment group) or cataract surgery only (control). The primary efficacy measure was unmedicated IOP \leq 21 mmHg at 1 year. The study met the primary outcome, with 72% of treatment eyes versus 50% of control eyes achieving the criterion ($P < 0.001$). At 1 year, IOP in both treatment groups was statistically significantly lower from baseline values. Sixty-six percent of treatment eyes versus 48% of control eyes achieved \geq 20% IOP

reduction without medication ($P < 0.003$). The overall incidence of adverse events was similar between groups with no unanticipated adverse device effects.

The ocular hypotensive efficacy seen with the stent in this study was found to be consistent with the trabecular bypass mechanism of action and results described in literature. (Fea, 2010; Spiegel et al., 2008 & 2009)

Compared with cataract surgery alone, implantation of the iStent concomitant with cataract extraction significantly increases trabecular outflow facility, reduces IOP and the number of medications. (Fernandez- Barrientos et al., 2010)

A study in cultured human anterior segments has shown that a single stent created the largest change in IOP, resulting in a mean of 12.4 ± 4.2 mm Hg, corresponding to an 84% increase in facility of outflow. Interestingly, IOP seemed to reach a baseline level of approximately 12 mm Hg, even with multiple stents. (Bahler et al., 2004)

The probable explanation is that only one is enough to bypass the barrier of the Schlemm's canal and the lumen of the iStent is large enough to drain the aqueous as if the Schlemm's wall is well functioning.

5.3 Place in the surgical armamentarium

The iStent is believed to reestablish natural trabecular outflow, and it leaves the conjunctiva untouched, and avoids the lifelong risk of complications associated with filtering blebs. Thus, iStent implantation in patients with mild to moderate open-angle glaucoma undergoing cataract surgery represents a novel therapeutic approach that provides clinically significant reductions in IOP and medication use.

5.4 Trabectome electrocautery device

Device

The Trabectome surgical device was cleared by the US Food and Drug Administration in January 2004 for the treatment of adult and juvenile open-angle glaucoma. The concept is similar in principle to *ab interno* trabeculotomy, the key difference being that a microelectrocautery device is used to ablate a strip of the trabecular meshwork and inner wall of Schlemm's canal, thus allowing direct access of aqueous to the collector channels. This theoretically bypasses the main site of resistance to aqueous outflow and reestablishes the natural drainage passageway out of the eye.

The Trabectome consists of a disposable footpedal activated handpiece and a console to adjust infusion, aspiration and electrocautery energy. The handpiece consists of a 19-gauge infusion sleeve, a 25-gauge aspiration port, and a bipolar electrocautery unit 150 μm away from an insulated footplate (Figure 5). The footplate is 800 μm in length from the heel to the tip, has a maximum width of 230 μm , and maximum thickness of 110 μm .

Indications

Trabectome may be an excellent surgical option for patients who require postoperative IOPs in the mid-to-high teens. It can be combined with cataract surgery.

- Early to moderate Primary open-angle glaucoma
- Pigmentary and pseudoexfoliative glaucoma.
- Patients with elevated IOP despite previous glaucoma surgery (trabeculectomy or a drainage tube)

Contraindications

Angle closure with or without peripheral anterior synechiae is the only contraindication. Trabecular meshwork without pigment may pose difficulty for proper gonioscopic identification of structures.

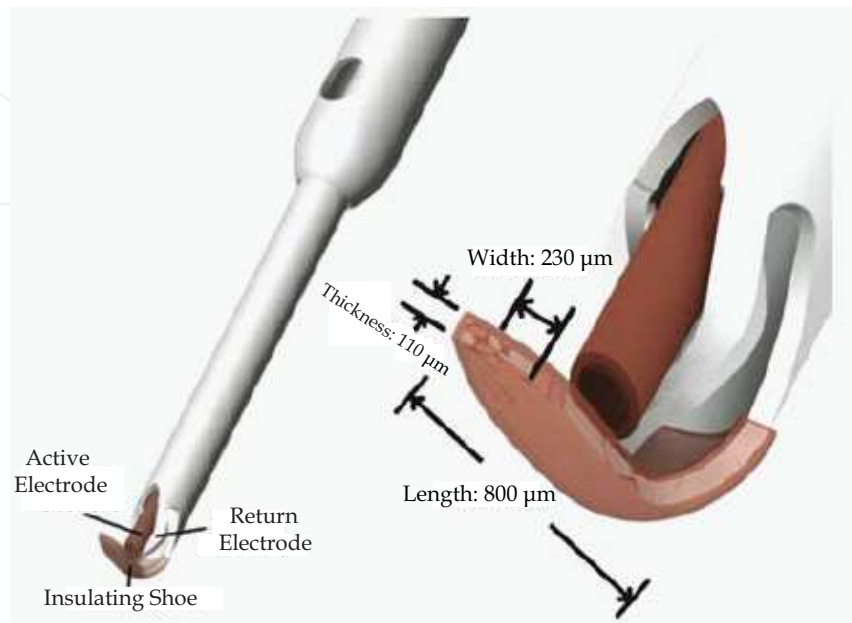


Fig. 5. Trabectome hand piece

Surgical procedure

Surgery is carried out with a temporal approach through a clear corneal incision of 1.6-1.8 mm to accommodate the electrocautery unit. Alternatively, when combined with clear cornea coaxial phacoemulsification, the main incision may be used for the Trabectome handpiece. Ophthalmic visco-devices are used to inflate and stabilize the anterior chamber and a gonioprism is used for direct visualization of the angle. Once the instrument has been inserted into Schlemm's canal, the foot pedal is depressed to begin electrocautery. The surgeon's hand simultaneously moves in one direction to ablate the tissue until the tip of the handpiece has reached the limit of visibility. The handpiece may then be turned to achieve ablation in the opposite direction again, to the limits of view. Total arc length amenable to treatment through a single incision is 60-90°. Tissue debris released during electrocautery can obscure the view hence aspiration and continuous irrigation are carried out. A clear corneal suture is applied and intracameral air is injected at the conclusion of Trabectome ablation to prevent postoperative hyphema.

When combined Trabectome and cataract surgery are done then the ab interno trabeculotomy is completed before starting the phacoemulsification. This order of operation prevents the formation of phacoemulsification-related corneal edema that could impair visualization of the angle structures.

Too low power settings and rapid movement of the handpiece should be avoided as it may lead to inadvertent tear of the trabecular meshwork and cause tissue from the inner wall of Schlemm's canal to accumulate in the gap of the footplate. In addition, the surgeon should make sure that the eye does not rotate during the treatment, as this indicates excessive pressure on the posterior wall of Schlemm's canal.

Many surgeons advocate the use of pilocarpine 1% 1 to 2 hours prior to Trabectome-only surgery to improve surgical visualization of the angle and to protect the crystalline lens in phakic patients. Postoperatively, pilocarpine can enhance aqueous outflow and prevent the development of peripheral anterior synechiae. The tapering of glaucoma medications is generally undertaken approximately 1 month after surgery.

The procedure has a learning curve, especially for surgeons not familiar with operating temporally or with various patient head positions.

Complications

Transient hyphemas are the typical complication, clearing within a few days. Other complications are rare in this procedure, but can include iridodialysis, cyclodialysis, and IOP spike. Sustained hyphema, wound leak, infection, choroidal effusion, and hemorrhage are not typically seen after this procedure.

5.5 Scientific evidence so far

Minckler et al reported a retrospective case series of 1127 Trabectome surgeries, with 738 Trabectome-only and 366 Trabectome-cataract surgeries. (Minckler et al., 2008) Overall, IOP reduced to 39% at 24 months (n=50), and with Trabectome only cases (n=46) the reduction was 40%. Surgery combined with cataract removal (n=45) showed an 18% decrease in IOP at 12 months. Medications were decreased by at least half in each cohort.

Francis et al for the Trabectome study group reported the short-term results of combined phacoemulsification and trabeculotomy by the internal approach with a follow-up to 21 months. (Francis et al., 2008) This prospective interventional case series comprised of 304 consecutive eyes with open-angle glaucoma and cataract having combined phacoemulsification and trabeculotomy with a Trabectome. The mean IOP was 20.0 mm Hg \pm 6.3 (SD) preoperatively, 14.8 \pm 3.5 mm Hg at 6 months, and 15.5 \pm 2.9 mm Hg at 1 year. There was a corresponding drop in glaucoma medications from 2.65 \pm 1.13 at baseline to 1.76 \pm 1.25 at 6 months and 1.44 \pm 1.29 at 1 year. Subsequent secondary glaucoma procedures were performed in 9 patients. The only frequent complication, blood reflux in 239 patients (78.4%), resolved within a few days.

Previous laser trabeculoplasty does not appear to significantly impact IOP, but may increase the need for glaucoma medication in patients undergoing Trabectome surgery (Vold and Dustin, 2010).

5.6 Place in surgical armamentarium

Early clinical experience with this technology has shown that patient selection, surgical technique, and postoperative medical management affect patients' outcomes. Though it is efficacious in IOP lowering, we still do not know what is the maximal amount of IOP lowering that can be attained, and whether this relates to other factors such as episcleral venous pressure.

5.7 Canaloplasty

Canaloplasty is an *ab externo* procedure which entails 360° intubation of Schlemm's canal, along with suture-assisted distension of the canal in order to restore physiologic outflow via the conventional pathway without the formation of a fistula or bleb (Khaimi, 2009). The iTrack 250 flexible microcatheter (iScience Interventional, Menlo Park, CA) for canaloplasty received FDA approval in 2008.

Device

The iScience device has a 45-mm working length flexible polymer microcatheter of 200- μ m shaft diameter with a rounded 250- μ m tip diameter (Figure 6). The catheter consists of a central support wire designed to provide a backbone for guidance during advancement and to add resistance to potential kinking of the microcatheter. The optical fibers in the microcatheter allow for transmission of a red blinking light from a laser-based micro-illumination system to the tip to assist in visualization and localization of the tip during passage. The microcatheter possesses a true lumen for the delivery of substances such as viscoelastic to expand the canal during passage or retraction. The proximal end of the device connects to the nonsterile laser-based micro-illumination light source on a mayo stand from one arm, with another arm connected to a sterile screw-mechanism syringe designed to assist in controlled injection of viscoelastic into Schlemm's canal.

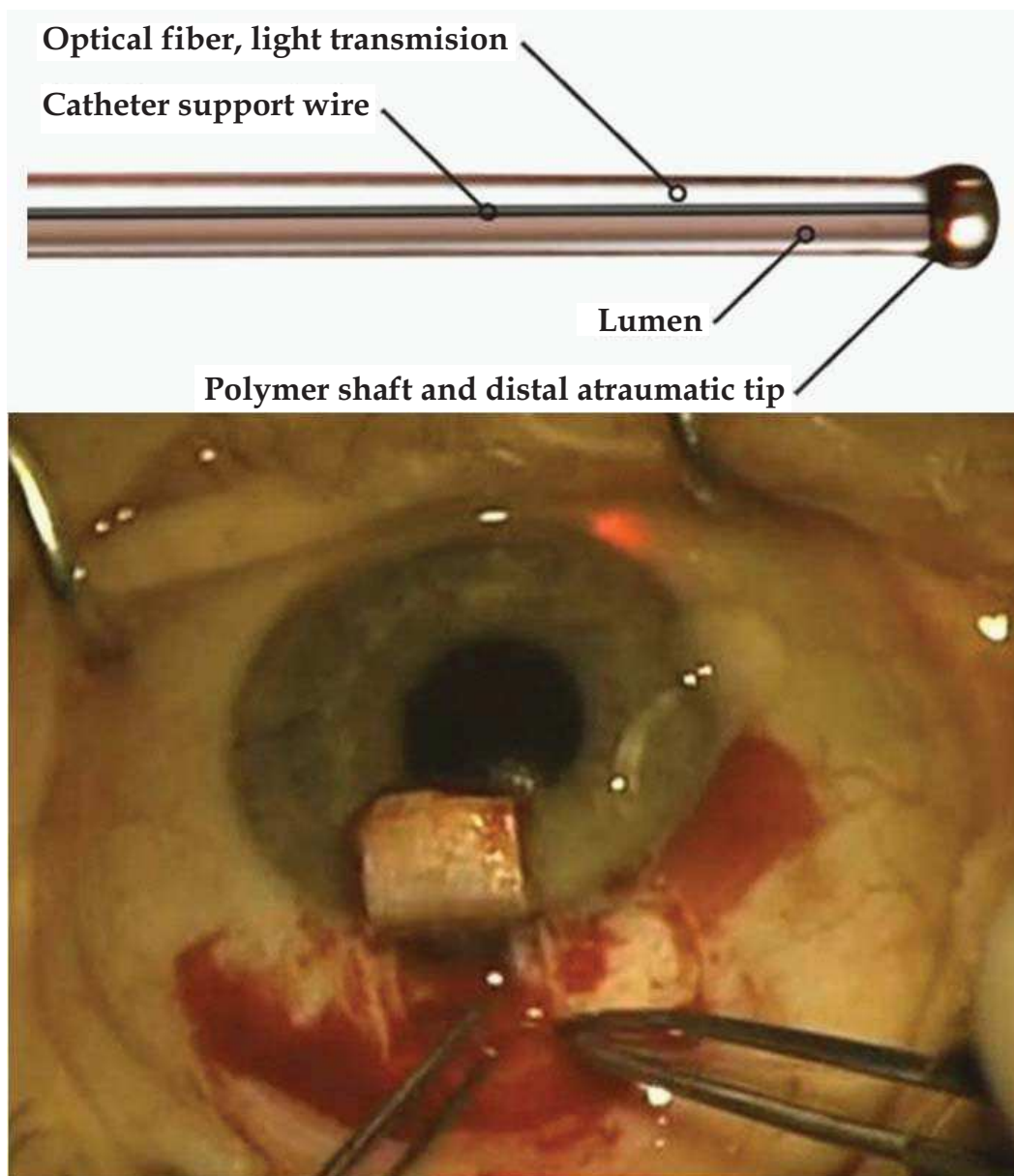


Fig. 6. iTrack250A canaloplasty microcatheter

Indications

- Mild-to-moderate open angle glaucoma
- Pigmentary glaucoma (Ichhpujani et al., 2011)
- Pseudoexfoliative glaucoma

Contraindications

- Scarring from prior trabeculectomy
- Patients with obvious scarring in Schlemm's canal due to prior medication use, laser, surgery or corneoscleral trauma at the limbus
- Anomalies in the anterior chamber angle

Surgical procedure

The chosen surgical site is the superior sclera and hence a traction suture is needed for maintaining a downgaze position. For a corneal traction a careful site selection is required so as to ensure the suture is placed several clock hours away from the intended surgical site.

A fornix based conjunctival peritomy is done leaving an anterior skirt of conjunctiva attached to the limbus with blunt dissection carried out posteriorly. Light wet field cautery is applied to the sclera, being careful to avoid aqueous and ciliary veins. A superficial parabolic scleral flap of approximately 5 mm anterior-posterior length by 5 mm width and one-third scleral thickness is fashioned with the help of a crescent knife, forward into clear cornea. A

deep inner scleral flap is then created approximately 1 mm inside from the edge of the superficial scleral flap. An approximately 100 mm thick layer of sclera should be left covering the choroid at the base of the deep dissection. Once the white limbus-parallel fibers of the scleral spur are visible at the deep dissection, fibers of the outer wall of Schlemm's canal should be visible by lifting of the deep flap with a toothed forceps. A paracentesis incision should be made in the clear cornea to lower the IOP to prevent outward bulging of Descemet's membrane and the inner wall of Schlemm's canal, reducing the likelihood of penetration into the anterior chamber during the ensuing delicate dissection. The deep flap is now advanced forward approximately another 1 mm to expose Descemet's membrane. Mermoud forceps can be used to delicately strip the inner wall of Schlemm's canal away. The corneal stroma should be separated from Descemet's window with surgical sponges such as Merocel. Once the window has been fashioned, the underside of the deep flap is scored with a sharp tip blade at the very anterior aspect and cut off with Vannas scissors. Each cut end of Schlemm's canal is then intubated with a 150-mm outer bore viscocanalostomy cannula, and a miniscule amount of high viscosity sodium hyaluronate is injected into each end to dilate the ostia and facilitate entrance of the iScience device into the canal.

With the help of nontoothed forceps, the microcatheter is introduced into one of the cut ends of Schlemm's canal and advanced 360° until the tip emerges from the other cut end of the canal. In a minority of patients successful catheterisation through the entirety of the canal fails. At times the microcatheter may pass into the suprachoroidal space posterior to Schlemm's canal. In such cases, the catheter should be immediately retracted and passage attempted in the opposite direction. Once the microcatheter has been passed 360° and the tip has emerged, a 10-0 Prolene suture with the needles cut off is tied around the shaft of the device near the tip with the two loose ends tied to the loop. The device is then withdrawn slowly from the opposite direction with controlled injection of viscoelastic every 2-3 clock hours, taking care not to cause Descemet's detachment.

Once the catheter has been removed, the 10-0 Prolene is cut from the tip, leaving two single 10-0 Prolene sutures in the canal with two loose ends emerging from each cut end of

Schlemm's canal. Each suture is tied to itself in a slipknot fashion with some back and forth movement in the canal, known as "flossing," to ensure that the suture sits anteriorly in Schlemm's canal. Suture tension is then assessed by pulling the suture knot posteriorly, until it is only barely able to reach the scleral spur. Suture tension is felt to play an important role in canaloplasty, where a greater suture tension results in more distension of Schlemm's canal with resultant greater IOP reduction and increased flow. The superficial scleral flap is then placed back into position and sutured in a watertight fashion with interrupted 10-0 nylon sutures. Conjunctiva is also closed in a water tight fashion with 10-0 vicryl sutures.

Complications

In trabeculectomy the natural anterior chamber fluid outflow is by-passed via an artificial fistula. Unlike trabeculectomy, canaloplasty attempts to re-establish the physiological anterior chamber fluid draining system by means of dilation of Schlemm's canal and its collector channels. If the anterior chamber pressure temporarily lowers the level of the venous capillary pressure, it is consistent with a patent piping system when a reverse flow with blood reflux into the anterior chamber can be observed as long as a minimal physiological pressure gradient from the anterior chamber in the direction of channel Schlemm's canal has been restored. Thus, an anterior chamber haemorrhage shows the desired consistency of the draining system and hence it should logically be expected after each successful procedure where hypotony in the postoperative period occurs. (Koch et al., 2010)

The surgery is technically challenging and hence there is a learning curve. Microhyphema (7.9%), early and late IOP elevations (7.9% and 2.4%, respectively), wound hemorrhage (2.4%), suture extrusion (1.6%), Descemet membrane detachment (DMD) (1.6%), and hypotony (0.8%) have been reported. (Grieshaber et al., 2010; Palmiero et al., 2010) Trabeculo-Descemet window fibrosis may occur in postoperative course.

5.8 Scientific evidence so far

Lewis and coworkers reported 3-year results of the safety and efficacy of canaloplasty either as a standalone procedure or in combination with cataract surgery in adult open angle glaucoma subjects. (Lewis et al., 2011) Three years postoperatively, all study eyes ($n = 157$) had a mean IOP of $15.2 \text{ mm Hg} \pm 3.5$ (SD) and mean glaucoma medication use of 0.8 ± 0.9 compared with a baseline IOP of $23.8 \pm 5.0 \text{ mm Hg}$ on 1.8 ± 0.9 medications. Eyes with combined cataract-canaloplasty surgery had a mean IOP of $13.6 \pm 3.6 \text{ mm Hg}$ on 0.3 ± 0.5 medications compared with a baseline IOP of $23.5 \pm 5.2 \text{ mm Hg}$ on 1.5 ± 1.0 medications. Intraocular pressure and number of medication, in all eyes were significantly decreased from baseline at every time point ($P < 0.001$). Late postoperative complications included cataract (12.7%), transient IOP elevation (6.4%), and partial suture extrusion through the trabecular meshwork (0.6%).

Koerber reported a comparative case series of 30 eyes of 15 adult patients with bilateral primary open-angle glaucoma who underwent canaloplasty in one eye and viscocanalostomy in the contralateral eye. (Koerber, 2011) With a follow-up period of 18 months, both the canaloplasty and viscocanalostomy groups showed statistically significant reductions in mean IOP ($P < 0.01$) and number of supplemental medications ($P < 0.01$) as compared with preoperative values. In the canaloplasty cohort, eyes had a mean IOP of $14.5 \pm 2.6 \text{ mm Hg}$ on 0.3 ± 0.5 medications at 18 months postoperatively as compared with preoperative levels of $26.5 \pm 2.7 \text{ mm Hg}$ on 2.1 ± 1.0 medications. In the viscocanalostomy cohort, eyes had a mean IOP of $16.1 \pm 3.9 \text{ mm Hg}$ on 0.4 ± 0.5 medications at 18 months as compared with preoperative levels of $24.3 \pm 2.8 \text{ mm Hg}$ on 1.9 ± 0.8 medications ($P = 0.02$). No patient in either cohort

experienced significant complications. The author concluded that canaloplasty showed slightly better efficacy to viscocanalostomy in the reduction of IOP ($P=0.02$).

Grieshaber and coworkers have shown that Canaloplasty produced a sustained long-term reduction of IOP in 60 eyes of black Africans with POAG independent of preoperative IOP. (Grieshaber et al., 2010)

5.9 Place in surgical armamentarium

The analogy of cardiac surgery is most appropriate to educate patients. In some patients, cardiac surgeons can stent or dilate the obstructed vessel with a less invasive angioplasty, while in others with more serious disease, surgeons may have to open the chest and perform a more complex procedure." For glaucoma patients, this means transitioning from canaloplasty to trabeculectomy.

6. DeepLight gold micro shunt

Device

The GMS (SOLX Ltd, Boston, Massachusetts) is a nonvalved flat-plate drainage device made from 24-K medical-grade (99.95%) gold. The device is composed of two leaflets fused together vertically concealing nine channels within the body that connect the anterior openings to the posterior ones (Figure 7). Two different models of the device exist, the GMS (XGS-5) and the GMS Plus (XGS-10), both measuring 5.2 mm long, 2.4 mm wide anteriorly and 3.2 mm wide posteriorly, but differing in weight and channel size. The XGS-5 model weighs 6.2 mg and is 60mm in thickness with the channels measuring 25mm in width and 44mm in height while the XGS-10 model weighs 9.2 mg and the channels measure 25mm in width by 68mm in height. Aqueous humor from the anterior chamber exiting through the uveoscleral pathway to the suprachoroidal space is enhanced by this device by allowing fluid to travel both through the channels in the shunt and also around the body of the shunt. (Melamed et al., 2009)

Indications

The suprachoroidal space appears to be an excellent pathway option for those patients who have had failed trabeculectomy or Schlemm's canal procedures.

Contraindications

- Recent angle closure glaucoma episode
- Uveitic glaucoma, iridocorneal endothelial syndrome, traumatic glaucoma, or neovascular glaucoma
- Other significant ocular disease, except cataract
- Active ocular infection
- Expected ocular surgery in next 12 months
- No suitable quadrant for implant

Surgical procedure

After a 4 mm fornix-based conjunctival peritomy, an approximately 3.5 mm scleral incision is created 2 mm posterior to the limbus or slightly further posteriorly in high myopes (can be inserted in any quadrant but easier in superotemporal quadrant). The dissection is carried out to near full thickness depth, where the choroid is visible through a thin layer of sclera. A scleral pocket at 95% depth is then created by tunneling anteriorly towards the

scleral spur. At this point, a vertical incision is made into the choroidal space and a small amount of suprachoroidal anesthesia and viscoelastic are administered with a blunt cannula. Via a sideport incision viscoelastic is filled in the anterior chamber at the anticipated site of entry of the gold shunt. Alternatively, an AC maintainer can be used and an entry is made into the anterior chamber at the level of the scleral spur through the previously constructed scleral tunnel.

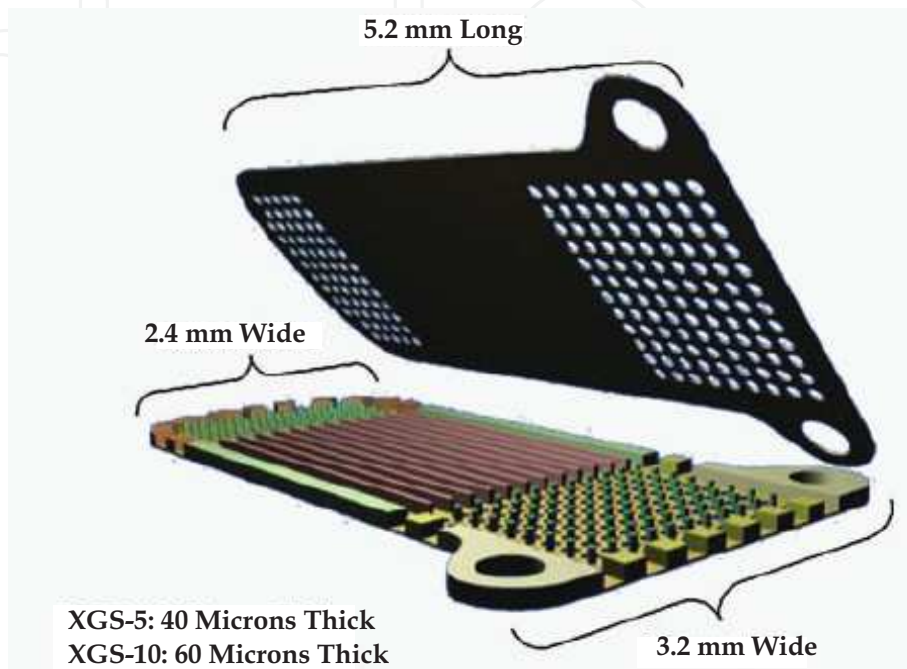


Fig. 7. Gold microshunt

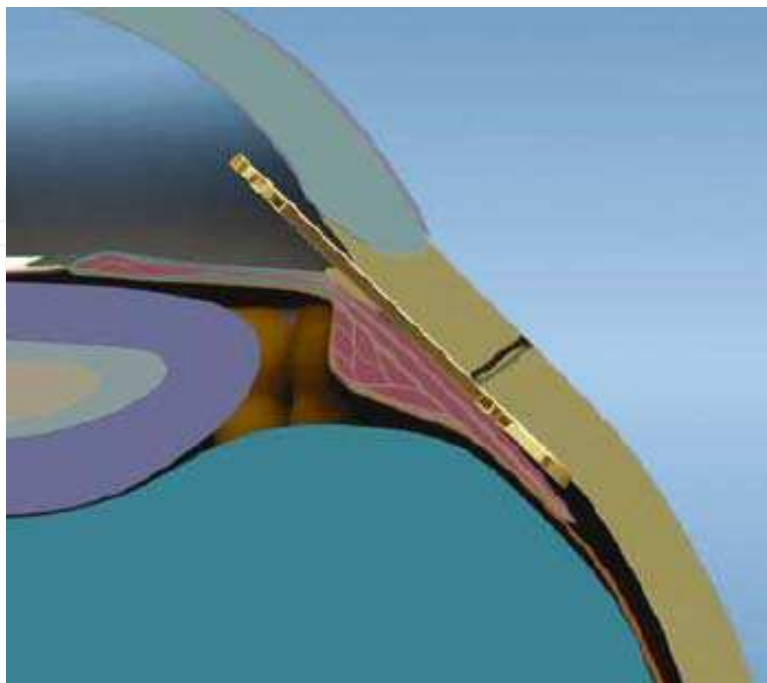


Fig. 8. Cross-section of eye showing correct GMS position

The shunt is placed through the scleral incision, ensuring the head of the device is in the anterior chamber (Figure 8). Positioning of the shunt is achieved posteriorly in the suprachoroidal space using a sharp 27-gauge needle against the shunt to gently encourage it into the suprachoroidal pocket expanded previously by viscoelastic while grasping the wound with a toothed forceps. A "Push then pull" approach works well while inserting the shunt through scleral incision in the anterior chamber.

Alternatively, an instrument such as a Sinsky hook can be utilized on the lateral positioning holes. All of the shunt openings on the posterior aspect should be concealed under the posterior scleral lip of the wound. The anterior aspect of the wound can also be manipulated through the anterior chamber to aid in positioning of the shunt. Intraoperative gonioscopy can help to confirm the proper and intended positioning of the gold shunt in the anterior chamber.

The overlying scleral wound is tightly sutured with 4–5 interrupted 10-0 nylon sutures to ensure watertight closure, as subconjunctival reservoir is not the intended mode of filtration in this surgical procedure. Finally, a 10-0 vicryl horizontal mattress suture is placed to reappose conjunctiva. The crescent-shaped anterior aspect of the shunt consists of a positioning hole, which can be used to adjust shunt positioning with an instrument such as a Sinsky hook. The posterior aspect of the shunt likewise possesses two lateral wings for shunt manipulation. Flow is directed through and around the shunt via the natural pressure gradient from the anterior chamber to the suprachoroidal space.

Placement of GMS in anterior chamber allows future access with 790nm Ti: sapphire laser and goniolens to selectively open specific windows.

Complications

Mild hyphema, hypotony, choroidal effusion, haemorrhage or detachment and shunt migration have been noted in few cases, in decreasing order of their occurrence.

6.1 Surgical evidence so far

Melamed and colleagues reported results of implantation of the GMS in 38 patients with uncontrolled glaucoma in a prospective 2-center study. (Melamed et al., 2009) The mean follow-up time was 11.7 months. The IOP decreased a mean (SD) of 9 mmHg from 27.6 (4.7) to 18.2 (4.6) mmHg ($P < 0.001$). Surgical success was achieved in 30 patients (79%) (IOP > 5 and < 22 mm Hg, with or without antiglaucoma medication). Eight patients had mild to moderate transient hyphema.

Mastropasqua and co workers used in vivo confocal microscopy to show that successful GMS implantation significantly increased conjunctival microcysts density and surface at the site of the device insertion. (Mastropasqua et al., 2010) These findings suggest that the enhancement of the aqueous filtration across the sclera may be one of the possible outflow pathways exploited by the shunt.

6.2 Place in surgical armamentarium

The European Agency for the Evaluation of Medicinal Products (EMA) gave this shunt CE approval in October 2005. It is undergoing Phase III trials in USA. The results till date appear promising. One of the advantages with gold micro-shunt is that in addition to working as an implantable microscopic shunt, the level of IOP control can be titrated by the laser. Additional micro channels can be opened with the laser in the clinicians' office.

6.3 EYEPASS Bi-Directional glaucoma implant

Device

The Eyepass Bi-Directional glaucoma implant (GMP Vision Solutions, Inc.) consists of a dual 6.0 mm long silicone tube bonded at 1 end for less than 1.0 mm, creating a Y-shape (Figure 9). (Dietlein et al., 2008) The inner diameter of the silicone tube is 125 μm and the outer diameter is 250 μm , making the tube narrow enough to fit the lumen of the Schlemm canal. The implant is sterilized by gamma radiation and is a single-use device that should be stored at a temperature between 15°C and 30°C.

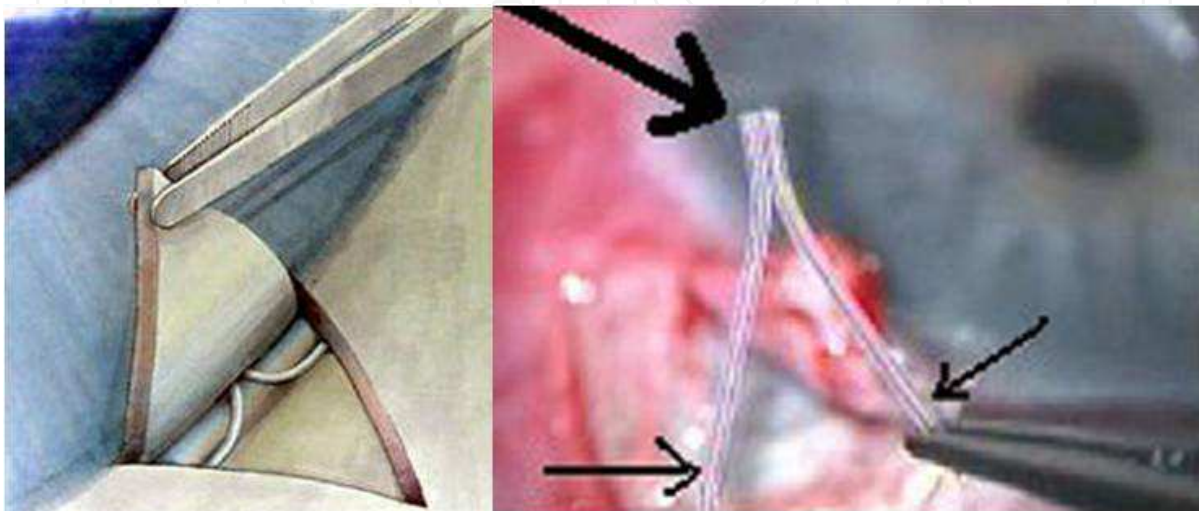


Fig. 9. Eyepass bidirectional implant

Surgical procedure

It can be used as a standalone procedure or in combination with cataract surgery. After a fornix-based superomedial conjunctival dissection and a mild wet field cautery, a two-third thickness triangular scleral flap with a 4 mm basis is dissected. Before the Schlemm canal is unroofed, clear corneal cataract surgery is performed. This is followed by the Schlemm canal unroofing by dissecting a second scleral flap or by opening the canal with small Vannas scissors. Before the Eyepass device is implanted in both lumina of the Schlemm canal, the openings on both sides of the canal are dilated by gentle injection of an OVD such as sodium hyaluronate 1.0% [Healon] through a viscocanalostomy cannula. Thereafter, the arms of the "Y" are inserted into the lumina of the Schlemm canal without exerting pressure in the direction of the anterior chamber. After both ends are buried in the Schlemm canal, the bonded end is inserted into the anterior chamber via a paracentesis almost 1.0 mm from the trabecular meshwork, toward the center of the anterior chamber and under the scleral flap. The implant does not need to be secured by sutures. The scleral flap is sutured to a watertight fit using interrupted 10-0 nylon sutures. The conjunctiva is closed with 8-0 polyglactin (Vicryl) sutures at the limbus.

Complications

The implant actually acts as a wick underneath the scleral flap, encouraging transscleral filtration in the early days after surgery; hence early postoperative hypotony may occur. Intraoperative perforation of the trabecular meshwork may also occur. Since this procedure entails conjunctival dissection, it may compromise other future ab-externo glaucoma surgery.

6.4 Surgical evidence so far

Dietlein et al conducted a small study to evaluate the safety and pressure-reducing efficacy of the Y-shaped Eyepass glaucoma implant in 12 glaucoma and cataract patients and found that combined cataract surgery with Eyepass shunt implantation was safe and appeared to be beneficial in glaucomatous eyes with cataract not requiring a low target IOP. (Dietlein et al., 2008) Perforation of the trabecular meshwork during Eyepass implantation occurred in 2 eyes requiring explantation and conversion to trabeculectomy. In the remaining 10 eyes, the mean maximum IOP was 30.4 mm Hg preoperatively, 12.0 mm 1 day postoperatively, 17.2 mm Hg at 4 weeks, and 18.3 mm at the end of the preliminary follow-up.

In case of trabecular meshwork perforation while inserting an arm of Eyepass, whether opening just 1 arm of the canal could achieve sufficient degree of surgical success is yet to be ascertained. Over the long term, the transscleral filtration seems to play a minor role in the IOP reducing effect of the Eyepass implant because of scarring and no antimetabolite induced favourable wound modulation. Role of antimetabolites to improve transscleral filtration is questionable at present.

6.5 Place in surgical armamentarium

The implant is currently undergoing Phase III trials.

7. Cypass micro stent

Device

Cypass (Transcend) is made from a biocompatible material (polyimide) and features a unique delivery system. The CyPass is a micro-implantable device, 6 mm in length, with a small lumen of 300 μ m (Figure 10). It allows for an *ab interno* surgical approach, which spares the conjunctiva, does not penetrate the sclera and leaves the trabecular meshwork intact.

Surgical procedure

It is implanted in the suprachoroidal space through a clear corneal incision, which coincides with the phacoemulsification incision in combined procedures. A special inserter is used to make the distal end of the device penetrate into the suprachoroidal space, while the proximal collar remains in the anterior chamber. Three rings on the collar keep the device in place, preventing movement.



Fig. 10. Cypass microstent

7.1 Scientific evidence so far

Early clinical results, with the Cypass being placed in combination with cataract surgery (study by Transcend; unpublished data), showed promising results, with a 42% IOP decrease and a 60% decrease in medication use at six months.

Ongoing clinical trials

Combination cypass and cataract surgery trial (COMPASS): Transcend's 480 patient domestic pivotal clinical trial, combines the Cypass and cataract surgery. Enrollment began in the second half of 2009 and the company hopes to complete it by the end of 2011 or in early 2012.

Cypass clinical evaluation trial (CYCLE): This is a European prospective, non-randomized multi-center trial that includes "all-comers" with a goal to assess the Cypass in a broad variety of glaucoma patients.

DUETTE: This is another European trial. Evaluating two different versions of the Cypass in a prospective and randomized study.

Place in surgical armamentarium

Cypass has been found to have few and minor complications compared with filtering procedures. In addition, it is a repeatable procedure, which leaves an intact superior conjunctiva, allowing filtering procedures to be performed at a later stage in case of failure. Preliminary findings need to be confirmed in prospective trials with larger series, evaluating long-term results.

8. Conclusion

The current gold standard, trabeculectomy, has done well for many medically refractory glaucoma patients in the past 40 years. Despite its efficacy in lowering IOP, relatively easy learning curve, it is fraught with not only short time but lifetime potential sight threatening issues. Glaucomatologists and bioengineers are leaving no stone unturned to find a better alternative which addresses the flaws of trabeculectomy. Ex-PRESS glaucoma filtration implant, Trabectome electrocautery device, iStent, Canaloplasty, Gold microshunt and Eyepass bidirectional valve are few milestones along the path of finding an ideal glaucoma device. Although for most devices, the studies are ongoing and the verdict on long term safety and efficacy is awaited, the future definitely seems promising. One size does not fit all in glaucoma. Much remains to be resolved about all these new innovative procedures in glaucoma. It is not wise to abandon time-tested trabeculectomy but it's time to be more selective in choosing surgical procedures.


9. References

- Ates, H, Palamar, M, Yagci, A, Egrilmez, S. (2010) Evaluation of Ex-PRESS mini glaucoma shunt implantation in refractory postpenetrating keratoplasty glaucoma. *J Glaucoma.*; 19:556-60.
- Bagnis, A, Papadia, M, Scotto, R, Traverso, CE. (2011) Obstruction of the Ex-PRESS Miniature Glaucoma Device: Nd: YAG Laser as a Therapeutic Option. *J Glaucoma.* 2011 Mar 21. (Epub ahead of print).
- Bahler, CK, Smedley, GT, Zhou, J, Johnson, DH (2004). Trabecular bypass stents decrease intraocular pressure in cultured human anterior segments. *Am J Ophthalmol.*; 138:988-94.

- Bissig, A, Feusier, M, Mermoud, A, Roy, S. (2010) Deep sclerectomy with the Ex-PRESS X-200 implant for the surgical treatment of glaucoma. *Int Ophthalmol.*; 30:661-8.
- Borisuth, NS, Phillips, B, Krupin T. (1999). The risk profile of glaucoma filtration surgery. *Curr Opin Ophthalmol*, 10, 2:112-116.
- Coleman, AL, Hill, R, Wilson, MR, et al (1995). Initial clinical experience with the Ahmed glaucoma valve implant. *Am J Ophthalmol*, 120:23-31.
- Dahan, E, Carmichael, TR. (2005) Implantation of a miniature glaucoma device under a scleral flap. *J Glaucoma*; 14:98-102.
- Dietlein, TS, Jordan, JF, Schild, A, et al. (2008) Combined cataract-glaucoma surgery using the intracanalicular Eyepass glaucoma implant: first clinical results of a prospective pilot study. *J Cataract Refract Surg.*; 34:247-52.
- Epstein, DL, Melamed, S, Puliatio, CA, Steinert, RF. (1985). Neodymium: YAG laser trabeculopuncture in open-angle glaucoma. *Ophthalmology*, 92:931-937.
- Fea, AM (2010). Phacoemulsification versus phacoemulsification with micro-bypass stent implantation in primary open-angle glaucoma: randomized double-masked clinical trial. *J Cataract Refract Surg.*, 36:407-12.
- Fernández-Barrientos, Y, García-Feijoó, J, Martínez-de-la-Casa JM, Pablo LE, Fernández-Pérez C, García Sánchez J. (2010). Fluorophotometric study of the effect of the glaukos trabecular microbypass stent on aqueous humor dynamics. *Invest Ophthalmol Vis Sci.*, 51:3327-32.
- Francis, BA, See, RF, Rao, NA, et al (2006). Ab interno trabeculectomy: development of a novel device (Trabectome) and surgery for open-angle glaucoma. *J Glaucoma*.15:68-73.
- Francis, BA, Minckler, D, Dustin, L, Kawji, S, Yeh, J, Sit, A, Mosaed S, Johnstone M; (2008) Trabectome Study Group. Combined cataract extraction and trabeculectomy by the internal approach for coexisting cataract and open-angle glaucoma: initial results. *J Cataract Refract Surg.*; 34:1096-103.
- Gandolfi S, Traverso CF, Bron A, Sellem E, Kaplan-Messas A, Belkin M. (2002) Short-term results of a miniature drainage implant for glaucoma in combined surgery with phacoemulsification. *Acta Ophthalmol Scand Suppl*; 236:66.
- Garg, SJ, Kanitkar, K, Weichel, E, Fischer, D. Trauma-induced extrusion of an Ex-PRESS glaucoma shunt presenting as an intraocular foreign body. *Arch Ophthalmol* 2005; 123:1270-2.
- Gedde, SJ, Schiffman, JC, Feuer, WJ, Herndon, LW, Brandt, JD, Budenz DL (2007). Treatment outcomes in the tube versus trabeculectomy study after one year of follow-up. *Am J Ophthalmol*, 143:9-22.
- Geffen, N, Trope, GE, Alasbali, T, et al (2010). Is the EX-PRESS glaucoma device magnetic resonance imaging safe? *J Glaucoma*, 19:116-118.
- Gindroz, F, Roy, S, Mermoud, A, Schnyder, CC (2011). Combined Ex-PRESS LR-50/IOL implantation in modified deep sclerectomy plus phacoemulsification for glaucoma associated with cataract. *Eur J Ophthalmol.*, 21:12-9.
- Griehaber, MC, Pienaar, A, Olivier, J, Stegmann, R. (2010) Canaloplasty for primary open-angle glaucoma: long-term outcome. *Br J Ophthalmol.*, 94:1478-82.
- Ichhpujani, P, Katz, LJ, Gille, R, Affel, E (2010). Imaging modalities for localization of an iStent (®). *Ophthalmic Surg Lasers Imaging*, 41:660-3.
- Ichhpujani, P, Barahimi, B, Shields, CL, Eagle, RC Jr, Katz LJ (2011). Canaloplasty for pigmentary glaucoma with coexisting conjunctival lymphoma. *Ophthalmic Surg Lasers Imaging*. Feb 10; 42 Online:e10-1. doi: 10.3928/15428877-20110203-01.
- Jordan, JF, Engels, BF, Dinslage, S, et al (2006). A novel approach to suprachoroidal drainage for the surgical treatment of intractable glaucoma. *J Glaucoma*, 15:200-205.

- Kaplan-Messas, A, Traverso, CF, Sellem, E, Zbigniew, Z, Belkin, M. (2002) The Ex-PRESS™ miniature glaucoma implant in combined surgery with cataract extraction: prospective study. *Invest Ophthalmol Vis Sci*; 43:3348A
- Kanner, EM, Netland, PA, Sarkisian, SR, et al (2009). Ex-PRESS miniature glaucoma device implanted under a sclera flap alone or combined with phacoemulsification cataract surgery. *J Glaucoma*.; 18:488-491.
- Koch, JM, Heiligenhaus, A, Heinz, C. (2010) Canaloplasty and Transient Anterior Chamber Haemorrhage: a Prognostic Factor? *Klin Monbl Augenheilkd*. Nov 16. [Epub ahead of print]
- Koerber, NJ (2011). Canaloplasty in One Eye Compared With Viscocanalostomy in the Contralateral Eye in Patients With Bilateral Open-angle Glaucoma. *J Glaucoma*. Jan 26. [Epub ahead of print]
- Khaimi, MA. (2009) Canaloplasty using iTrack 250 Microcatheter with Suture Tensioning on Schlemm's Canal. *Middle East Afr J Ophthalmol*.; 16:127-9.
- Krejci, L. (1972) Cyclodialysis with hydroxyethyl methacrylate capillary strip. *Ophthalmologica*; 164:113-121.
- Krupin, T, Podos, SM, Becker, B, Newkirk, JB. (1976). Valve implants in filtering surgery. *Am J Ophthalmol*, 81:232-235.
- Kupin, TH, Juzych, MS, Shin, DH, Khatana, AK, Olivier, MM (1995).Adjunctive mitomycin C in primary trabeculectomy in phakic eyes. *Am J Ophthalmol*, 119:30-39.
- Lankaranian, D, Razeghinejad, MR, Prasad, A, et al (2010). Intermediate-term results of the Ex-PRESS miniature glaucoma implant under a scleral flap in previously operated eyes. *Clin Experiment Ophthalmol*. Dec 22. doi: 10.1111/j.1442-9071.2010.02481.x. [Epub ahead of print].
- Lewis, RA, von Wolff, K, Tetz, M, et al (2007). Canaloplasty: circumferential viscodilation and tensioning of Schlemm's canal using a flexible microcatheter for the treatment of open-angle glaucoma in adults: interim clinical study analysis. *J Cataract Refract Surg*; 33:1217-1226.
- Lewis, RA, von Wolff, K, Tetz, M, et al. (2011) Canaloplasty: Three-year results of circumferential viscodilation and tensioning of Schlemm canal using a microcatheter to treat open-angle glaucoma. *J Cataract Refract Surg*.; 37:682-90.
- Lloyd, MA, Baerveldt, G, Heuer, DK, et al. (1994). Initial clinical experience with the Baerveldt implant in complicated glaucomas. *Ophthalmology*, 101:640-650.
- Maris, PJ, Jr, Ishida, K, Netland, PA. (2007) Comparison of trabeculectomy with Ex-PRESS miniature glaucoma device implanted under scleral flap. *J Glaucoma* 16: 14 - 19.
- Mastropasqua, L, Agnifili, L, Ciancaglini, M, et al (2010). In vivo analysis of conjunctiva in gold micro shunt implantation for glaucoma. *Br J Ophthalmol*.; 94:1592-6.
- Melamed, S, Ben Simon, GJ, Goldenfeld, M, Simon, G (2009).Efficacy and safety of gold micro shunt implantation to the supraciliary space in patients with glaucoma: a pilot study. *Arch Ophthalmol*; 127:264-9.
- Minckler, DS, Mosaed, S, Dustin, L, Francis, BA. (2008) Trabectome (trabeculectomy-internal approach): additional experience and extended follow-up. *Trans Am Ophthalmol Soc*.106:1-12.
- Molteno, ACB. (1969) New implant for drainage in glaucoma: clinical trial. *Br J Ophthalmol*, 53:606-615.
- Netland, PA. Obstruction (Also Known as Occlusion or Blockage) of the Ex-PRESS Miniature Glaucoma Device. *J Glaucoma*. Mar 21. [Epub ahead of print]
- Nichamin, LD. (2009) Glaukos iStent Trabecular Micro-Bypass. *Middle East Afr J Ophthalmol*., 16 (3):138-40.

- Nguyen, QH. Trabectome: a novel approach to angle surgery in the treatment of glaucoma. *Int Ophthalmol Clin.* Fall; 48:65-72.
- Nyska, A, Glovinsky Y, Belkin M, Epstein Y. (2003) Biocompatibility of the Ex-PRESS miniature glaucoma drainage implant. *J Glaucoma*; 12:275-80.
- Ozdamar, A, Aras, C, Karacorlu, M (2003). Suprachoroidal seton implantation in refractory glaucoma: a novel surgical technique. *J Glaucoma*; 12:354-359.
- Palmiero, PM, Aktas, Z, Lee, O, Tello, C, Sbeity, Z (2010). Bilateral Descemet membrane detachment after canaloplasty. *J Cataract Refract Surg.*; 36:508-11.
- Pinnas, G, Boniuk, M. (1969) Cyclodialysis with teflon tube implants. *Am J Ophthalmol*; 68:879-883.
- Razeghinejad, MR, Spaeth, GL. (2011). A history of the surgical management of glaucoma. *Optom Vis Sci.*, 88:E39-47.
- Rivier, D, Roy, S, Mermoud, A. (2007). Ex-PRESS R-50 miniature glaucoma implant insertion under the conjunctiva combined with cataract extraction. *J Cataract Refract Surg*, 33:1946-52.
- Samuelson, TW, Katz, LJ, Wells, JM, Duh, YJ, Giamporcaro JE (2010); US iStent Study Group. Randomized evaluation of the trabecular micro-bypass stent with phacoemulsification in patients with glaucoma and cataract. *Ophthalmology.*; 118:459-67.
- Seibold, LK, Rorrer, RA, Kahook, MY. (2011). MRI of the Ex-PRESS stainless steel glaucoma drainage device. *Br J Ophthalmol.*, 95:251-4.
- Spiegel, D, Wetzel, W, Neuhann, T, et al. (2009). Coexistent primary open-angle glaucoma and cataract: interim analysis of a trabecular micro-bypass stent and concurrent cataract surgery. *Eur J Ophthalmol.*, 19:393-9.
- Spiegel, D, García-Feijoó, J, García-Sánchez, J, Lamielle, H. (2008). Coexistent primary open-angle glaucoma and cataract: preliminary analysis of treatment by cataract surgery and the iStent trabecular micro-bypass stent. *Adv Ther.*; 25:453-64.
- Stewart, RM, Diamond, JG, Ashmore, ED, Ayyala, RS. (2005). Complications following Ex-PRESS glaucoma shunt implantation. *Am J Ophthalmol*, 140:340-1.
- Tavolato, M, Babighian, S, Galan, A (2006). Spontaneous extrusion of a stainless steel glaucoma drainage implant (Ex-PRESS). *Eur J Ophthalmol*; 16:753-5.
- Ticho, U, Ophir, A. (1993). Late complications after glaucoma filtering surgery with adjunctive 5-fluorouracil. *Am J Ophthalmol*, 115:506-510.
- Traverso, CE, De Feo, F, Messas-Kaplan, A, Denis, P, Levartovsky, S, Sellem, E, et al. (2005) Long term effect on IOP of a stainless steel glaucoma drainage implant (Ex-PRESS) in combined surgery with phacoemulsification. *Br J Ophthalmol*; 89:425-9.
- Wamsley, S, Moster, MR, Rai, S, Alvim, HS, Fontanarosa, J. (2004) Results of the use of the Ex-PRESS miniature glaucoma implant in technically challenging, advanced glaucoma cases: a clinical pilot study. *Am J Ophthalmol*; 138:1049-51.
- Wamsley, S, Moster, MR, Rai, S, Alvim, H, Fontanarosa, J, Steinmann, WC. (2004). Optonol Ex-PRESS miniature tube shunt in advanced glaucoma. *Invest Ophthalmol Vis Sci*; 45:994A.
- Vetrugno, M, Ferreri, P, Sborgia, C (2010). Ex-PRESS miniature glaucoma device in vitrectomized eyes. *Eur J Ophthalmol.*; 20:945-7.
- Vetrugno, M, Ferreri, P, Cardascia, N, Sborgia, C. (2011) Surgical reposition of a dislocated Ex-PRESS miniature device. *Eur J Ophthalmol.*; 21:212-4.
- Vold, SD, Dustin, L. Impact of laser trabeculoplasty on trabectome ((r)) outcomes. *Ophthalmic Surg Lasers Imaging.* 2010; 41:443-51.



Glaucoma - Basic and Clinical Concepts

Edited by Dr Shimon Rumelt

ISBN 978-953-307-591-4

Hard cover, 590 pages

Publisher InTech

Published online 11, November, 2011

Published in print edition November, 2011

This book addresses the basic and clinical science of glaucomas, a group of diseases that affect the optic nerve and visual fields and is usually accompanied by increased intraocular pressure. The book incorporates the latest development as well as future perspectives in glaucoma, since it has expedited publication. It is aimed for specialists in glaucoma, researchers, general ophthalmologists and trainees to increase knowledge and encourage further progress in understanding and managing these complicated diseases.

How to reference

In order to correctly reference this scholarly work, feel free to copy and paste the following:

Parul Ichhpujani and Marlene R. Moster (2011). Novel Glaucoma Surgical Devices, Glaucoma - Basic and Clinical Concepts, Dr Shimon Rumelt (Ed.), ISBN: 978-953-307-591-4, InTech, Available from: <http://www.intechopen.com/books/glaucoma-basic-and-clinical-concepts/novel-glaucoma-surgical-devices>

INTECH
open science | open minds

InTech Europe

University Campus STeP Ri
Slavka Krautzeka 83/A
51000 Rijeka, Croatia
Phone: +385 (51) 770 447
Fax: +385 (51) 686 166
www.intechopen.com

InTech China

Unit 405, Office Block, Hotel Equatorial Shanghai
No.65, Yan An Road (West), Shanghai, 200040, China
中国上海市延安西路65号上海国际贵都大饭店办公楼405单元
Phone: +86-21-62489820
Fax: +86-21-62489821

© 2011 The Author(s). Licensee IntechOpen. This is an open access article distributed under the terms of the [Creative Commons Attribution 3.0 License](#), which permits unrestricted use, distribution, and reproduction in any medium, provided the original work is properly cited.

IntechOpen

IntechOpen