

# We are IntechOpen, the world's leading publisher of Open Access books Built by scientists, for scientists

**4,800**

Open access books available

**122,000**

International authors and editors

**135M**

Downloads

Our authors are among the

**154**

Countries delivered to

**TOP 1%**

most cited scientists

**12.2%**

Contributors from top 500 universities



**WEB OF SCIENCE™**

Selection of our books indexed in the Book Citation Index  
in Web of Science™ Core Collection (BKCI)

Interested in publishing with us?  
Contact [book.department@intechopen.com](mailto:book.department@intechopen.com)

Numbers displayed above are based on latest data collected.

For more information visit [www.intechopen.com](http://www.intechopen.com)



## End Stage Glaucoma

Tharwat H. Mokbel  
*Mansoura University Mansoura,  
Egypt*

### 1. Introduction

Glaucoma is the second leading cause of blindness in the general population. The definition of end-stage glaucoma may be based on a very constricted visual field, or a markedly severed visual acuity (Gillies & Brooks et al., 2000). Many factors have been postulated to put the patient at a high risk. Achieving an individually fashioned target IOP is supposed to minimize the risk of glaucoma progression (Nouri-Mahdavi & Hoffman et al., 2004). Medical regimens may induce significant short and long term IOP fluctuations. Surgery should be considered in end stage glaucoma. Trabeculectomy has been reported to be associated with less diurnal IOP fluctuation compared to maximum medical therapy. Wipe-out phenomenon is a rare complication and may be considered as a blast from the past. Meanwhile, Trabeculectomy has many surgical difficulties. Emphasis on guidelines for a successful trabeculectomy without toil is presented, besides the new modalities to achieve a favorable outcome.

### 2. What is end stage glaucoma?

There is no universally accepted definition of end-stage glaucoma. It may be based on a very constricted visual field, less than 10 or a visual acuity of 20/200 or worse that is attributable to glaucoma (Gillies & Brooks et al., 2000).

#### 2.1 Importance

Glaucoma is the second leading cause of irreversible blindness in the general population, and the leading cause of blindness in black patients. Besides, patients with end-stage glaucoma have a high risk of further disease progression. Although peripheral vision is seriously affected, these patients may maintain good central vision sufficient enough to perform simple daily tasks.

#### 2.2 Diagnostic challenge

End stage glaucoma carries a diagnostic challenge. Visual field examination is either unreliable or impossible. Only when a central island of vision remains, visual field tests of the central degrees should be chosen. Small changes in the visual field may be deleterious to central vision but it can be difficult to differentiate them from inter-test fluctuation. Small neuroretinal rim changes may correspond to significant changes in the visual acuity. On the other hand, OCT may be useful in the detection of glaucomatous progression. In advanced or progressive glaucoma, imaging can be justified every 3–4 months to look for change (Bartz-Schmidt & Thumann G et al., 1999).

### 2.3 Risk factors for progression

Many factors have been proved to increase the risk of glaucoma progression in end stage glaucoma, The most important are elevated intraocular pressure (IOP), IOP fluctuations, male gender, less formal education, severity of disease, pseudoexfoliation syndrome, worsening visual fields during follow up, optic disc hemorrhage, advanced stage of disease, migraine, patient's expected longevity, and the possibility of systemic diseases e.g hypertension, diabetes, and myopia (Law & Nguyen et al., 2007).

### 3. Target IOP in end stage glaucoma

Target IOP is the IOP that minimizes the risk of glaucoma progression with minimum impact on the quality of life. Although the concept of a target IOP is debated, it is recommended that every patient should have an individualized target IOP and re-estimated according to the follow up. Target IOP may be a percent reduction from a baseline IOP or may be an absolute IOP reduction. It is generally assumed that aiming to achieve a target IOP of at least a 20% reduction from the initial pressure at which damage occurred is a useful starting point. For moderate and advanced damage, a 30 and 40% decrease of IOP from baseline, respectively, is proposed. In each individual, the efficacy of any treatment lowering the IOP less than 15% should be questioned. The range of IOP fluctuations should also be considered and when in doubt a diurnal curve is indicated. Besides, the greater the pre-existing glaucoma damage, the lower the target IOP should be. It is clinically relevant that in eyes with severe pre-existing damage, any further damage may be functionally important. Thus, IOP should be set low in end-stage glaucoma. Target pressures seem to drop to lower and lower levels each decade. Even a more lower target IOP may be needed if other risk factors are present specially diabetes mellitus and hypertension. Severe pre-existing damage in the fellow eye is another possible risk factor, as well as a positive family history of visual handicap caused by primary open-angle glaucoma (POAG). A further 3% IOP lowering for each risk factor or for each decade of life expectancy is advised. Periodical re-evaluation and adjustments are necessary if the visual field continues to worsen at a rate that is clinically significant, it may be necessary to aim for a lower target IOP after other causes have been excluded (Miglior & Bertuzzi , 2010)..

#### 3.1 Medical versus interventional strategy

The target IOP may not be achieved despite maximum medical therapy. Even if end stage glaucoma could be controlled medically, the lack of adherence and persistence with medication regimens may induce significant short and long term IOP fluctuations. These fluctuations have a deleterious effect on the visual outcomes. Medication may be inappropriate in some clinical situations. Extremely high IOP may be unlikely to be sufficiently reduced by medications. In this case medical treatment may be initiated briefly in order to operate at lower IOP. Some patients may have secondary conditions that interfere with the ability to administer medication such as dementia, mental illness, or arthritis. Economic problems are also challenges for patients in many locations. This may limit or effectively exclude access to medical treatment for glaucoma. Limited access to medical resources may be based on other factors such as distance from medical care and limited availability of practitioners and medications. On the other hand, glaucoma procedures are associated with more tight IOP control and minimal IOP fluctuations. There is a growing evidence that glaucoma procedures are more helpful in prevention of visual field loss when further IOP reduction is needed despite maximum medical therapy. There

are no clearly defined and accepted rules to decide when surgery is the appropriate therapeutic choice, but there are principles that seem to guide this decision. Several assumptions underlie the recommendation of surgery for the treatment of glaucoma. Among these are the observation that surgical IOP lowering stops or slows progressive glaucoma damage. Even more, greater IOP lowering can be achieved with surgery than with medication in many patients, while surgery has greater risk than medical treatment of glaucoma. Intra-operative risks such as suprachoroidal haemorrhage, and post-operative risks such as hypotony and bleb related infection can result in rapid and profound visual loss. For example, trabeculectomy has been reported to be associated with less diurnal IOP fluctuation compared with maximum medical therapy in patients with end stage glaucoma. On the contrary, if the central fixation has already been lost, glaucoma procedures add no more beneficial effect and it is suggested to consider withholding surgery.

## **4. Surgical intervention in end stage glaucoma**

### **4.1 Surgical options of end stage glaucoma**

The surgical options for end stage glaucoma are generally the same as those of earlier stages of glaucoma. Many trabeculectomy modalities are suitable for end stage glaucoma. While trabeculectomy is the treatment of choice in primary open angle glaucoma, consider lens removal (combined surgery) in patients with end-stage chronic angle closure glaucoma. This offers the best chance to deepen the anterior chamber and widen the angle. Trabeculectomy with antimetabolites reduces IOP more compared with trabeculectomy alone. Ologen collagen matrix is a new promising modality that carries a superior advantage over conventional trabeculectomies and antimetabolites. Glaucoma drainage implants are indicated after glaucoma filtration surgery failure, on the other hand cycloablation in the form of cyclophotocoagulation or cyclocryotherapy are indicated for eyes with poor vision.

### **4.2 Preoperative preparation**

A proper preoperative preparation is essential for a successful glaucoma surgery outcome. Adequate management of blood pressure, coagulation profile by the physician is crucial. Preoperative Visual field is important for medical and medico-legal reasons. Topical corticosteroids such as fluoromethelone may be used to calm down any claimed inflammation. Glaucoma lowering agents should be stopped several days in advance.

### **4.3 Anaesthetic precautions**

Ophthalmic anaesthesia planning is of great help in end stage glaucoma surgery. General anaesthesia is considered for one-eyed patients as possible. Certain precautions are mandatory during local anesthesia particularly reduction of the volume, addition of hyaluronidase and avoidance of orbital compression. Facial block is important to produce enough facial akinesia. Subtenon or peribulbar anaesthesia do worth consideration particularly for myopia.

### **4.4 Difficulties of surgical intervention in end stage glaucoma**

It has been well noticed that procedures in end stage glaucoma carries more surgical difficulties. This is because of the possibility of previous operations (glaucoma or cataract) and the long term use of topical glaucoma drugs. These co-morbidities have negative effects on the conjunctiva, and on the outcome of a new operation.

## 5. Conventional trabeculectomy in end stage glaucoma

Trabeculectomy should be fashioned properly and with extreme caution in end stage glaucoma to achieve the best favorable outcomes. Fornix-based flaps are preferred for better exposure of the sclera and less chance of a posterior scar formation. A corneal traction suture is suggested to avoid formation of a superior rectus haematoma. An anterior segment infusion system through the paracentesis is helpful in stabilizing the IOP during surgery, decrease the risk of serious complications, and enable more accurate suturing of the scleral flap. Bleb is fashioned under the upper lid to minimize discomfort and bleb-related complications, such as leak or infection. The scleral flap must be sufficiently large and of adequate thickness to provide resistance to aqueous outflow, especially if antimetabolites are used. Besides, the side incisions are left incomplete (1–2 mm from limbus) to encourage posterior flow and achieve a diffuse bleb. Scleral flap sutures can be pre-placed while the eye is still firm. Adjustment of sutures of the scleral flap should be based on intraoperative evaluation of flow.

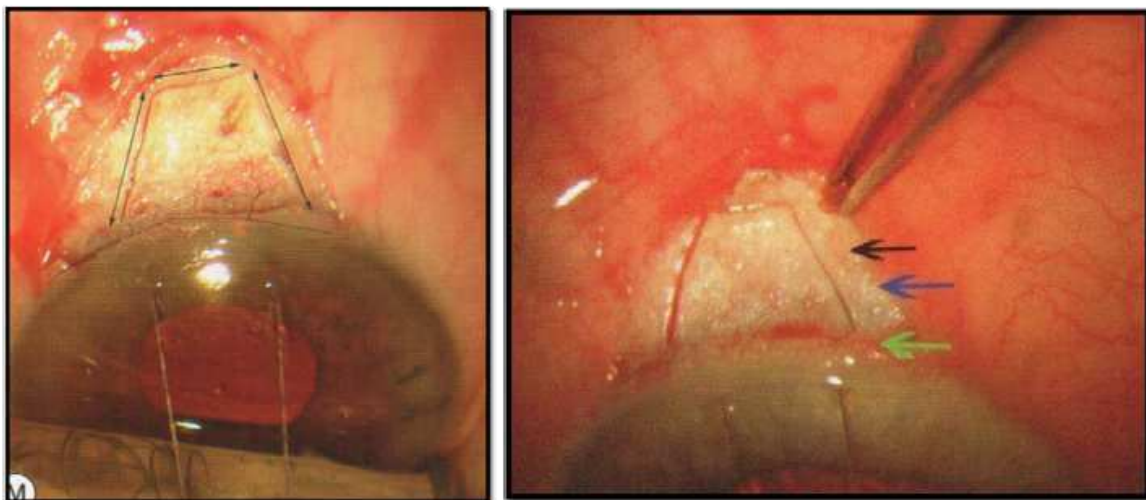


Fig. 1. (RT) Fornix-based flaps for better exposure of the sclera and less chances of a posterior scar. A corneal traction suture avoids the formation of a superior rectus haematoma, (LT) The scleral flap must be sufficiently large and of adequate thickness to provide resistance to aqueous outflow. (Fellman, 2009)

Many modalities of scleral flap sutures are of great help. Among those are fixed interrupted sutures that can be lasered later, releasable sutures that can be pulled out postoperatively and adjustable sutures that can be loosened transconjunctivally. Meticulous conjunctival closure is a priority to avoid hazardous postoperative bleb leakage and hypotony. Careful postoperative IOP measurement is indicated to detect early IOP spikes which could result in optic nerve damage. Bleb leakage and signs of inflammation should always be examined.

## 6. Trabeculectomy with antimetabolites

Tissue healing can be modulated with antimetabolites to improve outcomes of trabeculectomy. Antimetabolites are not very often used for the first trabeculectomies, but are mandatory after previous trabeculectomy or cataract surgery and for combined cataract-trabeculectomy surgery. Also they are indicated with trabeculectomy failure in the other eye



and for dark skin and young patients. Antimetabolites are applied with a low dose, short duration, and on the largest possible area. While preoperative subconjunctival mitomycin-C (MMC) has less cytotoxic effect on the ciliary body compared with intraoperative episcleral application, both preoperative and intraoperative applications of MMC are effective in controlling IOP with a safer course and less postoperative complications in preoperative subconjunctival injection. Argon laser trabeculoplasty as an adjuvant therapy before or after trabeculectomy is an issue of controversy. Black and white patients with advanced glaucoma respond differently. Blacks with end stage glaucoma benefit more from a regimen that begins with laser surgery, and whites benefit more from one that begins with trabeculectomy.

## 7. Glaucoma filtering surgery with amniotic membrane transplantation

### 7.1 Principle

Antimetabolites may influence the integrity of the conjunctival barrier, resulting in a thin-walled avascular bleb (Hutchinson & Grossniklaus et al., 1997). The end result is often poor epithelialization and increased susceptibility to leakage and hypotony or infection, sometimes months after surgery (Parrish & Minckler, 1996). On the other hand, amniotic membrane exhibits a number of characteristics that might be of benefit in glaucoma surgery, that is good epithelization, good integration with the surrounding tissue, a low healing response, suppression of TGF-B activity and poor immunogenicity (Willoch & Nicolaisen, 2003). These features of amniotic membrane make it an attractive tissue for use in glaucoma surgery. It has been used in filtration surgery as an adjunct to reduce scarring, for repair of leaking blebs and as a cover for valve implant (Fujishima & Shimazaki et al., 1998).

### 7.2 Operative technique

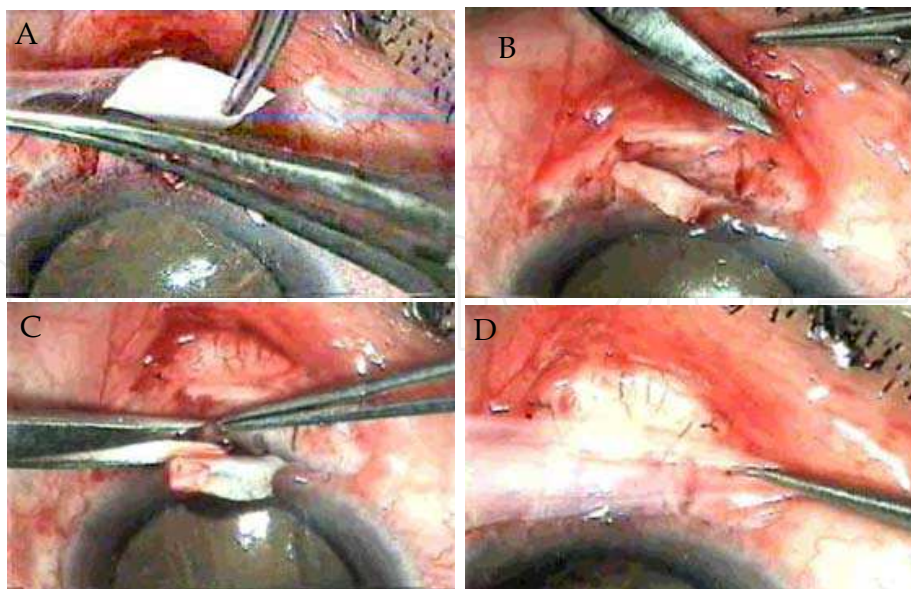


Fig. 2. (A) Peeling of amniotic membrane from Nitro cellulose paper, (B) Amniotic membrane graft is placed under the scleral flap and suturing of the graft to the sclera, (C) Trabeculectomy measuring 2X3 mm is done (D) Second graft over the scleral flap ( Mokbel & El-hefny et al., 2005)

Fornix based conjunctival flap, care was taken to ensure haemostasis during the whole surgical procedure. Scleral flap was done measuring 4x5 mm. Previously prepared amniotic membrane which is preserved in Dulbeccos Modified Eagles Media (DME) at -80°C and was known to be free from HIV, HCV, HBV and syphilis was used Fig. 2(A). Amniotic membrane graft measuring 3x8 mm with its epithelial side up was placed between the scleral flap and deep sclera and attached to the scleral with four 10-0 nylon sutures at the corners Fig. 2(B). The amniotic membrane was then retracted and trabeculectomy measuring 2x3 mm was done Fig. 2(C). The scleral flap was then closed by two 10/0 nylon sutures. A second graft of amniotic membrane measuring 1.5x1.5 cm was placed over the sclera and attached near the limbus by two 10-0 nylon sutures and posteriorly by other two sutures Fig. 2(D). The conjunctiva was then closed using two 8/0 virgin sutures at the corners. Postoperatively each patient received a subconjunctival injection of Dexamethazone and garamycin followed by topical application of 5 times daily tobramycin & Dexamethazone drops for 4 weeks. All antiglaucoma medications were stopped ( Mokbel & El-hefny et al., 2005).

### 8. Ologen collagen matrix

Ologen is porcine extracellular matrix made of atelocollagen cross-linked with glycosaminoglycan. Ologen is a biodegradable scaffolding matrix that induces a regenerative wound healing process without the need for antifibrotic agents. It is well known that episcleral fibrosis and sub-conjunctival scarring are the major causes of failure in glaucoma filtering surgery. Ologen collagen matrix can create the sub-conjunctival bleb and modulate the wound healing for the surgery. Ologen collagen matrix is a 3-D scaffold porous structure that can guide fibroblast to grow randomly, instead of linear alignment. This can reduce sub-conjunctival and trabdoor scars. Thus, Ologen collagen matrix carries the

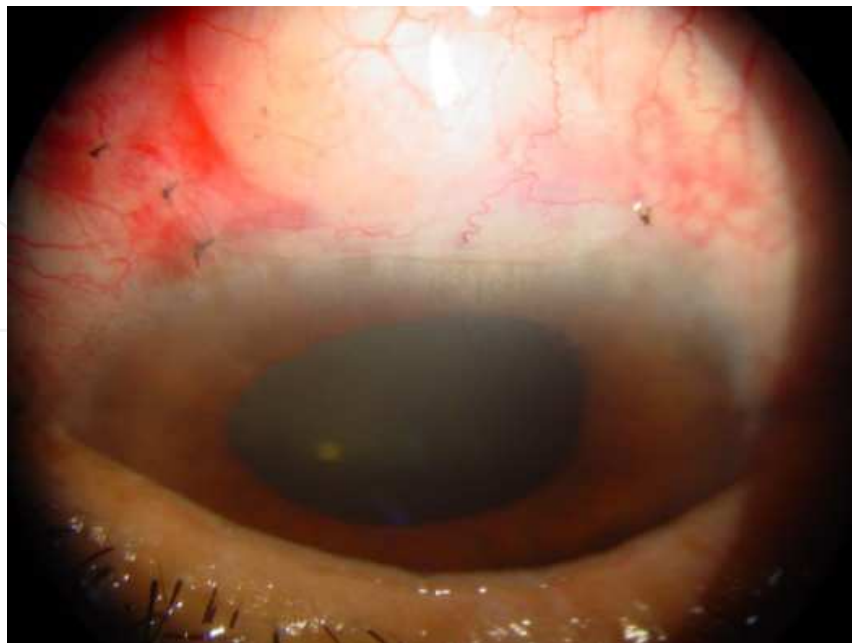

Fig. 3. Ologen implant,diffuse bleb and a well formed anterior chamber (photo of the author)

advantage of lowering IOP more safely and efficiently than standard trabeculectomy with MMC, with the merit of less possibility of bleb leaks and endophthalmitis compared with antimetabolites (Sarkisian, 2010).

The collagen matrix helps to limit hypotony through a tamponading effect over the scleral flap. On the other hand Ologen collagen matrix carry the disadvantage of increased cost, besides the difficulty of laser suture lysis.

### 8.1 Technique

According to the surgeon preference, limbal - or a fornix-based conjunctival flap are accepted. A loose stitch sclera flap is done in order to encourage aqueous flow for the filtering surgery. Ologen collagen matrix disc is implanted over the scleral flap. No suture is required to secure the implant, and as soon as it touches the sclera, it absorbs aqueous and molds to cover the scleral tissue. Collagen matrix therefore need not be presoaked or prepared in any way. After the collagen matrix's placement, the surgeon closes the conjunctiva in his or her usual meticulous fashion to ensure that the wound is watertight.

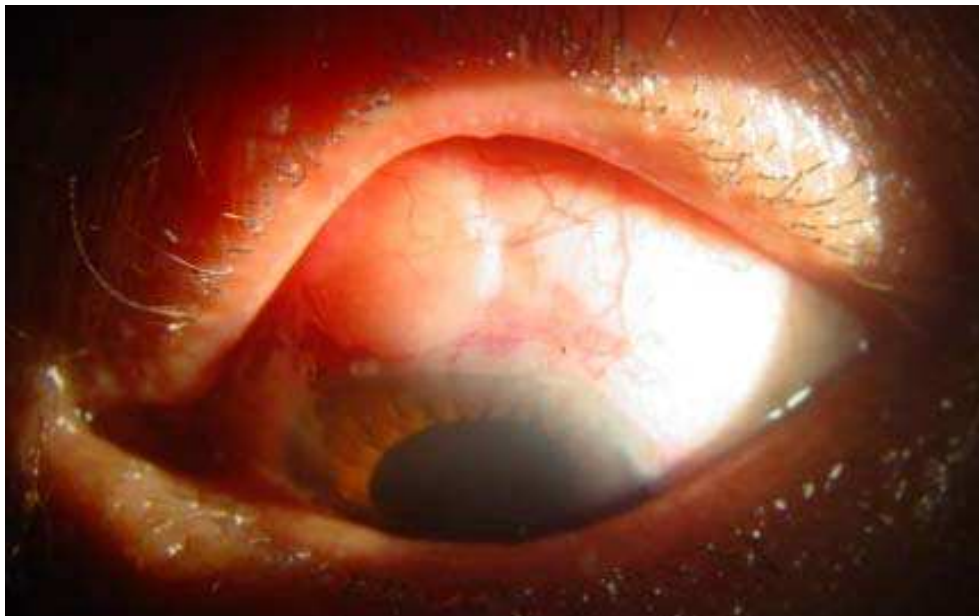


Fig. 4. Ologen implant, next day after surgery (photo of the author)

Ologen currently comes in two sizes for glaucoma filtering surgery: 6 X 2 mm and 12 X 1 mm. The numbers 6 and 12 stands for the diameter of the round implant, and the numbers 2 and 1 refer to its thickness. Ologen is biodegradable in 90 to 180 days. Ologen has been approved by the FDA in August 2009 (Sarkisian, 2010).

## 9. Aqueous shunting procedures with glaucoma drainage devices

Glaucoma drainage devices (GDDs) are indicated when trabeculectomy is unlikely to be successful. Besides, GDDs should be considered for socioeconomic or logistical issues relating to safety, follow-up care, etc. GDDs that do not have mechanisms to restrict aqueous flow require a suture ligature or internal stent or other flow restricting mechanism because the restriction of flow of aqueous humor from the eye is important in the prevention



of postoperative hypotony. There are several type of devices; however, they can be divided into two categories: anterior drainage devices and posterior drainage devices. Most posterior drainage devices are composed of a silicone or Silastic tube that is placed into the eye (through the limbus or pars plana) and through which aqueous humor passes into the episcleral-subconjunctival space near the globe's equator. In this area there is an episcleral plate that is designed to maintain an aqueous reservoir. There are three design features which distinguish different implants; the presence of a valve or mechanism to restrict the flow of aqueous humor from the eye, the surface area and configuration of the episcleral plate, and the the material used. Drainage devices without a built in flow restriction mechanism, such as the Molteno, Baerveldt, and Schocket band implants, may be inserted in a one-stage procedure, where the flow of aqueous is restricted by a suture ligature around the tube or an internal stent. On the other hand krupin Valve implant and Ahmed Glaucoma Valve implant have pressure-sensitive valves or mechanisms which restrict the flow of aqueous from the eye (Mokbel, 2005).

## 10. Cyclodestruction

Cyclodestructive procedures aim to decrease aqueous humor secretion by damaging the ciliary processes, thereby reducing intraocular pressure (IOP). Modalities for cyclodestruction include cyclocryotherapy, and cyclophotocoagulation, using the Nd:YAG or diode laser. Endoscopic, non-contact and contact modes of cyclophotocoagulation are available, with the contact diode mode most widely used, laser diode cyclophotocoagulation is the procedure of choice for end stage glaucoma when trabeculectomy and drainage implants have a high probability for failure or have high risk of surgical complications. Less intense laser therapy on a repeated basis rather than a single high dose treatment is suggested to minimize complications of treatment. The effectiveness of treatment should be assessed after 3-4 weeks, at which time re-treatment may be considered.

## 11. Risk of losing vision

The patient should be informed about the relative risk of losing vision from a surgical procedure in end-stage glaucoma eyes. Visually devastating complications include chronic hypotony (leading to hypotony maculopathy), retinal detachment, malignant glaucoma, corneal decompensation, endophthalmitis, and phthisis bulbi. A detailed clearly written patient consent is important. It should entail all the potential hazards from suggested surgical procedure.

### 11.1 Wipe-out phenomenon

The wipe-out phenomenon is unexplained vision loss following glaucoma surgery. Wipe-out phenomenon data comes from older retrospective reports using older surgical techniques. Newer data does not report the occurrence of the wipe-out phenomenon.

## 12. Conclusion

In end stage glaucoma there is a higher incidence of visual loss than early glaucoma. So, frequent patient monitoring and quick decision making should be done. The target IOP in

end stage glaucoma is lower than in early stage. Surgery should be considered in end stage glaucoma. Wipe-out phenomenon is a rare complication and may be considered as a blast from the past.


### 13. References

- Bartz-Schmidt K. U., Thumann G., Jonescu-Cuypers C. P., et al. (1999) Quantitative morphologic and functional evaluation of the optic nerve head in chronic open-angle glaucoma. *Surv Ophthalmol* 44; 1, pp.541-553.
- Fellman R. (2009). Trabeculectomy, In: *Glaucoma volume two surgical management*, Shaarawy T. & Sherwood M. & Hitchings R. and Crowston J. pp.(111-150), Saunders, 978-0-7020-2978-3, China.
- Fujishima H., Shimazaki J., Shinozaki N., Tsubota K. (1998) Trabeculectomy with the use of amniotic membrane for uncontrollable glaucoma. *Ophthalmic Surg.* 29; pp.928-943.
- Gillies W. E., Brooks A. M., Strang N. T. (2000). Management and prognosis of end stage glaucoma. *Clin Experiment Ophthalmol*, 28, PP.(405-408).
- Hutchinson A. K., Grossniklaus H. E., Brown R. H., McManus P. E. and Bradley G. K. (1997) Clinicopathologic features of excised mitomycin filtering bleb. *Arch Ophthalmol* 112, pp. 74-79.
- Law S. K., Nguyen A. M., Coleman A. L., et al. (2007) Severe loss of central vision in patients with advanced glaucoma undergoing trabeculectomy. *Arch Ophthalmol*, 125, pp.1044-1050.
- Miglior S. and Bertuzzi F. (2010). IOP: Target Pressures, In: *Pearls of Glaucoma Management*, Giaconi, J. & Law, S. & Coleman A. and Caprioli J. pp.(99-104), Springer-Verlag Berlin Heidelberg, 978-3-540-68238-7, New York.
- Mokbel T., (2005) Long term clinical experience with Ahmed valve in refractory glaucoma. *Bull. Ophthalmol. Soc. Egypt*, 98(3); pp 479-484.
- Mokbel T., El-hefny E., El-bendary A. (2005) Glaucoma filtering surgery with amniotic membrane transplantation. *Bull. Ophthalmol. Soc. Egypt*, 98(3); pp 419-423.
- Nouri-Mahdavi K., Hoffman D., Coleman A. L., et al. (2004) Predictive factors for glaucomatous visual field progression in the Advanced Glaucoma Intervention Study. *Ophthalmology* 111; pp1627-1635.
- Palmberg, P. (2005). outcome measures for Studies of glaucoma surgery, In: *Glaucoma surgery Open Angle Glaucoma*, Weinreb, R and Crowston, J. pp(1-7), Kugler, ISBN 90 6299 203 X, Netherlands.
- Parrish R. K. II and Minckler D. (1996) "Late endophthalmitis" filtering surgery time bomb? *Ophthalmology*. 103, pp. 1167-1168.
- Sarkisian, S. (2010). A Replacement for Antimetabolites? Ologen is a new product that modulates wound healing in glaucoma surgery. *Glaucoma Today*. winter2010, pp.22-24 .
- Topouzis, F. (2010). Procedural Treatments: Surgery in End-Stage Glaucoma, In: *Pearls of Glaucoma Management*, Giaconi J & Law S. & Coleman A. and Caprioli J. pp.(323-330), Springer-Verlag Berlin Heidelberg, ISBN 978-3-540-68238-7, New York.

Willoch C. M., Nicolaissen B. (2003). Amnion sheilded trabeculectomy. *Acta Ophthalmologica Scand.* pp.658-659.

IntechOpen

IntechOpen



## **Glaucoma - Basic and Clinical Concepts**

Edited by Dr Shimon Rumelt

ISBN 978-953-307-591-4

Hard cover, 590 pages

**Publisher** InTech

**Published online** 11, November, 2011

**Published in print edition** November, 2011

This book addresses the basic and clinical science of glaucomas, a group of diseases that affect the optic nerve and visual fields and is usually accompanied by increased intraocular pressure. The book incorporates the latest development as well as future perspectives in glaucoma, since it has expedited publication. It is aimed for specialists in glaucoma, researchers, general ophthalmologists and trainees to increase knowledge and encourage further progress in understanding and managing these complicated diseases.

### **How to reference**

In order to correctly reference this scholarly work, feel free to copy and paste the following:

Tharwat H. Mokbel (2011). End Stage Glaucoma, Glaucoma - Basic and Clinical Concepts, Dr Shimon Rumelt (Ed.), ISBN: 978-953-307-591-4, InTech, Available from: <http://www.intechopen.com/books/glaucoma-basic-and-clinical-concepts/end-stage-glaucoma>

**INTECH**  
open science | open minds

### **InTech Europe**

University Campus STeP Ri  
Slavka Krautzeka 83/A  
51000 Rijeka, Croatia  
Phone: +385 (51) 770 447  
Fax: +385 (51) 686 166  
[www.intechopen.com](http://www.intechopen.com)

### **InTech China**

Unit 405, Office Block, Hotel Equatorial Shanghai  
No.65, Yan An Road (West), Shanghai, 200040, China  
中国上海市延安西路65号上海国际贵都大饭店办公楼405单元  
Phone: +86-21-62489820  
Fax: +86-21-62489821



© 2011 The Author(s). Licensee IntechOpen. This is an open access article distributed under the terms of the [Creative Commons Attribution 3.0 License](#), which permits unrestricted use, distribution, and reproduction in any medium, provided the original work is properly cited.

IntechOpen

IntechOpen