

We are IntechOpen, the world's leading publisher of Open Access books Built by scientists, for scientists

4,800

Open access books available

122,000

International authors and editors

135M

Downloads

Our authors are among the

154

Countries delivered to

TOP 1%

most cited scientists

12.2%

Contributors from top 500 universities



WEB OF SCIENCE™

Selection of our books indexed in the Book Citation Index
in Web of Science™ Core Collection (BKCI)

Interested in publishing with us?
Contact book.department@intechopen.com

Numbers displayed above are based on latest data collected.
For more information visit www.intechopen.com



Repair of Impaired Host Peroxisomal Properties Cropped Up Due to Visceral Leishmaniasis May Lead to Overcome Peroxisome Related Genetic Disorder Which May Develop Later After Treatment

Salil C. Datta^{1,2}, Shreedhara Gupta³ and Bikramjit Raychaudhury^{1,2}

¹School of Biotechnology and Biological Sciences,
West Bengal University of Technology, Kolkata,

²Indian Institute of Chemical Biology, Kolkata

³Department of Chemistry, Heritage Institute of Technology, Anadapur, Kolkata
India

1. Introduction

The leishmaniasis is a group of diseases caused by protozoan haemoflagelates of the genus *Leishmania*^{1,2}. These parasites belong to the family of the *Trypanosomatidae* (order *Kinetoplastida*) and are closely related to the Trypanosomes³. Despite enormous efforts, it has proved difficult to predict the exact scale of the impact of leishmaniasis on public health, since many cases remain unreported or misdiagnosed⁴. It is estimated that approximately 12 million people are currently infected and a further 367 million are at risk of acquiring leishmaniasis in 88 countries, 72 of which are developing countries and 13 of them are among the least developed in the world^{1, 4}. Hence we can link leishmaniasis to poverty, economic development and various environmental changes such as deforestation, urbanization, migration of people into endemic areas and building of dams etc⁵. The annual incidence rate is estimated to be 1 to 1.5 million cases of cutaneous leishmaniasis (CL) and 5,00,000 cases of visceral leishmaniasis (VL); these are the two major clinical types of leishmaniasis⁶. The only proven vector of the *Leishmania* parasite is the blood-sucking female sandfly^{1,7} of the genus *Phlebotomus* in the old world and *Lutzomyia* in the new world⁸. The insects are 2-3 mm long (one-third the size of typical mosquitoes) and are found throughout the tropical and temperate parts of the world. The sandfly larvae require organic matter, heat and humidity for development and so are commonly found in house-hold rubbish, burrows of old trees and in cracks in house walls⁹. The sand flies usually feed at night while the host is asleep¹⁰. There are five most important *Leishmania* species namely *L. tropica*, *L. major*, *L. donovani*, *L. braziliensis braszliensis*, *L. b. peruviansis* and *L. mexicana* which cause the three forms of the disease dermal CL (oriental sore), VL and mucocutaneous leishmaniasis (Chiclero's diseases and Espundi)^{11, 12, 13}. *Leishmania* exhibits a dimorphic life cycle¹⁴ involving two life-cycle stages, the elongated promastigote with free flagellum present in the insect and the intracellular amastigote form¹⁵.

VL, commonly known as kala azar, is characterized by irregular bouts of fever, substantial weight loss, swelling of the spleen and liver, and anaemia (occasionally serious)¹⁶. VL was first described in 1903, by Dr. William Boog Leishman^{17, 18, 19}, an English military surgeon and Dr. Charles Donovan^{17, 20}, an Irish physician by identifying the parasites in spleen smears of a patient died of "Dum-Dum fever" i.e. a low degree of fever with hepatosplenomegaly and severe progressive cachexia (wasting), swollen lymph glands, leucopenia, thrombocytopaenia with relative monocytosis and loss of hair^{18, 20}. These physicians reported the existence of the parasite for visceral leishmaniasis and so the causative agent acquired the name as *Leishmania donovani*²¹. This is not to say that leishmaniasis did not exist before 1903, on the contrary. Archibadi in 1922 described an epidemic of Kala-azar, which occurred in the Garo hills of Assam²² and in Saudi Arabia^{23, 24} as far back as 1870. Cunningham recorded a similar disease that occurred in 1885, caused by a parasite²⁵, which was later named *Leishmania tropica*, the causative agent of CL²⁶. Nicolle in 1908 reported that mammals including dogs could act as reservoir hosts for the *Leishmania* parasite²⁷. Swaminath *et al* in 1942, proved using human volunteers that the *Leishmania* parasite could be transmitted by the phlebotomus sandflies²⁸.

If left untreated, the fatality rate of VL in developing countries can be as high as 100% within 2 years. The recommended drugs for VL are the pentavalent antimonials sodium stibogluconate (Pentostam) and Meglumine Antimoniate (Glucantime)²⁹. Both drugs have been used for over 50 years, and they require long courses of parenteral administration. The treatment has traditionally been unsatisfactory because of drug toxicities, poor responses, multiple disease syndromes and other factors including the recent emergence of antimony-resistant strains³⁰. Side effects of sodium stibo gluconate (SAG) include changes in liver function, biochemical pancreatitis, electrocardiogram (EKG) changes, musculoskeletal symptoms, thrombocytopenia etc. Alternative treatments for VL include the polyene antibiotic amphotericin B³¹ that constitute highly effective, less toxic lipid formulations^{32, 33}. In regions of India where there is a high frequency of resistance to antimony, amphotericin B in a dose of 15-20 mg/kg, body wt is administered intravenously (IV) over a period of 30-40 days³⁴. Recently several compounds of herbal origin have been reported to have potency against VL^{35, 36, 37}.

Post Kala azar dermal leishmaniasis (PKDL) occurs in India and mainly in Sudan and Kenya in Africa³⁸. Reports of PKDL in China, Iraq and Nepal have also been documented^{39,40}. In the new world PKDL is extremely rare⁴¹. Usually PKDL follows recovery from a Kala azar infection, though less commonly, it has been known to occur in patients who have not suffered previously from Kala azar⁴². Both the Indian and the African PKDL display similar symptoms. The disease begins with small measles-like lesions (hypopigmented macules, papules or nodules) appearing on the face, and gradually increase in size. Eventually the lesions spread to the upper trunk, arms, forearms, thighs, legs, abdomen, the neck and the back. The multiple lesions can coalesce to form larger lesions and can lead to the gross enlargement of facial features such as the nose and lips, giving an appearance similar to leprosy. The disease is particularly severe if the lesions spread to the mucosal surfaces of the nasal septum, hard and soft palate, oropharynx, larynx or the eye lids and the cornea leading to blindness^{43, 44}. Potentially the lesions can appear on any part of the body. There have been reports of lesions occurring on the glands of the penis and genital mucosa hence the possibility of PKDL being transmitted sexually. In addition to the disease being confused with leprosy, PKDL can also resemble cutaneous leishmaniasis, secondary syphilis and sarcoidosis⁴⁴. The lesions are usually self-limiting, however those that do not

heal spontaneously within six months have to be treated⁴⁵. Pentavalent antimonials remain the drugs of choice for treating PKDL. SAG at a dose of 20 mg/Kg of body weight administered intramuscularly for 4-5 months is recommended. In addition Ketoconazole and allopurinol can be given orally to improve response. In antimony resistant cases amphotericin B is an effective replacement^{44, 46}. The reason for incidence of PKDL is still not clear and the evidence is yet to be explored. Several studies indicate that PKDL may develop as a result of genetic disorder during the parasitic disease kala azar. Indian PKDL appears anything between 1-7 years after apparent cure of Kala azar, although longer periods of upto 20-30 years have been reported⁴⁷. The African form of the disease usually appears within a few months after cure, in most cases within 6 months, on average within 56 days. However it can develop during the treatment Kala azar, in which case the term Para Kala azar dermal leishmaniasis would seem more fitting⁴⁸. The choice available drug is limited and inadequate⁴⁹.

Although the geographical distribution of *Leishmania* infection is restricted to the area of distribution of *Phlebotomus* sandflies, Human immunodeficiency virus (HIV) infection may modify the traditional anthroponotic pattern of VL transmission. Very rarely *Leishmania* transmission has been described by alternative means that are also shared by HIV transmission, including blood transfusion⁵⁰ congenital transmissions^{51, 52, 53} and laboratory acquired⁵⁴. Worldwide, VL mainly occurs in HIV negative individuals more so in paediatric patients⁵⁵. The association of *Leishmania* with HIV⁵⁶ has lead to a significant shift in the age of people at risk^{57, 58, 59}.

In South West Europe, 75 per cent of HIV sero negative and 80-83 per cent of HIV positive patients seen with VL were men^{59, 60}.

Leishmania/HIV co-infection is emerging as a serious new disease pattern and is becoming increasingly frequent. Of the 1700 cases of co-infection reported to the World Health Organization from 33 countries worldwide up to 1998, 1440 cases were from South-West Europe: Spain (835), Italy (229), France (259) and Portugal (117). Of 965 cases retrospectively analyzed, 83.2 per cent were males, 85.7 per cent were young adults (20-40 yr) and 71.1 per cent were intravenous drug users⁶¹.

Most co-infections in the Americas are reported from Brazil where the incidence of HIV has risen from 0.8 cases per 100,000 inhabitants in 1986 to 10.5 cases per 100,000 inhabitants in 1997⁶². In India, the HIV/*Leishmania* co-infection has not been extensively studied. The risk of visceralization for HIV positive person, infected with *Leishmania* species typically associated with cutaneous disease, is not much of a problem, since VL is several thousand times more common than CL in India. However, this may be a very serious issue in the Mediterranean countries where CL is very common⁶³.

A majority of HIV/*Leishmania* co-infected cases show classical features of VL. These co-infected patients may also have other features, viz., atypical location due to decreased cell mediated immunity (CMI) ^{64,65}, parasitic dissemination to skin, cutaneous and reticulo-endothelial system (RES), a chronic and a relapsing course, poor drug response and lack of anti-leishmanial antibodies.

The incubation period is variable and may be age related^{66, 67}. Other concomitant opportunistic infections are diagnosed in 42-68 per cent of HIV-positive patients⁶⁸. Fever, pancytopenia, hepatosplenomegaly are common. Classically, splenomegaly may be less in HIV positive patients⁶⁹. Constitutional symptoms (asthenia, anorexia, weight loss etc.) are seen in 50-70 per cent of patients and lymphadenopathy in 15-60 per cent of patients. VL with HIV infection may present as pyrexia of unknown origin (PUO). Other opportunistic

infections like mycobacterial infection, cytomegalovirus (CMV), pneumonias and Acquired immune deficiency syndrome (AIDS) related neoplasms may also occur^{70, 71}.

Gastrointestinal (GI) symptoms are among the most frequent complaints^{72, 73, 74}. Leishman-Donovan (LD) bodies have been identified in up to 50 per cent of such patients. The commonest site of involvement is the jejunum^{75, 76}. Endoscopy and routine biopsy are important tools in the diagnosis. The symptoms may include diarrhoea, malabsorption, and hypoalbuminaemia and weight loss. There may be erosive gastro-duodenitis, ulcers and colony lesions.

Cutaneous involvement⁷⁷ may appear in the skin with Kaposi sarcoma, Herpes simplex or Zoster. *Leishmania* may be associated with dermatofibroma, psoriasis, Reiter's syndrome, bacillary angiomatosis, cryptococcosis and oral aphthous ulceration. It may also present as dermatomyositis like eruption^{78, 79}.

Respiratory tract involvement occurs in alveoli and pulmonary septa in 75 per cent of patients with VL⁸⁰. They could present with pulmonary tuberculosis and pneumonia, more commonly *Pneumocystis carinii* pneumonia (PCP). The symptoms could be cough, breathlessness, haemoptysis and excessive sputum production. Renal involvement can occur. Glomerulonephritis with mild proteinuria, haematuria and even acute renal failure have been reported. Tubulointerstitial damage can also occur⁸¹.

Central nervous system (CNS) involvement is very common in the late stages. Pandey et al⁸² reported cases in which HIV-*Leishmania* co-infection was associated with pulmonary tuberculosis and tuberculoma in the brain neurocysticercosis and tuberculous meningitis. AIDS dementia complex occurs in the late stages and may lead to early death. In such cases, cluster of differentiation 4 (CD4) count has been reported to be as low as <50 cells/mm³. Pancreatic, pulmonary, pleural, laryngeal, adrenal, pericardial, myocardial and lingual leishmaniasis have also been reported. Mucocutaneous leishmaniasis appears in 2-3 per cent of VL-HIV co-infected patients⁸³⁻⁸⁹.

Diagnosis is quite difficult as only 40-50 per cent of VL/HIV co-infected cases have a positive *Leishmania* serology⁹⁰. This percentage is inversely proportional to CD4 cell depletion. Anti-*Leishmania* antibodies in HIV-positive patients are 50 times less than those in HIV-negative patients⁹¹. Therefore, there may be many false negative tests. The direct examination of amastigotes in the splenic and bone marrow aspiration has been the gold standard. Detection of *Leishmania* antigens by Western blot in the urine samples is being tried. Polymerase chain reaction (PCR) techniques requiring blood and tissue samples are very time consuming^{92, 93}. However, when used in combination with Enzyme-linked immunosorbent assay (ELISA) and Direct Agglutination Test (DAT) the results are very encouraging. Nested PCR assay has a sensitivity of 95 per cent in the peripheral blood and 100 per cent in bone marrow/ splenic aspirates^{94, 95}.

Certain issues are significant in the management of HIV/*Leishmania* co-infected patients. Firstly, optimal duration of treatment is to be given. Secondly, the dose has to be monitored and thirdly, there is frequent relapse.

Sodium antimony gluconate (SAG) has developed resistance and low cure rates of 30-50 per cent have been reported³². In such patients, the treatment with SAG has to be given for a longer period⁹⁶. However, the longer duration of therapy may lead to cardiotoxicity. With SAG, there are frequent relapses as seen often in Bihar, India⁹⁷. Amphotericin B has also been tried and response rate of 60 per cent has been observed but 25-60 per cent of the patients treated with amphotericin B, are likely to have relapse during the first year after completion of treatment⁹⁸. HIV infected individuals are more likely to suffer from drug

related adverse events. In almost all the patients, depending on the CD4 counts (<200/ml) Highly Active Antiretroviral Therapy (HAART) can be given⁹⁹. Amphotericin B can be given at a dose of 1 mg/kg for 15 days. Although lipid formulations are less toxic, they are very costly⁹⁹. Pentamidine is usually not effective and should not be used due to its toxic effects. Oral miltefosine^{100, 101} is a promising alternative at a dose of 2.5 mg/kg for 28 days and has been tried by Thakur et al¹⁰² in six co-infected patients with good results. Besides treatment of VL and administration of HAART, other secondary infections like tuberculosis of the chest, oral candidiasis, CMV infections, *Pneumocystis carinii* pneumonia (PCP), toxoplasmosis, Kaposi sarcoma also need to be treated¹⁰³.

Peroxisomes^{104, 105} are the single-membrane bound, catalase containing cytoplasmic organelles that contain a fine granular matrix, present in all eukaryotic cells (except the red blood cells), including the mammalian host. No such catalase containing subcellular organelle is present in the parasitic protozoa *Leishmania*¹⁰⁶

Peroxisomes were first detected morphologically; their biochemical functions were characterized sometimes later. Johannes Rhodin, in 1954, described small organelles (0.5 μm in diameter) in mouse kidney cells and identified them as microbodies. Later in 1965, Christian de Duve¹⁰⁷ proposed the name peroxisomes (as they are peroxide-metabolizing organelles), for the distinct organelles isolated by density-gradient centrifugation. These organelles contained enzymes for both the production and disposal of hydrogen peroxide (H_2O_2). H_2O_2 generates reactive oxygen species, which are fatal in all respects. They interact with a variety of cellular macromolecules and lead to variety adverse effects like, membrane damage (lipid peroxidation), DNA damage (strand breakage), alteration in the protein structure (thiol oxidation) and the ultimate consequence may be the loss of cell viability (cytotoxicity and cell death)¹⁰⁸.

Catalase is the marker enzyme for peroxisome as it is the most abundant enzyme within the structure¹⁰⁹. Active catalase is a heme- containing protein with four identical subunits (tetramer). In mammalian liver and kidney cells, peroxisomes are roughly spherical and relatively large (0.5 to 1.5 μm in diameter). In other tissues, they are smaller (0.1 μm) and known as micro-peroxisomes. In mammalian cell, the average number of peroxisomes is approximately 400 that occupy 1% of the total volume of the cell. However, their size, number, and enzyme profile vary between different tissues¹¹⁰. In most cases, peroxisomes contain dense or granular matrix containing catalase (About 40% of the total peroxisomal protein is catalase) and a crystalline core composed of enzyme urate oxidase. Peroxisomes have a half-life of about 36 hrs and they divide by fission¹¹¹.

The process of formation of peroxisome involves multiple pathways. Lipids must be recruited to form the membrane. Lipid composition of the peroxisomal membrane differs from that of the total cellular profile¹¹². Peroxisomal proteins (not glycosylated) are synthesized in the cytosolic free polyribosomes¹¹³ and transported to pre-existing peroxisomes. These include both the peroxisomal membrane proteins (PMP) and peroxisomal enzymes¹¹⁴

The multifunctional structures begin through orchestrated reactions of some proteins, called peroxins¹¹⁵. These are the critical processes as their defects leave the cells either devoid of peroxisomes or with organelles rendered unable to carry out numerous biochemical and metabolic functions attributed to them; such failings often cause a disease¹¹⁶.

Approximately fifty different biochemical processes occur exclusively within a peroxisome. Some of the reactions are anabolic i.e. constructive, resulting in the synthesis of essential biochemical compounds including bile acids, cholesterol, plasmalogens (phospholipid analogues), and docosahexanoic acid (DHA), which is a long chain fatty acid that is a

component of complex lipids, including the membranes of central nervous system. Other reactions are catabolic i.e. destructive and lead to the lysis of some fatty acids, via β -oxidation including very long chain fatty acids¹¹⁷⁻¹¹⁹.

Peroxisomes contain several oxidative enzymes, which generate H_2O_2 as a by-product of their reactions. This highly poisonous reactive oxygen species (ROS) is rapidly converted to H_2O through the action of peroxisomal catalase, at least under most circumstances. A number of degenerative diseases are linked to ROS induced alternation in cellular functions¹²⁰. The reactions are catalyzed by appropriate FAD-linked enzyme: a) urate oxidase, b) xanthine oxidase, and c) L- and D- amino acid oxidases. Flavin oxidases reduce oxygen to H_2O_2 , which is then decomposed by catalase¹²¹. However the peroxisomal pathway differs from that of the mitochondria in several important respects¹²².

β -oxidation pathway similar to that of mitochondria is present in peroxisomes and the process is carried out by two distinct groups of enzymes. The classical first group utilizes straight chain saturated fatty acyl-CoA as substrates, whereas the second group acts on the branched chain acyl-CoA^{119, 124}.

Severe effects of peroxisomal dysfunction, which secondarily leads to several human and animal diseases, emphasize the importance of peroxisomes for survival. Depending on the specific defect, clinical manifestations range from the mild to the fatal.

There are about 25 peroxisomal disorders known, although the number of diseases that are considered to be separate, distinct peroxisomal disorder varies among the researchers and health practitioners^{125, 126}. Peroxisomal disorders are subdivided into two major categories.

The first category is the disorders resulting from a defect in a single peroxisomal enzyme¹²⁷. These disorders include hyperoxaluria type I (alanine: glyoxylate aminotransferase), Refsum's disease (phytanoyl-CoA hydroxylase), X-linked adrenoleukodystrophy (ALDP), rhizomelic chondrodysplasia punctata (RCDP) types II and III (dihydroxyacetone phosphate acyl transferase), and the β -oxidation disorders (acyl CoA-oxidase, bifunctional protein, and thiolase). These disorders result from a deficiency in only a single enzyme of the peroxisome, and therefore generally only affect a single peroxisomal metabolic pathway.

Conversely, there is also a set of disorders which results from a malfunction to form intact, normal peroxisomes, resulting in multiple metabolic abnormalities, which are referred to as peroxisome biogenesis disorders (PBD) or as generalized peroxisomal disorders¹²⁸ and include the Zellweger syndrome (ZS), Neonatal adrenoleukodystrophy (NALD), Infantile Refsum disease (IRD). Rhizomelic chondrodysplasia punctata (RCPD) type I.

Several proteins have been identified which play a role in the degradation of peroxisomes¹²⁹⁻¹³³. There are a number of reports in the literature describing the histology of the liver, spleen, and lymphoid organs of VL, during human disease and experimental infection¹³⁴⁻¹³⁶. In an experimental model of VL in golden hamsters, histopathological analysis showed¹³⁷ dissemination of the parasite mainly to liver & spleen. The former organ showed hypertrophy and hyperplasia of Kupffer cells with focal areas of inflammatory infiltration in nodular pattern. Gross examination of the liver indicated hepatomegaly. The spleen disclosed intense proliferation and enlargement of mononuclear phagocytic cells, revealing nodular configuration.

Both biochemical and morphological changes that take place in host peroxisomes during *Leishmania* infection, was detected^{138, 139} pointing to the occurrence of a peroxisomal disorder during this parasitic disease. Liver peroxisomes were found to be functionally defective when purified after *L. donovani* infection. The activities of key enzymes catalase, urate oxidase, dihydroxy acetyl phosphate acyl transferase (DHAPAT) and superoxide dismutase (SOD)

were either deficient or could not be detected after parasite infection. H_2O_2 producing peroxisomal β -oxidation was significantly elevated after 90 days of infection, with concomitant induction of superoxide radical production. Proteolytic activity in infected liver peroxisome was found to be inhibited, pointing to possible uneven processing of peroxisomal proteins. The morphology of peroxisomes after *Leishmania* infection was impaired. The evidence obtained for *Leishmania*-induced peroxisomal dysfunction may provide clues to develop new drugs against this parasite, capable of protecting normal function of this ubiquitous host organelle for successful treatment. Calcium is known to be stored in mitochondria and endoplasmic reticulum and is mobilized by second messengers^{140, 141}. As one of the vital organelles of eukaryotic system, role of peroxisomes in mobilizing calcium has recently been explored in which peroxisome was identified as a calcium-containing intracellular organelle for its possible candidacy as one of the mediators towards cell signaling¹⁴².

Immense interest has recently been developed to study peroxisomal properties in more details due to involvement of this mammalian microbody in normal cellular function¹⁴⁰. It has already been reported that infection due to *Leishmania* pathogen leads to host peroxisomal damage¹⁰⁸. As peroxisome is known to be involved in various metabolic pathways to monitor normal function of the host cells¹⁰⁹, it is essential that *Leishmania*-induced dysfunction of this organelle should totally be repaired during treatment of VL. Moreover, a group of human diseases can occur when peroxisomal properties are impaired⁷. It may lead to genetic disorder resulting in various other complications^{143, 144}. It is thus logical to investigate whether treatment of this parasite-borne disease with the existing drugs can reverse peroxisomal defects developed due to *Leishmania* infection to avoid post therapeutic problems¹¹¹ which may occur due to unavailability of specific non toxic drugs against this pathogenic disease. In the present work it has been clearly shown that resumption of normal peroxisomal function could not be attained when one of the existing drugs SAG¹¹² was used for chemotherapy against VL.

2. Materials and methods

2.1 Materials

All the reagents except fetal calf serum (FCS), Medium-199 and sodium antimony gluconate (SAG) were purchased from Sigma Chemicals, USA. Fetal calf serum and Medium-199 were obtained from Gibco BRL, USA. SAG was procured from GlaxoSmithKline, UK.

L. donovani strain MHOM/IN/AG/83 was obtained from Indian kala-azar patient¹⁴⁵ and maintained by intracardial passage every 8 weeks in Syrian golden hamsters. Promastigotes were obtained by transforming amastigotes isolated from infected spleen¹⁴⁶ and maintained in medium- 199 supplemented with 10% fetal calf serum in vitro.

2.2 In vivo study with SAG in *L. donovani* infected hamsters

Syrian Golden hamsters (4 weeks old weighing 50-65 gm) were infected individually with freshly purified *L. donovani* amastigotes through cardiac route. After 30 days of infection the animals were treated with SAG (30 mg/kg body weight). Each hamster received intramuscular injections of the drugs every alternate date for 15 days. The compound was dissolved in DMSO. The final concentration of DMSO was $\leq 0.1\%$ (v/v). Infected hamsters in the control group received 200ml of 0.1% DMSO per animal intramuscularly. Animals of all groups were sacrificed two month after administration of last treatment. The splenic parasite burden was determined from impressions smears after Giemsa staining¹⁴⁷. Total

parasite burden was calculated from the following formula – organ weight (mg) x number of amastigotes per cell nucleus x (2 x 10⁵) All animal experiments were approved by the local body of our institute's animal ethics committee.

2.3 Isolation of Hamster liver peroxisomes

Peroxisomes from normal and infected liver were purified according to the procedure already reported¹⁴⁸. Hamster liver was dissected out to homogenize with buffer at 4 °C containing 0.25 M sucrose, 10 mM TES of pH 7.5, 1 mM EDTA, 0.4 mM phenylmethylsulfonyl fluoride, 0.2 mM leupeptin and 0.1% ethanol. Light mitochondrial fraction from the homogenate was separated by differential centrifugation and then suspended in the same TES-EDTA buffer mentioned above at the 1:1 ratio of liver weight to buffer. 30% Nycodenz (w/v) was prepared in a buffer of pH 7.5 that contained 10 mM TES and 1 mM EDTA. 2 ml of the light mitochondrial suspension was layered over 10 ml of freshly prepared nycodenz solution and centrifuged at 105000×g for 50 min in a Sorvall-ultra 80 ultracentrifuge using T-865 fixed angle rotor. After centrifugation the interfacial materials were aspirated off to obtain pelleted peroxisome which was separated at the bottom of the centrifuge tube. Purified peroxisomes were then suspended in a minimum volume of homogenizing buffer to store at -20 °C.

2.4 Western blot analysis

Peroxisomal proteins were separated by a 10% SDS-PAGE¹⁴⁹ followed by affinity transfer blotting using nitrocellulose paper¹⁵⁰.

2.5 Activity staining for SOD

Peroxisomal SOD was separated on a 10% nondenaturing polyacrylamide gel¹⁴⁹ for activity staining¹⁵¹. Gels were incubated in solution A (20 mg Nitro Blue Tetrazolium in 10 ml glass distilled water) for 20 min, then in solution B (4mg Riboflavin, 0.4 gm K₂HPO₄ and 600 µl TEMED in 50 ml glass distilled water, pH 7.8) for another 20 min and finally illuminated until white bands appeared on a blue background

2.6 Assay of enzymes

Catalase activity was determined by monitoring the decomposition of H₂O₂ at 240 nm¹⁵². SOD activity was assayed by determining ability of this enzyme to inhibit pyrogallol autoxidation rate¹⁵³. The assay mixture contained 0.2mMpyrogallol in air-equilibrated 50mMTris-cacodylic acid buffer, pH 8.2, and 1mM ethylenediaminetetraacetic acid. Rate of autoxidation was obtained by monitoring the increase in absorbance at 420 nm in a Hitachi spectrophotometer, No U2000. SOD has the ability to inhibit autoxidation and the extent of inhibition is taken as the measure of enzymic activity. Protein was determined using Folin and Ciocalteu's phenol reagent¹⁵⁴.

2.7 Electron microscopy

Peroxisomes were fixed, processed to embed in Spur medium¹⁵⁵ to cut thin sections, and then stained to examine under an electron microscope (Hitachi-H600) at 75KV.

2.8 Immunofluorescence

Peroxisomes were fixed with formaldehyde in PBS for 15min, permeabilized 0.3% Triton X-100 in PBS for 5min, and then blocked with 3% bovine serum albumin in PBS for 30min.

were first incubated with appropriate primary antibodies (1: 100) for 30min followed by Alexa 633 coupled secondary antibody (1:100) for another 30min and then examined under TCS-SP Leica confocal microscope having krypton-argon mixed-laser facility.

2.9 Statistical analysis

Statistical analyses were conducted through Student's *t*-test as described¹⁵⁶

3. Results

3.1 Effect of SAG on Leishmania infected hamsters macrophages

Following 30 days of *L. donovani* infection the animals were treated SAG at a dose of 30 mg/kg body weight, dissolved in DMSO, and the splenic parasite burden was determined after two months of the last dose given as described in materials and methods. In case of the SAG treated animals, no parasite was detected (data not shown).

3.2 Electron microscopic study of Peroxisomes after SAG treatment

Peroxisomes were isolated from normal, *Leishmania* infected as well as cured SAG treated hamster livers and processed for electron microscopic studies. In case of normal peroxisomes, electron dense core was observed inside the matrix and the average diameter was found to be 0.37 μm (Figure 1A). But peroxisomes isolated after infection were found to be swollen with severe membrane distortion, and the electron core became scattered, and a few of them had no core inside. The average diameter of the swollen organelle was determined to be 0.82 μm (Figure 1B). Peroxisomes obtained after SAG treatment showed interesting results. The membranes were no more distorted and the organelles were reduced almost to their normal size. The average diameter was found to be 0.4 μm (Figure 1C). But in most of the organelles, the dense electron core inside the matrix was not detected.

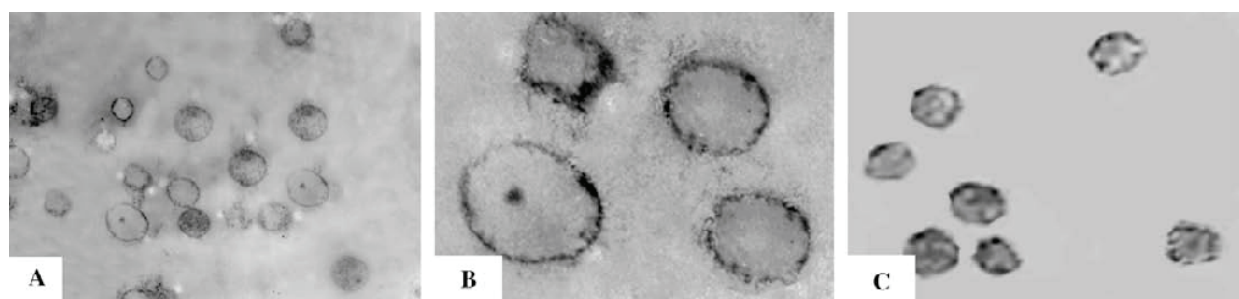


Fig. 1. Electron micrograph of hamster liver peroxisomes ($\times 50,000$). Peroxisomes after pre- and post-fixation with 6% gluteraldehyde and 1% osmium tetroxide were examined under Hitachi electron microscope at 75 KV. A. Normal Peroxisomes, B. Peroxisomes post 90 days infection, C. post SAG treatment

3.3 Assay of peroxisomal enzymes before and after SAG treatment

Peroxisomal marker enzyme catalase was assayed in peroxisomes isolated from normal, *L. donovani* infected as well as cured animal livers after SAG treatment. Specific activity of Catalase is known to be diminished during *Leishmania* infection¹⁵⁷ and the same was obtained in this case (Table 1), but catalase activity was not restored back in peroxisomes obtained from SAG treated cured hamsters (Table 1). Activity of another important peroxisomal enzyme SOD was also not detected in case of peroxisomes isolated after SAG treatment (Table 1).

Enzyme Specific Activity (unit/mg protein)	Normal	Infected	SAG Treated
Catalase	3373	1884	1763
SOD	3.2	ND	ND

Table 1. Enzyme activities in normal peroxisome, peroxisome after 90 days infection and peroxisomes after post SAG treatment. Results are in mean \pm S.D. for three different experiments

3.4 Protein profiles of peroxisomes

Figure 2 indicates that the peroxisomal protein profiles of normal, infected and SAG treated cured hamsters livers were different when subjected to SDS-PAGE. Densitometric scanning pointed to three distinct protein bands of Mr 104.5, 80.6 and 50.4, although when found to be present in peroxisomes after infection and after SAG treatment, they could not be detected in normal peroxisomes. Significant differences were also observed for the protein bands of Mr 30.2, 28.0, 20.9, 10.3 and 9.7 (Figure 2).

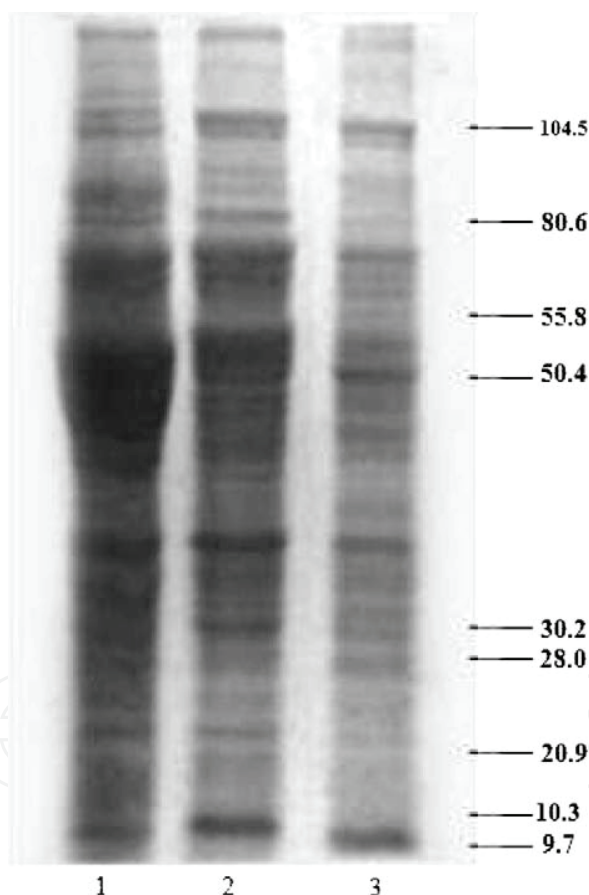


Fig. 2. SDS-PAGE analysis of peroxisome prepared from normal hamster liver (Lane 1), hamster liver infected with *Leishmania* parasite for 90 days (Lane 2), post SAG treatment (Lane 3). 40 μ g protein samples were run on 10% polyacrylamide gel

The same PAGE when subjected to Western Blotting and probed with anti Cu-Zn SOD to find out the presence of SOD in the organelles isolated at various conditions, showed that SOD was not detected in peroxisomes obtained infected as well as SAG treated cured hamsters (Figure 3).




Fig. 3. Western blot analysis of glycosomal proteins. Peroxisomes were subjected to SDS PAGE for separation of proteins, transferred to nitrocellulose, and then incubated With antibody against Cu- Zn SOD. Normal peroxisomes (Lane 1), peroxisomes post 90 days infection (Lane 2), peroxisomes post SAG treatment

3.5 Impact on SOD activity

Activity staining of native polyacrylamide gels clearly showed that SOD activity of infected and SAG treated peroxisomes was totally lost (Figure 4).

In a separate experiment, presence of SOD was examined using anti Cu-Zn SOD under confocal microscope. SOD was not detected in infected (Figure 5B) as well as in SAG treated (Figure 5C) hamster liver peroxisomes. Normal peroxisomes were used as positive controls (Figure 5A).

4. Discussion

Peroxisomes are abundant in host reticuloendothelial cells¹⁵⁸. The role and importance of peroxisomes in a wide variety of metabolic pathways, including longchain fatty acid β -oxidation, ether-linked glycerolipid biosynthesis, and H_2O_2 -based respiration, have been thoroughly studied¹⁵⁹⁻¹⁶¹. The importance of fatty acid β -oxidation for the survival of microorganisms in other parasitic and fungal diseases has already been documented¹⁶²⁻¹⁶⁴. Hamster liver peroxisomes are found to be severely damaged, both morphologically and bichemically, during *Leishmania* infection¹⁵⁷. The structure and function of this host organelle are reported to be highly affected by the parasitic attack. The pentavalent antimonial compound SAG are widely used as first-line chemotherapeutic^{165, 166} agents against all forms of leishmaniasis including visceral leishmaniasis^{167, 168}. In this work, we have assessed the status of host liver peroxisomes after the complete treatment of the *L. donovani* infected animals with standard dose of SAG.

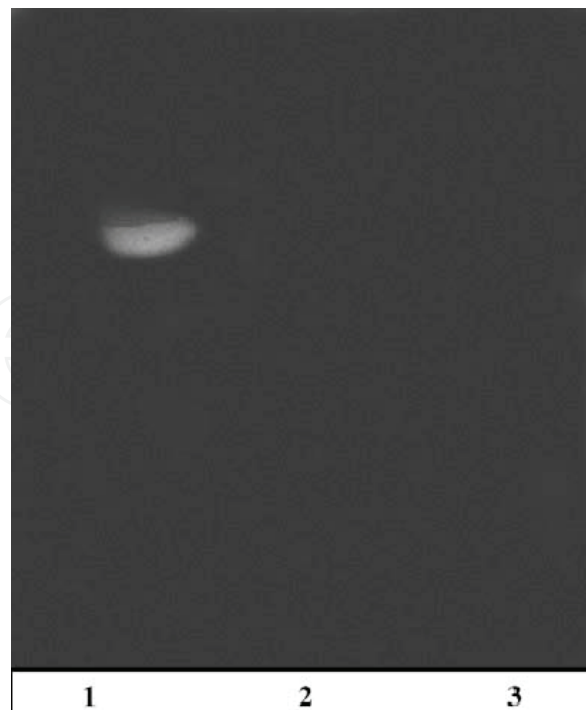

Fig. 4. Activity staining of SOD after conducting non denaturing PAGE. Staining was carried out according to the procedure described under Materials and methods Normal peroxisomes (Lane 1), peroxisomes post 90 days infection (Lane 2), peroxisomes post SAG treatment (Lane 3)

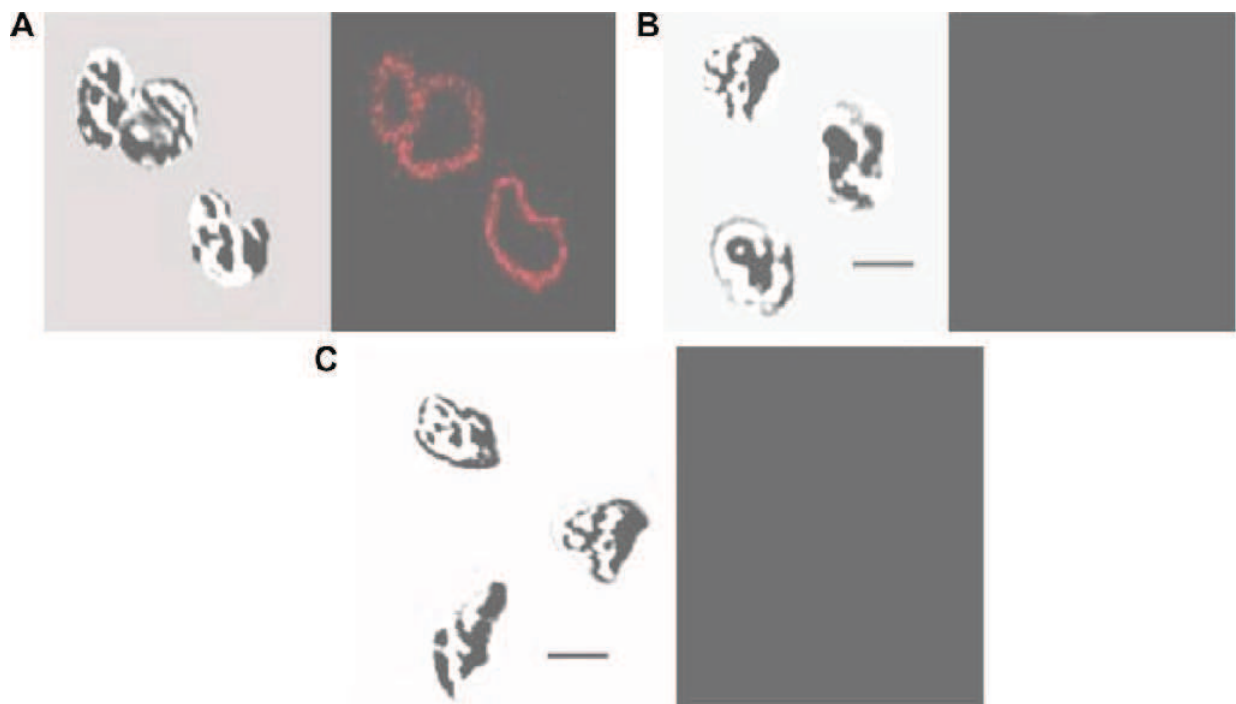


Fig. 5. Confocal microscopy of Normal Peroxisomes After treatment anti Cu-Zn SOD peroxisomes were examined under a Leica DM IRB inverted microscope. Normal peroxisomes (Set A), peroxisomes post 90 days infection (Set B), peroxisomes post SAG treatment (Set C)

Peroxisomes were isolated by standard procedure¹⁴⁸ from normal hamsters, also from animals after *Leishmania* infection and from hosts after complete cure of the parasitic disease using conventional SAG treatment^{169,170}. When parasite burden was measured two months after administration of the last dose, no parasite was detected in hamster spleen or liver, and that gave indication towards the complete cure of the disease.

The diameter of normal peroxisome is known to vary between 0.5 to 1.0 μm in animal tissues^{171, 172}. However, the average diameter of hamster liver peroxisome was found to be 0.37 μm . As evidenced by electron microscopic examination the morphology of the peroxisomes after parasite infection was found to be different. Membrane structure was damaged and the dense electron matrix¹⁷² was unevenly distributed, with the appearance of dark patches having an average diameter of 0.82 μm . The presence of large peroxisomes suggests the swelling of these organelles during infection. But the average diameter of peroxisomes isolated from hamsters after SAG treatment was determined to be 0.4 μm , which is quite similar to that of the normal organelles, indication that damaged peroxisomes are morphologically repaired after SAG treatment.

On the other hand, the key peroxisomal enzyme catalase^{173, 174, 175} was found to be less active after host-parasite interaction. But when catalase activity was examined in SAG treated hamster liver peroxisomes, it was found that the enzyme activity was not restored back, even after complete cure of the parasitic disease, indicating that the peroxisomes are biochemically not repaired after SAG treatment.

SOD is one of the key enzymes of oxygen defense system. It is known to be an essential factor in mediating normal cellular functions^{176, 177}. It is already reported that peroxisomal SOD activity is not detected after *Leishmania* infection¹⁵⁷. In this study, the results clearly revealed that this essential enzyme is absent even in the peroxisomes isolated from hamster livers, after SAG treatment. In a separate experiment, Western Blot analysis showed no band for SOD in case SAG treated host liver peroxisomes. Activity staining of native polyacrylamide gels also showed that activity of peroxisomal SOD, was lost completely after parasitic disease, and could not be detected after SAG treatment. Confocal microscopic studies also revealed the same results, indicating that peroxisomal SOD activity was not restored back post SAG therapy.

Difference in protein profile in peroxisomes isolated from normal, infected as well as SAG treated hamster livers also indicate towards the status of peroxisomes. Some distinct bands were found in the infected and SAG treated peroxisomes, but were absent in normal peroxisomes. During *Leishmania* infection, some proteins get damaged and also proteolytic cleavage takes place, as result, more bands were obtained in infected peroxisomes¹⁵⁷. The similarity in protein profiles between infected and SAG treated peroxisomes revealed that the biochemical properties of peroxisomes are not restored properly after SAG treatment.

Considering the knowledge we have gathered from the present work, it is clearly established that the peroxisomes, that get damaged during *Leishmania* infection are morphologically repaired after treatment with a common antileishmanial agent SAG, but the biochemical properties are not restored back.

PKDL is a common problem^{178, 179} in kala azar patients but the actual reason behind the occurrence of this disease is not yet known. Several peroxisomal disorders like ZS, IRD etc are also reported. Treatment with a common drug SAG, could repair the morphology of the distorted peroxisomes but the biochemical properties are not restored¹⁸⁰.

We propose that the peroxisomal defects caused by infection of the parasite *Leishmania donovani* lead to induce symptoms similar to genetic defects in the biogenesis of

peroxisomes. Although there is no authentic evidence available at this time, defective peroxisomes may also be the root to crop up PKDL in post kala-azar patients. Extensive investigations are still needed to sort out various unresolved problems in these areas to provide clues for new drug development against leishmaniasis. Present research in our laboratory is oriented towards this direction.

5. Conclusion

VL is a deadly disease of viscera caused by the parasite *Leishmania donovani* and also known as kala-azar. The internal organs particularly liver, spleen, bone marrow and lymph nodes are attacked when the parasitic protozoa is transmitted to humans by infected female sand fly bites. People of Mediterranean and adjacent countries are attacked with this pathogen in the form of flagellated promastigotes. However, aflagellated amastigotes are found inside and outside of the affected reticuloendothelial cells.

At this time there is no definite antileishmania agent which may be used confidently to treat VL for a permanent cure. Drugs of choice available in the market, are being taken up selectively by trial and error methods. Most of them are too toxic to cause severe secondary infections and at the same time very costly to afford. Moreover, drug resistance is one of the acute problems to provide guarantee for a complete cure of VL. As a result there is an urgent need to explore for new drug development against this parasitic disease which is lethal, if untreated.

While exploring our attempts to identify an authentic chemotherapeutic agent against VL we also took into account the occurrence of PKDL. There are reports to believe that cured kala-azar patients as certified by the physicians, are susceptible to return for the treatment of PKDL.

Cause of PKDL is still not known. It is possible that the said pathogenic disease is occurred due to continued impaired function of the internal host organs even after treatment with commonly found drugs. We have shown that host liver peroxisomal properties are impaired due to the attack by *Leishmania* pathogen. We have also reported that the affected peroxisomes are not repaired after adequate treatment with the existing drugs. Treated animals with deficiency in peroxisomal properties also do not survive for a long time.

It is known that that peroxisomal defects lead to various genetic disorders. It is still not known whether in treated patients of VL who are likely to carry peroxisomal deficiencies even after traditional treatments, symptoms similar to genetic defects in the biogenesis of peroxisomes are developed.

A novel chemotherapeutic agent has been discovered in our laboratory to prove that this antileishmania agent has the ability to repair peroxisomal damage which takes place due to attack by VL. This finding may lead to provide effective clues to develop new and more potent drugs to stop recurrence of this pathogenic disease in other forms including chance to trigger symptoms develop due to peroxisomal disorder.

6. References

- [1] Piscopo, T. V. and Mallia, A. C. Leishmaniasis. Postgrad Med J. 2006 82(972): 649-57. Review
- [2] Soares, R. P., Turco, S. J. *Lutzomyia longipalpis* (Diptera: Psychodidae: *Phlebotominae*): a review. An. Acad. Bras. Cienc. 2003 75 (3): 301-30

- [3] Opperdoes, F. 1997 8 October. Web Article and Desjeux, P. Human leishmaniasis: epidemiology and public health aspects. *World Health Stat Q* 1992 45: 267-75
- [4] The World Health Report: WHO 1996, Geneva: Switzerland.
- [5] World Health Organization (WHO). Annex 3: Burden of disease in DALYs by cause, sex and mortality stratum in WHO regions, estimates for 2001. In: *The world health report*. Geneva: WHO, 2002 192-7
- [6] WHO website (www.who.int) 1997
- [7] Wenyon, C. The transmission of *Leishmania* infections. *Trans R. Soc. Trop Med Hyg* 1932 25: 319
- [8] Killick-Kendrick, R. *Phlebotomine* vectors of the leishmaniasis: a review. *Med Vet Entomol* 1990 4: 1
- [9] Hawkey, P. M and Gillespie, S. H in *Medical Parasitology: A Practical Approach* by - published by Oxford University Press 1995 pp 151
- [10] Arias, J.R., Monteiro, P.S. and Zicker, F. The reemergence of visceral leishmaniasis in Brazil. *Emerg Infect Dis*. 1996 2(2): 145-6
- [11] Grevelink, S.A. and Lerner, E. A. Leishmaniasis. *J Am Acad Dermatol*. 1996 34(2 Pt 1): 257-72. Review
- [12] Opperdoes, F. 1997 8 October and Kane, M. M., and Mosser, D.M. *Leishmania* parasites and their ploys? To disrupt macrophage activation. *Curr. Opin. Hematol*. 2000 7: 26-31
- [13] Chang, K. P., Fong, D. and Bray, R. S. Leishmaniasis, in: K. P. Chang, R. S. Bray (Eds.), Elsevier, New York, 1985 pp. 1-30
- [14] Kamhawi, S. *Phlebotomine* sand flies and *Leishmania* parasites: friends or foes? *Trends Parasitol*. 2006 22(9): 439-45. Review
- [15] Zhang, W. W., Charest, H., Ghedin, E. and Matlashewski, G. Identification and over expression of the A2 amastigote-specific protein in *Leishmania donovani*, *Mol. Biochem. Parasitol*. 1996 78: 79-90.
- [16] Cunnigham, C. A. Parasite Adaptive Mechanisms in Infection by *Leishmania*; *Experimental and Molecular Pathology*. 2002 72: 132-41
- [17] Herwaldt, B. L. Leishmaniasis. *The Lancet*. 1999 354(9185): 1191-9. Review
- [18] Leishman, W. B. On the possibility of the occurrence of trypanosomiasis in India. 1903. *Natl Med J India*. 1994 7(4): 196-200.
- [19] Leishman, W. B. On the possibility of the occurrence of trypanosomiasis in India. 1903. *Indian J Med Res*. 2006 123(3): 1252-4
- [20] Donovan, C. On the possibility of the occurrence of trypanosomiasis in India. 1903. *Natl Med J India*. 1994 7(4): 196, 201-2
- [21] Sengupta, P.C., Bhattacharjee, B. and Ray, H. N. The cytology of *Leishmania donovani* (Laveran & Mesnil, 1903) Ross, 1903, *J. Indiana State Med Assoc*. 1953 22(8): 305-8
- [22] Sengupta, P. C. A report on kala-azar in Assam. *Ind Med Gaz*. 1951 86(6): 266-71 and A report on kala-azar in Assam (concl'd.). *Ind Med Gaz*. 1951 86(7): 312-7
- [23] al-Zahrani, M. A., Peters, W. and Evans, D. A. Visceral leishmaniasis in man and dogs in southwest Saudi Arabia. *Trans R Soc Trop Med Hyg*. 1988 82(6): 857
- [24] el Sebai, M.M. A case of kala azar in Saudi Arabia. *J Egypt Soc Parasitol*. 1987 17(1): 411
- [25] Cunnigham, C. A. Parasite Adaptive Mechanisms in Infection by *Leishmania*; *Experimental and Molecular Pathology*. 2002 72: 132-41

- [26] Alder, S. The transmission of *Leishmania tropica* by the bite of *Phlebotomus papatasi*. Indian J Med Res 1941 29: 803
- [27] Ashford, R.W. The leishmaniasis as model zoonoses. Ann. Trop. Med. Parasitol. 1997 91: 693-701
- [28] Swaminath, C., Shortt, H. and Anderson, L. Transmission of Indian kala-azar to man by the bites of *Phlebotomus argentipes*, ann. and burn. Indian Med Res 1942 30: 473
- [29] Sundar, S. and Chatterjee, M. Visceral leishmaniasis - current therapeutic modalities. Indian J Med Res. 2006 123: 345-352.
- [30] Brochu, C., Wang, J., Roy, G., Messier, N., Wang, X. Y., Saravia, N.G. and Ouellette, M. Antimony uptake systems in the protozoan parasite *Leishmania* and accumulation differences in antimony-resistant parasites. Antimicrob Agents Chemother. 2003 47(10): 3073-9
- [31] Thakur, C. P., Singh, R. K. Hazar, S. M. Kumar, R., Narain, S. and Kumar, A. Amphotericin B deoxycholate treatment of visceral leishmaniasis with newer modes of administration and precautions: a study of 938 cases. Trans. R. Soc Trop Med Hyg. 1999 93(3): 319-27
- [32] Sundar, S. Drug resistance in Indian visceral leishmaniasis. Tropical Medicine and International Health. 2001 6(II): 849-54
- [33] Bern, C., Adler-Moore, J., Berenguer, J., Boelaert, M., den Boer, M., Davidson, R. N., Figueras, C., Gradoni, L., Kafetzis, D. A., Ritmeijer, K., Rosenthal, E., Royce, C., Russo, R., Sundar, S. and Alvar, J. Liposomal amphotericin B for the treatment of visceral leishmaniasis. Clin Infect Dis. 2006 43(7): 917-24
- [34] Sudar, S., Jha, T, K. and Thakur, C. P. Oral Miltefosine for Indian visceral leishmaniasis. N. Engl. J. Med. 2002 347: 1739-46
- [35] Rocha LG, Almeida JR, Macedo RO, Barbosa-Filho JM. A review of natural products with antileishmanial activity. Phytomedicine 2005;12:514-35.
- [36] Bhattacharjee S, Gupta G, Bhattacharya P, Mukherjee A, Majumdar SB, Pal A, et al. Quassin alters the immunological patterns of murine macrophages through generation of nitric oxide to exert antileishmanial activity. J Antimicrob Chemother
- [37] Gupta. S, Datta, S.C et al. Momordicatin purified from fruits of *Momordica charantia* is effective to act as a potent antileishmania agent. Parasitology International. 2010 59: 192-197
- [38] Zijlstra, E. E, Musa, A.M. and Khalil, A. M. Post kala-azar dermal leishmaniasis. Lancet Infect Dis. 2003 3(2): 87-98
- [39] Ramesh, V. and Mukherjee, A. Post kala azar dermal leishmaniasis. Int. J. Dermatol. 1995 34(2): 85-91
- [40] Gang, U.K., Agrawal, S. and Rani, S. Post-kala-azar dermal leishmaniasis in Nepal. Int J Derm 2001 40:179-84
- [41] WHO expert committee report: Control of the leishmaniasis. 1991 Technical report series 793
- [42] Hashim, F. A., Ali, M. S., Satti, M., El-Hassan, A.M., Ghalib, H. W., El-Safi, S. and El-Hag, I. A. An outbreak of acute kala azar in a nomadic tribe in western Sudan: features of the disease in a previously non-immune population. Trans. R. Soc. Trop. Med. Hyg. 1995 88(4): 431-2

- [43] Hashim, F. A., Ahmed, A. E., El-Hassan, M., El-Mubarak, M. H., Yagi, H., Ibrahim, E. N. and Ali, M. S. Neurologic changes in visceral leishmaniasis. *Am. J. Trop. Med. Hyg.* 1995 52(2): 149-54
- [44] Ramesh, V. and Mukherjee, A. Post kala azar dermal leishmaniasis. *Int. J. Dermatol.* 1995 34(2): 85-91
- [45] Hashim, F. A., Khalil, E. A., Ismail, A. and El-Hassan, A. M. Apparently successful treatment of two cases of post kala azar dermal leishmaniasis with liposomal amphotericin B. *Trans. R. Soc. Trop. Med. Hyg.* 1995 89(4): 440
- [46] Gang, U.K., Agrawal, S. and Rani, S. Post-kala-azar dermal leishmaniasis in Nepal. *Int J Derm* 2001 40:179-84
- [47] Zijlstra, E. E., El-Hassan, A. M., Ismael, A., Ghalib, H. W. Endemic kala-azar in eastern Sudan: a longitudinal study on the incidence of clinical and subclinical infection and post kala azar dermal leishmaniasis. *Am. J. Trop. Med. Hyg.* 1994 51(6): 826-36
- [48] Salotra, P. and Singh, R. Challenges in the diagnosis of post kala-azar dermal leishmaniasis. *Indian J Med Res.* 2006 123(3): 295-310. Review
- [49] Tripathy, K, Rath, J et al. A Case of Post Kala-Azar Dermal Leishmaniasis in India. *Korean J Parasitol.*2010 48: 245-246. DOI: 10.3347/kjp.2010.48.3.245
- [50] Kostman, R., Barr, M., Bengtsson, E., Garnham, P. C. C. and Hult, G. Kala-azar transferred by exchange blood transfusion in two Swedish infants. In: *Proceedings of the 7th International Congress of Tropical Medicine and Malaria.* Geneva: Switzerland: World Health Organization; 1963 p. 384
- [51] Loke, Y. Transmission of parasites across the placenta. *Advances in Parasitology*, New York: Academic Press 1982 21: 155
- [52] Nuwayri-Salti, N. and Khansa, H. Direct non-infect vector transmission of *Leishmania* parasite in mice. *Int J Parasitol* 1985 15: 497
- [53] Napier, L. and Gupta, C. D. Indian Kala-azar in a new borne. *Indian Med Gaz* 1928 62: 199
- [54] Rosenthal, P. J., Chaisson, R. E., Hadley, W.K. and Leech, J. H. Rectal leishmaniasis in a patient with acquired immuno deficiency syndrome. *Am J Med* 1988 84: 307-9
- [55] Cascio, A., Colomba, C., Antinori, S., Orobello, M., Paterson, D. and Titone, L. Paediatric Visceral leishmaniasis in Western Sisily, Italy: A retrospective analysis of 111 cases. *Eur J Clin Microbiol Infect Dis* 2002 21: 277-82
- [56] Berhe, N., Hailu, A., Wolday, D., Negesse, Y., Cenini, P. and Frommel, D. Ethiopian visceral leishmaniasis patients co-infected with human immunodeficiency virus. *Trans. R. Soc. Trop. Med. Hyg.* 1995 89(2): 205-7
- [57] Belazzoug, S. Leishmaniasis in Mediterranean countries. *Vet Parasitol* 1992 44: 15-9
- [58] Aggarwal, P. and Prakash Wali, J. P. Profile of kala-azar in north India. *Asia Pacific J Public Health* 1991 5: 90-3
- [59] Pintado, V., Martin Rabadan, P., Rivera, M. L., Morino, S. and Bauza, E. Visceral leishmaniasis in human immunodeficiency virus infected and non-HIV infected patients- A comparative study. *Medicine* 2001 80: 54-73
- [60] The World Health Report, Geneva: World Health Organization. 2001
- [61] Desjeux, P., Meert, J.P., Piot, B., Alwar, J., Medrano, F.J. and Portus, M. *Leishmania/HIV* co-infection, South Western Europe 1990-98. Document WHO/LEISH/2000. 42 Geneva: World Health Organization

- [62] Rabello, A., Orsini, M. and Disch, J. *Leishmania*/ HIV coinfection in Brazil: an appraisal. *Ann Trop Med Parasitol* 2002 97: 17-28
- [63] Sinha, P. K., Pandey, K. and Bhattacharya, S. K. Diagnosis & management of *Leishmania*/HIV co-infection. *Indian J Med Res* 2005 121: 407-14
- [64] Montalban, C., Martinez Fernandez, R., Calleza, Z. L., Garcia- Diaz, Z. E., Rubio, R. and Dronda, F. Visceral leishmaniasis (Kala-azar) as an opportunistic infection in patients infected with human immunodeficiency virus in Spain. *Rev Infect Dis* 1989 11: 655-60
- [65] del Mar Sanz, M., Rubio, R., Casillas, A., Guijarro, C., Costa, J. R., Martinez, R. and de Dios Garcia, J. Visceral leishmaniasis in HIV infected patients. *AIDS* 1991 5: 1272-4
- [66] Evanas, T. G. Leishmaniasis. *Infect Dis Clin North Am* 1993 7: 527-46
- [67] Alvar, J., Canavate, C., Gutierrez-Solar, B., Jimen, E. Z. M., Laguna, F. and Lopez-Velez, R. *Leishmania* and human immunodeficiency virus co-infection: The first 10 years. *Clin Microbiol Rev* 1997 10: 298-319
- [68] De-Gorgolas, M. and Miles, M. A. Visceral leishmaniasis and AIDS. *Nature*. 1994 372(6508): 734
- [69] Montalban, C., Calleja, J. L., Erice, A., Laguna, F., Clotet, B. and Podzamczer, D. Visceral leishmaniasis in patients infected with human immunodeficiency virus- Co-operative group for the study of Leishmaniasis in AIDS. *J Infect* 1990 21: 261-70
- [70] Alvar, J., Gutierrez-Solar, B. and Molina, R. Prevalence of *Leishmania* infection among AIDS patients. *Lancet* 1992 339: 264-65
- [71] Miralles, P., Moreno, S., Perez-Tascon, M., Cosin, J., Diaz, M. D. and Bouza, E. Fever of uncertain origin in patients infected with the human immunodeficiency virus. *Clin Infect Dis* 1995 20: 872-5
- [72] Janoff, E.N. and Smith, P. D. Perspectives on gastro-intestinal infections in AIDS. *Gastrointest Clin North Am* 1988 17: 451-63
- [73] Malebranche, R., Arnoux, E., Guerin, J. M., Pierre, G. D., Laroche, S. E. and Pean-Guichard, C. Acquired immunodeficiency syndrome with severe gastrointestinal manifestations in Haiti. *Lancet* 1983 2: 873-8
- [74] Laguna, F., Garcia-Samaniego, J., Soriano, V., Valencia, E., Redondo, C. and Alonso, M. J. Gastro-intestinal leishmaniasis in human immunodeficiency virus infected patients: Report of 5 cases and review. *Clin Infect Dis* 1994 19: 48-53
- [75] Muigai, R., Gatei, D. and Shaunak, S. Jejunal function and pathology in visceral leishmaniasis. *Lancet* 1983 27: 476-9
- [76] Villanueva, J. L., Torre-Cisneros, J. and Jurado, R. *Leishmania* esophagitis in an AIDS patient: an unusual form of visceral leishmaniasis. *Am J Gastroenterol*. 1994 89: 273-5
- [77] Perrin, C., Taillan, B., Hofman, P., Mondain, V., Lefichoux, Y. and Michiels, J. F. Atypical cutaneous histological features of visceral leishmaniasis in acquired immunodeficiency syndrome. *Am. J Dermatopathol* 1995 17: 145-50
- [78] Romeu, J., Milla, F., Batlle, M., Sirera, G., Ferrendiz, C., Carreres, A., Condom, M. J. and Clotet, B. Visceral leishmaniasis involving lungs and a cutaneous Kaposi's sarcoma lesions. *AIDS* 1991 5: 1272
- [79] Lahdevirta, J., Maury, C. P., Teppo, A. M. and Repo, H. Elevated levels of circulating cachectin / TNF in patients with AIDS. *Am J Med* 1988 85: 289-91

- [80] Duarte, M. I. S., da Matta, V. L. R., Corbett, C. E. P, Laurenti, M. D, Chebabo, R. and Goto, H. Interstitial pneumonitis in human visceral leishmaniasis. *Trans R Soc Trop Med Hyg* 1989 83: 73-6
- [81] Clevenbergh, P., Okome, M. N. and Benoit, S. Acute renal failure as initial presentation of visceral leishmaniasis in an HIV 1 infected patient. *Scand J Infect Dis* 2002 100: 71-4
- [82] Pandey, K., Sinha, P. K., Ravidas, V. N. R., Kumar, N., Verma, N. and Lal, C. S. Nexus of infection with human immunodeficiency virus, pulmonary tuberculosis and visceral leishmaniasis: A case report from Bihar, India. *Am J Trop Med Hyg* 2005 72: 30-2
- [83] Berenguer, J., Moreno, S., Cercenado, E., Bernaldo de Quiros, J. C. and Garcia de la Fuente A, Visceral leishmaniasis in patients infected with human deficiency virus (HIV). *Ann Intern Med* 1989 111: 129-32
- [84] Greder, A., Malet, M. and Gautier, P. Pleurisy revealing leishmaniasis in acquired immunodeficiency syndrome. *Presse Med* 1989 18: 1390-1
- [85] Gonzalez-Anglada, M. I., Pena, J. M., Barbado, F. J., Gonzalez, J.J., Redondo, C. and Galera, C. Two cases of laryngeal leishmaniasis in patients infected with HIV. *Eur J Clin Microbiol Infect Dis* 1994 13: 509-11
- [86] Mondain-Miton, V., Toussaint-Gari, M., Hofman, P., Marty, P. Carles, M. and Desalvoldor, F. A typical leishmaniasis in a patient infected with human immunodeficiency virus. *Clin Infect Dis* 1995 21: 663-5
- [87] Mofredj, A., Guerin, M. J., Leibinger, F. and Masmoudi, R. Visceral leishmaniasis with pericarditis in an HIV infected patient. *Scand J. Infect Dis* 2002 34: 151-3
- [88] Vazquez-Pineiro, T., Fernandez-Alvarez, J. M., Gonzalo Lafuente, J. C., Cano, J., Gimeno, M. and Berenger, J. Visceral leishmaniasis: a lingual presentation in a patient with HIV infection. *Oral Surg Oral Med Oral Pathol Oral Radiol Endod* 1998 86: 179-82
- [89] Miralles, E. S., Nunez, M., Hilara, Y., Harto, A., Moreno, R. and Ledo, A. Mucocutaneous leishmaniasis and HIV. *Dermatology* 1994 189: 275-7
- [90] Manfredi, R., Mazzoni, A., Pileri, S., Marinacci, G., Nanetti, A., Poggi, S. and Chiodo, F. Simultaneous occurrence of visceral leishmaniasis and disseminated histoplasmosis in an Italian patient with HIV infection. *Infection*. 1994 22(3): 224-5
- [91] Mary, C., Lamouroux, D., Dunan, S. and Quilici, M. Western blot analysis of antibodies to *Leishmania infantum* antigens: potential of the 14-kD and 16-kD antigens for diagnosis and epidemiologic purposes. *Am J Trop Med Hyg* 1992 47: 764-71
- [92] Lopez, M., Inga, R., Cangalaya, M., Echevarria, J., Llanos- Cuentas, A. and Orrego, C. Diagnosis of *Leishmania* using the polymerase chain reaction: a simplified procedure for field work. *Am J Trop Med Hyg* 1993 49: 348-56
- [93] de Brujin, M. H., Labrada, L. A., Smyth, A. J., Santrich, C. and Barker, D.C. A comparative study of diagnosis by the polymerase chain reaction and by current clinical methods using biopsies from Colombian patients with suspected leishmaniasis. *Trop Med Parasitol* 1993 44: 201-7
- [94] Cruz, I., Canavate, C. and Rubio, J. M. A nested polymerase chain reaction (Ln-PCR) for diagnosing and monitoring *Leishmania infantum* infection in patients co-infected with human immunodeficiency virus. *Trans R Soc Trop Med Hyg* 2002 96(Suppl 1): S185-9


- [95] Fisa, R., Riera, C., Ribera, E., Gallego, M. and Portus, M. A nested polymerase chain reaction for diagnosis and follow up of human visceral leishmaniasis patients using blood samples. *Trans R Soc Trop Med Hyg* 2002 96 (Suppl 1): S191-4
- [96] Ritmeijer, K., Veeken, H, Melaku Y, Leal G, Amsalu R, Seaman J, Ethiopian visceral leishmaniasis: Generic and proprietary sodium stibogluconate are equivalent: HIV co-infected patients have a poor outcome. *Trans R Soc Trop Med Hyg* 2001 95: 668-72
- [97] Laguna, F., Lopez-Velez, R. and Pulido, F. Treatment of Visceral Leishmaniasis in HIV infected patients: a randomized trial comparing meglumine antimoniate with amphotericin B. Spanish HIV-*Leishmania* Study Group. *AIDS* 1999 13: 1063-9
- [98] Autran, B., Crxelain, G. and Li, T.S. Positive effects of combined antiretroviral therapy on CD4+ T-cell Homeostasis and function in advanced HIV disease. *Science*. 1997 277: 112-6
- [99] McBride, M., Linney, M., Calydon, E.J. and Weber, J. Visceral leishmaniasis following treatment with liposomal amphotericin B. *Clin Infect Dis* 1994 19: 362
- [100] Sundar, S., Jha, T. K., Thakur, C. P., Engel, J., Sindermann, H., Fischer, C., Junge, K., Bryceson, A. and Berman, J., Oral miltefosine for Indian visceral leishmaniasis. *New England Journal of medicine*. 2002 347(22): 1739-46
- [101] Jha, T. K., Sundar, S. and Thakur, C. P. Miltefosine as oral agent for the treatment of Indian visceral leishmaniasis. *N. Engl. J. Med.* 1999 341: 1795-800
- [102] Thakur, C.P., Sinha, P.K., Singh, R.K., Hassan, S.M. and Narain, S. Miltefosine in case of visceral leishmaniasis with HIV coinfection and rising incidence of this disease in India. *Trans R Soc Trop Med Hyg* 2000 94: 696-7
- [103] Matherson, S., Cabie, A., Parquin, F., Mayaud, C., Roux, P. and Antoine, M. Visceral leishmaniasis and HIV infection: unusual presentation with pleuropulmonary involvement, and effect of secondary prophylaxis. *AIDS* 1992 6: 238-40
- [104] Mannaerts, G.P. and Van Veldhoven, P.P. Metabolic pathways in mammalian peroxisomes; *Biochimie*. 1993 75: 147-58
- [105] Tolbert, N.E. Metabolic pathways in peroxisomes and glyoxysomes. *Annu Rev Biochem*, 1981 50: 133-57
- [106] Chang, K.P., Fong, D. and Bray, R.S. *Leishmaniasis*. New York: Elsevier, 1985
- [107] de Duve, Ch. The separation and characterization of subcellular particles. *Harvey Lect.* 1965 59: 49-87
- [108] Mahmoud, S.S., Michael, L.C., Jason, D.M., Roberts, L. J. and Mostafa, Z.B. Evidence against peroxisome proliferation – induced hepatic oxidative damage; *Biochemical Pharmacology*, 1997 53: 1369-74
- [109] Van-Den Bosch, H., Schutgens, R.B., Wanders, R.J. and Tager, J.M. Biochemistry of peroxisomes. *Ann Rev Biochem* 1992 61: 157-97
- [110] de Duve, C. Microbodies in the living cell. *Sci Am*. 1983 248(5): 74-84
- [111] Perdue, P.E. & Lazarow, P.B. Peroxisome biogenesis; *Annu Rev. Cell Dev. Biol.* 2001 17: 701-52
- [112] Opperdoes, F. R., Baudhuin, P., Coppens, I, De Roe C., Edwards, S. W., Weijers, P. J. and Misset, O. Purification, morphometric analysis, and characterization of the glycosomes (microbodies) of the protozoan hemoflagellate *Trypanosoma brucei*. *J Cell Biol.* 1984 98: 1178-84

- [113] Lazarow, P.B. and Fujiki, Y. Biogenesis of peroxisome. *Annu Rev. Cell Dev Biol* 1985 1: 459-530
- [114] Girzalsky, W., Rehling, P., Stein, K., Kipper, J., Blank, L., Kunau, W.H. and Erdmann, R. Involvement of Pex13p in Pex14p localization and peroxisomal targeting signal 2-dependent protein import into peroxisomes. *J Cell Biol.* 1999 144(6): 1151-62
- [115] Terlecky, S.R. and Fransen, M. How peroxisomes arise. *Traffic* 2000 1: 465-73.
- [116] Gould, S.J. and Valle, D. Peroxisome biogenesis disorders: genetics and cell biology. *Trends Genet.* 2000 16: 340-45
- [117] Lazarow, P.B. and de Duve, C. A fatty acyl-CoA oxidizing system in rat liver peroxisomes; enhancement by clofibrate, a hypolipidemic drug. *Proc Natl Acad Sci USA.* 1976 73: 2043-60
- [118] Demoz, A., Daniel, K., Lie, A.O. and Berge, R. K. Modulation of plasma and hepatic oxidative status and changes in plasma lipid profile by n-3 (EPA and DHA), n-6 (corn oil) and a 3-thia fatty acids in rats. *Biochimica et Biophysica Acta.* 1994 1199(3): 238-244
- [119] Henk, F., Tabak, B.I. and Distel, B. Peroxisomes: simple in function but complex in maintenance. *Trends in Cell Biology.* 1999 9(11): 447-453
- [120] Henk, F., Tabak, B.I. and Distel, B. Peroxisomes: simple in function but complex in maintenance. *Trends in Cell Biology.* 1999 9(11): 447-453
- [121] Masters, C.J. and Crane, D. I. On the role of the peroxisome in the ontogeny, ageing and degenerative disease. *Mech. Ageing Dev.* 1995 80: 69-83.
- [122] Singh, I. Mammalian Peroxisomes: metabolism of oxygen and reactive oxygen species. In: *Peroxisomes: Biology and Role in Toxicology and Disease*, ed. Reddy, J.K., Suga, T, Mannaerts, G.P., Lazarow, P.B., and Subramoni, S., eds. New York: Annals of the New York Academy of Sciences. 1996 804: 612-27.
- [123] Kondrup, J. and Lazarow, P.B. Flux of palmitate through the peroxisomal and mitochondrial beta-oxidation systems in isolated rat hepatocytes. *Biochim Biophys Acta.* 1985 835(1): 147-53
- [124] Baumgart, E., Vanhooren, J.C., Fransen, M., van Veldhoven, P.P. et al. Molecular characterization of the human peroxisomal branched-chain acyl-CoA oxidase: cDNA cloning, chromosomal assignment, tissue distribution, and evidence for the absence of the protein in Zellweger syndrome. *Proc Natl Acad Sci U S A* 1996 93(24): 13748-53
- [125] Raymond, G.V. Peroxisomal Disorders, *Current Opinions in pediatrics*, 1999 11: 572-76
- [126] Reddy, C., Janardan, K., Tetsuya Suga, and Guy P. Mannaerts, eds. *Peroxisomes: Biology and Role in Toxicology and Disease*, Annals of New York, Academy of Sciences. New York: New York Academy of Sciences. 1996 804
- [127] Schmitt, K., Molzer, B., Stockler, S., Tulzer, G. and Tulzer, W. Zellweger syndrome, neonatal adrenoleukodystrophy or infantile Refsum's disease in a case with generalized peroxisome defect. *Wien Klin Wochenschr.* 1993 105(11): 320-2
- [128] Weller, S., Gould, S.J. and Valle, D. Peroxisome biogenesis disorders. *Annu Rev Genomics Hum Genet.* 2003 4: 165-211
- [129] Schu, P.V., Takegawa, K., Fry, M.J., Stack, J.H., Waterfield, M.D. and Emr, S.D. Phosphatidylinositol 3-kinase encoded by yeast VPS34 gene essential for protein sorting. *Science.* 1993 260(5104): 88-91

- [130] Kiel, J.A., Rechinger, K.B., van der Klei, I.J., Salomons, F.A., Titorenko, V.I. and Veenhuis, M. The Hansenula polymorpha PDD1 gene product, essential for the selective degradation of peroxisomes, is a homologue of *Saccharomyces cerevisiae* Vps34p. *Yeast*. 1999 15(9): 741-54
- [131] Kim, J., Dalton, V.M., Eggerton, K.P., Scott, S.V. and Klionsky, D.J. Apg7p/Cvt2p is required for the cytoplasm-to-vacuole targeting, macroautophagy, and peroxisome degradation pathways. *Mol Biol Cell*. 1999 10(5): 1337-51
- [132] Tanida, I., Mizushima, N., Kiyooka, M., Ohsumi, M., Ueno, T., Ohsumi, Y. and Kominami, E. Apg7p/Cvt2p: A novel protein-activating enzyme essential for autophagy. *Mol Biol Cell*. 1999 10(5): 1367-79
- [133] Yuan, W., Stromhaug, P.E. and Dunn, W.A. Jr. Glucose-induced autophagy of peroxisomes in *Pichia pastoris* requires a unique E1-like protein. *Mol Biol Cell*. 1999 10(5): 1353-66
- [134] Singh, A.K., Tekwani, B.L., Guru, P.Y., Rastogi, A.K. and Pandey, V.C. Suppression of the hepatic microsomal cytochrome P-450 dependent mixed function oxidase activities in golden hamster during *Leishmania donovani* infection. *Pharmacol Res*. 1989 21(5): 507-12
- [135] Corbett, C. E. Histopathology of lymphoid organs in the experimental leishmaniasis. *Int J Exp Pathol*. 1992 73(4): 417-33
- [136] Leite, V.H., Croft. SL. Hepatic extracellular matrix in BALB/c mice infected with *Leishmania donovani*: *Int J Exp. Pathol*, 1996 77(4): 181-90
- [137] Goto, H. Immunological Parameters of visceral leishmaniasis of *Leishmania major*-infected golden hamsters; *Allergol Immunopathol (Madr)*. 1987 15(6): 349-53
- [138] Raychaudhury, B., Banerjee, S. and Datta, S.C. Peroxisomal function is altered during *Leishmania* infection, *Med. Sci. Monit* 2003 9: 125-129.
- [139] Vianna, V.L.P., Takiya, C.M. and de Brito-Gitirana, L. Histopathologic analysis of hamster hepatocytes submitted to experimental infection with *Leishmania donovani*, *Parasitol. Res*. 2002 88: 829-836
- [140] Titorenko, V.I. and Rachubinski, R.A. Dynamics of peroxisome assembly and function, *Trends Cell Biol*. 2001 1122-29
- [141] McCormack, J.G. and Denton, R.M. The role of mitochondrial Ca²⁺ transport and matrix Ca²⁺ in signal transduction in mammalian tissue, *Biochim. Biophys. Acta* 1990 1018: 287-291
- [142] Raychaudhury, B, Gupta, S and Datta. Peroxisome is a reservoir of intracellular calcium. *Biochim. Biophys. Acta* 2006 1760: 989-992
- [143] Fidaleo M. Peroxisomes and peroxisomal disorders: The main facts. *Experimental and Toxicologic Pathology*. 2010 62: 615-625
- [144] Wanders RJA, J.M. Tager et al Peroxisomal disorders in nerulogy. *J. Neurol. Sciences*. 1988 88: 1-39
- [145] Ghosh, A.K., Bhattacharya, F..K. and Ghosh, D..K. *Leishmania donovani*: amastigote inhibition and mode of action of berberine. *Exp. Parasitol* 198560, 404-13.
- [146] Jaffe, C.L., Grimaldi, G. and McMahon-Pratt, D.. In: Morel, C.M.(Ed.), *Genes and Antigens of Parasites: A Laboratory Manual*. Fundaaos Oswaldo Cruz, Rio de Janeiro. 1984 pp. 47.

- [147] Stauber, L.A., Franchino, E.M. and Grun, J.. An eight-day method of screening compounds against *Leishmania donovani* in the golden hamster. J. Protozool. 1958; 5, 269-73.
- [148] Datta, S.C., Ghosh, M. K. and Hajra A.K., Purification and properties of acyl/ alkyl dihydroxyacetonephosphate from guinea pig liver. J. Biol. Chem. 1990. 265, 8268-74.
- [149] Laemmli, U.K., Cleavage of structural proteins during the assembly of the head of bacteriophage T4. Nature 1970. 227, 680-85.
- [150] Towbin, H., Staehelin, T. and Gordon, J., Electrophoretic transfer of proteins from polyacrylamide gels to nitrocellulose sheets: procedure and some applications. Proc. Natl. Acad. Sci. USA 1979. 76, 4350-54.
- [151] Beauchamp, C., and Fridovich, I., Superoxide dismutase: improved assays and an assay applicable to acrylamide gels. Anal. Biochem 1971. 44, 276-87.
- [152] Leighton, F., Pool, B., Beaufy, H., Baudhuin, P., Coffey, J.W., Fouler, S. and de Duve C., The large-scale separation of peroxisomes, mitochondria and lysosomes from the livers of rats injected with Triton WR-1339. J. Cell Biol. 1968. 37, 482-513.
- [153] Markland, S. Markland, G.,. Involvement of superoxide anion radical in the autoxidation of pyrogallol and a convenient assay for superoxide dismutase. Eur. J. Biochem. 1974 47, 469-74.
- [154] Lowry, O. H., Rosebrough, N.J., Farr, A.L. and Randall, R. J.,. Protein estimation with the Folin-phenol reagent. J. Biol. Chem. 1951 193, 265-75.
- [155] Majumdar, S., Dey, S.N., Chaudhury, R. and Das, J., Intracellular development of cholera phage phi 149 under permissive and nonpermissive conditions: an electron microscopic study. Intervirology. 1988. 29, 27-38.
- [156] Mishra, B.N. and Mishra, M. K. Introductory Practical Biostatistics. Naya Prakash. 1983. p. 89.
- [157] Raychaudhury, B., Banerjee, S., Datta, S. C.,. Peroxisomal function is altered during *Leishmania* infection. Med. Sci. Monit 2003. 9, 125-29.
- [158] Wanders, R.J.A., Peroxisomes, lipid metabolism, and peroxisomal disorders. Mol. Genet. Metab. 2004. 83, 16-27.
- [159] Nguyen, S.D., Baes, M. and Veldhoven, P.P.V., Degradation of very long chain dicarboxylic polyunsaturated fatty acids in mouse hepatocytes, a peroxisomal process. Biochimica et Biophysica Acta. - Molecular and Cell Biology of Lipids 2008 1781: 400-5.
- [160] Van-Den Bosch, H., Schutgens, R.B., Wanders, R.J. and Tager, J.M., Biochemistry of peroxisomes. Ann Rev Biochem. 1992 61, 157-97
- [161] Lazarow, P.B., Moser, H.W.,. The metabolic basis of inherited diseases. vol II. New York: McGraw-Hill, 1995 2287-2324.
- [162] Goepfert, S. and Poirier, Y.,. β -Oxidation in fatty acid degradation and beyond. Current Opinion in Plant Biology, 2007 10, 245-51
- [163] Duran, E, Walker, D.J., Johnson, K. R.,. Developmental and tissue specific expression of 2-methyl branched α -chain enoyl Co-A reductase isoforms in the parasitic nematode. *Ascaris suum* Mol Biochem Parasitol. 1998 91, 307-18
- [164] Hamberg, M, Stereochemical aspects of fatty acid oxidation: hydroperoxide isomerases. Acta Chem Scand. 1996 50, 219-24.

- [165] Fricker, S.P., Mosi, R.M., Cameron, B.R., Baird, I., Zhu, Y., Anastassov, V., Cox, J., Doyle, P.S., Hansell, E., Lau, G., Langille, J., Olsen, M., Qin, L., Skerlj, R., Wong, R.S.Y., Santucci, Z. and McKerrow, J.H.,. Metal compounds for the treatment of parasitic diseases. *Journal of Inorganic Biochemistry* 2008. 102, 1839-45
- [166] Murray, H.W.,.Clinical and experimental advances in treatment of visceral leishmaniasis. *Antimicrob. Agents Chemother.* 2001 45, 2185-97.
- [167] Sinha,P.K., Ranjan, A., Singh, V.P., Das, V.N.R. , Pandey, K., Kumar, N. , Verma, N., Lal, C.S., Sur, D., Manna, B. and Bhattacharya,S.K.,. Visceral leishmaniasis (kala-azar) – the Bihar (India) perspective. *Journal of Infection.* 2006 53, 60-64
- [168] Werbozetz, K.,. Diamidines as antitrypanosomal, antileishmanial and antimalarial agents. *Curr Opin Investig Drugs.* 2006 7, 147-57.
- [169] Fricker, S.P., Mosi, R.M., Cameron, B.R., Baird, I., Zhu, Y., Anastassov, V., Cox, J., Doyle, P.S., Hansell, E., Lau, G., Langille, J., Olsen, M., Qin, L., Skerlj, R., Wong, R.S.Y., Santucci, Z. and McKerrow, J.H.,. Metal compounds for the treatment of parasitic diseases. *Journal of Inorganic Biochemistry.* 2008 102, 1839-45
- [170] Sundar, S, and Chatterjee, M. Visceral leishmaniasis - current therapeutic modalities. *Indian J Med Res.* 2006 123, 345-352.
- [171] Novikoff, A.B., and Novikoff, P.M.,.Microperoxisomes. *J Histochem Cytochem.* 1973 21, 963-66.
- [172] Wilcke, M, Hulthenby, K, Alexon S.H.E.,. Novel peroxisomal populations in subcellular fractions from rat liver. Implication for peroxisome structure and biogenesis. *J Biol Chem.* 1995 270, 6949-58
- [173] Baudhuin, P., Beaufy H, deDuve C.,. Combined biochemical and morphological study of particulate fraction from rat liver. Analysis of preparations enriched in lysosomes or in particles containing urate oxidase, D-amino acid oxidase, and catalase. *J Cell Biol.* 1965 26, 219-43.
- [174] Koepke, J.I., Wood, C.S., Terlecky, L.J., Walton, P.A. and Terlecky, S.R.,. Progeric effects of catalase inactivation in human cells. *Toxicology and Applied Pharmacology.* 2008 232, 99-108.
- [175] Schrader, M. and Fahimi, H.D.,. Peroxisomes and oxidative stress. *Biochim Biophys Acta* 2006 1763, 1755-66.
- [176] Herrero, E., Ros, J., Bellí, G. and Cabisco, E.,. Redox control and oxidative stress in yeast cells. *Biochimica et Biophysica Acta* 2008 1780, 1217-35
- [177] Fattman, C.L., Schaefer, L.M., and Oury, T.D.,. Extracellular superoxide dismutase in biology and medicine. *Free Radic. Biol. Med.* 2003 35: 236-56.
- [178] Dey, A. and Singh, S., Genetic heterogeneity among visceral and post kala azar dermal leishmaniasis strains from eastern India *Infection, Genetics and Evolution*, 2007. 7, 219-22
- [179] Zijlstra, E.E., Musa, A.M. and Khalil, A.M.,. Post kala-azar dermal leishmaniasis. *Lancet Infect Dis.* 2003 3, 87-98.
- [180] Gupta S, Raychaudhury B and Datta S.C Host peroxisomal properties are not restored to normal after treatment of visceral leishmaniasis with sodium antimony gluconate. *Exp. Parasitology* 2009 123 140-145.



Advances in the Study of Genetic Disorders

Edited by Dr. Kenji Ikehara

ISBN 978-953-307-305-7

Hard cover, 472 pages

Publisher InTech

Published online 21, November, 2011

Published in print edition November, 2011

The studies on genetic disorders have been rapidly advancing in recent years as to be able to understand the reasons why genetic disorders are caused. The first Section of this volume provides readers with background and several methodologies for understanding genetic disorders. Genetic defects, diagnoses and treatments of the respective unifactorial and multifactorial genetic disorders are reviewed in the second and third Sections. Certainly, it is quite difficult or almost impossible to cure a genetic disorder fundamentally at the present time. However, our knowledge of genetic functions has rapidly accumulated since the double-stranded structure of DNA was discovered by Watson and Crick in 1956. Therefore, nowadays it is possible to understand the reasons why genetic disorders are caused. It is probable that the knowledge of genetic disorders described in this book will lead to the discovery of an epoch of new medical treatment and relieve human beings from the genetic disorders of the future.

How to reference

In order to correctly reference this scholarly work, feel free to copy and paste the following:

Salil C. Datta, Shreedhara Gupta and Bikramjit Raychaudhury (2011). Repair of Impaired Host Peroxisomal Properties Cropped Up Due to Visceral Leishmaniasis May Lead to Overcome Peroxisome Related Genetic Disorder Which May Develop Later After Treatment, *Advances in the Study of Genetic Disorders*, Dr. Kenji Ikehara (Ed.), ISBN: 978-953-307-305-7, InTech, Available from: <http://www.intechopen.com/books/advances-in-the-study-of-genetic-disorders/repair-of-impaired-host-peroxisomal-properties-cropped-up-due-to-visceral-leishmaniasis-may-lead-to->

INTECH
open science | open minds

InTech Europe

University Campus STeP Ri
Slavka Krautzeka 83/A
51000 Rijeka, Croatia
Phone: +385 (51) 770 447
Fax: +385 (51) 686 166
www.intechopen.com

InTech China

Unit 405, Office Block, Hotel Equatorial Shanghai
No.65, Yan An Road (West), Shanghai, 200040, China
中国上海市延安西路65号上海国际贵都大饭店办公楼405单元
Phone: +86-21-62489820
Fax: +86-21-62489821

© 2011 The Author(s). Licensee IntechOpen. This is an open access article distributed under the terms of the [Creative Commons Attribution 3.0 License](#), which permits unrestricted use, distribution, and reproduction in any medium, provided the original work is properly cited.

IntechOpen

IntechOpen