

# We are IntechOpen, the world's leading publisher of Open Access books Built by scientists, for scientists

## 4,800

Open access books available

## 122,000

International authors and editors

## 135M

Downloads

Our authors are among the

## 154

Countries delivered to

## TOP 1%

most cited scientists

## 12.2%

Contributors from top 500 universities

**WEB OF SCIENCE™**Selection of our books indexed in the Book Citation Index  
in Web of Science™ Core Collection (BKCI)

Interested in publishing with us?  
Contact [book.department@intechopen.com](mailto:book.department@intechopen.com)

Numbers displayed above are based on latest data collected.

For more information visit [www.intechopen.com](http://www.intechopen.com)

## Lymphedema: Clinical Picture, Diagnosis and Management

Tanja Planinšek Ručigaj and Vesna Tlaker Žunter  
*Department of Dermatovenereology, University Clinical Centre Ljubljana  
Slovenia*

### 1. Introduction

Lymphedema is swelling due to excess accumulation of lymph in the tissues caused by inadequate lymph drainage (Mortimer, 2010). The protein-rich lymph accumulates in tissue when reabsorption is hindered or when the lymphatics are absent or blocked (Gaber, 2009). Lymphedema is most commonly seen on lower limbs (Figure 1), rarely on the upper limbs, and extremely rarely on the head or the trunk. The development of this process may take several years (Cohen et al, 2001).

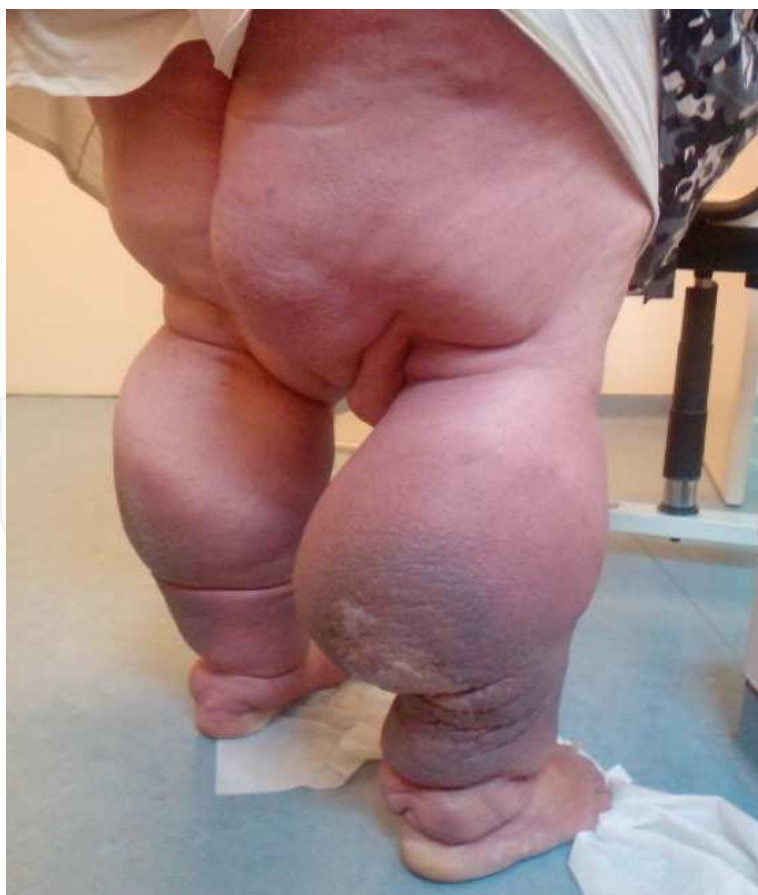

Fig. 1. Bilateral leg lymphedema.

The leading causes of lymphedema include cancer and therapy for malignant diseases, infections, chronic venous insufficiency, and congenital malformations (Planinšek Ručigaj et al, 2005).

## 2. Etiology and pathogenesis of lymphedema

Within the interstitial space – the space between tissue cells – fluid is always present. The amount of fluid depends on two factors: the amount introduced into the interstitial space, and the amount removed from it. Fluid enters the space from arterioles and venules; some returns to the venules, and the remainder is taken up by the lymphatics. In the normal physiologic state, entrance and exit are approximately equal, so that tissues retain their usual morphologic appearance and function. Edema (swelling) develops when the volume of interstitial fluid increases, either from increased inflow or decreased outflow, or both (Tretbar et al, 2008).

An imbalance between lymphatic flow and the capacity of lymphatic circulation (capillary filtration exceeding the capacity of lymphatic circulation) bring up to edema (Mortimer, 1998). The protein constituents of static lymph fluid may cause inflammation and subsequent tissue fibrosis. In patients with lymphedema, the overlying skin may develop cobblestoning, as well as a verrucous or mossy appearance (Philips, 2008).

Based on pathogenesis, one distinguishes two types of lymphedema: primary and secondary lymphedema (Gaber, 2009).

### 2.1 Primary lymphedema

Lymphedema arising from an intrinsic abnormality of the lymph-conducting pathways is referred to as primary lymphedema (Browse et al, 1985). The deficient lymphatics do not or can not propel the lymph in adequate amounts, and the fluid sequesters within the interstitial or lymphatic spaces (Tretbar et al, 2008). There is a simple classification by age of onset without reference to etiology or other clinical features into three types based on age at first appearance of disease: congenital lymphedema, which typically develops within two years of life, lymphedema praecox (present <35 years of age), and lymphedema tarda (first present >35 years of age). The problem can be unilateral or bilateral and may be familial or sporadic (Gaber 2009, Mortimer 2010, Moneta 2009). Primary lymphedema often occurs in the lower extremities, and affects women more often than men (Browse et al, 1985).

An increasing understanding of the genetic basis of primary lymphedema has further changed classification and to some extent made the praecox and tarda categories redundant. For example in lymphoedema–distichiasis syndrome (LDS), the onset of lower-limb oedema can range from puberty to 40 years old despite the same cause, namely a mutation in the *FOXC2* gene (Brice G et al, 2002). Conversely, LDS and Meige forms of primary lymphoedema can both present at puberty with similar lower limb lymphedema but have different genotypes and different mechanisms; LDS is associated with hyperplasia and valve reflux of collecting lymphatics whereas Meige's disease is associated with hypoplasia of collecting vessels. In the future, classification of lymphoedema is likely to be based on phenotype, unless the genotype is known (Mortimer 2010).

The development of lymphangiography in the 1950s resulted in a radiological classification: aplasia (no formed lymph pathways found), hypoplasia (lymphatics smaller or fewer than normal) and hyperplasia (lymphatics larger and more numerous). Aplasia, hypoplasia and

hyperplasia refer to abnormalities in the main (leg) conducting lymph vessels as opacified on lymphangiography, and not to the initial lymphatics, which are not imaged with this method. Further investigation revealed types of lymphoedema where few, if any, lymph conducting vessels could be identified in the foot, but vessels were found to be normal further up the limb (Browse 1996).

The causes of primary lymphedema are summarized in Table 1 (Mortimer 2010).

| Congenital onset |  | Postpubertal onset      |                             |
|------------------|--|-------------------------|-----------------------------|
| Familial         | Sporadic                                       | Familial                | Sporadic                    |
| Milroy's disease | Turner's syndrome                              | Distichiasis-lymphedema | Distal hypoplasia           |
|                  | Noonan's syndrome                              | Meige's disease         | Lymph reflux                |
|                  | Neurofibromatosis                              |                         | Ilioinguinal node sclerosis |
|                  | Proteus syndrome                               |                         | Yellow nail syndrome        |
|                  | Pure or mixed vascular lymphatic malformations |                         |                             |
|                  | Lymphangiomatosis                              |                         |                             |
|                  | Klippel-Trenaunay syndrome                     |                         |                             |
|                  | Mafucci's syndrome                             |                         |                             |
|                  | Amniotic bands                                 |                         |                             |

Table 1. Causes of primary lymphedema (Mortimer 2010)

## 2.2 Secondary lymphedema

Secondary lymphedema is swelling that follows some other incident or event, such as infection or injury (Tretbar 2008). The dysfunction of lymphatics in secondary lymphedema may be due to surgery, post-radiation fibrosis, infections, and primary or metastatic tumors, all causing lymphatic obstruction. Secondary lymphedema is much more frequent than primary (Planinšek Ručigaj T, 2010). The causes are summarized in Table 2 (Gaber 2009, Mortimer 2010).

In the Western world, surgery and radiation therapy for cancer (eg. breast and pelvic carcinoma, melanoma, head/neck cancer, Caposi sarcoma) are the leading cause of secondary lymphedema (Figures 2 and 3.) Lymphedema may appear as late as 30 years after the intervention. Due to increased cancer survival, the incidence of lymphedema is on the rise (Rockson 2001, Carpentier, 2002). Lymphatic tumors (e.g. lymphoma, sarcoma) may also cause lymphedema, however infrequently (Planinšek Ručigaj 2010).

Worldwide, venous insufficiency is a highly prevalent condition and is commonly accompanied by edema. It is assumed that venous edema is the sole consequence of increased capillary filtration from venous hypertension. As lymph drainage is the main buffer against edema, it is in fact the failure of local lymphatics to compensate for the

|              |  |
|--------------|--|
| Tumour       | Cancer surgery   |
|              | Radiotherapy   |
|              | Kaposi's sarcoma   |
|              | Infiltrative cancer  |
|              | Lymphoma   |
|              | Relapsed tumour  |
| Infection    | Filariasis   |
|              | Erysipelas, cellulitis, tuberculosis, lymphogranuloma inguinale, lice                        |
| Inflammation | Lymphatic occlusion: podoconiosis, pretibial myxedema, dermatitis (eg. hand eczema), rosacea |
|              | Granulomatous disease: orofacial granulomatosis, Crohn disease, sarcoidosis                  |
| Vascular     | Venous disease: postthrombotic syndrome, chronic venous insufficiency                        |
| Trauma       | Surgery: lymphadenectomy, vein harvesting  |
|              | Self-harm: tourniquet application, intravenous drug abuse, Secretan syndrome                 |
|              | Accident: degloving injury, burns  |
| Functional   | Static (prolonged standing), premenstrual, pregnancy   |
| Medications  | Oral contraceptives, psoralens, corticosteroids, antihypertensives, diuretics                |

Table 2. Causes of secondary lymphedema (Gaber 2009, Mortimer 2010)

increased lymph load from filtration that leads to edema. The small and precollecting lymphatics of the skin and subcutaneous tissues of the lower leg are damaged by prolonged venous hypertension. Lymphedema develops with chronic lipodermatosclerosis, with or without venous ulceration. Lymphedema associated with venous disease can give rise to the most gross swelling and skin changes owing to the combined effect of impaired lymph drainage and the increased lymph load (capillary filtration) (Mortimer 2010).

The leading cause of secondary lymphedema in the third world is filariasis, a worm (nematode) infection. Lymphatic filariasis is caused by *Wuchereria bancrofti*, *Brugia malayi*, or *Brugia timori*. The infection is transmitted by mosquitoes and other arthropods. The adult worms reside in lymphatic channels or lymph nodes, where they cause lymphatic dilatation and thickening of the vessel walls with subsequent fibrosis, lymphatic obstruction and lymphedema (elephantiasis tropica) (Rockson 2001, Neese 2000).



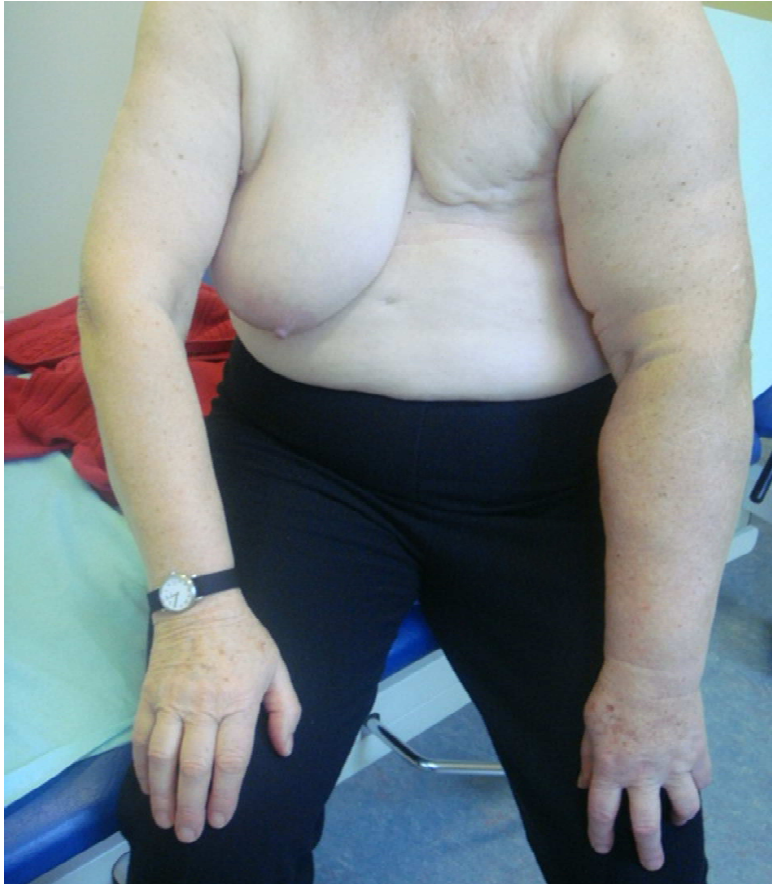

Fig. 2. Secondary lymphedema of the left arm after breast cancer surgery, including axillary lymphadenectomy.

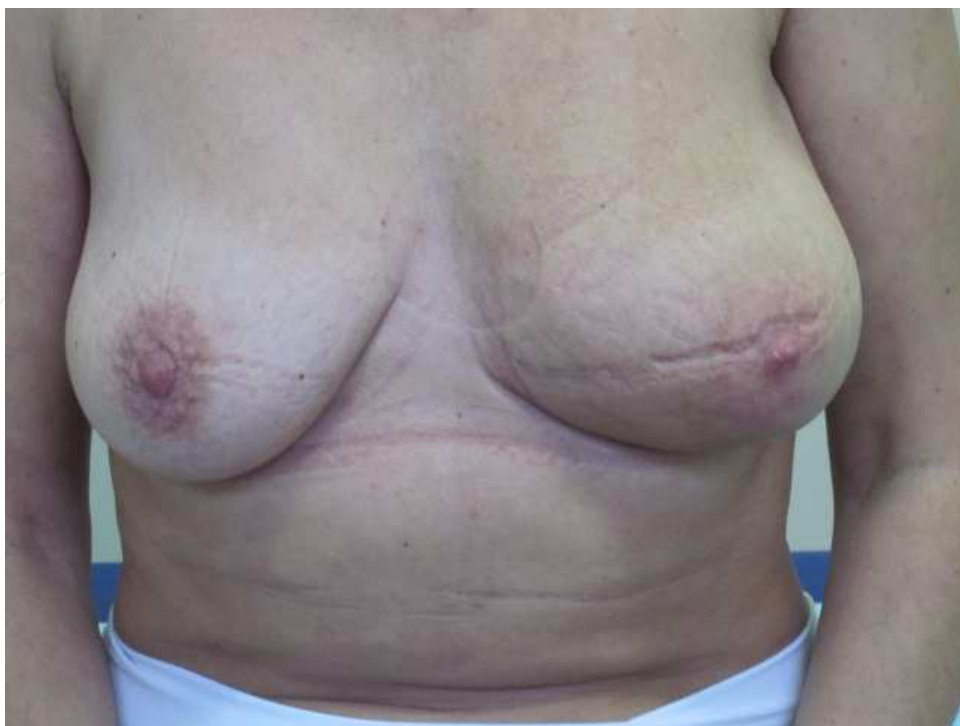

Fig. 3. Secondary lymphedema of the left breast after axillary lymphadenectomy.

### 3. Clinical picture and staging of lymphedema

Lymphedema differs from all other edemas (in which increased capillary filtration is the major factor) in that cells, proteins, lipids and debris accumulate in addition to water. This results in a 'solid' as well as a 'fluid' component to the swelling, so giving rise to the brawny nature of the edema which does not readily pit (Mortimer 1995). However, during the early stages, the swelling of lymphedema may be soft and pitting, therefore indistinguishable from other causes of oedema. Only during the later stages it develops the characteristics of 'true' lymphedema (Planinšek Ručigaj 2005).

The Stemmer-Kaposi sign is a helpful clinical sign in diagnosing lymphedema. It refers to the fact that, with lymphedema, the skin over the metatarsal-phalangeal joint of the second toe cannot be pinched up into a fold (Figure 4) (Stemmer 1976).

In lymphedema, skin creases become enhanced and hyperkeratosis develops. Dilatation of upper dermal lymphatics with consequent organization and fibrosis gives rise to papillomatosis. As dermal lymph stasis progresses, these skin changes become more marked and are referred to as elephantiasis. Occasionally, the tissue fibrosis and thickening may become so marked in the later stages of lymphedema that pitting is absent.

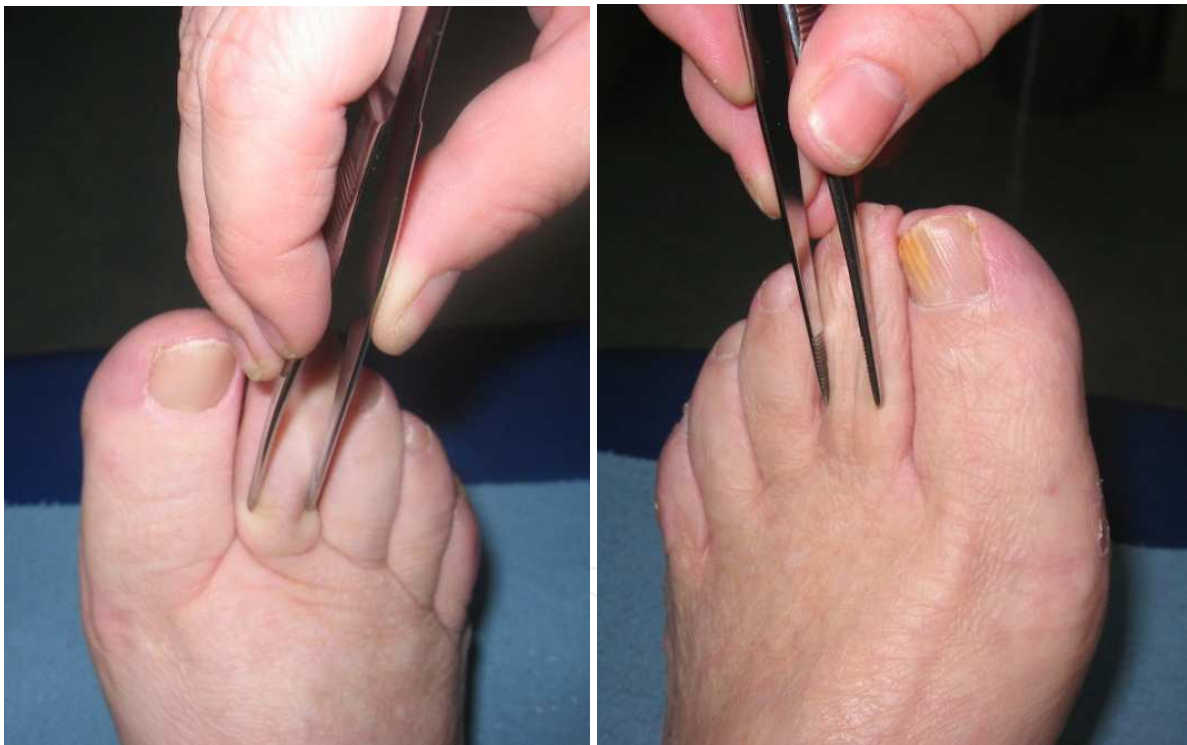

Fig. 4. The Stemmer-Kaposi sign. In lymphedema, the skin over metatarsal-phalangeal joint of the second toe can not be pinched into a fold (left, positive sign). In the absence of lymphedema (right), the skin can be readily pinched into a fold (negative sign).

Limb swelling leads to discomfort, limb heaviness, pain, reduced mobility and, on occasions, impaired function. The size and weight of affected limbs can result in secondary musculoskeletal complications such as back pain and joint problems. Thickening of the skin causes pseudoscleroderma and consequently impairs small-joint mobility. The difficulty in finding clothes or shoes to fit create social problems. Poor

footwear will further compound the swelling by discouraging a normal gait or enough exercise. Leakage of lymph through the skin (lymphorrhoea) may occur from engorged dermal lymphatics (Mortimer 2010).

### 3.1 Staging of lymphedema

Regardless of etiology, lymphedema is clinically staged by the extent of visible tissue degradation (Moneta 2009).

Latent or subclinical (stage 0) lymphedema may persist for months to years without any clinical evidence of lymphatic disturbance. Trigger events, e.g. insect sting, physical exertion, injuries or surgery, inflammation or warming of the limb may cause some minor foot edema or even severe limb edema, which is either reversible or may, with additional lymphatic overload, proceed to the following stage. In stage I, the edema is reversible, soft, disappearing spontaneously overnight or, with compression therapy, during the day. The skin is smooth, with small pits. Stage I may persist for several years. However, if left untreated, it sooner or later proceeds to the chronic stage II.

During the stage II, edema persists despite limb elevation. In the early stage, edema is still pitting, later the edema is non-pitting, elastic. The skin feels harder, fibrotic. This is the phase can not be reversed spontaneously without therapy.

During the stage III, which is also called elephantiasis, the edema is enormous. The skin shows trophic changes (fibrosis, hyperkeratoses, papillomatosis, hyperpigmentations, lymphoreas, ulcerations) and is prone to bacterial and fungal infections. The condition may only partly improve with appropriate therapy. (International Society of Lymphology 2003, Cohen 2001, Rockson 2001).

Lymphedema may be further classified by the volume of edema (minimal, moderate, or severe); speed of progression (benign, malignant type); and localization (distal, proximal type).

### 3.2 Complications of lymphedema

Chronic lymphedema is often complicated by recurrent lymphangitis/cellulitis and in the long-standing disease, numerous neoplastic complications have been described (Szuba & Rockson, 1998).

The accumulated fluid and proteins serve as a perfect culture medium for bacterial growth. Impaired lymphatic drainage impedes the local immune response, which, in turn, promotes bacterial and fungal invasion (Mallon & Ryan, 1994). The infection further impairs lymphatic drainage and the aggravation of the edema usually persists after the infection resolves. With recurrent infections, there is progressive damage of the lymphatic capillaries (Bollinger 1993). The clinical picture may vary from acute attacks of a rapidly progressive infection (high fever, chills and general malaise, with localized edema, erythema and characteristic changes of *peau d'orange*) to a subclinical course with, at best, subtle skin changes and normal body temperature. Recurrent attacks of cellulitis damage existing cutaneous lymphatics, worsen skin changes and further aggravate existing edema. Acute attacks of cellulitis usually resolve quickly after antibiotic therapy but tend to reoccur, becoming more resistant to antibiotic therapy when they do. Prophylaxis against cellulitis includes meticulous skin care, avoidance of minor trauma and the prophylactic use of antibiotics (Olszewski & Jamal, 1996, VanScoy & Wilkowske 1992).



In rare cases, chronic lymphedema may be complicated by the development of malignant tumors within the involved limb. Malignant tumors of a lymphedematous extremity can evolve from lymphedema of any etiology: postsurgical, traumatic, filarial and primary, but the phenomenon is most often observed in postmastectomy edema of the arm, with a described frequency of 0.45% (Szuba & Rockson 1998). The best-known associated malignancy is lymphangiosarcoma, however, other tumours have been recorded and include basal cell carcinoma, lymphoma, melanoma, malignant fibrous histiocytoma and Kaposi's sarcoma (Mortimer 2010).

#### 4. Diagnosis of lymphedema

Lymphedema can be surprisingly difficult to diagnose, especially in its early stages. Without a proper diagnosis, therapy is often delayed, allowing secondary fibrosis and lipid deposition to take place. Early treatment often results in rapid clinical improvement and prevents progression to the chronic phase of the disease (Szuba et al 2003).

The diagnosis of lymphedema requires careful history and clinical assessment, and exclusion of other causes of oedema.

History should include:

- Duration (acute vs. chronic) and previous therapy of edema;
- Pain, fatigue, paresthesias, mobility disturbances of the affected limb;
- Trigger events,
- Concurrent systemic signs/symptoms;
- Personal history of tumours, tumour therapy, postoperative complications;
- Personal history of injuries, surgery, infections, chronic venous insufficiency, deep venous thrombosis;
- Personal history of malabsorption syndrome, thyroid disease, cardiovascular disease, arterial hypertension, rheumatoid arthritis, transient obesity and lipedema, cerebrovascular disease, peripheral arterial disease, diabetes;
- Past and current medications, allergies;
- Occupation, hobbies;
- Family history.

Clinical assessment should include:

- Appearance of the skin (dry, flaky skin, fibrosis, papillomatosis, hyperkeratosis, hyperpigmentation, lymphorrhea, ulceration, warmth, erythema, pain of the affected area);
- Localization of edema;
- Assessment of the oedema (soft/hard or elastic/nonelastic);
- Comparison of limb diameters at several points (at the ankle, 10 cm above the upper and 10 cm below the lower margin of the patella);
- Stemmer-Kaposi sign - a diagnostic test that involves pinching of the skin on the upper surface of the second toe. In a negative result, it is possible to grasp a thin fold of tissue. In a positive result, which is characteristic of lymphedema, a plateau or a small pit is formed on the upper surface of the second toe when the tissue is pinched;
- Lymph node palpation;
- Mobility of the edematous limb;

- Presence of peripheral pulses, varicose veins;
- Inspection of feet and interdigital spaces, ingrowing nails,
- Systemic signs/symptoms (eg. fever, dyspnea etc.)

#### 4.1 Diagnostic tests in lymphedema

In many cases of advanced sustained disease, a typical history and characteristic clinical presentation establish the diagnosis of lymphedema with near certainty. Nevertheless, additional tests are sometimes necessary to confirm the presence of impaired lymphatic flow and/or the typical pattern of abnormal fluid distribution within the tissues. The diagnosis is more difficult to ascertain in the early stages, particularly when edema is mild or intermittent (Szuba & Rockson 1998).

Lymphoscintigraphy is the golden standard of imaging in diagnosing lymphedema. It offers an objective and reliable approach to diagnose and characterize the severity of lymphedema (Szuba et al 2003). Other available tests include indirect and direct lymphography, lymphatic capillaroscopy, magnetic resonance imaging (MRI), axial tomography, and ultrasonography (Szuba & Rockson 1998). Magnetic resonance lymphangiography is a new, and also promising, imaging modality of the lymphatic system (Peller et al. 2009).

Lymphoscintigraphy, broadly described as an assessment of the lymphatic clearance of injected radioactive particles, was initially developed in the 1950s (Moneta 2009). Particles smaller than a few nanometers usually leak into blood capillaries, whereas larger particles (up to about 100 nm) can enter the lymphatic capillaries and be transported to lymph nodes (Moghimi & Bonnemain 1999). The optimal colloidal size for lymphoscintigraphy is believed to be approximately 50–70 nm (Strand & Bergqvist 1989). Technetium ( $^{99}\text{Tc}^{\text{m}}$ ) labelled tracers such as sulphur colloid, microaggregated albumin and antimony sulphide are the most commonly used agents. In this minimally invasive procedure, intradermal or subcutaneous injection of the chosen radiolabeled tracer is performed, followed by subsequent gamma camera monitoring. Subfascial injection of the radiotracer may also be performed to analyse deep lymphatic system. The protocol for lymphoscintigraphy is not standardized and differs among diagnostic centers. Differences include the choice of radiotracer, the type and site of injection, the use of dynamic and static acquisition, and the acquisition times themselves. (Szuba 2003). A normal lymphoscintigram of the lower extremities is shown in Fig. 5, whereas Fig. 6 features a lymphoscintigraphic picture of lymphedema.

In extremity lymphedema assessment, a small volume of tracer (approximately 0.2 ml) is injected subcutaneously into the first to third web spaces on each hand or foot. Both limbs are examined, even if one appears normal, to detect sub-clinical abnormalities, provide internal comparison and monitor injection and camera technique. Images are acquired using a high-resolution, parallel hole, collimator. The arrival of tracer at the knees and groin (or elbows and axillae) is timed. A transmission scan using a flood source may be useful for anatomical localization. Quantitative parameters derived from tracer clearance data can be used to detect incipient lymphedema. After 30 min, if no groin (or axillary) activity is demonstrated, the patient is encouraged to mobilize/stress their limbs briefly. Lower extremity stress manoeuvres include walking, limb massage or bicycle exercise. For upper limb stressing, repetitive squeezing of a rubber ball, use of a hand-grip or massage can be used. They are then re-imaged to see if the proximal lymphatic system has been demonstrated. If there is still no activity, patients are encouraged to mobilize for several hours and delayed imaging is performed after 3–4 h (Scarsbrook et al 2007).

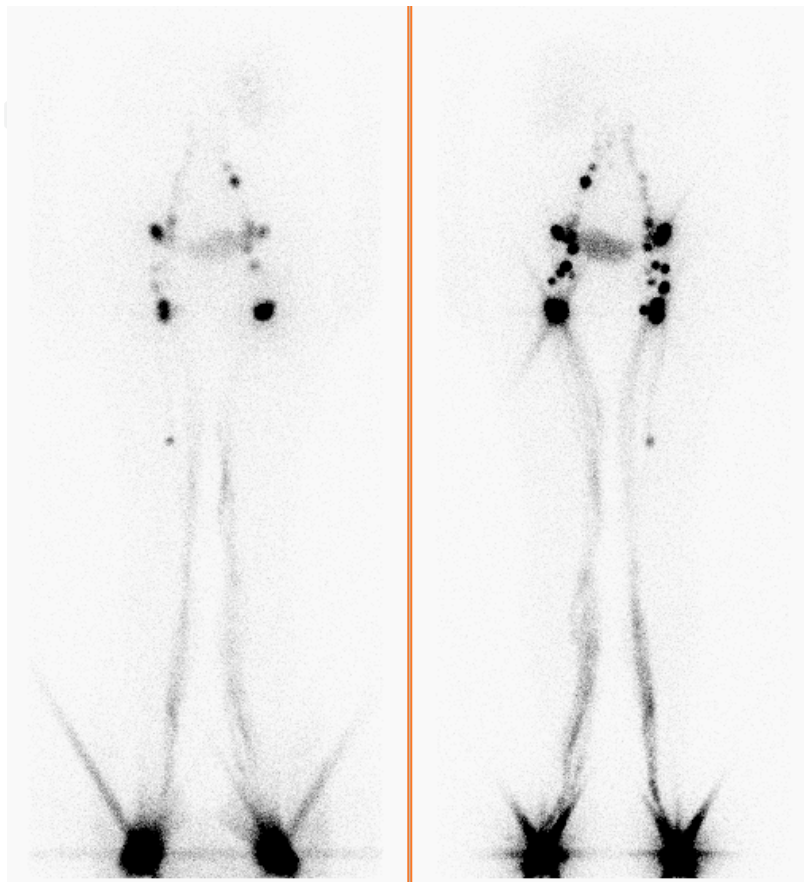


Fig. 5. Radioisotopic lymphography of the lower extremities in a patient with normally developed lymphatic system and normal lymphatic circulation (left, PA projection, right, AP projection). The radioindicator application site is seen as a large star-shaped activity in the lower part of the picture. Activity within the lymphatic vessels of the lower extremities can be observed, from the application site of the radioindicator on the dorsa of the feet, to the inguinal region, including several inguinal and abdominal lymph nodes. The lymphatic system of both extremities is virtually symmetrical. Image and interpretation courtesy of Marko Grmek.

## 5. Therapy of lymphedema

For decades, lymphedema has been thought by many clinicians to be non-curable and also largely untreatable. There now exist data supporting many types of successful treatment interventions, including medical and physical therapy (Gamble et al 2009). Surgery is not a

preferred treatment modality, but may be useful in selected cases. However, at the moment, there is no consensus on the therapy of lymphedema. Therapy should be tailored individually to the patient's clinical situation, history, and any coexisting illnesses, e.g. cancer. The aims of therapy are to reduce edema, to prevent its further accumulation, and to prevent any complications (e.g. infections). Patient compliance is of crucial importance, making continuous patient education and encouragement essential parts of management. (Planinšek Ručigaj et al 2010) Therefore, it is central to the management of lymphedema that patients get to understand their condition and know what they can do for themselves. Only then can a high level of motivation and compliance with treatment be generated.

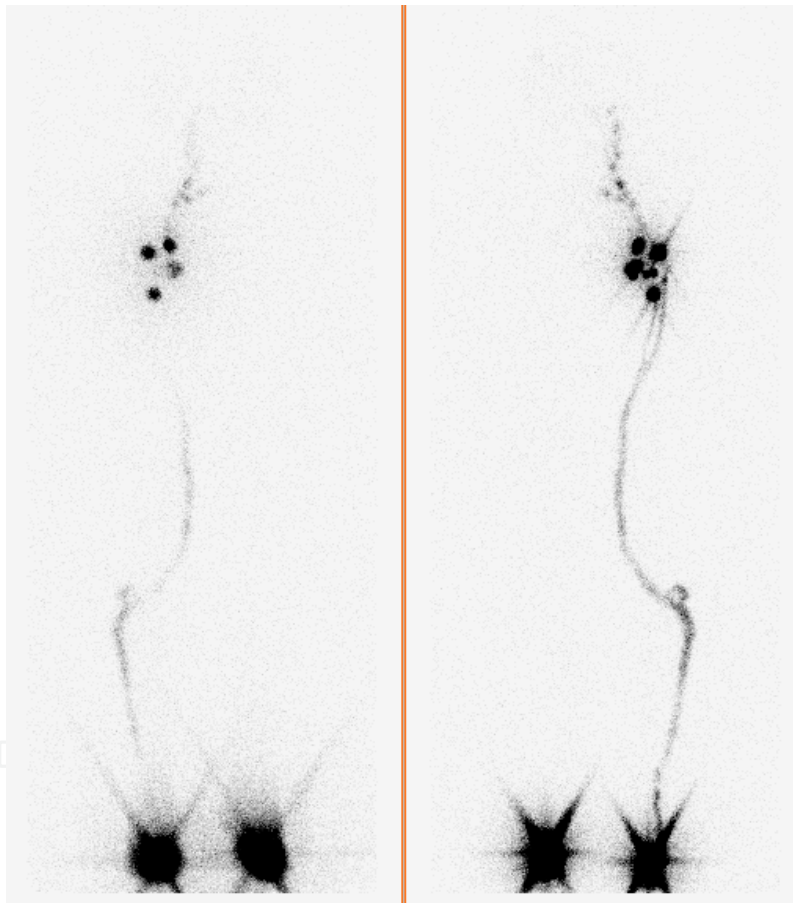


Fig. 6. Radioisotopic lymphography in a patient with absent lymphatic circulation in the right lower extremity (left, PA projection, right, AP projection). A star-shaped activity at the radioisotope application site is seen on both feet, and the activity in lymphatic vessels and nodes on the left side. There is no activity in the lymphatic vessels or lymph nodes of the right lower extremity. Image and interpretation courtesy of Marko Grmek.

### 5.1 Lymphedema risk factor management and risk reduction measures

Management of lymphedema should always include management of lymphedema risk factors and risk reduction measures (EWMA 2005, Planinšek Ručigaj 2005, Gamble et al 2009).

Other (accompanying) causes of edema must continue to be in the forefront of the clinician's thoughts in order not to neglect potentially dangerous and reversible causes. Deep venous thrombosis, recurrent malignancy, and active infection must be considered and ruled out as potential causes prior to initial treatment, and periodically thereafter. Cardiopulmonary, renal, or hepatic dysfunction must also be considered (Gamble et al 2009).

Meticulous skin care is of utmost importance to avoid scaling and cracking, and minimizing the risk for secondary bacterial or fungal infection. The skin should be daily washed with soap and water, and treated with an emollient cream to keep the protective skin barrier. An individually tailored exercise regimen should be recommended. Patients after cancer surgery should be monitored for the development of lymphedema, and treated as soon as possible (Planinšek Ručigaj et al 2010).

The patients with lymphedema should avoid injury to the affected extremity, including injections and insect stings, and temperature extremes, whether hot or cold, which can create vascular challenge and increase lymphatic load. Tight constriction and excessive overuse should also be avoided (Gamble et al 2009).

Increased body mass index (BMI) is a statistically significant predisposing factor for patients at risk for lymphedema as well (Soran et al 2010, Kizer et al 2011). Thus, a diet which maintains weight, or even promotes weight reduction, is encouraged to minimize development of edema (EWMA 2005, Gamble et al 2009).

### 5.2 Compression and physical therapy of lymphedema

The key treatment programme for lymphedema, known as decongestive lymphatic therapy, involves a combination of skin care, manual lymphatic drainage, inelastic multi-layer compression bandaging and exercise. Although this programme of care is well established, there is little understanding of how the different treatment components work or how to optimise the effects. Much of the evidence on how compression works is based on research into venous disease, which has been extrapolated to lymphedema (EWMA 2005).

Several studies have shown an impressive reduction in swelling as a result of compression (Badger et al 2004, McNeely 2004) but few have tried to elucidate the mechanism of action for this improvement. The following mechanisms may explain how compression reduces volume in a lymphedematous limb:

- reduction in capillary filtration
- shift of fluid into non-compressed parts of the body
- increase in lymphatic reabsorption and stimulation of lymphatic transport
- improvement in the venous pump in patients with veno-lymphatic dysfunction
- breakdown of fibrosclerotic tissue (EWMA 2005).

Compression therapy for lymphedema is based mainly on the use of elastic, short-stretch bandages, which has been clinically endorsed by only one randomised controlled trial that showed a consistently greater volume reduction in lymphedematous arms with short-



stretch multi-layer bandages compared to hosiery (Badger 2000). The summary of therapeutic recommendations for lymphedema by stages is shown in Table 3.

|           |   |
|-----------|---|
| Stage I   | 1. Evacuation of edema: long-stretch bandages/adhesive or nonadhesive short-stretch bandages and/or manual lymphatic drainage<br>2. Maintenance: medical compression stockings class II |
| Stage II  | 1. Evacuation of edema: adhesive or nonadhesive short-stretch bandages and/or manual lymphatic drainage<br>2. Maintenance: medical compression stockings class III/IV                   |
| Stage III | 1. Evacuation of edema: adhesive or nonadhesive short-stretch bandages and/or manual lymphatic drainage<br>2. Maintenance: medical compression stockings class III/IV                   |

Table 3. Recommended therapeutic interventions in lymphedema by stages (EWMA 2005).

## 6. Conclusion

Lymphedema is a chronic, progressive swelling of a part of the body, usually a limb. It may appear secondary to other diseases or as an isolated process. Lymphedema is most commonly seen on lower limbs, rarely on the upper limbs, and extremely rarely on the head or the trunk.

Ethiopathogenetically, lymphedema is classified into primary and secondary forms. Primary lymphedema may be hereditary or sporadic. Edema builds up due to lymphovascular or lymphonodular anomalies. In secondary lymphedema, which is much more common than the primary forms, the dysfunction of lymphatics is secondary due to other causes, such as infections, surgery, post-radiation fibrosis, and primary or metastatic tumors, all causing lymphatic obstruction. The leading cause of secondary lymphedema in the third world is filariasis, a worm (nematode) infection. Surgery and radiation therapy for cancer are the leading cause of secondary lymphedema in the Western world.

In some cases of lymphedema, particularly during the early stages, diagnostic tests may be necessary to confirm the lymphatic disturbance or point to the differential diagnosis. Lymphoscintigraphy (isotope lymphography) is the golden standard of imaging in diagnosing lymphedema. Lymphoscintigraphy involves the interstitial (dermis or subcutis) injection of a radio-labelled protein or colloid. Radioactivity, measured using a wide field-of-view gamma-camera, is determined over the injection site depot and at regions of interest over vessels or nodes. Measurement of transit times and time activity curves permit quantitative analysis of lymph drainage. Measurement of tracer uptake within axillary or inguinofemoral lymph nodes at a specified time following a standardized exercise routine will discriminate lymphedema from edema of non-lymphatic origin.

At the moment, there is no consensus on the therapy of lymphedema. Therapy should be tailored individually to the patient's clinical situation, history, and any coexisting illnesses, e.g. cancer. The aims of therapy are to reduce edema, to prevent its further accumulation, and to prevent any complications (e.g. infections). Patient compliance is of crucial importance, making continuous patient education and encouragement essential parts of

management. Edema should be reduced as early as possible, using compression therapy and/by manual lymph drainage. During improvement, compression stockings are required to maintain the improved condition.

## 7. Acknowledgment

The authors thank to Marko Grmek, MD, PhD, Department of Nuclear Medicine, University Medical Center Ljubljana, for kindly providing the images and interpretation of normal and abnormal lymphoscintigraphy of the lower extremities (Figures 5 and 6).

## 8. References

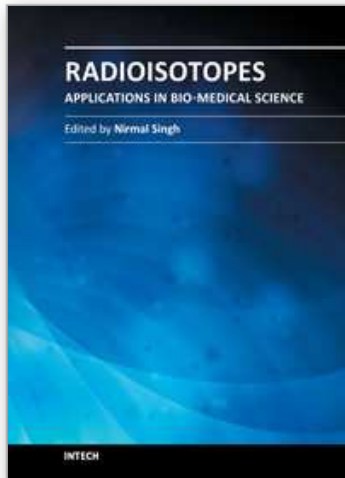
- Badger CM, Peacock JL, Mortimer PS. A randomized, controlled, parallelgroup clinical trial comparing multilayer bandaging followed by hosiery versus hosiery alone in the treatment of patients with lymphedema of the limb. *Cancer* 2000; 88(12): 2832-37
- Badger C, Preston N, Seers K, Mortimer P. Physical therapies for reducing and controlling lymphoedema of the limbs. *Cochrane Database Syst Rev* 2004; 4: CD003141
- Bollinger A. Microlymphatics of human skin. *Int J Microcirc Clin Exp* 1993; 12(1): 1-15
- Brice G, Mansour S, Bell R *et al.* Analysis of the phenotypic abnormalities in lymphoedema distichiasis syndrome in 74 patients with FOXC-2 mutations or linkage to 16q.24. *J Med Genet* 2002; (39) : 478-83
- Browse NL, Stewart G. Lymphoedema: pathophysiology and classification. *J Cardiovasc Surg* 1985; (6) : 91-106
- Browse NL. The diagnosis and management of primary lymphedema. *J Vasc Surg* 1996; (3): 181-4
- Carpentier PH. Physiopathology of lymphedema. *Rev Med Interne* 2002; 23 (3): 371-374
- Cohen SR *et al.* Lymphedema - Strategies for Management. *Cancer* 2001; 92 (4):980-987
- European Wound Management Association (EWMA). Focus Document: *Lymphoedema bandaging in practice*. London: MEP Ltd, 2005. Available from: [http://ewma.org/fileadmin/user\\_upload/EWMA/pdf/Position\\_Documents/2005\\_Lymphoedema/English\\_focus\\_doc\\_05.pdf](http://ewma.org/fileadmin/user_upload/EWMA/pdf/Position_Documents/2005_Lymphoedema/English_focus_doc_05.pdf)
- Gaber Y. Diseases of Lymphatics. In: Burgdorf WHC, Plewig G, Wolff HH, Landthaler M, eds. *Braun-Falco's Dermatology*. Heidelberg: Springer, 2009: 930-5
- Gamble GL, Cheville A, Strick D. Lymphedema: medical and physical therapy. . In: Gloviczki P, ed. *Handbook of venous disorders*. Guidelines of the American Venous Forum. London: Edward Arnold, 2009: 649-57
- International Society of Lymphology. The diagnosis and Treatment of Peripheral Lymphedema. *Lymphology* 2003; 36: 84-91
- Kizer NT, Thaker PH, Gao F, Zigelboim I, Powell MA, Rader JS, Mutch DG, Grigsby PW. The effects of body mass index on complications and survival outcomes in patients with cervical carcinoma undergoing curative chemoradiation therapy. *Cancer* 2011 Mar 1;117(5) :948-56
- Mallon EC, Ryan TJ. Lymphedema and wound healing. *Clin Dermatol* 1994; 12(1): 89-93

- McNeely ML, Magee DJ, Lees AW, et al. The addition of manual lymph drainage to compression therapy for breast cancer related lymphoedema: a randomized controlled trial. *Breast Cancer Res Treat* 2004; 86(2): 95-106.
- Moghim SM, Bonnemain B. Subcutaneous and intravenous delivery of diagnostic agents to the lymphatic system: applications in lymphoscintigraphy and indirect lymphography. *Adv Drug Deliv Rev* 1999;37:295-312
- Moneta G, ed. Lymphedema. In: Gloviczki P, ed. *Handbook of venous disorders. Guidelines of the American Venous Forum*. London: Edward Arnold, 2009: 629-634
- Mortimer PS. Pathophysiology of Lymphoedema. *Lymphology* 1998; 31: 3-6
- Mortimer PS. Managing lymphoedema. *Clin Exp Dermatol* 1995; (20): 98-106
- Mortimer PS. Disorders of Lymphatic vessels. In: Burns T, Breathnach S, Cox N, Griffiths C, editors. *Rook's Textbook of Dermatology*. Oxford: Wiley-Blackwell; 2010. p. 48.1-25
- Neese PY. Management of Lymphedema. *Lippincotts Prim Care Pract* 2000; 4(4): 390-399
- Olszewski W, Jamal S. The role of antibiotics in control of progression of lymphedema. In: Network NL, ed. *The Second National Lymphedema Network Conference*. Burlingame, California, 1996
- Peller PJ, Bender CE, Gloviczki P. Lymphoscintigraphy and lymphangiography. In: Gloviczki P, ed. *Handbook of venous disorders. Guidelines of the American Venous Forum*. London: Edward Arnold, 2009: 635-48
- Philips T. Ulcers. In: Bologna JL, Jorizzo LJ, Rapini RP, eds. *Dermatology*. St. Louis: Mosby/Elsevier, 2008: 1601-2
- Planinšek Ručigaj T, Košiček M, Kozak M, Grmek M. Obravnava bolnikov z limfedemom. *Slikovne metode v odkrivanju in zdravljenju žilnih bolezni*. Združenje za žilne bolezni Slovenskega zdravniškega društva. Ljubljana 2005: 168-83
- Planinšek Ručigaj T, Tlaker Žunter V, Miljković J. Compression therapy for lymphedema: our experience. *Acta Med Croatica* 2010 Jul;64(3):167-73
- Rockson SG; Lymphedema. *Am J Med*. 2001; 110: 288-29
- Scarsbrook AF, Ganeshan A, Bradley KM. Pearls and pitfalls of radionuclide imaging of the lymphatic system. Part 2: evaluation of extremity lymphoedema. *Br J Radiol* 2007 Mar; 80(951): 219-26
- Soran A, Wu WC, Dirican A, Johnson R, Andacoglu O, Wilson J. Estimating the Probability of Lymphedema After Breast Cancer Surgery. *Am J Clin Oncol*. 2010 Nov 30
- Stemmer R. Ein klinisches Zeichen zur Früh- und Differentialdiagnose des Lymphödems. *Vasa* 1976; (5) : 261-2
- Strand SE, Bergqvist L. Radiolabeled colloids and macromolecules in the lymphatic system. *Crit Rev Ther Drug Carrier Syst*. 1989;6:211-238
- Szuba A, Rockson G. Lymphedema: classification, diagnosis and therapy. *Vasc Med* 1998 3: 145
- Szuba A, Shin WS, Strauss HW, Rockson S. The Third Circulation: Radionuclide Lymphoscintigraphy in the Evaluation of Lymphedema. *J Nucl Med* 2003 Jan;44(1):43-57
- Tretbar LL, Morgan CL, Byung-Boong L, Simonian SJ, Blondeau B. *Lymphedema*. London: Springer, 2008: 12-31

Van Scoy RE, Wilkowske CJ. Prophylactic use of antimicrobial agents in adult patients.  
*Mayo Clin Proc* 1992; 67(3): 288–92

IntechOpen

IntechOpen



## **Radioisotopes - Applications in Bio-Medical Science**

Edited by Prof. Nirmal Singh

ISBN 978-953-307-748-2

Hard cover, 320 pages

**Publisher** InTech

**Published online** 21, November, 2011

**Published in print edition** November, 2011

The book *Radioisotopes - Applications in Bio-Medical Science* contains two sections: *Radioisotopes and Radiations in Bioscience* and *Radioisotopes and Radiology in Medical Science*. Section I includes chapters on medical radioisotope production, radio-labeled nano-particles, radioisotopes and nano-medicine, use of radiations in insects, drug research, medical radioisotopes and use of radioisotopes in interdisciplinary fields etc. In Section II, chapters related to production of metal PET (positron emission tomography) radioisotopes, 3-dimensional and CT (computed tomography) scan, SS nuclear medicine in imaging, cancer diagnose and treatments have been included. The subject matter will be highly useful to the medical and paramedical staff in hospitals, as well as researchers and scholars in the field of nuclear medicine medical physics and nuclear bio-chemistry etc.

### **How to reference**

In order to correctly reference this scholarly work, feel free to copy and paste the following:

Tanja Planinšek Ručigaj and Vesna Tlaker Žunter (2011). Lymphedema: Clinical Picture, Diagnosis and Management, *Radioisotopes - Applications in Bio-Medical Science*, Prof. Nirmal Singh (Ed.), ISBN: 978-953-307-748-2, InTech, Available from: <http://www.intechopen.com/books/radioisotopes-applications-in-bio-medical-science/lymphedema-clinical-picture-diagnosis-and-management>

**INTECH**  
open science | open minds

### **InTech Europe**

University Campus STeP Ri  
Slavka Krautzeka 83/A  
51000 Rijeka, Croatia  
Phone: +385 (51) 770 447  
Fax: +385 (51) 686 166  
[www.intechopen.com](http://www.intechopen.com)

### **InTech China**

Unit 405, Office Block, Hotel Equatorial Shanghai  
No.65, Yan An Road (West), Shanghai, 200040, China  
中国上海市延安西路65号上海国际贵都大饭店办公楼405单元  
Phone: +86-21-62489820  
Fax: +86-21-62489821



© 2011 The Author(s). Licensee IntechOpen. This is an open access article distributed under the terms of the [Creative Commons Attribution 3.0 License](#), which permits unrestricted use, distribution, and reproduction in any medium, provided the original work is properly cited.

IntechOpen

IntechOpen