

We are IntechOpen, the world's leading publisher of Open Access books Built by scientists, for scientists

4,800

Open access books available

122,000

International authors and editors

135M

Downloads

Our authors are among the

154

Countries delivered to

TOP 1%

most cited scientists

12.2%

Contributors from top 500 universities



WEB OF SCIENCE™

Selection of our books indexed in the Book Citation Index
in Web of Science™ Core Collection (BKCI)

Interested in publishing with us?
Contact book.department@intechopen.com

Numbers displayed above are based on latest data collected.
For more information visit www.intechopen.com



Ophthalmological Manifestations in Acute Lymphoblastic Leukemia

Javier Mateo¹, Francisco J. Ascaso¹, Esther Núñez¹,
Carlos Peiro¹, Gonzalo González² and José A. Cristóbal¹

¹Department of Ophthalmology,

²Department of Pediatrics, "Lozano Blesa" University Clinic Hospital, Zaragoza
Spain

1. Introduction

The aim of the present chapter is to review the different ophthalmological signs and symptoms that can be observed in acute lymphoblastic leukemia and the importance of the examination of these patients by an ophthalmologist whenever an ocular affection is suspected.

Acute lymphoblastic leukemia is a malignant neoplasm caused by the proliferation of poorly differentiated precursors of the lymphoid cells, which are known as blast cells. Blast cells replace the normal elements of the bone marrow, decreasing the production of normal blood cells and, therefore, causing anemia, thrombocytopenia and neutropenia. They can also infiltrate other organs, such as liver, spleen, lymph nodes or, less frequently, central nervous system. (Florensa et al, 2006; Ribera & Ortega, 2003; Sharma et al, 2004)

Acute lymphoblastic leukemia is the most common type of leukemia in children, although it is also seen in adult patients. If blood test results are abnormal or the doctor suspects leukemia despite normal cell counts, a bone marrow aspiration and biopsy are the next steps. Treatment is based on chemotherapy, radiotherapy and bone marrow transplantation. (Ribera & Ortega, 2003; Ortega, 2006; Ribera, 2006)

The dominant clinical feature of these diseases is usually bone marrow failure caused by accumulation of blast cells although any organ can be infiltrated. Furthermore, signs and symptoms of acute lymphoblastic leukemia can be secondary to the toxicity of chemotherapy and/or radiotherapy, graft versus host reaction following bone marrow transplantation, or infections due to immunosuppression. They can include fever, weakness, fatigue, breathlessness, opportunistic infections, weight loss, anorexia, easy bruising and bleeding, thrombosis, edema of the lower limbs and the abdomen, swollen liver or spleen, lymphadenopathy, or bone pain. (Florensa et al, 2006; Ribera & Ortega, 2003; Ortega, 2006)

Ophthalmological signs in patients suffering from leukemia were first described as "leukemic retinopathy" by Liebreich in 1863. (Campos-Campos et al, 2004; Guyer et al, 1989)

Reports of patients with acute lymphoblastic leukemia presenting with visual symptoms as the initial sign of the disease are rare (Kim et al, 2010). However, ocular changes in acute lymphoblastic leukemia are common. They have been reported to occur in up to 90% of patients with this disease (Kincaid & Green, 1983; Mesa, 2003).

The improvement of the survival of patients suffering from acute lymphoblastic leukemia has increased the incidence of ocular manifestations they develop. Ocular involvement is associated with a higher frequency of bone marrow relapses and central nervous system compromise weeks or months later, which means a poor prognosis and a low survival rate. (Ohkoshi & Tsiaras, 1992) Leukemic relapses are often diagnosed after ocular presentation. A lot of lesions are asymptomatic and the patient is diagnosed in a routine examination by an ophthalmologist. (Ribera & Ortega, 2003; Sharma et al, 2004; Ribera 2006) Therefore, it is important to consider an ophthalmic evaluation at the time of diagnosis of acute leukemia in adults and children.

The treatment of the ocular manifestations is complicated, as the penetration of the chemotherapeutic drugs to the eye is quite difficult, even when they are injected intrathecally. Radiotherapy is also used for the treatment. (Ribera & Ortega, 2003; Ortega, 2006; Ribera, 2006).

All the structures of the eye and its adnexal structures can be affected by acute lymphoblastic leukemia. Ophthalmic involvement in acute lymphoblastic leukemia can be classified into two major categories: primary or direct leukemic infiltration of the ocular structures; and secondary or indirect involvement. These secondary changes may be the result of hematologic abnormalities such as anemia, thrombocytopenia, leucopenia, and hyperviscosity. Likewise, opportunistic infections due to immunosuppression -particularly viral, protozoal and fungal infections- and the leukemia treatment itself may secondarily involve the ocular system (Rosenthal, 1983; Wu et al, 2006), as well as graft-versus-host reaction or toxicity of the chemotherapy or radiotherapy. (Sharma et al, 2004; Rosenthal, 1983).

2. Primary manifestations

2.1 Orbit and eyelids

All the structures of the orbit, including lacrimal glands, eyelids, soft tissues and extraocular muscles, may become affected in the course of acute lymphoblastic leukemia.

Orbital infiltration or a mass formation may cause exophthalmos and/or diplopia. Leukemic cells may infiltrate the soft tissues, extraocular muscles or lacrimal glands. All kinds of leukemia can affect the orbit, but it is more common in acute lymphoblastic leukemias. (Cardone et al, 2006; Sharma et al, 2004) The symptoms are not different from those caused by other orbital masses, so the diagnosis is usually made after a biopsy of the mass and anatomopathological study. (Abdelouahed et al, 2005).

When the eyelids are involved, they can suffer edema, inflammation, chemosis and pain.

2.2 Conjunctiva

Primary manifestations of conjunctiva involvement in acute lymphoblastic leukemia are caused by direct infiltration by blast cells. Hyperemia and edematization of the lower subpalpebral conjunctiva can be an unusual initial sign of acute lymphoblastic leukemia (Rosenthal, 1983). Infiltrates can also be seen, preferably around vessels (Fernández et al, 1999) or in the form of a conjunctival mass. (Cook & Bartley, 1997)

2.3 Sclera

Scleral infiltration is common during Acute lymphoblastic leukemia, around the episcleral vessels. It is usually asymptomatic and can be an autopsy finding (Sharma et al, 2004;

Burton et al, 2005). Sometimes, a scleral infiltration can simulate a scleritis. Recurrent episcleritis has been associated to adult T-cell leukemia. (Goto et al, 1993)

2.4 Cornea

Because cornea is an avascular structure, it is hardly ever affected by a direct leukemic infiltration. Occasionally there can be ring-shaped corneal ulcers, subepithelial limbal infiltrates and peripheral ulcers. (Taylor, 1997; Rosenthal, 1983; Eiferman et al, 1988).

2.5 Anterior chamber and iridocorneal angle

The space between cornea and lens may be affected in the form of anterior uveitis, pseudohypopyon or spontaneous hyphema.

Most types of leukemias may show protean ocular manifestations ranging from leukemic retinopathy to involvement of the iris and anterior chamber (Decker & Burnstine, 1993). Clinically evident infiltration of the iris by leukemic cells is not common. It occurs associated with the involvement of choroid and ciliary body. It is characterized by a change in iris color, and a pseudohypopyon, which is grey/yellow in color (Perry & Mallen, 1979). In acute lymphoblastic leukemia, hypopyon has been estimated at 2.5 to 18% of relapsed cases, depending on the stage of the disease (Decker & Burnstine, 1993; Yi et al, 2005; Wetzler & Lincoff, 2000; Ramsay & Lightman, 2001).

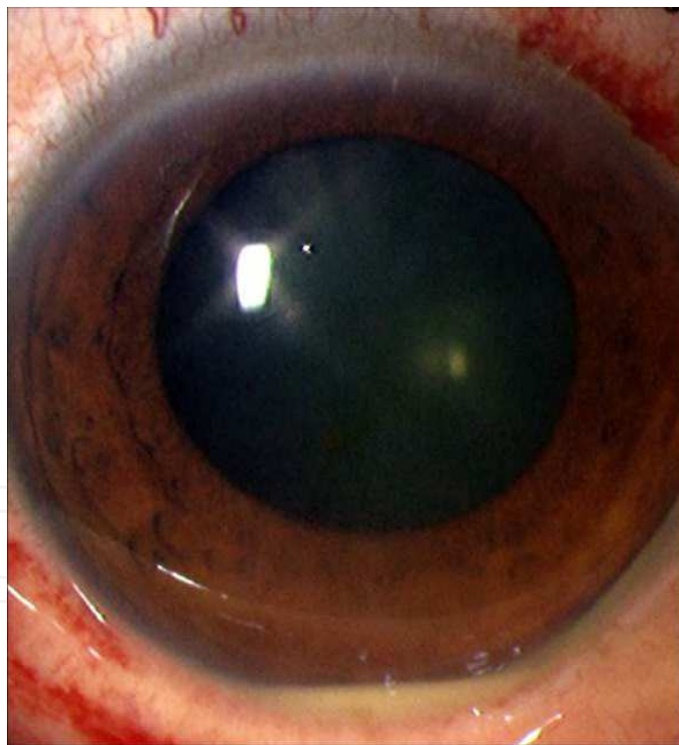


Fig. 1. Sterile hypopyon/pseudohypopyon in a patient with acute lymphoblastic leukemia.

Although leukemias have been identified as the cause of uveitis in only 5% of paediatric uveitis cases (Soylu et al, 1997), a hypopyon in a child would make us suspicious of a masquerade syndrome. Anterior chamber involvement in cases of acute lymphoblastic leukemia relapse is typically bilateral (Yi et al, 2005). The mechanisms by which the cells migrate into the anterior chamber are not clear.

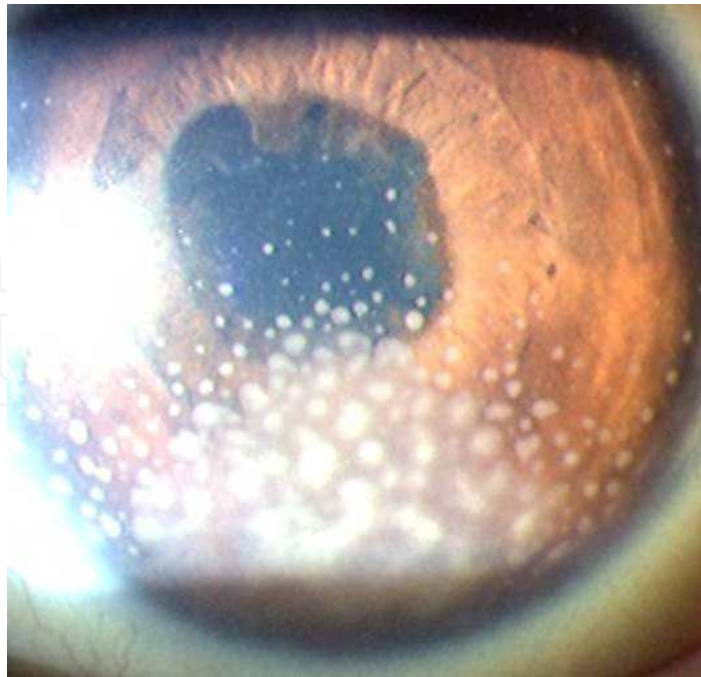


Fig. 2. Corneal precipitates in a case of uveitis secondary to acute lymphoblastic leukemia.

On histopathological examination, the iris may show diffuse involvement, especially at the root and sphincter. An iris biopsy can give us the diagnosis of leukemia (Campos-Campos et al, 2004). The intraocular pressure can be high enough to cause signs and symptoms of acute glaucoma with normal depth of anterior chamber (Wolintz et al, 1971). The raised intraocular pressure is probably due to infiltration of the trabecular meshwork (Rowan & Sloan, 1976).

Prompt anterior chamber paracentesis, and pathological studies should be done in such cases where history of leukemia is present even though other systemic investigations might indicate remission. Complete ocular examination including slit-lamp examination should be performed in all leukemic patients periodically. Early diagnosis is the aim to detect such extramedullary relapses so that timely referral and effective treatment can be initiated. (Campos-Campos et al, 2004)

In children, spontaneous hyphema is also a presentation of leukemia (Perry & Mallen, 1979). Usually clinically apparent involvement of the iris and anterior segment occurs with acute lymphoblastic leukemia (Rowan & Sloan, 1976; Fonken & Ellis, 1966). It may also occur less commonly with chronic lymphocytic leukemias (Martin, 1968) and myeloid leukemias (Perry & Mallen, 1979).

Any ophthalmic manifestation in children with leukemia should be detected and treated early. Radiotherapy is warranted in infiltration of the anterior chamber. The presence of ocular or central nervous system involvement indicates poor prognosis in acute childhood leukemia.

2.6 Retina

The retina is involved in leukemia very commonly. It is estimated that up to 70% of all patients with leukemia show fundus changes during the course of their disease (Alemayehu et al, 1996). Early manifestations are venous dilatation and tortuosity (Ballantyne & Michaelson, 1970).

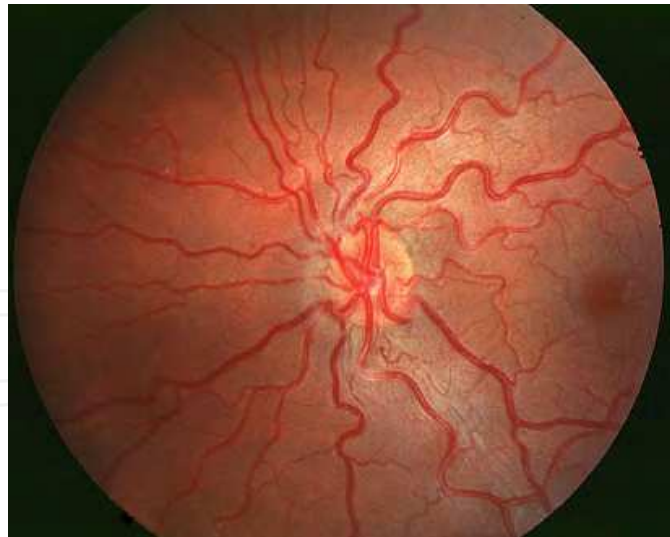


Fig. 3. Vascular congestion and tortuosity in a leukemic retinopathy

Other common retinal manifestations of acute lymphoblastic leukemia include retinal vascular sheathing, superficial retinal or intraretinal hemorrhages, and cotton wool spots, comprising what is called leukemic retinopathy (Rosenthal, 1983; Kincaid & Green, 1983; Park et al, 2000). Vascular occlusions have also been reported.

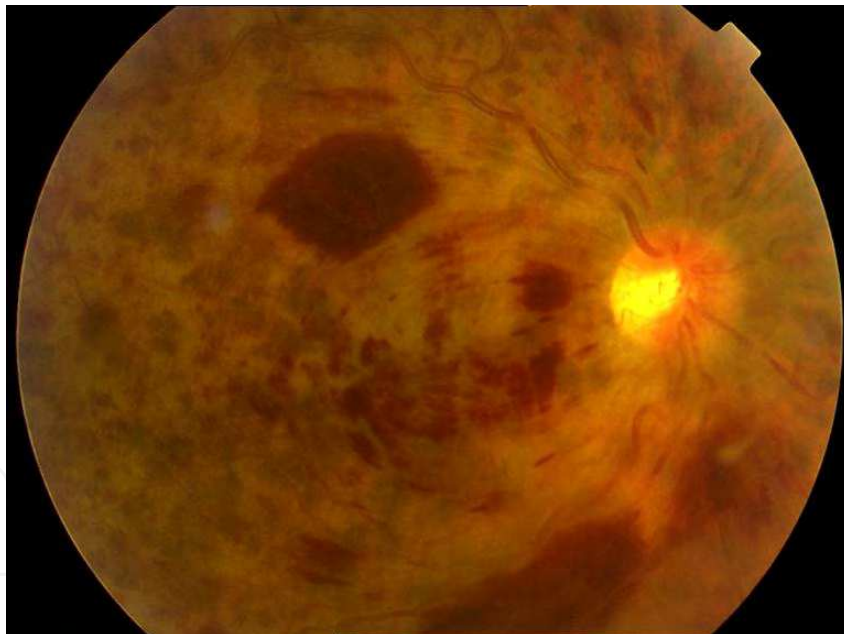


Fig. 4. Central retinal vein occlusion in a patient with hyperviscosity.

Retinal hemorrhages, usually in the posterior pole, may occur in all levels of the retina, but especially in the inner layers with focal destruction. They may be round or flame-shaped hemorrhages and often has a white component in the center. This white area consists of leukemic cells and debris, platelet-fibrin aggregates, or septic emboli (Abdallah et al, 2005). We may also see vitreous haemorrhages coming from retinal bleedings. Infiltrates and aggregates of leukemic cells are usually seen with surrounding hemorrhage (Kuwabara & Aiello, 1964). Large leukemic infiltrates can cause total retinal detachment

presenting as an isolated relapse (Primack et al, 1995). Smaller infiltrates tend to be perivascular. Subretinal infiltration in leukemia has been referred as subretinal hypopyon (Schworm et al, 1995). Cotton wool spots can be seen and are probably due to ischemia from anemia, hyperviscosity, or leukemic infiltration.

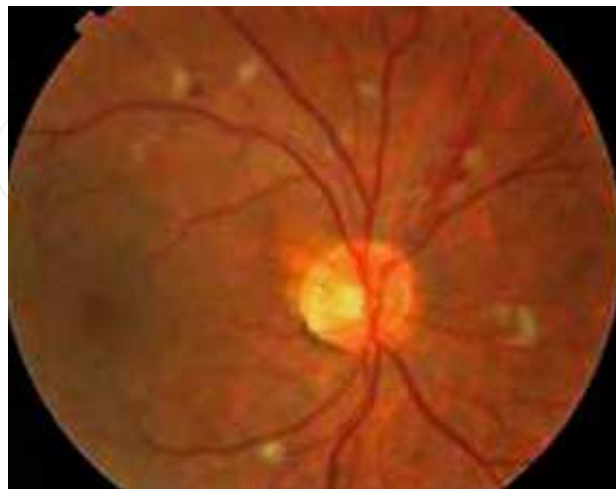

Fig. 5. Cotton-wool spots in a case of acute lymphoblastic leukemia.

Less frequent manifestations include microaneurysms which tend to be peripheral. The presence of microaneurysms is probably related to increased viscosity from elevated white blood cell count, and does not correlate with the hemoglobin level or platelet count (Jampol et al, 1975).

The internal limiting membrane generally acts as an effective barrier to leukemic cell infiltration (Kuwabara & Aiello, 1964). However, leukemic cells occasionally invade the vitreous body, possibly emerging from the optic nerve head. So, a bilateral dense cellular infiltration has been reported (Reese & Guy, 1993; Swartz & Schumann, 1980; Zhioua et al, 2001), resulting in a significant bilateral visual loss, and a vitrectomy may be necessary.

Although less commonly, serous retinal detachment, has been reported in only a few cases of acute lymphoblastic leukemia world-wide (Kincaid & Green, 1983; Tang et al, 1988; Stewart et al, 1989; Dahreddine et al, 2004), especially as a presenting sign of the disease or the first sign of relapse (Yang & Yu, 2009; Kim et al 2010).

Most of the reported cases of acute lymphoblastic leukemia with serous retinal detachment have involved younger patients (Reddy & Menon, 1998; Miyamoto et al, 2000; Malik et al, 2005) and are reported to be shallow in the posterior pole (Stewart et al, 1989; Miyamoto et al, 2000). Serous retinal detachment may develop as a result of choroidal involvement by leukemic cells or due to incompetence of the outer blood-retinal barrier inducing retinal pigment epithelial changes (Stewart et al, 1989; Hine & Kingham, 1979). The differential diagnosis of serous retinal detachment includes Vogt-Koyanagi-Harada disease, central serous chorioretinopathy, uveal effusion syndrome, age-related macular degeneration, choroidal hemangioma and metastatic neoplasm. The choroid is the most frequently involved ocular tissue in leukemia. Leukemic cell infiltration or hematologic disturbances may cause partial occlusion of the choriocapillaries and delay of choroidal circulation. The fact that systemic chemotherapy induced a rapid remission of exudative retinal detachment, consistent with previous reports, suggests leukemic cell infiltration as the underlying pathology (Yang & Yu, 2009). With an appropriate and early treatment, that can include

systemic chemotherapy and radiotherapy, serous retinal detachment may resolve completely with good recovery of visual acuity (Kim et al, 2010).

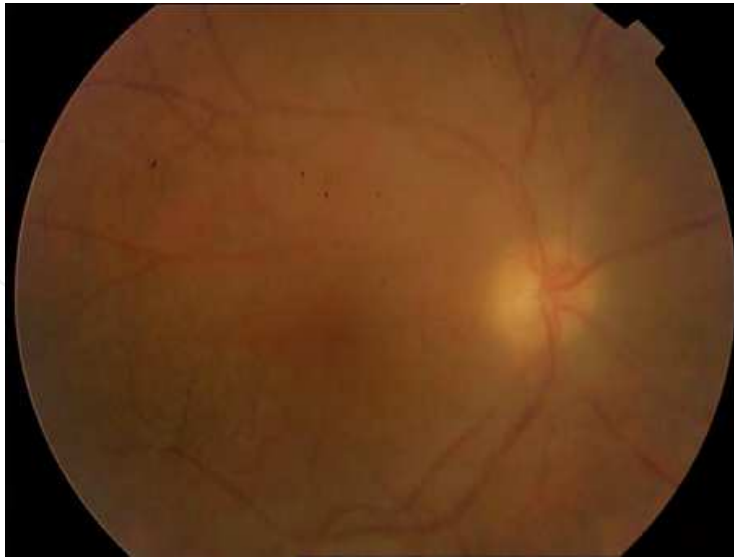


Fig. 6. Leukemic cells' infiltration of the vitreous body.

2.7 Choroid

The choroid is the most commonly affected ocular tissue, but choroidal involvement is often not clinically apparent. Sometimes choroidal and orbital leukemic infiltrate mimic advanced retinoblastoma. There can be a diffuse or perivascular involvement. When it is affected, the overlying retina can show alterations such as photoreceptor damage, retinal pigment epithelium atrophy or serous retinal detachment, usually affecting the posterior pole. (McManaway & Neely, 1994; Campos-Campos et al, 2004)

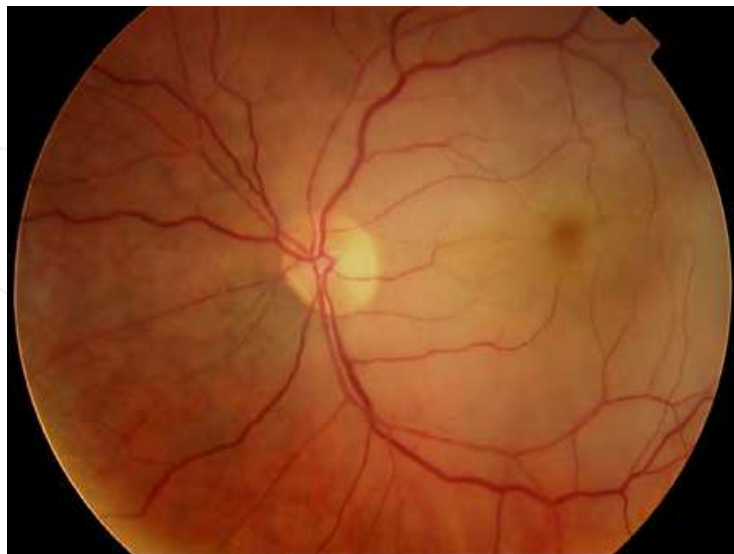


Fig. 7. Posterior pole serous detachment.

Uveal effusion syndrome is caused mainly by disruption of the transscleral outflow of intraocular fluid. Cytological examination of the choroidal fluid may detect atypical

lymphoid cells (Kase et al, 2010; Campbell et al, 1990; Schmiegelow et al, 1988). Leukemic infiltration of the choroid may cause a serous detachment of the retina, which is often bilateral. The fluoroangiographic aspect is similar to what is observed in acute choriocapillaris occlusion. (De Laey & De Gersem, 1989)

2.8 Optic nerve

The optic nerve is usually involved in central nervous system leukemia. It can happen in up to 13 to 18% of leukemias. Central nervous system involvement is becoming more frequent as new, more effective treatments have allowed an improvement of the survival of patients suffering from acute lymphoblastic leukemia (Arruga, 2000; Nikaido et al, 1988). The symptoms of central nervous system leukemia depend on the rise of the intracranial pressure and the affectation of the cranial nerves. They can include lethargy, nausea, vomiting, seizures and ocular symptoms such as blurred vision, loss of visual acuity or diplopia, when the cranial nerves III, IV or VI are affected. Sometimes the affectation of the optic nerve is asymptomatic and only papilloedema can be found. (Ribera & Ortega, 2003; Lin et al, 2004; Sharma et al, 2004; Mayo et al, 2002)

Papilloedema is the most frequent sign of optic nerve involvement. It can be due to direct infiltration of the nerve by leukemic cells, increased intraocular pressure, or swelling because of retrolaminar leukemic invasion. However, optic nerve can also be affected without the presence of papilloedema. (Joshi et al, 2009; Mateo et al, 2007; Bhatt et al 2008; Cleveland & Gelfand, 2009)

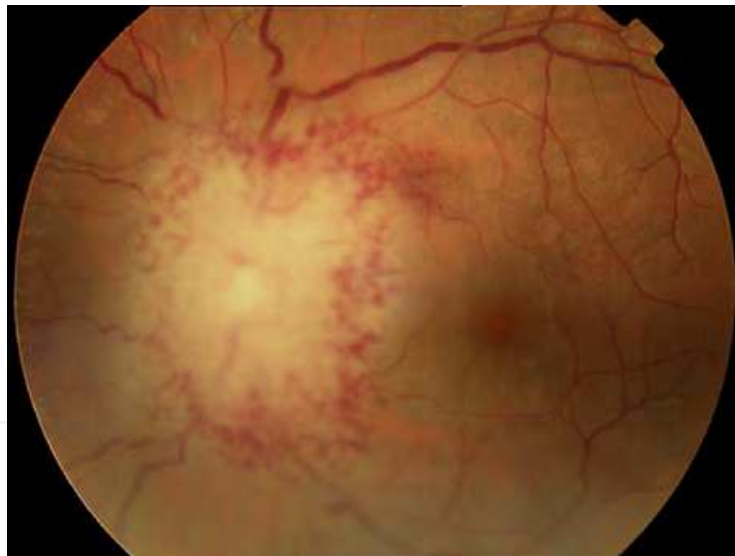

Fig. 8. Massive papilloedema in a patient with acute lymphoblastic leukemia.

The affectation of the optic nerve usually happens during the evolution of acute lymphoblastic leukemia, but it can also be the first sign of acute lymphoblastic leukemia or of extramedullary relapse after remission. (Mesa et al 2003) It always means a poor prognosis for the patient, especially if it happens when the patient is still receiving treatment, rather than after it. (Lo Curto et al, 1996; Bhatt et al, 2008; Schocket et al, 2003)

The treatment of optic nerve involvement is quite difficult, as the optic nerve is relatively unaffected by systemic chemotherapy and serves as a sanctuary of acute lymphoblastic leukemia. It usually includes intrathecal chemotherapy and radiotherapy. (Bandyopadhyay et al, 2010; Lo Curto et al, 1996)

3. Secondary manifestations

3.1 Orbit and eyelids

The structures of the orbit can show affectation after remission or secondary to chemotherapy, radiotherapy or graft versus host reaction. In immunocompromised patients, also opportunistic infections can happen.

Lacrimal glands are affected frequently, either by direct infiltration by leukemic cells, graft versus host reaction or radiation, causing a tear dysfunction and dry eye. If severe, it can cause conjunctival and corneal problems such as queratoconjunctivitis sicca, corneal ulcers which can even lead to a corneal perforation and endophtalmitis. (Sharma et al, 2004; Im & Yoon, 2010).

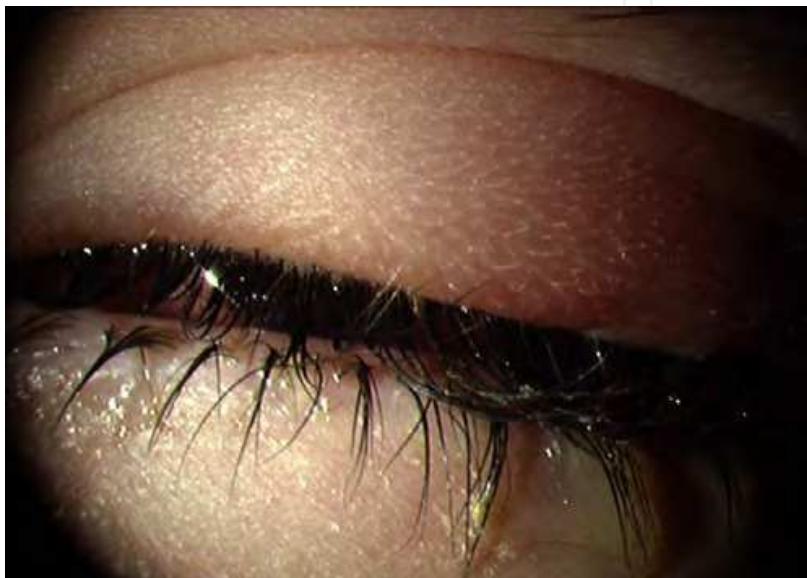


Fig. 9. Preseptal cellulitis in an immunocompromised patient.

Infectious diseases such as preseptal cellulitis or acute dacryocystitis can be seen in immunocompromised patients. They should be treated with both antibiotics and chemotherapy, as soon as possible, to avoid further complications. (Im & Yoon, 2010; Wirostko et al, 1999)

3.2 Conjunctiva

Secondary manifestations to blood disorders are not common. Hyperviscosity can produce vascular anomalies in the conjunctiva, which are more frequent in chronic leukemias. (Swartz & Jampol, 1975)

The most common involvement of the conjunctiva comes from conjunctivitis secondary to dry eye after a graft versus host reaction. The bone marrow transplantation, in which allogeneic bone marrow obtained from a HLA-matched donor is used, can be a part of the treatment of acute lymphoblastic leukemia. The patients treated are predisposed to suffer a graft against host disease. The incidence of ocular affectation is variable according to the series, reaching to achieve 81.8% of cases, and it is considered a marker of poor prognosis.

Keratoconjunctivitis sicca secondary to graft versus host reaction is difficult to manage. In the acute phase, there are four stages of severity: hyperemia, chemosis, pseudomembranous conjunctivitis with complete loss of conjunctival epithelium and finally, compromise of the

corneal epithelium. (Jabs et al, 1989; Sanders, 2002; Uchino et al, 2006) Its presence is related to vital prognosis with a mortality rate of 90% for stages 2 through 4 (Coskuncan 1994, Ohkoshi 1992).

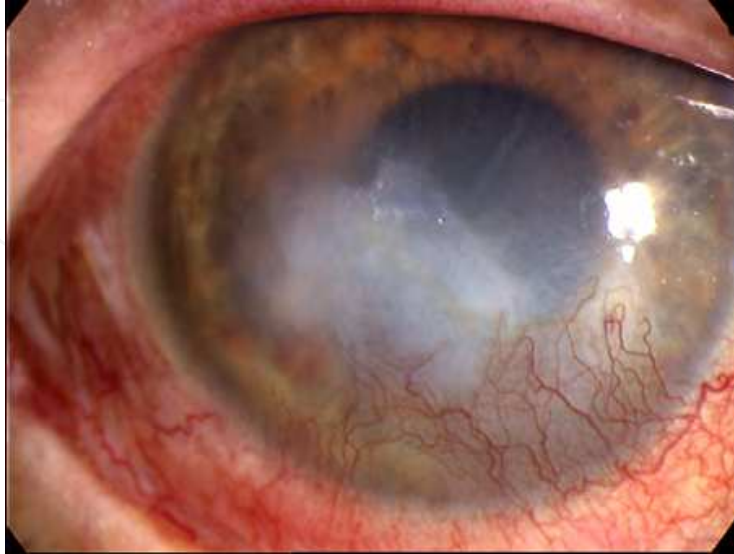

Fig. 10. Conjunctivitis sicca and corneal opacification in a patient with severe dry eye.

Dysfunction of the meibomian glands is another common manifestation of chronic graft against host disease. It is estimated that up to half of patients receiving allogeneic bone marrow transplantation are going to develop a dry eye 6 months later. (Ogawa & Kuwana, 1999)

An almost pathognomonic sign of passage to chronicity is the appearance of fibrous lines in the tarsal conjunctiva (Mondéjar et al, 2001). The severe dryness and the progressive superficial keratinization evolve towards the formation of ectropion, cicatricial lagophthalmos and a palpebral lichenification. A major impact of this is the emergence of severe and recurrent corneal erosions and ulcerations, which can even evolve to the drilling of trophic or infectious origin. (Mittelviehhaus & Auw-Hadrich, 2003)

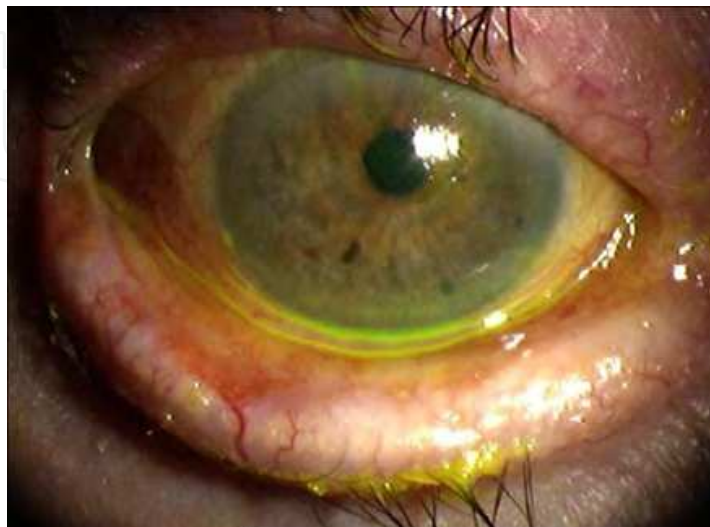

Fig. 11. Ectropion in a severe dry eye patient.

Other secondary manifestations are those due to complications of the antileukemic treatment and opportunistic ocular infections. Direct toxicity of methotrexate is associated with the appearance of keratoconjunctivitis. The immunosuppression attached to marrow failure typical of the leukemia and the secondary to chemotherapy, favours infections by different microorganisms. (Fernández et al 1999; Cogan, 1977)

3.3 Sclera

Occasionally, immunocompromised patients suffer opportunistic infectious scleritis.

3.4 Cornea

Some drugs used for chemotherapy can produce corneal toxicity: citarabine produces corneal toxicity by interfering with epithelium's synthesis of DNA. (Fernandez et al, 1999; Mondéjar et al, 2001)

Keratoconjunctivitis sicca is the most common manifestation of graft versus host reaction. In the more severe cases, keratitis, corneal ulcers or corneal opacification are not uncommon. (Jabs et al, 1989; Uchino et al, 2006) The appearance of calcareous corneal degeneration in patients with severe dry eye in graft against host disease has also been described. In these cases the deposit of calcium salts occurs in all the layers of the cornea. (Lavid et al, 1995) However, sometimes there is a rapid development of extracellular deposits of calcium at subepithelial level, causing the appearance of acute calcium keratopathy that is located in the interpalpebral zone (Carreras & Muiños, 1996). Given the frequency and severity of these alterations of the ocular surface, it is important a close monitoring of all patients who received bone marrow transplant and especially those who develop a graft against host disease aimed at early detection.

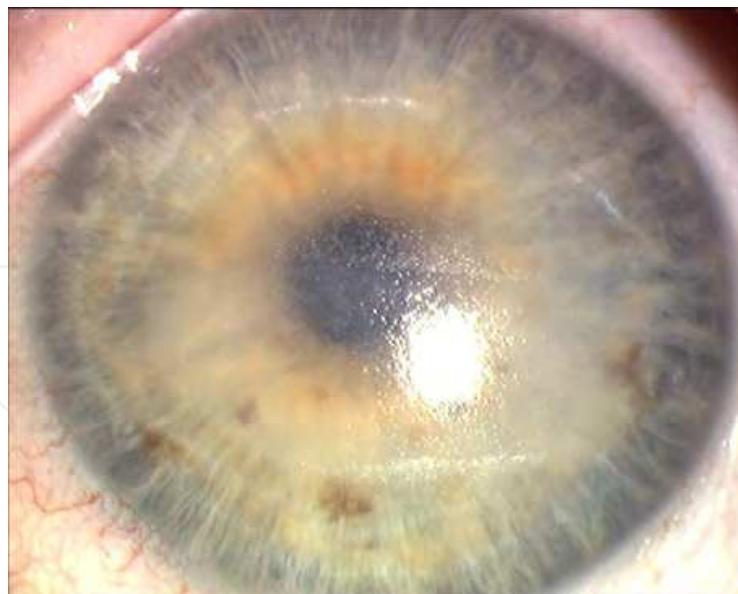

Fig. 12. Corneal opacification secondary to severe keratococonjunctivitis sicca.

In patients suffering from secondary immunosuppression, infections by microorganisms such as herpes and fungi are favoured. Some secondary manifestations are keratitis, corneal thinning, ulcers and even corneal melting and perforation. (Fernández et al, 1999; Cogan, 1977).

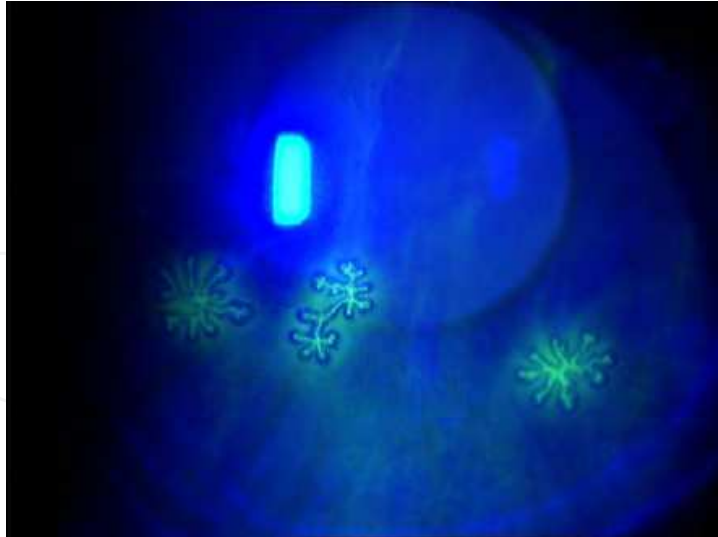


Fig. 13. Herpetic corneal ulcers.

3.5 Anterior chamber and iridocorneal angle

Extramedullary relapse of acute leukemias may masquerade as hypopyon uveitis (Ayliffe, 1995). Primary relapse of acute leukemia in the anterior segment is not uncommon (Ayliffe, 1995; Jancovic et al, 1995; MacLean et al, 1995; Soylyu et al, 1997).

It is possible an ischemia of the anterior segment secondary to anaemia or hyperviscosity. It might cause corneal edema, conjunctival chemosis, visual loss, anterior uveitis, increased intraocular pressure, cataracts and eye pain. (Sharma et al, 2004)

Cataracts may also develop as a consequence of the use of steroids, chemotherapy drugs or radiotherapy, or after ischemia caused by hyperviscosity or anaemia. (Elliott et al, 1985; Sharma et al 2004)

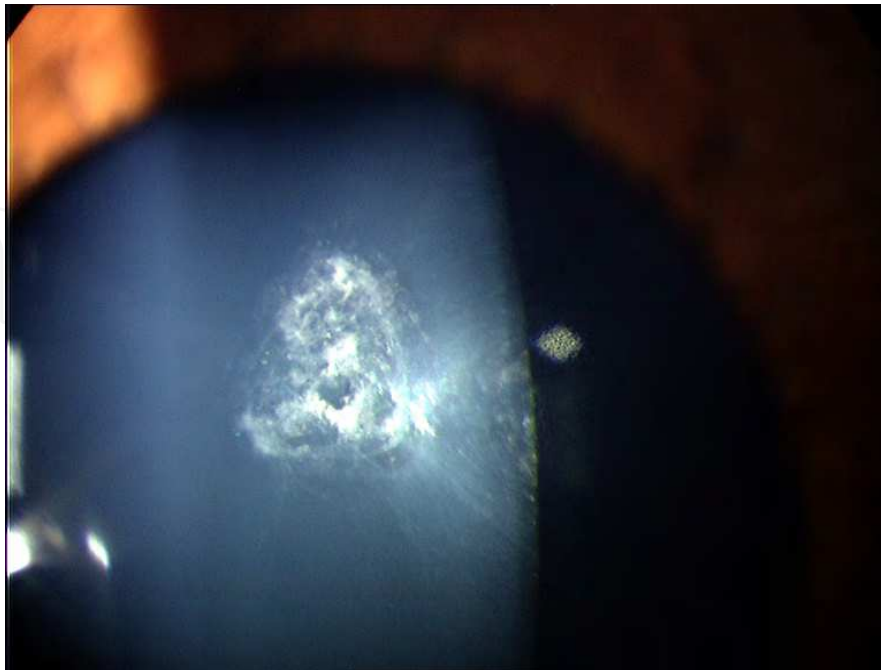


Fig. 14. Subcapsular cataract caused by the use of corticosteroids.

3.6 Retina

Patients with acute leukemia are susceptible to unusual and potentially life-threatening opportunistic infections that may involve the retina, especially during periods of neutropenia, which result both from the underlying disease as well as chemotherapy. These patients are susceptible to a wide variety of infections by viral (Cytomegalovirus, herpes virus), fungal (Candida, Aspergillus), protozoal, and bacterial organisms (Cogan, 1977). Cytomegalovirus infection is among the common viral infections in the immunocompromised hosts (Shibata et al, 1997). However, the prevalence of cytomegalovirus antigenemia and disease in patients with hematological malignancies who are not transplant recipients or HIV infected is largely unknown and is thought to be low (Taha et al, 2010). The virus invades the retina, causing necrosis, vascular sheathing, hemorrhage, and combined exudative and rhegmatogenous retinal detachment (Meredith et al, 1979).

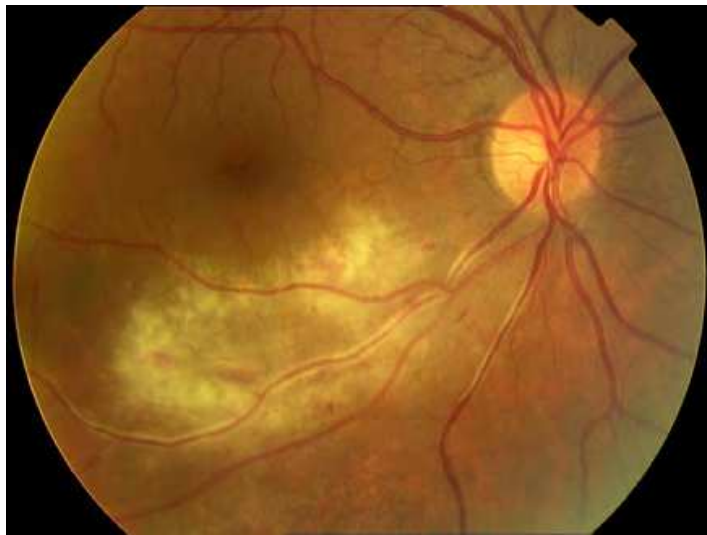


Fig. 15. Opportunistic infection by cytomegalovirus in a patient with neutropenia.

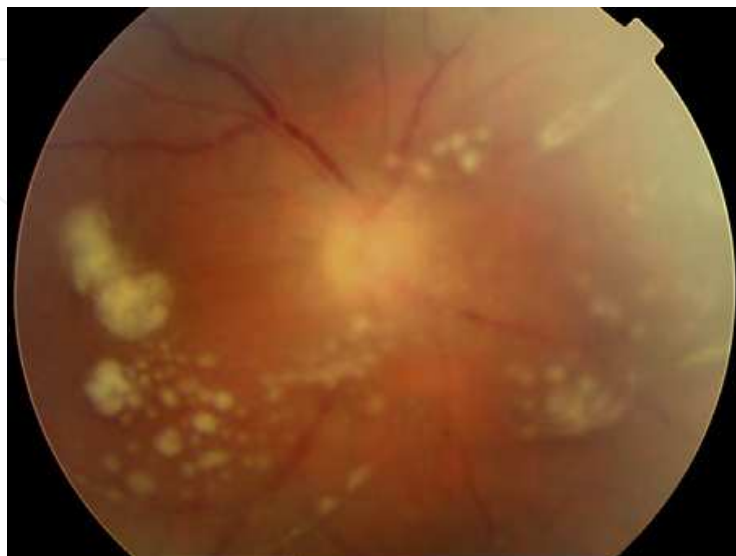

Fig. 16. Vitritis caused by Candida infection.

Other viruses (herpes simplex, varicella zoster, and mumps) may also cause necrotizing retinitis in immunocompromised hosts (Cogan, 1977). Herpes zoster can also cause peripheral corneal ulcer, keratitis, and scleritis (Walton & Reed, 1999). Mumps virus has been reported to be a cause of granulomatous uveitis (Al-Rashid & Cress, 1977). Fungi are common causes of ocular infection in leukemias. *Candida*, especially *Candida albicans*, is among the common infections in this subset of patients; when it involves the retina, it typically appears as focal, deep white lesions that can be singular or multiple. It may extend into the vitreous and cause uveitis and retinitis with characteristic cotton balls in the vitreous (Cogan, 1977). The rate of developing chorioretinitis in patients with candidemia has reduced markedly since the 1990's due to the early identification of candidemia in blood cultures coupled with a trend of early empiric antifungal therapy (Ninane et al, 1979). *Aspergillus* is also a common fungal infection in leukemic patients (Ellis & Little, 1973).

3.7 Choroid

Choroid secondary affection is much less common than primary. Retinochoroidal infarction has been detected during the treatment of acute lymphoblastic leukemia. (Kato et al, 2006).

3.8 Optic nerve

Secondary optic nerve affection include toxicity of chemotherapy, antibiotics or radiotherapy, ischemia after anaemia or hyperviscosity, and opportunistic infections in immunocompromised patients. (Joshi et al, 2009; Bhatt et al 2008; Cleveland & Gelfand, 2009).

4. Conclusion

Ophthalmological manifestations in patients suffering acute lymphoblastic leukemia are very common, partly thanks to the improvement of the survival because of the new and more efficient treatments, appearing in as much as 90% of the patients. They usually occur during the evolution of the illness, but they can be its first manifestation or the first sign of relapse after remission. (Kincaid & Green, 1983; Mesa, 2003)

Ocular involvement can be caused by direct infiltration by leukemic cells or be secondary to anemia, thrombocytopenia, leucopenia, hyperviscosity and opportunistic infections in immunosuppressed patients. All the structures of the eye can be affected, as well as the orbit, the eyelids and the lacrimal glands. (Sharma et al, 2004)

The treatment of the ocular manifestations is difficult, because the effect of chemotherapy in the eye is very limited. Radiotherapy is frequently used for the treatment. (Ribera & Ortega, 2003; Ortega, 2006; Ribera, 2006)

Every patient suffering acute lymphoblastic leukemia should get a complete ophthalmological exam regularly, to detect and treat eye problems in order to preserve vision and, even more important, in patients who are in remission, to diagnose relapses as soon as possible, because an early treatment can improve the patient's vital prognosis. (Mateo et al, 2007)

5. References

Abdallah E, Hajji Z, Mellal Z, Belmekki M, Bencherifa F, Berraho A (2005). Macular serous detachment revealing acute lymphoblastic leukemia. *J Fr Ophthalmol*, 28(1):39-44, ISSN 0181-5512.

- Abdelouahed K, Laghmari M, Tachfouti S, Cherkaoui W, Khorassani M, M'Seffer FA, Mohcine Z (2005). Leucémie aiguë lymphoblastique T/Lymphome lymphoblastique orbitaire chez l'enfant. *J Fr Ophtalmol*, 28(2):197-200, ISSN 0181-5512.
- Alemayehu W, Shamebo M, Bedri A, Mengistu Z (1996). Ocular manifestations of leukaemia in Ethiopians. *Ethiop Med J*, 34:217-224, ISSN 0014-1755.
- Al-Rashid RA, Cress C (1977). Mumps uveitis complicating the course of leukaemia. *J Pediatr Ophthalmol*, 14:100-102, ISSN 0022-345X.
- Arruga J (2000). Lesiones metastáticas y paraneoplásicas del nervio óptico. *Rev Neurol* 31:1256-1258. ISSN 0210-0010.
- Ayliffe W, Foster CS, Marcoux P, Upton M, Finkelstein M, Legmann A (1995). Relapsing acute myeloid leukaemia manifesting as hypopyon uveitis. *Am J Ophthalmol*, 119:361-364, ISSN 0002-9394.
- Ballantyne AJ, Michaelson IC (1970). *Textbook of the Fundus of the Eye*. Pp 290-292. Williams and Wilkins, ISBN 0443006598 Baltimore.
- Bhatt UK, Gregory ME, Madi MS, Fraser M, Woodruff HA (2008). Sequential leukemic infiltration and human herpesvirus optic neuropathy in acute lymphoblastic leukemia. *Journal of AAPOS* 12:200-202. ISSN 1528-3933.
- Bandyopadhyay S, Das D, Das G, Gayen S (2010). Unilateral optic nerve infiltration as an initial site of relapse of acute lymphoblastic leukemia in remission. *Oman J Ophthalmol* 3:153-154. ISSN 0974-7842.
- Burton BJ, Cunningham ET, Cree IA, Pavesio CE (2005). Eye involvement mimicking scleritis in a patient with chronic lymphocytic leukaemia. *Br J Ophthalmol*, 89(6):775-776, ISSN 0007-1161.
- Campbell RA, Bouldin TW, Peiffer RL (1990). Large histiocytes in the choroid of leukemic patients. *Arch Pathol Lab Med*, 114(2):210-211, ISSN 0003-9985.
- Campos-Campos LE, Mendoza-Altamirano L, Pérez RX, Beauregard-Escobar AM, Calderón LM (2004). Alteraciones oculares en pacientes pediátricos con leucemia aguda. *Rev Mex Oftalmol* 14:287-290, ISSN 01874519.
- Cardone S, Yen MT, Chévez-Barríos P, Foroozan R, Yen KG (2006). Recurrent Acute Lymphoblastic Leukemia Presenting in the Lacrimal Gland. *Ophthal Plast Reconstr Surg*, 22(1):56-57, ISSN 1537-2677.
- Cleveland KO, Gelfand MS (2009). Optic neuropathy following linezolid use in a patient with acute lymphocytic leukemia. *Clin Infect Dis* 49(4):645-646. ISSN 1537-6591.
- Cogan DG (1977). Immunosuppression and eye disease. *Am J Ophthalmol*, 83:777-788, ISSN 0002-9394.
- Cook BE, Bartley GB (1997). Acute lymphoblastic leukemia manifesting in an adult as a conjunctival mass. *Am J Ophthalmology* 124:104-105, ISSN 0002-9394.
- Coskuncan N, Jabs D, Dunn JP, Haller JA, Green WR, Vogelsang GB, Santos GW (1994). The eye in bone marrow transplantation. *Arch Ophthalmology*, 112:372-379, ISSN 0096-6339.
- Dahreddine M, Karim A, Moussaif H, Essakali NH, Mohcine Z (2004). White-centered retinal hemorrhage revealing acute lymphoblastic leukemia. *J Fr Ophtalmol*, 27(5):506-509, ISSN 0181-5512.

- Decker EB, Burnstine RA (1993). Leukemic relapse presenting as acute unilateral hypopyon in acute lymphocytic leukemia. *Ann Ophthalmol*, 25:346-349, ISSN 1530-4086.
- De Laey JJ, De Gerssem R (1989). Clinical aspects of leukemic infiltration of the choroid and the optic nerve. *J Fr Ophthalmol*, 12(11):819-825, ISSN 0181-5512.
- Eiferman R, Levartovsky S, Schultz (1988). Leukemic corneal infiltrates. *Am J Ophthalmology*, 105:319-320, ISSN 0002-9394.
- Elliott AJ, Oakhill A, Goodman S (1985). Cataracts in childhood leukaemia. *Br J Ophthalmol* 69:459-461, ISSN 0007-1161.
- Ellis W, Little HL (1973). Leukaemic infiltration of the optic nerve head. *Am J Ophthalmol*, 75:867-871, ISSN 0002-9394.
- Fernandez MC, Serrano JC, Jimenez S (1999). Valoración oftalmológica de los pacientes pediátricos con diagnóstico de leucemia. *Medunab* 2(6):149-154, ISSN 0123-7047.
- Florensa L, Pérez-Vila E, Woessner S. (2006) Introducción al estudio de las leucemias agudas. Clasificación. Descripción de las diferentes variedades. Formas especiales. In: *Hematología clínica 5ª ed.* Sans-Sabrafen S, Besses C, Vives JL. pp 409-436. Elsevier, ISBN 84-8174-779-3 Madrid.
- Fonken HA, Ellis PP (1966). Leukaemic infiltrates in the iris. *Arch Ophthalmol*, 76:32-36, ISSN 0003-9950.
- Giagounidis AA, Meckenstock G, Flacke S, Burk M, Wehmeier A, Aul C (1997). Pseudomonas aeruginosa blepharoconjunctivitis during cytoreductive chemotherapy in a woman with acute lymphocytic leukaemia. *Ann Hematol*, 75:121-123, ISSN 0939-5555.
- Goto K, Sugita M, Okada K, Hatano H, Ishiguro N, Yoshiki T, Ohno S (1993). Recurrent episcleritis associated with adult T cell leukaemia. *Br J Ophthalmol*, 77(11):743-744. ISSN 0007-1161.
- Guyer DR, Sch, Schachat AP, Vitale S, Markowitz JA, Braine H, Burke PJ, Karp JE, Graham M. (1989) Leukemic retinopathy. Relationship between fundus lesions and hematologic parameters at diagnosis. *Ophthalmology*, 96:860-864, ISSN 0161-6420.
- Hine JE, Kingham JD (1979). Myelogenous leukemia and bilateral exudative retinal detachment. *Ann Ophthalmol*, 11:1867-1872, ISSN 1530-4086.
- Im SK, Yoon KC (2010). Corneal perforation with preseptal cellulitis in a patient with acute lymphocytic leukemia. *J Korean Med Sci* 25(8):1251-1252, ISSN 1598-6357.
- Jabs DA, Wingard J, Green WR, Farmer ER, Vogelsang G, Saral R (1989). The eye in bone marrow transplantation. III. Conjunctival graft-versus-host disease. *Arch Ophthalmol*, 107:1343-1348, ISSN 0096-6339.
- Jampol LM, Goldberg MF, Busse B (1975). Peripheral retinal micro aneurysms in chronic leukaemia. *Am J Ophthalmol*, 80:242-248, ISSN 0002-9394. - Jankovic M, Conter V, Pretto G, Placa F, D'Incalci M, Masera G (1995). Isolated bilateral anterior chamber eye relapse in a child with acute lymphoblastic leukaemia. *Med Pediatr Oncol*, 25:109-112, ISSN 0098-1532.
- Joshi L, Taylor SRJ, Large O, Yacoub S, Lightman S (2009). A case of optic neuropathy after short-term linezolid use in a patient with acute lymphocytic leukemia. *Clin Infect Dis* 48:73-74. ISSN 1537-6591.


- Kato Y, Takano Y, Kobayashi M, Ito F, Hara T, Yanagisawa T, Hoshi Y, Eto Y (2006). Retinochoroidal infarction during the treatment of acute lymphoblastic leukemia. *Pediatr Int*, 48(5):495-497, ISSN 1442-200X.
- Kase S, Saito W, Saito A, Ohno S (2010). Uveal effusion syndrome caused by choroidal invasion of malignant lymphoma. *Jpn J Ophthalmol*, 54(1):109-110, ISSN 1613-2246.
- Kim J, Chang W, Sagong M (2010). Bilateral serous retinal detachment as a presenting sign of acute lymphoblastic leukemia. *Korean J Ophthalmol*, 24(4):245-248, ISSN 1011-8942.
- Kincaid MC, Green WR (1983). Ocular and orbital involvement in leukemia. *Surv Ophthalmol*, 27:211-232, ISSN 0039-6257.
- Kuwabara T, Aiello L (1964). Leukaemic military nodule in retina. *Arch Ophthalmol*, 72:494-497, ISSN 0003-9950.
- Lavid Jj, Herreras JM, Calonge M, Saornil MA, Aguirre C (1995). Calcareous corneal degeneration: report of two cases. *Cornea*, 14:97-102, ISSN 0277-3740.
- Lin YC, Wang AG, Yen MY, Hsu WM (2004). Leukaemic infiltration of the optic nerve as the initial manifestation of leukaemic relapse. *Eye* 18:546-550, ISSN 0950-222X.
- Lo Curto M, D'angelo P, Jankovik M, Fugardi MG, Ziino O, Casale F (1996). Isolated ocular relapse in childhood acute lymphoblastic leucemia during complete remission. *Haematologica* 81:47-50, ISSN 0390-6078.
- MacLean H, Clarke MP, Strong NP, Kernahan J (1995). Primary relapse of acute leukaemia in anterior segment of the eye. *Lancet* 346:500, ISSN 0140-6736.
- Malik R, Shah A, Greaney MJ, et al (2005). Bilateral serous macular detachment as a presenting feature of acute lymphoblastic leukemia. *Eur J Ophthalmol*, 15:284-286, ISSN 1120-6721.
- Martin B (1968). Infiltration of the iris in chronic lymphatic leukaemia. *Br J Ophthalmol* 52:781-785, ISSN 0007-1161.
- Mateo J, Abarzuza R, Núñez E, Cristóbal JA (2007). Infiltración bilateral del nervio óptico en un caso de leucemia aguda linfoblástica de células T en remisión. *Arch Soc Esp Oftalmol* 82:167-170, ISSN 0365-6691.
- Mayo GL, Carter JE, McKinnon SJ (2002). Bilateral optic disk edema and blindness as initial presentation of acute lymphocytic leukemia. *Am J Ophthalmol* 134:141-142, ISSN 0002-9394.
- McManaway JW, Neely JE (1994). Choroidal and orbital leukemic infiltrate mimicking advanced retinoblastoma. *J Pediatr Ophthalmol Strabismus*, 31(6):394-296, ISSN: 0191-3913.
- Meredith TA, Aaberg TM, Reeser FH (1979). Rhegmatogenous retinal detachment complicating CMV retinitis. *Am J Ophthalmol* 87: 793-796, ISSN 0002-9394.
- Mesa F, Cordovés L, García M, Losada MJ, Martín F (2003). Manifestaciones oculares como presentación de recaída de leucemia aguda linfoblástica de células T. *Arch Soc Canar Oftal* 14:91-94, ISSN 0211-2698.
- Mittelviehhaus H, Auw-Hadrich C (2003). Corneal complications after hematopoietic stem cell transplantation. *Ophthalmologe*, 100:222-229, ISSN 1433-0423.
- Miyamoto K, Kashii S, Honda Y (2000). Serous retinal detachment caused by leukemic choroidal infiltration during complete remission. *Br J Ophthalmol*, 84:1318-9, ISSN 0007-1161.

- Mondejar J, Navea A, Diaz-Llopis M (2001). Trasplante de médula ósea. Enfermedad del injerto contra el huésped. In: *Manifestaciones oftalmológicas de las enfermedades generales*. Sánchez-Salorio M, Díaz-Llopis M, Benítez del Castillo JM, Rodríguez T, pp 228-230, Mac Line, ISBN 84-89085-16-1, Madrid.
- Nikaido H, Mishima H, Ono H, Choshi K, Dohy H (1988). Leukemic involvement of the optic nerve. *Am J Ophthalmol* 105:294-298, ISSN 0002-9394.
- Ninane J, Taylor D, Day S (1979). Leukaemic hypopyon in acute lymphoblastic leukaemia after interruption of treatment. *Arch Dis Child* 54:73-74, ISSN 0003-9888.
- Ogawa Y, Kuwana M (2003). Dry eye as a major complication associated with chronic graft-versus-host disease after hematopoietic stem cell transplantation. *Cornea*, 22(Supl 1):S19-S27, ISSN 0277-3740.
- Ohkoshi K, Tsiaras WG (1992). Prognostic importance of ophthalmic manifestations in childhood leukaemia. *Br J Ophthalmol*, 1992, 76: 651-655, ISSN 0007-1161.
- O'Rourke JF, O'Connor GR (1980). The eye as a sanctuary in acute lymphoblastic leukaemia. *Lancet*, 1:452-453, ISSN 0140-6736.
- Ortega JJ. (2006) Leucemias agudas infantiles. In: *Hematología clínica 5ª ed*. Sans-Sabrafen S, Besses C, Vives JL. pp 437-450. Elsevier, ISBN 84-8174-779-3 Madrid.
- Park YK, Jun RM, Ahn CS (2000). A case of optic nerve infiltration of acute lymphocytic leukemia. *J Korean Ophthalmol Soc*, 41:2008-2012, ISSN 1011-8942.
- Perry HD, Mallen FJ (1979). Iris involvement in granulocytic sarcoma. *Am J Ophthalmol*, 87:530-532, ISSN 0002-9394.
- Primack JD, Smith ME, Tychsen L et al (1995). Retinal detachment in a child as the first sign of leukemic relapse. *J Pediatr Ophthalmol Strabismus*, 32:253-256, ISSN 0191-3913.
- Ramsay A, Lightman S (2001). Hypopyon uveitis. *Surv Ophthalmol*, 46:1-18, ISSN 0039-6257.
- Reddy SC, Menon BS (1998). A prospective study of ocular manifestations in childhood acute leukaemia. *Acta Ophthalmol Scand* 76:700-703, ISSN 1395-3907.
- Reese AB, Guy L (1993). Exophthalmos in leukaemia. *Am J Ophthalmol*, 16:718-720, ISSN 0002-9394.
- Ribera JM (2006). Tratamiento de la leucemia aguda linfoblástica del adulto, In: *Hematología clínica 5ª ed*. Sans-Sabrafen S, Besses C, Vives JL. pp 451-460. Elsevier, ISBN 84-8174-779-3 Madrid.
- Ribera JM, Ortega JJ. (2003) Leucemia linfocítica aguda. In: *Hematología*. García-Conde J, San Miguel JF, Sierra J, Urbano-Ispizua A, Vicente V, Vives JL. pp 1029-1042. Aran, ISBN 84-95913-23-2 Madrid.
- Rosenthal AR (1983). Ocular manifestations of leukemia: a review. *Ophthalmology*, 90:899-905, ISSN 0161-6420.
- Rowan PJ, Sloan JB (1976). Iris and Anterior chamber involvement in leukaemia. *Ann Ophthalmol*, 8:1081-1085, ISSN 1530-4086.
- Sanders JE (2002). Chronic graft-versus-host disease and late effect after hematopoietic stem cell transplantation. *Int J Hematol*, 76:15-28, ISSN 0925-5710.
- Schmiegelow K, Scherfig E, Prause JU, Jensen OA (1988). Isolated leukemic choroidal relapse in a child with acute lymphoblastic leukemia one year off therapy, diagnosed through transvitreal retino-choroidal biopsy. *Acta Ophthalmol Scand*, 66(1):33-37, ISSN 1395-3907.

- Schocket LS, Massaro-Giordano M, Volpe NJ, Galetta SL (2003). Bilateral optic nerve infiltration in central nervous system leukemia. *Am J Ophthalmol* 135:94-96. ISSN 0002-9394.
- Schworm HD, Nasemann JE, Schriever S (1995). Subretinal hypopyon in prolymphocytic leukaemia. *Br J Ophthalmol*, 79:863-864, ISSN 0007-1161.
- Swartz M, Schumann GB (1980). Acute leukaemic infiltration of the vitreous diagnosed by pars plana aspiration. *Am J Ophthalmol*, 90:326-330, ISSN 0002-9394.
- Sharma T, Grewal J, Gupta S, Murray PI. (2004) Ophthalmic manifestations of acute leukaemias: the ophthalmologist's role. *Eye*, 18,pp 663-672, ISSN 0950-222X.
- Shibata K, Shimamoto Y, Nishimura T, Okinami S, Yamada H, Miyahara M (1997). Ocular manifestation in adult T cell leukaemia/lymphoma. *Ann Hematol*, 74:163-168, ISSN 0939-5555.
- Soylu M, Ozdemir G, Anli A (1997). Pediatric uveitis in southern Turkey. *Ocul Immunol Inflamm*, 5:197-202, ISSN 0927-3948.
- Stewart MW, Gitter KA, Cohen G (1989). Acute leukemia presenting as a unilateral exudative retinal detachment. *Retina*, 9:110-114, ISSN 0275-004X.
- Swartz M, Jampol LM (1975). Comma shaped venular segment of conjunctiva chronic granulocytic leukemia. *Can J Ophthalmology*, 110:458-461, ISSN 0008-4182.
- Taha R, Al Hijji I, El Omri H, Al-Laftah F, Negm R, Yassin M, El Ayoubi H (2010). Two Ocular Infections during Conventional Chemotherapy in a Patient with Acute Lymphoblastic Leukemia: A Case Report. *Case Rep Oncol*, 3(2):234-239, ISSN 1662-6575.
- Tang RA, Vila-Coro AA, Wall S, et al (1988). Acute leukemia presenting as a retinal pigment epithelium detachment. *Arch Ophthalmol*, 106:21-22, ISSN 0003-9950.
- Taylor D (1997). Leukaemia, In: *Paediatric Ophthalmology 2nd ed*, Taylor D. pp 816-817. Blackwell Science, ISBN 086542831X Orford.
- Uchino M, Ogawa Y, Kawai M, Shimada H, Kameyama K, Okamoto S, Dogru M, Tsubota K (2006). Ocular complications in a child with acute graft-versus-host disease following cord blood stem cell transplantation: therapeutic challenges. *Acta Ophthalmol Scand*, 84(4):545-548, ISSN 1600-0420.
- Walton RC, Reed KL (1999). Herpes zoster ophthalmicus following bone marrow transplantation in children. *Bone Marrow Transplant*, 23: 1317-1320, ISSN 0268-3369.
- Wetzler M, Lincoff N (2000). Unusual manifestation of acute leukemia. Case 3 -Unilateral leukemic hypopyon. *J Clin Oncol*, 18: 3439-3440, ISSN 1527-7755.
- Wirotko WJ, Garcia GH, Cory S, Harris GJ (1999). Acute dacryocystitis as a presenting sign of pediatric leukemia. *Am J Ophthalmol*, 127:734-736, ISSN 0002-9394.
- Wolintz AH, Goldstein JH, Seligman BR, Rosner F, Wesely AC, Lee SL (1971). Secondary glaucoma in leukaemia. *Ann Ophthalmol*, 3:1211-1213, ISSN 0939-5555.
- Wu L, Calderon M, Hernandez G, et al (2006). Bilateral exudative retinal detachment as the first sign of relapsing acute myelogenous leukaemia. *Clin Exp Ophthalmol*, 34:623-625, ISSN 1442-9071.
- Yang HK, Yu HG (2009). Acute lymphoblastic leukemia manifesting as acute Vogt-Koyanagi-Harada disease. *Korean J Ophthalmol*. 23(4):325-328, ISSN 1011-8942.

- Yi DH, Rashid S, Cibas ES, Arrigg PG, Dana MR (2005). Acute unilateral leukemic hypopyon in an adult with relapsing acute lymphoblastic leukemia. *Am J Ophthalmol*, 139:719-721, ISSN 0002-9394.
- Yoken J, Forbes B, Maguire AM, Prenner JL, Carpentieri D (2002). Microsporidial endophthalmitis in a patient with acute myelogenous leukaemia. *Retina*, 22:123-125, ISSN 0275-004X.
- Zhioua R, Boussen I, Malek I, Ouertani A (2001). Acute lymphoblastic leukaemia and vitreous infiltration. A case study. *J Fr Ophthalmol*, 24:180-182, ISSN 0181-5512.

IntechOpen



Novel Aspects in Acute Lymphoblastic Leukemia

Edited by Dr. Stefan Faderl

ISBN 978-953-307-753-6

Hard cover, 258 pages

Publisher InTech

Published online 16, November, 2011

Published in print edition November, 2011

Acute lymphoblastic leukemia (ALL) has turned from a universally fatal to a highly curable disease in little more than four decades. Even though differences in outcome continue to exist between children and adults, intense efforts are under way to overcome this discrepancy and improve the prognosis of adult patients as well. This exemplary progress in ALL therapy has been possible by the combination of an increasingly better understanding of the biology of the disease, availability of a range of effective drugs, and astute designs and relentless executions of many clinical trials. ALL is a complex disease requiring complex therapy. Whereas this book cannot provide a comprehensive review of every one of its many facets, the chapters from many investigators from around the world nevertheless cover a number of relevant topics: aspects of the epidemiology of ALL in Hispanics, ophthalmologic manifestations of ALL, overviews of current therapy and drug-resistance mechanisms, novel biological pathways and targets, new drugs in development, and long-term consequences of CNS prophylaxis and therapy. The publishers and editor therefore hope that the prospective readers will find enough insight and information for their own endeavors.

How to reference

In order to correctly reference this scholarly work, feel free to copy and paste the following:

Javier Mateo, Francisco J. Ascaso, Esther Núñez, Carlos Peiro, Gonzalo González and José A. Cristóbal (2011). Ophthalmological Manifestations in Acute Lymphoblastic Leukemia, *Novel Aspects in Acute Lymphoblastic Leukemia*, Dr. Stefan Faderl (Ed.), ISBN: 978-953-307-753-6, InTech, Available from: <http://www.intechopen.com/books/novel-aspects-in-acute-lymphoblastic-leukemia/ophthalmological-manifestations-in-acute-lymphoblastic-leukemia>

INTECH
open science | open minds

InTech Europe

University Campus STeP Ri
Slavka Krautzeka 83/A
51000 Rijeka, Croatia
Phone: +385 (51) 770 447
Fax: +385 (51) 686 166
www.intechopen.com

InTech China

Unit 405, Office Block, Hotel Equatorial Shanghai
No.65, Yan An Road (West), Shanghai, 200040, China
中国上海市延安西路65号上海国际贵都大饭店办公楼405单元
Phone: +86-21-62489820
Fax: +86-21-62489821

© 2011 The Author(s). Licensee IntechOpen. This is an open access article distributed under the terms of the [Creative Commons Attribution 3.0 License](#), which permits unrestricted use, distribution, and reproduction in any medium, provided the original work is properly cited.

IntechOpen

IntechOpen