

# We are IntechOpen, the world's leading publisher of Open Access books Built by scientists, for scientists

**4,800**

Open access books available

**122,000**

International authors and editors

**135M**

Downloads

Our authors are among the

**154**

Countries delivered to

**TOP 1%**

most cited scientists

**12.2%**

Contributors from top 500 universities



**WEB OF SCIENCE™**

Selection of our books indexed in the Book Citation Index  
in Web of Science™ Core Collection (BKCI)

Interested in publishing with us?  
Contact [book.department@intechopen.com](mailto:book.department@intechopen.com)

Numbers displayed above are based on latest data collected.

For more information visit [www.intechopen.com](http://www.intechopen.com)



# Biopolymers as Wound Healing Materials: Challenges and New Strategies

Ali Demir Sezer<sup>1</sup> and Erdal Cevher<sup>2</sup>  
<sup>1</sup>*Faculty of Pharmacy, Marmara University,*  
<sup>2</sup>*Faculty of Pharmacy, Istanbul University,*  
*Turkey*

## 1. Introduction

Wound healing is a multi-factorial physiological process. The complexity of this phenomenon makes it prone to several abnormalities. Apart from cellular and biochemical components, several enzymatic pathways also become active during repair and help the tissue to heal. The goal of this chapter is to introduce the biomaterials community to the emerging field of self-healing materials, and also to suggest how one could utilize and modify self-healing approaches to develop new classes of biomaterials. On the other hand, natural and synthetic gel-like materials, films/membranes, composites, micro-/nanoparticulate systems have featured heavily in the development of biomaterials for wound healing and other tissue-engineering purposes. Nanofibrous membranes are highly soft materials with high surface-to-volume ratios, and therefore can serve as excellent carriers for therapeutic agents or accelerate wound healing. Biocompatible and biodegradable polymer scaffolds combined with cells or biological signals are being investigated as alternatives to traditional options for tissue reconstruction and transplantation. These approaches are already in clinical use as engineered tissues that enhance wound healing and skin regeneration. This chapter covers the recent reports on the preparation and biomedical applications of biopolymers and biomaterials based on pharmaceutical dosage forms and wound dressing.

## 2. Skin structure

Skin is the largest organ of the integumentary system, comprising 15 % of the body weight. It protects the organism against injury and damage, and prevents passing of microorganisms and lets water vapour permeation. Substances secreted by glands in the epidermis contribute to the preservation of water - electrolyte balance of the body. The skin regulates body temperature by vasodilation and vasoconstriction of cutaneous blood vessels, and is formed by two main layers, including epidermis covering the body surface, and the dermis involving the connective tissue (Junquera et al, 1992).

### 2.1 Epidermis

The epidermis consists of two different cell layers. It comes into existence whereas ectoderm is taking its form. Cells forming the top layer of epithelium undergo keratinisation and form

the dead layer of skin. Whereas dead cells are being pushed from the deeper portion of the epidermis toward the surface, they are replaced by proliferating cells by mitosis in the basal layer. This change is called cytomorphosis. Cytomorphosis takes an average of 15 to 30 days for a healthy individual. The basic cell type of epidermis is keratinocytes. The content of the keratin constantly changes in the epidermis because keratinocytes undergo changes in epidermis and consists of 85 % of total protein of the *Stratum corneum* (Gartner et al., 2001). Keratinocytes synthesize different keratins in different stages of cytomorphosis. Whereas basal layer cells include only low molecular weight keratins, cells with high molecular weight keratin begin to build the heap structure of the *Stratum corneum* as the cells move upward. Keratins in this layer are cross-connected by disulphide bonds at the same time. The epidermis consists of five layers. These are, respectively, from the inside to out (Junquera et al., 1992).

*Stratum basale (germinativum)*: This layer consists of a single row of cylindrical cells sitting on the basal membrane, located on the dermis and basal lamina. This layer is responsible for continuous renewal of the epidermis due to the proliferation of cells. Cytoplasmic fibrillar protein is found in all cells that form the structure. As proliferating cells migrate towards the upper layer, the number of protein filaments increases.

*Stratum spinosum*: This is a multi-storey layer composed of polygonal or squamous epithelial cells. The cytoplasm and cytoplasmic extensions are filled with bundles of fibrils and connected to each other with bridges on the cell surface. These cells are called spino-cellular cells, due to the spine-like structures around this layer of cells. All the layers of both *Stratum basale* and *Stratum spinosum* are called the Malpighian layer.

*Stratum granulosum*: This layer consists of small, flat, polygonal-shaped cells. These cells contain keratohyalin granules. The number of lamellar structures emerging in the *Stratum spinosum* increases in the *Stratum granulosum*, their contents are secreted to intercellular spaces as accumulating in the periphery of the cell, providing intercellular lipids, which are essential for the barrier function of the epidermis.

*Stratum lucidum (Transparent layer)*: This layer is composed of flat, transparent, and tightly gathered cells ranging from 3 to 5 rows. It is a thin layer that is only found in regions where the epidermis is thick. The cytoplasm of the *transparent layer* is filled with a substance refracting light called eleidin and cell organelles decrease in this layer. As tonofibrils become more numerous and regular, they make the cell membrane thicker. Desmosomes are located between cells and the amount of intercellular materials increases.

*Stratum corneum*: It is a dead cell layer having no nucleus. Keratin is found in the cytoplasm of these cells. Intercellular gaps are full of lipids which are secreted from the lamellar structures in the *Stratum spinosum* and *Stratum granulosum*. Superficial cells of the *Stratum corneum* shed continuously (desquamation) and new tissue is produced by mitosis of cells in the germinal layer. Keratinization occurs with the formation of disulfide groups from sulphhydryl groups of protein fibrils during migration to the upper layer. These protein fibrils make reticulated bundles, forming a substantial long chain by disulfide bonds and also including a dense, amorphous matrix between them, composed of keratohyalin granules. At this stage, the cell membrane thickens. This layer, formed by the thickening of the cell membrane, takes the shape of cornified cells losing its core and other organelles after reaching of keratohyalin granules to maximum point and forming of keratin lipids (Gartner et al., 2001; Junquera et al., 1992).

## 2.2 Dermis

The dermis is a type of elastic, flexible bond tissue locating under epidermis and is vascularised, enabling it to provide energy and nutrition to the epidermis. The dermis extends limitlessly by integrating to the subcutaneous layer and its thickness varies according to the region (Leeson & Leeson, 1981). Its surface contacting the epidermis is rough and composed of papillae. Papillae are named *Stratum papillare* by integrating deep surface of the epidermis. Some papillae also contain special nerve endings, called vascular papillae (Young & Heath, 2000). The deepest part of dermis is called as *Stratum reticulare*. This layer consists of irregular, dense connective tissue and has rather weak cells, primarily fibroblasts and macrophages. Hair follicles are concentrated around sebaceous and sweat glands in the dermis (Leeson & Leeson, 1981).

## 2.3 Hypodermis

Hypodermis, the subcutaneous layer, is a loose connective tissue located under the dermis and containing varying amounts of fat cells. Collagen and elastic fibrils within its structure continue into the dermis. Hair roots also are found in this layer (Junquera et al., 1992; Leeson et al., 1988). The increase in the number of fibrils results in a rigid binding of dermis to hypodermis and thus affects the mobility of the skin.

## 3. Wounds and burns

### 3.1 Types of wounds

A wound is the disruption of the integrity of anatomical tissues caused by exposure to any factor. Wounds are examined under two groups:

*Closed Wounds:* This group includes contusion, hematoma and abrasion. Contusion-type injuries involve damage to soft tissues, small blood vessels and deep tissue layers, resulting in their separation, but the anatomy of the skin remains intact. Oedema, and in later periods, atrophy and defective pigmentation are observed in wound and the healing is delayed. Vessel rupture or hyperaemia due to vessel damage is called hematoma and wounds such as scrapes are termed abrasions. The healing process is very painful because this type of wound involves damage to sensory nerves and the wound can easily become infected (Mutsaers et al., 1997).

*Open Wounds:* This group includes lacerations, cutting-pricking tool wounds, gunshot wounds, surgical wounds, insect bites and stings, radionecrosis, vascular neurological and metabolic wounds. Wounds except for lacerations cause serious damage to tissues beneath the skin. In laceration type wounds, skin and subcutaneous tissue have been destroyed, but deep tissues remain healthy. The anatomical integrity of tissues is damaged in cutting-pricking tool wounds without any tissue damage at the edges of the wound (Aydın, 2000; Kapoor & Appleton, 2005).

Wounds are also classified according to tissue loss.

*Wounds with Tissue Loss:* These types of wounds involve damage or loss in some or all of the skin layers. Healing occurs *via* filling of the wound area by granulation tissue typically growing from the base of a wound. Wounds that involve tissue loss are collected in two groups in proportion to the loss. In superficial wounds, the entire epidermis and the papillar layer of the dermis are damaged. The epidermis, all the layers of the dermis and even

subcutaneous tissue are damaged in full-thickness wounds covering second group (Mutsaers et al., 1997; Porth, 1998; Chanson et al., 2005).

*Wounds without Tissue Loss:* These kinds of wounds occur as a result of tissue crushing. The severity of bleeding occurring in tissue varies according to the condition of the wound. Tissues exposed to this kind of wound heal after granulation tissue formation in minimal level in first phase of healing process (Ruszczak, 2003).

### 3.2 Types of burns

Burn is a kind of wound that occurs when skin or organs are damaged by an electrical current, heat, chemical or flammable agent effect. It is known that burn-initiated pathophysiological events differ from other traumas, may cause death risks and lead to increasing capillary permeability, resulting in hypovolemia. Burn causes changes of vascular permeability, extravasation of plasma proteins, aggregation of platelets and increased fibrinolysis (Yenerman, 1986; Madri, 1990; Atiyeh et al., 2005).

Burns are divided into 4 groups according to the depth and the affected skin layers:

#### 3.2.1 First-degree burns

Only the outer layer of the epidermis and *Stratum corneum* are damaged in this type of burn, and there is no damage in the dermis. First-degree burns generally occur as a result of short-term heat or flame contact or long-term exposing to intense sunlight. First-degree burn areas are characterised by slight oedema, which diminishes after 24 hours. At this stage the skin begins to dry, there is no vesicle and infection is not seen. The wound heals within a week (Whitney & Wickline, 2003).

#### 3.2.2 Second-degree burns

These types of burns are deeper than first-degree burns and necrosis spread into the dermis. Damage covers the entire epidermis and some part of dermis. The wound is clinically characterised by pain, erythema and bullae. The recovery rate depends on the depth of skin injury and formation of infection. Generally, second-degree burns heal spontaneously in a short period if infection does not occur. If infection occurs in the wound, it can easily convert to third degree burn.

The burns in this group may be divided into two categories, termed superficial and deep dermal second-degree burns (Sparkes, 1997; Whitney & Wickline, 2003):

*Superficial Second Degree Burns:* These occur due to short period contact with flame or hot liquids. Generally, the upper portion of the *Stratum germinativum* is damaged in superficial second-degree burns. The surface is generally humid because of the leakage of liquid plasma from the burned area. Generally, less scarring than the deep dermal burns occurs. Recovery usually occurs within 3-4 weeks with zero or very mild scarring (Madri, 1990).

*Deep Dermal Burns:* These occur due to contact with chemicals such as flame, hot liquids or acids, or exposure to high electrical current. In these types of burns, whereas the epidermis is completely burned, damage extends to the *Stratum germinativum* and the bottom section of the dermis. In deep dermal burns, fluid loss and metabolic effects are the same as in third-degree burns. Wound pain is very severe during burning and hyperanesthesia may occur in some areas. The wound may develop into a third-degree burn if infection occurs in the burn area. The time required for re-epithelialisation depends on degradation in the dermis, the amount of burnt hair follicles and sweat



glands, and the width of infected areas. If the wound is properly preserved, it usually closes within 2 months, leaving some scarring on the skin surface. Scarring and contracture occur in healing areas where closing lasts longer than 2 months. In this case, it is very difficult to distinguish the wound from third-degree burns and treatment of this kind of wound will last longer (Porth, 1998; Shakespeare, 2001).

### 3.2.3 Third-degree burn

These kinds of burns result from hot water, fire and prolonged contact with electrical current. The wound area exhibits tautness and brightness as the elasticity of the skin is lost, causing abnormal shrinkage. In such cases, all structures within the skin sustain damage. The dermis and subcutaneous fat are destroyed as a result of coagulation necrosis. Thrombosis occurs in vessels under the skin. Increased capillary permeability and oedema is much higher in third-degree burns than second-degree burns. Skin is damaged in all layers and is characterised by autolysis and leukocytoclastic infiltration for 2 or 3 weeks. This event is usually associated with suppuration. Capillary bundles and fibroblasts are organised in granulation tissue under scar. If the burn affects subcutaneous fat, healing can take much longer. Burn affecting the muscle causes increasing in degradation of red blood cells. The care of third-degree burns requires removing scar tissue and covering the wound with a graft. If grafting is not carried out, a thick layer of granulation is shaped and the contraction of the area follows it. At this stage, re-epithelialisation, slightly, occurs on the edge of wound granulation is soft, can be infected and healing continues over several months. Permanent deep scars in the skin occur following healing in these kinds of wounds and surgical intervention is usually required to restore normal appearance (Moulin et al., 2000; Shakespeare, 2001).

### 3.2.4 Fourth-degree burns

This refers to the carbonization of burned tissues.

## 4. Wound and burn treatment

### 4.1 Developments in the treatment of wounds and burns

A range of methods has been used to treat wounds, dating back to ancient times. The earliest information on wound treatment is found in Egyptian medical documents, called the Ebers Papyrus. It is known that ancient Egyptians treated wounds by covering them frog skin and castor oil. The results have been limited and partially misleading, although humans have used many materials of biological origin in wound and burn treatment throughout history and have conducted various experiments on animals. The first wide-ranging microscopic study was conducted by Hartwell in the 1930s. Hartwell compared human wounds to those in pigs, rabbits, dogs and guinea pigs and found that the wound healing progress is different in human epithelial and subepithelial surfaces, compared to those of animals. If the pathological table of wound healing is also taken into account, it was confirmed that pig physiopathology was most similar to humans, followed by that of rabbits. Later, Gangjee et al. (1985) conducted studies of percutaneous wound healing. Winter et al. (1965) developed animal models of wounds and burns using pigs as a subject for wound treatment and concluded that, as the histology of skin and the wound healing mechanism differs between animals and humans, animal models or experiments can only provide a general indication of wound healing phases.

Researchers subsequently sought new materials for use in wound healing, due to the disadvantages of traditional dressings such as gauze, paraffin gauze, biological dressings, etc. The first synthetic material used for wound coverage was methyl cellulose. The common feature of all these materials is the necessity of physical protection from external factors and conditions. Many new materials have been used as the wound healing mechanism has become better understood. The usage of artificial dressing materials in forms such as film, spray, foam and gel have increased significantly in recent years (Shakespeare & Shakespeare, 2002; Stashak et al., 2004; Merei, 2004)

The following characteristics are required for ideal wound and burn dressing (Sheridan & Tompkins, 1999; Balasubramani et al., 2001; Jones et al., 2002);

- ease of application
- bioadhesiveness to the wound surface
- sufficient water vapour permeability
- easily sterilised
- inhibition of bacterial invasion
- elasticity and high mechanical strength
- compatibility with topical therapeutic agents
- optimum oxygen permeability
- biodegradability
- non-toxic and non-antigenic properties

Average water loss from normal human skin is 250 g/m<sup>2</sup>/day. In wounded skin, this figure can reach up 5000 g/m<sup>2</sup>/day according to the type of wound. If a wound dressing material is thin and has extreme water vapour permeability, it causes accumulation of liquid, bacterial growing and delay in recovery (Alper et al., 1982; Fansler et al., 1995). Wound coverings should be adequately adhesive to the wound surface and edges. At the end of treatment, cover material should also permit removal in such a manner that it does not harm any tissues, must not cause toxic or antigenic reactions, and must be biocompatible. The materials used should not cause contamination of microorganisms on the wound surface and, if possible, it should also prevent the proliferation of bacteria in normal skin flora. Wound dressing materials should be easy to apply and have sufficient elasticity and mechanical strength to be used in areas especially close to the joints. The surface of the dressing material that is in contact with the wound should support the development of fibrovascular tissue as creating a convenient platform for wound healing. Adequate oxygenation is important in wound healing, so dressing material should provide contact the wound with oxygen. In addition, major desirable characteristics are that wound dressing materials should be easily sterilised, have a long shelf-life, and be cost-effective (Quinn et al., 1985; Lloyd et al., 1998; Stashak et al., 2004).

#### **4.2 Classification of dressings used in wound and burn treatment**

Materials used to cover wounds and burns are also called artificial skin, as they fulfil the functions of normal skin within areas with wounds and partly destroyed skin.

Wound and burn covering materials are classified as follows (Freyman et al., 2001; Stashak et al., 2004);

1. Traditional dressing
2. Biomaterial-based dressings
3. Artificial dressings

#### 4.2.1 Traditional dressing

These are still the most commonly used materials for wound and burn dressings (Balasubramani et al, 2001). The traditional dressings, which are generally used during first intervention in wound treatment, prevent wound's contact with outer environment and bleeding (Sheridan & Tompkins, 1999; Stashak et al., 2004). The best sample of this group is gauze and gauze-cotton composites which have very high absorption capacity. As they cause rapid dehydration whereas they are being removed from the wound surface, they can cause bleeding and damage of newly formed epithelium (Naimer & Chemla, 2000; Stashak et al, 2004). Therefore, gauze composites with a non-adhesive inner surface are prepared to reduce the pain and trauma which can occur when removing traditional wound dressings from the wound surface.

Traditional wound dressings in the world market are shown in Table 1.

Dressing material	Brand name	Manufacturer
Paraffin gauze dressing containing 0.5% chlorhexidine acetate	Bactigras	Smith & Nephew
Paraffin gauze dressing	Jelonet	Smith & Nephew
Petrolatum gauze	Xeroform	Chesebrough-Pond's Inc.
Petrolatum gauze containing 3% bismuth tribromophenate	Xeroform	Chesebrough-Pond's Inc.
Scarlet Red dressing	Scarlet Red	Chesebrough-Pond's Inc.
Sterile hydrogel dressing	2nd skin®	Spenco
Highly absorbent cotton wool pad	Gamgee® pad	3M
Highly absorbent rayon/cellulose blend sandwiched with a layer of anti-shear high density polyethylene	Exu Dry Dressing	Smith & Nephew
Absorbent cotton pad	Telfa "Ouchless" Nonadherent Dressings	Kendall (Covidien)

Table 1. Traditional wound dressings in the world market.

Exudate leaking from traditional dressing materials usually increases the risk of infection and is one of the most significant problems of these type dressings. Antibacterial agents are added into the dressings to eliminate the infection. In addition, one of the most significant problems encountered in this material is foreign body reaction in the wound caused by cotton fibres. The biggest advantage of these materials is their low cost (Lim et al., 2000; Price et al., 2001; Stashak et al., 2004).

#### 4.2.2 Biomaterial-based dressings

The most convenient method used in complete closure of wounds and burns is autografting. However, inadequate donor areas for large wounds led to the search for a new tissue source (Sheridon et al., 2001). Biological dressings are natural dressings with collagen-type structures, generally including elastin and lipid.

Such dressings can mainly be categorised under the following groups (Sheridon et al., 2001; Kearney, 2001).



1. Allografts
2. Tissue derivatives
3. Xenografts

Some biomaterial-based dressings, which were used for the treatment of wounds and burns, is shown in Table 2.

Type of dressing	Dressing material	Brand name	References/ Manufacturer
Allograft	Scalp tissue	-----	Barnett et al. (1983)
	Amniotic membrane	-----	Peters and Wirth (2003)
Xenograft	Porcine tissue	Mediskin	Genetic Lab.
	Silver impregnated porcine tissue	E-Z derm	Genetic Lab.
Skin derivatives	Highly purified bovine collagen	-----	Chvapil et al. (1973)
	Formaline fixed skin	-----	Chvapil et al. (1973)

Table 2. Biomaterial-based dressings.

### Allografts

The most common source for this type of dressing is fresh or freeze-dried skin fragments taken from the patient's relatives or cadavers. Immune reaction as a result of the use of allograft can be seen and the body may reject the tissue. Infection risk also increases with suppression of the immune system to prevent the body's rejection of transplanted tissue.

The other disadvantages of these dressings include the difficulty of preparation, lack of donors, high cost and limited shelf life (Nanchahal et al., 2002; Ruszczak, 2003).

Amniotic membrane, which is separated from chorion, generally uses in superficial partial thickness burns as a dressing material for many years (Ravishanker et al., 2003). Though it has advantages such as ease of preparation and use, it has disadvantages like causing cross-infection and dehydration of the wound (Freyman et al., 2001; Jones et al., 2002). Amniotic membrane derived from a healthy donor is shown in Figure 1.

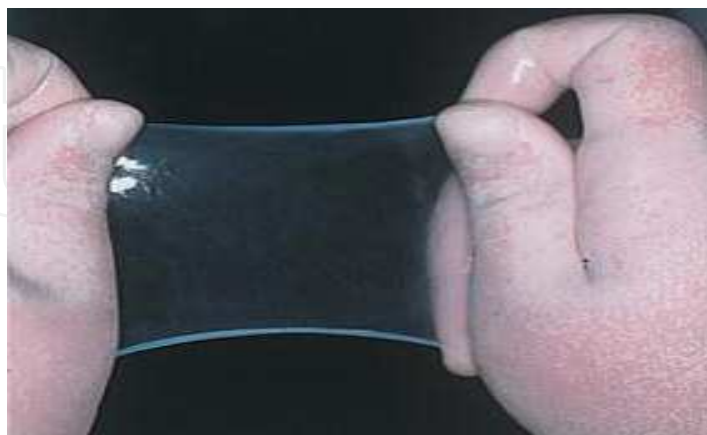

Fig. 1. The cryo-preserved amniotic membrane was thawed prior to its application (Hasegawa et al., 2007).

The effectiveness of amniotic membranes as dressing materials in burn treatment is summarized in Table 3.

Dressing quality	Amniotic membrane
Pain relief	+++
Infection prevention	+++
Good adherence to wound bed	+++
Promotion of re-epithelialisation	+++
Cost factor	++
Moist wound healing environment	++
Elasticity/conformability	+++
Easy application	++
Prevention of heat loss	+
Availability	++

+++ , very good; ++ , average; + , below average

Table 3. Qualities of an ideal dressing for partial-thickness burns (Branski et al., 2008).

*In vitro* epidermal cell cultures are new and currently expensive systems used to prepare dressing materials. These can be applied in the form of autologous or homologous epithelial cell cultures and are still at the development stage (Beckenstein et al., 2004; Manwaring et al., 2004).

#### Xenografts

Xenografts are commercially available materials contrary to autografts and allografts. The most common of xenografts is the ones derived from pig skin (Sheridan et al., 2001) which have a long shelf-life and can be sterilized easily (Sheridan & Tompkins, 1999). Although pig skin is not microscopically similar to human skin, it shows close similarity in terms of adhesion and collagen content. Its disadvantage is the risk of triggering an immune response due to the foreign tissue.

#### Tissue derivatives

These materials, derived from different forms of collagen, have the advantages like ease of preparation, low contamination risk and weak antigenic features. The greatest disadvantage of these materials is the risk of infection, particularly in long term usage (Jones et al., 2002; Stashak et al., 2004).

#### 4.2.3 Artificial dressings

The usage of traditional dressing materials and biomaterial-based dressings is restricted due to factors such as their stability problems and risk of infection. These conditions brought up the use of wound and burn dressing materials being cheaper and more effective, and having long shelf-life. Many dressing materials have ideal features for the treatment of wounds and burns; however, due to the variations between pathophysiology of the wound and burn, it is difficult to develop an artificial dressing material that meets all the criteria for optimum healing. Much research is currently being undertaken studies to develop wound dressing materials that can provide optimum healing conditions, taking into account all of these factors and healing mechanisms (inflammation, tissue replacement, fibrosis, coagulation, etc.) (Still et al., 2003; Stashak et al., 2004).

Some of artificial wound and burn dressing materials in world market are shown in Table 4.

Type	Dressing material	Brand name	Company
Film/membrane	Polyurethane	Omiderm	Omicron Scientific
		Opsite	Smith & Nephew
		Bioclusive	Johnson & Johnson
		Tegaderm	3M
	Polyvinyl chloride	Strech Neal	Colgate
	Nylon velour	Capran77C	Allied Chemical Corp.
	Polyvinylidene chloride	Saran Wrap	Asahi Kasei
	Polyurethane hydrocolloid	Granuflex	ConvaTec
	Synthetic fibre + aluminium	Aluderm	Söhnngen
	Synthetic fibre + metal	Scanpore tape	Norgeplaster
Foam	Activated charcoal	Carbopad	Charcoal
	Formalinized polyvinyl alcohol	Ivalon	Chardack
	Polyurethane	Lyof foam	Ultra Labs
	Poly(dimethylsiloxane)	Silastic	Dow Corning
Gel	Calcium alginate	Kaltostat	ConvaTec
	Polyurethane with grafted acrylamide and hydroxyethylmethacrylate	Omiderm	Omicron Scientific
Composite	Polypropylene film and polyurethane foam	Epigard	Parke-Davis
	Silicone film with a nylon fabric	Biobrane	Smith & Nephew
Spray	Methacrylic acid ethoxyethyl ester	Nobecutane	Astra Zeneca
	Polyhydroxyethylmethacrylate and polyethylene glycol 400	Hydron	Hydron Lab.

Table 4. Artificial wound and burn dressings in world market.

#### 4.2.3.1 Polymers used for artificial dressings

Many natural and synthetic polymers are being used in the preparation of artificial dressing materials.

The most widely used of these includes:

##### a. Natural polymers

##### Collagen

Collagen is a biodegradable and biocompatible protein mostly found in connective tissue. The first medical usage of collagen in humans was reported by Knapp et al. (1977) and was used to provide co-reaction of contour deformities. Bovine collagen was used as suture and hemostatic agents after years. In 1980, Zyderm 1 was released, a suspension form containing sterilised fibrillar bovine collagen that was used for injecting under the dermis in wounds. Today, collagen is used in numerous biomedical applications (Hafemann et al., 1999; Ortega & Milner, 2000). These include collagen suspensions for dermal injection, topical haemostatic agents, wound dressing materials, collagen suture and catguts, collagen gels for periodontal reconstruction, collagen sponges for the hemostasis and coating of joint, and collagen rich pig skin wound dressing materials (Gingras et al., 2003; Park et al., 2004).

### **Alginic acid and its salts**

Alginic acid, is a natural polysaccharide derived from brown algae such as *Laminaria* and *Ascophyllum* species. Alginic acid are formed by linear block copolymerization of D-mannuronic acid and L-guluronic acid. Alginic acid and its salts are used for the treatment of wound and burn due to their haemostatic properties. Their first applications were in the form of a gel, but sponges produced from calcium alginate are also used effectively in the treatment of wounds. It is also indicated that calcium alginate increases cellular activity properties such as adhesion and proliferation (Thomas, 2000a, 2000b and 2000c).

### **Hyaluronic acid and its derivatives**

Hyaluronic acid is a natural biopolymer that alternately consists of D-glucuronic acid and 2-acetamido-2-deoxy-D-glucose and is generally found in mammal's bond tissues and synovial fluids (Saliba, 2001; Kirker et al., 2002). It has been reported that hyaluronic acid interacts with proteins, proteoglycans, growth factors and tissue components called biomolecules which has vital importance in healing of various types of wounds (Park et al., 2003). This interaction plays an important role in acceleration of tissue repair and wound healing. Hyaluronic acid and its derivatives also play a role in the protection of the injured area against microorganisms due to their bacteriostatic activity (Miller et al., 2003; Lobmann et al., 2003).

### **Chitosan**

Chitosan, which is produced by deacetylation of kitin, is a linear polysaccharide composed of randomly distributed  $\beta$ -(1-4)-linked D-glucosamine (deacetylated unit) and N-acetyl-D-glucosamine (acetylated unit) (Muzzarelli & Muzzarelli, 2002; Krajewska, 2004). Chitosan is used in the treatment of wounds and burns due to its haemostatic effect (Ueno et al., 1999; Khor & Lim, 2003; Şenel & McClure, 2004). It is thought that chitosan accelerates the formation of fibroblasts and increases early phase reactions related to healing (Paul & Sharma, 2004). Chitosan can be prepared in a variety of forms, namely films, hydrogels, fibres, powders and micro-/nanoparticles. Applications of this biopolymer in commercial and biomedical fields have increased due to the low toxicity of chitosan and its biodegradation products, and its biocompatibility with blood and tissues (Berthold et al., 1994; Cho et al., 1999; Tan et al., 2001; Ishihara et al., 2002; Kim et al., 2002; Mi et al., 2002).

### **Fucoidan**

Fucoidan is a sulphated polyfucose polysaccharide and has attracted considerable biotechnological research interest since the discovery that it possessed anti-coagulant activity similar to that of heparin and also reported to possess other properties including anti-thrombotic, anti-inflammatory, anti-tumoral and anti-viral effects (Patankar et al., 1993). Many of these effects are thought to be due to its interaction with growth factors such as basic fibroblast growth factor (bFGF) and transforming growth factor- $\beta$  (TGF- $\beta$ ). Fucoidan may, therefore, be able to modulate growth factor-dependent pathways in the cell biology of tissue repair (O'Leary et al., 2004). In recent years, the research on drug and gene delivery systems, diagnostic microparticles and wound and burn healing formulations of fucoidan has been increasing in course of time (Sezer et al., 2008a and 2008b, Sezer & Akbuğa, 2009).

### **Poly-N-acetyl glucosamine**

Poly-N-acetyl glucosamine which is produced from marine microalgae, has hemostatic activity and are used as a support material in the treatment of burns and wounds (Pietramaggiori et al., 2008).

## **b. Synthetic polymers**

### **Polyurethanes and their derivatives**

Polyurethanes are copolymers containing urethane groups in their structures. In general, they are formed by conjugation of diol groups and diisocyanate groups with polymerisation reaction (Trumble et al., 2002). A large number of non-toxic polyurethanes are synthesized for use in biomedical applications. One of these, Pellethane 2363-80A which accelerates re-epithelialisation was used as dressing material in the treatment of burn and wound (Wright et al., 1998; Pachulski et al., 2002).

### **Teflon**

Teflon is a polymer that is synthesized by polymerization of tetrafluoroethylene at high temperature and pressure. Teflon is an inert material which is non-carcinogenic, insoluble in polar and nonpolar solvents, and which can be sterilized. It can take the desired shape by application of low-pressure and can easily be applied to the injured area (Raphael et al., 1999; Lee & Worthington, 1999).

### **Proplast**

Proplast which is the first synthetic biomaterial, specially developed for implant applications. It is among the particularly preferred materials in wound, burn and surgical applications due to its high biocompatibility with tissue (Şenyuva et al., 1997).

### **Methyl methacrylate**

Methyl methacrylate is a non-biodegradable synthetic polymer that is resistant to heat and UV. It is used as a dressing and supporting material in plastic surgery and the treatment of injuries (Nakabayashi, 2003).

### **Silicon**

Silicon is used extensively for biomedical purposes. It has low toxicity, low allergic properties and high biocompatibility in the body (O'Donovan et al., 1999; Jansson & Tengvall, 2001). This polymer, which is resistant to biodegradation, is used in the preparation of implant elastomers used in soft tissue repair and in the production of hypodermic needles and syringes (Van den Kerckhove et al., 2001; Park et al., 2002). In addition, silicon is also often used as wound support material in severe wounds and burns due to its high tissue compatibility (Whelan, 2002; Losi et al., 2004).

## **4.3 Pharmaceutical formulations used as dressings for wounds and burns**

Many pharmaceutical formulations have been recently developed as synthetic dressing material for wound and burn treatment.

### **4.3.1 Films/membranes**

These pharmaceutical dosage forms, which are available in thickness ranging from  $\mu\text{m}$  to mm, are prepared by different methods using one or more polymers. Films are ideal dressing materials and available in commercial. Films/membranes with a homogeneous polymeric network structure are used to treat the damaged area and generally protect the wound and burn area against external factors (Verma & Iyer, 2000; Stashak et al., 2004). The polymers used in the preparation of films include; polyurethane, polyvinylpyrrolidone (Yoo



& Kim, 2008), hyaluronic acid (Xu et al., 2007; Uppal et al., 2011), collagen (Boa et al., 2008), sodium alginate (Kim et al., 2008a and 2008b) chitosan and its derivatives (Tanigawa et al., 2008), poly-N-acetyl glucosamine (Pietramaggiore et al., 2008) and fucoidan (Sezer et al., 2007). In a clinical study, as a result of *in vitro* studies of polyurethane / poly (N-vinylpyrrolidone) composite film combinations, it was reported that their water absorption capacity was high and water vapour permeability was between 1816-2728 g /m<sup>2</sup> /day. It was seen that recovery in the injured area was significantly increased and a new epithelial tissue was formed in 15 day period following application of these prepared formulations to full-thickness wounds induced in a rat model (Yoo & Kim, 2008). Tanigawa et al. (2008) prepared scaffold formulations by using chitosan citrate and chitosan acetate, which are natural polymers, and examined the effectiveness of the formulations on wound healing in mice with damaged epidermis. The scaffold, prepared by a lyophilisation method, gave quite a distinct pore structure especially inside it, depending on the type of the acid used for the preparation of chitosan solution; the pore consisted of fibrous networks appeared in chitosan citrate, whereas the pore surround by cell walls occurred in chitosan acetate. Despite the large difference in the pore structure, both scaffolds were effective in regeneration of the outer skin. However, chitosan citrate scaffold provided better facilitation in wound healing than the chitosan acetate one (Tanigawa et al., 2008). Commercially available collagen-based film formulations also used in the treatment of dermal burns (Boa et al., 2008). In a recent study, the treatment efficacy of collagen-based films was investigated in second-degree burns created in 45 Wistar rats. The prepared collagen film formulations were applied to the wound alone or in combination with liposome formulations containing usnic acid, and then examined after 14 and 21 days. The use of the usnic acid provided more rapid substitution of type-III for type-I collagen on the 14th day, and improved the collagenisation density on the 21st day. It was concluded that the use of reconstituted bovine type-I collagen-based films containing usnic acid improved burn healing process (Nunes et al., 2011). Differences in healing of wounds are summarized in histological sections in Figure 2.

In another study, the researchers hypothesized that a poly-N-acetyl glucosamine (pGlcNAc) fibre patch might enhance wound healing in diabetic (db/db) mice. Wounds dressed with pGlcNAc patches for 1 h closed faster than control wounds, reaching 90% closure in 16.6 days, 9 days faster than untreated wounds. Granulation tissue showed higher levels of proliferation and vascularization after 1 h treatment than the 24 h and left-untreated groups. Foreign body reaction to the material was not noted in applications up to 24 h (Pietramaggiore et al., 2008).

The primary negative factor affecting healing of burns and wounds is the loss of skin integrity. It is indicated in the literature that wound and burn healing occur much more quickly with the help of a dressing material (Mutsaers et al., 1997; Kapoor & Appleton, 2005). Therefore, in recent years, the use of biopolymers has gained priority in tissue engineering and biotechnology, both as dressing material and in terms of enhancing treatment efficiency (Atiyeh et al., 2005).

A biopolymer, fucoidan, consisting of fucose and sulphate groups has been used for the treatment of burns and wounds (Sezer et al., 2007, 2008a and 2008b). It was reported that fucoidan shows anticoagulant effect and heparin activity (Sezer & Cevher 2011). It was also reported that films prepared with fucoidan do not prevent contact of the wound surface with air oxygen, provide the moisture balance in wound/burn area, accelerate the migration of fibroblasts and provide re-epithelialisation (Sezer et al., 2007) (Table 5).

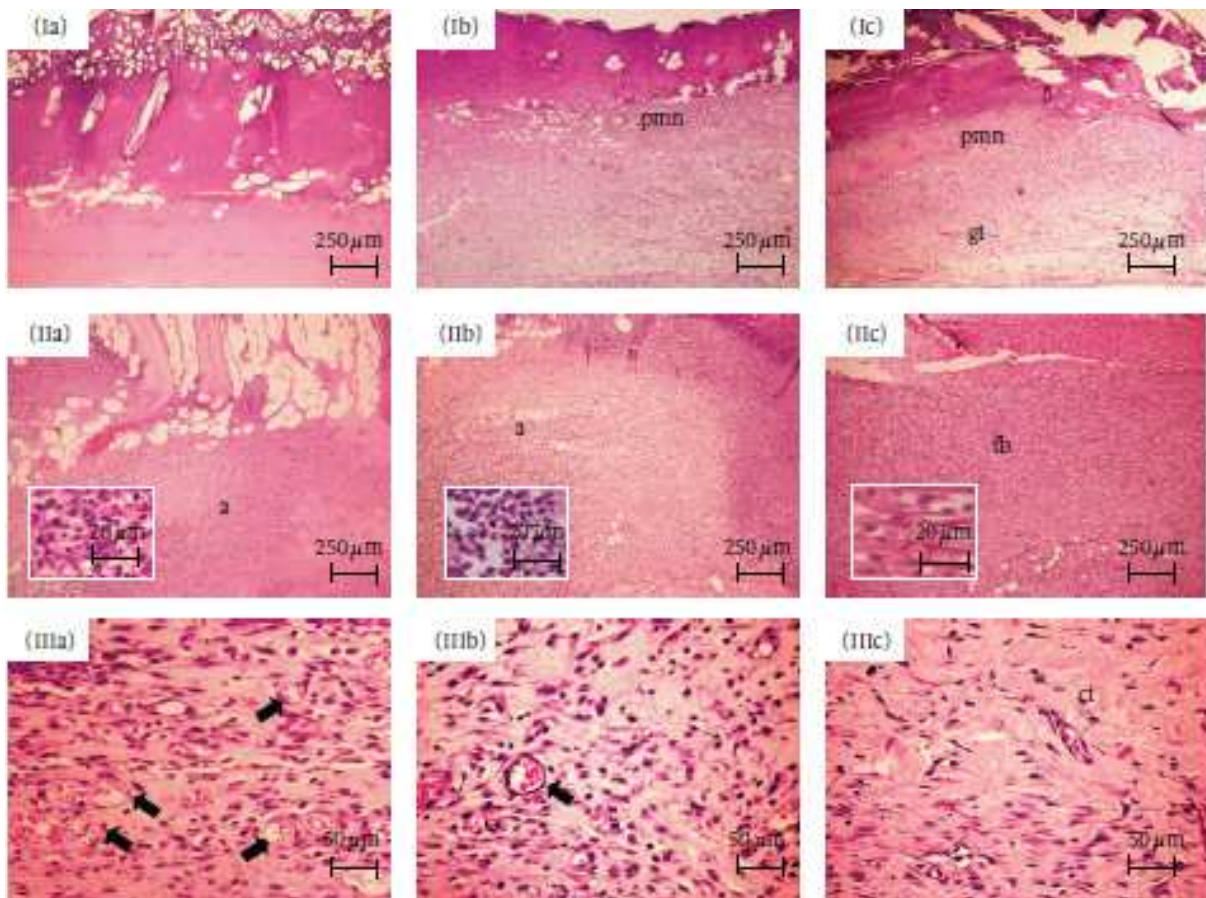


Fig. 2. Histological sections stained in hematoxylin-eosin. Seven days: (Ia) Lack of inflammatory response in the center of the burned area in COL. (Ib) Inflammatory infiltrate rich in polymorphonuclear neutrophils (pnm) in PHO. (Ic) Expressive content of polymorphonuclear neutrophils (pnm) in the top of the wound, and early granulation tissue (gt) formation in the bottom, in UAL. Fourteen days: (IIa and IIb) Intense acute inflammatory reaction (a) scattered within the burned area in COL and PHO, respectively. Neutrophils seen in detail. (IIc) Moderate infiltrate of neutrophils and lymphocytes in association to expressive fibroblastic proliferation (fb) in UAL. Fibroblasts seen in detail. Twentyone days: (IIIa and IIIb) Vascular component (arrows), and chronic inflammatory infiltrate, still evident in COL and PHO, respectively. (IIIc) Scanty inflammatory cells are seen within the cicatricial tissue (ct) in UAL. \*COL – animals treated with collagen-based films; PHO – animals treated with collagen films containing empty liposomes; UAL – animals treated with collagen-based films containing usnic acid incorporated into liposomes (Nunes et al., 2011).

Codes	Day 7				Day 14				Day 21			
	Fibroblast	Collagen	MN	PMNL	Fibroblast	Collagen	MN	PMNL	Fibroblast	Collagen	MN	PMNL
Control	+	—	—	+	+	—	—	+	+	+	+	+
	(6/6)	(5/6)	(5/6)	(2/6)	(4/6)	(4/6)	(4/6)	(3/6)	(4/6)	(3/6)	(6/6)	(5/6)
		(1/6)	(1/6)	(2/6)	(2/6)	(2/6)	(2/6)	(2/6)	(1/6)	(3/6)		(1/6)
				(2/6)				(1/6)	(1/6)			
FS	++	—	—	—	+	+	—	—	+	+	—	—
	(6/6)	(1/6)	(5/6)	(2/6)	(1/6)	(3/6)	(2/6)	(4/6)	(6/6)	(4/6)	(4/6)	(4/6)
		(5/6)	(1/6)	(4/6)	(5/6)	(3/6)	(4/6)	(2/6)		(2/6)	(2/6)	(2/6)
CF	+	—	—	+	+	+	—	+	+	+	—	—
	(6/6)	(4/6)	(5/6)	(4/6)	(4/6)	(6/6)	(4/6)	(4/6)	(5/6)	(4/6)	(2/6)	(3/6)
		(2/6)	(1/6)	(2/6)	(2/6)		(2/6)	(2/6)	(1/6)	(2/6)	(3/6)	(3/6)
											(1/6)	
CFE	+	+	—	+	+	++	+	—	—	—	—	—
	(6/6)	(6/6)	(3/6)	(3/6)	(1/6)	(4/6)	(3/6)	(6/6)	(4/6)	(5/6)	(6/6)	(6/6)
			(2/6)	(3/6)	(1/6)	(2/6)	(2/6)		(2/6)	(1/6)		
			(1/6)		(4/6)		(1/6)					

\*MN indicates mononuclear leukocyte; PMNL, polymorphonuclear leukocyte; —, absent; +, mild; ++, moderate; +++, severe; FS, fucoidan solution; CF, chitosan film without fucoidan; and CFE, chitosan film containing fucoidan.

Table 5. The score of the wound cells and collagen (Sezer et al., 2007).

#### 4.3.2 Gels

Gels are viscous semi-solid preparations formed by dispersion of inorganic or organic substances that have larger size than colloidal particles in a liquid phase. Hydrogels are semi-solid systems, formed by a combination of one or more hydrophilic polymer. They are among the dressing materials frequently used in the treatment of wounds and burns. As they are capable of absorbing much more water than their weight, they act as dressing, reducing potential irritation when in contact with tissue and other similar structures. They keep moisture at the application site and permit oxygen penetration (Hoffman, 2002; Jeong et al., 2002). Hydrogels have many advantages including patient compliance, treatment efficacy and ease of application. The advantages of hydrogels in wound and burn treatment can be listed as follows (Kumar et al., 2001; Hoffman, 2002; Jeong et al., 2002; Byrne et al., 2002);

- Bioadhesion of gels to the surface of the wound is high and this also eases the treatment due to increased contact with the wound
- Their structures facilitate the moisture and water vapour permeability necessary to heal the wound area
- Difficulties that are particularly related to the application to open wounds are not seen in these preparations
- They can easily be removed from the application site when adverse events seen

Natural polymers are generally preferred in the preparation of hydrogels. Hyaluronan is a biopolymer widely used in the treatment of wounds. It is non-toxic, non-immunogenic, and has very good resorption characteristics in biomedical applications, which allow this biopolymer to be used in the treatment of wounds. In a study, cross-linked glycol chitosan/hyaluronan hydrogels was prepared and found that they displayed the characteristics required of an ideal wound dressing material (Wang, 2006). Chitosan is obtained by partial deacetylation of the amines of chitin. Its use has been explored in various biomaterial and medical applications. Chitosan has desirable qualities, such as hemostasis, wound healing, bacteriostatic, biocompatibility, and biodegradability properties. Chitosan appears to have no adverse effects after implantation in tissues and, for this reason, it has been used for a wide range of biomedical applications. Chitosan was also used to inhibit fibroplasia in wound healing and to promote tissue growth and differentiation in culture (Alsarra, 2009).



The efficacy of chitosans with different molecular weights and deacetylation degrees was investigated in the treatment of wounds (Sezer, 2011). The treatment efficacy of gels prepared with chitosans with low, medium and high molecular weight was examined in a rat full-thickness wound model in which the epidermis and dermis had been damaged. Chitosan gel formulations were also compared with Fucidin® ointment containing fusidic acid. Chitosan was found to promote the migration of the inflammatory cells which are capable of the production and secretion of a large repertoire of pro-inflammatory products and growth factors at a very early phase of healing. Fucidin® ointment-treated rats revealed a site that was not completely healed but more improved and with a smaller lesion than that of untreated groups. In comparison with high molecular weight chitosan-treated wounds (after 12 days), the wound site was so perfectly healed that it was difficult to distinguish it from normal skin (Figure 3) (Alsarra, 2009).

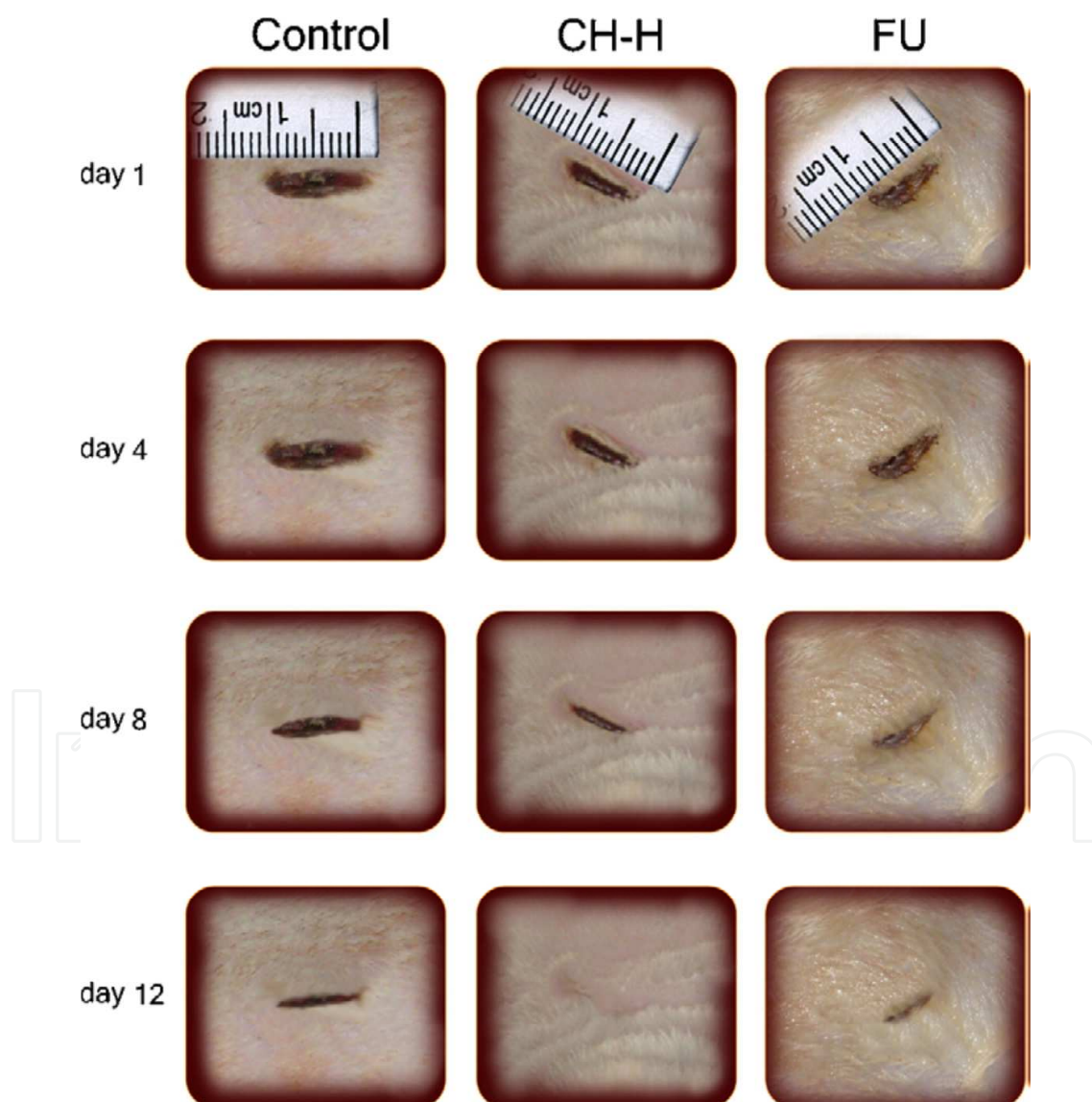


Fig. 3. Photographs of macroscopic appearances of wound excised from rats that were untreated (control), treated with high molecular weight chitosan (CH-H), or treated with Fucidin® ointment (FU) (Alsarra, 2009).

The efficacy of chitosan gel formulations containing silver sulfadiazine in the treatment of burn was examined. Due to its pseudoplastic characteristic and high bioadhesiveness, the chitosan gels with and without silver sulfadiazine showed a satisfactory retention time over the wounds. Wounds treated with chitosan gel with silver sulfadiazine showed a higher fibroblast production and a better angiogenesis than that of commercially available silver sulfadiazine cream, which are important parameters on the evolution of the healing process (Nascimento et al., 2009).

Polyvinyl alcohol hydrogels with different combinations, prepared with chitosan and dextran, are also used as wound dressing material. It was recorded that these cross-linked hydrogels are capable of ideal water absorption and swelling and provide an ideal moist environment necessary for wound healing. In addition, it has been reported in the literature that cross-linking of polyvinyl alcohol with dextran and chitosan increases the flexibility and elasticity of the gel (Sung et al., 2010; Hwang et al., 2010).

In another study, the novel thermoreversible wound gel formulation containing Polyhexadine showed good results for wound treatment and represented an alternative to silver sulfadiazine cream and iodine-based ointment, which are toxic and associated with many allergic reactions. The open randomized controlled single-center study was carried out on 44 patients in 2 parallel groups (Traumasept®wound covering gel vs. Flammazine®). The transparency of the thermosensitive gel formulation and absence of staining allowed for good wound assessment, without the need for painful cleaning, and the change from the fluid to the gel state enabled easy handling and filling the wound cavities (Goertz et al., 2010).

One of the most important parameters of the injured tissue pathology is to stop the bleeding and to protect the area with a protective support material in the first step. It is reported that hydrogels prepared using oxidised dextran and allylamine hydrochloride decreased coagulation and increased cloth strength and consequently are able to decrease the haemorrhage in clinical use (Peng & Shek, 2009).

The use of various proteins in topical wound treatment is also recorded in the literature (Ji et al., 2009). Wound treatment efficacy of methylcellulose gel dressings including recombinant human vascular endothelial growth factor (rhVEGF) have been examined by Ji et al. (2009). The dressings being studied were Adaptic®, Non-stick Dressing, Conformant 2®, Opsite®™ and Tegapore™. The criteria to select a compatible dressing include protein stability, absence of leachables from the dressing, and ability to retain gel on wound. Results showed that rhVEGF was significantly oxidized by Adaptic dressing in 24 h. Protein oxidation was likely due to the peroxides, as determined by ferrous oxidation with xylenol orange (FOX) assay, released into the protein solution from the dressing. In conclusion, Tegapore™ was considered suitable for the rhVEGF topical gel (Ji et al., 2009).

A similar study determined the gel properties of sodium carboxymethyl cellulose and fusidic acid and aimed to improve them as wound dressings. It was reported that swelling, flexibility and elasticity properties of sodium carboxymethyl cellulose (Na-CMC) gels was changed depending on sodium fucidate and the cross linker (PVA) content in the formulation. Hydrogel formulation containing 2.5% PVA, 1.125% Na-CMC and 0.2% sodium fucidate adsorbed exudate from the wound surface adequately and kept the moisture sufficiently in wound area and consequently, it was recommended as an ideal wound dressing material. (Lim et al., 2010).



Hydroxyapatite (HA) and silk fibroin (SF) composites are biomaterials used in wound treatment. It was reported that the polarized HA (pHA) transforms the SF structure into a porous three-dimensional scaffold. SF gel containing pHA was found to be higher promotive effects on wound healing, re-epithelialisation and matrix formation (Okabayashi et al., 2009).

Gelatine is commonly used in the treatment of wounds and burns, and acts as supportive tissue when used in the treatment of dermal burns with various biopolymers. Balakrishnan et al. (2005) applied hydrogel formulations containing oxidised alginate and gelatine to the 1 cm<sup>2</sup> full-thickness skin wounds created in rat model and the results evaluated histologically. At 15th day, test wounds appeared reduced in size with new epithelium noted at both the edges of the defect with the proliferation of basal layer and formation of the rete pegs. New collagen formed in the dermis appeared mature. Granulation tissue was seen in dermis. Granulation tissue formation is essential for permanent wound closure, since it fills the defects and prepares the way for re-epithelialisation. These findings support that alginate/gelatin hydrogel is able to provide suitable condition for granulation tissue formation. At 15th day, in test wounds, the defect area became smaller and filled with fibro-proliferative tissue. Inflammatory cells were absent. However, for some control wounds though the entire surface of the defect was covered with new epithelium, moderate number of inflammatory cells, predominantly lymphocytes and macrophages, were still present in the upper dermis. Though superficially neither control nor test wounds showed any reduction in defect area at 5th day, on measuring the wound re-epithelialisation it was found that both wounds have started healing (Balakrishnan et al., 2005).

In a previous study has shown successful treatment with fucoidan-chitosan hydrogels which were tested in New Zealand rabbits with second degree burn (Sezer et al., 2008a). In another study, chitin/chitosan, fucoidan and alginate hydrogel blends were prepared and the granulation tissue and capillary formation were found to be increased in the first 7 days of the treatment of induced wounds (Murakami et al., 2010).

#### 4.3.3 Sprays and foams

Sprays are pharmaceutical forms containing the solvent and polymer, forming a film layer on the surface of the wound when sprayed. The best example of a spray-based artificial wound and burn dressing is Hydron. It is prepared with polyhydroxyethyl methacrylate powder and liquid polyethylene glycol. When it is sprayed on the surface of the wound, it creates a thin and transparent film layer. In studies it was found that sprays reduce the pain of the wound, but have disadvantages including loss of integrity of the dressing and accumulation of sub-membrane fluid. Researchers stated that Hydron provides an effective treatment when applied to small partial thickness wounds and to areas which are away from joints (Dressler et al., 1980; Pruitt & Levine, 1984). Another example of aerosol sprays is papain-pectin sprays. The spray-on topical wound debrider composition consisting of 0.1% papain immobilized in 6% pectin gel was formulated for skin wound healing. The stability of the enzyme activity of this new formulated spray was compared with the 0.1% papain in water solution at the refrigerated temperature of 4°C. and 75°C. Prepared formulations were tested on experimental wounds created on rabbits. In the study groups treated by pectin-papain aerosol spray compared with a control group.

During the experiment, no obvious healing process inhibition or side effects were visually observed. Upon spray application on the surgical wound, the aerosol formed a thin, smooth, and even film staying in place on the wound bed without dripping, promoting wound healing after drying versus an untreated wound (as control). The spray bottle was easy to maneuver; making it possible to reach areas of each wound that otherwise might receive inadequate coverage. The progress of healing was overall higher with the spray at 2 times more in the first four days of treatment. The difference was calculated to be significant based on the Student's t-test method with the resulting  $p < 0.05$ . It was concluded that papain immobilized in pectin can be used for the development of effective aerosol spray system for wound healing in the areas of enzymatic debridement of necrotic tissue and liquefaction of slough to remove dead or contaminated tissue in acute and chronic lesions, such as diabetic ulcers, pressure ulcers, varicose ulcers, and traumatic infected wounds, postoperative wounds, burns, carbuncles, and pilonidal cyst wounds (Jáuregui et al., 2009).

Lyof foam, polyurethane foam, is normally hydrophobic; however, when applying heat and pressure, it becomes hydrophilic and, in this form, while providing blood and exudates absorption, it also prevents drying the wound surface completely (Johnson et al., 1998; Catarino et al., 2000; Fenn & Butler, 2001; Lehnert & Jhala, 2005).

#### 4.3.4 Composites

Composites developed for wound treatment may involve an elastic outer layer with high mechanical strength, which is resistant to the effects of the environment and provides moisture by preventing evaporation; in contrast, the inner layer provides adhesion of the composite to the surface of the wound. Telfa™ is a dressing material, including cotton, covered by polyester film and is used both for providing absorption and preventing dehydration of the wound surface (Kickhöfen et al., 1986). Clinical studies have been conducted of chitin nanofibrils/chitosan glycolate composites (Muzzarelli et al., 2007), salmon milt DNA/salmon collagen composites (Shen et al., 2008), polymer-xerogel composites (Costache et al., 2010), and autologous cellular gel matrix systems (Weinstein-Oppenheimer et al., 2010). Chitin and chitosan composites were found to be very promising in the treatment of wounds. Muzzarelli et al. (2007) tested the wound treatment activity of spray, gel and gauze forms of nanofibrils chitin/chitosan glycolate composites on both Wistar male rats and 75 patients between the ages of 45-70. Recovery was particularly good when applied gauze to gangrenous tissue (Figure 4).

It was shown that the nanofibrillar chitin/chitosan glycolate composites appeared to be most suitable as medicaments able to exert control over various biochemical and physiological processes involved in wound healing besides haemostasis. Whereas chitosan provided antimicrobial activity, cell stimulation capacity and filmogenicity, chitin nanofibrils restructured the gel, released N-acetylglucosamine slowly and recognised proteins and growth factors.

In another study, Shen et al. (2008) examined the neovascularization and fibrillogenesis effects of salmon milt DNA and salmon collagen (SC) composites when used for the treatment of wounds. Tissue loss of wounds treated with composites was repaired quickly and the epidermal layer was formed quickly by means of sDNA (Shen et al., 2008).

Biobrane, is a collagen-silicone based composite, uses as a skin graft to treat injuries (Figure 5). The outer layer of the membrane is a thin and semi-permeable layer consisting of silicon. This layer allows water permeation but prevents the entry of microorganisms. Type I pig collagen forms an inner layer with an inert, hydrophilic network structure and provides a

suitable platform for the development of granulation tissue. Water transfer can be maintained similar to that of natural skin by modifying the membrane thickness (Suzuki et al., 1990; Ou et al., 1998; Still et al., 2003).

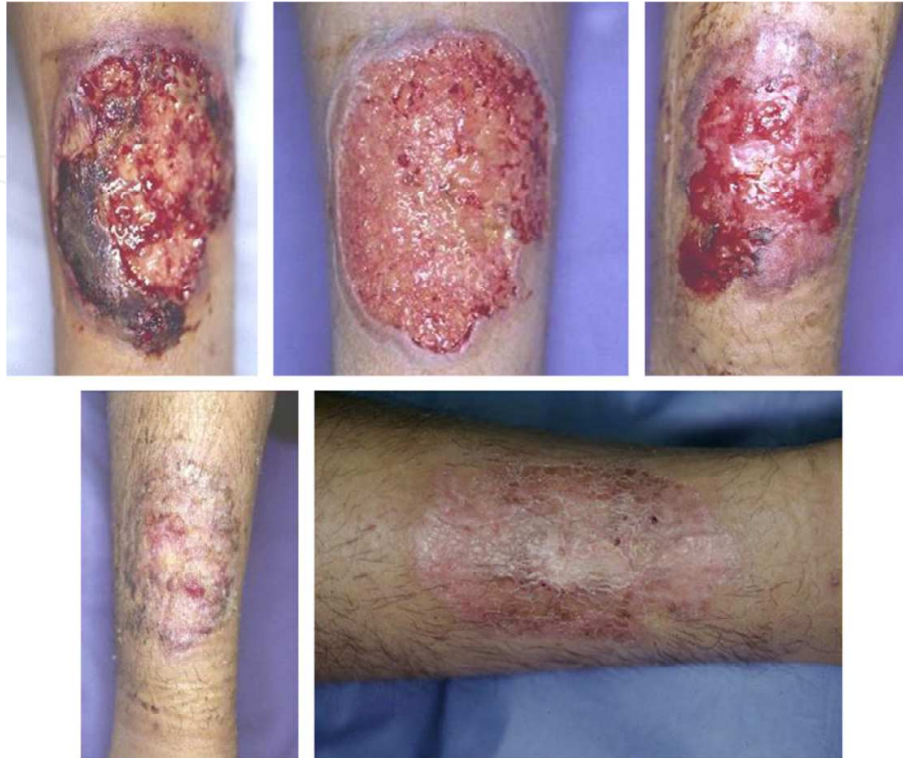

Fig. 4. Gangrenous pyoderma on tibial surface. Treated with Gauze and i.v. therapy of steroids and cyclosporine to ameliorate the wound bed. Complete healing in 40 days (Muzzarelli et al., 2007).

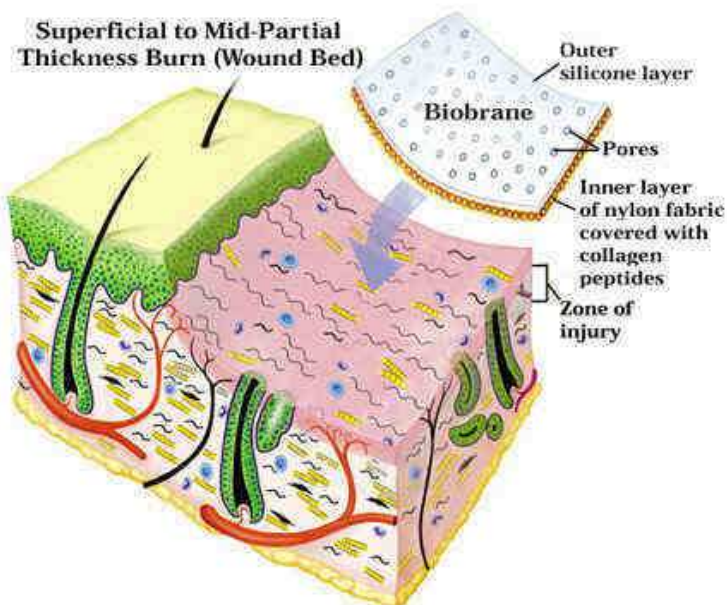


Fig. 5. Schematic observation of biobrane application on superficial to mid-partial thickness burn (<http://www.burnsurgery.com>).



Bilaminar composite membranes containing bovine collagen-based dermal analogue and silastic epidermis has been developed for the treatment of wounds and burns. It is stated that biocompatible bovine collagen-based dermal analogue slowly degrades and provides a suitable environment for the development of the patient's connective tissue; in addition, the epidermal layer's water vapour permeability is close to the skin and protects the wound from trauma and microorganisms (Still et al., 2003).

There are certain restrictions in the areas in which skin source materials can be applied as dressings. Biodegradable or non-biodegradable unilaminar and bilaminar composite membranes function as a serous crust and reduce pain but can not prevent infection. It is stated that synthetic composites do not constitute infection, are suitable for use with antimicrobial solutions and are easily applied to wound tissue (Van den Kerckhove et al., 2001; Van Zuijlen et al., 2003).

#### 4.3.5 Particulate systems

The biggest advantages of particulate systems are that, when applied locally to open wounds, they easily provide water vapour and oxygen permeability of the wound; and have large contact surfaces and high bioadhesiveness due to their multiparticulate structures. Drug release in the wound area can be controlled with particulate system, and this increases the speed of wound healing (Kawaguchi, 2000; Date & Patravale, 2004).

In recent studies on micro-/nanoparticulate systems in wound and burn treatment, the use of nitric oxide nanoparticles (Martinez et al., 2009), poly (ethylene-co-vinyl alcohol) nanofiber (Xu et al., 2011), silver nanoparticles (Lakshmana et al., 2010; Xu et al., 2011), fucoidan microparticles (Sezer et al., 2008b), collagen sponges (Still et al., 2003; Lee, 2005), and liposomes containing epidermal growth factor (Alemdaroglu et al., 2008) have examined. *Staphylococcus aureus* is a gram-positive bacteria, capable of rapidly proliferating in the injured area and causing infection, causes superficial and invasive skin infections. Wounded skin is suitable media for the growth of such pathogenic microorganisms. Various clinical studies have attempted to develop strategies and formulations to address this common issue of pathogenic infection. Topically applied nitric oxide (NO) is a potentially useful preventive and therapeutic strategy against superficial skin infections, including methicillin-resistant *Staphylococcus aureus* infections. NO modulates immune responses and is a significant regulator of wound healing (Martinez et al., 2009). NO nanoparticles were prepared by combination of sodium nitrite with tetramethylorthosilicate, polyethylene glycol, chitosan, glucose. The mechanisms through which the NO nanoparticles accelerate wound healing were further determined by establishing whether NO nanoparticles prevented collagen degradation by MRSA in the infected tissue. Collagen content was highest in both uninfected and infected wounds treated with NO nanoparticles, although nanoparticles-treated uninfected tissue also had high collagen content. The dispersed blue stain indicated thicker and more mature tissue collagen formation in wounds treated with NO nanoparticles, suggesting that NO nanoparticles exposure maintained dermal architecture through bacterial clearance, and ultimately by guarding collagen (Figure 6) (Martinez et al., 2009).

Silver has been used in wound treatment since ancient times. Ointments including silver sulfadiazine are also frequently used in the treatment of burns. Silver affects pathogenic bacteria in wound and burn areas in different ways. Silver ions interacting with bacterial enzymes are taken up inside the bacterial cells, impair the DNA of the bacteria and prevent cell proliferation. Silver ions also attach the cell wall and disrupt the integrity of cell

membrane and kill the bacteria (Klasen, 2000a and 2000b). Poly (ethylene-co-vinyl alcohol) fibre systems including silver nanoparticles were prepared for the treatment of wounds. The results showed that the nanofibre size can be controlled by regulating polymer solution concentration. It has been reported that high concentration of silver might change the fibre morphology. Results of bacterial tests showed that pathogen-restraining ability of the silver-encapsulated nanofibres was effective and proportional over a range of silver concentration, indicating its inflammation control capacity and the potential for applications in skin wound treatment (Xu et al., 2011).

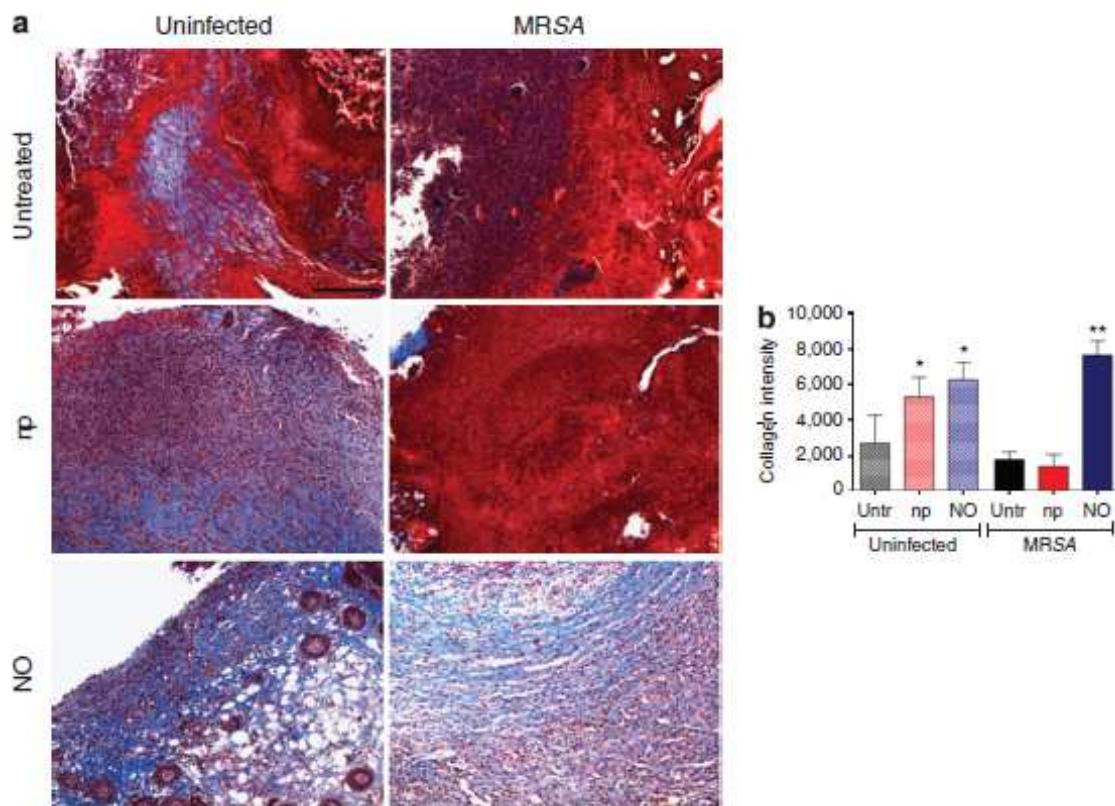


Fig. 6. NO-nps decrease collagen degradation in skin lesions of Balb/c mice. (a) Histological analysis of Balb/c mice uninfected and untreated, uninfected treated with nanoparticles without nitric oxide (NO) (np), uninfected treated with NO-nps (NO), untreated methicillin-resistant *Staphylococcus aureus* (MRSA)-infected, np-treated MRSA-infected, and MRSA-infected treated with NO, day 7. Mice were infected with  $10^7$  bacterial cells. The blue stain indicates collagen. Bar  $\frac{1}{4}$  25 mm. (b) Quantitative measurement of collagen intensity in 16 representative fields of the same size for uninfected and untreated, uninfected treated with nanoparticles without NO (np), uninfected treated with NO, untreated MRSA-infected, np-treated MRSA-infected, and MRSA-infected treated with NO wounds. Bars are the averages of the results, and error bars denote SDs. \* $P < 0.01$  in comparing the untreated groups with the uninfected np- and NO-treated groups; \*\* $P < 0.001$  in comparing the untreated groups with the MRSA + NO group (Martinez et al., 2009).

In another study, silver nanoparticles were synthesized by aqueous and organic methods and incorporated into electrospun polyurethane (PU) nanofibre to enhance the antibacterial as well as wound healing properties. The electrospinning parameters were optimized for PU



with and without silver nanoparticles. The water absorption, antibacterial and cytocompatibility of the PU-silver nanofibers were studied and compared to that of conventional PU foam. The results indicated that the PU-Ag nanofibers could be used for wound dressing applications (Lakshmana et al., 2010).

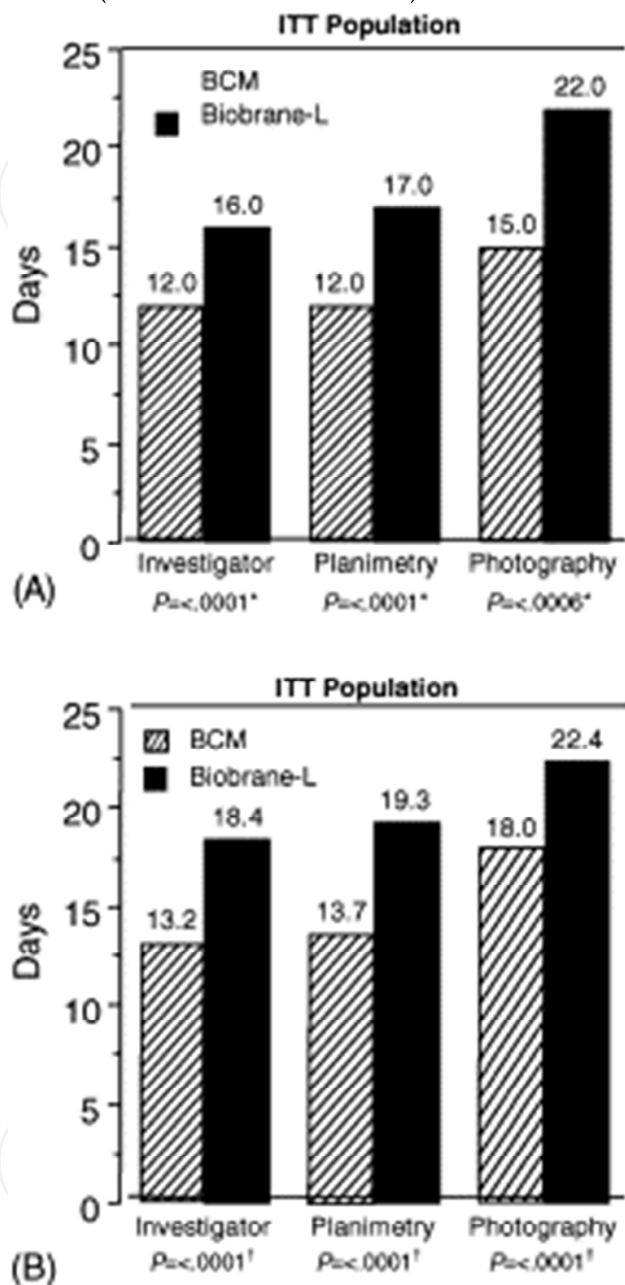


Fig. 7. Days to 100% wound closure. Median times to wound closure is shown in (A) and mean times are shown in (B). BCM indicates bilayered cellular matrix (OrCelTM); intent-to-treat (ITT). \*Log-rank test of the difference between treatment healing times, stratified by patient. †Paired t-test (Still et al., 2003).

In different stages of wound healing, various cell types, cytokines, coagulation factors, growth factors, complement activation and matrix proteins are involved in different extents. Collagen is one of the most important structural protein components of connective tissue. It is difficult to say at which stage collagen predominates because wound healing is a dynamic

event involving many stages. There are many different clinical applications of collagen. For example, collagen gel is often used to treat haemophilia patients due to its haemostatic effects (Tan et al., 2001; Lee et al., 2002; Ruszczak, 2003; Beckenstein et al., 2004). By using micro sponge technology, which is a new type of pharmaceutical dosage form, collagen-based particles are clinically tested in the treatment of wounds and burns and were reported to have positive results compared with commercial preparations (Ruszczak, 2003; Beckenstein et al., 2004). Still et al. (2003) examined the safety and efficacy of porous collagen sponge containing co-cultured allogeneic donor epidermal keratinocytes and dermal fibroblasts from human neonatal foreskin tissue (OrCel™) in facilitating timely wound closure of split-thickness donor sites in severely burned patients. Utilized a matched pairs design; each patient had two designated donor sites of equivalent surface area and depth. Sites were randomized to receive a single treatment of either OrCel™ or the standard dressing Biobrane-L®. The treatment of donor site wounds with OrCel™ is well tolerated, promotes more rapid healing, and results in reduced scarring when compared with conventional therapy with Biobrane-L® (Still et al., 2003). Data on wound closure as a result of the treatment are given in Figure 7. As seen in Figure 7, the cell based-membrane sponges improved the healing of the wound.

The efficacy of microsponges containing epidermal growth factor (EGF) was investigated clinically. It was found that the application of EGF microsponges to the burn surface increased the activity of fibrinogen and thus fibroblast synthesis and migration were seen at the injury site (Lee, 2005). Also, liposome systems in which EGF had been encapsulated was used as particulate carrier systems in the treatment of wounds and burns. Positive results were reported in terms of eschar tissue formation and wound healing with these systems, when especially used in the treatment of second-degree burns (Alemdaroglu et al., 2008).

## 5. Conclusion

The biopolymers are more effective as a wound-healing accelerator than synthetic polymers. The wound treated with biopolymers and biomaterials shows accelerated healing. Biopolymers structural arrangement is similar to that of normal skin. Consequently, the biopolymers are considered to be one of ideal materials with biocompatibility, biodegradability, and wound healing property as well as easy application.

## 6. References

- Alemdaroglu, C.; Degim, Z.; Çelebi, N.; Şengezer, M.; Alömeroglu, M. & Nacar, A.(2008). Investigation of epidermal growth factor containing liposome formulation effects on burn wound healing, *Journal of Biomedical Materials Research*, Vol.85A, pp.271-283.
- Alper, J.C.; Welch, E.A.; Ginsberg, M.; Bogaars, H. & Maguire, P. (1983). Moist wound healing under a vapor permeable membrane, *Journal of the American Academy of Dermatology*, Vol.8, pp.347-353.
- Alsarra, I.A. (2009). Chitosan topical gel formulation in the management of burn wounds, *International Journal of Biological Meacromolecules*, Vol.45, pp.16-21.
- Atiyeh, B.S.; Hayek, S.N. & Gunn, S.W. (2005). New technologies for burn wound closure and healing-review of the literature, *Burns*, Vol.31, pp.944-956.

- Balasubramani, M.; Kumar, T.R. & Babu, M. (2001). Skin substitutes: a review. *Burns*, Vol.27, pp.534-544.
- Balakrishnan, B.; Mohanty, M.; Umashankar, P.R. & Jayakrishnan, A. (2005). Evaluation of an in situ forming hydrogel wound dressing based on oxidized alginate and gelatin, *Biomaterials*, Vol.26, No.32, pp.6335-6342.
- Bao, L.; Yang, W.; Mao, X.; Mou, S. & Tang, S. (2008). Agar/collagen membrane as skin dressing for wounds, *Biomedical Materials*, Vol.3, pp.1-7.
- Barnett, A; Berkowitz, R.L.; Mills, R. & Vistnes, L.M. (1983). Scalp as skin graft donor site: rapid reuse with synthetic adhesive moisture vapour permeable dressings, *Journal of Trauma*, Vol.23, pp.148-151.
- Beckenstein, M.S.; Kuniaki, T. & Matarasso, A. (2004). The effect of scarguard on collagenase levels using a full-thickness epidermal model, *Aesthetic Surgery Journal*, Vol.24, pp.542-546.
- Berthod, F.; Saintigny, G.; Chretien, F.; Hayek, D.; Collombel, C. & Damour, O. (1994). Optimization of thickness, pore size and mechanical properties of a biomaterial designed for deep burn coverage, *Clinical Materials*, Vol.15, pp.259-265.
- Branski, L.K.; Herndon, D.N.; Celis, M.M.; Norbury, W.B.; Masters, O.E. & Jeschke, M.G. (2008). Amnion in the treatment of pediatric partial-thickness facial burns, *Burns*, Vol.34, No.3, pp.393-399.
- Byrne, M.E.; Park, K. & Peppas, N.A. (2002). Molecular imprinting within hydrogels, *Advanced Drug Delivery Reviews*, Vol.54, pp.149-161.
- Catarino, P.A.; Chamberlain, M.H.; Wright, N.C.; Black, E.; Campbell, K.; Robson, D. & Pillai, R.G. (2000). High-pressure suction drainage via a polyurethane foam in the management of poststernotomy mediastinitis, *Annals of Thoracic Surgery*, Vol.70, pp.1891-1895.
- Chanson, M.; Derouette, J.; Roth, I.; Foglia, B.; Scerri, I.; Dudez, T. & Kwak, B.R. (2005). Gap junctional communication in tissue inflammation and repair, *BBA*, Vol.1711, pp.197-207.
- Cho, Y.W.; Cho, Y.N.; Chung, S.H.; Yoo, G. & Ko, S.W. (1999). Water-soluble chitin as a wound healing accelerator, *Biomaterials*, Vol.20, pp.2139-2145.
- Chvapil, M.; Kronenthal, R.L. & Van Winkle, W. (1973). Medical and surgical applications of collagen, *International Review of Connective Tissue Research*, Vol.6, pp.1-61.
- Costache, M.C.; Qu, H.; Ducheyne, P. & Devore, D.I. (2010). Polymer-xerogel composites for controlled release wound dressings, *Biomaterials*, Vol.31, No.24, pp.6336-6343.
- Date, A.A. & Patravale, V.B. (2004). Current strategies for engineering drug nanoparticles, *Current Opinion in Colloid and Interface Science*, Vol.9, pp.222-235.
- Dressler, D.P.; Barbee, W.K. & Sprenger, R. (1980). The effect of Hydron® burn wound dressing on burned rat and rabbit ear wound healing, *Journal of Trauma*, Vol.20, pp.1024-1028.
- Fansler, R.F.; Taheri, P.; Cullinane, C.; Sabates, B. & Flint, L.M. (1995). Polypropylene mesh closure of the complicated abdominal wound, *American Journal of Surgery*, Vol.170, pp.15-18.
- Fenn, C.H. & Butler, P.E.M. (2001). Abdominoplasty wound-healing complications: assisted closure using foam suction dressing, *British Journal of Plastic Surgery*, Vol.54, pp.348-351.
- Freyman, T.M.; Yannas, I.V. & Gibson, L.J. (2001). Cellular materials as porous scaffolds for tissue engineering, *Progress in Materials Science*, Vol.46, pp.273-282.

- Gangjee, T.; Colaizzo, R. & Von Recum, A.F. (1985). Species-related differences in percutaneous wound healing, *Annals of Biomedical Engineering*, Vol.13, No.5, pp.451-467.
- Gingras, M.; Paradis, I. & Berthod, F. (2003). Nerve regeneration in a collagen-chitosan tissue-engineered skin transplanted on nude mice, *Biomaterials*, Vol.24, pp.1653-1661.
- Goertz, O.; Abels, C.; Knie, U.; May, T.; Hirsch, T.; Daigeler, A.; Steinau, H.U. & Langer, S. (2010). Clinical safety and efficacy of a novel thermoreversible polyhexanide-preserved wound covering gel, *European Surgical Research*, Vol. 44, No.2, pp.96-101.
- Hafemann, B.; Ensslen, S.; Erdmann, C.; Niedballa, R.; Zühlke, A.; Ghofrani, K. & Kirkpatrick, C.J. (1999). Use of a collagen/elastin-membrane for the tissue engineering of dermis, *Burns*, Vol.25, pp.373-384.
- Hasegawa, T.; Mizoguchi, M.; Haruna, K.; Mizuno, Y.; Muramatsu, S.; Suga, Y.; Ogawa, H. & Ikeda, S. (2007). Amnia for intractable skin ulcers with recessive dystrophic epidermolysis bullosa: report of three cases, *Journal of Dermatology*, Vol. 34, pp.328-332.
- Hoffman, A.S. (2002). Hydrogels for biomedical applications, *Advanced of Drug Delivery Reviews*, Vol.43, pp.3-12.  
<http://www.burnsurgery.com>
- Hwang, M.R.; Kim, J.O.; Lee, J.H.; Kim, Y.I.; Kim, J.H.; Chang, S.W.; Jin, S.G.; Kim, J.A.; Lyoo, W.S.; Han, S.S.; Ku, S.K.; Yong, C.S. & Choi, H.G. (2010). Gentamicin-loaded wound dressing with polyvinyl alcohol/dextran hydrogel: gel characterization and *in vivo* healing evaluation, *AAPS PharmSciTech*, Vol.11, No.3, pp.1092-1103.
- Integument. (2001). Ed, L.P. Gartner & J.L. Hiatt, Color Textbook of Histology. Vol. 14, pp. 325-342, W.B. Saunders Company, Philadelphia, USA.
- Jansson, E. & Tengvall, P. (2001). *In vitro* preparation and ellipsometric characterization of thin blood plasma clot films on silicon, *Biomaterials*, Vol.22, pp.1803-1808.
- Jáuregui, K.M.G.; Cabrera, J.C.C.; Ceniceros, E.P.S.; Hernández, J.L.M. & Ilyina, A. (2009). A new formulated stable papain-pectin aerosol spray for skin wound healing, *Biotechnology and Bioprocess Engineering*, Vol.14, pp.450-456.
- Jeong, B.; Kim, S.W. & Bae, Y.H. (2002). Thermosensitive sol-gel reversible hydrogels, *Advanced of Drug Delivery Reviews*, Vol.54, pp.37-51.
- Ji, J.A.; Borisov, O.; Ingham, E.; Ling, V. & Wang, Y.J. (2009). Compatibility of a protein topical gel with wound dressings, *Journal of Pharmaceutical Sciences*, Vol.98, No.2, pp.595-605.
- Johnson, P.A.; Fleming, K. & Avery, C.M.E. (1998). Latex foam and staple fixation of skin grafts, *British Journal of Oral and Maxillofacial Surgery*, Vol. 36, pp.141-142.
- Jones, I.; Currie, L. & Martin, R. (2002). A guide to biological skin substitutes, *British Journal of Plastic Surgery*, Vol.55, pp.185-193.
- Kapoor, M. & Appleton, I. (2005). Wound healing: abnormalities and future therapeutic targets, *Current Anaesthesia & Critical Care*, Vol.16, pp.88-93.
- Kawaguchi, H. (2000). Functional polymer microspheres. *Progress in Polymer Science*, Vol.25, pp.1171-1210.
- Kearney J.N. (2001). Clinical evaluation of skin substitutes, *Burns*, Vol.27, pp.545-551.
- Khor, E.; Lim, L.Y. (2003). Implantable applications of chitin and chitosan, *Biomaterials*, Vol.24, pp. 2339-2349.
- Kickhöfen, B.; Wokalek, H.; Scheel D. & Ruh, H. (1986). Chemical and physical properties of a hydrogel wound dressing, *Biomaterials*, Vol.7, pp.67-72.



- Kim, I.; Park, J. W.; Kwon, I.C.; Baik, B.S. & Cho, B.C. (2002). Role of BMP  $\beta$ ig-h3, and chitosan in early bony consolidation in distraction osteogenesis in a dog model, *Plastic and Reconstructive Surgery*, Vol.109, pp.1966-1977.
- Kim, J.O.; Choi, J.Y.; Park, J.K.; Kim, J.H.; Jin, S.G.; Chang, S.W.; Li, D.X.; Hwang, M.R.; Woo, J.S.; Kim, J.A.; Lyoo, W.S.; Yong, C.S. & Choi, H.G. (2008). Development of clindamycin-loaded wound dressing with polyvinyl alcohol and sodium alginate, *Biological and Pharmaceutical Bulletin*, Vol. 31, No.12, pp.2277-2282.
- Kim, J.O.; Park, J.K.; Kim, J.H.; Jin, S.G.; Yong, C.S.; Li, D.X.; Choi, J.Y.; Woo, J.S.; Yoo, B.K.; Lyoo, W.S.; Kim, J. & Choi, H. (2008). Development of polyvinyl alcohol-sodium alginate gel-matrix-based wound dressing system containing nitrofurazone, *International Journal of Pharmaceutics*, Vol.359, pp.79-86.
- Kirker, K.R.; Luo, Y.; Nielson, J.H.; Shelby, J. & Prestwich, G.D. (2002). Glycosaminoglycan hydrogel films as bio-interactive dressings for wound healing, *Biomaterials*, Vol.23, pp.3661-3671.
- Klasen, H.J. (2000a). A historical review of the use of silver in the treatment of burns. I. early uses, *Burns*, Vol.26, pp.117-130.
- Klasen, H.J. (2000b). A historical review of the use of silver in the treatment of burns. II. renewed interest for silver, *Burns*, Vol.26, pp.131-138.
- Knapp, T.R.; Kaplan, E.N. & Daniels, J.R. (1977). Injectable collagen for soft tissue augmentation, *Plastic and Reconstructive Surgery*, Vol.60, pp.398-405.
- Krajewska, B. (2004). Application of chitin and chitosan based materials for enzyme immobilizations: a review, *Enzyme and Microbial Technology*, Vol.35, pp.126-139.
- Kumar, N.; Ravikumar, M.N.V. & Domb, A.J. (2001). Biodegradable block copolymers, *Advanced of Drug Delivery Reviews*, Vol.53, pp.23-44.
- Lakshmana, L.R.; Shalumona, K.T.; Naira, S.V.; Jayakumara, R. & Nair, S.V. (2010). Preparation of silver nanoparticles incorporated electrospun polyurethane nanofibrous mat for wound dressing, *Journal of Macromolecular Science, Part A: Pure and Applied Chemistry*, Vol.47, pp.1012-1018.
- Lee, A.R. (2005). Enhancing dermal matrix regeneration and biomechanical properties of 2<sup>nd</sup> degree-burn wounds by EGF-impregnated collagen sponge dressing, *Archives of Pharmacal Research*, Vol.28, No.11, pp.1311-1316.
- Lee, C.H.; Singla, A. & Lee, Y. (2001). Biomedical application of collagen, *International Journal of Pharmaceutics*, Vol.221, pp.1-22.
- Lee, J.J. & Worthington, P. (1999). Reconstruction of the temporomandibular joint using calvarial bone after a failed teflon-proplast implant, *Journal of Oral and Maxillofacial Surgery*, Vol.57, pp.457-461.
- Lehnert, B. & Jhala, G. (2005). The use of foam as a postoperative compression dressing, *Journal of Foot and Ankle Surgery*, Vol.44, pp.68-69.
- Lim, J.K.; Saliba, L.; Smith, M.J.; McTavish, J.; Raine, C. & Curtin, P. (2000). Normal saline wound dressing-is it really normal?, *British Journal of Plastic Surgery*, Vol.53, pp.42-45.
- Lim, S.J.; Lee, J.H.; Piao, M.G.; Lee, M.K.; Oh, D.H.; Hwang, du H.; Quan, Q.Z.; Yong, C.S. & Choi, H.G. (2010). Effect of sodium carboxymethylcellulose and fucidic acid on the gel characterization of polyvinylalcohol-based wound dressing, *Archives of Pharmacal Research*, Vol.33, No.7, pp.1073-1081.
- Lloyd, L.L.; Kennedy, J.F.; Methacanon, P.; Paterson, M. & Knill, C.J. (1998). Carbohydrate polymers as wound management aids, *Carbohydrate Polymers*, Vol. 37, pp.315-322.

- Losi, P.; Lombardi, S.; Briganti, E. & Soldani, G. (2004). Luminal surface microgeometry affects platelet adhesion in small-diameter synthetic grafts, *Biomaterials*, Vol.25, pp.4447-4455.
- Madri J.A. (1990). Inflammation and healing. Ed: J. M. Kissane, Anderson's Pathology. Vol. 1, pp. 67-110, The C.V. Mosby Company, St. Louis, USA.
- Manwaring, M.E.; Walsh, J.F. & Tresco P.A. (2004). Contact guidance induced organization of extracellular matrix, *Biomaterials*, Vol.25, pp.3631-3638.
- Martinez, L.R.; Han, G.; Chacko, M.; Mihi, M.R.; Jacobson, M.; Gialanella, P.; Friedman, A.J.; Nosanchuk, J.D. & Friedman J.M. (2009). Antimicrobial and healing efficacy of sustained release nitric oxide nanoparticles against *Staphylococcus aureus* skin infection, *Journal of Investigative Dermatology*, Vol. 129, No. 10, pp.2463-2469.
- Mi, F.; Wu, Y.; Shyu, S.; Schoung, J.; Huang, Y.; Tsai, Y. & Hao J. (2002). Control of wound infections using a bilayer chitosan wound dressing with sustainable antibiotic delivery, *Journal of Biomedical Materials Research*, Vol.59, pp.438-449.
- Miller, R.S.; Steward, D.L.; Tami, T.A.; Sillars, M.J.; Seiden, A.M.; Shete, M.; Paskowski, C. & Welge, J. (2003). The clinical effects of hyaluronic acid ester nasal dressing (Merogel) on intranasal wound healing after functional endoscopic sinus surgery, *Otolaryngology-Head and Neck Surgery*, Vol.128, pp.862-869.
- Moulin, V.; Auger, F.A.; Garrel, D. & Germain, L. (2000). Role of wound healing myofibroblasts on re-epithelialization of human skin, *Burns*, Vol.26, pp.3-12.
- Mutsaers, S.E.; Bishop, J.E.; McGrouther, G. & Laurent, G.J. (1997). Mechanisms of tissue repair: from wound healing to fibrosis, *International Journal of Biochemistry & Cell Biology*, Vol.29, pp.5-17.
- Murakami, K.; Aoki, H.; Nakamura, S.; Nakamura, S.; Takikawa, M.; Hanzawa, M.; Kishimoto, S.; Hattori, H.; Tanaka, Y.; Kiyosawa, T.; Sato, Y. & Ishihara, M. (2010). Hydrogel blends of chitin/chitosan, fucoidan and alginate as healing-impaired wound dressings, *Biomaterials*, Vol.31, No.1, pp.83-90.
- Muzzarelli, C. & Muzzarelli, R.A.A. (2002). Natural and artificial chitosan-inorganic composites, *Journal of Inorganic Biochemistry*, Vol.92, pp.89-94.
- Muzzarelli, R.A.A.; Morganti, P.; Morganti, G.; Palombo, P.; Palombo, M.; Biagini, G.; Belmonte, M.M.; Giantomassi, F.; Orlandi, F. & Muzzarelli, C. (2007). Chitin nanofibrils/chitosan glycolate composites as wound medicaments, *Carbohydrate Polymers*, Vol. 70, pp. 274-284.
- Naimer, S.A. & Chemla, F. (2000). Elastic adhesive dressing treatment of bleeding wounds in trauma victims, *American Journal of Emergency Medicine*, Vol.18, pp.816-819.
- Nakabayashi, N. (2003). Dental biomaterials and the healing of dental tissue, *Biomaterials*, Vol.24, pp.2437-2439.
- Nanchahal, J.; Dover, R. & Otto, W.R. (2002). Allogeneic skin substitutes applied to burns patients, *Burns*, Vol.28, pp.254-257.
- Nascimento, E.G.; Sampaio, T.B.; Medeiros, A.C. & Azevedo, E.P. (2009). Evaluation of chitosan gel with 1% silver sulfadiazine as an alternative for burn wound treatment in rats, *Acta Cirurgica Brasileira*, Vol.24, No.6, pp.460-465.
- Nunes, P.S.; Albuquerque-Júnior, R.L.C.; Cavalcante, D.R.R.; Dantas, M.D.M.; Cardoso, J.C.; Bezerra, M.S.; Souza, J.C.C.; Serafini, M.R.; Quitans-Jr, L.J.; Bonjardim, L.R. & Araújo A.A.S. (2011). Collagen-based films containing liposome-loaded usnic acid as dressing for dermal burn healing, *Journal of Biomedicine and Biotechnology*, Article ID. 761593.


- O'Donovan, D.A.; Mehdi, S.Y. & Eadie, P.A. (1999). The role of mepitel silicone net dressings in the management of fingertip injuries in children, *Journal of Hand Surgery*, Vol.24, pp.727-730.
- Okabayashi, R.; Nakamura, M.; Okabayashi, T.; Tanaka, Y.; Nagai, A. & Yamashita, K. (2009). Efficacy of polarized hydroxyapatite and silk fibroin composite dressing gel on epidermal recovery from full-thickness skin wounds, *Journal of Biomedical Materials Research Part B: Applied Biomaterials*, Vol.90B, pp.641-646.
- O'Leary, R.; Rerek, M. & Wood, E.J. (2004). Fucoidan modulates the effect of transforming growth factor (TGF)-beta1 on fibroblast proliferation and wound repopulation in in vitro models of dermal wound repair, *Biological and Pharmaceutical Bulletin*, Vol.27, No.2, pp.266-270.
- Ortega, M.R. & Milner, S.M. (2000). Human beta defensin is absent in burn blister fluid, *Burn*, Vol.26, pp.724-726.
- Ou, L.F.; Lee, S.Y.; Chen, Y.C.; Yang, R.S. & Tang, Y.W. (1998). Use of biobrane in pediatric scald burns-experience in 106 children, *Burns*, Vol.24, pp.49-53.
- Pachulski, R.; Zasadil, M.; Adkins, D. & Hanif, B. (2002). High incidence of Pellethane 90A lead malfunction, *Europace*, Vol.4, pp.45-47.
- Park, S.; Lee, K.C.; Song, B.S.; Cho, J.H.; Kim, M.N. & Lee, S.H. (2002). Microvibration transducer using silicon elastic body for an implantable middle ear hearing aid, *Mechatronics*, Vol.12, pp.1173-1184.
- Park, S.N.; Kim, J.K. & Suh, H. (2004). Evaluation of antibiotic-loaded collagen-hyaluronic acid matrix as a skin substitute, *Biomaterials*, Vol.25, pp.3689-3698.
- Park, S.N.; Lee, H.J.; Lee, K.H. & Suh, H. (2003). Biological characterization of EDC-crosslinked collagen-hyaluronic acid matrix in dermal tissue restoration, *Biomaterials*, Vol.24, pp.1631-1641.
- Patankar, M.S.; Oehninger, S.; Barnett, T.; Williams, R.L. & Clark, G.F. (1993). A revised structure for fucoidan may explain some of its biological activities, *Journal of Biological Chemistry*, Vol. 268, No.29, pp.21770-21776.
- Paul, W. & Sharma, C.P. (2004). Chitosan and alginate wound dressings: a short review, *Trends in Biomaterials & Artificial Organs*, Vol.18, pp.18-23.
- Peng, H.T. & Shek, P.N. (2009). Development of in situ-forming hydrogels for hemorrhage control, *Journal of Materials Science: Materials in Medicine*, Vol.20, No.8, pp.1753-1762.
- Peters, G. & Wirth, C.J. (2003). The current state of meniscal allograft transplantation and replacement, *Knee*, Vol.10, No.1, pp.19-31.
- Pietramaggiore, G.; Yang, H.J.; Scherer, S.S.; Kaipainen, A.; Chan, R.K.; Alperovich, M.; Newalder, J.; Demcheva, M.; Vournakis, J.N.; Valeri, C.R.; Hechtman, H.B. & Orgill, D.P. (2008). Effects of poly-N-acetyl glucosamine (pGlcNAc) patch on wound healing in db/db mouse, *Journal of Trauma*, Vol.64, No.3, pp.803-808.
- Price, R.D.; Das-Gupta, V.; Frame, J.D. & Navsaria, H.A. (2001). A study to evaluate primary dressings for the application of cultured keratinocytes, *British Journal of Plastic Surgery*, Vol.54, pp. 687-696.
- Pruitt, B.A. & Levine, N.S. (1984). Characteristics and uses of biologic dressings and skin substitutes, *Archives of Surgery*, Vol.119, pp.312-322.
- Rao, S.B. & Sharma, C.P. (2007). Use of chitosan as a biomaterials: studies on its safety and hemostatic potential, *Journal of Biomedical Materials Research*, Vol.34, pp.21-28.
- Raphael, K.G.; Marbach, J.J.; Wolford, L.M.; Keller, S.E. & Bartlett, J.A. (1999). Self-reported systemic, immune-mediated disorders in patients with and without proplast-teflon

- implants of the temporomandibular joint, *Journal of Oral and Maxillofacial Surgery*, Vol.57, pp.364-370.
- Ravishanker, R.; Bath, A.S. & Roy, R. (2003). Amnion Bank the use of long term glycerol preserved amniotic membranes in the management of superficial and superficial partial thickness burns, *Burns*, Vol. 29, No.4, pp.69-74.
- Ruszczak, Z. (2003). Effect of collagen matrices on dermal wound healing, *Advanced of Drug Delivery Reviews*, Vol.55, pp.1595-1611.
- Saliba, M.J. (2001). Heparin in the treatment of burns: a review, *Burns*, Vol.27, pp.349-358.
- Sezer, A.D. (2011). Chitosan: properties and its pharmaceutical and biomedical aspects. In: Focus on chitosan research, Samuel P. Davis, editor pp.377-398, Nova Publisher, ISBN: 978-1-61324-454-8, Hauppauge, Newyork, USA.
- Sezer, A.D. & Akbuğa, J. (2006). Fucosphere--new microsphere carriers for peptide and protein delivery: preparation and in vitro characterization, *Journal of Microencapsulation*, Vol.23, No.5, pp.513-522.
- Sezer, A.D. & Akbuğa, J. (2009). Comparison on in vitro characterization of fucospheres and chitosan microspheres encapsulated plasmid DNA (pGM-CSF): formulation design and release characteristics, *AAPS PharmSciTech*, Vol.10, No.4, pp.1193-1199.
- Sezer, A.D. & Cevher, E. (2011). Fucoidan: is a versatile biopolymer for biomedical applications, In: Biomaterials and nanostructures are for active implants, Meital Zilberman, editor. pp.377-406, Springer-Verlag Publisher, ISBN: 978-3-642-18064-4, Heidelberg, Berlin, Germany.
- Sezer, A.D.; Cevher, E.; Hatipoğlu, F.; Oğurtan, Z.; Baş, A.L. & Akbuğa, J. (2008). Preparation of fucoidan-chitosan hydrogel and its application as burn healing accelerator on rabbits, *Biological and Pharmaceutical Bulletin*, Vol.31, No.12, pp.2326-2333.
- Sezer, A.D.; Cevher, E.; Hatipoğlu, F.; Oğurtan, Z.; Baş, A.L. & Akbuğa, J. (2008). The use of fucosphere in the treatment of dermal burns in rabbits, *European Journal of Pharmaceutics and Biopharmaceutics*, Vol.69, No.1, pp.189-198.
- Sezer, A.D.; Hatipoğlu, F.; Cevher, E.; Oğurtan, Z.; Baş, A.L. & Akbuğa, J. (2007). Chitosan films containing fucoidan as a wound dressing for dermal burn healing: Preparation and in vitro/in vivo evaluation, *AAPS PharmSciTech*, Vol.8, No.2, Article 39, E1-E8.
- Shakespeare, P. & Shakespeare V. (2002). Survey: use of skin substitute materials in UK burn treatment centres, *Burns*, Vol.28, pp.295-297.
- Shakespeare, P. (2001). Burn wound healing and skin substitutes, *Burns*, Vol.27, pp.517-522.
- Shen, X.; Nagai, N.; Murata, M.; Nishimura, D.; Sugi, M. & Munekata, M. (2008). Development of salmon milt DNA/salmon collagen composite for wound dressing, *Journal of Materials Science: Materials in Medicine*, Vol.19, pp.3473-3479.
- Sheridan, R.L. & Tompkins, R.G. (1999). Skin substitutes in burns, *Burns*, Vol.25, pp.97-103.
- Sheridan, R.L.; Morgan, J.R. & Mohammad R. (2001). Biomaterials in burn and wound dressing. Ed: Severian D., Polymeric Biomaterials, Dumitriu Severian, editor. pp.451-458, Marcel Dekker, ISBN: 0-8247-8969-5, New York, USA.
- Singer, A.J.; Mohammad, M.; Thode, H.C. & McClain, S.A. (2000). Octylcyanoacrylate versus polyurethane for treatment of burns in swine: a randomized trail, *Burns*, Vol.26, pp.388-392.
- Skin. Ed: Junquera, L.C.; Carneiro, J. & Kelley, O.R., Basic Histology. Vol. 18, pp.357-370, Prentice-Hall International Inc., Rio de Janerio, Brasil.



- Skin. Ed: Young, B. & Heath J.W., *Wheather's Functional Histology*. Vol. 9, pp.157-171, Churchill Livingstone, Philadelphia, USA.
- Sparkes, B.G.: Immunological responses to thermal injury, *Burns*, Vol.23, pp.106-113.
- Stashak, T.S.; Farstvedt, E. & Othic, A. (2004). Update on wound dressings: indications and best use, *Clinical Techniques in Equine Practice*, Vol.3, pp.148-163.
- Still, J.; Glat, P.; Silverstein, P.; Griswold, J. & Mazingo, D. (2003). The use of a collagen sponge/living cell composite material to treat donor sites in burn patients, *Burns*, Vol.29, No.8, pp.837-841.
- Suh, J.K.F. & Matthew, H.W.T. (2000). Application of chitosan-based polysaccharide biomaterials in cartilage tissue engineering: a review, *Biomaterials*, Vol.21, pp.2589-2598.
- Sung, J.H.; Hwang, M.R.; Kim, J.O.; Lee, J.H.; Kim, Y.I.; Kim, J.H.; Chang, S.W.; Jin, S.G.; Kim, J.A.; Lyoo, W.S.; Han, S.S.; Ku, S.K.; Yong, C.S. & Choi, H.G. (2010). Gel characterisation and in vivo evaluation of minocycline-loaded wound dressing with enhanced wound healing using polyvinyl alcohol and chitosan, *International Journal of Pharmaceutics*, Vol.392, No.1-2, pp.232-240.
- Suzuki, S.; Matsuda, K.; Isshiki, N.; Tamada, Y. & Ikada, Y. (1990). Experimental study of a newly developed bilayer artificial skin, *Biomaterials*, Vol.11, pp.356-360.
- Şenel, S. & McClure, S.J. (2004). Potential applications of chitosan in veterinary medicine, *Advanced of Drug Delivery Reviews*, Vol.56, pp.1467-1480.
- Şenyuva, C.; Yücel, A.; Erdamar, S.; Çetinkale, O.; Seradjmir, M. & Özdemir, C. (1997). The fate of alloplastic materials placed under a burn scar: an experimental study, *Burns*, Vol.23, pp.484-489.
- Tan, W.; Krishnaraj, R. & Desai, T.A. (2001). Evaluation of nanostructured composite collagen-chitosan matrices for tissue engineering, *Tissue Engineering*, Vol.7, pp.203-210.
- Tanigawa, J.; Miyoshi, N. & Sakurai, K. (2008). Characterization of chitosan/citrate and chitosan/acetate films and applications for wound healing, *Journal of Applied Polymer Science*, Vol.110, pp.608-615.
- The skin and its appendages (The Integument). (1981). Ed: Leeson T.S. & Leeson C.R., *Histology*. Vol. 10, pp. 308-327, W.B. Saunders Company, Philadelphia, USA.
- The skin and its appendages (The Integument). (1988). Ed: Leeson T.S., Leeson C.R., Paparo A.A., *Text/Atlas of Histology*. Vol. 10, s. 362-393, W.B. Saunders Company, Philadelphia, USA.
- Thomas, S. (2000a). Alginate dressings in surgery and wound management-Part 1, *Journal of Wound Care*, Vol. 9 No.2 pp.56-60.
- Thomas, S. (2000b). Alginate dressings in surgery and wound management-Part 2, *Journal of Wound Care*, Vol. 9 No.3 pp.115-119.
- Thomas, S. (2000c). Alginate dressings in surgery and wound management-Part 3, *Journal of Wound Care*, Vol. 9 No.4 pp.163-166.
- Tissue repair and wound healing. (1998). Ed: Porth C.M., *Pathophysiology*. Vol. 2, pp.43-48, Lippincott, Philadelphia, USA.
- Tissue repair and wound healing. (1998). Ed: Porth C.M., *Pathophysiology*., Vol. 2, pp.289-293, Lippincott, Philadelphia, USA.
- Trumble, D.R.; McGregor, W.E. & Magovern, J.A. (2002). Validation of a bone analog model for studies of sternal closure, *Annals of Thoracic Surgery*, Vol.74, pp.739-745.
- Ueno, H.; Mori, T. & Fujinaga, T. (2001). Topical formulation and wound healing applications of chitosan. *Advanced of Drug Delivery Reviews*, Vol.52, pp.105-115.

- Ueno, H.; Yamada, H.; Tanaka, I.; Kaba, N.; Matsuura, M.; Okumurai, M.; Kadosawa T. & Fujinaga, T. (1999). Accelerating effects of chitosan for healing at, early phase of experimental open wound in dogs, *Biomaterials*, Vol.20, pp.1407-1414.
- Uppal, R.; Ramaswamy, G.N.; Arnold, C.; Goodband, R. & Wang, Y. (2011). Hyaluronic acid nanofiber wound dressing: Production, characterization, and in vivo behavior, *Journal of Biomedical Materials Research Part B: Applied Biomaterials*, Vol.97B, pp.20-29.
- Van den Kerckhove, E.; Stappaerts, K.; Boeckx, W.; Van den Hof B.; Monstrey, S.; Van der Kelen, A. & Cubber J. (2001). Silicones in the rehabilitation of burns: a review and overview, *Burns*, Vol.27, pp. 205-214.
- Van Zuijlen, P.P.M.; Ruurda, J.J.B.; Van Veen, H.A.; Marle, J.V.; Van Trier, A.J.M.; Groenevelt, F.; Kreis, R.W. & Middelkoop, E. (2003). Collagen morphology in human skin and scar tissue: no adaptations in response to mechanical loading at joints, *Burns*, Vol.29, pp.423-431.
- Verma, P.R.P. & Iyer, S.S. (2000). Controlled transdermal delivery of propranolol using HPMC matrices: design and *in-vitro* and *in-vivo* evaluation, *Journal of Pharmacy and Pharmacology*, Vol.52, pp.151-156.
- Wang, W. (2006). A novel hydrogel crosslinked hyaluronan with glycol chitosan, *Journal of Materials Science: Materials in Medicine*, Vol.17, No.12, pp.1259-1265.
- Weinstein-Oppenheimer, C.R.; Aceituno, A.R.; Brown, D.I.; Acevedo, C.; Ceriani, R.; Fuentes, M.A.; Albornoz, F.; Henríquez-Roldán C.F.; Morales, P.; Maclean, C.; Tapia, S.M. & Young, M.E. (2010). The effect of an autologous cellular gel-matrix integrated implant system on wound healing, *Journal of Translational Medicine*, Vol.8, No.59, pp.1-11.
- Whelan, J. (2002). Smart bandages diagnose wound infection, *DDT*, Vol.7, pp.9-10.
- Whitney, J.D. & Wickline, M.M. (2003). Treating chronic and acute wounds with warming: review of the science and practice implications, *Journal of Wound Care*, Vol.30, pp.199-209.
- Winter, G.D. (1965). A note on wound healing under dressings with special reference to perforated-film dressings, *Journal of Investigative Dermatology*, Vol.45, pp.299-302.
- Wright, K.A.; Nadire, K.B.; Busto, P.; Tubo, R.; McPherson, J.M. & Wentworth, B.M. (1998). Alternative delivery of keratinocytes using a polyurethane membrane and the implications for its use in the treatment of full-thickness burn injury, *Burns*, Vol.24, pp.7-17.
- Xu, C.; Xu, F.; Wang, B. & Lu, T. (2011). Electrospinning of poly(ethylene-co-vinyl alcohol) nanofibres encapsulated with ag nanoparticles for skin wound healing, *Journal of Nanomaterials*, Article ID 201834.
- Xu, H.; Ma, L.; Shi, H.; Gao, C. & Han, C. (2007). Chitosan-hyaluronic acid hybrid film as a novel wound dressing: *in vitro* and *in vivo* studies, *Polymers for Advanced Technologies*, Vol.18, pp.869-875.
- Yenerman, M. (1986). Genel Patoloji. 1<sup>st</sup> edition, pp.271-294, Istanbul Üniversitesi, Istanbul, Turkey.
- Yoo, H. & Kim, H. (2008). Characteristics of Waterborne polyurethane/poly (n-vinylpyrrolidone) composite films for wound-healing dressings, *Journal of Applied Polymer Science*, Vol.107, pp.331-338.



## **Biomaterials Applications for Nanomedicine**

Edited by Prof. Rosario Pignatello

ISBN 978-953-307-661-4

Hard cover, 458 pages

**Publisher** InTech

**Published online** 16, November, 2011

**Published in print edition** November, 2011

These contribution books collect reviews and original articles from eminent experts working in the interdisciplinary arena of biomaterial development and use. From their direct and recent experience, the readers can achieve a wide vision on the new and ongoing potentialities of different synthetic and engineered biomaterials. Contributions were selected not based on a direct market or clinical interest, but on results coming from a very fundamental studies. This too will allow to gain a more general view of what and how the various biomaterials can do and work for, along with the methodologies necessary to design, develop and characterize them, without the restrictions necessary imposed by industrial or profit concerns. Biomaterial constructs and supramolecular assemblies have been studied, for example, as drug and protein carriers, tissue scaffolds, or to manage the interactions between artificial devices and the body. In this volume of the biomaterial series have been gathered in particular reviews and papers focusing on the application of new and known macromolecular compounds to nanotechnology and nanomedicine, along with their chemical and mechanical engineering aimed to fit specific biomedical purposes.

### **How to reference**

In order to correctly reference this scholarly work, feel free to copy and paste the following:

Ali Demir Sezer and Erdal Cevher (2011). Biopolymers as Wound Healing Materials: Challenges and New Strategies, Biomaterials Applications for Nanomedicine, Prof. Rosario Pignatello (Ed.), ISBN: 978-953-307-661-4, InTech, Available from: <http://www.intechopen.com/books/biomaterials-applications-for-nanomedicine/biopolymers-as-wound-healing-materials-challenges-and-new-strategies>

**INTECH**  
open science | open minds

#### **InTech Europe**

University Campus STeP Ri  
Slavka Krautzeka 83/A  
51000 Rijeka, Croatia  
Phone: +385 (51) 770 447  
Fax: +385 (51) 686 166  
[www.intechopen.com](http://www.intechopen.com)

#### **InTech China**

Unit 405, Office Block, Hotel Equatorial Shanghai  
No.65, Yan An Road (West), Shanghai, 200040, China  
中国上海市延安西路65号上海国际贵都大饭店办公楼405单元  
Phone: +86-21-62489820  
Fax: +86-21-62489821

© 2011 The Author(s). Licensee IntechOpen. This is an open access article distributed under the terms of the [Creative Commons Attribution 3.0 License](#), which permits unrestricted use, distribution, and reproduction in any medium, provided the original work is properly cited.

IntechOpen

IntechOpen