

We are IntechOpen, the world's leading publisher of Open Access books Built by scientists, for scientists

4,800

Open access books available

122,000

International authors and editors

135M

Downloads

Our authors are among the

154

Countries delivered to

TOP 1%

most cited scientists

12.2%

Contributors from top 500 universities



WEB OF SCIENCE™

Selection of our books indexed in the Book Citation Index
in Web of Science™ Core Collection (BKCI)

Interested in publishing with us?
Contact book.department@intechopen.com

Numbers displayed above are based on latest data collected.

For more information visit www.intechopen.com



Adverse Pregnancy Outcome in Antiphospholipid Antibodies Syndrome: Pathogenic Mechanisms and Clinical Management

Nicoletta Di Simone and Chiara Tersigni
*Department of Obstetrics and Gynaecology,
Catholic University of Sacred Heart, Rome
Italy*

1. Introduction

The term antiphospholipid antibodies syndrome (APS) defines an autoantibody induced thrombophilia, associated to recurrent thrombosis and pregnancy complications (Hughes, 1993). Diagnosis of APS requires both serological positivity for antiphospholipid antibodies (aPL), a heterogeneous family of autoantibodies directed against protein phospholipid complexes, and the onset of the diagnostic clinical manifestations (see more below). Indeed, it has been widely shown that aPL are not sufficient *per se* to determine clinical manifestations of APS and that the likelihood that aPL may contribute to the pathogenesis of thrombosis or pregnancy complications, or both, varies between clinical settings (Meroni et al., 2004).

To better define this complex syndrome, it must clarify that APS is commonly distinguished between “primary APS”, not associated to other autoimmune diseases, and “secondary APS”, when aPL serological positivity and clinical features of APS occur in the context of a known autoimmune disease. The majority of patients with secondary APS are affected from Systemic Lupus Erythematosus (SLE) and develop aPL serological positivity. About 40% of patients with SLE have aPL positivity (Mok et al., 2005) but less than 40% of them will eventually have thrombotic events (Ruiz-Irastorza et al., 2004; Tektonidou et al., 2009). Actually, it is still unknown if APS and SLE are two manifestations of the same disease or if underlying SLE could favour the development of APS (Miyakis et al., 2006). Accordingly, distinction between primary or secondary APS it is not so easy and have to be made carefully (Miyakis et al., 2006).

2. Clinical manifestations of APS

2.1 Systemic features

Venous thrombosis, or embolism, are the most frequent manifestations of APS and might occur in any vascular vessel while, in congenital thrombophilias, mostly involve venous bed (Cervera, 2002). Among the arterial vessels, the central nervous system is the district most

often affected, usually in the form of stroke or transient ischaemic attack (Cervera et al., 2002). aPL have also been associated with venous sinus thrombosis, myelopathy, chorea, migraine, and epilepsy (Sanna et al., 2003). Furthermore, in patients with SLE an association between serum anticardiolipin antibodies and cognitive impairment has been found (Hanly et al., 1999; Menon et al., 1999) as well as a mild cognitive dysfunction in more than 40% of patients with APS (Tektonidou et al., 2006).

Cardiovascular features of APS include valvular disease, coronary artery disease, intracardiac thrombus formation, pulmonary hypertension and dilated cardiomyopathy (Koniari et al., 2010). Cardiac valvular pathology commonly affects the mitral valve, followed by the aortic and tricuspid ones, determining irregular thickening of the valve leaflets due to deposition of immune complexes that may lead to vegetations and valve dysfunction. These lesions are almost frequent and may be a significant risk factor for stroke (Khamashta et al., 1990; Koniari et al., 2010).

Renal manifestations of APS generally took place as hypertension with proteinuria and renal insufficiency (Amigo et al., 1992; Tektonidou et al., 2004) with the most frequent renal histopathological features associated being thrombotic microangiopathy or, less often, fibrous intimal hyperplasia, focal cortical atrophy and arterial occlusions (Tektonidou et al., 2004).

Other clinical features associated to APS are haematological alterations, like thrombocytopenia and haemolytic anaemia, skin ulcers, avascular bone necrosis and also the endocrinologic manifestation of adrenal insufficiency (Cervera et al., 2002). Livedo reticularis, found in about a quarter of patients with APS, represents a physical sign that often suggests to the clinician the right diagnosis and, among patients with APS, it also identifies those at a higher risk for arterial thrombosis (Ruiz-Irastorza et al., 2010; Francès et al., 2005).

2.2 Adverse pregnancy outcomes associated to APS

Beyond thromboses, obstetric complications are the other main features of APS. Such association is confirmed by several epidemiological studies and experimental models showing that passive transfer of aPL IgG induces foetal loss and growth retardation in pregnant naive mice, giving the proof that aPL are involved in determining the clinical manifestations of the syndrome (Meroni et al., 2010).

The most common adverse pregnancy outcome associated to APS is recurrent miscarriage, defined as three or more unexplained consecutive miscarriages before the 10th week of gestation. Other obstetric features of APS are unexplained foetal deaths, occurring at or beyond the 10th week of gestation, and premature births of a morphologically healthy newborn baby before the 34th week of gestation because of eclampsia or severe pre-eclampsia (Miyakis et al., 2006).

Recurrent miscarriage occurs in about 1% of the general population attempting to have children (Stirrat, 1990) and about 10-15% of women with recurrent miscarriage are diagnosed with APS (Rai et al., 1995; Yetman & Kutteh, 1996). Foetal death in the second or third trimesters of pregnancy occurs in up to 5% of unselected pregnancies (Silver, 2007) but it is less likely as pregnancy advances (Smith et al., 2004). Although foetal death occurs significantly most often in APS (Oshiro et al., 1996), the overall contribution to the pathogenesis of this syndrome is unknown, because of the effect of other possible contributing factors such as underlying hypertension or pre-existing comorbidities, like SLE or renal diseases.

Pregnant women with diagnosis of APS are at increased risk for developing preeclampsia or placental insufficiency, but it is still unknown the precise relationship between aPL and the occurrence of such clinical manifestations (Clark et al., 2007). Furthermore, aPL seem to be detectable in 11 – 29% of women with preeclampsia, compared with 7% or less in controls and in 25% of women delivering growth restricted fetuses (Clark et al., 2007). Finally, results from prospective cohort studies indicate that of pregnant women with high concentrations of aPL, 10 – 50% develop preeclampsia, and more than 10% of these women deliver infants who are small for gestational age (Clark et al., 2007).

3. Diagnostic criteria

According to the last International consensus statement for APS diagnostic criteria, in order to make diagnosis of the syndrome the combination of at least one clinical and one laboratory criterion is required (Miyakis et al., 2006) (Table 1).

Clinical criteria	Laboratory criteria
<p>Vascular thrombosis</p> <ul style="list-style-type: none"> • One or more clinical episodes of arterial, venous, or small vessel thrombosis, in any tissue or organ. • Thrombosis should be supported by objective validated criteria – ie, unequivocal findings of appropriate imaging studies or histopathology. For histopathological support, thrombosis should be present without substantial evidence of inflammation in the vessel wall. <p>Pregnancy morbidity, defined by one of the following criteria:</p> <ul style="list-style-type: none"> • One or more unexplained deaths of a morphologically healthy foetus at or beyond the 10th week of gestation, with healthy foetal morphology documented by ultrasound or by direct examination of the fetus. • One or more premature births of a morphologically healthy newborn baby before the 34th week of gestation because of: eclampsia or severe preeclampsia defined according to standard definitions or recognized features of placental failure. • Three or more unexplained consecutive spontaneous abortions before the 10th week of gestation, with maternal anatomical or hormonal abnormalities and paternal and maternal chromosomal causes excluded. In studies of populations of patients who have more than one type of pregnancy morbidity, investigators are strongly encouraged to stratify groups of patients according to one of the three criteria. 	<ul style="list-style-type: none"> • Lupus anticoagulant present in plasma, on two or more occasions at least 12 weeks apart, detected according to the guidelines of the International Society on Thrombosis and Hemostasis (Scientific Subcommittee on lupus anticoagulant/ phospholipid- dependent antibodies). • Anticardiolipin antibody of IgG or IgM isotype, or both, in serum or plasma, present in medium or high titres (ie, >40 GPL or MPL, or greater than the 99th percentile) on two or more occasions, at least 12 weeks apart, measured by a standardized ELISA. • Anti-β2-glycoprotein 1 antibody of IgG or IgM isotype, or both, in serum or plasma (in titres greater than the 99th percentile), present on two or more occasions, at least 12 weeks apart, measured by a standardized ELISA, according to recommended procedures.

Table 1. Revised diagnostic criteria of APS (Miyakis et al., 2006).

4. Pathogenetic mechanisms mediated by aPL

4.1 Vascular thrombosis

The molecular mechanisms underlying thrombosis and foetal death in APS have long been investigated. The main target antigens reported in patients with APS include beta-2-glycoprotein-1 (β 2GPI), prothrombin and annexin V (Galli et al., 2003). Other putative antigens are thrombin, protein C, protein S, thrombomodulin, tissue plasminogen activator, kininogens (high or low molecular), prekallikrein, factor VII/VIIa, factor XI, factor XII, complement component C4, heparan sulfate proteoglycan, heparin, oxidised low-density lipoproteins (Galli et al., 2003; Rand et al., 2010). The main autoantigens are attracted to negatively charged phospholipids exposed on the outer side of cell membranes in great amounts only under special circumstances such as damage or apoptosis (e.g. endothelial cell) or after activation (e.g. platelets) (Galli et al., 2003).

Endothelial cells, activated by aPL with anti- β 2GPI activity, express adhesion molecules such as intercellular cell adhesion molecule-1, vascular cell adhesion molecule-1, E-selectin, and both endothelial cells and monocytes upregulate the production of tissue factor (TF) (Pierangeli et al., 2008). All at once, activated platelets increase expression of glycoprotein IIb-IIIa and synthesis of thromboxane A₂, determining a procoagulant state (Figure 1). (Pierangeli et al., 2006; Pierangeli et al., 2008; Lopez-Pedrerera et al., 2008; Montiel-Manzano et al., 2007; Vega-Ostertag et al., 2005). Additional mechanisms promoting clot formation could be represented by interaction of aPL with proteins implicated in clotting regulation; such as annexin A5, prothrombin, factor X, protein C and plasmin (de Groot & Derksen, 2005; Pierangeli et al., 2008; Rand et al., 2010).

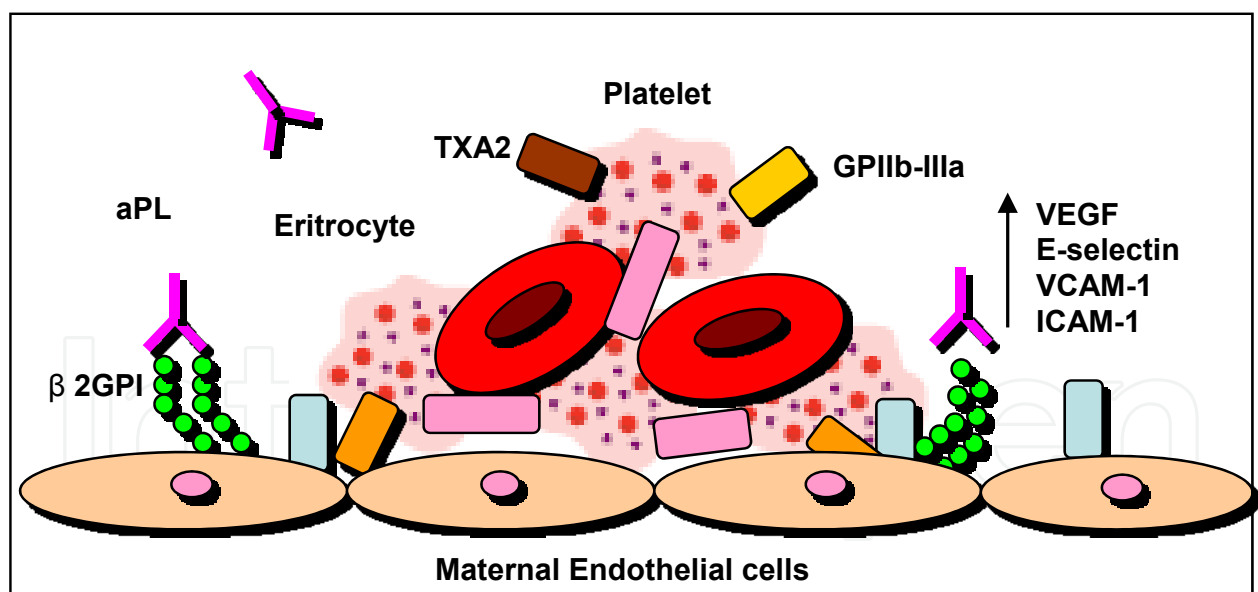


Fig. 1. aPL-mediated mechanism of thrombosis.

aPL are able to activate endothelial cells and platelets leading to a procoagulant state (first hit). The occurrence of a second hit, like inflammation, can lead to clot formation.

Recent results from studies in mice highlight the role of inflammation in the pathogenesis of APS, showing a central role for complement activation in thrombosis and foetal loss induced by aPL (Pierangeli et al., 2005; Girardi et al., 2004). Because many individuals with high aPL

antibody titers remain asymptomatic, a second hit hypothesis have been proposed. It is likely that in the aPL-induced vascular procoagulant state, activation of the complement cascade might close the loop and provoke thrombosis, often in the presence of a second hit, like tobacco, inflammation, or oestrogens (Meroni et al., 2004; de Groot & Derksen, 2005; Ruiz-Irastorza et al., 2010).

4.2 Placental thrombosis

Based on the knowledge of the process of intravascular aPL-mediate clot formation (Figure 1), initially intraplacental thrombosis was considered the main pathogenic mechanism mediating foetal loss in APS. This hypothesis of placental damage was supported by the finding of thrombosis and infarction in placentas from women with APS and by the demonstration of aPL capability to induce a procoagulant state *in vitro* through several mechanisms including the ability of the aPL antibodies (specifically, anti- β 2GPI antibodies) to disrupt the anticoagulant annexin A5 shield on trophoblast and endothelial cell monolayers (Peaceman & Rehnberg, 1993; Nayar & Lage, 1996; Rand et al., 2010). Supporting the *in vitro* findings, a significantly lower distribution of annexin A5 covering the intervillous surfaces was found in the placentas of aPL-positive women in comparison with normal controls (Rand et al., 1994). Nevertheless, thrombotic events cannot account for all of the histopathologic findings in placentae from women with APS and other mechanisms of reproductive impairment are likely to be involved (Out et al., 1991; Park, 2006).

4.3 Defective placentation

4.3.1 Trophoblast invasiveness impairment

New aPL-mediated pathogenic mechanisms have been proposed during the last ten years: anti- β 2GPI antibodies seem to bind directly the maternal decidua and the invading trophoblast, determining defective placentation.

On the foetal side, β 2GPI has been shown to be expressed on trophoblast cell membranes, explaining the placental tropism of anti- β 2GPI antibodies. Being a cationic plasma protein, β 2GPI has been suggested to bind to exposed phosphatidylserine on the external cell membranes of trophoblasts undergoing syncitium formation (Meroni et al., 2010).

β 2GPI-dependent antibodies can adhere to human trophoblast cells *in vitro* (Di Simone et al., 2000), consistently with the hypothesis that the visibility of anionic PLs on the external cell surface during intertrophoblastic fusion might offer a useful substrate for the cation PL-binding site (Katsuragawa et al., 1997; Rote et al., 1998). The binding to anionic structures induces the expression of new cryptic epitopes and/or increases the antigenic density, two events that are apparently pivotal for the antibody binding (Wang S.X. et al., 2000). *In vitro* studies with both murine and human monoclonal antibodies as well as with polyclonal IgG antibodies from APS patients have clearly demonstrated a binding to trophoblast monolayers (Lyden et al., 1992; Di Simone et al., 2000). Interestingly, once bound antibodies obtained from patients with APS can affect the trophoblast functions *in vitro*, inducing cell injury and apoptosis, inhibition of proliferation and syncytia formation, decreased production of human chorionic gonadotrophin, defective secretion of growth factors and impaired invasiveness (Figure 2) (Di Simone et al., 2000). β 2GPI-dependent aPL seem, therefore, to represent the main pathogenic autoantibodies in obstetrical APS. Accordingly, it has been hypothesized that most of these potentially pathogenic autoantibodies should be absorbed at the placental level, where β 2GPI is expressed, and should not be transferred to the fetus.

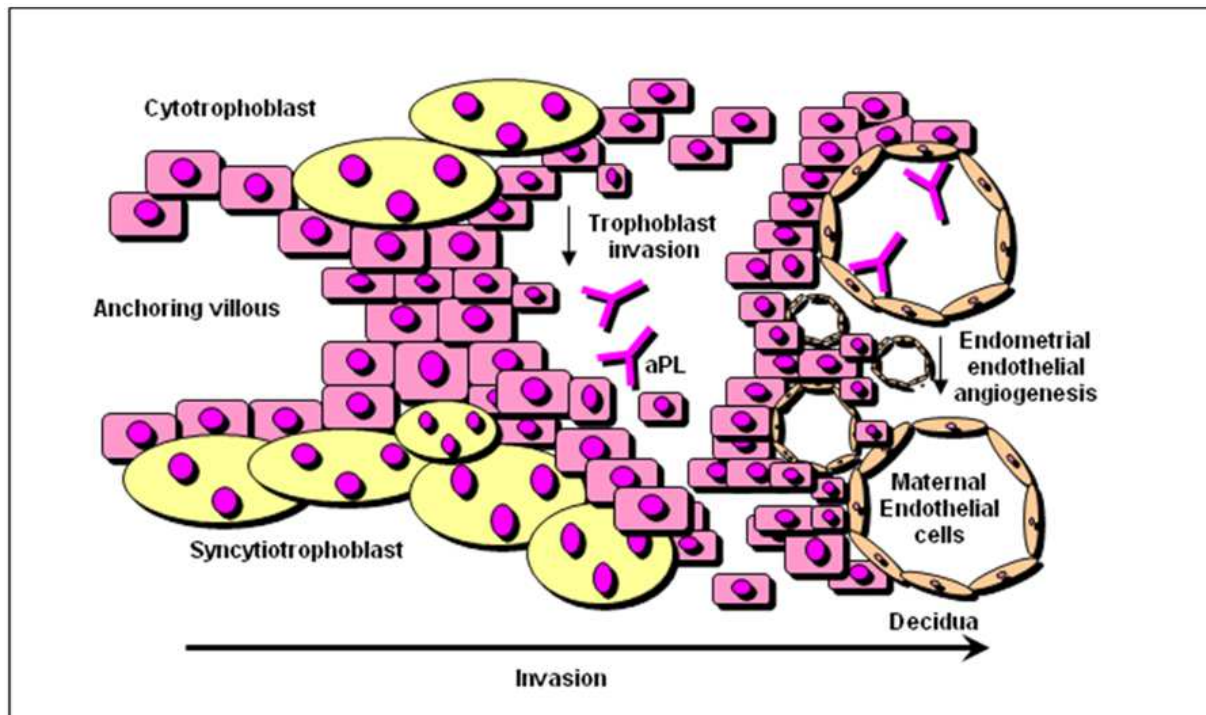


Fig. 2. aPL-mediated inhibition of trophoblast invasiveness and endometrial angiogenesis. Placental development has been proposed to be impaired by aPL direct binding to trophoblast cells, reducing its invasiveness and inhibiting cell proliferation, syncytia formation, secretion of human chorionic gonadotrophin and growth factors. Furthermore, aPL have also been suggested to inhibit maternal decidual angiogenesis, providing an additional mechanism able to explain placental failure associated to APS.

Recent findings have underlined a further mechanism by which aPL binding to human trophoblast could affect its functions: the aPL-mediated reduction of placental Heparin-Binding Epidermal Growth Factor-like growth factor (HB-EGF) expression. HB-EGF is a member of the EGF family (Raab & Klagsbrun, 1997; Iwamoto & Mekada, 2000). It has been shown to induce an invasive trophoblast phenotype in human and mouse blastocysts (Martin et al., 1998; Wang J., 2000) and to initiate molecular and cellular changes characteristic of decidualization in mice (Paria et al., 2001). HB-EGF is expressed in the human placenta during the first trimester, primarily within the villous trophoblast, but also in the extravillous cytotrophoblast, predominantly at the sites of cytotrophoblast extravillous invasion (Leach et al., 1999). Women with preeclampsia and infants small for gestational age display decreased placental expression of HB-EGF (Leach et al., 2002), strongly suggesting an association between HB-EGF down-regulation, poor trophoblast invasion, and failed physiologic transformation of the spiral arteries occurring in these disorders.

Interestingly, also in placental tissue obtained from women with APS, reduced expression of HB-EGF has been found (Di Simone et al., 2010a). Furthermore, polyclonal and monoclonal aPL have been shown to bind trophoblast monolayers *in vitro* significantly reducing the synthesis and the secretion of HB-EGF (Di Simone et al., 2010a). The ability of exogenous recombinant HB-EGF to reduce the aPL mediated effects on trophoblast cells supports the hypothesis of a key pathogenic role of this molecule in mediating APS-related adverse pregnancy outcomes. The experimental conditions did not involve complement activation,

indicating that aPL may also affect placental tissue through direct, complement-independent effects, as previously suggested (Pierangeli et al., 2008).

4.3.2 Endometrial angiogenesis inhibition

On the maternal side, endometrial endothelial angiogenesis inhibition has been suggested to be an additional aPL-mediated mechanism of placental damage (Figure 2). aPL seem to selectively bind *in vitro* to endothelial cells isolated from human endometrium (HEEC) and to inhibit endothelial cell differentiation into capillary-like tubular structures, by reducing MMP-2 activity and VEGF secretion, via a suppression of NF κ B DNA binding activity. Such an aPL-mediated inhibition of angiogenesis has also been confirmed *in vivo* in murine models showing a reduced angiogenesis in subcutaneous implanted angioreactors in aPL-inoculated mice (Di Simone et al., 2010b). Since it is well known that endometrial angiogenesis and decidualization, as well as trophoblast invasion, are fundamental prerequisites for successful implantation and the beginning of pregnancy, aPL-inhibition of such a central process in human placental development provides an important additional mechanism able to explain the association between APS and pregnancy complications associated to placental failure, like miscarriage, foetal growth restriction and preeclampsia.

4.4 Inflammation

It is widely accepted that a physiological pregnancy development requires a fine regulation of the maternal immune response during embryo implantation. Acute inflammatory events are recognized causes of a negative pregnancy outcome, and proinflammatory mediators, such as complement, tumor necrosis factor (TNF), and CC chemokines, have been shown to play a role in animal models of aPL-induced foetal loss (Chaouat, 2007). Intraperitoneal injections of large amounts of human IgG with aPL activity to pregnant naive mice after embryo implantation induce considerable placental inflammatory damage that results in foetal loss and growth retardation. An inflammation-mediated aPL damage has also been demonstrated by immunohistochemical and histological examination of murine deciduas, showing deposition of human IgG and mouse complement, neutrophil infiltration and local TNF secretion, in association with a transient but significant increase in blood TNF levels (Holers et al., 2002; Girardi et al., 2003; Berman et al., 2005). Furthermore, it has been demonstrated that in response to aPL-generated C5a, neutrophils express TF potentiating inflammation in the deciduas and leading to miscarriages in mice (Figure 3). Importantly, TF in myeloid cells, but not trophoblasts, seem to be associated with foetal injury, suggesting that the site for pathologic TF expression is neutrophils (Redecha et al., 2007). The pathogenic mechanism of complement-mediated foetal loss induced by aPL is also supported by the protection that deficiency in complement components confers on the animals, or that follows from *in vivo* inhibition of complement (Thurman et al., 2005; Girardi et al., 2006).

In another experimental model of foetal loss, mice deficient in chemokine-binding protein D6, a placental receptor that recognizes the majority of inflammatory CC chemokines and targets them for degradation, were more susceptible to foetal loss when passively infused with a small amount of human aPL IgG than wild-type mice or mice infused with normal IgG (Martinez de la Torre et al., 2007). Altogether, these findings suggest that a local acute inflammatory response might have a role in experimental aPL-mediated foetal loss.

Although C4d and C3b fragments have been shown to be deposited in the placentas of patients with APS, analysis of abortive material or full-term placentae from women with APS has not provided conclusive information about the pathogenic contributions of acute local inflammatory events and complement deposition (Park, 2006; Shamonki et al., 2007). In order to confirm this hypothesis more studies on human placentas are required.

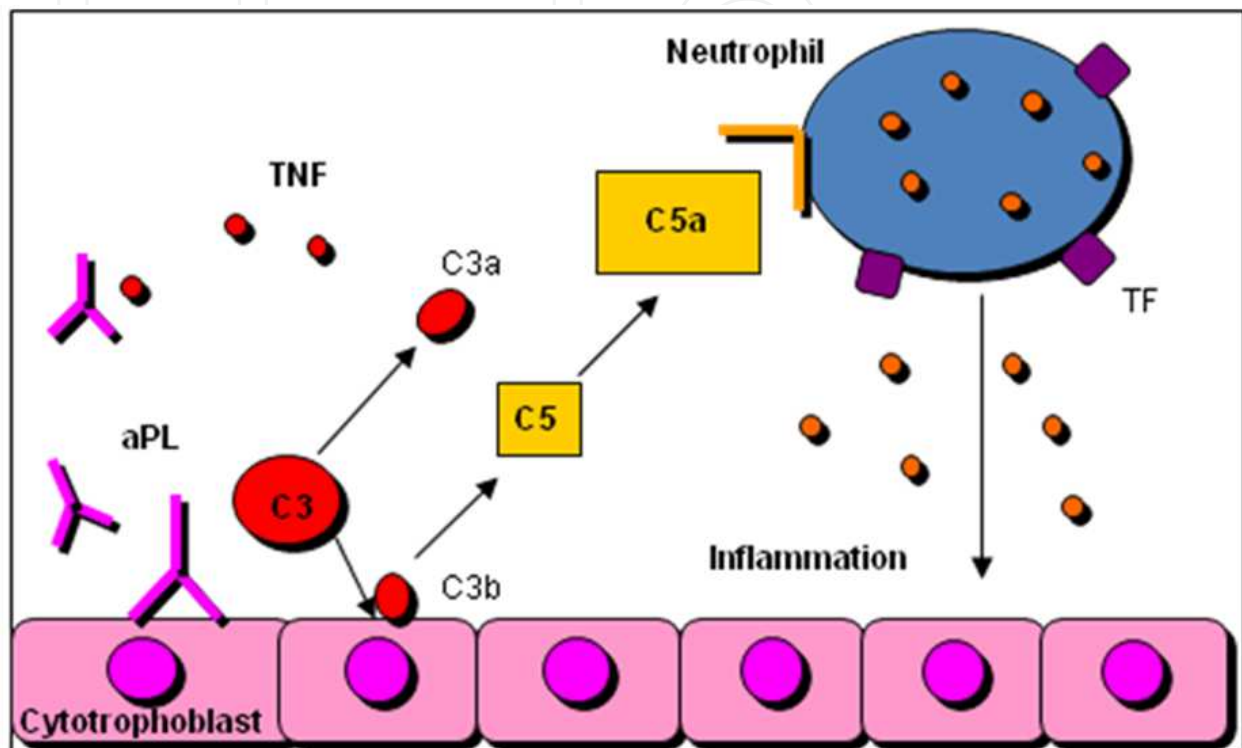


Fig. 3. aPL-mediated activation of complement system and foetal loss.

Endothelial cells, activated by aPL, express adhesion molecules and activated platelets increase expression of glycoprotein IIb-IIIa and synthesis of thromboxane A₂, determining a procoagulant state (first hit). The occurrence of a second hit, like inflammation, can lead to clot formation.

5. Pregnancy management

Women with APS should be carefully managed by the physician during pregnancy. A clinical manifestations of APS associated to a high risk for maternal health in pregnancy is severe pulmonary hypertension, representing a contraindication to pregnancy. Furthermore, women with APS should be suggested to delay pregnancy when uncontrolled increase of blood pressure or recent thrombotic events have occurred (Ruiz-Irastorza et al., 2008, 2010). More than 70% of pregnant women with APS properly managed will have a good pregnancy outcome (Bramhan et al., 2010). However, a complete profile of aPL should be performed before planning of pregnancy. These tests do not need to be repeated during pregnancy, since subsequent negative results after diagnosis do not eliminate the risk of complications (Ruiz-Irastorza et al., 2008, 2010). Frequent prenatal visits and obstetric ultrasound, every 2-4 weeks, should be done in order to early detect pregnancy

complications like maternal hypertension, proteinuria and other features of preeclampsia, placental insufficiency, foetal loss, foetal growth restriction and the need for iatrogenic preterm birth (Branch & Khamashta, 2003). Surveillance testing should begin at 32 weeks' gestation, or earlier if placental insufficiency is suspected, and should continue at least every week until delivery. Uterine and umbilical artery Doppler assessments are used for the high risk for preeclampsia, placental insufficiency, and foetal growth restriction after the 24th week of gestation in this category of patients and normal examinations have high negative predictive values (Le Thi Huong et al., 2006).

Nowadays, despite the controversies raised by clinical trials (Kutteh, 1996; Rai et al., 1997; Farquharson et al., 2002; Laskin et al., 2009; Noble et al., 2005; Stephenson et al., 2004), the gold standard treatment of patients with APS and history of recurrent early miscarriage is a combination of either low-dose heparin or low-molecular weight heparin and low-dose aspirin (Empson et al., 2005, Bates et al., 2008). Best pregnancy outcomes are achieved with heparin started in the early first trimester when a live embryo is detectable by ultrasound. For pregnant women with APS who have had a previous thrombotic event, low-dose aspirin and therapeutic dose heparin or low-molecular weight heparin anticoagulation are recommended (Bates et al., 2008).

Results from randomised trials do not define optimum treatment for women with foetal death (>10 weeks' gestation) or previous early delivery (<34 weeks' gestation) due to severe preeclampsia or placental insufficiency. Most experts recommend low-dose aspirin and either prophylactic or intermediate-dose heparin (Branch & Khamashta, 2003; Empson et al., 2005; Bates et al., 2008).

Use of glucocorticoids to treat pregnant women with APS have been shown to be less effective than heparin plus aspirin (Silver et al., 1993; Cowchock et al., 1992) as well as administration of intravenous immunoglobulins, either when added to heparin or used alone, do not ameliorate pregnancy outcome. However, intravenous immunoglobulins treatment should be considered whether classic treatment with aspirin plus heparin is not effective (Triolo et al., 2003; Branch et al., 2000; Vaquero et al., 2001), although it has been associated to an increased risk of pregnancy loss or premature birth, compared with heparin and low-dose aspirin (Empson et al., 2005).

Vitamin K antagonists (warfarin) are the gold standard treatment of APS clinically manifested with thromboses but, because of teratogenic risk, should be avoided between 6 and 12 weeks' of gestation. To avoid risk of foetal bleeding, warfarin after 12 weeks' gestation should be given only in exceptional circumstances (Bates et al., 2008; Østensen et al., 2004). Furthermore, women with APS should be treated with antithrombotic drug also during the post-partum period (Bates et al., 2008). Women with history of thrombosis need long-term anticoagulation, and it would be better to switch the treatment to warfarin, as soon as possible after delivery. In patients with no previous thrombosis, prophylactic dose heparin or low-molecular-weight heparin therapy for 6 weeks after delivery are recommended (Bates et al., 2008). Finally, both heparin and warfarin are safe for breastfeeding mothers (Østensen et al., 2004).

6. Conclusions

Although modern management and treatment of APS in pregnancy significantly ameliorate pregnancy outcome, more efforts are needed in order to unravel aPL-mediated pathogenic mechanisms still not understood and to open new perspective of therapies of this complex and multifactorial syndrome.

7. References

- Amigo M.C., Garcia-Torres R., Robles M., Bochicchio T. & Reyes P.A. (1992). Renal involvement in primary antiphospholipid syndrome. *J Rheumatol*, Vol. 19, No. 8, (Aug 1992), pp. 1181-1185.
- Bates S.M., Greer I.A., Pabinger I., Sofaer S. & Hirsh J; American College of Chest Physicians. (2008). Venous thromboembolism, thrombophilia, antithrombotic therapy, and pregnancy: American College of Chest Physicians Evidence-Based Clinical Practice Guidelines (8th edn). *Chest*, Vol. 133, No. 6 (Jun 2008), pp. 844 - 886.
- Berman J., Girardi G. & Salmon J.E. (2005). TNF- α is a critical effector and a target for therapy in antiphospholipid antibody-induced pregnancy loss. *J Immunol*, Vol. 174, No. 1, (Jan 2005), pp. 485-490.
- Bramham K., Hunt B.J., Germain S., Calatayud I., Khamashta M., Bewley S. & Nelson-Piercy C. (2010). Pregnancy outcome in different clinical phenotypes of antiphospholipid syndrome. *Lupus*, Vol. 19, No. 1, (Jan 2010), pp. 58 - 64.
- Branch D.W., Peaceman A.M., Druzin M., Silver RK, El-Sayed Y., Silver R.M., Esplin M.S., Spinnato J. & Harger J. (2000). Peaceman AM, Druzin M, et al. A multicenter, placebo-controlled pilot study of intravenous immune globulin treatment of antiphospholipid syndrome during pregnancy. *Am J Obstet Gynecol*, Vol. 182, No. 1, (Jan 2000), pp. 122-127.
- Branch D.W. & Khamashta M.A. (2003). Antiphospholipid syndrome: Obstetric diagnosis, management and controversies. *Obstet Gynecol*, Vol. 101, No. 6, (Jun 2003), pp. 1333-1344.
- Cervera R., Piette J.C., Font J., Khamashta M.A., Shoenfeld Y., Camps M.T., Jacobsen S., Lakos G., Tincani A., Kontopoulou-Griva I., Galeazzi M., Meroni P.L., Derksen R.H., de Groot P.G., Gromnica-Ihle E., Baleva M., Mosca M., Bombardieri S., Houssiau F., Gris J.C, Quéré I., Hachulla E., Vasconcelos C., Roch B., Fernández-Nebro A., Boffa M.C., Hughes G.R. & Ingelmo M. Euro-Phospholipid Project Group. (2002). Antiphospholipid syndrome: clinical and immunologic manifestations and patterns of disease expression in a cohort of 1,000 patients. *Arthritis Rheum*, Vol. 46, No.4, (Apr 2002), pp. 1019-1027.
- Chaouat G. (2007). The Th1/Th2 paradigm: still important in pregnancy? *Semin Immunopathol* Vol. 29, No. 2, (Jun 2007), pp. 95-113.
- Clark E.A., Silver R.M. & Branch D.W. (2007). Do antiphospholipid antibodies cause preeclampsia and HELLP syndrome? *Curr Rheumatol Rep*, Vol. 9, No. 3, (Jun 2007), pp. 219-225.
- Cowchock F.S., Reece E.A., Balaban D., Branch D.W. & Plouffe L. (1992). Repeated foetal losses associated with antiphospholipid antibodies: a collaborative randomized trial comparing prednisone with low-dose heparin. *Am J Obstet Gynecol*, Vol. 166, No. 5, (May 1992), pp. 1318-1323.
- de Groot P.G. & Derksen R.H. Pathophysiology of the antiphospholipid syndrome. *J Thromb Haemost*, Vol. 3, No. 8, (Aug 2005), pp. 1854-1860.
- Di Simone N., Meroni P.L., de Papa N., Raschi E., Caliandro D., De Carolis C.S., Khamashta M.A., Atsumi T., Hughes G.R., Balestrieri G., Tincani A., Casali P. & Caruso A. (2000). Antiphospholipid antibodies affect trophoblast gonadotropin secretion and

- invasiveness by binding directly and through adhered beta2-glycoprotein I. *Arthritis Rheum*, Vol. 43, No. 1, (Jan 2000), pp. 140-150.
- Di Simone N., Marana R., Castellani R., Di Nicuolo F., D'Alessio M.C., Raschi E., Borghi M.O., Chen P.P., Sanguinetti M., Caruso A. & Meroni P.L. (2010a). Decreased expression of heparin-binding epidermal growth factor-like growth factor as a newly identified pathogenic mechanism of antiphospholipid-mediated defective placentation. *Arthritis Rheum*, Vol. 62, No. 5, (May 2010), pp. 1504-1512.
- Di Simone N., Di Nicuolo F., D'Ippolito S., Castellani R., Tersigni C., Caruso A., Meroni P. & Marana R. (2010b). Antiphospholipid antibodies affect human endometrial angiogenesis. *Biol Reprod*, Vol. 83, No. 2, (Aug 2010), pp. 212-219.
- Empson M., Lassere M., Craig J. & Scott J. (2005). Prevention of recurrent miscarriage for women with antiphospholipid antibody or lupus anticoagulant. *Cochrane Database Syst Rev*, Vol. 18, No. 2, (Apr 2005), CD002859.
- Farquharson R.G., Quenby S. & Greaves M. (2002). Antiphospholipid syndrome in pregnancy: a randomized, controlled trial of treatment. *Obstet Gynecol*, Vol. 100, No. (2002), pp. 408 - 413.
- Francès C., Niang S., Laffitte E., Pelletier F., Costedoat N. & Piette J.C. (2005). Dermatologic manifestations of the antiphospholipid syndrome: two hundred consecutive cases. *Arthritis Rheum*, Vol. 52, No. 6, (Jun 2005), pp. 1785-93.
- Galli M., Luciani D., Bertolini G. & Barbui T. (2003). Anti-beta 2-glycoprotein I, antiprothrombin antibodies, and the risk of thrombosis in the antiphospholipid syndrome. *Blood*, 2003, Vol. 102, No. 8, (Oct 2003), pp. 2717-2723.
- Girardi G., Berman J., Redecha P., Spruce L., Thurman J.M., Kraus D., Hollmann T.J., Casali P., Carroll M.C., Wetsel R.A., Lambris J.D., Holers V.M. & Salmon J.E. (2003). Complement C5a receptors and neutrophils mediate foetal injury in the antiphospholipid syndrome. *J Clin Invest*, Vol. 112, No. 11, (Dec 2003), pp. 1644-1654.
- Girardi G., Redecha P. & Salmon J.E. (2004). Heparin prevents antiphospholipid antibody-induced foetal loss by inhibiting complement activation. *Nat Med*, Vol. 10, No.11, (Nov 2004), pp. 1222-1226.
- Girardi G., Yarin D., Thurman J.M., Holers V.M. & Salmon J.E. (2006). Complement activation induces dysregulation of angiogenic factors and causes foetal rejection and growth restriction. *J Exp Med*, Vol. 203, No. 9, (Sep 2006), pp. 2165-2175.
- Hanly J.G., Hong C., Smith S. & Fisk J.D. (1999). A prospective analysis of cognitive function and anticardiolipin antibodies in systemic lupus erythematosus. *Arthritis Rheum*, Vol. 42, No.4, (Apr 1999), pp. 728-734.
- Holers V.M., Girardi G., Mo L., Guthridge J.M., Molina H., Pierangeli S.S., Espinola R., Xiaowei L.E., Mao D., Vialpando C.G. & Salmon J.E. (2002). Complement C3 activation is required for antiphospholipid antibody-induced foetal loss. *J Exp Med*, Vol. 195, No. 2, (Jan 2002), pp. 211-220.
- Hughes, G.R.V. (1993) The antiphospholipid syndrome: ten years on. *Lancet*, Vol. 7, No. 342, (Aug 1993), pp. 341 - 344.
- Iwamoto R. & Mekada E. (2000). Heparin-binding EGF-like growth factor: a juxtacrine growth factor. *Cytokine Growth Factor Rev*, Vol. 11, No. 4, (Dec 2000), pp. 335-344.

- Katsuragawa H., Kanzaki H., Inoue T., Hirano T., Mori T. & Rote N.S. (1997). Monoclonal antibody against phosphatidylserine inhibits in vitro human trophoblastic hormone production and invasion. *Biol Reprod*, Vol. 56, No. 1, (Jan 1997), pp. 50-58.
- Khamashta M.A., Cervera R., Asherson R.A., Font J., Gil A., Coltart D.J., Vázquez J.J., Paré C., Ingelmo M. & Oliver J. (1990). Association of antibodies against phospholipids with heart valve disease in systemic lupus erythematosus. *Lancet*, Vol. 335, No. , (1990), pp. 1541-1544.
- Koniari I., Siminelakis S.N., Baikoussis N.G., Papadopoulos G., Goudevenos J. & Apostolakis E. (2010). Antiphospholipid syndrome; its implication in cardiovascular diseases: a review. *J Cardiothorac Surg*, Vol. 5, No. 101 (Nov 2010), pp. 1-10.
- Kutteh W.H. (1996). Antiphospholipid antibody-associated recurrent pregnancy loss: treatment with heparin and low-dose aspirin is superior to low-dose aspirin alone. *Am J Obstet Gynecol*, Vol. 174, No. (1996), pp. 1584 - 1589.
- Laskin C.A., Spitzer K.A., Clark C.A., Crowther M.R., Ginsberg J.S., Hawker G.A., Kingdom J.C., Barrett J. & Gent M. (2009). Low molecular weight heparin and aspirin for recurrent pregnancy loss: results from the randomized, controlled HepASA trial. *J Rheumatol*, Vol. 36, No. (May 2009), pp. 279 - 287.
- Le Thi Huong D., Wechsler B., Vauthier-Brouzes D., Duhaut P., Costedoat N., Andreu M.R., Lefebvre G. & Piette J.C. (2006). The second trimester Doppler ultrasound examination is the best predictor of late pregnancy outcome in systemic lupus erythematosus and/or the antiphospholipid syndrome. *Rheumatology*, Vol. 45, No. 3, (Mar 2006), pp. 332-338.
- Leach R.E., Khalifa R., Ramirez N.D., Das S.K., Wang J., Dey S.K., Romero R. & Armant D.R. (1999). Multiple roles for heparin-binding epidermal growth factor-like growth factor are suggested by its cell-specific expression during the human endometrial cycle and early placentation. *J Clin Endocrinol Metab*, Vol. 84, No. 9, (Sep 1999), pp. 3355-63.
- Leach R.E., Romero R., Kim Y.M., Chaiworapongsa T., Kilburn B., Das S.K., Dey S.K., Johnson A., Qureshi F., Jacques S. & Armant D.R. (2002). Pre-eclampsia and expression of heparin-binding EGF-like growth factor. *Lancet* , Vol. 360, No. 9341, (Oct 2002), pp. 1215-1219.
- Lyden T.W., Vogt E., Ng A.K., Johnson P.M. & Rote N.S. (1992). Monoclonal antiphospholipid antibody reactivity against human placental trophoblast. *J Reprod Immunol*, Vol. 22, No. 1, (Jun 1992), pp. 1-14.
- Lopez-Pedrerá C., Cuadrado M.J., Herández V., Buendía P., Aguirre M.A., Barbarroja N., Torres L.A., Villalba J.M., Velasco F. & Khamashta M. (2008). Proteomic analysis in monocytes of antiphospholipid syndrome patients: Dereglulation of proteins related to the development of thrombosis. *Arthritis Rheum*, Vol. 58, No. 9, (Sep 2008), pp. 2835 - 2844.
- Martin K.L., Barlow D.H. & Sargent I.L. (1998). Heparin-binding epidermal growth factor significantly improves human blastocyst development and hatching in serum-free medium. *Hum Reprod*, Vol. 13, No. 6, (Jun 1998), pp. 1645-1652.
- Martinez de la Torre Y., Buracchi C., Borroni E.M., Dupor J., Bonecchi R., Nebuloni M., Pasqualini F., Doni A., Lauri E., Agostinis C., Bulla R., Cook D.N., Haribabu B., Meroni P., Rukavina D., Vago L., Tedesco F., Vecchi A., Lira S.A., Locati M. &

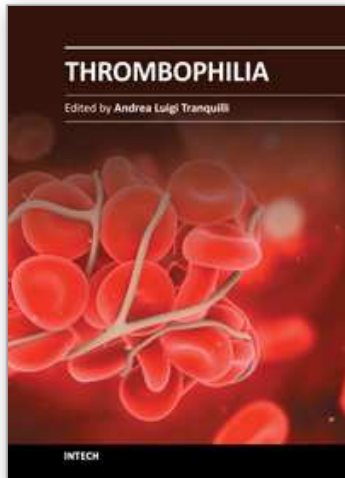
- Mantovani A. (2007). Protection against inflammation- and autoantibody-caused foetal loss by the chemokine decoy receptor D6. *Proc Natl Acad Sci*, Vol. 104, No. 7, (Feb 2007), pp. 2319-2324.
- Menon S., Jameson-Shortall E., Newman S.P., Hall-Craggs M.R., Chinn R. & Isenberg D.A. (2005). A longitudinal study of anticardiolipin antibody levels and cognitive functioning in systemic lupus erythematosus. *Arthritis Rheum*, Vol. 42, No.4, (Apr 1999), pp. 735-741.
- Meroni P.L., Borghi M.O., Raschi E., Ventura D., Sarzi Puttini P.C., Atzeni F., Lonati L., Parati G., Tincani A., Mari D. & Tedesco F. (2004). Inflammatory response and the endothelium. *Thromb Res*, Vol. 114, No.5-6, (2004), pp. 329-334.
- Meroni P.L., Tedesco F., Locati M., Vecchi A., Di Simone N., Acaia B., Pierangeli S.S. & Borghi M.O. (2010). Anti-phospholipid antibody mediated foetal loss: still an open question from a pathogenic point of view. *Lupus*, Vol. 19, No.4, (Apr 2010), pp. 453-456.
- Mok C.C., Tang S.S., To C.H. & Petri M. (2005). Incidence and risk factors of thromboembolism in systemic lupus erythematosus: a comparison of three ethnic groups. *Arthritis Rheum*, Vol. 52, No.9, (Sep 2005), pp. 2774-2782.
- Miyakis S., Lockshin M.D., Atsumi T., Branch D.W., Brey R.L., Cervera R., Derksen R.H., DE Groot P.G., Koike T., Meroni P.L., Reber G., Shoenfeld Y., Tincani A., Vlachoyiannopoulos P.G. & Krilis S.A. (2006). International consensus statement on an update of the classification criteria for definite antiphospholipid syndrome (APS). *J Thromb Haemost*, Vol. 4, No.2, (Feb 2006), pp. 295-306.
- Montiel-Manzano G., Romay-Penabad Z., Papalardo de Martínez E., Meillon-García L.A., García-Latorre E., Reyes-Maldonado E. & Pierangeli S.S. (2007). In vivo effects of an inhibitor of nuclear factor-kappa B on thrombogenic properties of antiphospholipid antibodies. *Ann N Y Acad Sci*, No. 1108, (Jun 2007), pp. 540-553.
- Nayar R. & Lage J.M. (1996). Placental changes in a first trimester missed abortion in maternal systemic lupus erythematosus with antiphospholipid syndrome; a case report and review of the literature. *Hum Pathol*, Vol. 27, No. 2, (Feb 1996), pp. 201-206.
- Noble L.S., Kutteh W.H., Lashey N., Franklin R.D. & Herrada J. (2005). Antiphospholipid antibodies associated with recurrent pregnancy loss: prospective, multicenter, controlled pilot study comparing treatment with low-molecular weight heparin versus unfractionated heparin. *Fertil Steril*, Vol. 83, No. (2005), pp. 684 - 690.
- Oshiro B.T., Silver R.M., Scott J.R., Yu H. & Branch D.W. (1996). Antiphospholipid antibodies and foetal death. *Obstet Gynecol*, Vol. 87, No. 4, Apr 1996), pp. 489 - 493.
- Østensen M., Khamashta M., Lockshin M., Parke A., Brucato A., Carp H., Doria A., Rai R., Meroni P., Cetin I., Derksen R., Branch W., Motta M., Gordon C., Ruiz-Irastorza G., Spinillo A., Friedman D., Cimaz R., Czeizel A., Piette J.C., Cervera R., Levy R.A., Clementi M., De Carolis S., Petri M., Shoenfeld Y., Faden D., Valesini G. & Tincani A. (2006). Anti-inflammatory and immunosuppressive drugs and reproduction. *Arthritis Res Ther*, Vol. 8, No. 3 (May 2006), pp. 209 - 227.
- Out H.J., Kooijman C.D., Bruinse H.W. & Derksen R.H. (1991). Histopathological finding from patient with intrauterine foetal death and antiphospholipid antibodies. *Eur J Obstet Gynecol*, Vol. 41, No. 3, (Oct 1991), pp. 179-186.

- Park A.L. (2006). Placental pathology in antiphospholipid syndrome, In: *Hughes' Syndrome*, Khamashta M. A. pp. 362-374, Springer-Verlag, London.
- Paria B.C., Ma W., Tan J., Raja S., Das S.K., Dey S.K. & Hogan B.L. (2001). Cellular and molecular responses of the uterus to embryo implantation can be elicited by locally applied growth factors. *Proc Natl Acad Sci U S A*, Vol. 98, No. 3, (Jan 2001), pp. 1047-1052.
- Peaceman, A.M. & Rehnberg, K.A. (1993). The effect of immunoglobulin G fractions from patients with lupus anticoagulant on placental prostacyclin and thromboxane production. *Am J Obstet Gynecol*, Vol. 169, No. 6, (Dec 1993), pp. 1403-1406
- Pierangeli S.S., Girardi G., Vega-Ostertag M., Liu X., Espinola R.G. & Salmon J. (2005). Requirement of activation of complement C3 and C5 for antiphospholipid antibody mediated thrombophilia. *Arthritis Rheum*, Vol. 52, No.7, (Jul 2005), pp. 2120-2124.
- Pierangeli S.S., Chen P.P., González E.B. (2006). Antiphospholipid antibodies and the antiphospholipid syndrome: an update on treatment and pathogenic mechanisms. *Curr Opin Hematol*, Vol. 13, No. 5, (Sep 2006), pp. 366-375.
- Pierangeli S.S., Chen P.P., Raschi E., Scurati S., Grossi C., Borghi M.O., Palomo I., Harris E.N. & Meroni P.L. (2008). Antiphospholipid antibodies and the antiphospholipid syndrome: pathogenic mechanisms. *Semin Thromb Hemost*, Vol. 34, No.3, (Apr 2008), pp. 236-250.
- Raab G. & Klagsbrun M. (1997). Heparin binding EGF growth factor. *Biochim Biophys Acta*, Vol. 1333, No. 3, (Dec 1997), pp. 179-99.
- Rai R.S., Regan L., Clifford K., Pickering W., Dave M., Mackie I., McNally T. & Cohen H. (1995). Antiphospholipid antibodies and β 2-glycoprotein-I in 500 women with recurrent miscarriage: results of a comprehensive screening approach. *Hum Reprod*, Vol. 10, No. 8, (Aug 1995), pp. 2001-2005.
- Rai R., Cohen H., Dave M. & Regan L. (1997). Randomised controlled trial of aspirin and aspirin plus heparin in pregnant women with recurrent miscarriage associated with phospholipid antibodies (or antiphospholipid antibodies). *BMJ*, Vol. 314, No. (1997), pp. 253 - 257.
- Rand, J.H., Wu X.X., Guller S., Gil J., Guha A., Scher J. & Lockwood C.J. (1994). Reduction of annexin-V (placental anticoagulant protein-I) on placental villi of women with antiphospholipid antibodies and recurrent spontaneous abortion. *Am J Obstet Gynecol*, Vol. 171, No. 6, (Dec 1994), pp. 1566-1572.
- Rand, J.H., Wu X.X., Quinn A.S. & Taatjes D.J. (2010). The annexin A5-mediated pathogenic mechanism in the antiphospholipid syndrome: role in pregnancy losses and thrombosis. *Lupus*, Vol. 19, No. 4, (Apr 2010), pp. 460-469.
- Redecha P., Tilley R., Tencati M., Salmon J.E., Kirchhofer D., Mackman N. & Girardi G. (2007). Tissue factor: a link between C5a and neutrophil activation in antiphospholipid antibody induced foetal injury. *Blood*, Vol. 110, No. 7, (Oct 2007), pp. 2423-2431.
- Rote N.S., Vogt E., DeVere G., Obringer A.R. & Ng A.K. (1998) The role of placental trophoblast in the pathophysiology of the antiphospholipid antibody syndrome. *Am J Reprod Immunol*, Vol. 39, No. 2, (Feb 1998), pp. 125-136.
- Ruiz-Irastorza G., Egurbide M.V., Ugalde J. & Aguirre C. (2004). High impact of antiphospholipid syndrome on irreversible organ damage and survival of patients

- with systemic lupus erythematosus. *Arch Intern Med*, Vol. 164, No. 1, (Jan 2004), pp. 77-82.
- Ruiz-Irastorza G. & Khamashta M.A. Lupus and pregnancy: ten questions and some answers. *Lupus*, Vol. 17, No. 5, (May 2008), pp. 416-420.
- Ruiz-Irastorza G., Crowther M., Branch W. & Khamashta M.A. (2010). Antiphospholipid syndrome. *Lancet*, Vol. 76, No. 9751, (Oct 2010), pp. 1498-1509.
- Sanna G., Bertolaccini M.L., Cuadrado M.J., Khamashta M.A. & Hughes G.R. (2003). Central nervous system involvement in the antiphospholipid (Hughes) syndrome. *Rheumatology*, Vol. 42, No. 2, (Feb 2003), pp. 200 - 213.
- Shamonki J.M., Salmon J.E., Hyjek E. & Baergen R.N. Excessive complement activation is associated with placental injury in patients with antiphospholipid antibodies. *Am J Obstet Gynecol*, Vol. 196, No. 2, (Feb 2007), p. 167. e1-5.
- Silver R.K., MacGregor S.N., Sholl J.S., Hobart J.M., Neerhof M.G. & Ragin A. (1993). Comparative trial of prednisone plus aspirin versus aspirin alone in the treatment of anticardiolipin antibody-positive obstetric patients. *Am J Obstet Gynecol*, Vol. 169, No. 6, (Dec 1993), pp. 1411 - 1417.
- Silver R.M. (2007). Foetal death. *Obstet Gynecol*, Vol. 109, No. 1, (Jan 2007), pp. 153-167.
- Smith G.C.S., Crossley J.A., Aitken D.A., Pell J.P., Cameron A.D., Connor J.M. & Dobbie R. (2004). First-trimester placentation and the risk of antepartum stillbirth. *JAMA*, Vol. 292, No. 18, (Nov 2004), pp. 2249 - 2254.
- Stephenson M.D., Ballem P.J., Tsang P., Purkiss S., Ensworth S., Houlihan E. & Ensom M.H. (2004). Treatment of antiphospholipid antibody syndrome (APS) in pregnancy: a randomized pilot trial comparing low molecular weight heparin to unfractionated heparin. *J Obstet Gynaecol Can*, Vol. 26, No. (2004), pp. 729 - 734.
- Stirrat G.M. (1990). Recurrent miscarriage I: definition and epidemiology. *Lancet*, Vol. 336, No. 8716, (Sep 1990), pp. 673-675.
- Tektonidou M.G., Sotsiou F., Nakopoulou L., Vlachoyiannopoulos P.G. & Moutsopoulos H.M. (2004). Antiphospholipid syndrome nephropathy in patients with systemic lupus erythematosus and antiphospholipid antibodies: prevalence, clinical associations, and long-term outcome. *Arthritis Rheum*, Vol. 50, No. 8, (Aug 2004), pp. 2596-2579.
- Tektonidou M.G., Varsou N., Kotoulas G., Antoniou A. & Moutsopoulos H.M. (2006). Cognitive deficits in patients with antiphospholipid syndrome: association with clinical, laboratory, and brain magnetic resonance imaging findings. *Arch Intern Med*, Vol. 166, No. 20, (Nov 2006), pp. 2278-2284.
- Tektonidou M.G., Laskari K., Panagiotakos D.B. & Moutsopoulos H.M. (2009). Risk factors for thrombosis and primary thrombosis prevention in patients with systemic lupus erythematosus with or without antiphospholipid antibodies. *Arthritis Rheum*, Vol. 61, No. 1, (Jan 2009), pp. 29-36.
- Thurman, J.M., Kraus D.M., Girardi G., Hourcade D., Kang H.J., Royer P.A., Mitchell L.M., Giclas P.C., Salmon J., Gilkeson G. & Holers V.M. (2005). A novel inhibitor of the alternative complement pathway prevents antiphospholipid antibody-induced pregnancy loss in mice. *Mol Immunol*, Vol. 42, No. 1, (Jan 2005), pp. 87-97.
- Triolo G., Ferrante A., Ciccia F., Accardo-Palumbo A., Perino A., Castelli A., Giarratano A. & Licata G. (2003). Randomized study of subcutaneous low molecular weight heparin plus aspirin versus intravenous immunoglobulin in the treatment of recurrent

- foetal loss associated with antiphospholipid antibodies. *Arthritis Rheum*, Vol. 166, No. 5, (Mar 2003), pp. 728-731.
- Vaquero E., Lazzarin N., Valensise H., Menghini S., Di Pierro G., Cesa F. & Romanini C. (2001). Pregnancy outcome in recurrent spontaneous abortion associated with antiphospholipid antibodies: a comparative study of intravenous immunoglobulin versus prednisone plus low-dose aspirin. *Am J Reprod Immunol*, Vol. 45, No. 3, (Mar 2001), pp. 174-179.
- Vega-Ostertag M., Casper K., Swerlick R., Ferrara D., Harris E.N. & Pierangeli SS. (2005). Involvement of p38 MAPK in the up-regulation of tissue factor on endothelial cells by antiphospholipid antibodies. *Arthritis Rheum*, Vol. 52, No. 5, (May 2005), pp. 1545-1554.
- Wang S.X., Sun Y.T. & Sui S.F. (2000). Membrane-induced conformational change in human apolipoprotein. *H Biochem J*, Vol. 348, (May 2000), pp. 103-106.
- Wang J., Mayernik L., Schultz J.F. & Armant D.R. (2000). Acceleration of trophoblast differentiation by heparinbinding EGF-like growth factor is dependent on the stage-specific activation of calcium influx by ErbB receptors in developing mouse blastocysts. *Development*, Vol. 127, No. 1, (Jan 2000), pp. 33-44.
- Yetman D.L. & Kutteh W.H. (1996). Antiphospholipid antibody panels and recurrent pregnancy loss: prevalence of anticardiolipin antibodies compared with other antiphospholipid antibodies. *Fertil Steril*, Vol. 66, No. 4, (Oct 1996), pp. 540-546.

IntechOpen



Thrombophilia

Edited by Prof. Prof. Andrea Tranquilli

ISBN 978-953-307-872-4

Hard cover, 226 pages

Publisher InTech

Published online 09, November, 2011

Published in print edition November, 2011

Thrombophilia(s) is a condition of increased tendency to form blood clots. This condition may be inherited or acquired, and this is why the term is often used in plural. People who have thrombophilia are at greater risk of having thromboembolic complications, such as deep venous thrombosis, pulmonary embolism or cardiovascular complications, like stroke or myocardial infarction, nevertheless those complications are rare and it is possible that those individuals will never encounter clotting problems in their whole life. The enhanced blood coagulability is exacerbated under conditions of prolonged immobility, surgical interventions and most of all during pregnancy and puerperium, and the use of estrogen contraception. This is the reason why many obstetricians-gynecologists became involved in this field aside the hematologists: women are more frequently at risk. The availability of new lab tests for hereditary thrombophilia(s) has opened a new era with reflections on epidemiology, primary healthcare, prevention and prophylaxis, so that thrombophilia is one of the hottest topics in contemporary medicine.

How to reference

In order to correctly reference this scholarly work, feel free to copy and paste the following:

Nicoletta Di Simone and Chiara Tersigni (2011). Adverse Pregnancy Outcome in Antiphospholipid Antibodies Syndrome: Pathogenic Mechanisms and Clinical Management, Thrombophilia, Prof. Prof. Andrea Tranquilli (Ed.), ISBN: 978-953-307-872-4, InTech, Available from:

<http://www.intechopen.com/books/thrombophilia/adverse-pregnancy-outcome-in-antiphospholipid-antibodies-syndrome-pathogenic-mechanisms-and-clinical>

INTECH
open science | open minds

InTech Europe

University Campus STeP Ri
Slavka Krautzeka 83/A
51000 Rijeka, Croatia
Phone: +385 (51) 770 447
Fax: +385 (51) 686 166
www.intechopen.com

InTech China

Unit 405, Office Block, Hotel Equatorial Shanghai
No.65, Yan An Road (West), Shanghai, 200040, China
中国上海市延安西路65号上海国际贵都大饭店办公楼405单元
Phone: +86-21-62489820
Fax: +86-21-62489821

© 2011 The Author(s). Licensee IntechOpen. This is an open access article distributed under the terms of the [Creative Commons Attribution 3.0 License](#), which permits unrestricted use, distribution, and reproduction in any medium, provided the original work is properly cited.

IntechOpen

IntechOpen