

# We are IntechOpen, the world's leading publisher of Open Access books Built by scientists, for scientists

**4,800**

Open access books available

**122,000**

International authors and editors

**135M**

Downloads

Our authors are among the

**154**

Countries delivered to

**TOP 1%**

most cited scientists

**12.2%**

Contributors from top 500 universities



**WEB OF SCIENCE™**

Selection of our books indexed in the Book Citation Index  
in Web of Science™ Core Collection (BKCI)

Interested in publishing with us?  
Contact [book.department@intechopen.com](mailto:book.department@intechopen.com)

Numbers displayed above are based on latest data collected.

For more information visit [www.intechopen.com](http://www.intechopen.com)



# Novel Insights Into Stenosis on Coronary Angiography—Outline of Functional Assessment of Stable Angina Patients with Angiographic Stenosis

Shinichiro Tanaka

*The Second Department of Internal Medicine,  
Gifu University Graduate School of Medicine, Gifu  
The Department of Cardiology,  
Gifu Prefectural General Medical Center, Gifu  
Japan*

## 1. Introduction

Coronary angiography is an invasive technique for imaging the coronary artery lumen and remains one of the most accurate methods for diagnosing coronary artery disease. Furthermore, this invasive technique is the standard method for guiding revascularization procedures such as percutaneous coronary intervention (PCI) and coronary-artery bypass graft (CABG), as well as for guiding stent placement during PCI. However, the degree of coronary stenosis is usually decided by visual estimation of the percentage diameter narrowing using the proximal assumed normal arterial as a reference. There is 20% variation among readings of experienced angiographers, and the same angiographer may even render a different interpretation at a time remote from the first reading. Borderline stenosis, or angiographic narrowing of 40 to 70%, does not always correspond to abnormal physiology and myocardial ischemia (1,2). For such lesions, noninvasive or direct physiological measurements of impaired flow validate the decision to initiate revascularization therapy. Though quantitative coronary angiography can be reproduced for assessment of coronary stenosis, the inability to determine the functional severity of coronary stenosis remains a limitation of coronary angiography.

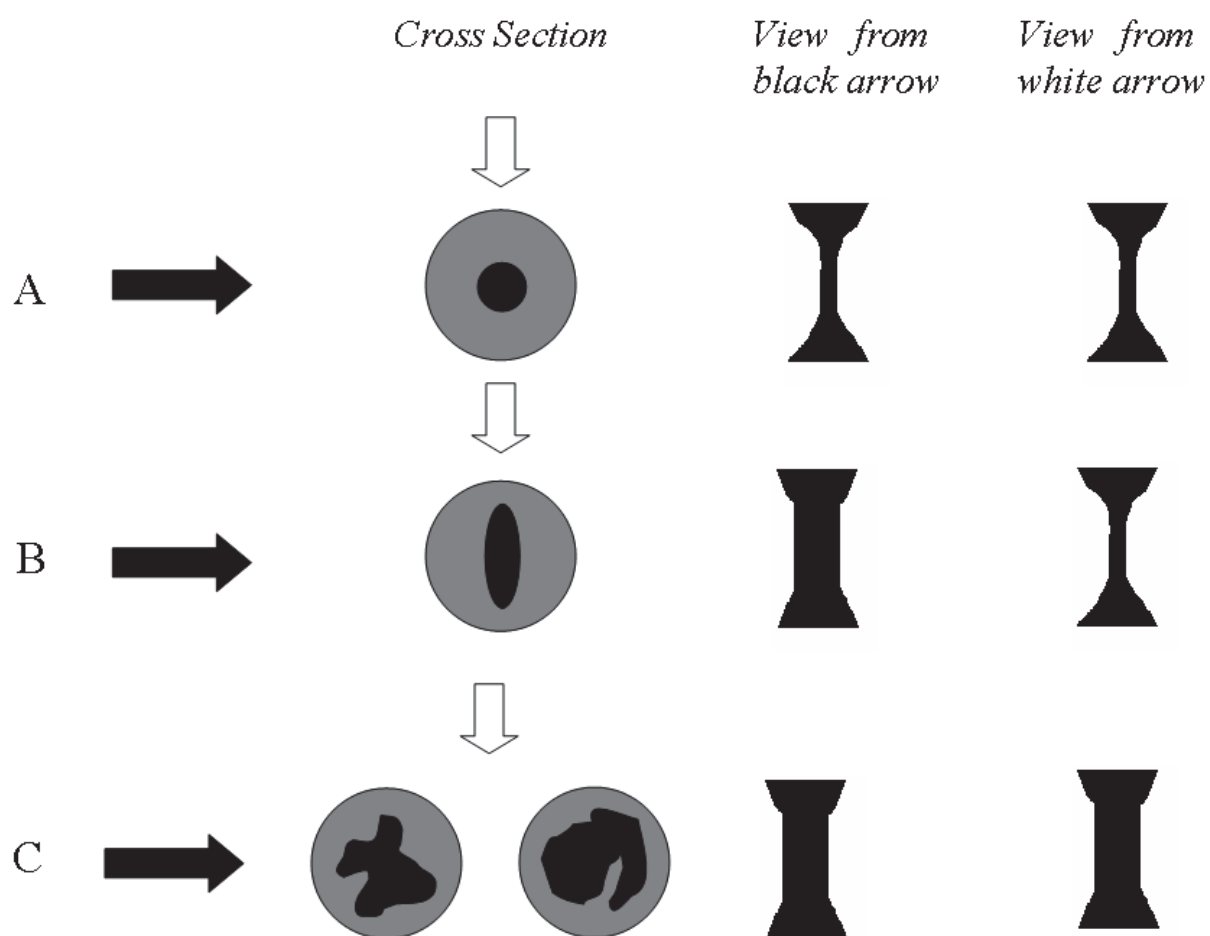
Intracoronary physiological parameters have been introduced to assess functional coronary lesion severity during cardiac catheterization. Measurement of coronary flow reserve (CFR; coronary flow velocity response to adenosine) and fractional flow reserve (FFR<sub>myo</sub>; coronary pressure-derived with adenosine) provide information about functional severity (3). Furthermore, FFR<sub>myo</sub>, which is calculated from coronary pressure measurements, is an invasive index used to identify a stenosis responsible for reversible ischemia (4,5,6).

For most patients with stable angina, the goal of treatment is complete, or nearly complete elimination of anginal chest pain and return to normal activities with a functional capacity corresponding to Canadian Cardiovascular Society (CCS) class I angina. This goal should be accomplished with minimal side effects, as well as with a reduced risk of mortality (7). The

topics of this chapter encompass the activities of daily life and functional stenosis in patients with angiographically demonstrated stenosis.

## 2. Functional severity

For coronary angiographic assessment employing cardiac catheterization, it should be noted that the stenotic lumen is compared to a nearby angiographically normal lumen, which may still show diffuse atherosclerotic disease. Furthermore, lesions containing diffuse, concentric, symmetrical disease, remodeling, or dissection, will be underestimated when disease severity is assessed (Fig.1). CFR and FFR<sub>myo</sub>, which provide information about functional severity, can be performed during cardiac catheterization.



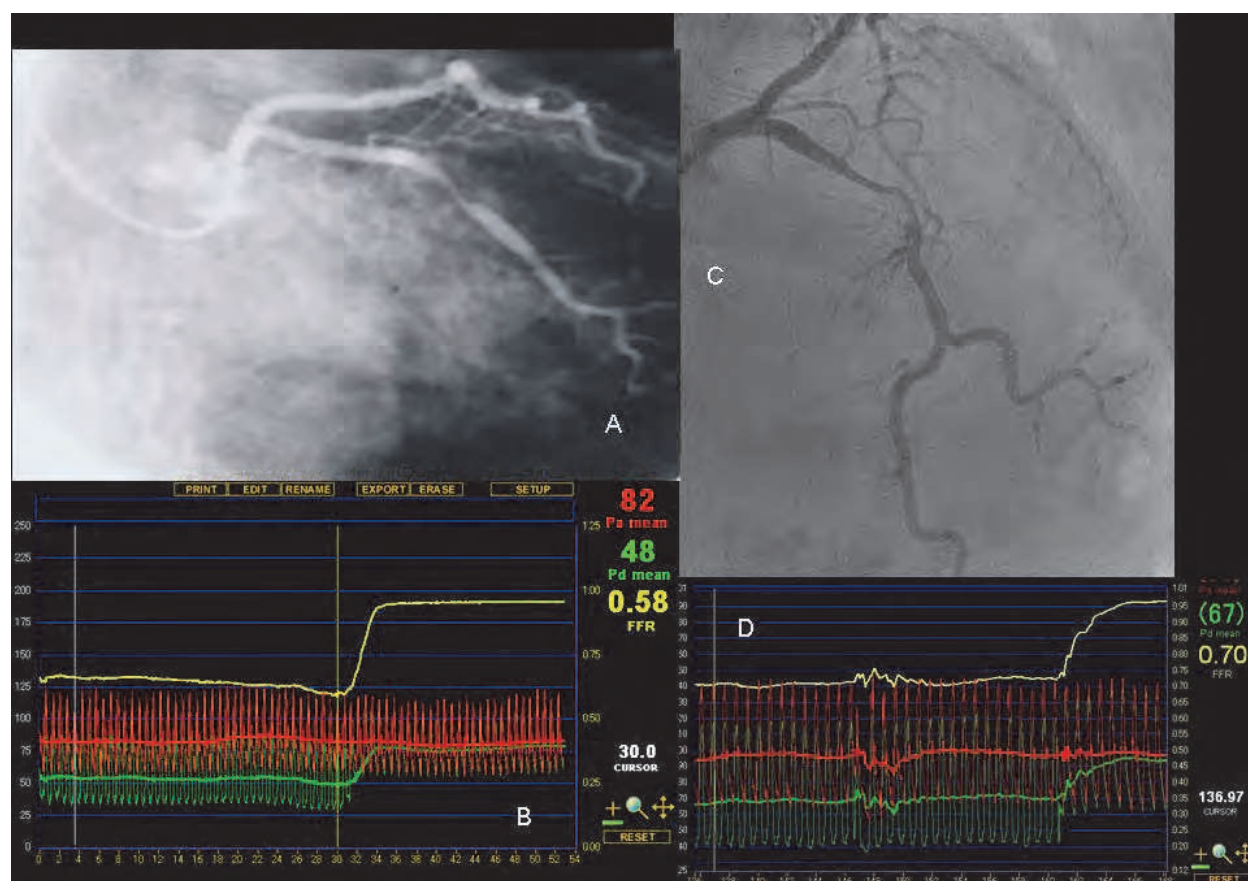
(A) Stenosis can be visualized from multiple angles. (B) Stenosis can be viewed as indicated by the white arrow, but is normally visualized as indicated by the black arrow. Stricture necessitates changing the angle. (C) Vascular conduits appear normal at all angles despite the existence of stenosis.

Fig. 1. Angiographic images and vascular conduits

CFR reflects both epicardial and microvascular disease but does not identify these entities by itself (8,9). Intra-coronary flow velocity can be measured with a 0.014-inch doppler guide wire during baseline measurements and maximum hyperemia which is induced by administering adenosine. CFR was calculated as the ratio of hyperemic to baseline of the average peak velocity (10,11). CFR can also be measured with a temperature sensor-tipped

guidewire, as the ratio of the inverse mean transit times obtained by thermodilution curves at baseline and during hyperemia (12,13,14). The parameters of CFR show agreement at a cut-off value of 2.0 (11,15).

On the other hand, FFRmyo is an accurate functional index of epicardial stenosis (4,5). Intra-coronary pressure can be measured with a 0.014-inch pressure-monitoring guidewire, which was first calibrated, then set to be equal with the aortic pressure in the guiding catheter, and finally positioned distal to the coronary lesion. Mean aortic and distal pressures were obtained during baseline measurements, and FFRmyo was calculated as the ratio of the mean distal pressure to the mean aortic pressure during maximum hyperemia (3,4,5). Although a previous report emphasized the importance of combining pressure and flow velocity measurements to evaluate coronary lesion severity and microvascular involvement (11), FFRmyo is a reliable index of the functional severity of coronary stenosis, and an FFRmyo value of 0.75 distinguishes stenoses associated with inducible ischemia from those that are not. Indeed, in patients with stable chest pain, the most important prognostic factor is the occurrence of myocardial ischemia reflected by an FFRmyo of  $< 0.75$  (5,6, Fig.2).

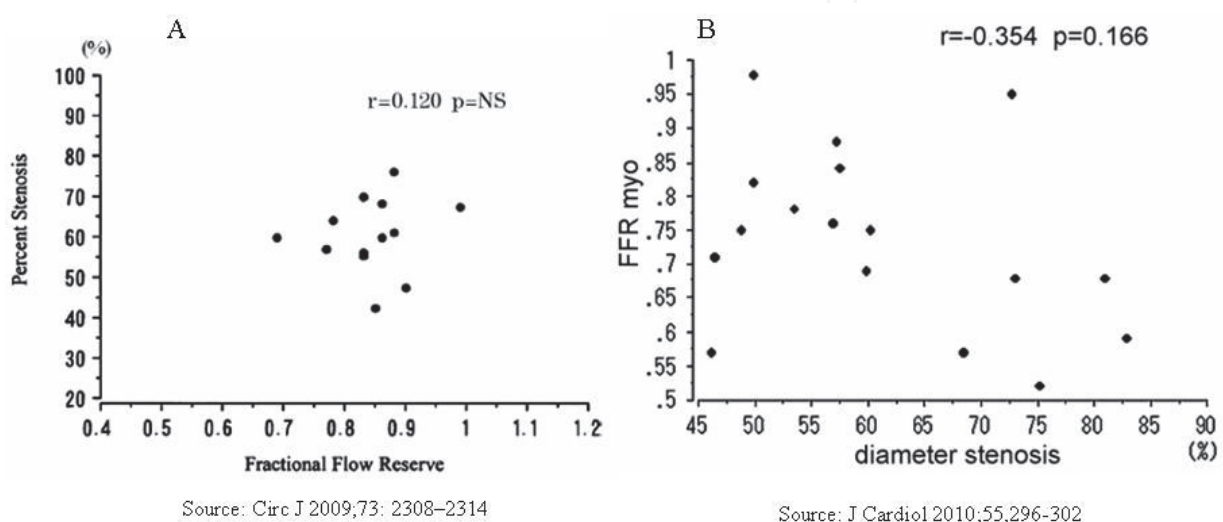


In the case on the left, angiographic stenosis was 56% in the left circumflex branch (LCX) by quantitative coronary angiography (A). During adenosine infusion, the wire was pulled back to track coronary pressure from the far distal LCX to the catheter, and after crossing the lesion produced a change in coronary pressure (FFRmyo = 0.58).

Likewise, in the case shown on the right, angiographic stenosis was 46% in left anterior descending branch (LAD) by quantitative coronary angiography (C), and FFRmyo = 0.70 (D)

Fig. 2. Representative case of FFRmyo

Even when treated with PCI, the clinical outcomes of these patients are significantly worse than those of patients with functionally insignificant stenoses ( $\text{FFR}_{\text{myo}} \geq 0.75$ ) (16,17). When  $\text{FFR}_{\text{myo}}$  was used to divide patients into a group in which stenosis was most likely to be physiologically significant ( $\text{FFR}_{\text{myo}} < 0.75$ ) and a group in which it was not, the overlap between the 2 groups in terms of angiographic severity was so large that it suggested angiography (16,17) could not be used to predict the absence or presence of inducible ischemia in individual patients (4,18, Fig.3). In fact, however, in patients with multivessel coronary artery disease undergoing PCI with drug eluting stents, routine measurement of FFR in addition to angiographic guidance, as compared with PCI guided by angiography alone, results in a significant reduction in major adverse events (19).



(A) The percent stenosis is likely to be physiological;  $\text{FFR}_{\text{myo}}$ . (B) The overlap between stenosis and  $\text{FFR}_{\text{myo}}$  was large.

Fig. 3. Variations in percent stenosis on coronary angiography and  $\text{FFR}_{\text{myo}}$

### 3. Functional capacity

The factors contributing to impaired exercise capacity appear to be multifactorial and include increasing age, sedentary lifestyle, depression, obesity and other comorbidities as well as impaired cardiovascular function. Poor exercise capacity is generally considered to be a predictor of mortality in patients with ischemic heart disease as well as all cause mortality (20,21). Traditional exercise tests such as the treadmill test or walking distance in 6 minutes are well-known methods for measurement of exercise capacity.

Additionally, self-assessed questionnaires, such as the Duke Activity Status INDEX (DASI) (22), the Specific Activity Questionnaire (SAQ) (23) and the Veterans Specific Activity Questionnaire (VSAQ) (24), can also measure exercise capacity as a well validated measure of functional capacity that can be expressed as metabolic equivalents (METs) and have been shown to correlate with adverse outcomes. Self-assessed questionnaires can be a simple and easy tool that contributes to the global risk assessment (10).

The cardiopulmonary exercise test (CPX) is useful for measurement of exercise capacity employing various parameters at each stage in a series of exercises (Fig.4). A symptom-limited incremental exercise test is usually performed using an upright, electromagnetically braked cycle ergometer or treadmill with measurement of breath-by-breath  $\text{VO}_2$ , carbon dioxide



production (VCO<sub>2</sub>) and minute ventilation (VE). This evaluates peak VO<sub>2</sub>, oxygen uptake at the anaerobic threshold (AT) and so on. A 12-lead electrocardiogram (ECG) and heart rate were continuously monitored throughout the test, and cuff blood pressure was measured every minute using an automatic manometer. CPX testing is more useful than self-assessed health status, which is subjective and can vary among patients depending upon symptom complexity and the unique perceptions, expectations and preferences of individuals (7).

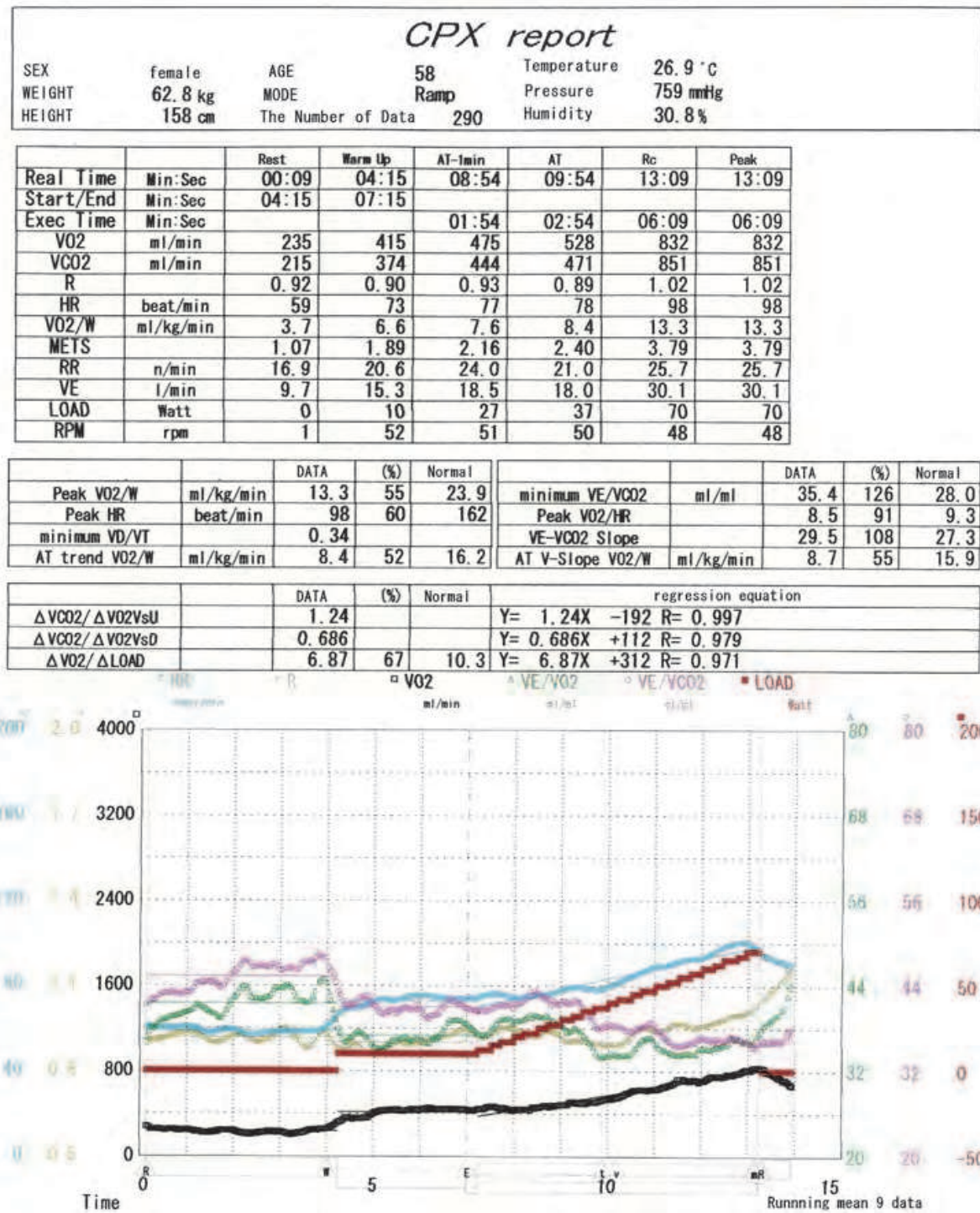


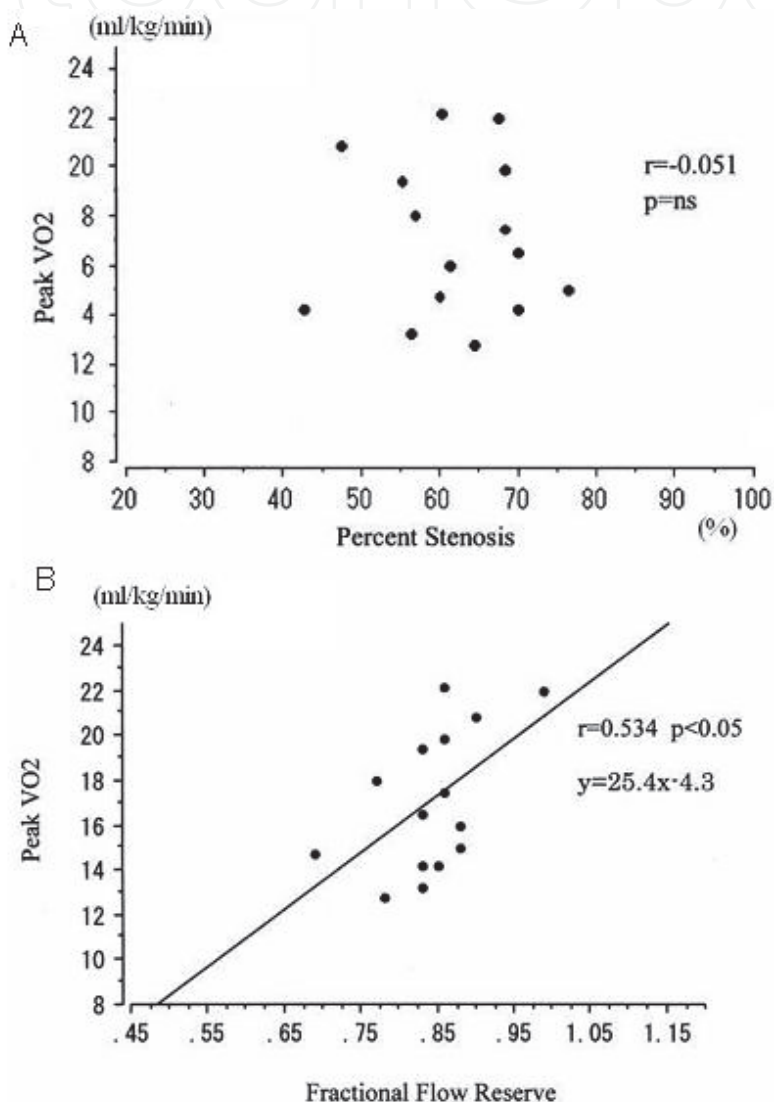
Fig. 4. Representative case of CPX

#### 4. Functional severity and exercise capacity in patients with angiographic stenosis

Coronary angiography employing cardiac catheterization has an important role in revascularization procedures such as PCI, and PCI has become a common initial management strategy for patients with stable angiographic stenosis. However, at present, the initial management strategy of patients with stenosis on coronary angiography should be to reduce not only the risks for major cardiac events but also to eliminate angina and allow a return to normal activities. Previous studies have shown that PCI does not reduce the long-term rates of death, myocardial infarction or other major cardiovascular events with compared to optimal medical therapy alone (25). PCI can provide an incremental benefit in quality of life compared with that provided by optimal medical therapy alone among patients with chronic coronary artery disease for approximately 24 months (26). Another previous study showed that in patients with stable coronary artery disease and an angiographically documented stenosis treatable by PCI, a 12-month exercise-training program resulted in a higher event-free survival rate and higher exercise capacity than standard PCI (27). Additionally, PCI significantly increased exercise capacity values such as AT and peak VO<sub>2</sub> in patients with peak VO<sub>2</sub> < 15 ml/kg/min, whereas it yielded no significant improvement in those with peak VO<sub>2</sub> ≥ 15 ml/kg/min (28). Based on these observations, the existence of stenosis on coronary angiography is an insufficient indication for revascularization. It has been reported that an increase in functional capacity as indicated by self-assessed questionnaire is associated with an increase in CFR, although 86% of subjects did not have significant stenosis on coronary angiography (10). Impaired overall functional capacity is independently associated with coronary microvascular dysfunction or endothelial dysfunction, among the most important determinants of myocardial ischemia. On the other hand, routine FFR<sub>myo</sub> measurement with angiographic guidance resulted in a significant reduction in major adverse cardiac effects, even when patients underwent PCI with drug-eluting stents (19). Furthermore, FFR<sub>myo</sub> is associated with inducible ischemia which other measures are not, thereby providing higher accuracy than for any other invasive or noninvasive test. According to the aforementioned reports, it seemed that the existence of stenosis on coronary angiography is a notwell validated measure of stable angina. FFR<sub>myo</sub> and functional capacity should be determined in stable angina patients with angiographic stenosis. Previously, we assessed the relationship between FFR<sub>myo</sub> and CPX values (4).

Our study subjects were 15 males (65.8±/−8.9 years old) with stable angina and 75% angiographic stenosis in one coronary artery. Eligible patients had no evidence of acute coronary syndromes, prior myocardial infarction, significant valvular heart disease, diabetes mellitus treated with insulin, smoking; or occupational, orthopedic and other conditions that precluded exercise. Neither did they have left main coronary artery stenosis > 25% or high-grade proximal left anterior descending artery stenosis with significant stenosis (> 75%) of other vessels, nor left ventricular angiography-based detection of abnormal wall motions such as asynergy or diffuse hypokinesis, or reduced left ventricular function (ejection fraction < 55%). The %diameter stenosis (%DS) was determined to be 61.7±/−9.1% based on quantitative coronary angiography. Mean FFR<sub>myo</sub> was 0.84±/−0.66, peak VO<sub>2</sub> was 17.1±/−3.2ml/kg/min and AT was 11.1±/−2.0ml/kg/min. There was no significant correlation between %DS and FFR<sub>myo</sub> ( $r = 0.12$ ,  $p = \text{ns}$ , Fig.3A), peak VO<sub>2</sub> ( $r = -0.051$ ,  $p = \text{ns}$ ) or AT ( $r = -0.013$ ,  $p = \text{ns}$ ). By contrast, there was a significant positive correlation (Fig.5) between FFR<sub>myo</sub> and peak VO<sub>2</sub> ( $r = 0.534$ ,  $p < 0.05$ ) and between FFR<sub>myo</sub> and AT ( $r =$

0.542,  $p < 0.05$ ). A previous study showed stable angina patients with impaired functional capacity as assessed by a CPX test to likely have reduced FFR<sub>myo</sub>. The present study also showed that an FFR<sub>myo</sub> value of 0.75 reflects stenoses associated with inducible ischemia and hence appears to correspond to a peak VO<sub>2</sub> value of 15.0. A cut-off value of FFR<sub>myo</sub> of 0.75 nearly matched the exercise capacity value (peak VO<sub>2</sub>; 15 ml/kg/min) improvement with PCI. As noted above, exercise capacity in patients with stable angina reflects functional rather than angiographic stenosis. Exercise training can improve myocardial perfusion, as revealed by myocardial scintigraphy, as well as maximal exercise capacity (27). Therefore, that study suggested that it may be possible to improve FFR<sub>myo</sub> by increasing exercise capacity through training.



(A) There is no correlation between angiographic stenosis and peak VO<sub>2</sub>. However, there is a positive correlation between FFR<sub>myo</sub> and peak VO<sub>2</sub> (B). (Source: Circ J 2009;73: 2308–2314)

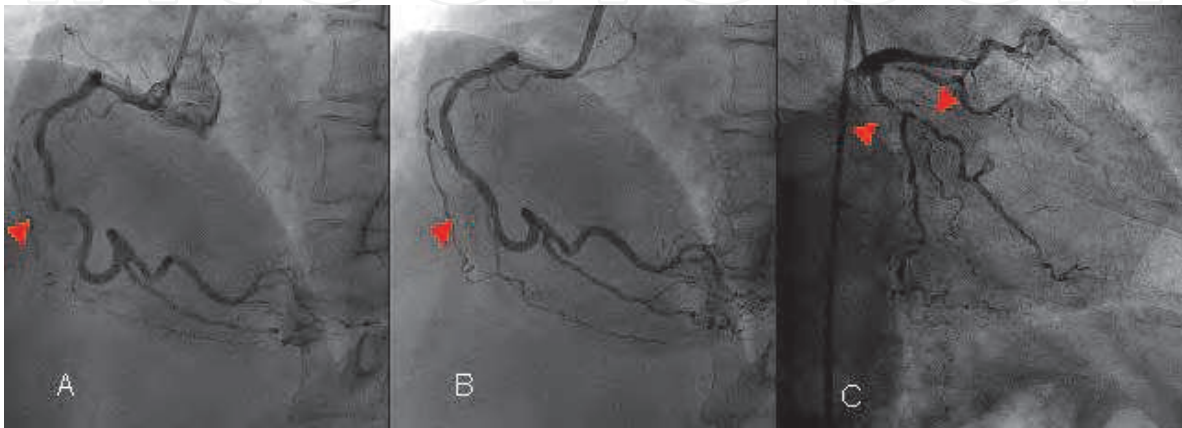
Fig. 5. Relationship between exercise capacity and stenosis.

#### 4.1 Case report

This is a representative case showing improvement in functional capacity despite the existence of angiographic stenosis.



A 58-year-old woman presented with unstable angina. Coronary angiography revealed 99% stenosis of the right coronary artery (RCA#3), and 75% stenosis (#11) and 90% stenosis (#12) of the left circumflex branch (LCX). She received stent implantation to #3 in the emergent stage (Fig.6). Thallium-201 scintigraphy with adenosine revealed ischemia in the LCX area (Fig.7A). PCI was recommended, but the patient refused because the condition was asymptomatic in her daily life. This patient did not wish to undergo revascularization of the LCX and continue to receive cardiac rehabilitation (physical training at AT level). Peak VO<sub>2</sub> increased from 13.3 ml/kg/min (Fig.4) to 16.8 ml/kg/min. Thallium-201 scintigraphy (Fig.7B) with adenosine documented improved myocardial perfusion distal to the LCX. (Ischemia area reduced from 13.7% to 8.75%)



There was (A) 99% stenosis of the right coronary artery (RCA #3) and a (B) stent was implanted. Left coronary angiography revealed 75% stenosis (#11) and 90% stenosis (#12) of the left circumflex branch (LCX).

Fig. 6. Coronary angiographies of case report

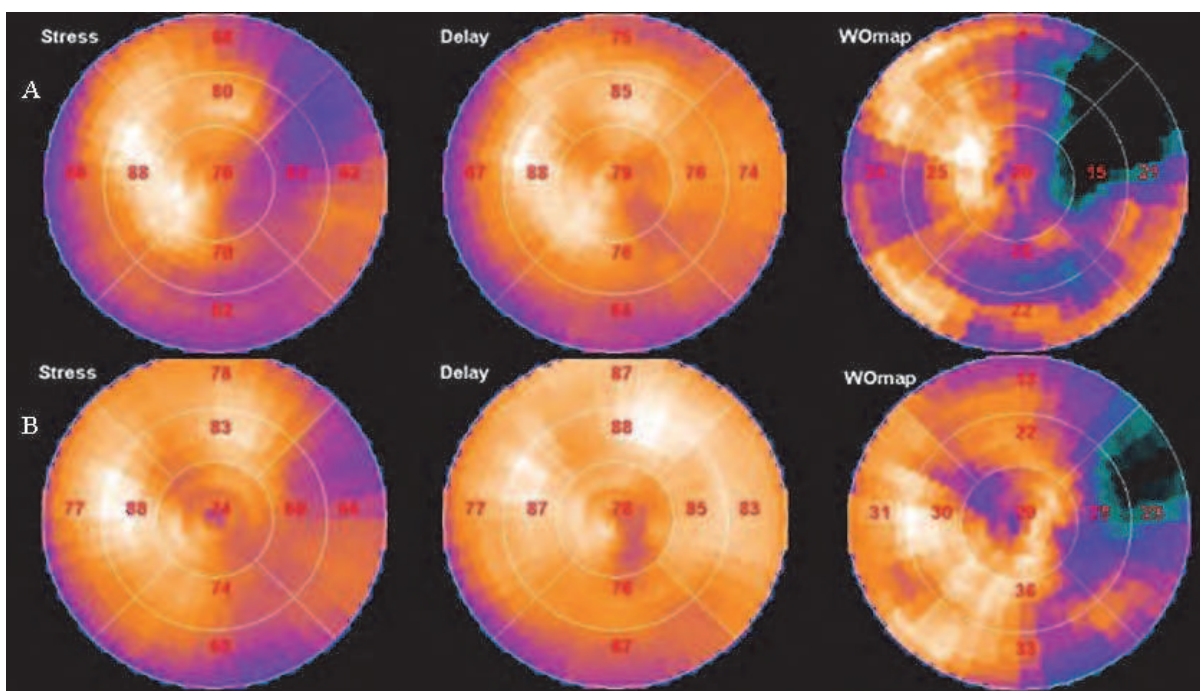
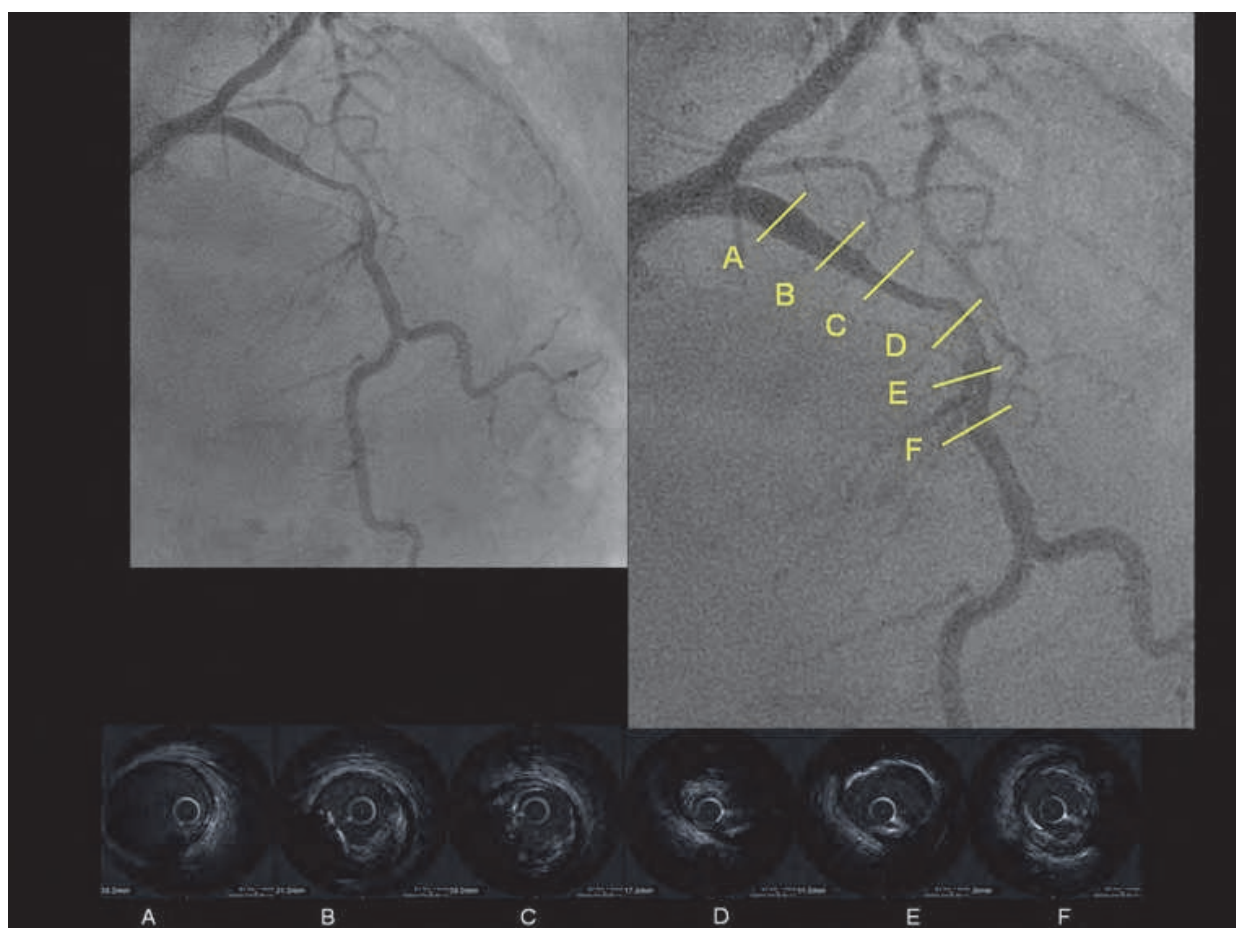


Fig. 7. Bull's eye image from thallium-201 single-photon emission computed tomography (A) pre-training (ischemic area 13.7%), and (B) post-training (ischemic area 8.75%)

### 5. Functional severity, exercise capacity and tissue characterization

Acute coronary syndrome is triggered by microscopic ulcerations of vulnerable atherosclerotic plaques. The majority of vulnerable plaques appear “angiographically insignificant” before their rupture (less than 75% diameter stenosis). In contrast, most of the “significant” plaques (greater than 75% stenosis) visualized at angiography are at low risk for plaque rupture (29).

Intravascular ultrasound (IVUS) allows cross-sectional imaging of coronary arteries and provides a more comprehensive assessment of the atherosclerotic plaques in vivo (30, Fig 8). Studies using IVUS have indicated that coronary atherosclerosis is underestimated when visually analyzing angiographic results owing to coronary compensatory remodeling and the diffuse nature of coronary atherosclerosis, which frequently makes the reference vessel appear normal angiographically (31).

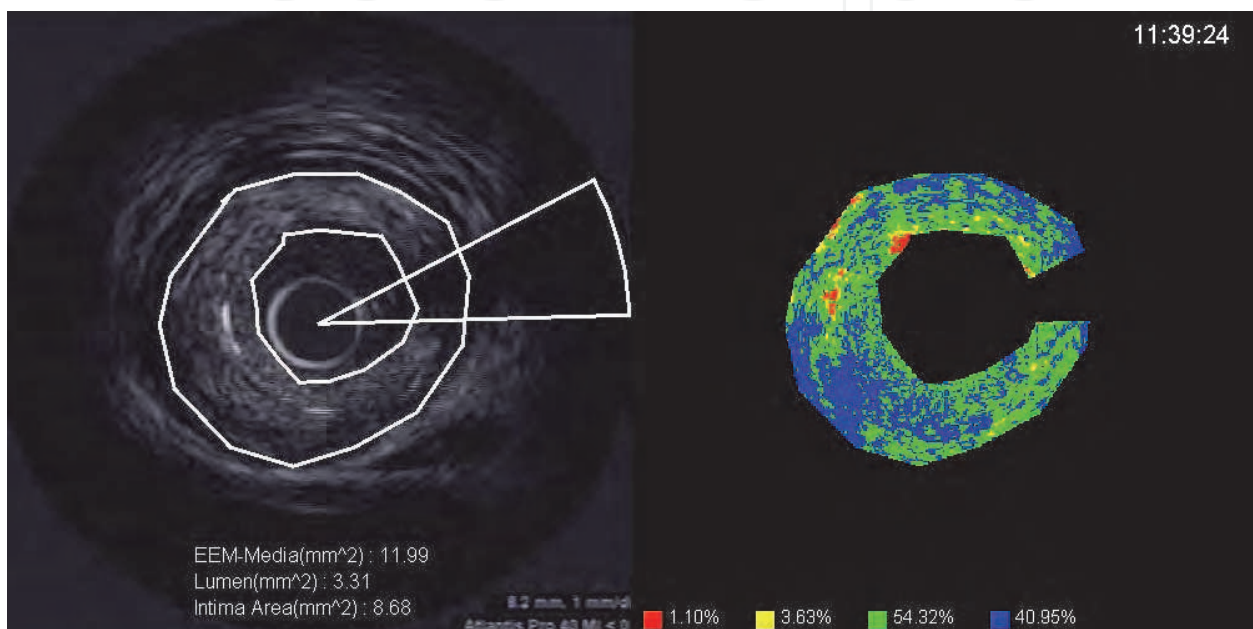


Intravascular ultrasound provides an image of an atheroma in a normal segment (B,E) as well as a stenotic lesion (C,D) on angiography

Fig. 8. Representative angiographic and IVUS images

An integrated backscatter intravascular ultrasound (IB-IVUS) system has been developed in which two-dimensional color-coded maps allowing plaque tissue characterization in coronary arteries can be constructed by computer (32,33). A computer equipped with IB-IVUS software is connected to the IVUS imaging system to obtain radio frequency signal output, signal trigger output, and video image output. IB is calculated as the average power

of the ultrasound backscattered signal from a small volume of tissue using fast Fourier transform measured in decibels (dB) (32). IB-IVUS is a useful method for analyzing coronary plaque tissue (Fig.9), which accurately and quantitatively differentiates among calcification, dense fibrosis, fibrosis and lipid components (33). IB-IVUS results previously suggested that classifying plaques as vulnerable or stable using this technique is an effective means of predicting acute coronary syndrome. When evaluated using IB-IVUS, plaques are deemed vulnerable when the lipid area is > 65% and the fibrotic area is < 25% (30). Thus, functional stenosis and tissue characterization may be linked to clinical outcome. Previously, we assessed the relationship between functional stenosis and the characterization of plaque tissue using FFRmyo and IB-IVUS (18).



The initial image was constructed by tracing the lumen and the external elastic membrane. In the color-coded map, red is calcification, yellow and green are fibrosis, and blue represents the lipid pool.

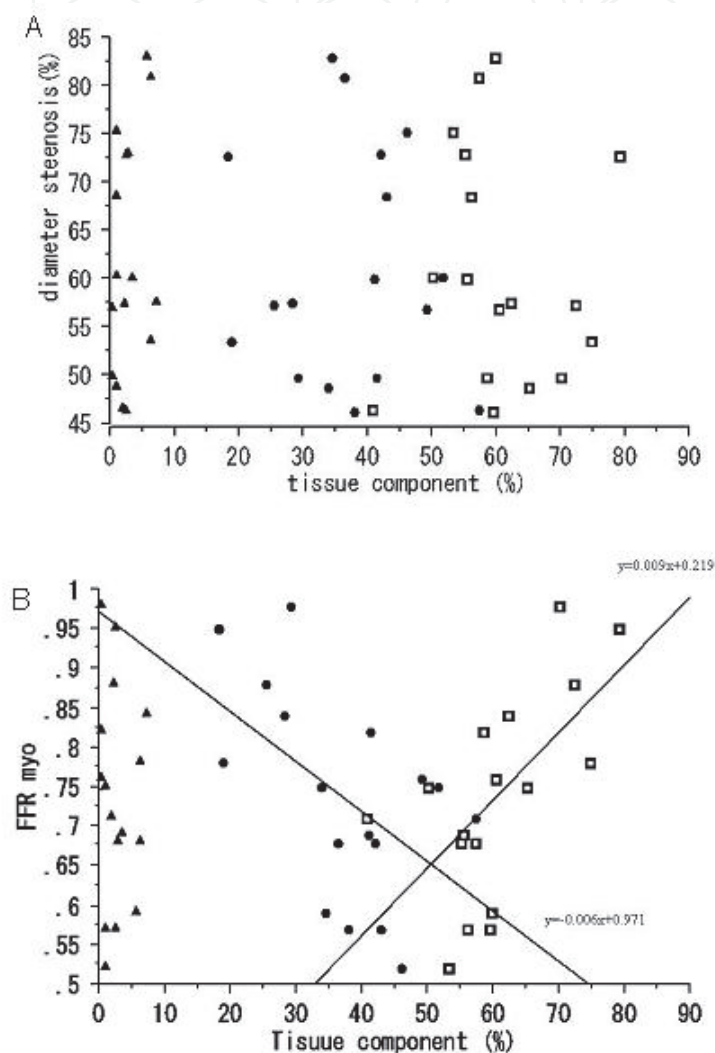
Fig. 9. Representative IB-IVUS images

We studied 17 lesions showing 75%-stenosis visually by coronary angiography in 17 stable angina patients (64.2+/-9.1 years old, 11 males). We found no correlation between FFRmyo and %DS ( $r = -0.354$ ,  $p = 0.166$ , Fig.3B). Nor was there a correlation between FFRmyo and plaque burden ( $r = -0.241$ ,  $p = 0.359$ , Fig.1B), or between FFRmyo and minimum lumen cross-sectional area ( $r = -0.002$ ,  $p = 0.995$ ). Likewise, neither %DS nor plaque burden correlated with the tissue characterization values (Figs.10A). There was no correlation between FFRmyo and %CA (calcification area) ( $r = -0.068$ ,  $p = 0.799$ ). By contrast, we observed a significant positive correlation between FFRmyo and %F ( $r = 0.620$ ,  $p = 0.0067$ ), and a significant negative correlation between FFRmyo and %LP (lipid pool area) ( $r = -0.524$ ,  $p = 0.0293$ ) (Fig.10B).

Our previous findings indicate that the tissue characteristics of coronary plaques in intermediate lesions affect functional stenosis. Fibrous tissue and FFRmyo also correlate positively. Lipid pool and FFRmyo correlate negatively. The apparently contradictory results obtained in this study might be explained by the progression of human atherosclerotic lesions leading to increasing fibrosis and stenosis. Distal pressure, additionally, decreases with the severity of coronary narrowing in the epicardial arteries,



contributing to the progression of atherosclerosis. However, intermediate or moderate lesions remain distinct in terms of functional and angiographic severity. The increase in fibrous tissue is likely an adaptive response to this distal pressure aimed at redistributing and modulating the mechanical stress (34). The increased fibrosis may also be an adaptive response to reduced elasticity of the arterial wall in the area of the lesion. An earlier in vivo study showed that elasticity in the area of stenosis can exacerbate the pressure drop across the lesion, thereby reducing flow (35).



(A) There was no correlation between angiographic stenosis and tissue characterization (B). There was a significant positive correlation between FFR<sub>myo</sub> and fibrosis, and a significant negative correlation between FFR<sub>myo</sub> and the lipid pool: ▲, %CA = percent calcification area; □, %F = percent fibrotic area; ●, %LP = percent lipid pool area. (Source: J. Cardiol; 2010 ;55,296–302)

Fig. 10. Relationship between stenosis and tissue characterization

Our studies showed that angina patients with reduced FFR<sub>myo</sub> are likely to have reduced functional capacity, and that the tissue characteristics of coronary plaques in intermediate lesions affect functional stenosis. According to these studies, high exercise capacity in patients with stable angiographic stenosis is linked to the stability of coronary plaques. Another report on coronary computed tomographic angiography indicated that coronary



plaque characteristics were identified in patients with progressively reduced exercise times, and that functional ischemia was more severe in those with mixed plaque. (36)


Thus, though coronary angiography is one of the most accurate methods for diagnosing coronary artery disease, comprehensive assessment of health status is necessary for stable angina patients with angiographic stenosis.

## 6. References

- [1] Zir LM, Miller SW, Dinsmore RE, Gilbert JP, Harthorne JW. Interobserver variability in coronary angiography. *Circulation*. 1976;53:627-32.
- [2] DeRouen TA, Murray JA, Owen W. Variability in the analysis of coronary arteriograms. *Circulation*. 1977;55:324-8.
- [3] Kern MJ, de Bruyne B, Pijls NH. From research to clinical practice: current role of intracoronary physiologically based decision making in the cardiac catheterization laboratory. *J Am Coll Cardiol*. 1997;30:613-20.
- [4] Tanaka S, Noda T, Segawa T, Minagawa T, Watanabe S, Minatoguchi S. Relationship between functional exercise capacity and functional stenosis in patients with stable angina and intermediate coronary stenosis. *Circ J*. 2009 ;73:2308-14.
- [5] Pijls NH, De Bruyne B, Peels K, Van Der Voort PH, Bonnier HJ, Bartunek J, Koolen JJ, Koolen JJ. Measurement of fractional flow reserve to assess the functional severity of coronary-artery stenoses. *N Engl J Med*. 1996;334:1703-8.
- [6] Pijls NH, Van Gelder B, Van der Voort P, Peels K, Bracke FA, Bonnier HJ, el Gamal MI. Fractional flow reserve. A useful index to evaluate the influence of an epicardial coronary stenosis on myocardial blood flow; *Circulation*. 1995;92:3183-93.
- [7] Tanaka S, Yokoyama C, Kawamura I, Takasugi N, Kubota T, Ushikoshi H, Aoyama T, Kawasaki M, Nishigaki K, Takemura G, Minatoguchi S. Conservative medication follow-up for over 20 years of a patient with ischemic heart disease after diagnosis of chronic total occlusion of the 3 main coronary arteries. *Circ J*. 2008;72:1205-9.
- [8] Albertal M, Regar E, Van Langenhove G, Carlier SG, Serrano P, Boersma E, Bruyne B, Di Mario C, Piek J, Serruys PW; DEBATE Investigators. Flow velocity and predictors of a suboptimal coronary flow velocity reserve after coronary balloon angioplasty. *Eur Heart J*. 2002;23:133-8.
- [9] Albertal M, Voskuil M, Piek JJ, de Bruyne B, Van Langenhove G, Kay PI, Costa MA, Boersma E, Beijsterveldt T, Sousa JE, Belardi JA, Serruys PW; Doppler Endpoints Balloon Angioplasty Trial Europe (DEBATE) II Study Group. Coronary flow velocity reserve after percutaneous interventions is predictive of periprocedural outcome. *Circulation*. 2002;105:1573-8.
- [10] Handberg E, Johnson BD, Arant CB, Wessel TR, Kerensky RA, von Mering G, Olson MB, Reis SE, Shaw L, Bairey Merz CN, Sharaf BL, Sopko G, Pepine CJ. Impaired coronary vascular reactivity and functional capacity in women: results from the NHLBI Women's Ischemia Syndrome Evaluation (WISE) Study; *J Am Coll Cardiol*. 2006 7;47: S44-9.
- [11] Meuwissen M, Chamuleau SA, Siebes M, Schotborgh CE, Koch KT, de Winter RJ, Bax M, de Jong A, Spaan JA, Piek JJ. Role of variability in microvascular resistance on fractional flow reserve and coronary blood flow velocity reserve in intermediate coronary lesions. *Circulation*. 2001;103:184-7.
- [12] Matsuo H, Watanabe S, Yasuda S, Hirose T, Iwama M, Tanaka S, Yamaki T, Ono K, Takahashi H, Segawa T, Matsuno Y, Minatoguchi S, Fujiwara H. Myocardial perfusion during transient slow-flow in the patient with old vein graft intervention: assessment by

- serial measurement of pressure-derived fractional flow reserve and thermodilution-derived coronary flow reserve. *Catheter Cardiovasc Interv.* 2003;60:392-8.
- [13] De Bruyne B, Pijls NH, Smith L, Wievegg M, Heyndrickx GR. Coronary thermodilution to assess flow reserve: experimental validation. *Circulation.* 2001;104:2003-6.
- [14] Pijls NH, De Bruyne B, Smith L, Aarnoudse W, Barbato E, Bartunek J, Bech GJ, Van De Vosse F. Coronary thermodilution to assess flow reserve: validation in humans. *Circulation.* 2002;105:2482-6.
- [15] Miller DD, Donohue TJ, Younis LT, Bach RG, Aguirre FV, Wittry MD, Goodgold HM, Chaitman BR, Kern MJ. Correlation of pharmacological <sup>99m</sup>Tc-sestamibi myocardial perfusion imaging with poststenotic coronary flow reserve in patients with angiographically intermediate coronary artery stenoses. *Circulation.* 1994;89:2150-60.
- [16] Bech GJ, De Bruyne B, Pijls NH, de Muinck ED, Hoorntje JC, Escaned J, Stella PR, Boersma E, Bartunek J, Koolen JJ, Wijns W. Fractional flow reserve to determine the appropriateness of angioplasty in moderate coronary stenosis: a randomized trial; *Circulation.* 2001;103:2928-34.
- [17] Pijls NH, van Schaardenburgh P, Manoharan G, Boersma E, Bech JW, van't Veer M, Bär F, Hoorntje J, Koolen J, Wijns W, de Bruyne B. Percutaneous coronary intervention of functionally nonsignificant stenosis: 5-year follow-up of the DEFER Study; *J Am Coll Cardiol.* 2007;49:2105-11.
- [18] Tanaka S, Noda T, Segawa T, Iwama M, Minagawa T, Watanabe S, Minatoguchi S. Relation between functional stenosis and tissue characterization of intermediate coronary plaques in patients with stable coronary heart disease. *J Cardiol.* 2010;55:296-302.
- [19] Tonino PA, De Bruyne B, Pijls NH, Siebert U, Ikeno F, van' t Veer M, Klauss V, Manoharan G, Engstrøm T, Oldroyd KG, Ver Lee PN, MacCarthy PA, Fearon WF; FAME Study Investigators. Fractional flow reserve versus angiography for guiding percutaneous coronary intervention. *N Engl J Med.* 2009 15;360:213-24.
- [20] Gulati M, Pandey DK, Arnsdorf MF, Lauderdale DS, Thisted RA, Wicklund RH, Al-Hani AJ, Black HR. Exercise capacity and the risk of death in women: the St James Women Take Heart Project. *Circulation.* 2003;108:1554-9.
- [21] Mora S, Redberg RF, Cui Y, Whiteman MK, Flaws JA, Sharrett AR, Blumenthal RS. Ability of exercise testing to predict cardiovascular and all-cause death in asymptomatic women: a 20-year follow-up of the lipid research clinics prevalence study. *JAMA.* 2003;290:1600-7.
- [22] Hlatky MA, Boineau RE, Higginbotham MB, Lee KL, Mark DB, Califf RM, Cobb FR, Pryor DB. A brief self-administered questionnaire to determine functional capacity (the Duke Activity Status Index). A brief self-administered questionnaire to determine functional capacity (the Duke Activity Status Index). *Am J Cardiol.* 1989;64:651-4.
- [23] Rankin SL, Briffa TG, Morton AR, Hung J. A specific activity questionnaire to measure the functional capacity of cardiac patients. *Am J Cardiol.* 1996;77:1220-3.
- [24] Myers J, Bader D, Madhavan R, Froelicher V. Validation of a specific activity questionnaire to estimate exercise tolerance in patients referred for exercise testing. *Am Heart J.* 2001;142:1041-6.
- [25] Boden WE, O'Rourke RA, Teo KK, Hartigan PM, Maron DJ, Kostuk WJ, Knudtson M, Dada M, Casperson P, Harris CL, Chaitman BR, Shaw L, Gosselin G, Nawaz S, Title LM, Gau G, Blaustein AS, Booth DC, Bates ER, Spertus JA, Berman DS, Mancini GB, Weintraub WS; COURAGE Trial Research Group. Optimal medical therapy with or without PCI for stable coronary disease. *N Engl J Med.* 2007;356:1503-16.
- [26] Weintraub WS, Spertus JA, Kolm P, Maron DJ, Zhang Z, Jurkovicz C, Zhang W, Hartigan PM, Lewis C, Veledar E, Bowen J, Dunbar SB, Deaton C, Kaufman S,

- O'Rourke RA, Goeree R, Barnett PG, Teo KK, Boden WE; COURAGE Trial Research Group, Mancini GB. Effect of PCI on quality of life in patients with stable coronary disease; *N Engl J Med*. 2008;359:677-87.
- [27] Hambrecht R, Walther C, Möbius-Winkler S, Gielen S, Linke A, Conradi K, Erbs S, Kluge R, Kendziorra K, Sabri O, Sick P, Schuler G. Percutaneous coronary angioplasty compared with exercise training in patients with stable coronary artery disease: a randomized trial. *Circulation*. 2004;109:1371-8.
- [28] Barmeyer A, Meinertz T. Anaerobic threshold and maximal oxygen uptake in patients with coronary artery disease and stable angina before and after percutaneous transluminal coronary angioplasty; *Cardiology*. 2002;98: 127-31.
- [29] Fraker TD Jr, Fihn SD; 2002 Chronic Stable Angina Writing Committee; American College of Cardiology; American Heart Association, Gibbons RJ, Abrams J, Chatterjee K, Daley J, Deedwania PC, Douglas JS, Ferguson TB Jr, Gardin JM, O'Rourke RA, Williams SV, Smith SC Jr, Jacobs AK, Adams CD, Anderson JL, Buller CE, Creager MA, Ettinger SM, Halperin JL, Hunt SA, Krumholz HM, Kushner FG, Lytle BW, Nishimura R, Page RL, Riegel B, Tarkington LG, Yancy CW. 2007 chronic angina focused update of the ACC/AHA 2002 guidelines for the management of patients with chronic stable angina: a report of the American College of Cardiology/American Heart Association Task Force on Practice Guidelines Writing Group to develop the focused update of the 2002 guidelines for the management of patients with chronic stable angina. *J Am Coll Cardiol*. 2007;50:2264-74.
- [30] Sano K, Kawasaki M, Ishihara Y, Okubo M, Tsuchiya K, Nishigaki K, Zhou X, Minatoguchi S, Fujita H, Fujiwara H. Assessment of vulnerable plaques causing acute coronary syndrome using integrated backscatter intravascular ultrasound. *J Am Coll Cardiol*. 2006;47:734-41.
- [31] Nissen SE, Yock P. Intravascular ultrasound: novel pathophysiological insights and current clinical applications. *Circulation*. 2001;103:604-16.
- [32] Kawasaki M, Takatsu H, Noda T, Sano K, Ito Y, Hayakawa K, Tsuchiya K, Arai M, Nishigaki K, Takemura G, Minatoguchi S, Fujiwara T, Fujiwara H. In vivo quantitative tissue characterization of human coronary arterial plaques by use of integrated backscatter intravascular ultrasound and comparison with angioscopic findings. *Circulation*. 2002;105:2487-92
- [33] Okubo M, Kawasaki M, Ishihara Y, Takeyama U, Kubota T, Yamaki T, Ojio S, Nishigaki K, Takemura G, Saio M, Takami T, Minatoguchi S, Fujiwara H. Development of integrated backscatter intravascular ultrasound for tissue characterization of coronary plaques. *Ultrasound Med Biol*. 2008;34:655-63.
- [34] Stary HC, Chandler AB, Dinsmore RE, Fuster V, Glagov S, Insull W Jr, Rosenfeld ME, Schwartz CJ, Wagner WD, Wissler RW. A definition of advanced types of atherosclerotic lesions and a histological classification of atherosclerosis. A report from the Committee on Vascular Lesions of the Council on Arteriosclerosis, American Heart Association. *Circulation*. 1995;92:1355-1374.
- [35] Siebes M, Campbell CS, D'Argenio DZ. Fluid dynamics of a partially collapsible stenosis in a flow model of the coronary circulation. *J Biomech Eng*. 1996 ;118:489-97
- [36] Lin FY, Saba S, Weinsaft JW, Wong FJ, Szulc M, Kligfeld P, Okin PM, Berman DS, Shaw LJ, Min JK. Relation of plaque characteristics defined by coronary computed tomographic angiography to ST-segment depression and impaired functional capacity during exercise treadmill testing in patients suspected of having coronary heart disease. *Am J Cardiol*. 2009 ;103:50-8.



## **Advances in the Diagnosis of Coronary Atherosclerosis**

Edited by Prof. Suna Kirac

ISBN 978-953-307-286-9

Hard cover, 378 pages

**Publisher** InTech

**Published online** 09, November, 2011

**Published in print edition** November, 2011

Coronary artery disease (CAD) and its consequences are most important morbidity and mortality reasons in the developed and developing countries. To prevent hard end-points, early definitive diagnosis and optimum therapy play significant role. Novel advanced diagnostic tests which are biomarkers of inflammation, cell adhesion, cell activation and imaging techniques provide to get the best result in the detection and characterization of calcified or uncalcified atherosclerotic plaques. In spite of last developments in the imaging methods, coronary catheterization is still frequently performed. Following the first cardiac catheterization performed in 1844, date by date historical developments and the mechanics of cardiac catheterization techniques, risks associated with coronary angiography, and also, preventions and treatments of possible complications have been presented in this book. Other important issue is radiation exposure of patients and staff during coronary angiography and scintigraphy. Radiation dose reduction techniques, general radiation protection principles have been discussed in related chapters.

### **How to reference**

In order to correctly reference this scholarly work, feel free to copy and paste the following:

Shinichiro Tanaka (2011). Novel Insights Into Stenosis on Coronary Angiography—Outline of Functional Assessment of Stable Angina Patients with Angiographic Stenosis, *Advances in the Diagnosis of Coronary Atherosclerosis*, Prof. Suna Kirac (Ed.), ISBN: 978-953-307-286-9, InTech, Available from: <http://www.intechopen.com/books/advances-in-the-diagnosis-of-coronary-atherosclerosis/novel-insights-into-stenosis-on-coronary-angiography-outline-of-functional-assessment-of-stable-angi>

**INTECH**  
open science | open minds

### **InTech Europe**

University Campus STeP Ri  
Slavka Krautzeka 83/A  
51000 Rijeka, Croatia  
Phone: +385 (51) 770 447  
Fax: +385 (51) 686 166  
[www.intechopen.com](http://www.intechopen.com)

### **InTech China**

Unit 405, Office Block, Hotel Equatorial Shanghai  
No.65, Yan An Road (West), Shanghai, 200040, China  
中国上海市延安西路65号上海国际贵都大饭店办公楼405单元  
Phone: +86-21-62489820  
Fax: +86-21-62489821



© 2011 The Author(s). Licensee IntechOpen. This is an open access article distributed under the terms of the [Creative Commons Attribution 3.0 License](#), which permits unrestricted use, distribution, and reproduction in any medium, provided the original work is properly cited.

IntechOpen

IntechOpen