

# We are IntechOpen, the world's leading publisher of Open Access books Built by scientists, for scientists

4,800

Open access books available

122,000

International authors and editors

135M

Downloads

Our authors are among the

154

Countries delivered to

TOP 1%

most cited scientists

12.2%

Contributors from top 500 universities



WEB OF SCIENCE™

Selection of our books indexed in the Book Citation Index  
in Web of Science™ Core Collection (BKCI)

Interested in publishing with us?  
Contact [book.department@intechopen.com](mailto:book.department@intechopen.com)

Numbers displayed above are based on latest data collected.  
For more information visit [www.intechopen.com](http://www.intechopen.com)



# Cardiac Catheterization and Coronary Angiography in Patients with Cardiomyopathy

Ali Ghaemian

*Mazandaran University of Medical Sciences  
Iran*

## 1. Introduction

Cardiomyopathies are a group of heart diseases that influence muscles directly and are not related to congenital, valvular, and pericardial diseases (Salehifar et al., 2008). Cardiomyopathies are usually classified on the basis of structural or functional causes. Thus, dilated cardiomyopathy is characterized by an enlarged ventricular chamber size and reduced cardiac contractility, hypertrophic cardiomyopathy is characterized by hypertrophy of the ventricular walls and increased cardiac performance and finally the restrictive form is characterized by stiff ventricular walls which restrict diastolic filling of the ventricle while systolic performance is not impaired (Ammash et al., 2000; Dec & Fuster, 1994). The classification by the American Heart Association Scientific Statement panel divides cardiomyopathy into primary and secondary causes (Maron et al., 2006). In this classification primary cardiomyopathies are subdivided into genetic, mixed and acquired groups.

## 2. Dilated cardiomyopathy

Dilated cardiomyopathy (DCM) is characterized by enlargement of one or both ventricles accompanied by impaired myocardial systolic function. DCM is the most common cardiomyopathy. Patients with DCM usually have symptoms and signs of congestive heart failure and there are many cardiac and systemic causes leading to DCM. However, in about 50 percent or more of the patients with DCM, the etiology can not be identified. Thus, the patient is called as having an idiopathic DCM (Felker et al., 2000).

### 2.1 Natural history and prognosis

Because of different etiologies patients have variable presentations. Asymptomatic patients with left ventricular dysfunction to advanced stages of heart failure are two sides of the spectrum of presentations of the patients. The annual mortality ranges between 10 and 50 percents (Levy et al., 2006). While survival of some patients is good, some cardiomyopathy patients have poor prognosis. For example, cardiomyopathy patients with human immunodeficiency virus and amyloidosis do not have long-term survival (Levy et al., 2006). Patients with idiopathic DCM have variable natural history. Some patients may be stable over years or even decades. This stability may be in response to pharmacological or device

therapy or it can be due to spontaneous reverse remodeling. On the other hand, the clinical stability of some patients deteriorates suddenly and the hemodynamic situation requires inotropic or mechanical support (Teuteberg et al., 2006).

## **2.2 Etiology**

DCM is the major cause of congestive heart failure (CHF). Other most frequent specific Cardiomyopathies causing CHF include ischemic or hypertensive cardiomyopathies and nonsystolic heart failure (Owan et al., 2006). In DCM after excluding the specific disease about 50 percent is called idiopathic DCM (Felker et al., 2000). However, some of these idiopathic DCM cases are caused by genetic abnormalities or some environmental etiologies that are not diagnosed at the time of primary presentation and with more imaging or molecular evaluation, many of these idiopathic cases will have a specific etiology.

## **2.3 Specific forms of dilated cardiomyopathy**

There are many important causes of secondary CMP including alcohol, HIV infection, metabolic impairments and cardiotoxic drugs such as doxorubicin. There are four specific causes of dilated CMP with more probability of recovery.

### **2.3.1 Tachycardia-induced cardiomyopathy**

Patients with recurrent or permanent tachycardia such as atrial fibrillation or supraventricular tachycardia may develop CHF or DCM. Atrial fibrillation is a frequent disease among patients affected by CHF (Ghaemian et al., 2011). There is a high probability of recovery by controlling the arrhythmia (Redfield et al., 2000). Thus, patients should be treated to restore normal sinus rhythm.

### **2.3.2 Peripartum cardiomyopathy**

This form of cardiomyopathy presents between 6 months to the last month of pregnancy (Elkayam et al., 2001). Usually the prognosis is good. However, women who recover the first attack are at increased risk of recurrence during the next pregnancies.

### **2.3.3 Broken heart or tako-tsubo syndrome**

This CMP is usually caused by a stressful condition. This CMP is more common in women and the patients usually recover with treatment. Electrocardiogram may show findings of myocardial infarction, but in coronary angiography epicardial coronary arteries do not show stenosis.

### **2.3.4 Alcoholic cardiomyopathy**

This form of CMP usually is related to the amount of consumption of alcohol with recovery by cessation of alcohol. The mechanism usually is direct toxicity of the alcohol (Fernandez-sola et al., 2006). This CMP is more common in men, patients usually have a history of excessive consumption of alcohol for more than 10 years. Patients may have a fulminant course with biventricular failure. Alcohol may precipitate some arrhythmias including atrial fibrillation or supraventricular tachycardia. Many electrocardiographic abnormalities including QT interval prolongation are common. Hemodynamic and echocardiographic findings are similar to those of DCM patients. Cessation of consumption of the alcohol is the main component of treatment.

## **2.4 Clinical presentation of the dilated cardiomyopathy**

DCM is more frequent in middle age man, but it affects all ages. The incidence if ischemic CMP is higher than DCM. The clinical presentation of patients with DCM is variable. While some patients gradually become symptomatic, others may develop symptoms over only weeks and yet some of them have fulminant course of congestive heart failure (McCarthy et al., 2000). The most frequent symptoms of patients are dyspnea and fatigue.

## **2.5 Laboratory evaluation**

Screening the biochemical testing including serum electrolytes, calcium, phosphorus and serum creatinine is necessary. Rheumatological tests such as antinuclear antibody (ANA) and erythrocyte sedimentation rate should also be obtained. Endocrine tests including thyroid function test and urinary examination of catecholamine levels may be helpful. Serum troponin levels to assess myocardial necrosis and brain natriuretic peptide levels are usually obtained.

### **2.5.1 Electrocardiography**

Nonspecific electrocardiographic changes include sinus tachycardia, interventricular conduction delay and poor R progression and left bundle branch block. Other electrocardiographic abnormalities such as ST segment and T wave abnormalities may also be seen. Patients may show a wide spectrum of supraventricular and ventricular arrhythmia.

### **2.5.2 Echocardiography**

By two-dimensional echocardiography ventricular size and function are usually evaluated. Doppler echocardiography is helpful to evaluate valvular stenosis or regurgitation and restrictive filling patterns. Dobutamine stress echocardiography is helpful to differentiate ischemic from idiopathic DCM and also to assess contractile reserve of myocardium.

### **2.5.3 Radionuclide imaging**

This imaging technique is useful to identify ischemic CMP and also can assess cardiac function and ejection fraction of both ventricles.

### **2.5.4 Magnetic Resonance Imaging (MRI)**

Cardiac MRI is useful to diagnose some specific CMPs such as myocarditis, amyloidosis, sarcoidosis and infiltrative and inflammatory cardiomyopathies and arrhythmogenic right ventricular dysplasia (Maceira et al., 2005; Mahrholdt et al., 2004; Tandri et al., 2005).

## **3. Ischemic cardiomyopathy**

When myocardial dysfunction is secondary to occlusion of the coronary arteries, the term ischemic CMP is used and is the most common cause of heart failure. Based on the pathophysiological processes ischemic CMP may be classified into three groups. The first one is called myocardial hibernation. In this form of ischemic CMP a reduced coronary flow will result in persistent contractile dysfunction and revascularization procedures will usually restore myocardial function, at least partially. Myocardial stunning is the second form of ischemic CMP. In this form the contractile dysfunction of the viable myocardium is transient and is usually caused by reduced sensitivity of contractile proteins to calcium.

Finally in the third type, the contractile dysfunction is secondary to irreversible cell death of the myocardium.

### **3.1 Revascularization in ischemic CMP**

In patients with ischemic CMP revascularization is beneficial only when the myocardium is viable and revascularization procedures cause an improvement in left ventricular function. In patients with severe left ventricular dysfunction, but with viable myocardium, coronary artery revascularization results in an average 8 to 10 percent of improvement in left ventricular ejection fraction (Kumpati et al., 2001). This will be associated with improvement in clinical situation and survival of the patients. However, if the viable myocardium is not considerable improvement of left ventricular function will not occur. It has been reported that 20 to 25 percent or more of the myocardium is the threshold of myocardial viability for which surgery is indicated (De Bonis & Alfieri 2006). Patients with ischemic CMP should be examined for detection of myocardial viability. Thallium-201 single-photon emission computed tomography (SPECT) and dobutamine stress echocardiography are usually used for this purpose. When both of these two methods predicated viability, the global left ventricular ejection fraction rose from 35 to 40 percent after operation (Starling et al., 2003). In other reports positron emission tomography (PET) was better than SPECT to predict improvement of left ventricular ejection fraction after revascularization (Pagano et al., 1999; Starling et al., 2003). In a meta-analysis of 24 studies in patients with ischemic CMP revascularization decreased the risk of death by 79.6 percent in patients with viable myocardium detected by SPECT, dobutamine echocardiography or positron emission tomography (Bishay et al., 2000). Thus, in patients with heart failure secondary to coronary artery disease coronary angiography and viability study should be performed.

## **4. Right and left heart catheterization**

Catheterization of the right and left side of the heart are usually performed to examine the hemodynamics of the heart i.e. to measure intracardiac pressure, cardiac outputs, and vascular resistances. In patients with heart failure, respiratory failure, valvular heart disease, pericardial disease, restrictive or hypertrophic cardiomyopathies hemodynamic assessment is of great value for the diagnosis and management of the patients. If necessary angiographic procedures such as left or right ventriculography, pulmonary angiography, and aortography may be performed during cardiac catheterization. Besides, selective angiographic procedures include native coronary, coronary bypass graft and carotid angiography.

### **4.1 Hemodynamic evaluation**

Catheterization laboratories use disposable, fluid - filled transducers to measure pressure. For hemodynamic evaluation, the right heart catheter is placed in the pulmonary artery and a pigtail catheter in the aorta. Cardiac out is usually measured by the thermodilution method. Oxymetric analysis is performed on the blood collected from the aorta and the pulmonary artery, cardiac output is calculated by the Fick method, the presence of a left- to - right shunt is also screened. Catheter of the aorta is advanced into the left ventricle and the right- sided catheter into pulmonary capillary wedge position and the pressures are measured simultaneously. Then the right sided catheter is withdrawn and all the pressures are recorded. With the simultaneous measurement of the pressure of right and left ventricles it is possible to screen for restrictive or constrictive physiology. Then by pulling back the left- sided catheter the pressure gradient across the aortic valve is determined.

## 4.2 Complications

Cardiac catheterization also is a safe procedure, potentially has some complications. In patients with left ventricular thrombus or aortic valve endocarditis it is better to avoid inserting catheters into the left heart. Catheter induced arrhythmia is another potential complication of right or left heart. Right or left bundle branch blocks may occur if the catheter is placed in the right ventricular outflow tract or crossed the aortic valve, respectively. Thus, patients with right or left bundle branch block are at potential risk of developing complete heart block during cardiac catheterization. Renal failure, contrast reactions, vascular complications are the more common complications of cardiac catheterization. The incidence of cerebrovascular accident, myocardial infarction, and death is less than 1 percent. Other rare complications include infection, chamber or vessel perforation, cholesterol embolism, air embolism, and radiation -induced skin injury.

## 4.3 Right heart catheterization

Right heart catheterization is performed from the right internal Jugular, femoral or subclavian veins using a balloon flotation catheter. For right heart catheterization fluoroscopy is not necessary and by attaching the catheter to a pressure transducer the operator can advance the catheter. Pressure is recorded in the right sided chambers and the pulmonary artery. With the catheter in the pulmonary artery, it is possible to measure thermodilution cardiac output and perform oximetry to detect a shunt and determine cardiac output by the Fick method. The catheter also can be advanced to a pulmonary capillary wedge position to obtain the wedge pressure. If by the pressure-guided technique catheter does not advance successfully and also when the right heart catheterization is performed from the femoral veins fluoroscopy is used. The normal pressure of the right atrium is 2 to 6 mmHg with positive "a" and "v" waves and negative "x" and "y" descents (Fig.1).

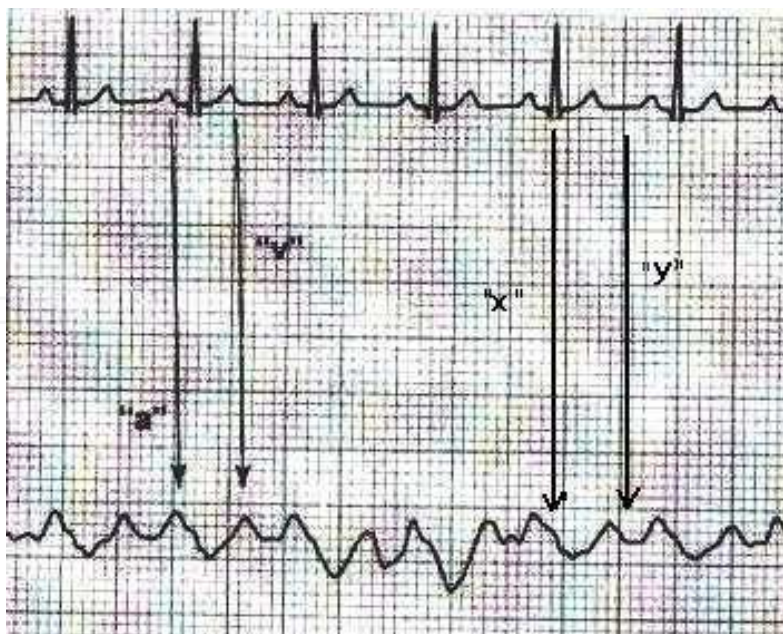


Fig. 1. Normal right atrial waveform

The atrial contraction increases the right atrial pressure producing the "a" wave. At the initial part of ventricular systole the downward motion of the tricuspid valve and the atrial relaxation produce the "x" descent. An inconsistent "c" waves after the "a" represents the

motion of the tricuspid annulus toward the right atrium at the onset of the ventricular systole. The distance of the "c" from the "a" is the same as the PR interval in the electrocardiogram and first degree atrioventricular block produces a more visible "c" wave. The "x" descent represents the decrease of the right atrial pressure in ventricular systole which is followed by the "v" wave in atrial diastole when the right atrium is filled by venous return. The peak of the "v" wave occurs at the end of ventricular systole when the right atrium is maximally filled and is at the same time of T wave on the electrocardiogram. The final "y" descent represents the rapid emptying of the right atrium at the initial part of ventricular diastole when the tricuspid valve opens. As shown in Figure 2 the normal right ventricular systolic pressure is 20 to 30mmHg, and normal right ventricular end-diastolic pressure is 0 to 8 mmHg. The right ventricular pressure normally consists of a rapid rise of pressure followed by a decline during ventricular contraction and then rapid downward motion with ventricular relaxation. At the beginning of diastole the pressure is low and with ventricular filling increases gradually.

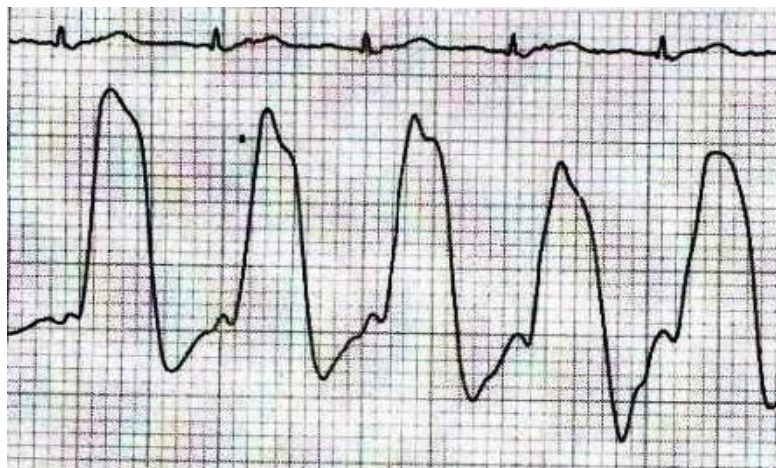


Fig. 2. Normal right ventricular waveform

The normal range of pulmonary artery systolic pressure is about 20 to 30 mmHg while the diastolic pressure is 4 -12 mmHg . As is shown in Figure 3 the pressure waveform of the pulmonary artery increase rapidly during systole and reaches a peak. However, during diastolic descent of the pressure there is a dicrotic notch.

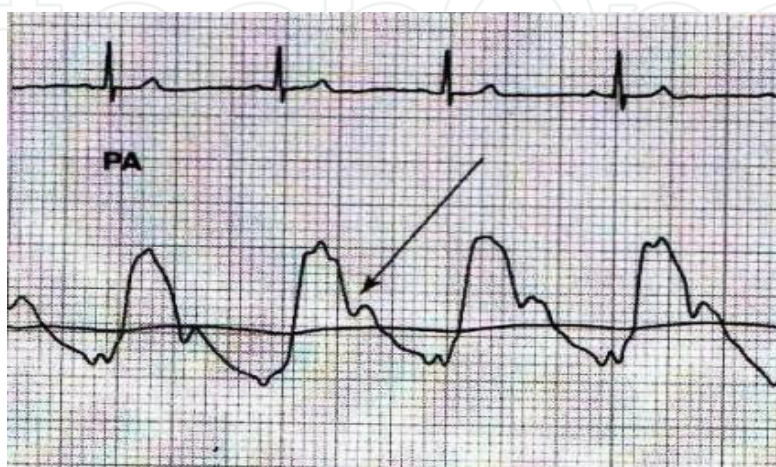


Fig. 3. Normal pulmonary artery waveform

During right heart catheterization the pulmonary capillary wedge pressure (PCWP) waveform is usually evaluated. The pressure waveform is better to obtain with an end-hole catheter. The end-hole catheter obstructs the antegrade flow into the pulmonary artery, so it reflects the left atrial pressure, or the PCWP. This pressure can be obtained by a Swan-Ganz catheter in the pulmonary artery. By inflating the balloon of this catheter and obstructing the flow, the PCWP is obtained. The normal mean pressure of the PCWP is about 2 to 14mmHg and consists of positive "a" and "v" and negative "x" and "y" waves (Fig.4).

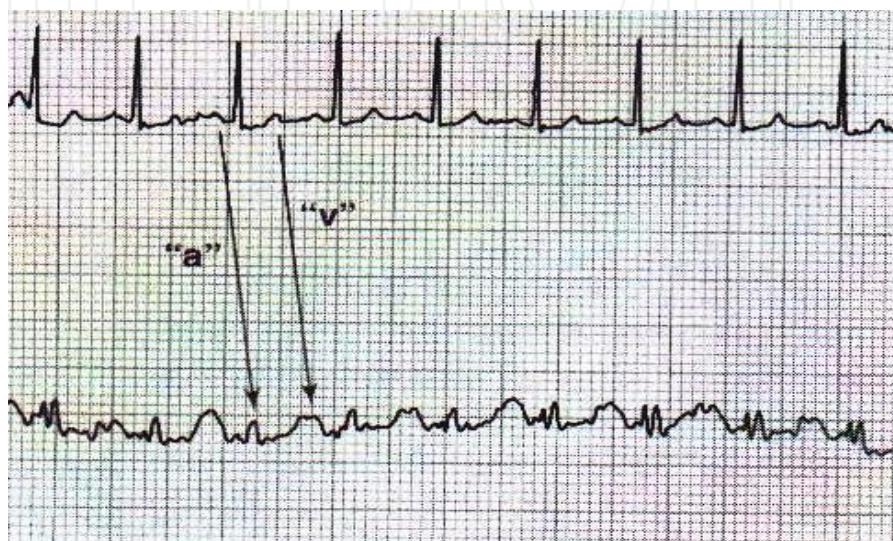

Fig. 4. Normal pulmonary capillary wedge pressure waveform

However, "c" wave which is sometimes seen in an atrial pressure is usually not seen in PCWP and also because the PCWP is the pressure transmitted through the pulmonary capillary bed, a time delay occurs between an electrocardiographic event and the onset of the relevant wave. For example the "a" wave of the right atrial pressure follows the P wave of the electrocardiogram by about 80 milliseconds while it is about 240 milliseconds in PCWP. Also, the peak of the "v" wave in PCWP tracing occurs after the T wave. Finally it should be noted that the oxygen saturation obtained from the catheter in the PCWP position is greater than 90%.

#### 4.4 Left heart catheterization

Left heart catheterization is usually performed using a pigtail catheter. The catheter is advanced to the ascending aorta and then is positioned in the left ventricle. For this purpose, it may be necessary to rotate the catheter clockwise or counterclockwise gently to cross the valve. Occasionally a J-tipped stiff guide wire should be used.

The left ventricular waveform has a rapid upstroke during ventricular contraction and then during relaxation the pressure decreases (Fig.5).

At the initial part of the diastole the ventricular pressure is low and increases slowly until the end diastolic portion and the normal diastolic pressure is 8 to 16 mmHg. Left ventricular end-diastolic pressure is the pressure just before the abrupt increase in systolic pressure. Central aortic pressure waveforms normally have a rapid upstroke, a systolic peak followed by a dicrotic notch due to closure of the aortic valve (Fig.6).



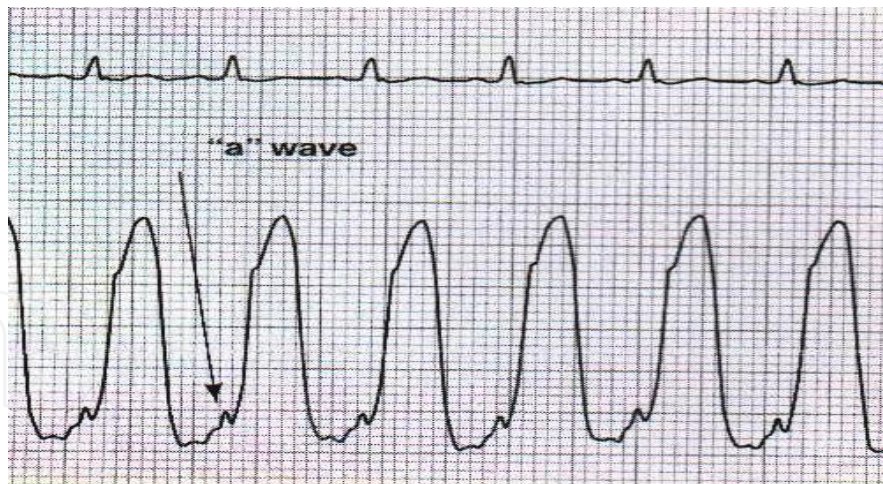


Fig. 5. Prominent “a” wave in left ventricular waveform

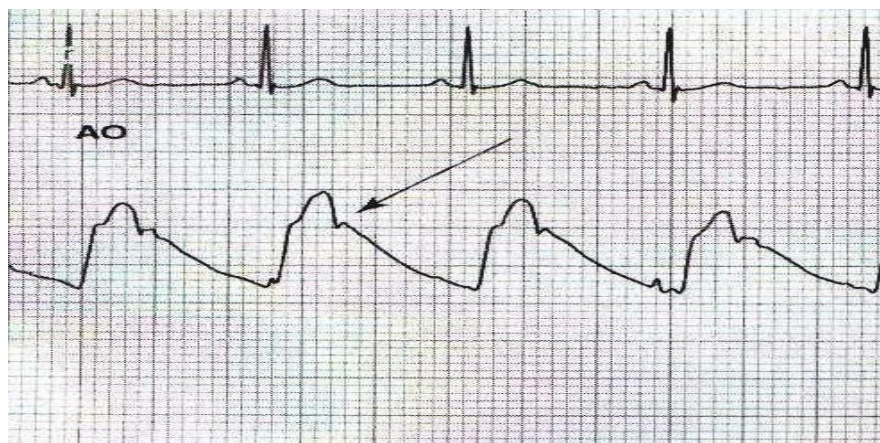


Fig. 6. Normal central aortic waveform

During hemodynamic evaluation for screening for the presence of a restrictive or constrictive physiology, simultaneous measurement of left and right ventricular pressures is performed. Normally peak systolic pressure changes during expiration and inspiration in the right and left ventricle parallel each other (Fig.7) and the diastolic pressures of the two ventricles differ by at least 5 mmHg during the respiratory cycle (Fig.8).

#### 4.5 Hemodynamic calculations

During cardiac catheterization and hemodynamic evaluation, hemodynamic calculations are made. For example, calculation of the cardiac output by the Fick method, calculations of the pulmonary and peripheral vascular resistances, and calculations of the mitral and aortic valves areas can be obtained. However, most of the computerized hemodynamic data collection systems have the softwares to calculate these values automatically.

#### 4.6 Trans - septal heart catheterization

In some situations it is not possible to enter the left ventricle via retrograde approach. For example, in the presence of a mechanical aortic valve at severe aortic stenosis it may be necessary to measure left ventricular pressure or perform left ventriculography and trans -

septal approach can be helpful. During some interventional procedures such as mitral balloon valvuloplasty, percutaneous mitral valve repairs with clips, some electrophysiologic procedures, and placement of a percutaneous left ventricular assist device may require trans-septal puncture.

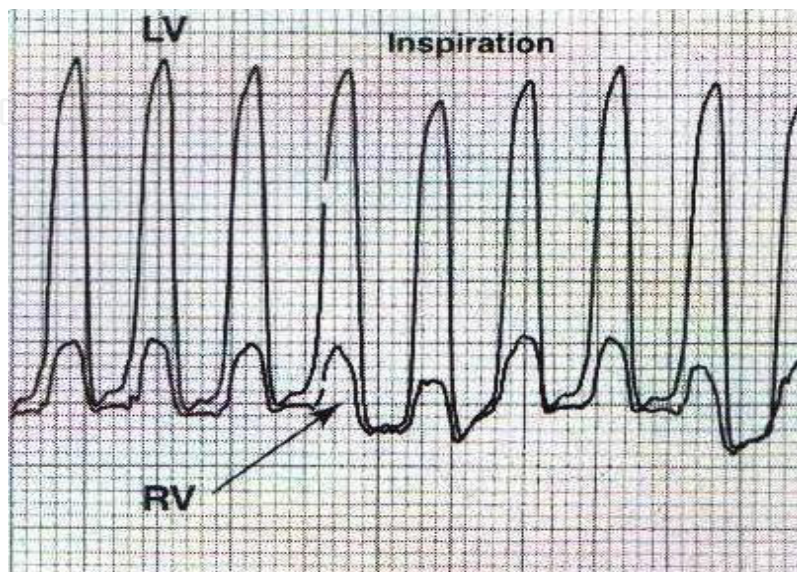


Fig. 7. Normal concomitant waveform of right ventricle and left ventricular in systole

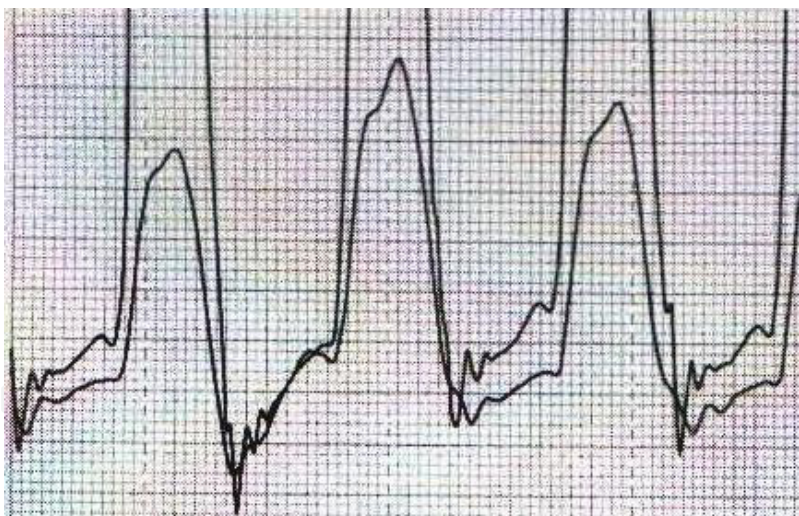


Fig. 8. Normal concomitant right and left ventricular waveform in diastole

During a trans-septal puncture the goal is usually to puncture the atrial septum at the fossa ovalis and the procedure is performed from the right femoral vein. At the same time a pigtail catheter is positioned on the aortic valve to identify the aorta by fluoroscopy. The puncture of the interatrial septum is performed using the Brockenbrough needle inserted into a dilator. After the puncture, a guidewire is advanced into the left atrium and the dilator is advanced over the wire in order to position the sheath within the left atrium and left atrial pressure is recorded. Then based on the procedure, the rest of the catheterization or intervention can be performed.

### 5. Abnormal hemodynamic waveforms in patients

In patients with left ventricular systolic dysfunction including dilated CMP the hemodynamic findings are nonspecific. Heart failure increases the pulmonary capillary wedge pressure and right-sided pressures. Chronic heart failure increases the pulmonary artery pressure because of reactive and fixed increases in pulmonary vascular resistance, leading to pulmonary hypertension and secondary tricuspid regurgitation and right heart failure. In patients with systolic dysfunction left ventricular end-diastolic pressure is increased and a prominent “a” wave may be seen (Fig 9).

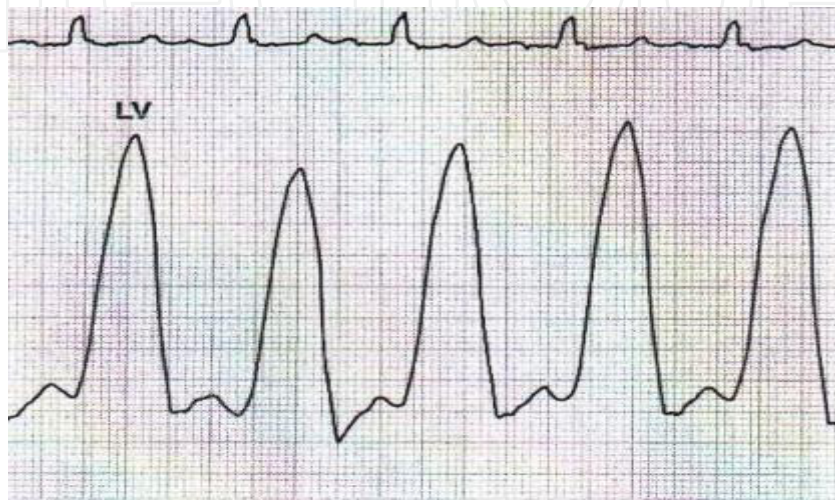


Fig. 9. Pressure waveform in a patient with left ventricular dysfunction showing a prominent “a” wave

In patients with advanced stages of left ventricular dysfunction, left ventricular pressure may have a delay to reach the systolic peak due to diminished contractility (Fig 10).

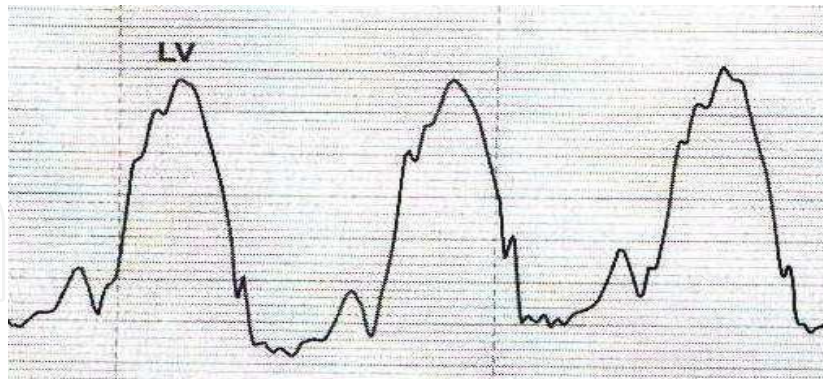


Fig. 10. Left ventricular pressure waveform in a patient with severe left ventricular dysfunction which have a triangular appearance

Another presentation of severely reduced left ventricular contractility is the appearance of pulsus alternans on the aortic or left ventricular pressure waveform (Fig 11).

Ambulatory patients with dilated CMP may have a relatively low normal resting cardiac output and a modest elevation in both right- and left-sided filling pressures. However, in advanced stages of heart failure, the systemic vascular resistance rises significantly in response to the reduced cardiac output. Also, in advanced heart failure in dilated CMP patients

biventricular failure is usually characteristic. The right atrial pressure waveform will demonstrate steep “x” and “y” descents indicative of severe volume overload and right ventricular systolic and diastolic dysfunction. Kussmaul sign, i.e., absence of the normal respiratory fall in the right atrial pressure is common and as a result of tricuspid regurgitation the “y” descent is steep. The PCWP waveform may demonstrate a prominent “v” wave. The left ventricular pressure waveform is characterized by an elevation in pressure throughout early diastole. The arterial tracing may show a narrow pulse pressure (pulsus parvus).

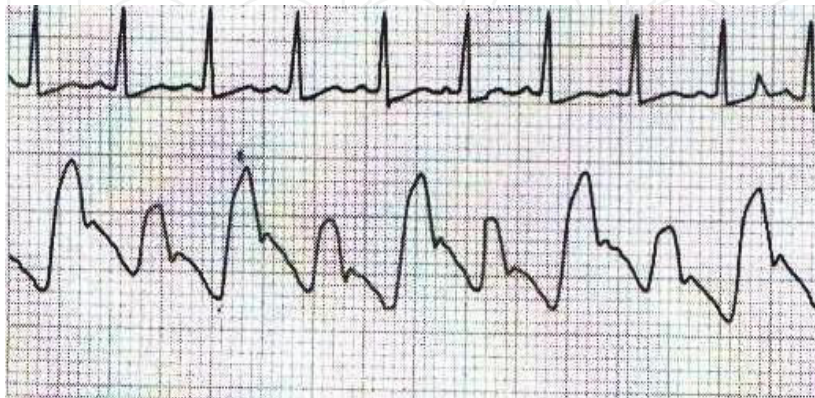


Fig. 11. Aortic pressure tracing in a patient with severe left ventricular dysfunction pulsus alternans

In patients with right-sided heart failure similar to left heart failure, pulsus alternans may be present in right-sided pressure waveforms (Fig 12).

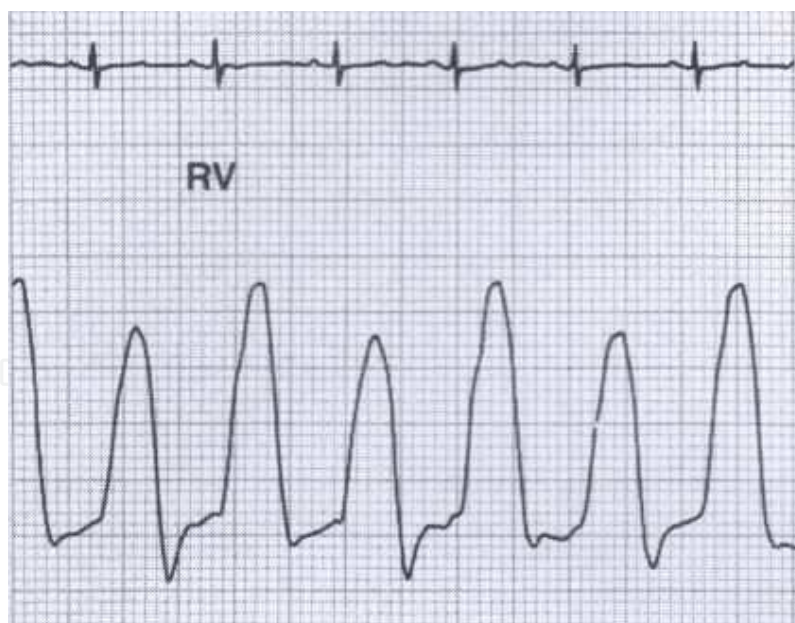


Fig. 12. Pulsus alternans in the right ventricular wave form in a patient with right-sided heart failure

In the case of tricuspid regurgitation secondary to pulmonary hypertension as in primary tricuspid regurgitation a prominent “v” wave on the right atrial waveform may appear (Fig 13) and in severe cases of tricuspid regurgitation ventricularization of the right atrial waveform may occur (Fig 14).

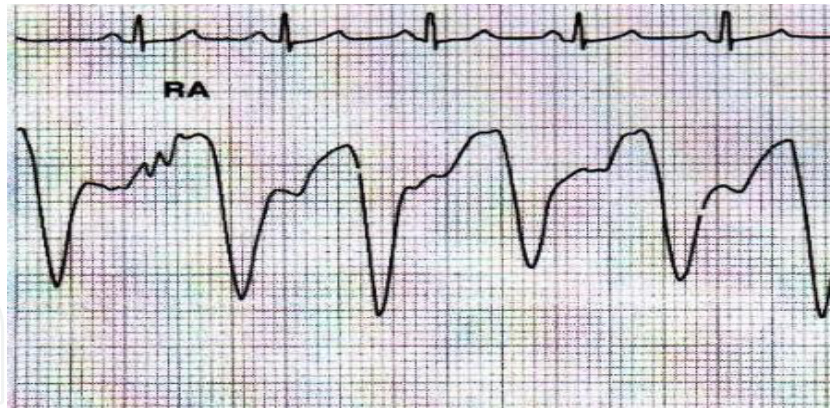


Fig. 13. Prominent “v” wave in the right atrial pressure in a patient with severe tricuspid regurgitation

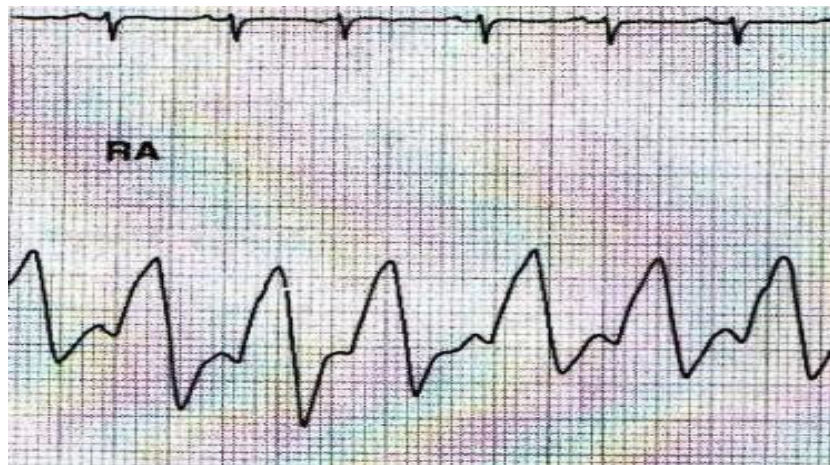


Fig. 14. Ventricularization of the right atrial waveform in a patient with severe tricuspid regurgitation

In patients with hypertrophic obstructive cardiomyopathy the systolic anterior motion of the mitral valve obstructs the left ventricular outflow tract causing a pressure gradient between the left ventricle and aorta (Fig 15). And the aorta pressure waveform may show the characteristic pattern of spike and dome configuration (Fig 16). In some cases the gradient may be absent at rest but can be provoked by decreasing the preload.

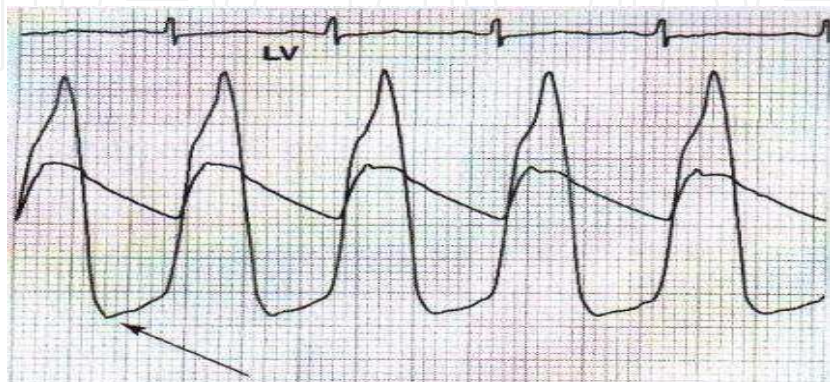


Fig. 15. Simultaneous left ventricular and aortic pressure waveform in a patient with hypertrophic obstructive cardiomyopathy which shows significant pressure gradients at rest

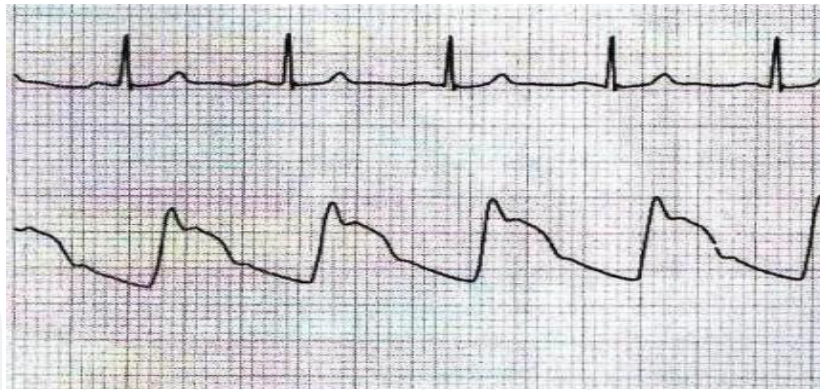


Fig. 16. Aortic pressure waveform showing “spike-and-dome” configuration

## 6. Left ventriculography

Left ventriculography is performed during a left heart catheterization to assess left ventricular function. Left ventriculography can also be helpful to identify the presence of mitral regurgitation, ventricular septal defect, and left ventricular hypertrophy. In patients with high pulmonary capillary wedge pressure or left ventricular end-diastolic pressure the injection of contrast may impose the patient to the risk of acute pulmonary edema. In addition, in patients with a mobile left ventricular thrombus seen on echocardiography it is better not to perform left ventriculography. Left ventriculography is commonly performed by a power injector and a pigtail catheter positioned in the mid ventricle.

For assessment of ventricular systolic function, ejection fraction is calculated via left ventriculography. Usually computer-based software is applied and the left ventricular end-diastolic and end-systolic contours are traced. Diastolic and systolic areas can be determined and based on the assumptions regarding the geometry of the heart, ventricular volumes are calculated and then the left ventricular ejection fraction can be calculated. Furthermore, in patients with coronary artery disease, regional left ventricular function can be assessed. Based on the distribution of the coronary arteries the left ventricle is divided into some segments. The contractions of the segments are evaluated. If the contraction of each segment is reduced it is classified as “hypokinetic” and if there is no contraction it is called “akinetic”. Finally, if during systole the segment moves outward it is called “dyskinetic”. In patients with hypertrophic cardiomyopathy, because of excessive hypertrophy, in left ventriculography cavity obliteration and a small ventricular end-systolic volume are commonly seen. In these patients if ventricular outflow tract obstruction also is present, systolic anterior motion of the mitral valve can be noted. Interestingly, in apical form of hypertrophic cardiomyopathy the ventriculogram appears with a “spade” – shaped contour. In patients with apical ballooning syndrome who have transient severe left ventricular dysfunction in the absence of coronary artery disease left ventriculography shows aneurysm of the left ventricle which predominantly affects the apex of the heart.

## 7. Right ventriculography

Right ventriculography is usually indicated in congenital heart disease. However, right ventriculography in adults may be helpful in the diagnosis of right ventricular dysplasia and determination of right ventricular systolic function. In patients with arrhythmogenic right ventricular dysplasia several findings associated with this disorder have been noted. However, there is no pathognomonic feature in right ventriculography in these patients.

## 8. Coronary angiography

Coronary angiography is considered the gold standard for diagnosing coronary artery disease and can be useful to differentiate ischemic from dilated forms of cardiomyopathies. During coronary angiography the dominant vessel and also the vascular territories for each artery can be identified. Obstructive coronary artery disease is usually defined by angiography when a greater than 50% diameter narrowing is seen. When the lesions narrow the lumen by more than 70%, they are generally believed to be hemodynamically significant. However, there are some limitations regarding the usefulness of coronary angiography in diagnosing coronary artery disease. Coronary angiography only assesses the arterial lumen, while atherosclerosis is a disease of the arterial wall. There may be a substantial amount of plaque in the arterial wall before it is evident by angiography. Thus, a normal coronary arteriogram does not exclude the presence of coronary artery disease. Second, there is a wide range of interobserver variability in interpreting the coronary arteriogram of a patient. Third, depending on the image quality, the operator technique, patient body habitus, the vessel tortuosity, and the presence of overlapping segments, the ability of the angiography to assess a lesion may be affected. Finally, for identification of a luminal narrowing a reference normal segment of the vessel is usually used for comparison. In patients with diffuse coronary lesions, a true normal segment is not present and the arterial lumen may appear uniform.

Ischemic cardiomyopathy results following severe coronary artery disorders and usually angiography must be performed for proper diagnosis (Shokrzadeh et al., 2008). Coronary atherosclerosis usually causes narrowing of the lumen of the coronary arteries in advanced stages. In the early stages of atherosclerosis, compensatory enlargement of the artery maintains the coronary artery lumen. Thus, coronary angiography which only assesses the arterial lumen can not detect the early stages of atherosclerosis. However, techniques such as intravascular ultrasound provide images of arterial wall and detect coronary atherosclerosis in earlier stages. Coronary atherosclerosis can be detected anywhere along the course of the artery.

There are many indications for performing coronary angiography. For example, in different clinical situations such as myocardial infarction, acute coronary syndromes stable angina, patients with valvular or congenital heart diseases coronary angiography may be useful to define coronary artery anatomy. However, coronary angiography should not be performed in patients who do not want to undergo revascularization, patients with severe left ventricular dysfunction in whom revascularization is not likely to improve ventricular function, patients with acute bleeding, unexplained fever, and in patients with severe coagulopathy.

## 9. Conclusion

Cardiac catheterization is performed in patients with heart failure to assess the etiology, to evaluate the hemodynamic status of the patient, and to define therapeutic responses. While the major part of the hemodynamic evaluation is assessed in the supine state, exercise conditions can also be evaluated. After hemodynamic evaluation of the patient angiography should be performed to define the coronary anatomy and if needed left ventriculography to assess ventricular contractility. Ventriculography is also helpful to define ventricular size and mitral regurgitation, although most patients will have had complete echocardiographic study prior to catheterization. In the absence of coronary artery disease to explain

ventricular dysfunction, an endomyocardial biopsy should be considered for a specific diagnosis.

## 10. Acknowledgement


I wish to thank Dr Safoora Masoumi for her help in providing this chapter.

## 11. References

- Ammash, NM., Seward, JB., Bailey, KR., Edwards, WD., & Tajik, AJ. (2000). Clinical profile and outcome of idiopathic restrictive cardiomyopathy. *Circulation*, Vol. 101, No.21, (May 2000), pp.2490-2496, ISSN 0009-7322
- Bishay, ES., McCarthy, PM., Cosgrove, DM., Hoercher, KJ., Smedira, NG., Mukherjee, D., White, J., & Blackstone, EH.(2000). Mitral valve surgery in patients with severe left ventricular dysfunction. *Eur J Cardiothorac Surg*, Vol.17, No.3, (Mar 2000), pp.213-221, ISSN 1010-7940
- De Bonis, M., & Alfieri, O.(2006). Surgery insight: Surgical methods to reverse left ventricular remodeling. *Nat Clin Pract Cardiovasc Med*, Vol.3, No.9, (Sep 2006), pp.507-513, ISSN 1759-5002
- Dec, GW., & Fuster, V.(1994). Idiopathic dilated cardiomyopathy. *N Engl J Med*, Vol. 331, No.23, (Dec 1994), pp.1564-1575, ISSN 0028-4793
- Elkayam, U., Tummala, PP., Rao, K., Akhter, MW., Karaalp, IS., Wani, OR., Hameed, A., Gviyada, I., & Shotan A.(2001) Maternal and fetal outcomes of subsequent pregnancies in women with peripartum cardiomyopathy. *N Engl J Med*, Vol.344, No.21(May 2001), pp.1567-1571, ISSN 0028-4793
- Felker, GM., Thompson, RE., Hare, JM., Hruban, RH., Clemetson, DE., Howard, DL., Baughman, KL., & Kasper, EK. (2000) Underlying causes and long-term survival in patients with initially unexplained cardiomyopathy. *N Engl J Med*, Vol.342, No.15, (Apr 2000), pp.1077-1084, ISSN 0028-4793
- Fernández-Solà, J., Fatjó, F., Sacanella, E., Estruch, R., Bosch, X., Urbano-Márquez, A., & Nicolás, JM.(2006) Evidence of apoptosis in alcoholic cardiomyopathy. *Hum Pathol*, Vol.37, No.8(Aug 2006), pp.1100-1110, ISSN 0046-8177
- Ghaemian, A., Salehifar, E., Jalalian, R., Ghasemi, F., Azizi, S., Masoumi, S., Shiraj, H., Mohammadpour, RA., & Bagheri GA.(2011). Zinc and Copper Levels in Severe Heart Failure and the Effects of Atrial Fibrillation on the Zinc and Copper Status. *Biol Trace Elem Res*, [ Epub ahead of print], (2011 Jan), DOI 10.1007/s12011-011-8956-6
- Kumpati, GS., McCarthy, PM., & Hoercher, KJ.(2001). Surgical treatments for heart failure. *Cardiol Clin*, Vol.19, No .4, (Nov 2001), pp. 669-681, ISSN 0160-9289
- Levy, WC., Mozaffarian, D., Linker, DT., Sutradhar, SC., Anker, SD., Cropp, AB., Anand, I., Maggioni, A., Burton, P., Sullivan, MD., Pitt, B., Poole-Wilson, PA., Mann, DL., & Packer, M.(2006) The Seattle heart failure model-Prediction of survival in heart failure.*Circulation*, Vol.113, No.11, ( Mar 2006), pp.1424-1433, ISSN 0009-7322
- Maceira, AM., Joshi, J., Prasad, SK., Moon, JC., Perugini, E., Harding, I., Sheppard, MN., Poole-Wilson, PA., Hawkins, PN., & Pennell DJ. (2005).Cardiovascular magnetic resonance in cardiac amyloidosis. *Circulation*, Vol .111, No.2, (Jan 2005), pp.186-193, ISSN 0009-7322
- Mahrholdt, H., Goedecke, C., Wagner, A., Meinhardt, G., Athanasiadis, A., Vogelsberg, H., Fritz, P., Klingel, K., Kandolf, R., & Sechtem U.(2004) Cardiovascular magnetic



- resonance assessment of human myocarditis-A comparison to histology and molecular pathology. *Circulation*, Vol. 109, No.10, (Mar 2004), pp. 1250-1258, ISSN 0009-7322
- Maron, BJ., Towbin, JA., Thiene, G., Antzelevitch, C., Corrado, D., Arnett, D., Moss, AJ., Seidman, CE., Young, JB., American Heart Association., Council on Clinical Cardiology., Heart Failure and Transplantation Committee., Quality of Care and Outcomes Research and Functional Genomics and Translational Biology Interdisciplinary Working Groups., & Council on Epidemiology and Prevention.(2006). Contemporary definitions and classification of the cardiomyopathies – An American Heart Association Scientific Statement from the Council on Clinical Cardiology, Heart Failure and Transplantation Committee; Quality of Care and Outcomes Research and Functional Genomics and Translational Biology Interdisciplinary Working Groups; and Council on Epidemiology and Prevention. *Circulation*, Vol.113, No.14, (Apr 2006), pp 1807-1816, ISSN 0009-7322
- McCarthy, RE., Boehmer, JP., Hruban, RH., Hutchins, GM., Kasper, EK., Hare, JM., & Baughman KL.(2000). Long-term outcome of fulminant myocarditis as compared with acute (nonfulminant) myocarditis. *N Engl J Med*, Vol.342, No.10, (Mar 2000), pp. 690-695, ISSN 0028-4793
- Owan, TE., Hodge, DO., Herges, RM., Jacobsen, SJ., Roger, VL., & Redfield MM.(2006) Trends in prevalence and outcome of heart failure with preserved ejection fraction. *N Engl J Med*, Vol.355, No.3, (Jul 2006), pp.251-259, ISSN 0028-4793
- Pagano, D., Bonser, RS., & Camici, PG. (1999) .Myocardial revascularization for the treatment of post-ischemic heart failure. *Curr Opin Cardiol*, Vol.14, No.6, (Nov 1999), pp.506-509, ISSN 0268-4705
- Redfield, MM., Kay, GN., Jenkins, LS., Mianulli, M., Jensen, DN., & Ellenbogen, KA.(2000) Tachycardia-related cardiomyopathy: A common cause of ventricular dysfunction in patients with atrial fibrillation referred for atrioventricular ablation. *Mayo Clinic Proc*, Vol.75, No.8(Aug 2000), pp.790-795, ISSN 0025-6196
- Salehifar, E., Shokrzadeh, M., Ghaemian, A., Aliakbari, S., & Saeedi Saravi, SS.(2008). The study of Cu and Zn serum levels in idiopathic dilated cardiomyopathy (IDCMP) patients and its comparison with healthy volunteers. *Biol Trace Elem Res*, Vol.125, No.2, ( Nov 2008), pp.97-108 ISSN 0163-498
- Shokrzadeh, M., Ghaemian, A., Salehifar, E., Aliakbari, S., Saravi, SS., & Ebrahimi, P.(2009). Serum zinc and copper levels in ischemic cardiomyopathy. *Biol Trace Elem Res*, Vol.127, No.2, (Feb 2009), pp.116-123, ISSN 0163-498
- Starling, RC., McCarthy, PM., & Yamini, MH.(2003). Surgical treatment of chronic congestive heart failure, In: *Heart Failure: A Companion to Braunwald's Heart Disease*, D.L. Mann, (Ed.), pp.717-736, WB Saunders, ISBN 0721694454 Philadelphia
- Tandri, H., Saranathan, M., Rodriguez, ER., Martinez, C., Bomma, C., Nasir, K., Rosen, B., Lima, JA., Calkins, H., & Bluemke DA.(2005). Noninvasive detection of myocardial fibrosis in arrhythmogenic right ventricular cardiomyopathy using delayed-enhancement magnetic resonance imaging. *J Am Coll Cardiol*, Vol.45, No.1, (Jan 2005), pp.98-103, ISSN 0735-1097
- Teuteberg, JJ., Lewis, EF., Nohria, A., Tsang, SW., Fang, JC., Givertz, MM., Jarcho, JA., Mudge, GH., Baughman, KL., & Stevenson LW.(2006) Characteristics of patients who die with heart failure and a low ejection fraction in the new millennium. *J Cardiac Fail*, Vol .12, No. 1, (Feb 2006), pp.47-53, ISSN 071-9164



## **Advances in the Diagnosis of Coronary Atherosclerosis**

Edited by Prof. Suna Kirac

ISBN 978-953-307-286-9

Hard cover, 378 pages

**Publisher** InTech

**Published online** 09, November, 2011

**Published in print edition** November, 2011

Coronary artery disease (CAD) and its consequences are most important morbidity and mortality reasons in the developed and developing countries. To prevent hard end-points, early definitive diagnosis and optimum therapy play significant role. Novel advanced diagnostic tests which are biomarkers of inflammation, cell adhesion, cell activation and imaging techniques provide to get the best result in the detection and characterization of calcified or uncalcified atherosclerotic plaques. In spite of last developments in the imaging methods, coronary catheterization is still frequently performed. Following the first cardiac catheterization performed in 1844, date by date historical developments and the mechanics of cardiac catheterization techniques, risks associated with coronary angiography, and also, preventions and treatments of possible complications have been presented in this book. Other important issue is radiation exposure of patients and staff during coronary angiography and scintigraphy. Radiation dose reduction techniques, general radiation protection principles have been discussed in related chapters.

### **How to reference**

In order to correctly reference this scholarly work, feel free to copy and paste the following:

Ali Ghaemian (2011). Cardiac Catheterization and Coronary Angiography in Patients with Cardiomyopathy, *Advances in the Diagnosis of Coronary Atherosclerosis*, Prof. Suna Kirac (Ed.), ISBN: 978-953-307-286-9, InTech, Available from: <http://www.intechopen.com/books/advances-in-the-diagnosis-of-coronary-atherosclerosis/cardiac-catheterization-and-coronary-angiography-in-patients-with-cardiomyopathy>

**INTECH**  
open science | open minds

### **InTech Europe**

University Campus STeP Ri  
Slavka Krautzeka 83/A  
51000 Rijeka, Croatia  
Phone: +385 (51) 770 447  
Fax: +385 (51) 686 166  
[www.intechopen.com](http://www.intechopen.com)

### **InTech China**

Unit 405, Office Block, Hotel Equatorial Shanghai  
No.65, Yan An Road (West), Shanghai, 200040, China  
中国上海市延安西路65号上海国际贵都大饭店办公楼405单元  
Phone: +86-21-62489820  
Fax: +86-21-62489821

© 2011 The Author(s). Licensee IntechOpen. This is an open access article distributed under the terms of the [Creative Commons Attribution 3.0 License](#), which permits unrestricted use, distribution, and reproduction in any medium, provided the original work is properly cited.

IntechOpen

IntechOpen