

We are IntechOpen, the world's leading publisher of Open Access books Built by scientists, for scientists

4,800

Open access books available

122,000

International authors and editors

135M

Downloads

Our authors are among the

154

Countries delivered to

TOP 1%

most cited scientists

12.2%

Contributors from top 500 universities

**WEB OF SCIENCE™**Selection of our books indexed in the Book Citation Index
in Web of Science™ Core Collection (BKCI)

Interested in publishing with us?
Contact book.department@intechopen.com

Numbers displayed above are based on latest data collected.

For more information visit www.intechopen.com

Complications of Cardiac Catheterization

Mariano García-Borbolla¹, Rafael García-Borbolla²
and Begoña Balboa³

¹*Hospital Virgen Macarena*

²*Hospital de Jerez*

³*Hospital Virgen del Rocío*

Spain

1. Introduction

Cardiac catheterization was primarily a diagnostic procedure that was used to evaluate hemodynamics, ventricular function, and coronary anatomy. However, the introduction of improved angioplasty equipment and new interventional devices in the 1980s made catheterization an important tool in the treatment of cardiovascular disease.

Although diagnostic catheterization and percutaneous coronary intervention are done by skin puncture rather than incision, and under local rather than general anesthesia, they can cause a variety of adverse events, ranging from minor problems without long-term sequelae to major complications requiring immediate corrective action. Furthermore, newer interventional procedures may be associated with different and, in some cases, more frequent complications.

2. Major complications

The risk of producing a major complication (death, myocardial infarction, or major embolization) during diagnostic cardiac catheterization is generally well below 1 percent. As a result, the risk-to-benefit ratio still favors performing this procedure as a part of the evaluation of potentially fatal or lifestyle limiting cardiac disease.

The risk of an adverse event, for the individual patient, is dependent upon demographics, cardiovascular anatomy, clinical circumstances including comorbidities, the experience of the operator, and the type of procedure being performed (**table 1 A-C**) [1]. Severe peripheral artery disease is a risk factor for all of the major complications.

2.1 Death

Death following diagnostic cardiac catheterization is now rare. Compared with the 1 percent mortality rate seen in the 1960s, the second registry of the Society for Cardiac Angiography revealed that the procedural mortality had fallen to 0.1 percent in the more than 200,000 patients catheterized between 1984 and 1987 [2].

High-risk subgroups have been identified in multiple large series [1-9]:

	Percent
Mortality	0.11
Myocardial infarction	0.05
Cerebrovascular accident	0.07
Arrhythmia	0.38
Vascular complications	0.43
Contrast reaction	0.37
Hemodynamic complications	0.26
Perforation of heart chamber	0.28
Other complications	0.28
Total of major complications	1.70

Noto, TJ Jr, Johnson, LW, Krone, R, et al. Cardiac catheterization 1990: A report of the Registry of the Society for Cardiac Angiography and Interventions (SCA&I). Cathet Cardiovasc Diagn 1991; 24:75.

Table 1. (A): Risk of cardiac catheterization and coronary angiography (based on 59,792 patients)

Variable	Odds ratio
Moribund	10.22
Shock	6.52
Acute MI <24 h	4.03
Renal insufficiency	3.30
Cardiomyopathy	3.29
Aortic valve disease	2.72
Mitral valve disease	2.33
Heart failure	2.33
New York Heart Association Functional	
Class I	1.00
Class II	1.15
Class III	1.32
Class IV	1.52
Hypertension	1.45
Unstable angina	1.42
Outpatient/inpatient	0.63

Moribund indicates a patient who responds poorly due to a life threatening condition.

MI: myocardial infarction.

Scanlon, PJ, Faxon, DP, Audet, AM, et al, J Am Coll Cardiol 1999; 33:1756.

Table 1. (B): Multivariate predictors of major complications of coronary angiography (based on 58,332 procedures)

Acute renal failure
Chronic renal failure secondary to diabetes
Active gastrointestinal bleeding
Unexplained fever, which may be due to infection
Untreated active infection
Acute stroke
Severe anemia
Severe uncontrolled hypertension
Severe symptomatic electrolyte imbalance
Severe lack of cooperation by patient due to psychological or severe systemic illness
Severe concomitant illness that drastically shortens life expectancy or increases risk of therapeutic interventions
Refusal of patient to consider definitive therapy such as PTCA, CABG, or valve replacement
Digitalis intoxication
Documented anaphylactoid reaction to angiographic contrast media
Severe peripheral vascular disease limiting vascular access
Decompensated heart failure or acute pulmonary edema
Severe coagulopathy
Aortic valve endocarditis

PTCA: percutaneous transluminal coronary angioplasty; CABG: coronary artery bypass graft.
 Scanlon, PJ, Faxon, DP, Audet, AM, et al, J Am Coll Cardiol 1999; 33:1756.

Table 1. (C): Relative contraindications to coronary angiography

- Patients with valvular heart disease, chronic kidney disease, diabetes mellitus requiring insulin therapy, peripheral artery disease, cerebrovascular disease, and pulmonary insufficiency all appear to have an increased incidence of death and major complications from cardiac catheterization. Mortality is especially high in those with preexisting renal insufficiency who have further deterioration of renal function within 48 hours after the procedure, particularly when dialysis is required [10].
- A similar increase in risk is seen with severe disease of the left main coronary artery (compared to single vessel disease) and with a left ventricular ejection fraction (LVEF) below 30 percent (compared to an LVEF above 50 percent).
- Age above 60 years and below one year and women have an increased mortality rate after catheterization.
- New York Heart Association functional class IV is associated with an almost tenfold increase in mortality compared with classes I and II (**table 2**).

Class	New York Heart Association functional classification	Canadian Cardiovascular Society functional classification	Specific activity scale
I	Patients with cardiac disease but without resulting limitations of physical activity. Ordinary physical activity does not cause undue fatigue, palpitation, dyspnea, or anginal pain.	Ordinary physical activity, such as walking and climbing stairs, does not cause angina. Angina with strenuous or rapid prolonged exertion at work or recreation.	Patients can perform to completion any activity requiring ≥ 7 metabolic equivalents, eg, can carry 24 lb up eight steps; do outdoor work (shovel snow, spade soil); do recreational activities (skiing, basketball, squash, handball, jog/walk 5 mph).
II	Patients with cardiac disease resulting in slight limitation of physical activity. They are comfortable at rest. Ordinary physical activity results in fatigue, palpitation, dyspnea, or anginal pain.	Slight limitation of ordinary activity. Walking or climbing stairs rapidly, walking uphill, walking or stair climbing after meals, in cold, in wind, or when under emotional stress, or only during the few hours after awakening. Walking more than two blocks on the level and climbing more than one flight of ordinary stairs at a normal pace and in normal conditions.	Patients can perform to completion any activity requiring ≤ 5 metabolic equivalents, eg, have sexual intercourse without stopping, garden, rake, weed, roller skate, dance fox trot, walk at 4 mph on level ground, but cannot and do not perform to completion activities requiring ≥ 7 metabolic equivalents.
III	Patients with cardiac disease resulting in marked limitation of physical activity. They are comfortable at rest. Less than ordinary physical activity causes fatigue, palpitation, dyspnea, or anginal pain.	Marked limitation of ordinary physical activity. Walking one to two blocks on the level and climbing more than one flight in normal conditions.	Patients can perform to completion any activity requiring ≤ 2 metabolic equivalents, eg, shower without stopping, strip and make bed, clean windows, walk 2.5 mph, bowl, play golf, dress without stopping, but cannot and do not perform to completion any activities requiring > 5 metabolic equivalents.
IV	Patient with cardiac disease resulting in inability to carry on any physical activity without discomfort. Symptoms of cardiac insufficiency or of the anginal syndrome may be present even at rest. If any physical activity is undertaken, discomfort is increased.	Inability to carry on any physical activity without discomfort - anginal syndrome may be present at rest.	Patients cannot or do not perform to completion activities requiring > 2 metabolic equivalents. Cannot carry out activities listed above (Specific activity scale III).

Table 2. Comparison of three methods of assessing cardiovascular disability

2.2 Myocardial infarction

Although periprocedural myocardial ischemia is fairly common, infarction is rare. The general risk of myocardial infarction (MI) in most series is less than 0.1 percent [2-7]. However, the risk of precipitating an MI in an individual patient is influenced by patient-related and technique-related factors. Risk factors that predispose patients to MI during the procedure include:

- Recent non-ST elevation acute coronary syndrome.
- Extension of disease (0.17 percent with left main coronary disease versus 0.06 percent in single vessel disease) [2].
- Diabetes mellitus requiring insulin therapy [1].

2.3 Stroke and transient ischemic attack

A stroke is a rare but potentially devastating complication of cardiac catheterization. The incidence of stroke was 0.07 to 0.10 percent in an analysis of two large databases [2,11] and has more recently been reported to be as high as 0.2 to 0.4 percent [12]. Risk factors for stroke include the severity of coronary artery disease, the length of fluoroscopy time, diabetes, hypertension, prior stroke, or renal failure [11,12]

Stroke and transient ischemic attacks are thought to be caused by disruption of atheromatous plaques on the walls of the aorta. The risk of intracerebral hemorrhage is increased in those receiving anticoagulation or thrombolytic therapy as well as with any of the following: age ≥ 75 years; female sex; systolic blood pressure ≥ 160 mmHg; black race; and low body weight (**table 3**). Based on the number of the risk factors present, the rate of intracerebral hemorrhage varies from less than 1 percent to more than 4 percent.

Risk Factors*	
Age ≥ 75 years	
Black race	
Female sex	
Prior history of stroke	
Systolic blood pressure ≥ 160 mmHg	
Weight ≤ 65 kg for women or ≤ 80 kg for men	
INR >4 or PT >24 •	
Use of alteplase (versus other thrombolytic agent)	
Risk score	Rate of intracranial hemorrhage, percent
0 or 1	0.69
2	1.02
3	1.63
4	2.49
≥ 5	4.11

* Each risk factor is worth 1 point if present, 0 points if absent. Points are added to determine the risk score.

• INR: international normalized ratio; PT: prothrombin time.

Brass, LM, Lichtman, JH, Wang, Y, et al. Intracranial hemorrhage associated with thrombolytic therapy for elderly patients with acute myocardial infarction: results from the cooperative cardiovascular project. *Stroke* 2000; 31:1802.

Table 3. Cooperative cardiovascular project risk model for intracranial hemorrhage with thrombolytic therapy

Meticulous attention to technical factors such as wire and catheter exchanges is mandatory in all patients, regardless of risk. Transient neurologic deficits may also result from the injection of high osmolar contrast agents into the carotid or vertebral arteries. The majority of patients with a periprocedural stroke have an unfavorable neurologic outcome and, in one study, the in-hospital mortality was 32 percent [11].

2.4 Role of valvular aortic stenosis

The risk of stroke may be particularly high in patients with valvular aortic stenosis (AS) who undergo retrograde catheterization of the aortic valve [13,14]. This was demonstrated in a study of 152 patients with severe AS (mean age 71 years) who were randomly assigned to cardiac catheterization with or without catheter passage through the valve [13]. The following findings were noted:

- Detailed neurologic examination done before and after the catheterization demonstrated clinically apparent deficits in 3 percent of those who underwent retrograde catheterization, but in none of the other patients.
- Cranial MRI done before and after the catheterization demonstrated focal lesions consistent with cerebral emboli in 22 percent of those who underwent retrograde catheterization of the aortic valve, but in none of the patients who did not.

As a result, retrograde catheterization should be performed with caution in patients with severe calcific AS and only when the information sought cannot be reliably obtained noninvasively [14].

2.5 Asymptomatic embolic events

The incidence of stroke after cardiac catheterization was 0.07 to 0.10 percent in an analysis of two large databases [2,11]. However, asymptomatic embolic events are much more common [13,15,16].

This was illustrated in a prospective study of 48 patients (mean age 62 years) who underwent cardiac catheterization and angiography and, in some patients, percutaneous coronary intervention; magnetic resonance imaging (MRI) was performed before and about 24 hours after the procedure [15]. There were no embolic lesions on diffusionweighted imaging at baseline, but seven patients (15 percent) had nine cerebral infarcts after the procedure; all were asymptomatic.

Similar findings were noted in a report of 47 unselected patients in whom transcranial Doppler was used to detect microemboli and MRI to detect new lesions [16]. The median number of solid (ie, not gaseous) microemboli was significantly higher with a transradial compared to a transfemoral access (57 versus 36). New MRI lesions occurred in 5 of 33 patients (15 percent) after transradial catheterization, compared to none of nine after transfemoral catheterization. Most of the patients with new lesions remained asymptomatic. These observations suggest that catheter manipulation in the diseased aortic root releases small pieces of atherosclerotic debris more commonly than suspected, based upon the fortunately low incidence of clinically apparent stroke. The same principles presumably apply to peripheral embolism.

3. Local vascular complications

Local complications at the site of catheter insertion are among the most common problems seen after cardiac catheterization.

These problems may include acute thrombosis, distal embolization, dissection or poorly controlled bleeding (which may be manifested as free hemorrhage or contained hematoma in the femoral or retroperitoneal areas), pseudoaneurysm, or arteriovenous fistula. Hemorrhage and hematoma are usually evident within 12 hours after the procedure by virtue of local discomfort, hypotension, or falling hematocrit, which lead to confirmatory noninvasive testing (ultrasound or CT). In contrast, other complications such as pseudoaneurysm and arteriovenous fistula may not become apparent for days to weeks afterward.

3.1 Hemostasis at the access site

The traditional approach to catheter removal at the conclusion of cardiac catheterization was local hand-applied pressure for 15 to 30 minutes.

Two alternative approaches are available: mechanical clamp compression and more importantly, arterial puncture closing devices:

3.1.1 Mechanical clamp

Mechanical clamp compression reduces the amount of staff time and effort required to assure hemostasis, and may reduce the rate of vascular complications. One trial randomly assigned 778 patients to hand applied pressure or mechanical clamp pressure; the latter reduced the frequency of ultrasound-defined femoral vascular complications (femoral artery thrombosis, echogenic hematoma, pseudoaneurysm, or arteriovenous fistulae formation) by 63 percent [17]. However, clamping does not decrease the importance of having staff in attendance to ensure that the device is placed and remains in the correct position.

The circumstances which may make mechanical clamps the preferred method of achieving hemostasis include procedures where longer hemostasis time is anticipated: larger sheaths, excessively anticoagulated patients, recognized hematoma, and dual antiplatelet therapy

3.1.2 Closure devices

Arterial puncture closing devices (APCDs) eliminate the need for prolonged arterial compression and reduce the subsequent interval of bed rest that is otherwise required. Two types of APCDs in clinical use include collagen hemostatic puncture closure devices [18-21] and suture-mediated devices [22].

APCDs may increase the risk of local vascular complications. In a meta-analysis of 30 trials including 4000 patients who underwent coronary angiography or PCI, nonsignificant increases in the incidence of groin hematoma, bleeding, and pseudoaneurysm formation were associated with use of these devices compared to manual compression [23]. When only those trials with an intention-to-treat analysis were included, the relative risks of groin hematoma and pseudoaneurysm formation were significantly increased (1.89 and 5.40, respectively).

A larger meta-analysis that included 30 studies involving 37,066 patients concluded that the risk of complications depended upon the specific device used and whether the procedure was a diagnostic catheterization or a PCI [24]. In the overall analysis, there was a significant increase in risk with an APCD (odds ratio [OR] 1.34, 95% CI 1.01- 1.79). For reports limited to diagnostic studies, there were no significant differences between APCDs and mechanical compression, although there were trends toward fewer complications with the AngioSeal

device (OR 0.71) and toward more complications with the VasoSeal and Perclose devices (OR 1.85 and 1.51, respectively).

For reports limited to PCI, there were no significant differences between APCDs and mechanical compression overall. However, there was a significant increase in vascular complications with the VasoSeal device (OR 2.52).

Closure devices also increase the risk of local infection or endarteritis [25,26]. Although this complication is infrequent (0.3 percent in one series) [26], it can be serious when it occurs. Consideration should be given to periprocedural antibiotics in immunocompromised patients following prolonged arterial access or when sterility has been breached when a closure device is used. It may also be prudent for the operator to change gloves prior to using an arterial closure device. (See 'Infection' below.) An angiogram of the femoral artery should be performed prior to use of an APCD. Use of closure devices should be avoided if a hematoma has formed during the procedure, or in the presence of severe iliofemoral vascular disease, and when the access site is below the bifurcation of the superficial and profunda femoral arteries.

3.1.3 Prior warfarin therapy

Among patients who are being treated with warfarin, the optimal approach is to withhold warfarin and wait until the INR reaches 1.5 before proceeding with catheterization. When the procedure cannot be delayed, it has been suggested that, in patients with an INR of 2.0 to 3.0, manual pressure hemostasis may be sufficient to prevent excess bleeding [27]. In patients with an INR >3.0, administration of fresh frozen plasma prior to arterial sheath removal may be warranted. The transradial approach may also be useful in such cases. The risk of local bleeding in warfarin-treated patients is likely to be greater in those undergoing PCI who are often treated with heparin, clopidogrel, and a glycoprotein IIb/IIIa inhibitor. These patients typically have longer intraarterial times and more manipulation of the arterial access site. Increase in risk is seen with severe disease of the left main coronary artery (compared to single vessel disease) and with a left ventricular ejection fraction (LVEF) below 30 percent (compared to an LVEF above 50 percent).

3.2 Hematoma formation

Hematoma formation is not uncommon in the soft tissue of the upper thigh and the patient should be advised that the development of a large area of ecchymosis is likely. Although most resolve over a period of days, femoral nerve compression can occur, which may take weeks to months to resolve. Patients should be advised to avoid strenuous activity or lifting heavy objects within the first week following arterial catheterization. Surgical repair for a hematoma is generally not required.

3.2.1 Retroperitoneal extension

If the arterial puncture occurs above the inguinal ligament, hematoma may extend into the retroperitoneal space, causing hypotension and ipsilateral flank pain. CT scanning or abdominal ultrasonography can help to establish the diagnosis. Treatment is usually conservative, consisting of bed rest and blood transfusion rather than surgical correction. Reversal of systemic anticoagulation may be indicated if bleeding persists or is associated with hemodynamic compromise.

3.3 Arteriovenous fistula

Ongoing bleeding from the arterial puncture site may decompress into the adjacent venous puncture site, leading to the formation of an arteriovenous fistula. This complication may be recognized by the presence of a thrill or continuous bruit at the site of catheter insertion. Surgical repair is usually necessary, since fistulae tend to enlarge over time. The most common finding at surgery is a puncture site below the common femoral artery, which illustrates the importance of careful technique in avoiding this complication [1].

3.4 Prior pseudoaneurysm

If a hematoma remains in continuity with the arterial lumen, a pseudoaneurysm may develop with blood flow into and out of the hematoma cavity during systole and diastole. A pseudoaneurysm is most often recognized by the presence of a pulsatile mass with a systolic bruit over the catheter insertion site; it can be confirmed by duplex ultrasonography. Almost all pseudoaneurysms occur within the first three days after removal of the arterial sheath, and most of the remaining cases by seven days after sheath removal [28].

The main risk factor for pseudoaneurysm formation is an inadequate period of manual compression. This was illustrated in a series of 581 angiographic procedures involving transfemoral arterial catheterization [29]. A pseudoaneurysm occurred in 14 percent of the first 300 procedures in which standard manual compression was performed, compared to 1.1 percent of the next 281 procedures when manual compression was continued for at least five minutes after local bleeding had stopped.

Other risk factors include large bore sheaths, postprocedural anticoagulation, antiplatelet therapy during the intervention, age >65 years, obesity, hypertension, peripheral artery disease, hemodialysis, cannulation of the superficial rather than common femoral artery, and complex interventions [28-30].

Surgical management should be performed when a pseudoaneurysm occurs at the site of a vascular anastomosis, becomes very large and threatens or causes skin necrosis, is expanding rapidly, occurs spontaneously, as it may be infected, or there is a failure of a minimally invasive procedure [30]. Expanding hematomas have a propensity towards eventual rupture, especially if the patient is maintained on anticoagulation [1,7,31,32].

Treatment of smaller pseudoaneurysms may be accomplished with either direct ultrasound-guided compression or with ultrasound-guided local injection of thrombin or collagen into the pseudoaneurysm cavity, which has a higher success rate [28,33-35]. Although an effective approach, ultrasound-guided compression is uncomfortable for both the patient and the person applying compression.

The success rate of ultrasound-guided injection of bovine thrombin was illustrated in a series of 240 patients with simple or complex pseudoaneurysms [28]. The primary success rate was 96 percent with simple pseudoaneurysms and 89 percent with complex pseudoaneurysms. The secondary success rate was 99.6 percent (all but one patient). The authors also reviewed 34 studies with 1388 patients; the overall success rate was 97.2 percent.

The high success rate of ultrasound-guided injection has made it the treatment of choice for most postcatheterization pseudoaneurysms [30]. However, the procedure should not be performed when, as defined above, there is an indication for surgical management.

In rare cases, pseudoaneurysms less than 2 cm can be managed conservatively and monitored by serial imaging to confirm spontaneous resolution.

3.5 Arterial thrombosis

Arterial thrombosis is rare and occurs slightly more often when the brachial approach is used [3,4]. Predisposing factors to femoral artery thrombosis include small vessel lumen, peripheral artery disease, diabetes mellitus, female sex, placement of a large diameter catheter or sheath (eg, intraaortic balloon pump), or a long catheter dwell time [2-7,31,32]. Patients with lower extremity pain or paresthesia, plus reduced or absent distal pulses not responding to catheter removal, should be evaluated for possible flow obstructing thrombus or dissection. Urgent vascular surgery or thrombectomy may be required for preservation of the limb.

3.6 Radial artery access

Local vascular complications appear to occur less frequently with radial artery access. This issue was best addressed in a meta-analysis that evaluated 12 randomized trials including 3224 patients comparing radial with femoral access [36]. The risk of major adverse cardiac events was similar for the two approaches. Radial access was associated with a significantly lower incidence of access site complications (odds ratio 0.20, 95% CI 0.09-0.42), but a significantly higher rate of procedural failure (odds ratio 3.30, 95% CI 1.63-6.71), probably due to the specific technical skills required for this method.

3.6.1 Integrity of the palmar arch

Radial artery cannulation is associated with a 5 to 19 percent chance of radial artery occlusion [37]. This complication is not clinically important in most patients because the hand is perfused by both the radial and ulnar arteries with extensive collateral flow between the two. However, some patients have incomplete palmar arches, which may diminish collateral perfusion, possibly leading to hand ischemia in the presence of radial artery occlusion.

The modified Allen test has traditionally been used to identify patients at increased risk from radial artery catheterization. However, many centers now use pulse oximetry and plethysmography.

The modified Allen test, originally developed to evaluate patients with thromboangiitis obliterans, assesses the adequacy of collateral blood supply from the ulnar artery to the hand via the palmar arches. The test consists of the following steps:

- The patient's hand is initially held high while the fist is clenched and both radial and ulnar arteries are compressed; this allows the blood to drain from the hand.
- The hand is then lowered and the fist is opened.
- After pressure is released over the ulnar artery, color should return to the hand within six seconds, indicating a patent ulnar artery and an intact superficial palmar arch. The test is considered abnormal if 10 seconds or more is required for color to return.

In two large series of patients undergoing cardiac catheterization, an abnormal Allen test result was obtained in 6 and 27 percent [38,39]. The importance of an abnormal test was evaluated in a study of 55 patients undergoing coronary angiography, 20 of whom had an abnormal test [37]. After 30 minutes of subsequent radial artery occlusion, the patients with an abnormal test had significantly reduced blood flow to the thumb and an elevated thumb capillary lactate.

Based upon such observations, radial artery catheterization is usually not performed in patients with an abnormal modified Allen test. A possible exception occurs in patients with

an excessive estimated risk from a femoral approach (eg, severe peripheral artery disease, large abdominal aortic aneurysm, morbid obesity) [37].

The results of the modified Allen test can be altered by a number of factors, including overextension of the wrist, skin tension over the ulnar artery, and operator error. As a result, an appreciable number of false positive and false negative results have been reported [38]. As an alternative, many centers use a more direct assessment of blood flow to the thumb during radial artery occlusion, which can be accomplished with pulse oximetry and plethysmography [38,40].

The traditional modified Allen test was compared to pulse oximetry and plethysmography in a consecutive series of 1010 patients referred for diagnostic cardiac catheterization [38]. The modified Allen test was considered abnormal if palmar blanching persisted for ≥ 10 seconds after release of ulnar compression. Plethysmography was observed for two minutes during radial artery compression. Plethysmography was characterized as follows:

- **A:** no change in the amplitude of the pulse tracing during compression
- **B:** reduction in amplitude with compression
- **C:** loss of pulse tracing with initial compression, but recovery of flow during two minutes of compression (signifying development of collateral flow)
- **D:** loss of pulse tracing with no recovery

Patients in categories A, B and C were considered to have a patent ulnopalmar arch, and therefore eligible for radial catheterization.

The modified Allen test was abnormal in significantly more patients than plethysmography (6.3 versus 1.5 percent). The authors concluded that plethysmography more accurately demonstrates the adequacy of the ulnopalmar arch, and that the modified Allen test may unnecessarily exclude some patients from radial artery catheterization. However, the number of patients who underwent radial artery catheterization was not reported, and the value of either test for predicting ischemic complications following radial artery catheterization was not assessed.

4. Arrhythmias

A variety of arrhythmias and conduction disturbances can occur during catheterization. The most common, ventricular premature beats, may be induced by catheter introduction into the right or left ventricle, and are generally without clinical importance or impact.

4.1 Ventricular tachycardia or fibrillation

Ventricular tachycardia or fibrillation is rare complications of catheterization, occurring in 0.4 percent of cases in the second registry of the Society for Cardiac Angiography [2]. These arrhythmias may result from excess catheter manipulation or, more commonly, from intracoronary contrast injection. This complication occurs more commonly when ionic and hyperosmolar contrast agents are used.

4.2 Atrial arrhythmias

Atrial arrhythmias can be induced by cardiac catheterization, especially in response to catheter placement into or out of the right atrium during right heart catheterization. These arrhythmias usually do not require immediate treatment unless they produce ischemia or hemodynamic instability.

Atrial flutter is generally well tolerated and can be treated with burst atrial pacing, or electrical or pharmacologic cardioversion. Atrial fibrillation, on the other hand, can cause clinical sequelae in the setting of a rapid ventricular response or if the loss of atrial systole results in hypotension, as in a patient with mitral stenosis or diastolic ventricular dysfunction. Synchronized cardioversion should be performed immediately in patients who are hemodynamically unstable.

4.3 Bradycardia

Bradycardia commonly occurs during coronary angiography, most often at the end of the injection of ionic contrast into the right coronary artery. Forceful coughing helps to clear the contrast, support perfusion, and restore normal cardiac rhythm. Tachycardia or fibrillation is rare complications of catheterization, occurring in 0.4 percent of cases in the second registry of the Society for Cardiac Angiography [2]. These arrhythmias may result from excess catheter manipulation or, more commonly, from intracoronary contrast injection. This complication occurs more commonly when ionic and hyperosmolar contrast agents are used.

Vasovagal reactions, which can include bradycardia, hypotension, yawning, and/or sweating, are seen in up to 3 percent of patients, particularly if they have pain or are anxious [2]. These reactions may occur with palpation or compression of the artery prior to needle access.

Treatment usually consists of volume administration, atropine (0.5 to 1.0 mg intravenously), and removal of the painful stimulus. Patients with critical coronary or valvular disease may undergo irreversible decompensation from vagally-mediated hypotension. As a result, rapid reversal of hypotension is crucial in this setting.

4.4 Conduction disturbances

Conduction disturbances are a rare cause of bradycardia in the catheterization laboratory. Patients with pre-existing left bundle branch block may develop asystole with right heart catheterization. Patients with pre-existing right bundle branch block may develop asystole during left heart catheterization. Atropine is rarely helpful in patients who develop complete heart block, but its administration is still recommended. Coughing may help support the circulation while the right heart catheter is exchanged for a temporary pacing wire. Prophylactic placement of a temporary pacemaker is not necessary, even in patients with bundle branch block or intervention in the right coronary artery.

Frank asystole is rare and there is generally sufficient time for insertion of a pacing wire through a venous sheath [41].

5. Perforation of the heart or great vessels

Perforation is an extremely rare complication of cardiac catheterization. Higher risk procedures are those that involve stiffer catheters, including transseptal catheterization, endomyocardial biopsy, balloon valvuloplasty, needle pericardiocentesis, and placement of a pacing catheter. Older adult women appear to be at particular risk.

Cardiac perforation is generally heralded by bradycardia and hypotension due to vagal stimulation induced by blood in the pericardium. If the patient is hemodynamically stable, echocardiography is suggested to document the presence of blood in the pericardial space. However, emergent pericardiocentesis should be performed via the subxiphoid approach in the presence of hemodynamic instability.

Since pericardiocentesis is itself associated with complications, it is best performed under echocardiographic guidance or with pressure monitoring. In a study of 91 cases of acute tamponade during catheterization, pericardiocentesis was the only therapy necessary in 82 percent [42].

Reversal of anticoagulation may cause blood in the pericardial space to "gel." As a result, we generally try to aspirate the majority of the blood in the pericardial space prior to the administration of protamine [1].

6. Allergic reactions

Allergic reactions during catheterization may be precipitated by three agents: the local anesthetic, the contrast agent, or protamine sulfate.

6.1 Local anesthetic

In patients claiming previous reaction to a local anesthetic, the use of a preservative-free agent (such as bupivacaine or mepivacaine) may be a safe alternative [1].

6.2 Iodinated contrast agents

Reaction to the contrast agent occurs in up to 1 percent of patients [2-7]. The risk of such a reaction is highest in patients with a history of prior contrast reactions. Other conditions, such as asthma and other atopic diseases, also confer some risk.

There are several steps that can reduce the incidence of a reaction in a high-risk patient:

- Premedication with corticosteroids and H1 antihistamines can reduce the incidence of a severe reaction (eg, bronchospasm or shock) to below 1 percent (**table 4**).
- The patient should receive a nonionic contrast agent. The incidence of crossreactivity in patients who have had previous reactions to older agents is low, although all patients with previous reactions should be premedicated [1]. In the past, nonionic contrast agents were used selectively, given their higher cost.

Prednisone 50 mg orally 13,7, and 1 h prior to procedure [In children: 0.5 to 0.7 mg/kg orally, up to 50 mg]
Diphenhydramine 50 mg PO/IM/ or IV 1 h prior to procedure [In children: 1.25 mg/kg orally, up to 50 mg]
Lower / iso-osmolar RCM should be recommended
Emergency therapy should be available

Table 4. Pretreatment for patients with previous adverse reactions to RCM

However, the cost of nonionic contrast has fallen significantly. Thus, we recommend using nonionic contrast in all patients undergoing coronary angiography.

If a severe reaction does occur, it should be treated in the same manner as anaphylaxis, and can be sometimes be reversed by using boluses of intravenous epinephrine (1:10,000 epinephrine so that 1 mL = 0.1 mg). One mL of this solution should be administered approximately every minute until the arterial pressure is restored.

However, the rapidity of dosing must be adjusted by the degree of hypotension and the level of assessed hypoperfusion. It is rare for a patient to require a total dose of more than 1.0 mg (10 mL).

Contrast-induced acute renal failure represents another complication that is discussed below.

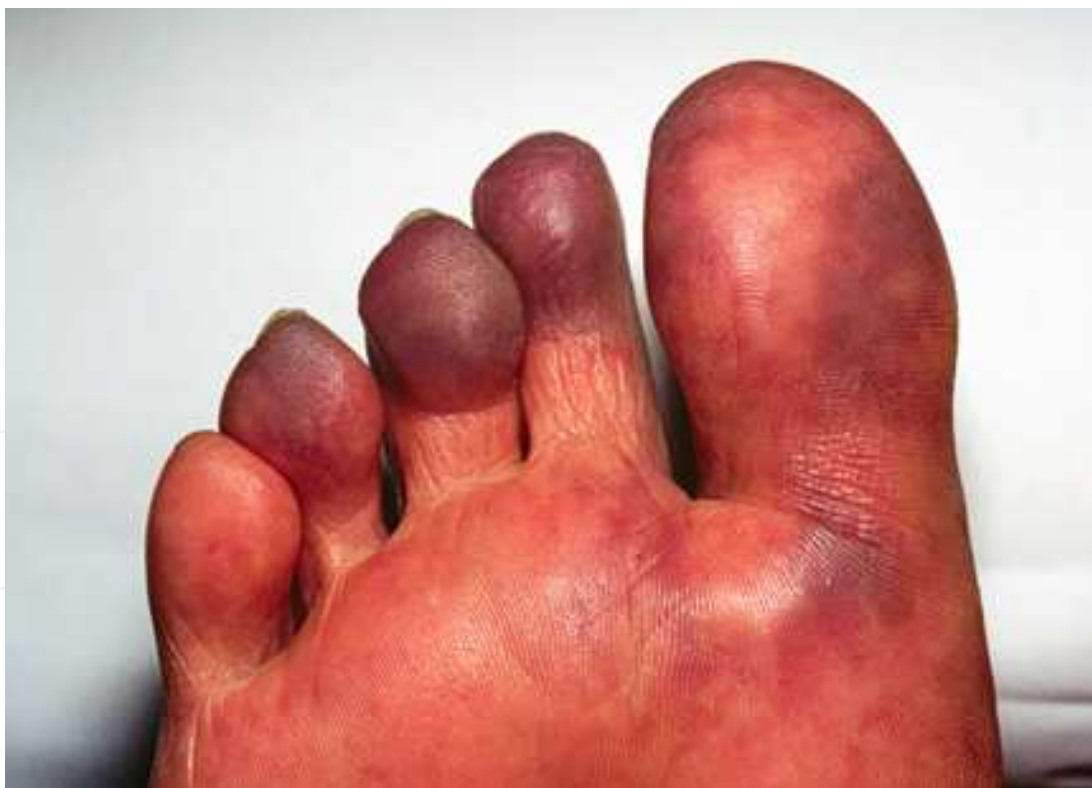6.3 Protamine

Allergic reactions to protamine sulfate occur occasionally, more often in insulin-dependent diabetic patients who have received NPH insulin (which contains protamine) in the past [1]. The rapid administration of protamine sulfate can also provoke back pain of unknown etiology.

In current practice, protamine is rarely administered. Most diagnostic catheterizations are done without heparin anticoagulation and in most interventional procedures the heparin is either allowed to wear off over the next two to three hours prior to sheath removal, or the sheath is removed in the fully anticoagulated state using an arterial closure device.

7. Atheroembolism

During the process of cardiac catheterization, atheromatous debris is often scraped from the aortic wall. This debris can cause systemic embolization, including cutaneous, renal, retinal, cerebral, and gastrointestinal emboli (**photo 1** and **photo 2** and **photo 3**). To minimize the risk of stroke or visual impairment, arterial catheter exchanges are best performed over a wire in the descending aorta at the level of the diaphragm (for closed loop catheters) and in the ascending aorta for angiographic catheters. Once arterial access has been obtained, the practice of readvancing the guidewire through the infrarenal aorta rather than exchanging it through a catheter should be avoided.

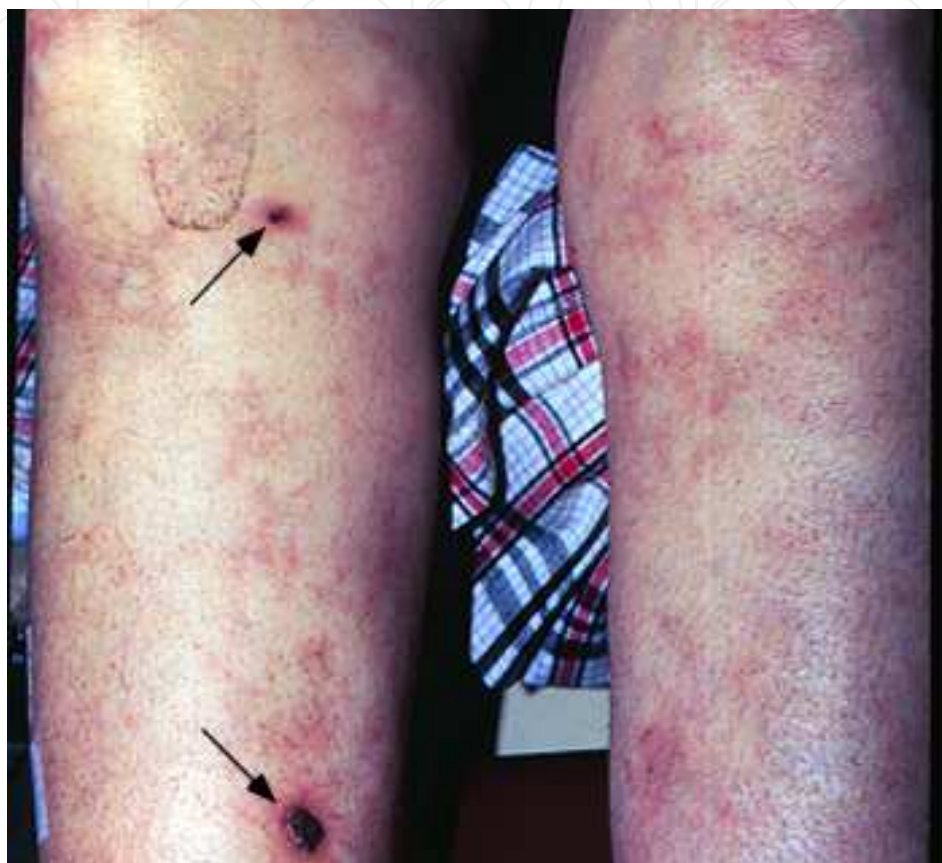

Blue toes are a classic manifestation of peripheral embolization of atheromatous material from proximal arterial sources (eg, aorta); the pedal pulses are often normal. This patient, who has a 30-year history of type 1 diabetes and severe peripheral vascular disease, presented with foot pain and discoloration. Cholesterol microemboli from the aorta were suspected to be the cause.

Photo 1. Blue toe syndrome

The high rate of release of atheromatous debris was illustrated in a series of 1000 patients undergoing percutaneous coronary intervention: 51 percent had aortic atheromatous material retrieved from the catheter after back flow of blood [43]. There were no associated in-hospital ischemic complications, probably due to sufficient withdrawal of blood containing the debris prior to the injection of contrast.

The reported incidence of atheroembolic events varies from 0.6 to 0.9 percent in retrospective studies to 1.4 to 1.9 percent in prospective series [44].



Patient with lupus and anti-phospholipid antibodies with livedo reticularis (manifested by a reddish-cyanotic, reticular pattern of the skin) which has resulted in ulcer formation (arrows).

Photo 2. Livedo reticularis

The clinical features of atheroembolism after diagnostic cardiac catheterization were examined in a prospective evaluation of 1786 patients ≥ 40 years of age [45]. The following observations were made:

- 25 patients (1.4 percent) were diagnosed with atheroembolism; 12 had cutaneous signs (eg, "blue toes" syndrome, livedo reticularis) (**photo 1** and **photo 2**) and 16 had acute renal failure that was considered to be atheroembolic in origin because it persisted for at least two weeks (while contrast nephropathy typically reverses within the first week).
- Eosinophil counts were significantly higher in patients suffering from atheroembolism both before and after catheterization.
- Four patients with atheroembolism died in hospital (16 percent); all had progressive renal dysfunction. The mortality rate was much lower (0.5 percent) in the patients without atheroembolism.

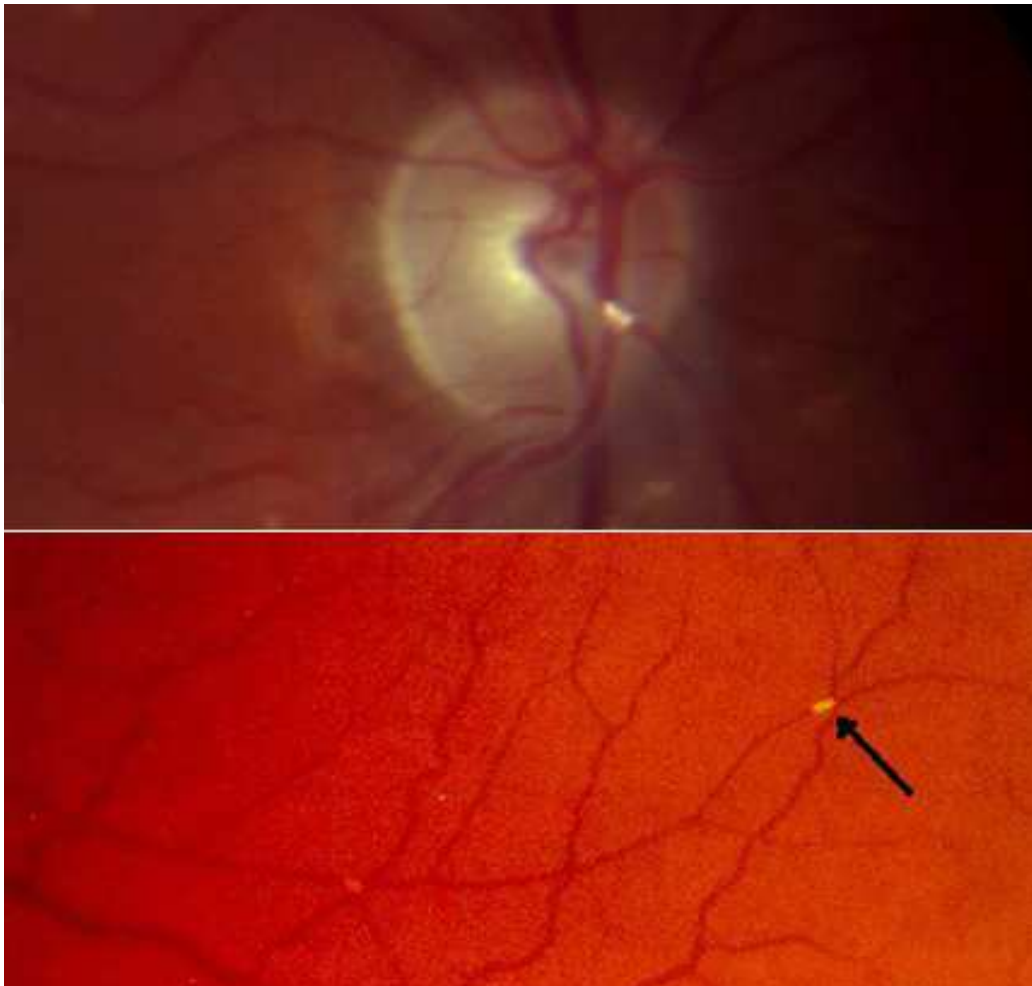


Photo 3. Hollenhorst plaque (cholesterol crystal, arrow) in retinal artery

8. Acute renal failure

There are three major causes of renal dysfunction related to cardiac catheterization: contrast-induced acute renal failure, renal atheroemboli, and hemodynamic instability with renal hypoperfusion.

8.1 Contrast nephropathy

At least 5 percent of patients who undergo cardiac catheterization experience a transient rise in the plasma creatinine concentration of more than 1.0 mg/dL (88 micromol/L) due to contrast-induced renal dysfunction [46].

However, there is substantial variability in risk among patients, some of whom have a risk that exceeds 50 percent. The risk is greatest in patients with moderate to severe renal insufficiency and diabetes.

The plasma creatinine concentration usually returns to baseline within seven days, and less than 1 percent of patients, usually diabetic patients with underlying severe chronic kidney disease, go on to require chronic hemodialysis.

Nonionic low osmolal contrast agents are now administered for the majority of radiologic procedures using intravascular contrast media, as a result of increased patient tolerability and decreased hypersensitivity reactions. However, in patients at risk for contrast nephropathy, we

prefer the use of iso-osmolal agents (approximately 290 mosmol/kg) rather than low osmolal agents (500 to 850 mosmol/kg) because of a lower risk of contrast nephropathy.

The 2007 focused update of the ACC/AHA/SCAI 2005 PCI guidelines recommended the use of iso-osmolal in preference to low osmolal agents in patients with chronic kidney disease [47].

8.2 Renal atheroemboli

The kidney is one of the principal end organs that may be affected by atheroembolic events. (See 'Atheroembolism' above.) There are three main findings that suggest that atheroemboli rather than contrast nephropathy is responsible for the development of acute renal failure after catheterization:

- The presence of other signs of embolization such as blue toes (**photo 1**), livedo reticularis (**photo 2**), Hollenhorst plaques in the retina (**photo 3**), and/or abdominal pain.
- Transient eosinophilia and hypocomplementemia.
- Persistent renal failure after seven days.

In a review of 1786 consecutive patients undergoing cardiac catheterization, acute renal failure developed in 0.9 percent overall and in 64 percent of those with evidence of any atheroembolism [45]. In this report, acute renal failure was considered to be due to renal atheroembolism if it had persisted for at least two weeks, well beyond the time at which contrast nephropathy should have resolved.

9. Infection

Cardiac catheterization procedures are performed using sterile technique. Thus, both local infection and bacteremia are rare and endocarditis prophylaxis during cardiac catheterization is not recommended for patients with valvular disease. Infection is approximately 10 times more common with the brachial approach compared to the femoral approach (0.6 versus 0.06 percent) [2-7].

Infection control guidelines for the cardiac catheterization laboratory were updated in 2006 by the Society for Cardiovascular Angiography and Interventions [48]. These guidelines emphasize the importance of handwashing caps, gowns, gloves, and masks to protect the patient against bacterial infection, and measures such as eye wear and vaccination for hepatitis B to protect laboratory personnel.

10. Radiation exposure

Patients undergoing diagnostic and interventional cardiac catheterization receive substantial radiation exposure.

11. Endomyocardial biopsy

Endomyocardial biopsy of right ventricular tissue is made using a relatively stiff catheter. Complications such as perforation of the heart or great vessels, life threatening arrhythmias, or heart block requiring permanent pacing occur uncommonly.

12. Conclusions

Cardiac catheterization is a common procedure with very low incidence of complications nowadays. We can consider different kind of adverse events. On the one hand, the events


related with the artery access, that are the most common, like haematoma, pseudoaneurysm or dissection. On the other hand, we can observe complications more severe like embolizations, renal failure or allergic reactions. Death is an uncommon complication, with a is generally well below 1 percent. It is very important to know the potential adverse events of these procedures in order to be aware to prevent it as better as possible.

13. References

- [1] Baim, DS, Grossman, W. Complications of cardiac catheterization. In: *Cardiac Catheterization, Angiography and Intervention*, Baim, DS, Grossman, W (Eds), Williams & Wilkins, Baltimore 1996. p.17.
- [2] Johnson LW, Lozner EC, Johnson S, et al. Coronary arteriography 1984-1987: a report of the Registry of the Society for Cardiac Angiography and Interventions. I. Results and complications. *Cathet Cardiovasc Diagn* 1989; 17:5.
- [3] Dorros G, Cowley MJ, Simpson J, et al. Percutaneous transluminal coronary angioplasty: report of complications from the National Heart, Lung, and Blood Institute PTCA Registry. *Circulation* 1983; 67:723.
- [4] Kennedy JW. Complications associated with cardiac catheterization and angiography. *Cathet Cardiovasc Diagn* 1982; 8:5.
- [5] Noto TJ Jr, Johnson LW, Krone R, et al. Cardiac catheterization 1990: a report of the Registry of the Society for Cardiac Angiography and Interventions (SCA&I). *Cathet Cardiovasc Diagn* 1991; 24:75.
- [6] Laskey W, Boyle J, Johnson LW. Multivariable model for prediction of risk of significant complication during diagnostic cardiac catheterization. The Registry Committee of the Society for Cardiac Angiography & Interventions. *Cathet Cardiovasc Diagn* 1993; 30:185.
- [7] Wyman RM, Safian RD, Portway V, et al. Current complications of diagnostic and therapeutic cardiac catheterization. *J Am Coll Cardiol* 1988; 12:1400.
- [8] King KM, Ghali WA, Faris PD, et al. Sex differences in outcomes after cardiac catheterization: effect modification by treatment strategy and time. *JAMA* 2004; 291:1220.
- [9] Hemmelgarn BR, Southern DA, Humphries KH, et al. Refined characterization of the association between kidney function and mortality in patients undergoing cardiac catheterization. *Eur Heart J* 2006; 27:1191.
- [10] Gruberg L, Mintz GS, Mehran R, et al. The prognostic implications of further renal function deterioration within 48 h of interventional coronary procedures in patients with pre-existent chronic renal insufficiency. *J Am Coll Cardiol* 2000; 36:1542.
- [11] Segal AZ, Abernethy WB, Palacios IF, et al. Stroke as a complication of cardiac catheterization: risk factors and clinical features. *Neurology* 2001; 56:975.
- [12] Hamon M, Baron JC, Viader F, Hamon M. Periprocedural stroke and cardiac catheterization. *Circulation* 2008; 118:678.
- [13] Omran H, Schmidt H, Hackenbroch M, et al. Silent and apparent cerebral embolism after retrograde catheterisation of the aortic valve in valvular stenosis: a prospective, randomised study. *Lancet* 2003; 361:1241.
- [14] Chambers J, Bach D, Dumesnil J, et al. Crossing the aortic valve in severe aortic stenosis: no longer acceptable? *J Heart Valve Dis* 2004; 13:344.

- [15] Büsing KA, Schulte-Sasse C, Flüchter S, et al. Cerebral infarction: incidence and risk factors after diagnostic and interventional cardiac catheterization--prospective evaluation at diffusion-weighted MR imaging. *Radiology* 2005; 235:177.
- [16] Lund C, Nes RB, Ugelstad TP, et al. Cerebral emboli during left heart catheterization may cause acute brain injury. *Eur Heart J* 2005; 26:1269.
- [17] Pracyk JB, Wall TC, Longabaugh JP, et al. A randomized trial of vascular hemostasis techniques to reduce femoral vascular complications after coronary intervention. *Am J Cardiol* 1998; 81:970.
- [18] Ward SR, Casale P, Raymond R, et al. Efficacy and safety of a hemostatic puncture closure device with early ambulation after coronary angiography. *Angio-Seal Investigators. Am J Cardiol* 1998; 81:569.
- [19] Kapadia SR, Raymond R, Knopf W, et al. The 6Fr Angio-Seal arterial closure device: results from a multimember prospective registry. *Am J Cardiol* 2001; 87:789.
- [20] Silber S, Gershony G, Schön B, et al. A novel vascular sealing device for closure of percutaneous arterial access sites. *Am J Cardiol* 1999; 83:1248.
- [21] Silber S, Tofte AJ, Kjellevand TO, et al. Final report of the European multi-center registry using the Duett vascular sealing device. *Herz* 1999; 24:620.
- [22] Baim DS, Knopf WD, Hinohara T, et al. Suture-mediated closure of the femoral access site after cardiac catheterization: results of the suture to ambulate and discharge (STAND I and STAND II) trials. *Am J Cardiol* 2000; 85:864.
- [23] Koreny M, Riedmüller E, Nikfardjam M, et al. Arterial puncture closing devices compared with standard manual compression after cardiac catheterization: systematic review and meta-analysis. *JAMA* 2004; 291:350.
- [24] Nikolsky E, Mehran R, Halkin A, et al. Vascular complications associated with arteriotomy closure devices in patients undergoing percutaneous coronary procedures: a meta-analysis. *J Am Coll Cardiol* 2004; 44:1200.
- [25] Geary K, Landers JT, Fiore W, Riggs P. Management of infected femoral closure devices. *Cardiovasc Surg* 2002; 10:161.
- [26] Cherr GS, Travis JA, Ligush J Jr, et al. Infection is an unusual but serious complication of a femoral artery catheterization site closure device. *Ann Vasc Surg* 2001; 15:567.
- [27] El-Jack SS, Ruygrok PN, Webster MW, et al. Effectiveness of manual pressure hemostasis following transfemoral coronary angiography in patients on therapeutic warfarin anticoagulation. *Am J Cardiol* 2006; 97:485.
- [28] Krueger K, Zaehring M, Strohe D, et al. Postcatheterization pseudoaneurysm: results of US-guided percutaneous thrombin injection in 240 patients. *Radiology* 2005; 236:1104.
- [29] Katzenschlager R, Ugurluoglu A, Ahmadi A, et al. Incidence of pseudoaneurysm after diagnostic and therapeutic angiography. *Radiology* 1995; 195:463.
- [30] Webber GW, Jang J, Gustavson S, Olin JW. Contemporary management of postcatheterization pseudoaneurysms. *Circulation* 2007; 115:2666.
- [31] Muller DW, Shamir KJ, Ellis SG, Topol EJ. Peripheral vascular complications after conventional and complex percutaneous coronary interventional procedures. *Am J Cardiol* 1992; 69:63.
- [32] Popma JJ, Satler LF, Pichard AD, et al. Vascular complications after balloon and new device angioplasty. *Circulation* 1993; 88:1569.

- [33] Paulson EK, Sheafor DH, Kliewer MA, et al. Treatment of iatrogenic femoral arterial pseudoaneurysms: comparison of US-guided thrombin injection with compression repair. *Radiology* 2000; 215:403.
- [34] La Perna L, Olin JW, Goines D, et al. Ultrasound-guided thrombin injection for the treatment of postcatheterization pseudoaneurysms. *Circulation* 2000; 102:2391.
- [35] Hamraoui K, Ernst SM, van Dessel PF, et al. Efficacy and safety of percutaneous treatment of iatrogenic femoral artery pseudoaneurysm by biodegradable collagen injection. *J Am Coll Cardiol* 2002; 39:1297.
- [36] Agostoni P, Biondi-Zoccai GG, de Benedictis ML, et al. Radial versus femoral approach for percutaneous coronary diagnostic and interventional procedures; Systematic overview and meta-analysis of randomized trials. *J Am Coll Cardiol* 2004; 44:349.
- [37] Greenwood MJ, Della-Siega AJ, Fretz EB, et al. Vascular communications of the hand in patients being considered for transradial coronary angiography: is the Allen's test accurate? *J Am Coll Cardiol* 2005; 46:2013.
- [38] Barbeau GR, Arsenault F, Dugas L, et al. Evaluation of the ulnopalmar arterial arches with pulse oximetry and plethysmography: comparison with the Allen's test in 1010 patients. *Am Heart J* 2004; 147:489.
- [39] Benit E, Vranckx P, Jaspers L, et al. Frequency of a positive modified Allen's test in 1,000 consecutive patients undergoing cardiac catheterization. *Cathet Cardiovasc Diagn* 1996; 38:352.
- [40] Hovagim AR, Katz RI, Poppers PJ. Pulse oximetry for evaluation of radial and ulnar arterial blood flow. *J Cardiothorac Anesth* 1989; 3:27.
- [41] Harvey JR, Wyman RM, McKay RG, Baim DS. Use of balloon flotation pacing catheters for prophylactic temporary pacing during diagnostic and therapeutic catheterization procedures. *Am J Cardiol* 1988; 62:941.
- [42] Tsang TS, Freeman WK, Barnes ME, et al. Rescue echocardiographically guided pericardiocentesis for cardiac perforation complicating catheter-based procedures. The Mayo Clinic experience. *J Am Coll Cardiol* 1998; 32:1345.
- [43] Keeley EC, Grines CL. Scraping of aortic debris by coronary guiding catheters: a prospective evaluation of 1,000 cases. *J Am Coll Cardiol* 1998; 32:1861.
- [44] Bashore TM, Gehrig T. Cholesterol emboli after invasive cardiac procedures. *J Am Coll Cardiol* 2003; 42:217.
- [45] Fukumoto Y, Tsutsui H, Tsuchihashi M, et al. The incidence and risk factors of cholesterol embolization syndrome, a complication of cardiac catheterization: a prospective study. *J Am Coll Cardiol* 2003; 42:211.
- [46] Tommaso CL. Contrast-induced nephrotoxicity in patients undergoing cardiac catheterization. *Cathet Cardiovasc Diagn* 1994; 31:316.
- [47] King SB, 3rd, Smith, SC Jr, Hirshfeld, JW Jr, et al. 2007 Focused Update of the ACC/AHA/SCAI 2005 Guideline Update for Percutaneous Coronary Intervention: a report of the American College of Cardiology/American Heart Association Task Force on Practice Guidelines: 2007 Writing Group to Review New Evidence and Update the ACC/AHA/SCAI 2005 Guideline Update for Percutaneous Coronary Intervention, Writing on Behalf of the 2005 Writing Committee. *Circulation* 2008; 117:261.
- [48] Chambers CE, Eisenhauer MD, McNicol LB, et al. Infection control guidelines for the cardiac catheterization laboratory: society guidelines revisited. *Catheter Cardiovasc Interv* 2006; 67:78.



Advances in the Diagnosis of Coronary Atherosclerosis

Edited by Prof. Suna Kirac

ISBN 978-953-307-286-9

Hard cover, 378 pages

Publisher InTech

Published online 09, November, 2011

Published in print edition November, 2011

Coronary artery disease (CAD) and its consequences are most important morbidity and mortality reasons in the developed and developing countries. To prevent hard end-points, early definitive diagnosis and optimum therapy play significant role. Novel advanced diagnostic tests which are biomarkers of inflammation, cell adhesion, cell activation and imaging techniques provide to get the best result in the detection and characterization of calcified or uncalcified atherosclerotic plaques. In spite of last developments in the imaging methods, coronary catheterization is still frequently performed. Following the first cardiac catheterization performed in 1844, date by date historical developments and the mechanics of cardiac catheterization techniques, risks associated with coronary angiography, and also, preventions and treatments of possible complications have been presented in this book. Other important issue is radiation exposure of patients and staff during coronary angiography and scintigraphy. Radiation dose reduction techniques, general radiation protection principles have been discussed in related chapters.

How to reference

In order to correctly reference this scholarly work, feel free to copy and paste the following:

Mariano García-Borbolla, Rafael García-Borbolla and Begoña Balboa (2011). Complications of Cardiac Catheterization, *Advances in the Diagnosis of Coronary Atherosclerosis*, Prof. Suna Kirac (Ed.), ISBN: 978-953-307-286-9, InTech, Available from: <http://www.intechopen.com/books/advances-in-the-diagnosis-of-coronary-atherosclerosis/complications-of-cardiac-catheterization>

INTECH
open science | open minds

InTech Europe

University Campus STeP Ri
Slavka Krautzeka 83/A
51000 Rijeka, Croatia
Phone: +385 (51) 770 447
Fax: +385 (51) 686 166
www.intechopen.com

InTech China

Unit 405, Office Block, Hotel Equatorial Shanghai
No.65, Yan An Road (West), Shanghai, 200040, China
中国上海市延安西路65号上海国际贵都大饭店办公楼405单元
Phone: +86-21-62489820
Fax: +86-21-62489821

© 2011 The Author(s). Licensee IntechOpen. This is an open access article distributed under the terms of the [Creative Commons Attribution 3.0 License](#), which permits unrestricted use, distribution, and reproduction in any medium, provided the original work is properly cited.

IntechOpen

IntechOpen