

# We are IntechOpen, the world's leading publisher of Open Access books Built by scientists, for scientists

## 4,800

Open access books available

## 122,000

International authors and editors

## 135M

Downloads

Our authors are among the

## 154

Countries delivered to

## TOP 1%

most cited scientists

## 12.2%

Contributors from top 500 universities

**WEB OF SCIENCE™**Selection of our books indexed in the Book Citation Index  
in Web of Science™ Core Collection (BKCI)

Interested in publishing with us?  
Contact [book.department@intechopen.com](mailto:book.department@intechopen.com)

Numbers displayed above are based on latest data collected.

For more information visit [www.intechopen.com](http://www.intechopen.com)

# History of Coronary Angiography

Ryotaro Wake, Minoru Yoshiyama et al.\*  
*Osaka City University Graduate School of Medicine,  
Osaka City General Hospital, Tsukazaki Hospital  
Japan*

## 1. Introduction

Diagnostic cardiac catheterization is recommended whenever it is clinically important to define the presence of cardiac disease that cannot be evaluated adequately by noninvasive techniques. Because the risk of a major complication from cardiac catheterization is less than 1% with mortality of less than 0.08%, many doctors can perform the catheterization safely now. We discuss the history of coronary angiography.

## 2. X-ray

We must talk about X-rays, at first, when we discuss the history of coronary angiography. In 1895, Roentgen discovered the x-rays. In 1896, X-rays of fractures had been obtained and published. Walter B. Cannon observed the movements of the opaque mass in the stomach and subsequently with mixing bismuth subnitrate described the nature and site of peristaltic activity in cats as seen on the fluoroscopic screen.

Walsh published "The Röntgen Rays in Medical Work. New York: William Wood, 1898." He reproduced a chest film that clearly showed the position and dimensions of the heart and describe a number of cardiac and aortic conditions that he visualized radiographically. The radiograph in his book required an exposure time of 20 minutes, with the tube only 30 inches (76 cm) from the radiographic plate (Figure 1).

## 3. Angiogram

Visualization of human blood vessels was achieved in January 1896, during the month after the announcement of Roentgen's discovery, when Haschek and Lindenthal injected Teichmann's mixture, composed mainly of calcium carbonate, into the blood vessels of an amputated hand. A published photograph of their original roentgenogram clearly showed the potential of the method for visualizing the vascular bed (Figure 2).

Morton who was a pioneer American radiologist wrote a text entitled "The X-ray, or, Photography of the Invisible and Its Value in Surgery. New York: American Technical

---

\* Hidetaka Iida, Hiroaki Takeshita, Takanori Kusuyama, Hitoshi Kanamitsu, Hideya Mitsui, Yukio Yamada, Shinichi Shimodozono and Kazuo Haze  
*Osaka City University Graduate School of Medicine, Osaka City General Hospital, Tsukazaki Hospital, Japan*

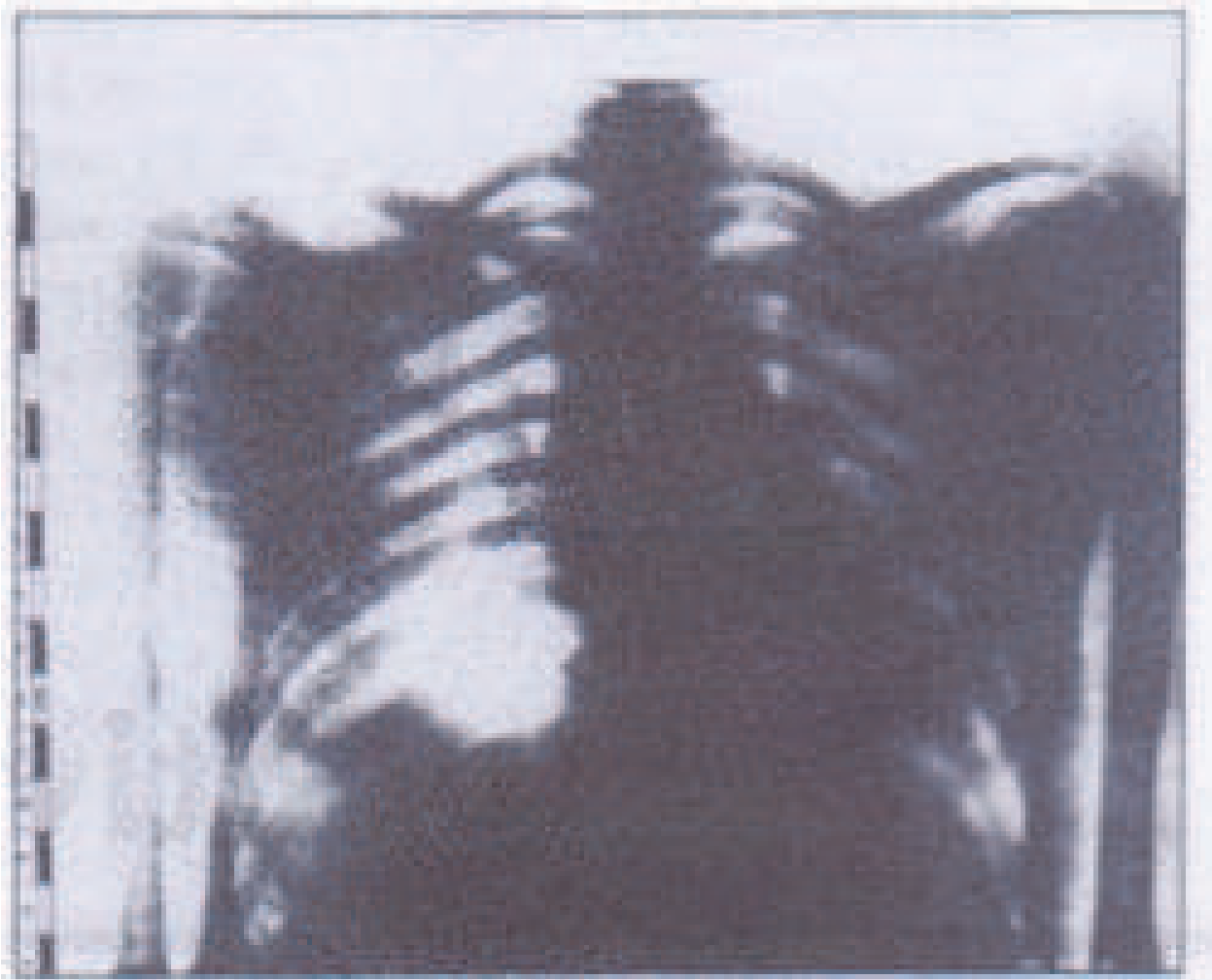

Fig. 1. The chest film from "The Röntgen Rays in Medical Work".

Book Company. 1896." In this book, his remarks concerning contrast studies are intriguing.

In teaching the anatomy of the blood vessels, the X-ray opens out a new and feasible method. The arteries and veins of dead bodies may be injected with a substance opaque to the X-ray and thus, their distribution may be more accurately followed than by any possible dissection. The feasibility of this method applies equally well to the study of the structures and organs of the dead body. To a certain extent, therefore, X-ray photography may replace both dissection and vivisection, and in the living body, the location and size of a hollow organ may be ascertained by causing the subject to drink a harmless fluid more or less opaque to the X-ray, or an effervescing mixture which will cause distention, and then taking the picture.

In 1920, a radiographic atlas devoted only to the systemic arteries of the body was published in England, "The X-ray atlas of the systemic arteries of the body. London: Balliere, Tindall, and Cox, 1920," by Orrin. The reproductions showed blood vessels in cadavers with great clarity (Figure 3).

In 1910, Franek and Alwens introduced a suspension of bismuth and oil into the hearts of dogs and rabbits directly through the large veins and observed the passage of droplets from the heart into the lungs. In 1922, the work of Sicard and Forestier represented the next major

advance, when they used Lipiodol, an early oil-based contrast medium, to study the bronchial tree and then the spinal subarachnoid space. In 1923, they injected 5 ml of Lipiodol into the femoral vein of a dog and, with the aid of fluoroscopy, watched droplets move with increasing speed from the iliac vein into the heart. The Lipiodol was then pulverized by ventricular contraction, thrown with great speed into the pulmonary artery and finally spread as multiple emboli into the small vessels of the lungs, disappearing in 10-12 minutes. Next, they repeated the experiment with human subjects, in whom they carefully observed the course of the opaque oil from the antecubital vein to the pulmonary capillaries. They reported that the patients coughed as the oil reached the lungs but suffered no other ill effects.

In 1923, Berberich and Hirsch reported the first arteriograms and venograms obtained in human subjects, using 20% strontium bromide (Figure 4). In 1924, Brooks described the intraarterial injection of sodium iodide as a means of showing vessels of the lower extremities in humans (Figure 5).

In 1928, Moniz et al. described carotid angiography and its application to the study of cerebral lesions (Figure 6).

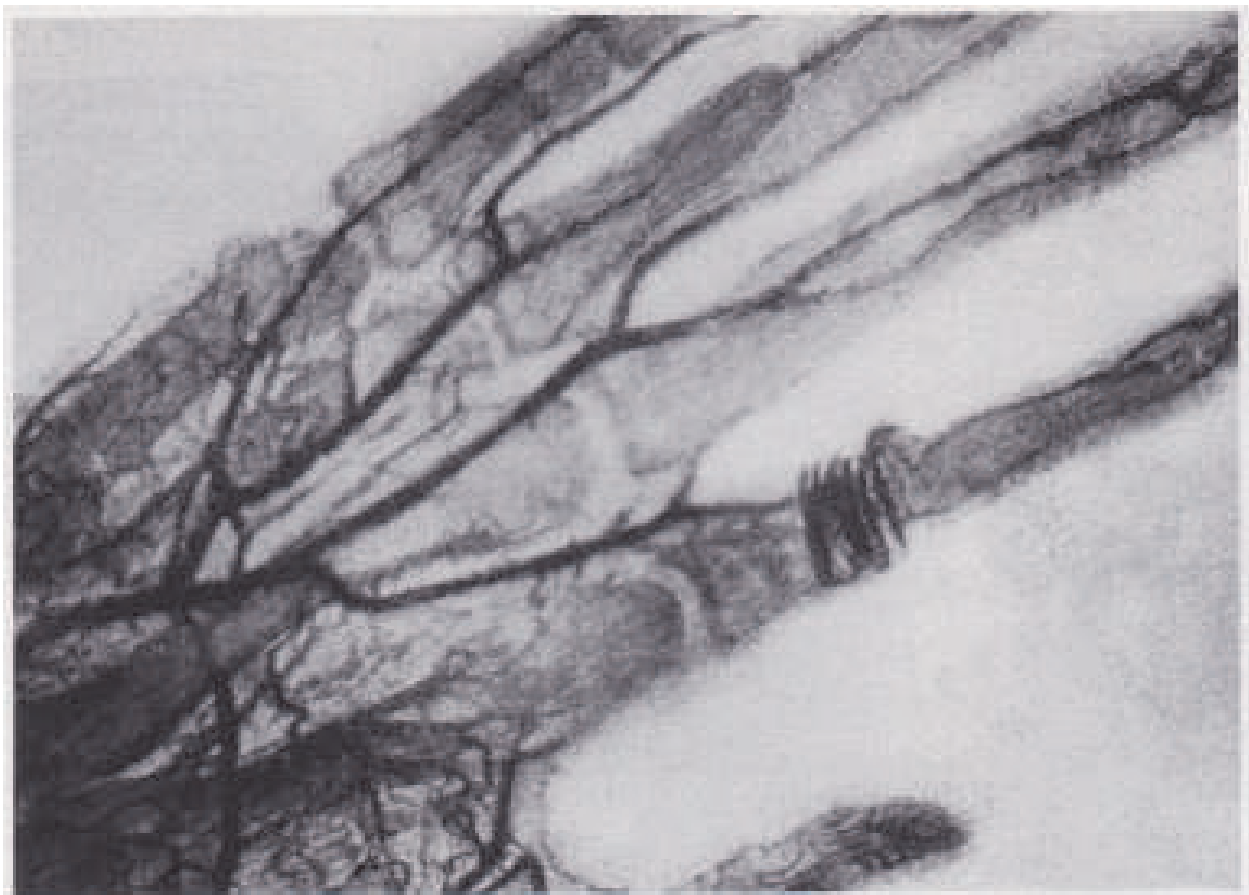


Fig. 2. A roentgenogram made by Haschek and Lindenthal after the injection of Teichman's mixture into the blood vessels of an amputated hand (Haschek E. Lindenthal O'F. A contribution to the practical use of the photography according to Röntgen. *Wien Klin Wochenschr* 1896:9:63.).

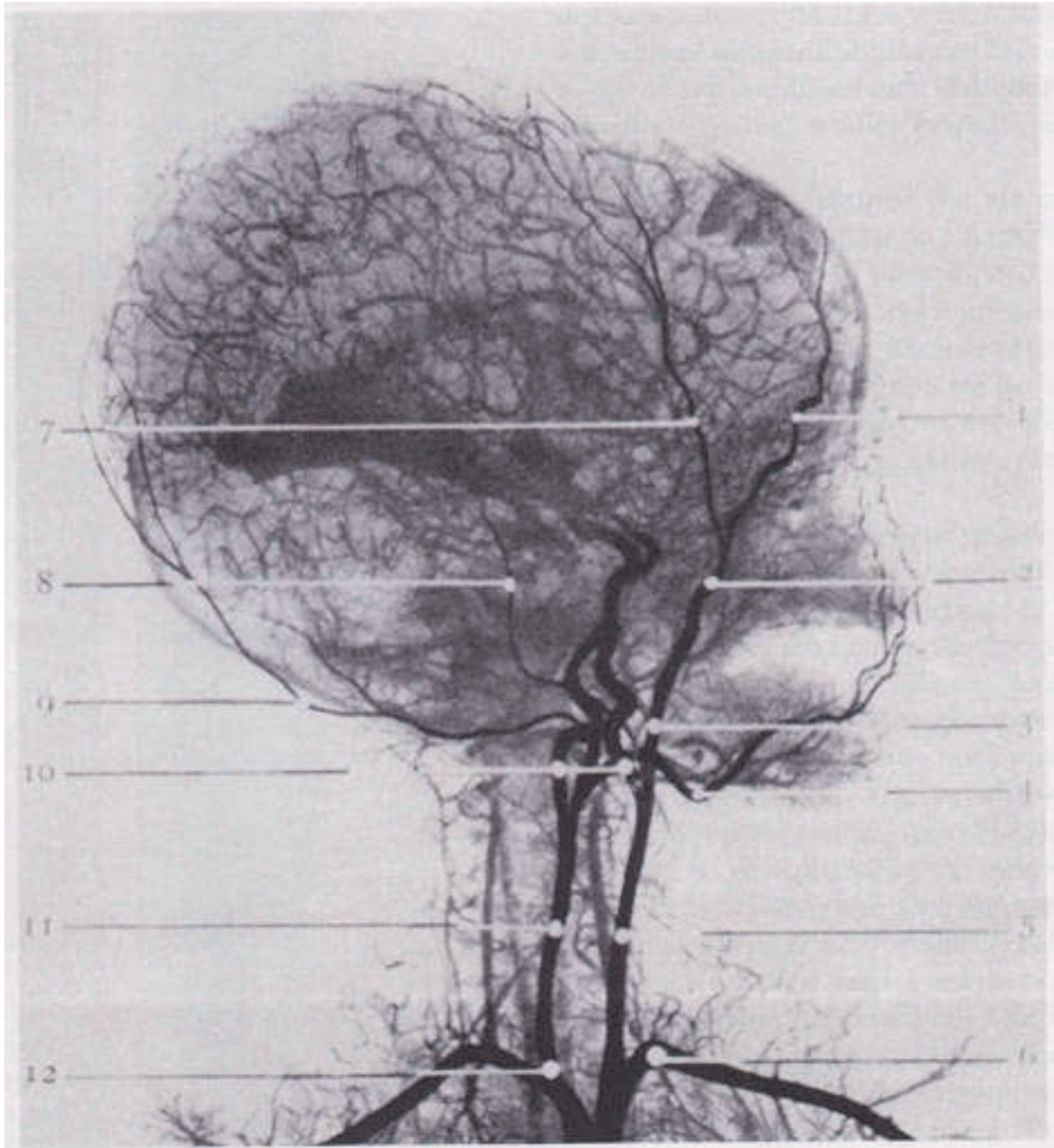


Fig. 3. Reproduction of a 1920 roentgenogram of a cadaver after the injection of opaque medium into the cerebral vessels (Orrin HC. *The x-ray atlas of the systemic arteries of the body*. London: Balliere, Tindall, and Cox,1920.).

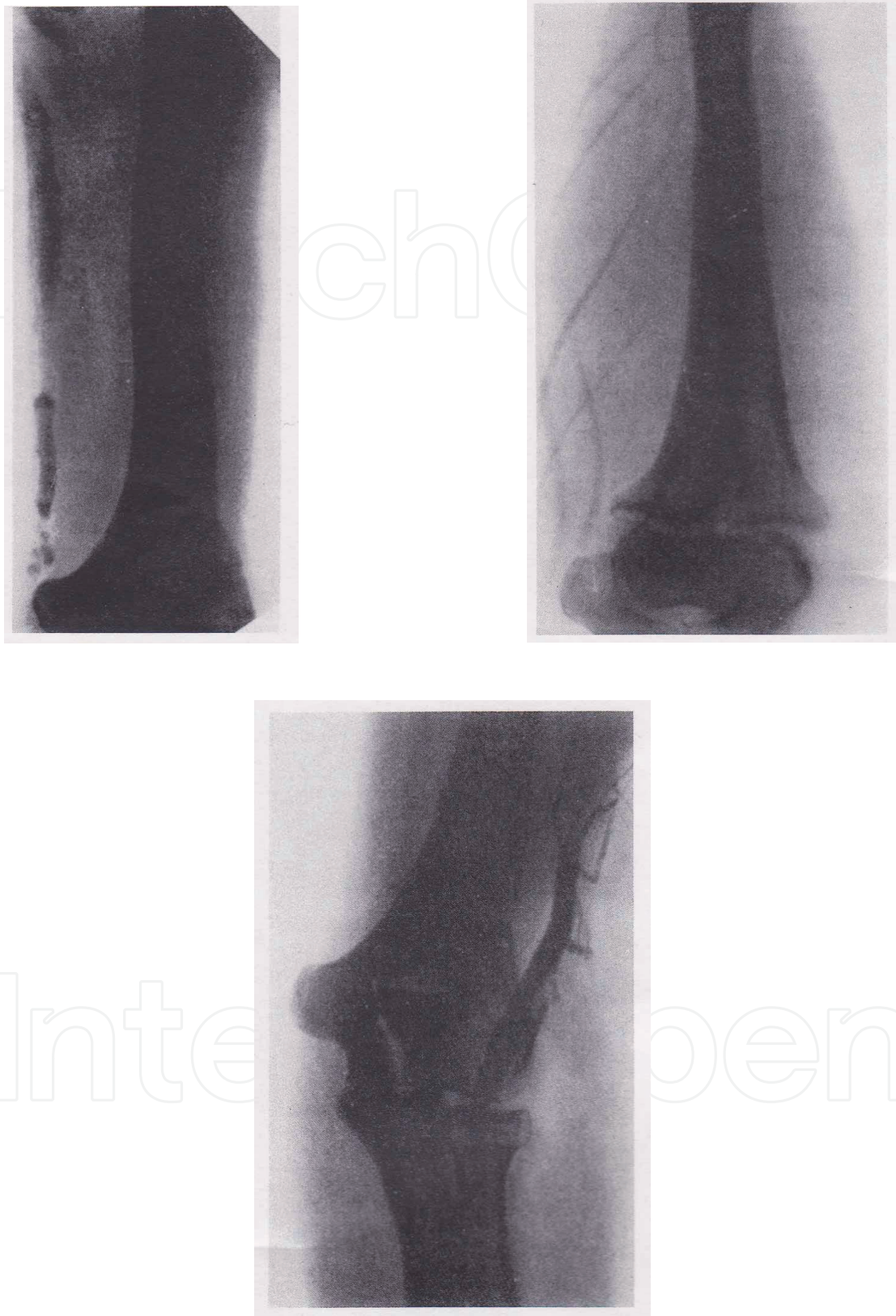

Fig. 4. Venographic studies obtained by Berberich and Hirsch in 1923. They injected 20% strontium bromide into the veins of the upper extremity (Berberich J Munchen Klin Wochenschr 1923;49:2226).

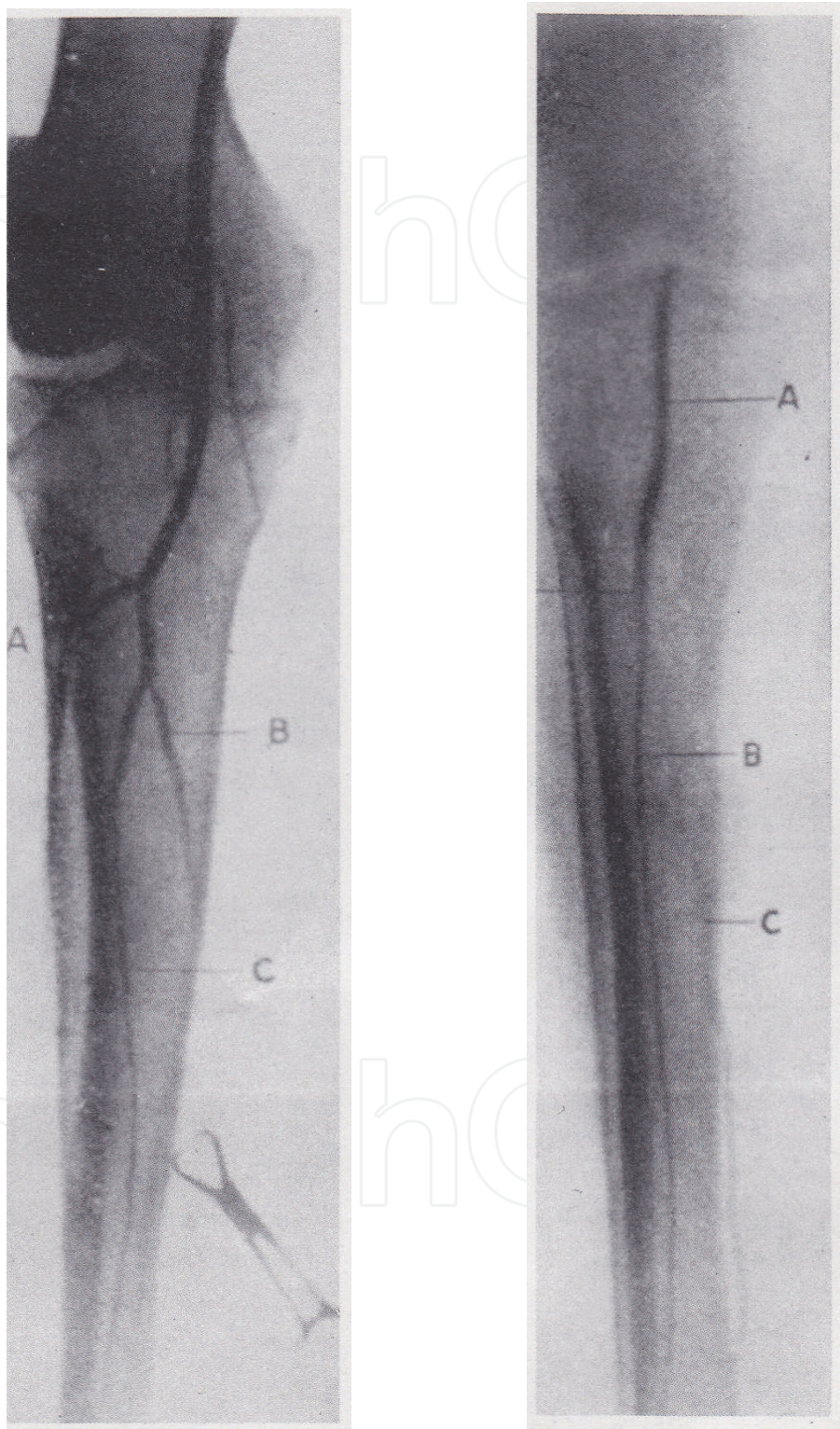


Fig. 5. The first femoral arteriogram obtained in a human subject. Brooks used sodium iodide as a means of demonstrating the vessels of the lower extremities in 1924(Brooks B. Intraarterial injection of sodium iodide. JAMA 1924; 82:1016.).

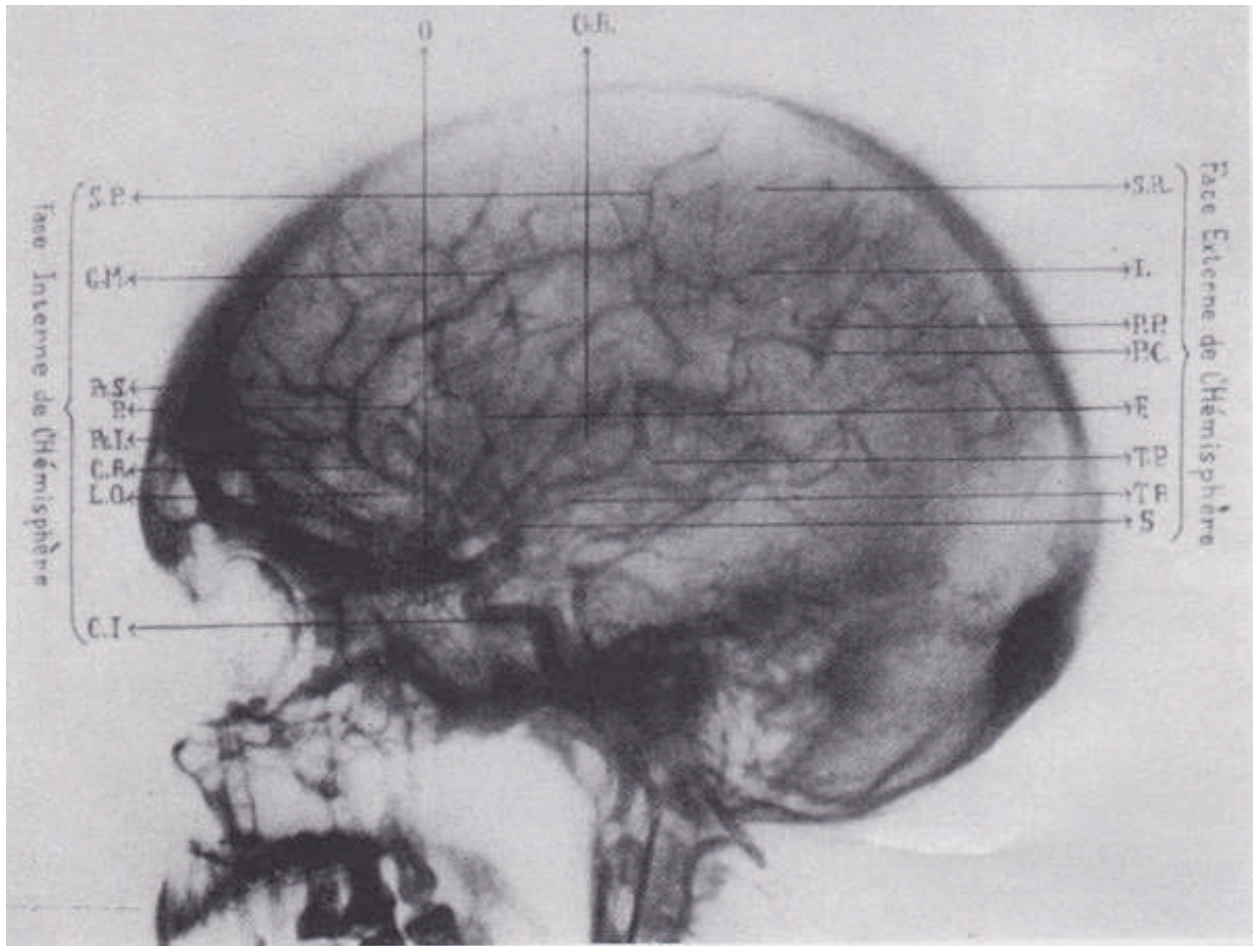


Fig. 6. Reproduction of a cerebral arteriogram (Moniz E. *J Radiol Electrol Med Nucl* 1928;12:72.)

#### 4. Cardiac catheterization

As Andre Cournand remarked in his Nobel lecture of December, 11th, 1956 ([http://nobelprize.org/nobel\\_prizes/medicine/laureates/](http://nobelprize.org/nobel_prizes/medicine/laureates/)). Cournand and his colleagues led us into a new era in the understanding of cardiac function in humans. According to Cournand, cardiac catheterization was performed and so named by Claude Bernard in 1844. The subject was a horse, and both the right and left ventricles were entered by retrograde approach from the jugular vein and carotid artery.

His careful application of scientific method to the study of cardiac physiology using the cardiac catheter demonstrated the enormous value of this technical innovation. An era of investigation of cardiovascular physiology in animals then followed, resulting in the development of many important techniques and principles (pressure manometry, the Fick cardiac output method), which awaited direct application to the patient with heart disease.



In 1928, Werner Forssmann, having practiced on a cadaver, inserted a 65 cm catheter into his own antecubital vein until he felt that it had reached the right atrium [1] (Figure 7). With the catheter dangling from his arm, he walked through a hospital basement to the radiographic room. There he obtained a roentgenogram that confirmed his belief that the catheter tip had in fact reached the right atrium.

During the next 2 years, Forssmann continued to perform catheterization studies including six additional attempts to catheterize himself. Bitter criticism, based on an unsubstantiated belief in the danger of his experiments, caused Forssmann to turn his attention to other concerns, and he eventually pursued another catheter-related career as a urologist. Nevertheless, for his contribution and foresight he shared the Nobel Prize in Medicine with Andre Cournand and Dickinson Richards in 1956. Forssmann's primary goal in his catheterization studies was to develop a therapeutic technique for the direct delivery of drugs into the heart.

He wrote, "If cardiac action ceases suddenly, as is seen in acute shock or in the heart disease, or during anesthesia or positioning, one is forced to deliver drugs locally. In such cases the intracardiac injection of drugs may be life saving. However, this may be a dangerous procedure because of many incidents of laceration of coronary arteries and their branches leading to cardiac tamponade, and death. Because of such incidents, one often waits until the very last moment and valuable time is wasted. Therefore I started to look for a new way to approach the heart, and I catheterized the right side of the heart through the venous system."

Others, however, appreciated the potential of using Forssmann's technique as a diagnostic tool. In 1930, Klein reported 11 right heart catheterizations, including passage to the right ventricle and measurement of cardiac output using Fick's principle. In 1932, Padillo and coworkers reported that right heart catheterization and measurement of cardiac output in two subjects. Except for these few early studies, application of cardiac catheterization to study the circulation in normal and disease states was fragmentary until the work of Andre Cournand and Dickinson Richards, who separately and in collaboration produced a remarkable series of investigations of right heart physiology in humans [2]. In 1947, Dexter reported his studies on congenital heart disease and passed the catheter to the distal pulmonary artery, describing "the oxygen saturation and source of pulmonary capillary blood" obtained from the pulmonary artery wedge position [3]. Subsequent studies from Dexter's laboratory [4] and by Werko elaborated the use of this pulmonary artery wedge position and reported that pressure measured at this position was a good estimate of pulmonary venous and left atrial pressure. During this exciting early period, catheterization was used to investigate problems in cardiovascular physiology by McMichael and Sharpey-Shafer in England. Lenegre and Maurice in Paris and Warren, Stead, Bing, Dexter, Cournand and others in the United States [5-9].

Further developments came rapidly in the 1950s and 1960s. Retrograde left heart catheterization was first reported by Zimmerman and others [10] and Limon-Lason and Bouchard in 1950. The percutaneous (rather than cut-down) technique was developed by Seldinger in 1953 and was soon applied to cardiac catheterization of both the left and right heart chambers [11]. Trans-septal catheterization was first developed by Ross [12] and Cope [13] in 1959 and quickly became accepted as a standard technique. Selective coronary angiography was reported by Sones and others in 1959 and was perfected to

remarkable excellence over the ensuing years [14]. Coronary angiography was modified for a percutaneous approach by Ricketts and Abrams [15] in 1962 and Judkins [16] in 1967. In 1970, Swan and Ganz introduced a practical balloon-tipped, flow-guided catheter technique enabling the application of catheterization outside the laboratory [17]. Better radiographic imaging techniques and less toxic radiographic contrast agents have been developed progressively, as many numbers of diagnostic catheterizations has performed (Figure 8).

In 1977, Grüntzig and others introduced the technique of balloon angioplasty, known as percutaneous transluminal coronary angioplasty (PTCA) [18].

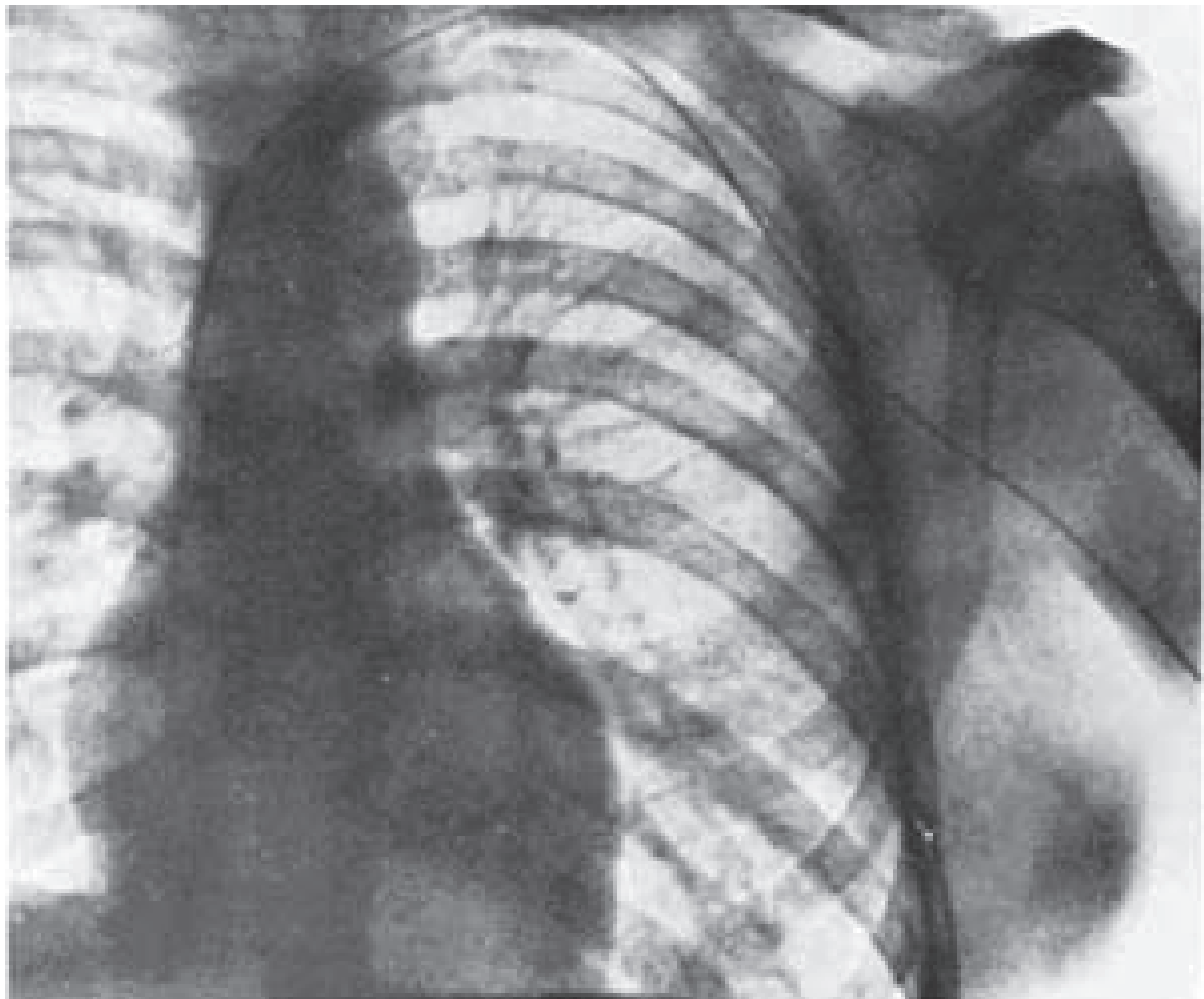


Fig. 7. The first documented cardiac catheterization. At age 25, while receiving clinical instruction in surgery at Eberswalde, Werner Forssmann passed a catheter 65 cm through one of his left antecubital veins until its tip entered the right atrium. He then walked to the radiology department where this roentgenogram was taken (Klin Wochenschr 1929;8:2085. Springer-Verlag, Berlin, Heidelberg, New York).

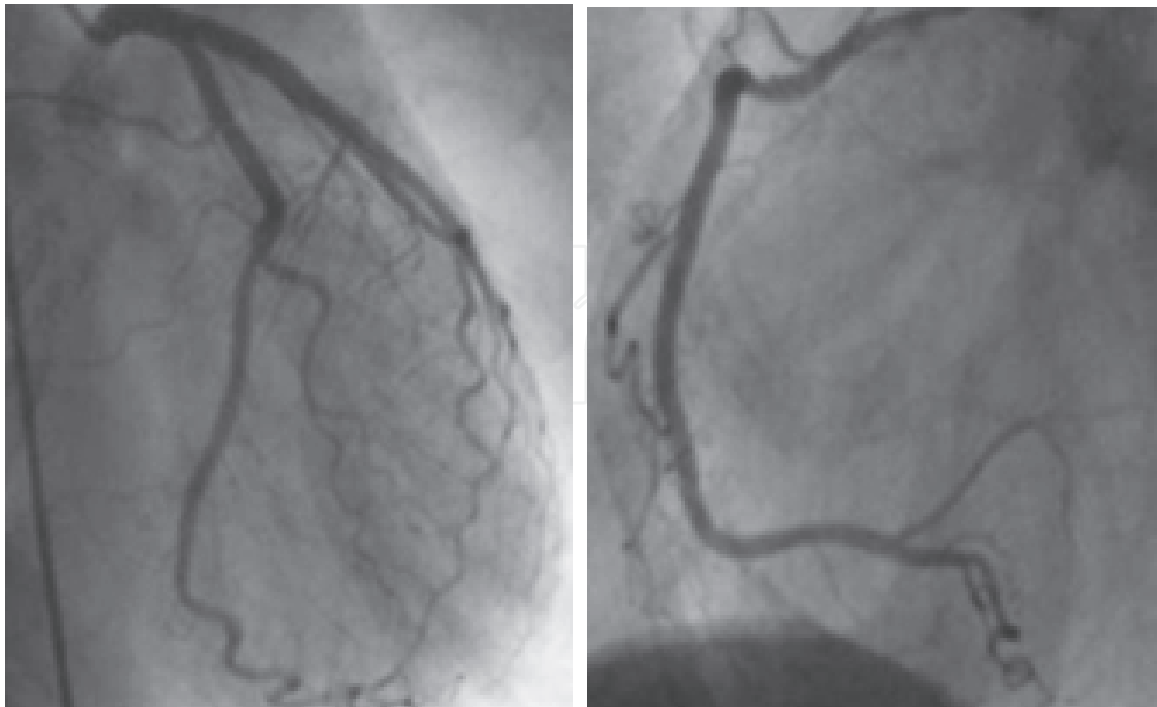


Fig. 8. Normal coronary angiogram. Left panel: left coronary artery. Right Panel: right coronary artery.

### 5. Equipments for coronary angiography

In the 1960s, great strides were made in the quality of image amplification, particularly with the introduction of the cesium iodide tube. Simultaneously, powerful generators capable of millisecond exposures and high contrast levels were developed. Cine cameras evolved into dependable instruments with fine-quality lenses that provide extraordinarily good resolution in modern 35-mm cine angiocardiology. Videotape recording techniques improved strikingly. Instantaneous playback of tape-recorded images has afforded great utility and safety in determining whether desired anatomic and physiologic information has been attained, thereby precluding additional unnecessary studies (Figure 8).

The introduction of angled views for the study of congenital and acquired heart disease was an important technical innovation [19]. Equipment companies responded with engineering advances that made angled views relatively simple: the C-arm, the U-arm, and the parallelogram.

Recently, the development of non-invasive angiography device is advancing. Echocardiography, scintigraphy, cardiac computed tomography and cardiac magnetic resonance imaging play increasingly important roles in the evaluation of the heart and great vessels, non-invasively. It is already an established technique for the evaluation of congenital heart disease, cardiac tumors and disorders of the aorta and pericardium. They can evaluate ventricular function and regurgitation of blood across heart valves.

### 6. Conclusion

Medicine moves so fast that its evolution tends to be forgotten. In particularly, techniques that have become an integral part of the standard device of diagnosis or therapy are passed

to each new generation of physicians and trainees. We perform them without their having sense of efforts involved in the initial development of those techniques.


In this one decade, we would be astonished at how far the field has come and how much information can be gathered on the structure and function of the heart from diagnostic imaging. A century is a short time in the history of medicine, but it has been an eventful lifetime.

## 7. References

- [1] Shapiro, S.M. et al. (1997) Primary pulmonary hypertension: improved long-term effects and survival with continuous intravenous epoprostenol infusion. *J Am Coll Cardiol*, Vol.30, No.2, pp. 343-349
- [2] Cournand, A. et al. (1945) Measurement Of Cardiac Output In Man Using The Technique Of Catheterization Of The Right Auricle Or Ventricle. *J Clin Invest*, Vol. 24, No.1, pp. 106-116
- [3] Dexter, L. et al. (1947) Studies Of Congenital Heart Disease. Ii. The Pressure And Oxygen Content Of Blood In The Right Auricle, Right Ventricle, And Pulmonary Artery In Control Patients, With Observations On The Oxygen Saturation And Source Of Pulmonary "Capillary" Blood. *J Clin Invest*, Vol. 26, No. 3, pp. 554-560
- [4] Hellems, H.K. et al. (1949) Pulmonary capillary pressure in man. *J Appl Physiol*, Vol. 2, No. 1, pp. 24-29
- [5] Bing, R.J. et al. (1947) Catheterization of the coronary sinus and the middle cardiac vein in man. *Proc Soc Exp Biol Med*, Vol. 66, No. 1, pp. 239
- [6] Bing, R.J. et al. (1947) Physiological studies in congenital heart disease. *Bull Johns Hopkins Hosp*, Vol. 80, No.2, pp. 107-120
- [7] Burchell, H.B. et al. (1948) Cardiac catheterization in the diagnosis of various cardiac malformations and diseases. *Mayo Clin Proc*, Vol. 23, No. 22, pp. 481 – 487
- [8] Stead, E.A., Jr. and Warren, J.V. (1947) Cardiac output in man; an analysis of the mechanisms varying the cardiac output based on recent clinical studies. *Arch Med Interna*, Vol. 80, No. 2, pp. 237-248
- [9] Stead, E.A., Jr. et al. (1948) Cardiac output in congestive heart failure; an analysis of the reasons for lack of close correlation between the symptoms of heart failure and the resting cardiac output. *Am Heart J*, Vol. 35, No.4, pp. 529-541
- [10] Zimmerman, H.A. et al. (1950) Catheterization of the left side of the heart in man. *Circulation*, Vol. 1, No. 3, pp. 357-359
- [11] Seldinger, S.I. (1953) Catheter replacement of the needle in percutaneous arteriography; a new technique. *Acta radiol* 39 (5), 368-376
- [12] Ross, J., Jr. (1959) Transeptal left heart catheterization: a new method of left atrial puncture. *Ann Surg*, Vol. 149, No. 3, pp. 395-401
- [13] Cope, C. (1959) Technique for transeptal catheterization of the left atrium; preliminary report. *J Thorac Surg*, Vol. 37, No. 4, pp. 482-486
- [14] Ryan, T.J. (2002) The coronary angiogram and its seminal contributions to cardiovascular medicine over five decades. *Circulation*, Vol. 106, No. 6, pp. 752-756
- [15] Ricketts, H.J. and Abrams, H.L. (1962) Percutaneous selective coronary cine arteriography. *JAMA*, Vol. 181, pp. 620-624
- [16] Judkins, M.P. (1967) Selective coronary arteriography. I. A percutaneous transfemoral technic. *Radiology*, Vol. 89, No.5, pp. 815-824

- [17] Swan, H.J. et al. (1970) Catheterization of the heart in man with use of a flow-directed balloon-tipped catheter. *N Engl J Med*, Vol. 283, No. 9, pp. 447-451
- [18] Gruntzig, A.R. et al. (1979) Nonoperative dilatation of coronary-artery stenosis: percutaneous transluminal coronary angioplasty. *N Engl J Med*, Vol. 301, No. 2, pp. 61-68
- [19] Bargeron, L.M., Jr. et al. (1977) Axial cineangiography in congenital heart disease. Section I. Concept, technical and anatomic considerations. *Circulation*, Vol. 56, No. 6, pp. 1075-1083

IntechOpen



## **Advances in the Diagnosis of Coronary Atherosclerosis**

Edited by Prof. Suna Kirac

ISBN 978-953-307-286-9

Hard cover, 378 pages

**Publisher** InTech

**Published online** 09, November, 2011

**Published in print edition** November, 2011

Coronary artery disease (CAD) and its consequences are most important morbidity and mortality reasons in the developed and developing countries. To prevent hard end-points, early definitive diagnosis and optimum therapy play significant role. Novel advanced diagnostic tests which are biomarkers of inflammation, cell adhesion, cell activation and imaging techniques provide to get the best result in the detection and characterization of calcified or uncalcified atherosclerotic plaques. In spite of last developments in the imaging methods, coronary catheterization is still frequently performed. Following the first cardiac catheterization performed in 1844, date by date historical developments and the mechanics of cardiac catheterization techniques, risks associated with coronary angiography, and also, preventions and treatments of possible complications have been presented in this book. Other important issue is radiation exposure of patients and staff during coronary angiography and scintigraphy. Radiation dose reduction techniques, general radiation protection principles have been discussed in related chapters.

### **How to reference**

In order to correctly reference this scholarly work, feel free to copy and paste the following:

Ryotaro Wake, Minoru Yoshiyama, Hidetaka Iida, Hiroaki Takeshita, Takanori Kusuyama, Hitoshi Kanamitsu, Hideya Mitsui, Yukio Yamada, Shinichi Shimodozono and Kazuo Haze (2011). History of Coronary Angiography, *Advances in the Diagnosis of Coronary Atherosclerosis*, Prof. Suna Kirac (Ed.), ISBN: 978-953-307-286-9, InTech, Available from: <http://www.intechopen.com/books/advances-in-the-diagnosis-of-coronary-atherosclerosis/history-of-coronary-angiography>

**INTECH**  
open science | open minds

### **InTech Europe**

University Campus STeP Ri  
Slavka Krautzeka 83/A  
51000 Rijeka, Croatia  
Phone: +385 (51) 770 447  
Fax: +385 (51) 686 166  
[www.intechopen.com](http://www.intechopen.com)

### **InTech China**

Unit 405, Office Block, Hotel Equatorial Shanghai  
No.65, Yan An Road (West), Shanghai, 200040, China  
中国上海市延安西路65号上海国际贵都大饭店办公楼405单元  
Phone: +86-21-62489820  
Fax: +86-21-62489821

© 2011 The Author(s). Licensee IntechOpen. This is an open access article distributed under the terms of the [Creative Commons Attribution 3.0 License](#), which permits unrestricted use, distribution, and reproduction in any medium, provided the original work is properly cited.

IntechOpen

IntechOpen