

We are IntechOpen, the world's leading publisher of Open Access books Built by scientists, for scientists

4,800

Open access books available

122,000

International authors and editors

135M

Downloads

Our authors are among the

154

Countries delivered to

TOP 1%

most cited scientists

12.2%

Contributors from top 500 universities



WEB OF SCIENCE™

Selection of our books indexed in the Book Citation Index
in Web of Science™ Core Collection (BKCI)

Interested in publishing with us?
Contact book.department@intechopen.com

Numbers displayed above are based on latest data collected.

For more information visit www.intechopen.com



Encephalitis Due to *Loa loa*

Jean Paul Akue
International Center For Medical Research
Franceville (CIRMF),
Gabon

1. Introduction

Loa loa encephalitis is becoming an important public health problem, as it impedes the use of some important drugs (ivermectin and DEC) for mass control of filarial disease in parts of West Africa where onchocerciasis is endemic. *Loa* encephalitis may occur either spontaneously or following chemotherapy targeting *Loa loa*. Although *Loa loa* is restricted to the West African rain forest block, imported cases are described throughout the world, due to intense economic, cultural and touristic population exchanges. The most common clinical features of loiasis are swelling angioedema (calabar oedema) and ocular passage of the adult worm under the conjunctiva (eye worm). *Loa loa* disease may be particularly severe in expatriates (Nutman et al., 1986). *Loa loa* may cause a localized or systemic disease with involvement of deep organs including the kidney and heart. Only one-third of infected individuals have microfilariae in peripheral blood, leading to an underestimation of the prevalence of this infection. Most expatriates with loiasis have the adult worm but are amicrofilaremic (Churchill et al., 1996). The heterogeneous clinical expression of loiasis encephalopathy calls for greater awareness among scientist and medical practitioners worldwide.

2. The pathogen: *Loa loa*

Loa loa is a filarial worm restricted to West Africa (Figure 1), from Guinea in the north through Benin to Uganda in the East, Gabon, Cameroun and Nigeria in the west, and Angola in the South. Parts of Cameroun, Gabon, Nigeria, Congo Brazzaville and Congo Kinshasa (DRC) are hyperendemic. Common clinical signs include eye worm and calabar swelling. *Loa loa* adults produce microfilariae that are released into the peripheral blood. They reach their maximal concentration in peripheral blood during daytime (diurnal periodicity). This larval stage of *Loa loa* is the likely etiologic agent of encephalitis during loiasis. The parasite was first described in 1770 (Mongin, 1770) in the eye of a servant in the island of St Domingue. Only few autochthonous case of loiasis has been reported outside of Africa, in India (Barua et al., 2005; Kethan, 2007), although *Loa loa* can develop successfully in *Chrysops atlanticus*, which is widespread in Louisiana and Mississippi (Orihel & Lowrie, 1975). *Loa loa* is thought to infect 13 million individuals living in endemic zones (Fain, 1978), as well as individuals visiting these areas (Varhaug,2005; Carbonez et al.,2002; Hee-Yoon et

al., 2008). However, this prevalence is based on the detection of microfilariae in blood and may therefore be an under-estimation, as about one-third of subjects are amicrofilaremic (Dupont et al., 1988). The adult worm can survive for up to 15 years in its human host.

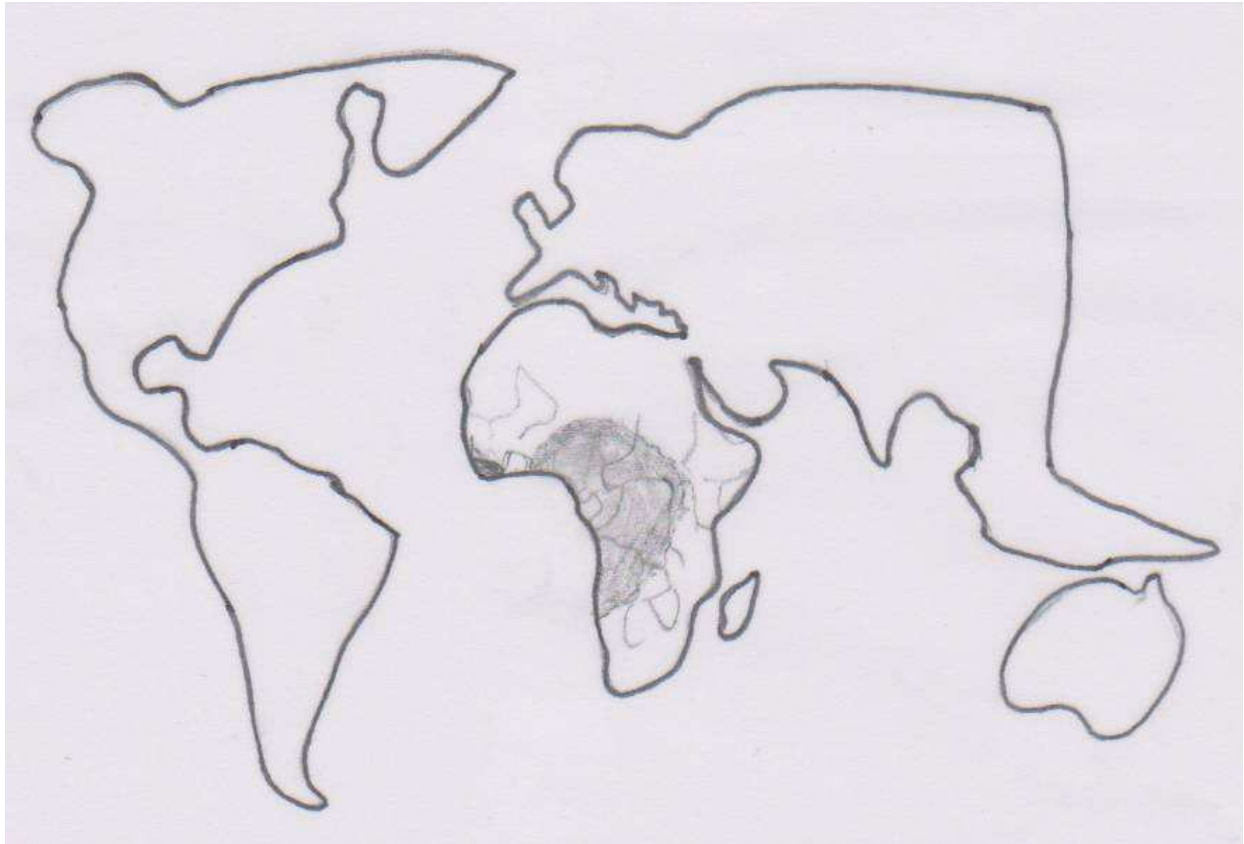

Fig. 1. Distribution of *Loa loa*

The life cycle of *Loa loa* (Figure 2) starts when a female fly of the genus *Chrysops* (*C. silacea*, *dimidiata* or *distinctipennis*) bites an individual harboring *L. loa* microfilariae. The microfilariae reach the stomach of the fly and migrate to the fat body after several mutations to stage L3 (infective larvae). These migrate to the proboscis and are deposited in the host's skin during the next blood meal. Once in the skin, the infective stages moult and reach the adult stage about a year later. The adult remains under the skin but can migrate to different parts of the body, including the ocular conjunctiva (hence the name 'eye worm'). Microfilariae have a diurnal periodicity, being found in peripheral blood from about 5 am to 7 pm, with peak from 9 am to 5 pm (Kershaw, 1950). The existence of an animal reservoir is a possibility (Fain., 1981), as about 10% of blood meals of *C. silacea* and *C. dimidiata* (Gouteux et al., 1989) from hippopotami, rodents, wild ruminants and monitor lizards contain *L. loa* microfilaria, and human *L. loa* isolates have been successfully maintained in drills (Duke, 1957), baboons, and patas (Orihel & Moore., 1975), rhesus (Grieve et al., 1985), and mandrill monkeys (Pinder et al., 1994).

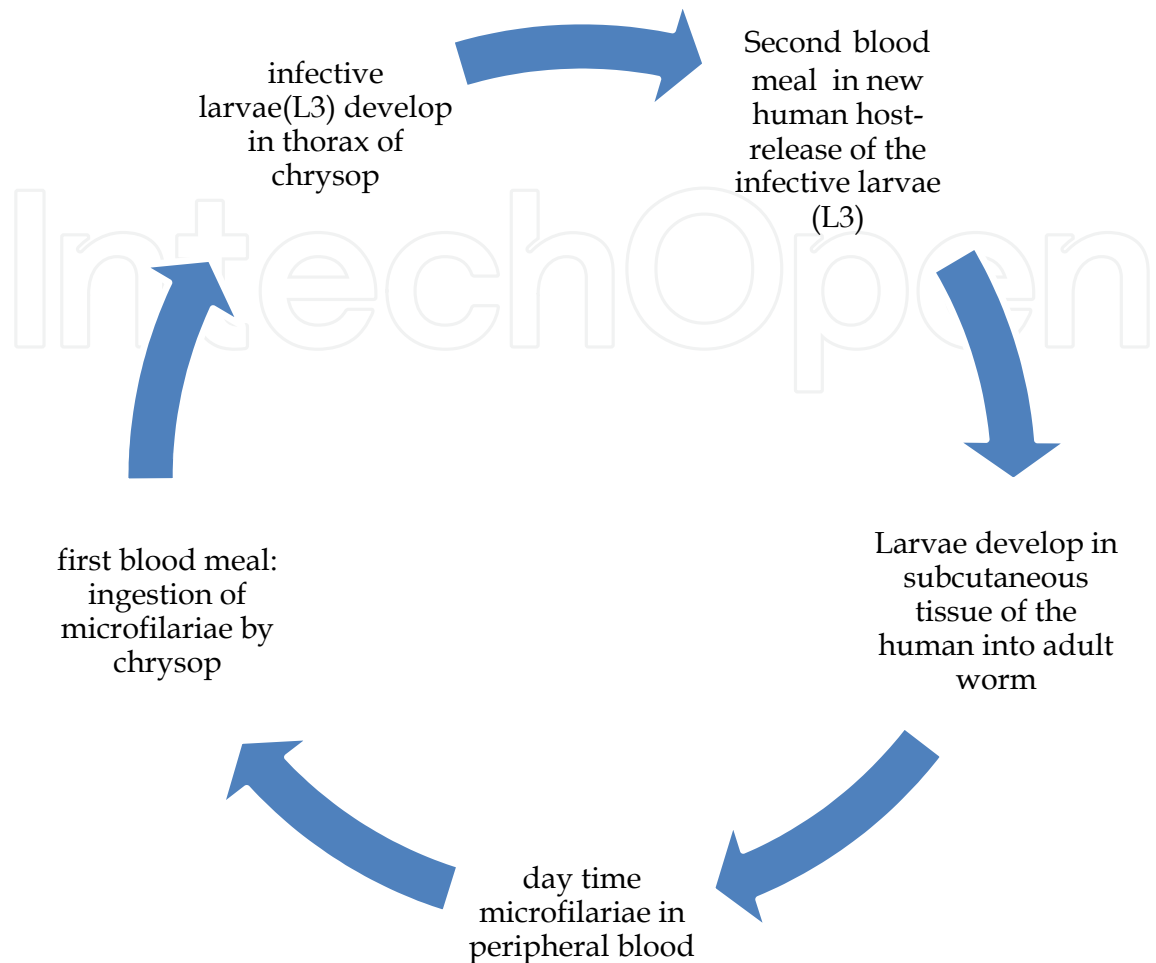


Fig. 2. Life cycle of *Loa loa*

3. The vectors

Chrysops dimidiata and *C. silacea* (Figure 3) (family *Tabanidae*) live in the canopy, and are particularly attracted by smoke and blue tissue. They lay eggs on mud or leaves overhanging water, and the larvae develop in detritus, taking a year before they pupate, with probably seven moults. The pupa is partially buried and the adult emerges after 1-3 weeks. Chrysops is a good intermediate host or vector for *Loa loa*, and it is not unusual to find more than one hundred infective larvae in one fly. For vector control, William (1963) used water emulsions containing various concentrations of DDT, dieldrin, aldrin or gamma-BHC, and found that *Tabanus* larvae were more susceptible than *Chrysops* larvae to all the insecticides tested. Dieldrin emulsion can keep breeding sites free of tabanid larvae for at least eight months (Crewe & Williams, 1964), and has been proposed for the control of chrysops larvae. However, vector control is difficult due to the scale and remote location of breeding sites.



Fig. 3. *Chrysop silacea*, vector of *Loa loa*

4. Diagnosis of loiasis

4.1 Clinical diagnosis

Calabar swelling commonly appears on the arm, elbow, face, or chest, and is often accompanied by localized pruritus and discomfort. Another diagnostic sign is ocular passage (Figure 4) of the adult worm (eye worm). These two signs are the most frequent and specific among autochtones and visitors. However, eye worm is more frequent in autochtones than in visitors, while calabar swelling is more common among visitors (82%) (Churchill et al., 1996). Visitors may develop a syndrome of immunological hypersensitiveness (Nutman et al., 1986) characterized by high titers of antifilarial antibodies, elevated IgE levels (Klion et al., 1991), hypereosinophilia, frequent pruritus around the angioedema, and complications such as endomyocardial fibrosis, renal disease, lymphoma (Gerd et al., 1996), and subcutaneous nodules. Calabar swelling and eye worm may appear alone or simultaneously. Retinal hemorrhage can occur in case of high microfilaremia (Toussaint & Danis 1965), especially after treatment with DEC or ivermectin. Examination of the fundus is therefore necessary, even in the absence of antifilarial treatment. Onset of calabar swelling and eye worm may be followed by cardiac (Andi et al., 1981), renal (Pilay et al., 1973; Bariety et al., 1967) or neurological disorders. Non specific symptoms include pruritus, fever, urticaria, rash, myalgia and arthralgia.

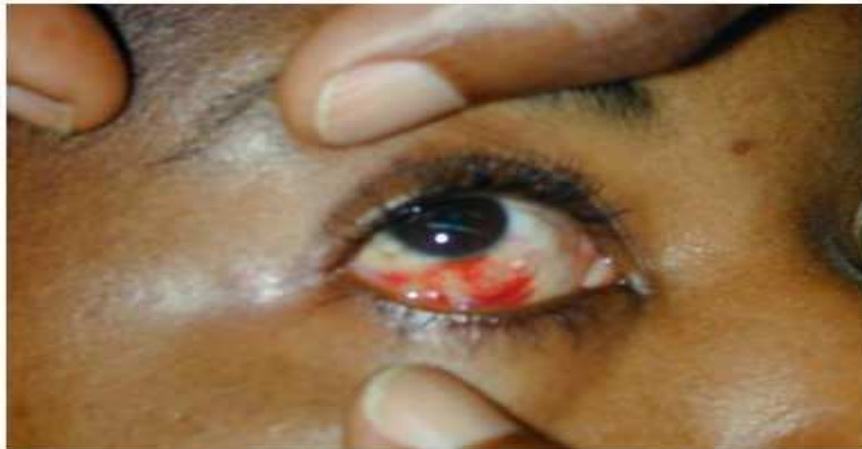

Fig. 4. Ocular passage of *Loa loa* adult worm

4.2 Biological diagnosis

Direct specific diagnosis

Direct specific diagnosis is based on detection of *Loa loa* microfilaria in peripheral blood or of the migrating adult worm. In wet films of blood samples taken around noon, *Loa loa* microfilaria are highly mobile, with a snake-like movement among red blood cells, enveloped in a translucent membrane (sheath). Body size is 231-300 μm by 5-7 μm . A concentration technique on fresh blood can be used: 1 ml of blood is diluted 10X in PBS (Akue et al., 1996), then red cells are lysed with 2% saponin and the solution is centrifuged at 2000 rpm for 10 minutes. The pellet is smeared on a slide and examined under a microscope. Microfilariae appear as described above. Microfilariae can also be stained with Giemsa in a

thick blood film, allowing *Loa loa* to be distinguished from other filariae by their size (253-300 μm long), their unstained sheath, and the presence of several nuclei inside the body, reaching the tail but not the cephalic extremity. Direct examination of cerebrospinal fluid (CSF) after centrifugation may be positive for microfilariae in case of neurological signs. The migrating adult worm is most readily detected during its ocular passage. The adult is 2-7 cm long, the female being longer than the male.

IntechOpen

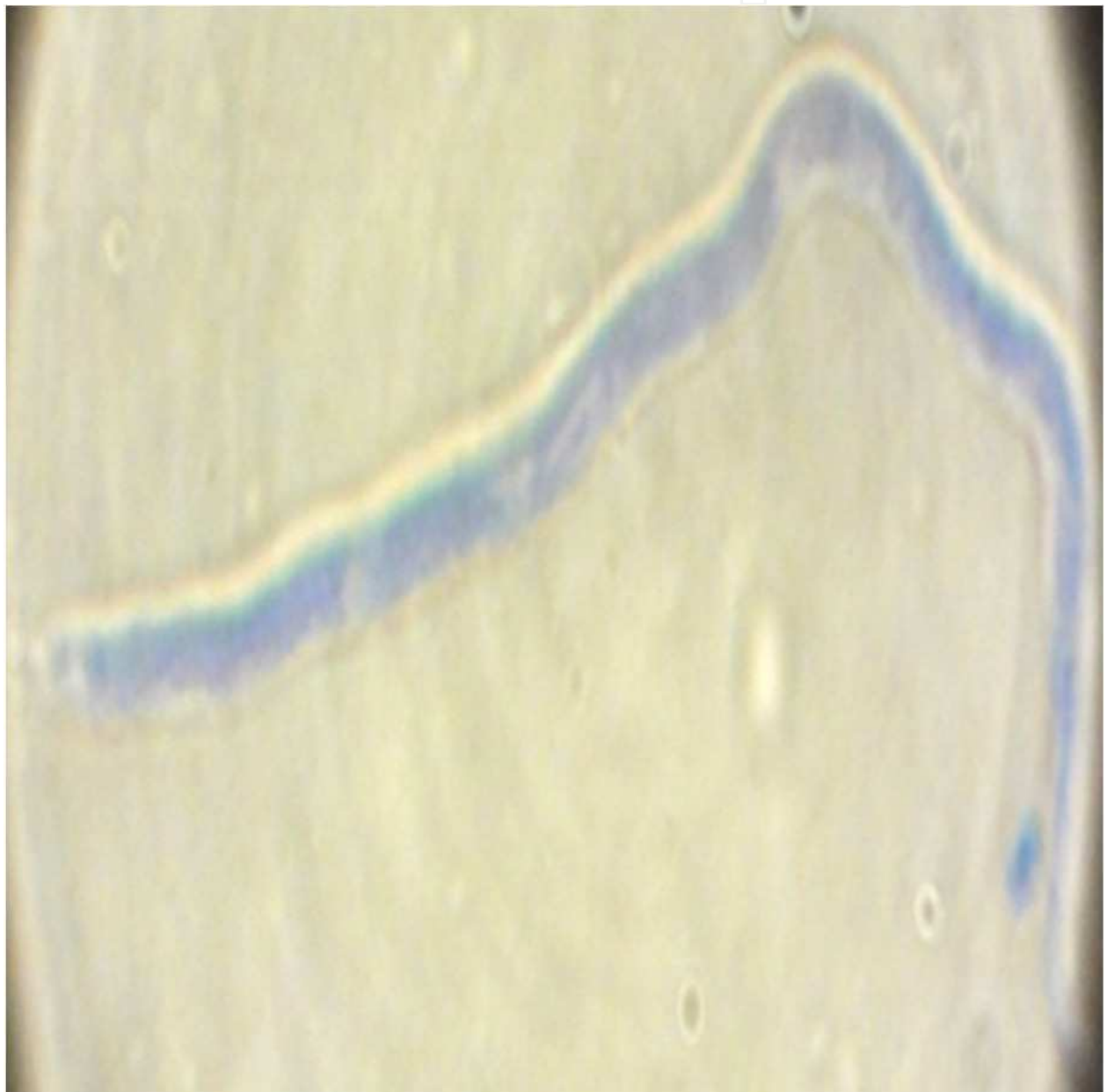

Fig. 5. Stained *Loa loa* microfilaria

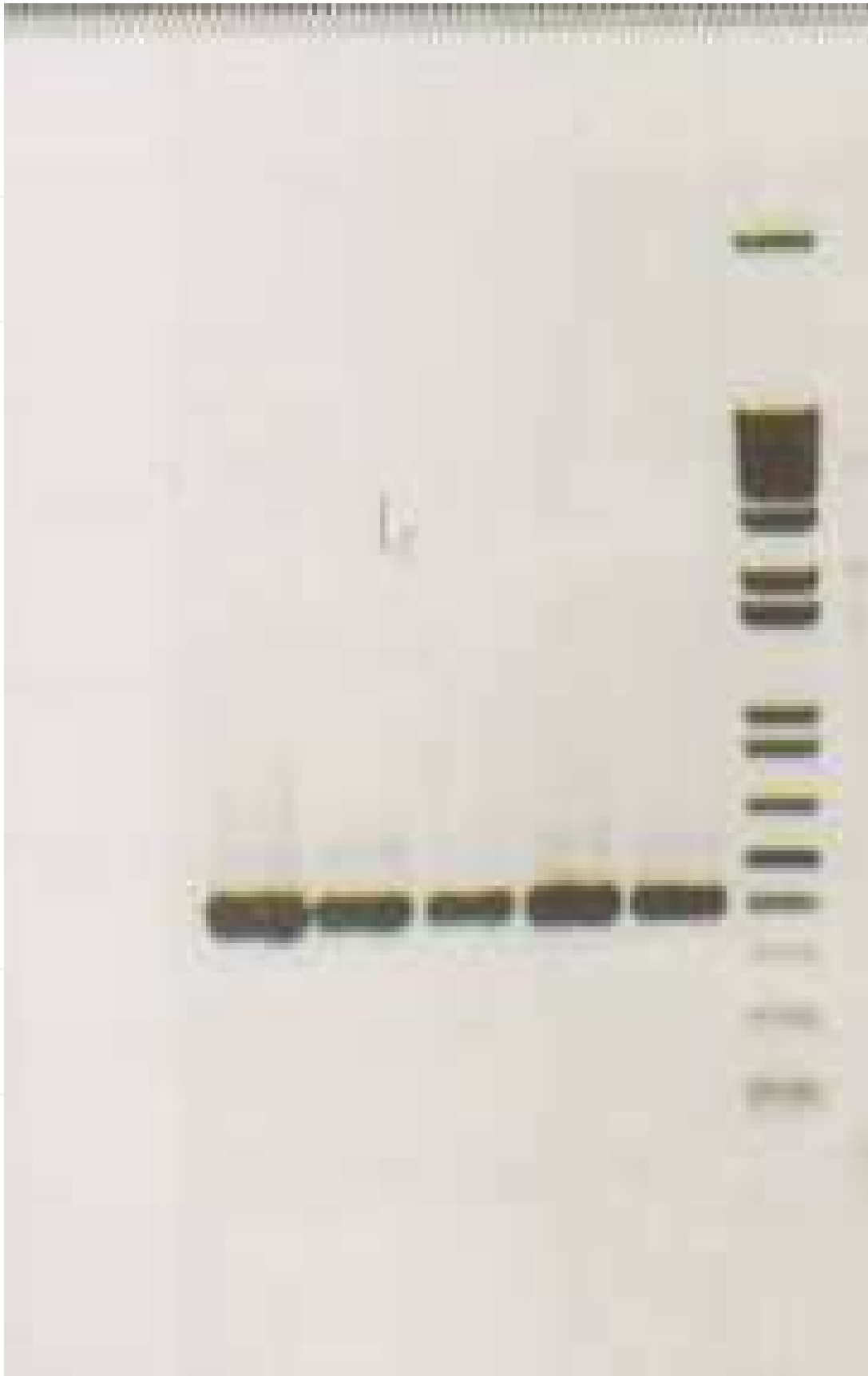

Fig. 6. Amplification of *Loa loa* 15 kDa gene by PCR for diagnosis

Indirect (presumptive) diagnosis

Indirect diagnosis is based on hypereosinophilia (25%) in general among non indigenous population from endemic zone, and elevated total IgE. As most infected people are amicrofilaremic, indirect methods based on antibody or gene detection are valuable. One of the first such methods was the immunofluorescent antibody test (IFAT) using fixed microfilaria. Others include ELISA detection of specific IgG4 against a crude extract of *Loa loa* worm, a method that appears to be specific and sensitive for both microfilaremic and amicrofilaremic forms (Akue et al., 1994). Its sensitivity and specificity (relative to *Mansonnella perstans*) are reported to be better than 90% for parasitologically proven loiasis in a co-endemic area. However, crude extracts are in limited supply. A luciferase immunoprecipitation system (LIPS) based on detection of IgG to *Loa loa* recombinant antigen L1XP-1 has been recently developed and shows high specificity but limited sensitivity. A rapid LIPS format improves the specificity by limiting cross-reactivity with *O. volvulus* (Burbelo et al., 2008). The same L1XP-1 antigen was used to develop an ELISA method for the detection of specific IgG4 antibodies, but sensitivity was poor (56%) (Klion et al., 2003). Molecular diagnosis may consist of detecting the ladder R3 gene (Ajuh et al., 1995) of *Loa loa* in DNA extracted from whole blood (Touré et al., 1997). However, although highly specific, the test is impractical in rural areas and non specialized laboratories. In general, these methods, although specific, are not sensitive enough to detect all cases of loiasis and are not available at many points of care.

5. Treatment and prophylaxis of uncomplicated loiasis

The treatment of loiasis is based on two major microfilaricides, namely ivermectin (Mectizan® or Stromectol®) and diethylcarbamazine (DEC or Notezine®). With ivermectin, a single dose of 200 µg/kg is sufficient. DEC treatment starts with one-quarter of a tablet (one tablet = 100 mg), then the dose is doubled every day until the maximum dose of 400 mg/day is reached. These treatments must be preceded by precise counting of microfilariae in the patient's blood. If the count is higher than 8000 mf/ml, DEC will be administered at a dose of 8 mg/kg for 21 days under hospital supervision. This treatment is usually combined with antihistamine and corticosteroid therapy during the first week. Proposed chemoprophylaxis includes the use of repellents, and weekly intake of one tablet of DEC (100 mg). Plasmapheresis may be envisaged in case of very high microfilaremia (Muylle et al., 1983; Abel et al., 1986).

6. Encephalopathy in loiasis: clinical features

Loiasis encephalitis is usually a consequence of treatment with dimethyl carbamizine citrate (DEC) or ivermectin (Mectizan), although it may also occur spontaneously.

6.1 Encephalopathy following treatment

The symptoms occur gradually, starting 2 days after ivermectin treatment, or after 24-36 hours of DEC treatment. The patient's condition generally becomes serious after 3 to 5 days. The most common manifestations are vertigo, loss of balance, speaking difficulties, arthralgia, abdominal pain, diarrhea, fever, vomiting, diffuse hypertonia, loss of osteotendinous reflexes, no response to pain, conjunctival or retinal hemorrhage, pruritus, neurological disorders with altered consciousness (obnubilation), renal impairment, coma

and death after a few days. Laboratory tests show numerous *Loa loa* microfilaria in peripheral blood, cerebrospinal fluid (CSF) and urine. Loaisis encephalopathy is classified according to the neurological manifestations, their time of onset, and biological findings, in three categories: definite, probable and possible (Scientific working Group on SEA, 2003).

6.1.1 Definite *Loa loa* encephalopathy: microscopic examination of brain tissue obtained by autopsy or needle biopsy is consistent with *Loa loa* encephalopathy (vasculopathy with evidence of *Loa loa* microfilariae), and onset of central nervous system (CNS) disorders within 7 days of treatment with mectizan, progressing to coma without remission.

6.1.2 Probable *Loa loa* encephalopathy: encephalopathy (without seizures, usually febrile) in a previously healthy person with no other cause of encephalopathy, and onset of CNS symptoms and signs within 7 days of treatment with metizan, progressing to coma without remission; and >10 000 mf/ml of peripheral blood pre-treatment, or >1000 mf/ml within 6 months post-treatment, or >2700 mf/ml within 6 months of treatment, and /or *L. loa* microfilariae in CSF.

6.1.3 Possible *L. loa* encephalopathy: encephalopathy (without seizures, usually febrile) in a previously healthy person with no other underlying cause of encephalopathy, and onset of CNS symptoms and signs within 7 days of treatment with mectizan, progressing to coma without remission, and semi-quantitatively or qualitatively positive (+, ++ or +++) for *L. loa* microfilariae in peripheral blood or CSF.

6.2 Spontaneous encephalopathy

Spontaneous cases are rare but may be under-estimated. A number of apparently cases of spontaneous encephalitis have been reported (Bonet ,1943; Gallais et al., 1954; Carayon et al., 1959; Same Ekobo et al., 1981; Tuna Lukiana et al., 2006). In some case described by Kivit (1952), patients might have taken antifilarial drugs. The symptomatology is variable and may start with calabar swelling accompanied by itching, asthenia, facial edema, abdominal pain, diarrhea, violent headache, renal failure, hemiplegia or double hemiplegia, with mental disorders, functional impairment, altered consciousness including coma, usually terminating in sudden death. The process can last between 1 and 3 months, with hyperthermia in some case. The electroencephalogram may be abnormal (Bogaert et al., 1955). Microfilaria will be present in CSF and usually in peripheral blood, with albuminuria, red blood cells and leukocytes in urine (Lukiana et al., 1996).

7. Treatment of loiasis encephalopathy

Treatment of *L. loa* encephalitis is based on nursing, nutritional support and re-hydration. According to Serious Adverse events (SEA) Experts in *Loa loa* endemic areas (Scientific working Group on SAE, 2003) Corticosteroids and antihistamines should be avoided. The reasons for avoidance of corticosteroids are the lack of evidence of efficacy for this condition and potential harmful effect; while the antihistaminic treatment should be avoid because of the lack of efficacy and they sedate patient with a neurologic condition, interfering with diagnosis and neurologic assessment. The protocol suggested here is based on that described by Gardon et al., 1999. It is based on vital monitoring (pulse, arterial pressure, temperature, consciousness (Glasgow score), hydration, complete neurological and clinical examination every hour then every three hours. When the patient is dehydrated and systolic pressure is below 9 cmHg: perfuse 500 ml of Ringer lactate solution over 30 min; if no improvement, continue to perfuse until systolic pressure reaches 10 cmHg and

diuresis 1 ml/kg/hour. Perfuse 2000 ml of 5% glucose (including 6 g of NaCl, 3-4 g of KCl, 2 g of calcium) or mixt sera (with 4 g of KCl and 2 g of calcium) for 24 hours for an adult weighing 60 kg, or 500 ml every 6 hours (28 drops/minute). If dehydration persists, perfuse 1000 ml of these solutions over 8 hours, depending on clinical status. In case of fever, add 1 ml of solution per kilogram for each degree above 37°C. In case of coma, the treatment aim is to avoid bedsores, bronchial accumulation and intercurrent disorders, by mobilizing the patient every three hours and massages to prevent complications of decubitus; urinary probing, mouth care with sodium bicarbonate solution, and eye care with 9% NaCl. Pose of oropharyngeal canicle. If the Glasgow score is less than 10/15, transfer to a specialized intensive care unit. If recovery is slow, use gastric gavage with milk, soja.... Complementary examinations are necessary to rule out any other causes of coma (meningitis, hypo- or hyperglycemia, cerebral malaria, etc.), including thick blood smear (to search for *Loa loa* and malaria); glycemia, glycosuria, proteinuria and lumbar puncture (the liquid should be clear, but *Loa loa* microfilaria should be present between days 3 and 7 in *Loa loa* encephalitis). Removal of eye worm has been reported to cure spontaneous encephalitis (Kenney and Hewitt, 1950).

8. The mechanism of encephalopathy and risk factors in loiasis:

A high density of microfilaria (> 30000 mf/ml) seems to be the most plausible risk factor for *Loa loa* encephalopathy (Figure. 7). In addition, the genetic heterogeneity of this parasite could explain the higher prevalence of encephalopathy in certain regions. However, parasites isolated in parts of Cameroon with a high prevalence of encephalopathy were not found to differ genetically from those found in other regions of Africa (Gabon and Nigeria) (Higazi et al., 2004). It has also been suggested that hybridization between simian and human strains of *Loa loa* may be a cofactor for encephalopathy, but this remains to be demonstrated. Although it is possible to cross human and simian strains of *Loa loa*, animal strains do not develop in humans, as demonstrated by implantation of simian adult parasites or injection of infective larvae (L3) in human volunteers (Duke, 2004; Nutman et al., 1991). Moreover, vectors of simian strains of *C. langi* and *C. centurionis* do not bite humans and tend to be active after dark. In contrast, human strains of *Loa loa* can be transmitted to non human primates, and hybrids of human and simian strains can be produced experimentally. However, the two sets of strains normally develop in different host-parasite systems (Fain, 1988), and such hybrids are unlikely to occur in natural conditions. A genetic predisposition to developing microfilaremia (Garcia et al., 1999) could also favor the onset of encephalitis in some cases. Coinfection by *Loa loa* and other parasites such as *Plasmodium* (Hartgers et al., 2006; Kamgno et al., 2008) bacteria (Bonnet et al., 1943; Cattan et al., 1960) and viruses (Cauchie et al., 1965), might cause lesions through which microfilaria could enter the nervous system and brain. However, it has been reported that treatment of such coinfections has little impact on the outcome of encephalitis (Kamgno et al., 2008). Finally, alcohol consumption has also been forwarded as a possible risk factor (scientific working group, 2003).

The pathophysiologic mechanisms underlying encephalitis in patients with loiasis may involve massive microfilarial death, leading to vascular embolism and inflammation. Interactions with drugs and other substances (alcohol, drugs, dietary components, etc.) may also play a role, through competition for biological carrier molecules. Glycoprotein P, a component of the blood-brain barrier, plays a role in drug entry to the brain. Substance P deficiency could lead to a rise in drug concentrations in the brain, resulting in severe

neurotoxicity. This deficiency could be caused by genetic polymorphism, deficient glycoprotein P production, or glycoprotein P inhibition. Indeed, severe neurological adverse effects of ivermectin are observed in CF-I mice, that are deficient in MDRIA glycoprotein P (Kwei et al., 1999). Several drug carrier molecules such as MDR, MRP, OATP and glycoprotein P have been detected on the apical and basolateral membranes of epithelial cells in cerebral capillary membranes (Cordon Cardo et al., 1989; Huai-Yun et al., 1998; Kusuhara et al., 1998; Gao et al., 1999). Glycoprotein P is the most widely studied of these molecules. The risk of encephalitis could also be influenced by genetic factors. Indeed, dogs homozygous for a 4-bp deletion of the *MDR1* gene (resulting in premature termination of glycoprotein P synthesis) are highly sensitive to ivermectin (Mealy et al., 2001). In addition, CFI mice exhibiting low glycoprotein P production are more sensitive to ivermectin neurotoxicity than their wild-type counterparts (Umberhauer et al., 1997). In addition to the neurotoxicity of ivermectin accumulating in the brain, through a deficiency in glycoprotein P or other carriers, neurotoxicity may result from interactions between drugs competing for the same carrier binding site. Other glycoprotein P substrates may compete with ivermectin, leading to a reduction in ivermectin efflux from the brain. This has been demonstrated in mice treated with both ivermectin and cyclosporine (Marques-Santos et al., 1999). It is important to note that ivermectin and DEC both lead to progressive neurological complications in patients with high microfilaremia and also ocular lesions (retinal or subconjunctival hemorrhage) linked to microemboli created by the parasite. It therefore appears that the etiology of *Loa loa*-associated encephalitis associated with these two drugs is linked to clumping of dead microfilaria in vessels, leading to emboli and local vascular inflammation.

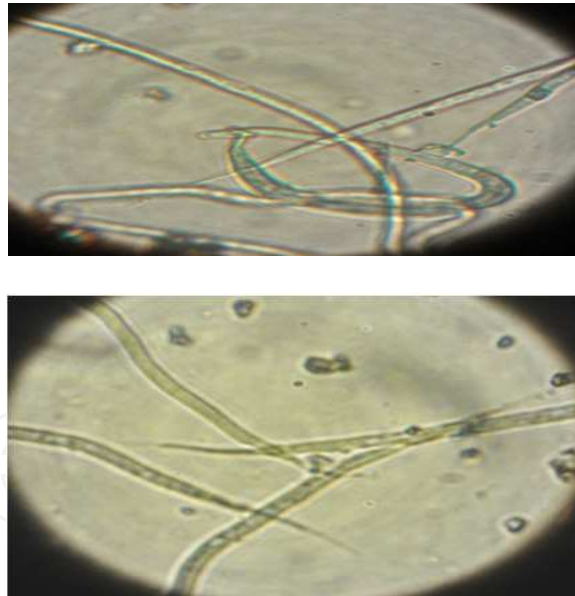
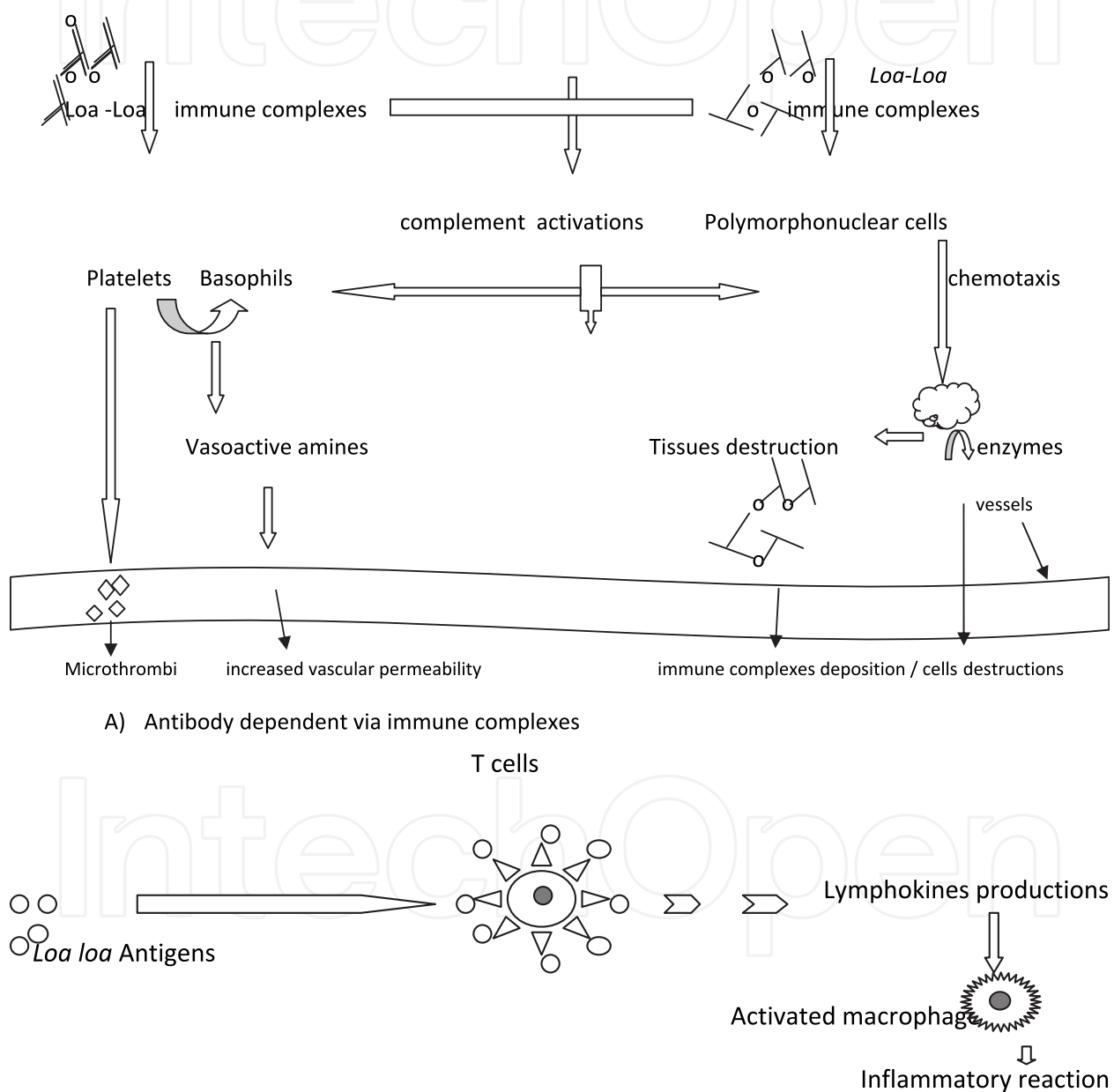


Fig. 7. Two views of *Loa loa* microfilariae in blood of an hypermicrofilaremic individual

It seems that the adult worm and microfilaria are both risk factors for spontaneous encephalitis. Adult worms have been implicated in the neuropsychological complications of loiasis in two European patients (Kenny & Hewitt, 1950). In both cases, extraction of the adult worm led to a clinical improvement and to a decline in eosinophilia from 56-50% to 3%. Location of adult worms in the subarachnoid space at the base of the brain has also been implicated in neuropsychological complications (Bertrand-Fontaine et al., 1948). The abundance of microfilaria is an important risk factor, because of their mobility in small

vessels and capillaries and outside the circulatory apparatus. How exactly microfilaria cross the blood-brain barrier remains to be determined. As stated above, coinfection by other pathogens (such as *Plasmodium*) could weaken this barrier, leading to vascular lesions that allow microfilaria to enter the brain. Head trauma could have a similar effect. In well-documented cases of encephalitis (Bogaert et al., 1955), it has been shown that microfilaria cross the vascular barrier and penetrate into deep tissues, where focal necrosis occurs around dead parasites. These foci are surrounded by inflammation and fibrosis, and giant multinucleated cells arise in the spleen, liver and brain. Aggregates of neurological



B) Cell-dependent via T cells
 Fig. 8. Potential immunological mechanisms for induction of *Loa loa* encephalitis

lymphocytes and histiocytes may form in cardiac tissue, with a few leukocytes close to microfilaria in extracranial organs. There is no evidence of phagocytosis. Alternatively, complications could be due to obstruction caused by microfilarial and to the toxicity of their metabolic products (Weil et al., 1926).

The immune response could also play a role in encephalitis due to *Loa loa*, for example through the formation of circulating immune complexes that deposit in tissues and vessels. This could result in complement activation and influx of polymorphonuclear cells and basophils, followed by the release of vasoactive amines, causing retraction of endothelial cells and increased vascular permeability. Polymorphonuclear cells that fail to phagocytose deposits of immune complexes may degranulate, causing local tissue damage (Fig. 8A). The large amount of antigens associated with abundant microfilariosis may persistently stimulate an inefficient antibody response resembling type III hypersensitivity. Chronic lesions induced by such phenomena could lead to vessel destruction and encephalitis when they occur in the brain, or nephropathies when the kidneys are affected. Cardiac and renal involvement have both been described in loaisis. Alternatively, T lymphocytes sensitized by *Loa loa* antigens (Fig. 8B) could release cytokines, thus attracting activated macrophages. With the persistence of *Loa loa* antigens, activated macrophages could trigger chronic granulomatous reactions resembling type IV hypersensitivity. Such responses are observed in chronic infections such as schistosomiasis (Brian et al., 1983). Granulomas have been observed in the brain of a person infected by *Loa loa*. These observations suggest that type III and IV hypersensitivity reactions could be involved in the development of *Loa loa* encephalopathy. Finally, it is conceivable that spontaneous encephalitis is the end result of a long process involving deposits of immune complexes in several deep organs, the most sensitive being the brain and kidneys. Cofactors (drugs, coinfection, etc.) could accelerate this process.

9. Ongoing and future directions

Administration of filaricidal drugs in massively infected patients often results in encephalitis, in the absence of any other known cause. The mechanism underlying encephalitis in this setting is unclear. Microfilaria have been found in *parasite*-infected animal brains (Hashimoto, 1939, quoted by Janssens, 1952), including those coinfecting by trypanosomes (Peruzzi, 1928). Consequently, the presence of *Loa loa* microfilaria in the brain cannot alone explain the onset of encephalitis. The heterogeneous nature of the associated clinical manifestations poses problems for prevention and timely patient management. Studies based on an experimental model, such as non human primates infected by human isolates, could help to identify predictive markers of *Loa loa* encephalitis and specific clinical complications (Orihel & Ebrehard 1985; Duke, 1960). Indeed, clinical expression of this filariasis is similar in humans and non human primates (Pinder et al., 1994), and hypermicrofilariaemia can be reproduced in non human primates. Despite the existence of potent microfilaricidal drugs (DEC and ivermectin), new macrofilaricides or compounds capable of inducing a gradual decline in microfilaria without triggering encephalitis are needed. Most cases of encephalitis have been reported in Cameroon during mass treatment with ivermectin, but similar cases may go unreported in other endemic regions, especially if they occur in rural settings without adequate medical facilities. Specific studies are needed to evaluate the prevalence and characteristics of *Loa loa* encephalopathy in endemic areas. Studies of polymorphisms of human drug carrier molecules and proinflammatory cytokine synthesis are also necessary. As all current treatments, including albendazole (Blum et al., 2001), can induce encephalitis in

highly microfilaremic patients, the antifilarial activity of African traditional herbal remedies may be of interest. Most of these plants are well accepted and tolerated, and preliminary cytotoxicity results are encouraging (Mengome et al., 2010). There is currently no evidence of the existence of a symbiont in *Loa loa* (McGarry et al., 2003; Buttner et al., 2003), that might warrant concurrent antibiotic therapy for patients with loasis. Because *Loa loa* infection often goes undiagnosed, cases of encephalitis in *Loa loa* endemic areas may be attributed to viruses, bacteria or other parasites. This underdiagnosis is due partly to the lack of a simple, specific and rapid diagnostic test available at points of treatment for use by non specialists. Some candidate antigens have been identified and produced (Azzibrouck et al., 2010). Although spontaneous encephalitis may be caused by the adult worm, life-threatening forms are generally due to massive death of microfilaria. However, in endemic areas, about one-third of infected persons are microfilaremic and only 5% are strongly microfilaremic, the remainder being amicrofilaremic (Van Hoegaerden et al., 1986; Dupont et al., 1988). The fact that these latter persons live permanently in areas of continuous transmission without becoming microfilaremic points to the existence of a natural control mechanism. Further studies of these subjects could help to find ways of clearing microfilaria without triggering encephalitis. Noteworthy immunological differences have been found between microfilaremic and amicrofilaremic subjects. The latter patients exhibit a stronger immune response against *Loa loa* antigens, both qualitatively and quantitatively (Pinder et al., 1988; Pinder et al., 1992; Egwang et al., 1988a; Egwang et al., 1988b; Egwang et al., 1989; Akue et al., 1997; Akue et al., 1998; Baize et al., 1997; Akue & Devaney, 2002). Finally, more work is needed to determine the role of immune complex deposition in the onset of encephalitis in patients with loasis.

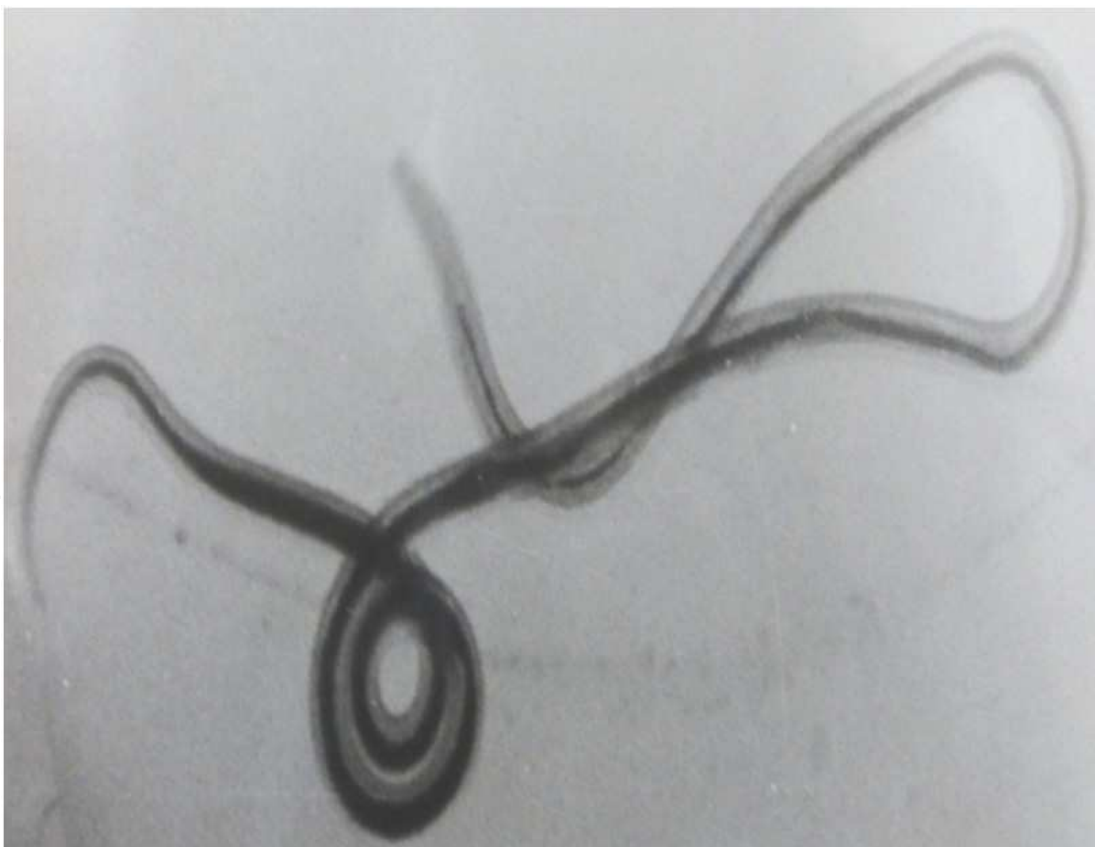


Fig. 9. *Loa loa* adult worm

10. Conclusion

The risk of *Loa loa* encephalitis must be taken in to account when managing patients in and from endemic areas. This severe form can occur spontaneously or be triggered by antifilarial treatment in highly microfilaraemic patients. The underlying mechanism appears to include embolism following massive death of microfilaria, genetic polymorphism of biological drug carriers, and immunological processes. More work is needed to develop a diagnostic test, as well as new drugs and possibly a vaccine. Further characterization of *Loa loa* encephalitis in endemic regions and in animal models is needed to understand the mechanisms underlying the onset and outcome of encephalitis in patients with loiasis.

11. Acknowledgement

The work on filariae *Loa loa* is supported by CIRMF. CIRMF is sponsored by total Gabon, Gabonese state and Ministère de la coopération Française. We thank Ms Line Mengome, Hubert Moukana and Mbou Moutsimbi Roger Antoine for their assistance during the preparation of the manuscript.

12. References

- Abel L, Joly v, Yeni P, Carbon C. (1986). Apheresis in the management of loiasis with high microfilariaemia and renal disease. *British Medical Journal* , Vol. 292, No. 4 January 1986) pp 24, ISSN
- Andi JJ, FF Bishara, OO Soyinka. (1981). Relation of severe eosinophilia and microfilariasis to chronic African endomyocardial fibrosis. *British Heart Journal*, Vol.45, No. 6, (June 1981), pp. 672-680, ISSN:
- Akue Jean Paul, Devaney Eileen. (2002). Transmission Intensity Affects Both Atigen - Specific and Nonspecific T-cell Proliferative Responses in *Loa loa* Infection . *Infection and Immunity*, Vol. 70,pp.1475-1480,ISSN: 0019-9567
- Akue JP, Egwang TG, Devaney E. (1994). High level of parasite specific IgG4 in the absence of microfilaremia in *Loa loa* infection. *Tropical Medicine and Parasitology* ,Vol.45,No. 3, pp. 246-248, ISSN 9177-2392
- Akue Jean Paul, Marcel Hommel, Eileen Devaney. (1997). high levels of Parasite-Specific IgG1 correlate with the amicrofilaraemic State in *Loa loa* Infection. *Journal of Infectious Diseases*, Vol. 175, pp:158-163 ISSN: 0022-1899
- Akue JP Hommel M, Devaney E. (1998). IgG subclass recognition of *Loa loa* antigens and their correlation with clinical status in individuals from Gabon. *Parasite Immunology* , Vol. 20,pp.387-393,ISSN:0141-9838
- Akue JP, Hommel M, Devaney E. (1996). Markers of *Loa loa* infection in permanent residents of a loiasis endemic area of Gabon. *Transactions of the Royal Society of Tropical Medicine and Hygiene*, Vol. 90,pp. 115- 118, ISSN:
- Ajuh PM, Akue JP, Boutin P, Everaere S Egwang TG. (1995). *Loa loa*: structural diversity of a 15kDa repetitive antigen. *Experimental Parasitology* ,Vol. 81, pp.145-153, ISSN:0014-4894
- Baize S, Wahl G, Soboslay P T, Egwang T G, Georges AJ. (1997). T helper responsiveness in human *Loa loa* infection: defective specific proliferation and cytokine production by CD4+ T cells from microfilaraemic subjects compared with amicrofilaraemics. *Clinical and Experimental Immunology*, Vol. 108,pp.272-278,ISSN:00099104


- Barua P., N Barua, NK Hazarka, S Dia. (2005). *Loa loa* in the anterior chamber of the eye: A case report. *Indian journal of Medical Microbiolog*, Vol. 23, pp 59-60,
- Bariety J, Barbier M, Laigre Mc et al. (1967). Proteinurie et loase. Etude histologique, optique et electronique d'une cas. *Bulletin et Memoires de la Societe Médicale des Hopitaux de Paris*, Vol. 118, pp 1015-1025
- Bertrand-Fontaine, Schneider, Wolfrohm, Cognard. (1948). Un cas de filariose cérébrale (double hémiplégie au cours d'une filariose à *F. loa*). *Bulletin et Memoires de la Société Médicale des Hopitaux de Paris*, Vol. 32-33, N° 5, pp 1092-1095
- Bonnet M.(1943). Réflexions sur un cas de méningite aiguë à microfilaria *Loa* . *Médecine Tropicale*, Vol.3, (Mars, 1943),pp. 273-277, ISSN : 0025-682X
- Burbelo P D, Roshan Ramanathan, Klion AD, Iadarola, M J and Nutman TB. (2008). Rapid, novel, specific, high-throughput assay for diagnosis of *Loa loa* infection. *Journal of Clinical Microbiology*, Vol. 46, No 7, (July, 2008), pp.2298-2304, ISSN: 0095-1137, online ISSN: 1098-660X
- Buttner DW, Wanji S, Bazzocchi, Bain and Fischer P. (2003). Obligatory symbiotic *Wolbachia* endobacteria are absent from *Loa loa* . *Filaria Journal*, Vol.2 ,ISSN:1475-2883
- Brian R, Ott, N. Peter Libbey, Richard J. Ryter, Wayne M. Trebbin. (1983). Treatment of Schistosome -Induced Glomerulonephritis A cas report and Review of the Literature. *Archives of Internal Medicine*. Vol. 143 No. 7 (July 1983), pp1477-1479
- Blampain Azzibrouck G Akue JP, Richard Lenoble D. (2010). Production and immunological characterization of a recombinant subunit of *Loa loa* polyprotein antigen. *Parasitology*, Vol.137, pp.1119-1128, ISSN:0031-1820
- Blum M, Wiestner A, Fuhr P and Hatz C. (2001). Encephalopathy following *Loa loa* treatment with albendazole. *Acta Tropica*, Vol.78, pp. 63-65, ISSN: 0001-706X
- Cattan R, Frumusan P, Levy C. (1960). Encephalopathie filarienne. *Bulletin et Mémoires de la Société Médicale des Hopitaux de Paris*, Vol. 7,pp. 808-810
- Cauchie C, Rutsaert J, Thys O, Bonnyns M, Perrier O. (1965). Encephalite à *Loa loa*, traitée par l'association de cortisone et de carbamazine. *Rev Belg Pathol Med Exp* .,Vol. 31, pp. 232-244
- Carbonez G, Van De Sompel W, Zeyen T. (2002). Subconjunctival *Loa loa* Worm : Case Report. *Bulletin Société Belge Ophtalmologie* Vol. 283, pp 45-48
- Carayon A, Collomb H, Sankalé M. (1959). Du polymorphisme des complications neuropsychiques des filarioses (A propos de quatre observations personnelles dont deux inédites). *Bulletin Société Médecine Afrique Noire Langue Française*, Vol.4, pp.299-312, ISSN : 0049-1101
- Cordon - Cardo C, O'Brien JP, Casals D, Ritman Graver L, Beidler JI, Melamed MR and Bertino JR. (1989). Multidrug resistance gene P-glycoprotein is expressed by endothelial cells at blood-brain barrier sites. *Proceedings of the National Academic of Science USA* Vol. 86, pp. 695-698
- Churchill DR, Morris C, Fakoya A, Wright SG, and Davidson RN. (1996). Clinical and laboratory features of patients with loiasis (*Loa loa* filariasis) in The UK. *Journal of infection*, vol.33, No 2, (September, 1996),pp. 103-109, ISSN. 0163-4453
- Crew W, and Williams P. (1964). Studies on the control of the vectors of loiasis in west Africa. Effect of low concentrations of dieldrin in the mud of natural tabanid breeding sites in the rain forest of the Cameroons. *Annals of Tropical Medicine Parasitology*, Vol. 58,pp.343-346, ISSN:0003-4983

- Duke BOL. (2004). Failed attempts at experimental transplantation and transmission of nocturnally-periodic simian *Loa* from monkey to man. *Filaria Journal* , Vol. 3, No.5 (29 July 2004), doi: 10.1186/1475-2883-3-5
- Duke B O L. (1960). Studies on loiasis in monkeys. II-The population dynamics of the microfilariae of *Loa* in experimentally infected drills (*Mandrillus leucophaeus*). *Annals of Tropical Medicine and Parasitology*, Vol. 54, pp.15-31, ISSN: 0003-4983
- Duke B O L. (1957). Experimental Transmission of *Loa loa* from man to monkey. *Nature*, Vol. 179, pp.1357-1358, ISSN: 0028-0836
- Dupont A, Zue-Ndong, J and Pinder M. (1988). Common occurrence of amicrofilaremic *Loa loa* filariasis within the endemic region. *Transactions of the Royal Society of Tropical Medicine and Hygiene*, Vol.8, No. 5, (September, -October 1988), pp.730, ISSN: 0035-9203
- Egwang TG, Akue JP, Dupont A, Pinder M. (1988a). The identification and partial characterization of an immunodominant 29-31kilodalton surface antigen expressed by adult worms of the human filarial *Loa loa*. *Molecular and Biochemical Parasitology*, Vol. 31, pp. 263-272, ISSN: 0166-6851
- Egwang TG, Dupont A, Pinder M. (1989). Differential recognition of *Loa loa* antigens by sera of human subjects from a loiasis endemic zone. *American Journal of Tropical Medicine and Hygiene*, Vol. 41, pp. 664-673, ISSN:0002-9637
- Egwang TG, Dupont A, Akue JP, Pinder M. (1988b). Biochemical and immunochemical characterization of surface and excretory-secretory antigens of *Loa loa* microfilariae. *Molecular and Biochemical Parasitology*, Vol. 31, pp.251-261, ISSN: 0166-6851
- Ekobo Same, Same-Voisin, Eben-Moussi, Ongmagne. (1981). A propos d'un cas de meningo-encephalite filarienne à *Loa loa*. *Rappels des critères de diagnostic de certitude. Afrique Médecine* 20 : 359-361
- Fain A. (1978). Les problèmes actuels de la loase. *Bulletin de l'Organisation Mondiale de la Santé* , vol.56, No. 2,(June ,1978), pp.155-167, ISSN. 0047-96
- Fain A.(1981). Epidemiologie et pathologie de la loase. *Annales de la Société Belge de Médecine Tropicale*, vol.61,pp. 277-285, ISSN. 0365-6527
- Gao B, steiger B, Noe B, Fritschy JM and Meier PJ. (1999). Localisation of the organic anion transporting polypeptide 2(Oatp2) in capillary endothelium and choroids plexus epithelium of rat brain. *Journal of Histochemistry and Cytochemistry*, Vol. 47,pp. 1255-1263, ISSN: 0022-1554
- Garcia A. L Abel, M. Cot, P. Richard, S. Ranque, J. Feingold, F. Demenais, M. Boussinesq and J-P Chippaux. (1999). Genetic epidemiology of host predisposition microfilaremia in human loiasis. *Tropical Medecine and International Health* Vol. 4, No.8, pp.565-574.
- Gallais P, Collomb H, Guedel J. (1954).Les manifestations neuropsychique des filarioses. *Médecine Tropicale* Vol.14, pp.663-677, ISSN: 0025-682X
- Gardon J, Kamgno J, Fobi G, Essiené, A; Ntep M, Gaxotte P, Boussinesq M, Kollo B. (1999). Depistage , identification et prise en charge des effets secondaires graves imputables à la loase et au traitement par ivermectine au cours des campagnes de lutte contre l' onchocercose. *Bulletin de Liaison Documentation de l' OCEAC* Vol. 32, No.1, pp.37-52, ISSN :0225-5352
- Gerd D. Burchard, Ulrike Reimold-Jehle, Volker Burkle, Harald Kretschmer, M Vierbuchen, Paul Racz, and Ying Lu. (1996). Splenectomy for Suspected Malignant Lymphoma in Two Patients with Loiasis. *Clinical Infectious Disease,s* Vol. 23, No. 5 (November 1996), pp 979-982

- Grieve, R.B. Eberhard M.L, Jacobson RH, and T C Orihel. (1985). *Loa loa* antibody responses in experimentally infected baboons and rhesus monkeys. *Tropical Medicine and Parasitology*, Vol. 36,pp.225-229
- Gouteux JP, Noireau F, Staak C. (1989). The host preference of *Chrysops silacea* and *C. dimidiata* (Diptera:Tabanidae) in an endemic area of *Loa loa* in the Congo. *Annals of Tropical Medicine and Parasitology* Vol.83, pp.167-172, ISSN: 0003-4983
- Hartgers Fc and Yazdanbakhsh M. (2006). Co infection of helminthes and malaria: modulation of the immune responses to malaria. *Parasite Immunology*, Vol. 28, No. 10, (October 2006), pp. 497-506
- Hee-Yoon Cho, Yoon-Jung Lee, Sun-Young Shin, Hyun-Ouk Song, Myoung-Hee Ahn, Jae-Sook Ryu. (2008). Subconjunctival *Loa loa* with Calabar Swelling. *Journal of Korean Medical Science*, Vol. 23, No. 4, pp 731-733, doi: 10.3346/Kms.2008.23.4.731
- Higazi Tarig B, Amy D Klion, Michel Boussinesq, and Thomas R Unnasch. (2003). Genetic heterogeneity in *Loa loa* parasites from southern Cameroon: A preliminary study . *Filaria Journal*, Vol. 3 No. 4 (29 June 2004), doi: 10.1186/1475-2883-3-4
- Huai-Yun H,Secret DT, Mark KS, Carney D, Brandquist C, Elmquist WF and Miller DW. (1998). Expression of multidrug resistance-associated protein (MRP) in brain microvessel endothelial cells. *Biochemical and Biophysical Research Communication*, Vol. 243,pp.816-820, ISSN:0006-291X
- Janssens P G.(1952). Remarques au sujet de la possibilité de manifestations nerveuses ou psychiques causes par les filarioses.
- Kamgno J, Michel Boussinesq, François Labrousse, Blaise Nkegoum, Bjorn I. Thylefors, and Charles D. Mackenzie (2008). Case Report : Encephalopathy after Ivermectin Treatment in a patient Infected with *Loa loa* and *Plasmodium* spp . *American Journal of Tropical Medicine and Hygiene*. Vol. 78, No. 4, pp.546-551
- Kenny M and Hewitt R. (1950). Psychoneurotic disturbances in filariasis, and their relief by removal of worms or treatment with hetrazan. *American Journal of Tropical Medicine and Hygiene*, Vol 30, pp 893
- Kenney M, and R Hewitt. (1950). Psychoneurotic disturbances in filariasis, and their relief by removed of adult worms or treatment with hetrazan. *American journal of Tropical Medicine and Hygiene*, Vol. 30, No. 6,pp. 895-899
- Kershaw, W E. (1950). Studies on the epidemiology of filariasis in West Africa, with special reference to British Camerouns and the Niger delta 1. Methods of survey for infections with *Loa loa* and *Acanthocheilonema perstans*. *Annals of Tropical Medicine and Parasitology* , Vol. 44,pp. 361-378, ISSN: 0003-4983
- Kivits M. (1952). Quatre cas d'encéphalite mortelle avec invasion du liquide céphalo-rachidien par *Microfilaria Loa*. *Annales de la Société Belge de Médecine Tropicale*, Vol. 32, pp.235-242, ISSN : 0365-6527
- Kusuhara H, Suzuki H, Naito M, Tsuru T and Sugiyama Y. (1998). Characterization of efflux transport of organic anions in a mouse brain capillary endothelial cell line. *Journal of Pharmacology and Experimental Therapeutic*, Vol. 285, pp.1260-1265, ISSN:0022-3565
- Klion AD, Vijaykumar A, Oei T, Martin B and Nutman TB. (2003). Serum immunoglobulin G4 antibodies to the recombinant antigen L1-SXP-1 are highly specific for *Loa loa* infection. *Journal of Infectious Diseases*, Vol.187, pp.128-133, ISSN:0022-1899
- Klion AD, Moussougbodji A, Sadeler B C, Ottesen E A, Nutman T B. (1991). Loiasis in endemic and non endemic populations: immunologically mediated differences in clinical presentation. *Journal of Infectious Diseases* Vol.163,pp.1318-1325, ISSN: 0022-1899

- Kwei G Y, R F Alvaro, Q Chen, H J Jenkins, C E A C Hop, C A Keohane, V T Ly, J R Strauss, R W Wang, Z Wang, T R Pippert, and D R Umberhauer. (1999). Disposition of ivermectin and cyclosporin A in CF-I mice deficient in MDR1A p-glycoprotein. *Drug Metabolism and Disposition*, Vol. 27 No. 5, pp. 581-587
- Marques-Santos LF, Bernardo RR, de Paula EF and Rumjanek VM. (1999). Cyclosporin A and trifluperazine, two resistance modulating agents, increase ivermectin neurotoxicity in mice. *Pharmacology and Toxicology* Vol. 84, pp. 125-129. ISSN: 0901-9928
- Mealey KL, Bentjen SA and Waiting DK. (2001). Frequency of the mutant MDRI allele associated with ivermectin sensitivity in a sample population of collies from the northwestern United States. *American Journal of Veterinary Research* Vol.16, pp.89-94, ISSN: 0002-9645
- McGarry HF, Pfarr K, Egerton G, Hoerauf A, Jean Paul Akue , Peter Enyong , Samuel Wanji ,Sabine L. Klager , Albert E Bianco, Nick J.Beeching, and Mark Taylor. (2003). Evidence against *Wolbachia* symbiosis in *Loa loa*. *Filaria Journal*.Vol. 2, ISSN:1475-2883, doi:10.1186/1475-2883-2-9
- Mengome Line Edwige, Akue Jean Paul, Souza Alain, Feuya Tchoua Guy Raymond, Nsi Emvo Edouard. (2010). *In vitro* activities of plant extracts on human *Loa loa* isolates and cytotoxicity of eukaryotic cells. *Parasitology Research*, Vol.107,pp.643-650, ISSN: 0031-1820
- Mongin.(1770). Observations sur un ver trouvé dans la conjonctive a Maribou, ile Saint Domingue. *Journal de Medicine Chirurgie Pharmacie etc* (Paris), vol.32, pp.338-339
- Muylle Ludo, Henri Taelman, Robert Moldenhauer, Roger Van Brabant, Marc E Peetermans. (1983). Usefulness of apheresis to extract microfilarias in management of loiasis. *British Medical Journal*, Vol. 287, N° 20, (August 1983), pp 519-520
- Nutman T B. (1991). Experimental Infection of Human with Filariae. *Clinical Infectious Diseases*, Vol. 13, No. 5, pp. 1018-1022, doi: 10.1093/clinids/13.5.1018
- Nutman TB, Miller KD, Mulligan M, Ottesen EA. (1986). *Loa loa* infection in temporary residents of endemic regions; recognition of hyperresponsive syndrome with characteristic clinical manifestations. *Journal of Infectious Diseases*, vol.154, No 1, (July, 1986),pp.10-18, ISSN: 0022-1899
- Orihel TC and Eberhard ML. (1985). *Loa loa*: the development and course of patency in experimentally-infected primates. *Tropical Medicine and Parasitology* ,Vol.36, pp. 215-224, ISSN 0177-2392
- Orihel TC and Lowrie RC. (1975a). *Loa loa*: the development to the infective stage in American deerfly, *Chrysop atlanticus*. *American Journal of Tropical Medicine and Hygiene*, vol. 24, No. 4 (July,1975) pp.610-615, ISSN : 0002-9637
- Orihel TC, and PJ Moore. (1975b). *Loa loa* : Experimental infection in two species of African primates. *American Journal of Tropical Medicine and Hygiene*, Vol. 24, No. 4 (July, 1975), pp. 606-609, ISSN: 0002-9637
- Pal Varhaug. (2009). Subconjunctival *Loa loa*: first case report from Norway. *Acta Ophthalmologica*, pp. 929-930, doi:10.1111/j.1755-3768.2009.01600.X
- Perruzzi, M. (1928). Une filariose cérébrale chez cinq singes atteints de méningo-encéphalite à trypanosomes. *Rapport final de la commission Interne de la S.D.N pour l'étude de la trypanosomiase humaine*. Genève, pp322
- Pilay VKG, Kirch E, Kurtzman NA. (1973). Glomerulopathy associated with filarial loiasis *JAMA* ,Vol. 225, pp. 179

- Pinder M, Leclerc A, Everaere S. (1992). Antibody-dependent cell-mediated immune reactions to *Loa loa* microfilaraemic subjects. *Parasite immunology*, Vol. 14, pp.541-556, ISSN:0141-9838
- Pinder M, Dupont A, Egwang TG. (1988). Identification of a surface antigen on *Loa loa* microfilariae the recognition of which correlates with the amicrofilaraemic state in man. *Journal of Immunology*, Vol.141, pp.2480-2486, ISSN:0022-1767
- Pinder M, Everaere S, Roelants G E. (1994). *Loa loa*: Immunological responses during experimental infections in mandrills (*Mandrillus sphinx*). *Experimental Parasitology*, Vol. 79, pp. 126-136, ISSN: 0014-4894
- Scientific Working Group on serious adverse events in *Loa loa* endemic areas. (2003). Report of a Scientific Working Group on Serious Adverse Events following Mectizan® treatment of onchocerciasis in *Loa loa* endemic areas. *Filaria Journal*, Vol. 2, (October 24, 2003) pp Suppl 1: S2
- Toussain D, Danis P. (1965). Retinopathy in generalized *Loa loa* filariasis. A clinicopathological study. *Archive Ophthalmology*, Vol.74,pp. 470-476, ISSN: 0003-9950
- Touré FS, Egwang TG, wahl G, Millet P, Bain O, and Georges A J. (1997). Species-specific sequence in the repeat 3 region of the gene encoding a putative *Loa loa* allergen: A diagnostic tool for occult loiasis. *American Journal of Tropical Medicine and Hygiene*, Vol.60, pp.50-57, ISSN: 0002-9637
- Tuna Lukiana, Madone Mandina, Nanituma H Situakibanza, Marcel M Mbula, Bompeka F Lepira, Wobin T Odio, Kamgno Joseph and Boussinesq Michel. (2006). A possible case of spontaneous *Loa loa* encephalopathy associated with a glomerulopathy. *Filaria Journal*, Vol. 5, pp. 1-7, ISSN: 1475-2883
- Umbenhauer DR, Lankas GR, Pippers TR, Wise LD, Carwright ME, Hall SJ, and Beare CM. (1997). Identification of the a P-glycoprotein-deficient subpopulation in the CF-I mouse strain using a restriction fragment length polymorphism. *Toxicology and Applied Pharmacology*, Vol. 146, pp. 88-94, ISSN: 0041-008X
- Van Bogaert, L, Dubois, A, Janssens P, Radermecker J, Tverdy G and Wanson M. (1955). Encephalitis in *Loa loa* filariasis. *Journal of Neurology, Neurosurgery and Psychiatry*, Vol. 18, No. 2, (May, 1955), pp. 103-119
- Van Hoegaerden M, Chabaud B, Akue JP, Ivanoff B. (1987). Filariasi due to *Loa loa* and *Mansonella perstans*: distribution in the region of Okondja, Haut Ogooue Province, Gabon with parasitological and serological follow-up over one year. *Transaction of Royal Society of Tropical Medicine and Hygiene*, Vol. 81, pp. 441-446 ISSN:035-9203
- Vijay D Khetan. (2007). Subconjunctival *Loa loa* with calabar swelling. *Indian Journal Ophthalmology*, Vol. 55 No. 2, pp.165-166, doi: 10.4103/0301-4738.30727
- Wail S S, Popow P, and Prjadko E. (1926). Uber die pathologisch-anatomischen Veränderungen bei Filariosis *Virchows Archiv*, Vol. 259, N° 3, (March 1926), pp 642-646
- Williams P (1963) Studies on the control of vectors of loiasis in West Africa. III: comparison of the toxicities of DDT, dieldrin, aldrin and gamma-BHC to late-instan Tabanid larvae. *Annals of Tropical Medicine and Parasitology* Vol. 57, pp.182-190, ISSN:0003-4983



Non-Flavivirus Encephalitis

Edited by Dr. Sergey Tkachev

ISBN 978-953-307-720-8

Hard cover, 360 pages

Publisher InTech

Published online 16, November, 2011

Published in print edition November, 2011

This book covers the different aspects of non-flavivirus encephalitis of different etiology. The first section of the book considers general problems of epidemiology such as study of zoonotic and animal vectors of encephalitis causative agents and methods and approaches for encephalitis zoonoses investigations. The members of different virus species are known to be the causative agents of encephalitis, so the second section of the book is devoted to these viral pathogens, their epidemiology, pathology, diagnostics and molecular mechanisms of encephalitis development by such viruses as HIV/SIV, herpes simplex virus type 1 and equine herpesvirus 9, measles virus, coronaviruses, alphaviruses and rabies virus. The next section of the book concerns the study of protozoan pathogens such as toxoplasma and amoebae. The last section of the book is devoted to multicellular pathogen as human *Filaria Loa Loa* - a filarial worm restricted to the West Africa.

How to reference

In order to correctly reference this scholarly work, feel free to copy and paste the following:

Jean Paul Akue (2011). Encephalitis Due to *Loa loa*, *Non-Flavivirus Encephalitis*, Dr. Sergey Tkachev (Ed.), ISBN: 978-953-307-720-8, InTech, Available from: <http://www.intechopen.com/books/non-flavivirus-encephalitis/encephalitis-due-to-loa-loa>

INTECH
open science | open minds

InTech Europe

University Campus STeP Ri
Slavka Krautzeka 83/A
51000 Rijeka, Croatia
Phone: +385 (51) 770 447
Fax: +385 (51) 686 166
www.intechopen.com

InTech China

Unit 405, Office Block, Hotel Equatorial Shanghai
No.65, Yan An Road (West), Shanghai, 200040, China
中国上海市延安西路65号上海国际贵都大饭店办公楼405单元
Phone: +86-21-62489820
Fax: +86-21-62489821

© 2011 The Author(s). Licensee IntechOpen. This is an open access article distributed under the terms of the [Creative Commons Attribution 3.0 License](#), which permits unrestricted use, distribution, and reproduction in any medium, provided the original work is properly cited.

IntechOpen

IntechOpen