

We are IntechOpen, the world's leading publisher of Open Access books Built by scientists, for scientists

4,800

Open access books available

122,000

International authors and editors

135M

Downloads

Our authors are among the

154

Countries delivered to

TOP 1%

most cited scientists

12.2%

Contributors from top 500 universities



WEB OF SCIENCE™

Selection of our books indexed in the Book Citation Index
in Web of Science™ Core Collection (BKCI)

Interested in publishing with us?
Contact book.department@intechopen.com

Numbers displayed above are based on latest data collected.
For more information visit www.intechopen.com



Current Diagnosis and Management of Angle-Closure Glaucoma

Rafael Castañeda-Díez, Mariana Mayorquín-Ruiz,
Cynthia Esponda-Lamoglia and Oscar Albis-Donado
*Asociación para Evitar la Ceguera en México,
Mexico City
Mexico*

1. Introduction

Angle-closure glaucoma is probably the first entity historically related with the Glaucomas. A large portion of global blindness is caused by angle-closure glaucoma, an estimated 3.9 million blind persons for the year 2010 and a projected 5.3 million for 2020. Well over 20 million people are estimated to become affected in the next ten years, with about 70% of the cases being women. (Quigley & Broman, 2006).

Angle-closure glaucoma represents the second most common type of glaucoma, but its impact is more critical due to a greater likelihood of blindness than in patients with open-angle glaucomas (Johnson & Foster, 2005). An accurate and timely diagnosis is essential, in order to start the appropriate and very specific treatment that may prevent progression to greater, irreversible damage. (Quigley & Broman, 2006).

2. Definition

Angle-closure glaucoma (ACG) includes a number of entities with closed angle, elevated intraocular pressure and optic nerve damage with corresponding visual field defects as common markers. These entities are characterised by iridotrabecular apposition, iridotrabecular synechiae or both.

Depending on gonioscopy, intraocular pressure and optic nerve findings, we can distinguish 3 distinct categories of these entities: primary angle closure suspect, primary angle closure, and angle-closure glaucoma.

In primary angle-closure, the trabecular meshwork can only be seen in 180° or less by gonioscopy, the intraocular pressure remains in normal limits and no structural damage to the optic nerve is present. Eyes with occludable angles have similar gonioscopic findings, intraocular pressure becomes elevated, but still no optic nerve damage is yet present (primary angle closure suspect). Additionally, angle-closure glaucoma eyes have evident signs of optic nerve damage. (European Glaucoma Society [EUGS], 2009).

They can be further classified into primary and secondary forms. Primary angle-closure glaucoma occurs in an anatomically and functionally predisposed eye, it is not a consequence of other ocular or systemic abnormalities.

Secondary forms of angle-closure glaucoma are caused by other ocular or systemic abnormalities, such as uveitis, neovascular glaucoma, Marfan's Syndrome or even some medications, such as Topiramate. (Yanoff & Duker, 2004).

3. Classification

According to clinical presentation angle-closure glaucoma is classically classified in three types: acute, subacute or chronic. (Tasman & Jaeger, 2004).

3.1 Acute angle-closure glaucoma

This is probably the most frequent type of presentation. Acute ACG is estimated to represent 15% to 45% of all angle-closure glaucomas, (Friedman, 2001) and usually presents with a rapid onset of symptoms. The patient complains of ocular pain of varying severity: from deep, localized, ocular pain to a vaguely diffuse headache. The pain can sometimes be ignored by the patient, who becomes worried about other symptoms such as nausea and vomiting (vagal symptoms) often accompanying visual symptoms such as blurred vision, coloured halos around lights and visual loss.

Reduced visual acuity, photophobia, conjunctival and ciliary congestion, corneal oedema and shallow peripheral anterior chamber with cells and flare are frequent findings. Intraocular pressure usually exceeds 40 mmHg. Other signs such as iris atrophy, posterior synechiae, glaukomflecken and structural optic nerve damage (cupping or pallor) are indicative of previous angle-closure glaucoma episodes.

Poor visualization of anterior segment structures during an acute attack is very common, due to corneal oedema. If gonioscopy is feasible, central corneal compression with a four mirror gonioscopy lens (Forbes indentation technique) pushes aqueous to the peripheral anterior chamber, helping differentiate between appositional and synechial angle closure (Figures 4, A and B). These exploration manoeuvres should not be performed in very symptomatic patients, in whom the intraocular pressure is extremely elevated.

Spontaneous resolution of an acute attack, although possible, is very rare; immediate medical and surgical treatment are often necessary.

3.2 Subacute angle-closure glaucoma

Symptoms in subacute ACG may be similar to those in acute angle-closure glaucoma, but of intermittent or lower intensity, and may spontaneously disappear. Symptoms may include: intermittent pain, headache, conjunctival and ciliary congestion, blurred vision and coloured halos around lights. The diagnosis is challenging, because of the spontaneous resolution after a couple of hours, and the possibility of confusion with other ocular or systemic diseases. It is important to be highly suspicious in order to make the correct diagnosis and improve prognosis with timely treatment. (Tasman & Jaeger, 2004). This particular group of patients are frequently confused with normal-tension glaucomas and non-arteritic anterior ischemic optic neuropathy, due to the presence of optic nerve cupping and sectorial pallor in a patient with IO in the normal range during the daytime.

3.3 Chronic angle-closure glaucoma

These type of ACG is characterized by the presence of peripheral anterior synechia (PAS) that close the angle in a variable extension confirmed by gonioscopy and Forbes indentation

technique. Progressive closure of the angle by PAS corresponds well with the increase in IOP. The patient may be asymptomatic until vision loss becomes evident, unless they are lucky enough to be diagnosed on a routine ophthalmologic examination.

4. Angle anatomy

In normal angles the following structures should be seen in gonioscopy: Schwalbe's line, trabecular meshwork, scleral spur and the ciliary body band (Figure 1). Some other findings may be present in normal or abnormal angles.

4.1 Schwalbe's line

Schwalbe's line is the most anterior structure seen on gonioscopy. It is a collagen condensation of Descemet's membrane, which lies between the corneal endothelium and the trabecular meshwork. It is normally seen as a thin, translucent line that protrudes into the anterior chamber. This prominence is quite variable and may have heavy pigmentation over it.

4.2 Trabecular meshwork

Continuing posterior to Schwalbe's line is the trabecular meshwork. It extends to the scleral spur, has a dull gray appearance and is somewhat translucent, except for a tenuous pigmentation of the lower half of the trabecular meshwork. Schlemm's canal can be seen through it sometimes, when blood refluxes during gonioscopy.

4.3 Scleral spur

The next posterior structure is the scleral spur; a short extension of sclera forming the inferior wall of a scleral pocket where Schlemm's canal rests and the longitudinal ciliary muscle normally inserts. It appears white and opaque and is seen as a thin white line below the trabecular meshwork.

4.4 Ciliary body band

The ciliary body band is seen on gonioscopy below the scleral spur as a pale gray to dull brown band. The width of visible ciliary band will depend on the iris insertion, and this fact makes it variable.

4.5 Other findings

4.5.1 Pigmentation

Chronic episodes of angle closure may leave patches of pigment at the level of contact, mostly at the trabecular meshwork, but, depending on the degree of apposition, the pigment clumps may be seen above Schwalbe's line. Heavy, but diffuse, pigmentation of the trabecular meshwork is more typical of pigment dispersion syndrome and pseudoexfoliation. The presence of more diffuse and somewhat grey pigmentation above Schwalbe's line is called Sampaolesi's line, and is highly suggestive of pseudoexfoliation syndrome. It can be concurrent with ACG, especially when the zonules begin to become affected and the lens tends to move forward. Previous trauma is another cause of angle pigmentation, but it is usually accompanied by other more prominent signs, such as pupillary sphincter ruptures, angle recession or a cyclodialysis cleft, but it can also be confirmed by the subtle finding of disinserted or ruptured iris processes.

4.5.2 Iris processes

Normal iris processes are fine strands of iris tissue that can reach the scleral spur, or even the posterior third of the trabecular meshwork. Long iris processes are more anterior and reach anterior portions of the trabecular meshwork. Iris tissue that reaches Schwalbe's line is actually a defining feature of Axenfeld's anomaly.

4.5.3 Blood vessels

Blood vessels may be a normal finding or a sign of disease. Normal blood vessels are usually circumferential and close to the scleral spur, but never above it. Abnormal vessels, on the other hand, are usually due to retinal hypoxia or some forms of uveitis. They cross over the scleral spur and will cover the trabecular meshwork, initially in segments. Neovessels will eventually interfere with aqueous outflow, and cause secondary angle closure due to peripheral anterior synechiae (PAS). Neovessels associated with Fuch's heterochromic iridocyclitis tend to be finer, more fragile, and almost never reach beyond the trabecular meshwork or cause PAS.

5. Angle exploration

Gonioscopy is done to determine the anterior chamber angle characteristics such as the level of iris insertion, the shape of the peripheral iris, the width of the angle, the degree of trabecular pigmentation and areas of PAS or apposition. The anterior chamber angle can be evaluated by different techniques: van Herick technique, direct or indirect gonioscopy. (EUGS, 2009; Friedman & He, 2008).




Fig. 1. Gonioscopy of open angle seen by three-mirrored Goldmann lens. Normal iris processes can be seen reaching the scleral spur.

5.1 Van Herick grading

Van Herick's method is an integral part of eye examination and is used to describe the peripheral anterior chamber depth by using an oblique beam of light at the slit-lamp (Figures 2 and 3). The angle is considered as non-occludable when there is an space between

the endothelium and the anterior iris surface that measures at least one half of the peripheral corneal thickness (Table 1). (EUGS, 2009).

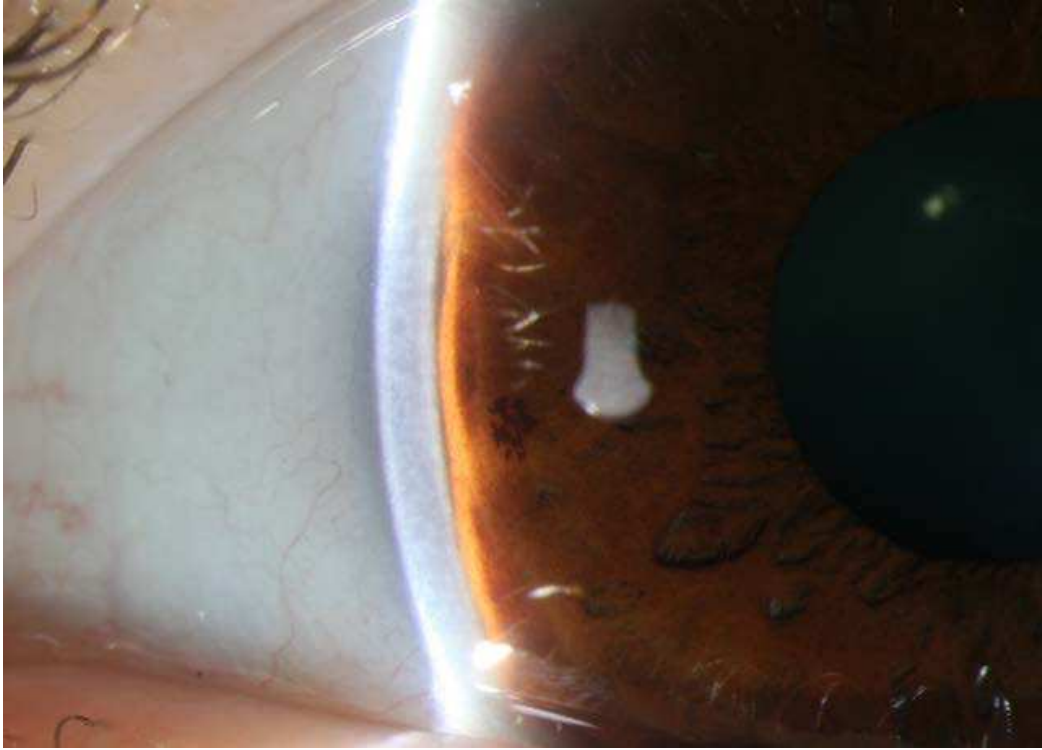


Fig. 2. Van Herick's method: Peripheral anterior chamber depth is evaluated with a narrowed slit-lamp beam angled at 60° , passing through the cornea at the limbus. This photograph shows an example of van Herick's grade I.

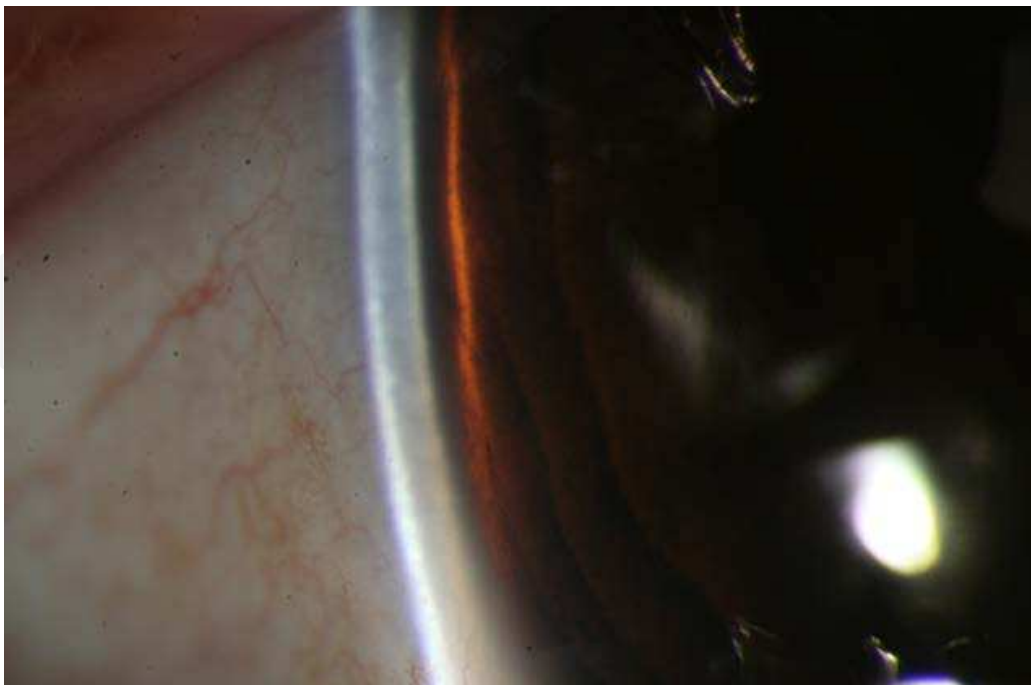


Fig. 3. This photograph shows an example of van Herick's grade III, considered non-occludable.

Van Herick's method is easy to perform and correlates well with gonioscopy, (Wolfs et al., 1997) but cannot replace it. If one uses the van Herick's method like the only form of angle evaluation, important information will be missed about the anatomic appearance of angle structures, such as peripheral iris shape, the relationship between the anterior surface of the lens and the posterior surface of the iris, the number of angle structures that can be seen with or without indentation, the presence or absence of PAS and its extension, the changes in angle opening in dark/light conditions, among others. (Tasman & Jaeger. 2004; EUGS, 2009)

Grade	Characteristics
0	Irido-corneal contact
I	Space between iris and corneal endothelium of $< 1/4$ of corneal thickness
II	When the space is $> 1/4 < 1/2$ of corneal thickness
III	Considered not occludable, with an irido-endothelial distance $> 1/2$ corneal thickness

Table 1. Van Herick's grading system.

5.2 Direct gonioscopy

In direct gonioscopy, light from the anterior chamber passes through the cornea and through a contact goniolens, permitting a direct and adequately magnified view of angle structures, and making simultaneous comparison of both eyes possible. One of the most common goniolenses used for this technique is Koeppel's contact goniolens. (Tasman W, Jaeger E. 2004; EUGS, 2009)

5.3 Indirect gonioscopy

In this technique light from the anterior chamber is reflected on a mirror, allowing an indirect (inverted) view of the anterior chamber angle. Indirect gonioscopy, in our point of view, must be performed in all glaucoma patients and suspects at least once a year. Indirect gonioscopy is the gold standard technique to categorize glaucoma suspects or patients into open or closed-angle categories. There are two main types of lenses used for indirect gonioscopy: three-mirrored Goldmann type lens and the four-mirrored Posner type goniolenses. We consider four-mirrored lenses as ideal to perform excellent gonioscopy. These lenses have a contact surface that is smaller than the cornea, permitting indentation gonioscopy, have no need of lubricating agents, and permit faster viewing of four quadrants without rotating the lens. The three-mirror Goldmann lens facilitates application of laser (e.g. trabeculoplasty), but requires rotating the lens in order to view all quadrants at the same time and cannot be used for performing indentation gonioscopy. Indentation gonioscopy must be done when van Herick's grading is suggestive of angle-closure or the patient is being evaluated as an angle-closure glaucoma suspect. (Figures 4: A and B)

5.4 Common classifications of the anterior chamber angle

Gonioscopy grading systems are useful to record findings using a systematic approach. They help classify patients into open, occludable or closed angle varieties and also help comparing gonioscopic observations through time in the same eye. There are two types of classification: simpler systems that only evaluate the degree of angle opening (Shaffer and

Scheie systems) and more comprehensive ones, such as Spaeth's system, that also evaluates the level of iris insertion, iris configuration and extent of angle opening. The later is a bit more time consuming because of its sophistication, and might be difficult to perform on a demanding setting. (Friedman & He, 2008)




Fig. 4. A.



Fig. 4. B.

Fig. 4. Indentation gonioscopy. Figure 4A: Angle viewed without indentation and figure 4B is the same angle with indentation, making the trabecular meshwork and the scleral spur to become visible. Notice the peripheral convexity of the iris during indentation and the peripheral anterior synechia that remains despite indentation.

For routine clinical evaluation we prefer Shaffer's system, which evaluates the number of visible angle structures while maintaining the surface of the gonioscopic lens perpendicular to the observation axis, taking care to avoid inadvertently changing angle structures during examination. When a four-mirrored lens is used, indentation should be avoided at the beginning, in order to achieve a reliable exploration in primary position. Then dynamic indentation and dark/light gonioscopy should be performed in all cases being evaluated for narrow angles or when van Herick's is suggestive of angle-closure, in order to verify the presence of PAS, or reproducible apposition of iris and trabecular structures (Figure 4).

Grade	Visible Structures	Characteristics
0	No angle structures are visible	Angle closed
1	Schwalbe's line	Angle-closure likely
2	Schwalbe's line and trabecular meshwork	Angle-closure possible
3	Schwalbe's line, trabecular meshwork, and scleral spur	Angle-closure unlikely
4	Schwalbe's line, trabecular meshwork, scleral spur and ciliary body band	Angle-closure unlikely

Table 2. Shaffer's grading system.



Fig. 5. This photograph illustrates the examination of the irido-lenticular channel using a narrow slit-lamp beam through a goniolens. In this example there is no irido-lenticular contact, made evident by a visible space between the light beam on the lens and that on the iris.

Scheie's system is designed to describe closure, also based on the number of visible angle structures, so grade 0 corresponds to a wide open angle and 4 to a closed angle. Spaeth's system uses angle grading in degrees, and also describes iris insertion (or apparent iris insertion) and configuration. All other findings should also be properly described, and their location and extension in clock-hours should also be noted. A drawing of all additional findings can prove to be very useful for long-term follow-up.

Another characteristic of the anterior chamber that can be examined is the degree of irido-lenticular contact. This can be evaluated with a narrow slit-lamp beam that passes through the lens and the pupil margin through a gonioscope (Figure 5).

6. Mechanisms of angle-closure

There are two main mechanisms of primary angle-closure: Pupillary block and iris plateau. It is important to recognize them because pupillary block responds well to a laser peripheral iridotomy and plateau iris responds better to a laser peripheral iridotomy plus argon laser peripheral iridoplasty. (EUGS, 2009; Friedman, 2001; Polikoff et al., 2005; Tasman & Jaeger, 2004)

The predominant mechanism of acute angle-closure is pupillary block and represents around 75% of cases of primary angle-closure. In eyes with shallow anterior chamber, the more anterior position of the lens, in addition to greater anterior surface curvature, increases the area of contact of the posterior iris surface to the lens, facilitating a pressure differential between the anterior and posterior chambers that causes forward bowing of the relaxed, peripheral iris. Silver and Quigley (2004), explored the hypothesis that the differential pressure between the anterior and posterior chambers arises from the dynamics of aqueous flow across the iris-lens channel, (Figure 5) estimating that the magnitude of the posterior to anterior pressure difference was greater with increases in channel length or aqueous inflow and with decreases in channel height or pupil diameter.

In plateau iris, the anterior chamber depth appears to be normal, and the iris plane remains flat, but the angle looks narrow or closed due to the shape of the peripheral iris, which drops abruptly in the far periphery, making a narrow recess over the trabecular meshwork. The mechanisms that increase iridotrabecular contact are: thicker iris, anterior iris insertion and anterior position of the ciliary body. Eyes with plateau iris configuration may have angle-closure when the pupil is mydriatic due to iridotrabecular apposition.

In plateau iris configuration, the associated relative pupillary block can be treated by a laser peripheral iridotomy. The term plateau iris syndrome is used whenever gonioscopy confirms angle-closure in the presence of a patent iridotomy. When performing indentation in these cases the iris can be pushed posteriorly, so it assumes a concave shape that follows the lens curvature, but the peripheral iris remains elevated due to the position of the ciliary processes. Treatment for these cases should be argon or diode laser iridoplasty, or permanent pilocarpine, if laser treatment is not available.

Another mechanism participating in primary angle-closure is lens size and position. Eyes with a thicker and anteriorly positioned lens tend to have shallower anterior chambers. (George et al., 2003). Zonular abnormalities due to congenital abnormalities (e.g. Marfan's syndrome), trauma or even pseudoexfoliation, can also predispose to angle-closure in a previously deep anterior chamber. (Ritch & Schlötzer-Schrehardt, 2001; Dureau, 2008).

Secondary causes of angle-closure, such as phacomorphic, uveitic and neovascular cases, need to be promptly identified in order to establish a specific treatment.

7. Angle-closure glaucoma suspect and risk factors

Early identification of high-risk angle-closure suspects has the potential of delivering a very effective and timely preventive treatment (iridotomy). An angle-closure glaucoma suspect is a patient who has two or more quadrants of iridotrabecular contact in dark-room gonioscopy, normal intraocular pressure, without PAS and no damage to the optic nerve. These patients sometimes have transitory, but recurrent, morning symptoms, namely headache, eye pain, nausea, blurred vision and even halos around lights.

Risks factors for primary angle-closure glaucoma include: demographic, anatomic, genetic and other external factors.

7.1 Demographic risk factors

The prevalence of primary angle-closure glaucoma varies among different populations. It is 0.8% in the general Eskimo population (1.2% in women, and increases to 2.5% beyond 40 years of age, while in a general British population it is as low as 0.09%. Both prevalence and incidence data demonstrate that angle-closure affects East Asian people more frequently than European people. (Bonomi, 2000; George et al., 2003; Nathan et al. 2003; Yip & Foster, 2006; Van Rens et al., 1988).

Women are at greater risk for angle-closure glaucoma. Women have a shallower anterior chamber depth and have shorter axial length than men. A statistical model estimates that 70% of people affected by angle-closure are women. The prevalence of all categories of angle-closure is 2-5 times higher in women than in men. (Quigley & Broman, 2006)

Age is another important risk factor for developing angle-closure glaucoma. According to a population study, age varied between 40 and 60 years in angle-closure diagnosed patients. However there are other studies where a bimodal distribution was noticed, with the first peak of incidence between 53 and 58 years old and a second peak between 63 and 70 years old. Occludable-angle prevalence in Asian populations increases from 54.3 years, but the average for closed-angle glaucoma is 57.95 years; less than 4 years separate occludable angles from definite glaucoma. Older age is also related to a decrease in anterior chamber depth due to the thickening and anterior movement of the lens. (George et al., 2003; Quigley & Broman, 2006)

7.2 Ocular anatomic characteristics

Primary angle-closure glaucoma eyes have an average axial length about 1 mm shorter than normal eyes, making hyperopes more predisposed than emmetropes or myopes to angle-closure glaucoma. Occludable angles, short eyes, shallower anterior chamber depth, thicker lenses, and a closer relationship between the lens and the posterior iris surface in a patient with acute angle-closure glaucoma are other anatomical risk factors that should also be sought in the fellow eye. Cross-sectional and clinical studies consistently find that smaller eyes with these characteristics are at higher risk for angle-closure. (George et al., 2003; Thomas et al., 2004)

The contralateral eye of a patient with an acute angle-closure glaucoma is considered at risk of developing an acute attack, and a prophylactic peripheral iridotomy is recommended. If less than 180° of trabecular meshwork is visible on gonioscopy without indentation or if the angle closes in dark conditions, the risk of angle-closure glaucoma is also higher.

Eyes with occludable angles are characterized by shorter axial lengths, and normal women have shorter eyes than men (22.07 mm vs. 22.58 mm respectively). In a similar way the proportion of lens thickness to axial length is significantly greater in this group of patients.

About 22% of occludable angles progress towards closed-angle glaucoma. (George et al., 2003; Thomas et al., 2004)

Some zonular diseases may be related to secondary angle-closure glaucomas, such as exfoliation syndrome, Marfan's Syndrome and Weil-Marchesani Syndrome, among others. (Ritch & Schlötzer-Schrehardt, 2001; Dureau, 2008)

7.3 Genetic and other external factors

Similarities in ocular biometry in first-degree relatives of angle-closure patients, indicates that angle-closure related anatomical characteristics are at least partially heritable. The risk of developing angle-closure glaucoma was reported to be 3.5 times higher in first degree relatives of affected Inuit patients. In Chinese twins the heritability of anterior chamber depth and drainage angle width could be as high as 70–90%. (He, 2010)

Pupillary dilation can induce angle-closure in very shallow anterior chambers, but in less shallow anterior chambers it can actually open the angle due to posterior displacement of the lens-iris diaphragm. Dilation can also induce pupillary block when the pharmacological effect is ebbing, especially when the pupil is at mid-mydriasis, at a time when the patients are probably going back home from consultation. The risk of an acute angle-closure attack is 3 in 10,000 patients dilated if dapiprazole and pilocarpine are used for reverting mydriasis (Bonomi et al., 2000; Patel et al., 1995; Wolfs et al., 1997). Other systemic medications like antiparkinsonian drugs, tricyclic antidepressants, monoamine oxidase inhibitors, vasoconstrictors and anticholinergics in general may produce an acute angle-closure glaucoma attack in predisposed patients. (Lachkar & Bouassida, 2007). The use of two or more drugs, potentiates the mydriatic effect and the risk of an acute attack in predisposed eyes.

8. Clinical diagnosis

8.1 Prodromal symptoms

These symptoms are caused by the sudden increase and decrease of intraocular pressure, when narrow angles close and reopen. Prodromic symptoms can be precipitated by mydriatic or miotic drops, dim light, prone or semi prone and sympathetic stimulation, so an acute attack is a matter of time.

Patients with prodromal symptoms usually have mild to moderate morning headache, accompanied with nausea, blurred vision and rainbow-hued haloes around bright lights. Symptoms can be recurrent, but short-lived because the pupillary block is broken when light induces myosis on waking-up.

8.2 Acute angle-closure glaucoma

In acute angle-closure glaucoma, acute signs and symptoms become permanent and severe, especially when the rise in intraocular pressure is abrupt.

Angle-closure is always present, the iris is in contact to the peripheral cornea and the trabecular meshwork. During the first few hours of an acute attack synechiae have not yet formed, but the longer the iris is against the angle, the risk for anterior synechia formation is higher and almost certain. Once this happens, the angle will no longer open with an iridectomy and trabecular outflow will be permanently affected.

Blurred vision and haloes (with the blue-green component nearest the light source) around lights are due to aqueous that is forced into the corneal stroma, causing stretching of

collagen lamellae and, eventually, epithelial oedema. The cornea then becomes hazy and bullae may appear (Figure 6).



Fig. 6. Corneal epithelial oedema in a patient with an acute angle-closure glaucoma.

Mid-mydriasis: Paralysis and ischemia of the pupillary sphincter are caused by the increase in intraocular pressure, causing a fixed mid-dilated pupil.

Venous congestion: This occurs when intraocular pressure exceeds that of episcleral veins. Iris blood vessels become dilated and also the veins in the conjunctiva, giving the patient a painful red eye (Figure 7).

Sector atrophy of the iris: The abrupt increase in intraocular pressure causes an interruption of the arterial supply to the iris, resulting in ischemia which causes damage to the iris, leaving behind patches of stromal atrophy (Figure 8).

Aqueous flare: Due to vascular congestion, proteins leak out into the anterior chamber, usually causing mild aqueous flare. Pigment particles can also be seen in the aqueous humor, and can eventually be found deposited on the endothelium and on the iris surface.

Glaukomflecken: Small, multiple, irregular or patchy, gray-dot opacities are areas of ischemia of the anterior capsule epithelium secondary to the increase in intraocular pressure (Figure 9). They can be at different depths from the anterior capsule, indicating a chronology of previous attack. Once an iridotomy is patent and recurrent attacks are prevented, lens growth will bury glaukomflecken spots under newer, transparent layers of lens epithelial cells.

Autonomic Stimulation: nausea and vomiting may accompany the acute angle-closure attack, sometimes complicating the diagnosis. The oculocardiac reflex produces bradycardia and there is often profuse sweating.

Disc and field changes: the optic nerve head can be seen hyperemic due to venous congestion and edematous within 24 hours of the rise in intraocular pressure. Field changes may be difficult to document due to the intense pain, corneal changes and decreased vision during an acute attack, but field constriction has been shown and an important decrease in vision might become permanent if the pressure remains elevated. Visual symptoms and vision abnormalities usually improve, once pressure is normalized.

Synechia: The iris is pushed against the trabecular meshwork during the first hours of an angle-closure attack. An iridotomy will break the attack and separate the iris from the trabecular meshwork. If the attack is not promptly broken, iris congestion and inflammation will promote the formation of peripheral anterior synechia, which might become permanent, and even cause posterior synechia formation. (Tasman & Jaeger, 2004; Yanoff & Duker 2004).

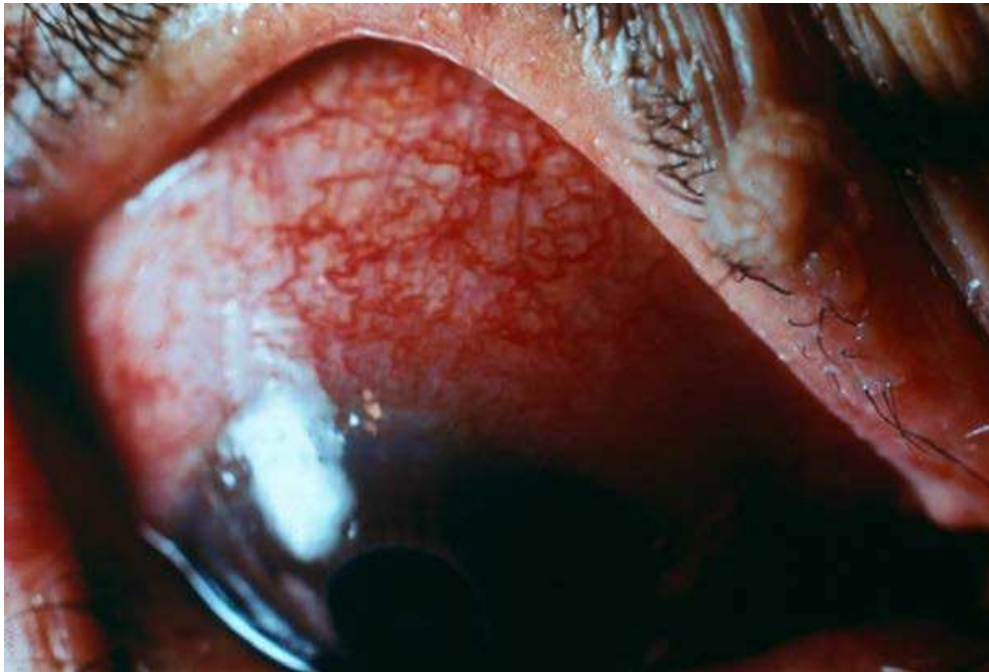


Fig. 7. Ciliary and conjunctival vessel congestion in a patient with an acute attack of angle-closure glaucoma.

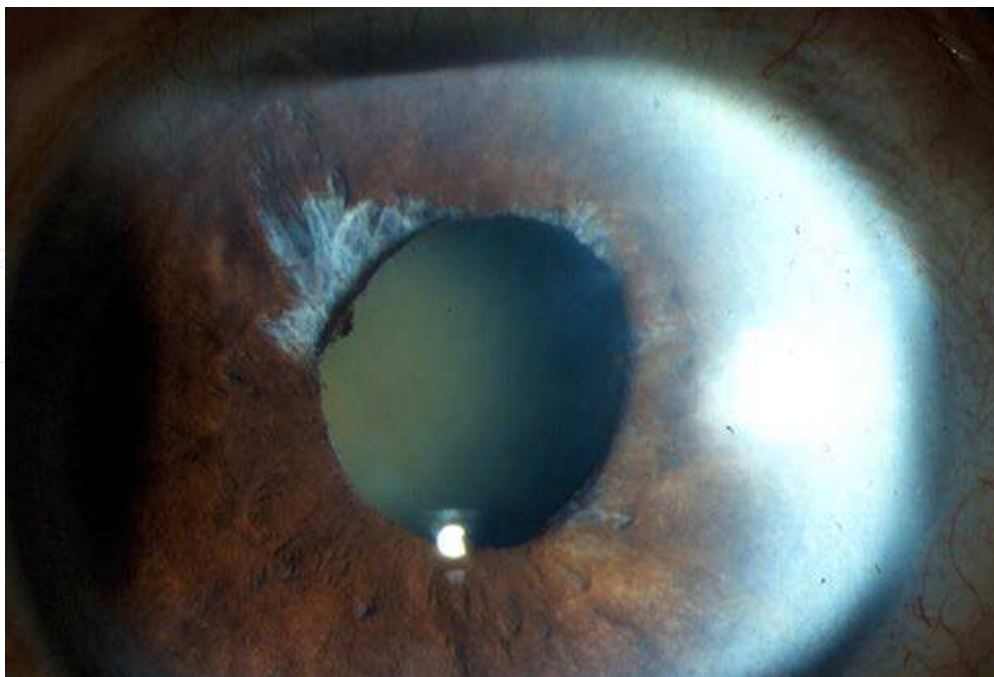


Fig. 8. Sector iris atrophy. The pupil might remain in a fixed position, usually mid-mydriasis.

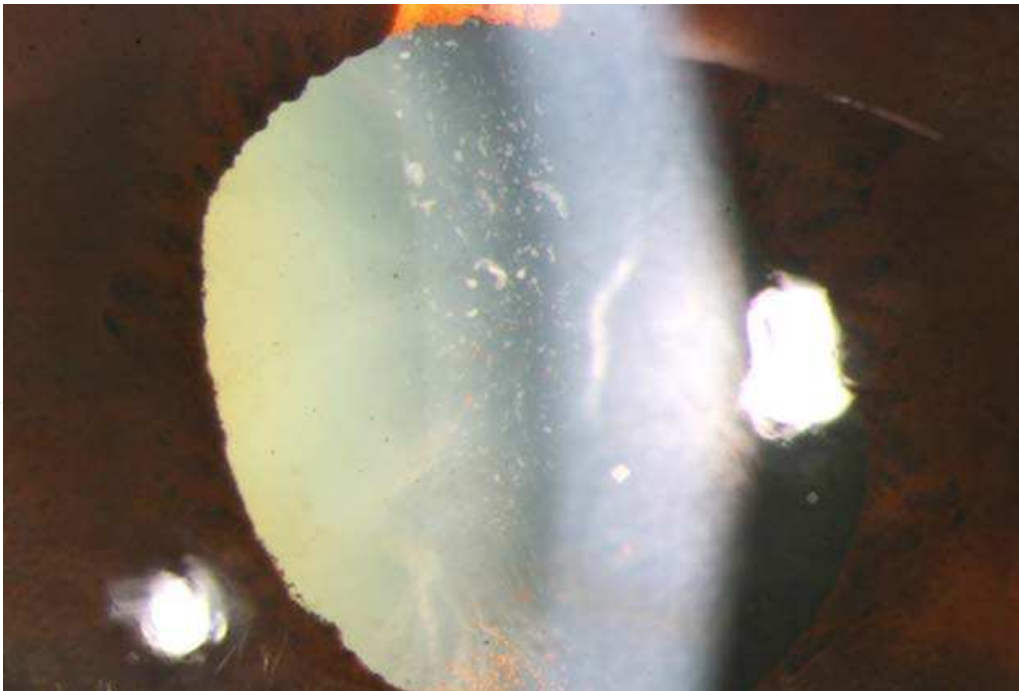


Fig. 9. Multiple gray dot like opacities behind the anterior capsule, glaukomflecken.

8.3 Chronic angle-closure glaucoma

This type of presentation occurs when angle-closure is gradual, or “creeping”. The area of contact between the iris and trabecular meshwork increases silently, and gradually. Intraocular pressure begins to rise and since this rise is gradual, the patient might not have any symptoms.

During an examination, the angle is occluded or occludable in most of its circumference (Figure 8), decreasing outflow facility, elevating IOP and consequently developing cupping, field defects and vision loss.

PAS also form in this type of angle-closure, because the iris is in chronic contact with the trabecular meshwork. Before PAS form, signs of iris and trabecular meshwork contact can be seen, such as clumps of pigment on the trabecular meshwork or areas of contact that can be opened by pressing on the cornea with a gonioscens.

9. Other diagnostic techniques

Modern ultrasound and optical techniques are now available, that contribute to the understanding of anatomical mechanisms participating in angle-closure. Ultrabiomicroscopy is a relatively new technique developed in 1990 by Pavlin and Foster. It is a very high frequency ultrasound (50-80 MHz) that allows visualization of anterior segment structures with a lateral resolution of 50 microns and an axial resolution of 20 microns. It can obtain images of the ciliary body, zonule, lens, iris, angles, anterior chamber and cornea. Higher frequencies (100 MHz) have been developed enabling Schlemm’s canal to be evaluated (iScience surgical). It is possible to analyze the in vivo mechanisms of interaction among anterior segment structures. Ritch et al. have used ultrabiomicroscopy to identify four possible anatomic sites of origin of angle-closure glaucoma: the iris (pupillary block), the ciliary body (plateau iris), the lens (phacomorphic glaucoma) and posterior to the

lens (malignant glaucoma). Ultrabiomicroscopy is also useful in evaluating secondary angle-closure glaucomas, such as those caused by iridociliary cysts, lens subluxation or microspherophakia.

Anterior segment optical coherence tomography is a non-contact, optical instrument that uses a wavelength of 1310 nm and permits acquisition of images of anterior segment with a transverse resolution of 60 microns and an axial resolution of 10-20 microns. It has the disadvantage of light absorption by the sclera and iris, so structures such as the ciliary body and the iris-anterior capsule interaction are not visible. Even though the scleral spur is harder to detect by anterior segment optical coherence tomography in open and closed angles, a quantitative analysis of the angle is still possible. Spectral domain or Fourier optical coherence tomography uses a shorter wavelength of 830 nm, that allows a higher resolution with shorter penetration in tissues. Images of Schwalbe's line, trabecular meshwork and Schlemm's canal can be obtained.

The Pentacam-Sheimpflug camera is a non-contact high resolution imaging system that constructs a 3 dimensional image of anterior segment. Angle analysis is subjective, once the user places markers on the endothelium and the iris plane. Measures in closed angles have a limited correlation with gonioscopy and ultrabiomicroscopy.

10. Treatment

Angle-closure glaucoma treatment options are: medical, laser and surgical (table 3). Treatment in all types of angle-closure glaucoma should be directed towards reduction of intraocular pressure, reopening the angle and preventing and/or stopping optic nerve damage. Indications for each treatment modality vary depending on clinical presentation, but more than one might be needed in an individual patient. In the case of acute angle-closure glaucoma, defining the mechanisms that are participating in the pathogenesis of the event, such as pupillary block, PAS, non-pupillary block or coexistence of all, will lead us to decide initial management.

Medical treatment	Laser treatment	Surgical treatment
Pilocarpine	Argon laser peripheral iridotomy	Anterior chamber paracentesis
Hyperosmotic agents (glycerin and mannitol)	Argon laser iridoplasty	Iridectomy
Carbonic anhydrase inhibitors	Argon laser iridotomy	Lens/cataract extraction
Alpha agonists	Nd:YAG iridotomy	Filtering surgeries
Prostaglandin analogs		Cyclodestructive surgeries
Beta blockers		

Table 3. Treatment options for angle-closure glaucoma.

10.1 Medical treatment

Initial approach of a patient with acute angle-closure glaucoma with pupillary block is medical in most cases. The goals are to lower IOP, alleviate pain, and clear the cornea so an iridotomy can be safely made. It is important to indicate drugs that will lower intraocular pressure in a short period of time.

10.1.1 Hyperosmotic agents

Hyperosmotic agents act by creating an osmotic differential between blood vessels and extravascular tissues, thus they are thought to work by dehydrating the vitreous, reducing its volume, and lowering intraocular pressure. They start acting 10 to 20 minutes after being administered, reach their peak action an hour later. The effect lasts for approximately 5 hours. Some of them are administered orally (glycerol and isosorbide) and others like mannitol need intravenous administration (table 4). It is important to consider that if a patient has nausea and vomit, glycerol and isosorbide might not be tolerated. Side effects of glycerol and isosorbide include: diuresis, nausea, vomit, headache, backache, diarrhoea and fever. Other class side effects (including mannitol) are: cardiovascular overload, intracranial haemorrhage, pulmonary oedema, renal insufficiency and metabolic acidosis. Some systemic conditions like diabetes, arterial hypertension, cardiac and prostatic diseases, should be kept in mind when a patient is receiving hyperosmotic agents, since side effects in those cases can be especially harmful.

Mannitol tends to form fine crystalline precipitates in cold solutions. If this occurs, the solution can be heated and used.

Drug	Dose
Glycerol	1-1.5 g per kg of body weight in a 50% oral solution
Isosorbide	1.5 g per kg of body weight in a 50% oral solution
Mannitol	1-2 g per kg of body weight in a 20% solution. Intravenous rate of 3-5 mL per minute

Table 4. Hyperosmotic agent doses for acute angle-closure glaucoma.

10.1.2 Systemic carbonic anhydrase inhibitors

Carbonic anhydrase is an enzyme that catalyzes the hydration of carbon dioxide and dehydration of carbonic acid. The inhibition of this enzyme (specifically its isoenzyme II form) in the ciliary processes reduces production of aqueous humor. Maximum effect in lowering intraocular pressure occurs 2 hours after the initial dose. Acetazolamide has oral and injectable formulations. Systemic side effects include: paresthesias, taste alterations, loss of appetite, headaches, diarrhoea, nausea, vomit, hypokalemia and metabolic acidosis. Rare side effects include Steven-Johnson syndrome aplastic anemia and urolithiasis. Its use is contraindicated in patients allergic to sulfonamides, patients with sickle cell anemia, those with renal failure and Addison's disease. Patients with diabetes, hepatic insufficiency and chronic obstructive pulmonary disease have to be closely observed when taking acetazolamide, since metabolic acidosis can worsen their systemic conditions.

Drug	Dose
Acetazolamide	125 to 250 mg every 6-8 hrs
Methazolamide	25 to 100 mg every 12 hours

Table 5. Systemic carbonic anhydrase inhibitors dose.

10.1.3 Cholinergic agents

Parasympathomimetic drugs, such as pilocarpine, act in muscarinic receptors (M3) of the iris sphincter muscle, causing it to contract and inducing myosis. It also induces contraction of the longitudinal ciliary muscle, which improves trabecular meshwork opening. Pilocarpine is also used for preparing a patient for laser iris treatment, because it makes the iris thinner and facilitates iridotomies, and improves visualisation of peripheral iris for iridoplasty. Pilocarpine is also useful as a temporary treatment in cases of plateau iris syndrome, previous to iridoplasty.

The intraocular pressure lowering effect starts within 2 hours of instillation. Pilocarpine dosing for acute angle-closure is shown in table 6. The use of pilocarpine carries the risk of side effects that worsen the clinical symptoms in angle-closure glaucoma. Caution must be taken in eyes with very high intraocular pressure, since receptors of the ischemic iris sphincter muscle become unresponsive to the drug, although ciliary muscle contraction causes anterior displacement of the lens diaphragm, shallower anterior chamber depth and worsening of the clinical picture. Pilocarpine must also be avoided in cases where the mechanism of angle-closure is lens induced, as in phacomorphic or pseudoexfoliation glaucomas, and in cases where the mechanism is aqueous misdirection, as in malignant glaucomas. It should not be used for secondary angle-closure glaucomas, such as neovascular glaucoma, because of the risk of hyphema and inflammation. Other side effects are: myopia, aggravation of a pre-existing iritis or ocular inflammation, and an increase on the risk of rhegmatogenous retinal detachment.

Drug	Dose
Pilocarpine (2%, 4%)	1 drop every 5 minutes, 2 doses in the acute phase Repeat dose every 2-3 hours until iridotomy is performed

Table 6. Pilocarpine dose in acute angle-closure glaucoma.

10.1.4 Beta-blockers

They act by reducing the production of aqueous humor. Whether selective or not, beta-blockers lower IOP by about 20-40%. Systemic side effects are: bronchoconstriction, masquerading of signs and symptoms of hypoglycemia, bradycardia, lowering cardiac output, auriculo-ventricular block, systemic hypotension. The usual topical dosing is shown in table 7.

Drug	Dose
Timolol, Carteolol, Levobunolol, Metipranolol and Betaxolol	1 drop every 12 hours

Table 7. Beta blockers dose in acute and chronic angle-closure glaucoma.

10.1.5 Alpha 2 agonists

Adrenergic receptors in the eye are located in the iris and ciliary body muscle and epithelium, retina and retinal pigment epithelium. The intraocular pressure lowering effect of these drugs has a dual mechanism: by lowering aqueous production and by increasing aqueous outflow through the uveoscleral pathway. The mydriatic effect of these drugs and the possibility of worsening angle-closure do not exceed their benefit in lowering intraocular pressure in an acute attack of angle-closure. Epinephrine and dipivalyl epinephrine are contraindicated in cases of occludable angles. Brimonidine and apraclonidine are equally efficient in preventing IOP elevation after anterior segment laser procedures like iridotomy or trabeculoplasty (Chen et al., 2001).

10.1.6 Prostaglandin analogues

Prostaglandin analogues latanoprost, travoprost and bimatoprost, are drugs that enhance the aqueous uveoscleral outflow in healthy and glaucomatous eyes. Its use in the acute attack of angle-closure glaucoma is not recommended but they have been proved effective in lowering the intraocular pressure in eyes with previous patent iridotomy or in chronic angle-closure glaucoma. The presence of PAS or anatomical changes of the ciliary body or the degree of angle narrowing or closure, have not proved to alter the efficacy of prostaglandin analogues for lowering intraocular pressure. (Aung et al., 2005)

10.1.7 Other manoeuvres

Other measures taken in cases of acute angle-closure glaucoma in which weak zonular fibers or a lens mediated elevation of intraocular pressure are participating, include supine positioning of the patient and corneal indentation, that will allow the lens to move backwards improving in some cases the passage of aqueous humor from posterior to the anterior chamber. Topical anti-inflammatory drops are also useful.

Once the acute attack is relieved, and iridotomy is performed, long-term medical treatment can be indicated to avoid further damage of the optic nerve.

10.2 Laser treatment

Once medical therapy has achieved IOP lowering and corneal oedema has improved, a careful examination of the angle and optic nerve is recommended. Iridotomy should be performed in all types of primary angle-closure glaucoma in order to alleviate pupillary block, avoid future acute attacks and lower intraocular pressure (Figure 10). Anterior chamber central depth does not change after an iridotomy, but the periphery does become deeper, the iris assumes a more planar configuration, closer to the anterior lens capsule and equator, and the iridocorneal angle widens, reducing the risk of PAS development. The contralateral eye should also be evaluated and a prophylactic iridotomy considered. (Friedman, 2001; Gazzard et al., 2003; Hsiao et al., 2003; Kashiwagi et al., 2004; Lim et al., 2004)

Japanese patients with iridotomies and a mean follow-up of 5.8 years showed that 50% of eyes with acute attack and 14% of contralateral eyes required topical treatment after iridotomy to control intraocular pressure. About 46% of patients with chronic angle-closure glaucoma required topical treatment after iridotomy for the same purpose. Additionally that study showed that 18% of eyes that had had an acute attack of angle-closure glaucoma and were receiving topical treatment and iridotomy, still required trabeculectomy to adequately control intraocular pressure. (Aung et al., 2001; Hsiao et al., 2003; Kashiwagi et al, 2004).

Iridotomy in plateau iris, produces no significant changes in anterior chamber depth, or the distance between the trabecular meshwork and ciliary body, iris thickness, angle opening distance at 500 microns, or the distance between the trabecular meshwork and iris, but it does decrease iridozonular distance and any relative pupillary block.

In a study of 90 Asian patients who had had an angle-closure attack with a mean 6.3 years of follow up, blindness was present in 17.8% of the affected eyes, 50% had demonstrable optic nerve glaucomatous damage, and visual acuity was also decreased in a large proportion of patients, mainly because of cataract. (Aung et al., 2004)

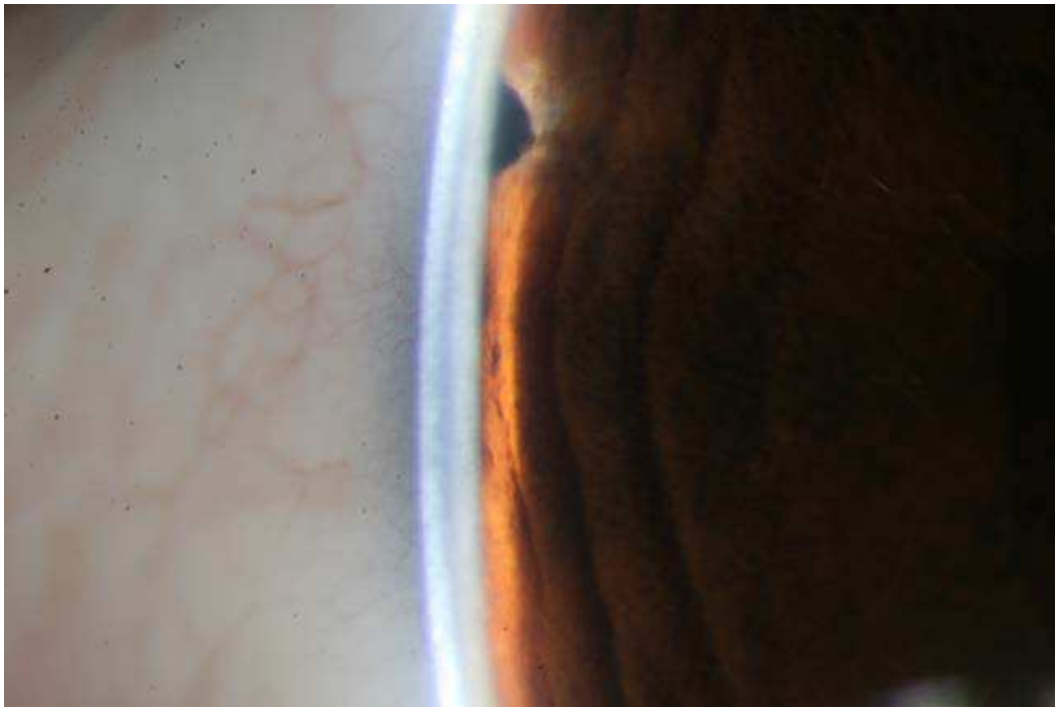

Fig. 10. Peripheral laser iridotomy.

Visual fields performed during an attack reveal generalized or mixed defects that may be reversible. Most defects fall in the 9 to 21 degree area, with a tendency towards superior locations. A decrease in the nerve fiber layer can also be shown and occurs mainly at the poles. Damage tends to be more severe in eyes that initially present with an acute attack of angle-closure glaucoma. (Bonomi et al., 1999; Aung et al., 2004)

Peripheral iridoplasty (Figure 11) has proved to be more effective in lowering IOP than medical therapy during the first two hours of an acute attack, but it can be impossible to achieve if corneal opacity is present. (Lam, Et. al. 2002) It is considered as the first line of treatment for patients with plateau iris syndrome, effectively controlling IOP as long as PAS are not present. Lasers and indications used are described in table 8.

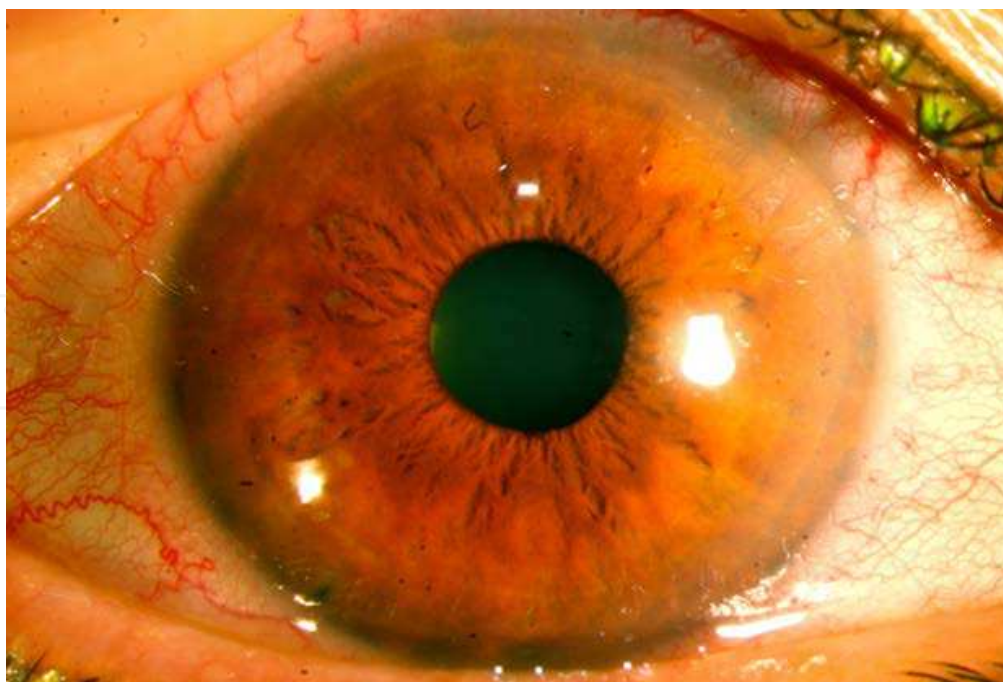


Fig. 11. Peripheral laser iridoplasty, note the greyish burn marks in the periphery, and a patent infero-temporal iridotomy.

Procedure	Laser used	Indications
Iridotomy	Nd:YAG Argon Sequential argon-ND:YAG	Occludable angle Contralateral eye of an acute ACG Narrow or closed angle in more than 180 degrees with optic nerve damage and high IOP Acute ACG
Peripheral Iridoplasty	Argon	Plateau iris In preparation for laser trabeculoplasty After iridotomy if iris apposition is still present Before an iridotomy, in cases of thick, inflamed or rubeotic irises.

Table 8. Laser treatment

Complications that can be found as consequence of laser treatment are: IOP peaks, inflammation, failure of the iridotomy, diplopia, bleeding, cataract, corneal trauma, retinal burns, malignant glaucoma, lens-induced uveitis and rare cases recurrence of herpetic keratouveitis (Hou C et al, 2004), Charles Bonnet syndrome (formed visual hallucinations) (Tan et al, 2004) and choroidal effusion, especially if iridotomy is performed with an argon laser.

10.3 Surgical treatment

Surgery can be indicated for the acute angle-closure glaucoma attack whenever medical and laser treatment have failed to control IOP, when medical treatment is contraindicated and when there is poor cooperation during laser treatment.

In chronic angle-closure glaucomas indications for surgical treatment also include sub-optimal IOP control with medical and laser treatment, and the presence of media opacities such as cataract.

10.3.1 Iridectomy

Although laser iridotomy has proved to have less complications than surgical iridectomy, this procedure is still useful when the cornea is not clear enough for laser treatment and in some cases of secondary angle-closure glaucoma. A surgical iridectomy should also be considered in ocular inflammatory diseases. Spencer et al. (2011) found a low rate of success of laser iridotomy in eyes with uveitis and iris bombe, with a mean time to failure of 85 days.

10.3.2 Other surgical options

Some authors have suggested other therapeutic measures such as paracentesis of the anterior chamber with a 15 ° knife to produce a self-sealing wound, alleviate pain, and clear the cornea for iridotomy. However this technique is invasive and the number of reported patients is small, and should not be considered as a first option in the treatment of this entity (Lam et al. 2002).

Removal of the lens by phacoemulsification has also been advocated as a treatment option. In a prospective study patients in whom IOP had been partially lowered with medical therapy, phacoemulsification with intraocular lens implantation was performed, and IOP had lowered to a mean 12 mmHg by postoperative day seven, however this is a small sample with a short follow-up time. (Ming Zhi et al., 2003).

Initial trabeculectomy has also been studied, reporting a decent success rate, but with a greater incidence of complications due to operating on an inflamed eye. This increased risk of complications should be taken into account when deciding on trabeculectomy. (Aung et al., 2000)

11. References


- Aung, T., Tow, S., Yap, E., Chan, S., & Seah, S. (2000). Trabeculectomy for acute primary angle-closure. *Ophthalmology*, 107, 7 (Jul 2000), pp.1298-302
- Aung, T., Ang, L., Chan, S., & Chew, P. (2001). Acute primary angle-closure: long-term intraocular pressure outcome in asian eyes. *Am J Ophthalmol*, 131, 1 (Jan 2001), pp:7-12
- Aung, T., Chew, P. (2002). Review of recent advancements in the understanding of primary angle-closure glaucoma. *Curr Opin Ophthalmol*, 13, 2, (Apr 2002), pp. 89-93
- Aung, T., Friedman, D., Chew, P., Ang, L., Gazzard, G., Lai, Y., Yip, L., Lai, H., Quigley, H., & Seah, S. (2004). Long-term outcomes in asians after acute primary angle-closure. *Ophthalmology*, 111, 8, (Aug 2004), pp.1464-1469
- Aung, T., Chan, Y., Chew, P., EXACT Study Group. (2005). Degree of Angle-closure and the Intraocular Pressure-Lowering Effect of Latanoprost in Subjects with Chronic Angle-Closure Glaucoma. *Ophthalmology*, 112, 2, (Feb 2005), pp. 267-271
- Badlani, V., Quinones, R., Wilensky, J., Hawkins, A., & Edward, D. (2003). Angle-closure glaucoma in teenagers. *J Glaucoma*, 12, 3, (Jun 2003), pp. 198-203

- Bonomi, L., Marchini, G., Marraffa, M., Bernardi, P., De Franco, I., Perfetti, S., & Varotto, A. (2000). Epidemiology of angle-closure glaucoma: prevalence, clinical types, and association with peripheral anterior chamber depth in the Egna-Neumarket Glaucoma Study. *Ophthalmology*, 107, 5, (May 2000), pp. 998-103
- Chen, T., Ang R., Grosskreutz, C., Pasquale, L., & Fan, J. (2001). Brimonidine 0.2% versus apraclonidine 0.5% for prevention of intraocular pressure elevations after anterior segment laser surgery. *Ophthalmology*, 108, 6, (Jun 2001), pp.1033-8
- Congdon, N., Friedman, D. (2003) Angle-closure glaucoma: impact, etiology, diagnosis, and treatment. *Curr Opin Ophthalmol*, 14, 2, (Apr 2003), pp. 70-73
- Dureau, P. (2008). Pathophysiology of zonular diseases. *Curr Opin Ophthalmol*, 19, 1, (Jan 2008), pp. 27-30
- European Glaucoma Society. (2009). Terminology and Guidelines for Glaucoma. Dogma, ISBN 978-88-87434-28-6, Italy
- Friedman, D. (2001) Who needs an iridotomy?. *Br J Ophthalmol*, 85, 9, (Sep 2001), pp. 1019-21
- Friedman, D., He, M. (2008) Anterior Chamber Angle Assessment Techniques. *Surv Ophthalmol*, 53, 3, (May-Jun 2008), pp. 250-273
- Gaton, D., Mimouni, K., Lusky, M., Ehrlich, R., & Weinberger, D. (2003) Pupillary block following posterior chamber intraocular lens implantation in adults. *Br J Ophthalmol*, 87, 9, (Sep 2003), pp. 1109-11.
- Gazzard, G., Friedman, D., Devereux, J., Chew, P., & Seah, S. (2003) A prospective ultrasound biomicroscopy evaluation of changes in anterior segment morphology after iridotomy in asian eyes. *Ophthalmology*, 110, 3, (Mar 2003), pp.630-638
- George, R., Paul, P., Baskaran, M., Ramesh, S., Raju, P., Arvind, H., McCarty, C., & Vijaya, L. (2003). Ocular biometry in occludable angles and angle-closure glaucoma: a population based survey. *Br J Ophthalmol*, 87, 4, (Apr 2003), pp. 399-402
- Geyer, O., Loewenstein, A., Shalmon, B., Neudorfer, M., & Lazar, M. (1995). The additive miotics effects of dapiprazole and pilocarpine. *Graefes Arch Clin Exp Ophthalmol*, 233, 7, (Jul 1995), pp.448-451.
- Gil-Carrasco, F., Salinas-Van Orman, E. (2002). *Manual de terapéutica médico quirúrgica en glaucoma*. Grupo Ixel Editores, Mexico
- Quigley, H., Broman, A. (2006) The number of people with glaucoma worldwide in 2010 and 2020. *Br J Ophthalmol*, 90, 3, (Mar 2006), pp. 262-267
- He, M. (2010) Angle-Closure Glaucoma: Risk Factors, In: *Pearls of Glaucoma Management*, Giaconi, J., Law, S., & Caprioli, J., pp. 415-419, Springer-Verlag, ISBN 978-3-540-68238-7, Berlin Heidelberg
- Hou, Y., Chen, C., Wang, I., & Hu, F. (2004) Recurrent herpetic keratouveitis following Yag laser peripheral iridotomy. *Cornea*, 23, 6, (Aug 2004), pp. 641-642
- Hsiao, C., Hsu, C., Shen, S., & Chen, H. (2003). Mild-term follow-up of Nd:YAG laser iridotomy in asian eyes. *Ophthalmic Surg Lasers Imaging*, 34, 4, (Jul-Aug 2003), pp. 291-298
- Johnson, G., Foster, P. (2005) Can we prevent angle-closure glaucoma?. *Eye (Lond)*, 19, 10, (Oct 2005), pp.1119-24.
- Kashiwagi, K., Abe, K., & Tsukahara, S. (2004) Quantitative evaluation of anterior segment biometry by peripheral laser iridotomy using newly developed scanning peripheral anterior chamber deep analyzer. *Br J Ophthalmol*, 88, 8, (Aug 2004), pp. 1036-1041

- Khokhar, S., Sethi, H., Sony, P., Sudan, R., & Soni, A. (2002) Pseudophakic pupillary block caused by pupillary capture after phacoemulsification and in the bag Acrysof lens implantation. *J Cataract Refract Surg*, 28, 7, (Jul 2002), pp. 1291-1292
- Kobayashi, H., Hirose, M., & Kobayashi, K. (2000). Ultrasound biomicroscopic analysis of pseudophakic pupillary block glaucoma induced by Soemmering's ring. *Br J Ophthalmol*, 84, 10, (Oct 2000), pp. 1142-1146
- Lachkar, Y., Bouassida, W. (2007). Drug-induced acute angle closure glaucoma. *Curr Opin Ophthalmol*, 18, 2, (Mar 2007), pp. 129-133
- Lai, J., Tham, C., Lam, D. (1999) Limited argon laser peripheral iridoplasty as immediate treatment for an acute attack of primary angle-closure glaucoma: a preliminary study. *Eye (Lond)*, 13, Pt 1, (1999), pp. 26-30
- Lam, D., Lai, J., Tham, C., Chua, J., & Poon, A. (2002) Argon laser peripheral iridoplasty vs conventional systemic medical therapy in treatment of acute primary angle-closure glaucoma: a prospective, randomized, controlled trial. *Ophthalmology*, 109, 9, (Sep 2002), pp. 1591-1596
- Lam, D., Chua, J., Tham, C., & Lai, J. (2002) Efficacy and safety of immediate anterior chamber paracentesis in the treatment of acute angle-closure glaucoma. *Ophthalmology*, 109, 1, (Jan 2002), pp. 64-70
- Lam, D., Tham, C., Lai, J., & Leung, D. (2007). Current approaches to the management of acute primary angle-closure. *Curr Opin Ophthalmol*, 18, 2, (Mar 2007), pp. 146-51
- Lim, L., Aung, T., Husain, R., Wu, Y., Gazzard, G., & Seah, S. (2004) Configuration of the drainage angle in first year after laser peripheral iridotomy. *Ophthalmology*, 111, 8, (Aug 2004), pp. 1470-1474
- Ming, Z., Lim, A., & Yin W. (2003). A pilot study of lens extraction in the management of acute primary angle-closure glaucoma. *Am J Ophthalmol*, 135, 4, (Apr 2003), pp. 534-536
- Nongpiur, M., Ku, J., & Aung, T. (2011). Angle-closure glaucoma: a mechanistic review. *Curr Opin Ophthalmol*, 22, 2, (Mar 2011), pp. 96 - 101
- Patel, K., Javitt, J., Tielsch, J., Street, D., Katz, J., Quigley, H., & Sommer, A. (1995). Incidence of acute angle-closure glaucoma after pharmacologic mydriasis. *Am J Ophthalmol*, 120, 6, (Dec 1995), pp. 709-717
- Polikoff, L., Chanis, R., Toor, A., Ramos-Esteban, J., Fahim, M., Gagliuso, D., & Serle, J. (2005). The effect of laser iridotomy on the anterior segment anatomy of patients with plateau iris configuration. *J Glaucoma*, 14, 2, (Apr 2005), pp. 109-113.
- Quigley, H., Broman, A. (2006). The number of people with glaucoma worldwide in 2010 and 2020. *Br J Ophthalmol*, 90, 3, (Mar 2006), pp. 262-267
- Ritch, R., Schlötzer-Schrehardt, U. (2001). Exfoliation Syndrome. *Surv Ophthalmol*, 45, 4, (Jan-Feb 2001), pp. 265-315
- Sakai, H., Ishikawa, H., Shinzato, M., Nakamura, Y., Sakai, M., & Sawaguchi, S. (2003) Prevalence of ciliochoroidal effusion after prophylactic laser iridotomy. *Am J Ophthalmol*, 136, 3, (Sep 2003), pp. 537-538
- Saw, S., Gazzard, G., & Friedman, D. (2003). Interventions for Angle-Closure Glaucoma. *Ophthalmology*, 110, 10, (Oct 2003), pp. 1869-1879
- Silver, D., Quigley, H. (2004). Aqueous flow through the iris-lens channel: estimates of differential pressure between the anterior and posterior chambers. *J Glaucoma*, 13, 2, (Apr 2004), pp. 100-107

- Spencer, N., Hall, A., & Stawell, R. (2001). Nd:YAG laser iridotomy in uveitic glaucoma. *Clinical & Experimental Ophthalmology*, 29, 4, (Aug 2001), pp. 217-219
- Tan, C., Yong, V., & Au, E. (2004). Onset of Charles Bonnet syndrome (formed visual hallucinations) following bilateral laser peripheral iridotomies. *Eye*, 18, 6, (Jun 2004), pp. 647-649
- Tasman, W., Jaeger, E. (2004). *Duane's Clinical Ophthalmology*. Lippincott-Williams and Wilkins, Philadelphia
- Thomas, R., Sekhar, G., & Kumar, R. (2004). Glaucoma management in developing countries: medical, laser and surgical options for glaucoma management in countries with limited resources. *Curr Opin Ophthalmol*, 15, 2, (Apr 2004), pp. 127-131
- Van Rens, G., Arkell, S., Charlton, W., & Doesburg, W. (1988). Primary angle-closure glaucoma among Alaskan Eskimos. *Doc Ophthalmol*, 70, 2-3, (Oct-Nov 1988), pp. 265-76
- Wolfs, R., Grobbee, D., Hofman, A., & de Jong P. (1997). Risk of acute angle-closure glaucoma after diagnostic mydriasis in nonselected subjects: The Rotterdam Study. *Invest Ophthalmol Vis Sci*, 38, 12, (Nov 1997), pp. 2683-87
- Yanoff, M., Duker, J. (2008). *Ophthalmology*. Mosby-Elsevier, ISBN 978-0-323-04332-8, United Kingdom
- Yip, J., Foster, P. (2006) Ethnic differences in primary angle-closure glaucoma. *Curr Opin Ophthalmol*, 17, 2, (Apr 2006), pp. 175-180

IntechOpen



Glaucoma - Current Clinical and Research Aspects

Edited by Dr. Pinakin Gunvant

ISBN 978-953-307-263-0

Hard cover, 376 pages

Publisher InTech

Published online 09, November, 2011

Published in print edition November, 2011

This book summarizes current literature about research and clinical science in glaucoma and it is a synopsis and translation of the research conducted by individuals who are known in each of their respective areas. The book is divided into two broad sections: basic science and clinical science. The basic science section examines bench- and animal-modeling research in an attempt to understand the pathogenesis of glaucoma. The clinical science section addresses various diagnostic issues and the medical, laser and surgical techniques used in glaucoma management.

How to reference

In order to correctly reference this scholarly work, feel free to copy and paste the following:

Rafael Castañeda-Díez, Mariana Mayorquín-Ruiz, Cynthia Esponda-Lamoglia and Oscar Albis-Donado (2011). Current Diagnosis and Management of Angle-Closure Glaucoma, *Glaucoma - Current Clinical and Research Aspects*, Dr. Pinakin Gunvant (Ed.), ISBN: 978-953-307-263-0, InTech, Available from: <http://www.intechopen.com/books/glaucoma-current-clinical-and-research-aspects/current-diagnosis-and-management-of-angle-closure-glaucoma>

INTECH

open science | open minds

InTech Europe

University Campus STeP Ri
Slavka Krautzeka 83/A
51000 Rijeka, Croatia
Phone: +385 (51) 770 447
Fax: +385 (51) 686 166
www.intechopen.com

InTech China

Unit 405, Office Block, Hotel Equatorial Shanghai
No.65, Yan An Road (West), Shanghai, 200040, China
中国上海市延安西路65号上海国际贵都大饭店办公楼405单元
Phone: +86-21-62489820
Fax: +86-21-62489821

© 2011 The Author(s). Licensee IntechOpen. This is an open access article distributed under the terms of the [Creative Commons Attribution 3.0 License](#), which permits unrestricted use, distribution, and reproduction in any medium, provided the original work is properly cited.

IntechOpen

IntechOpen