

We are IntechOpen, the world's leading publisher of Open Access books Built by scientists, for scientists

4,800

Open access books available

122,000

International authors and editors

135M

Downloads

Our authors are among the

154

Countries delivered to

TOP 1%

most cited scientists

12.2%

Contributors from top 500 universities



WEB OF SCIENCE™

Selection of our books indexed in the Book Citation Index
in Web of Science™ Core Collection (BKCI)

Interested in publishing with us?
Contact book.department@intechopen.com

Numbers displayed above are based on latest data collected.
For more information visit www.intechopen.com



Laparoscopic Surgery for Severe Ulcerative Colitis

Kazuhiro Watanabe, Hitoshi Ogawa, Chikashi Shibata, Koh Miura,
Takeshi Naitoh, Masayuki Kakyou, Takanori Morikawa, Sho Haneda,
Naoki Tanaka, Katsuyoshi Kudo, Shinobu Ohnuma,
Hiroyuki Sasaki and Iwao Sasaki
*Department of Surgery, Tohoku University Graduate School of Medicine
Japan*

1. Introduction

Ulcerative colitis is occasionally exacerbated by fulminant manifestation of colitis. Severe ulcerative colitis is usually defined based on Trulove and Witts' criteria (Table 1) (Truelove & Witts, 1955). The incidence of severe colitis in ulcerative colitis is 5 to 15 percent (Chen et al., 1998). If the patient is not improving despite intensive medical therapy, emergency colectomy is mandatory. In such a case, the patient is often malnourished and anemic, and has received high dose of steroids; therefore, the usual option in patients with severe ulcerative colitis is subtotal colectomy and ileostomy with preservation of the rectum (Gurland & Wexner, 2002). Restorative proctectomy can be done at a later time after the patient has recovered fully and steroids have been withdrawn (Fig. 1).

(1) >6 stools/day
(2) Bloody diarrhea
(3) Fever $\geq 37.5^{\circ}\text{C}$
(4) Heart rate ≥ 90 / min
(5) Hemoglobin ≤ 10 g/dl
(6) Erythrocyte sedimentation rate ≥ 30 mm/hr

Table 1. Definition of severe ulcerative colitis based on Trulove and Witts' criteria (Truelove & Witts, 1955). When criteria (1) and (2) are applied, either criterion (3) or (4) is applied, and four of the six criteria are applied, the ulcerative colitis is diagnosed as severe

The earliest reports of the laparoscopic approach to ulcerative colitis in the elective setting are from the early 1990s (Peters, 1992; Wexner et al., 1992). These first results did not seem very promising, the laparoscopic technique appeared too difficult to apply, too time-consuming, and comorbidity was high. The authors discouraged the use of laparoscopic approach for patients requiring total colectomy. However, with advances in technology and

experience of laparoscopic surgery, more favourable results have been stated (Marcello et al., 2000; Brown et al., 2001; Hamel et al., 2001; Hashimoto et al., 2001; Seshadri et al., 2001; Ky et al., 2002; Gill et al., 2004; Kienle et al., 2005; Larson et al., 2005). These reports have shown the advantages of laparoscopic total colectomy such as reduced postoperative pain, earlier return of intestinal function, decreased length of hospital stay, and improved cosmesis (Table 2). On the basis of these results, recent studies have evaluated the feasibility and safety of minimally invasive surgery for selected patients with severe ulcerative colitis. Minimally invasive surgery techniques include laparoscopic-assisted colectomy and hand-assisted laparoscopic surgery. In this article, an overview of current status of minimally invasive surgery to severe ulcerative colitis is provided.

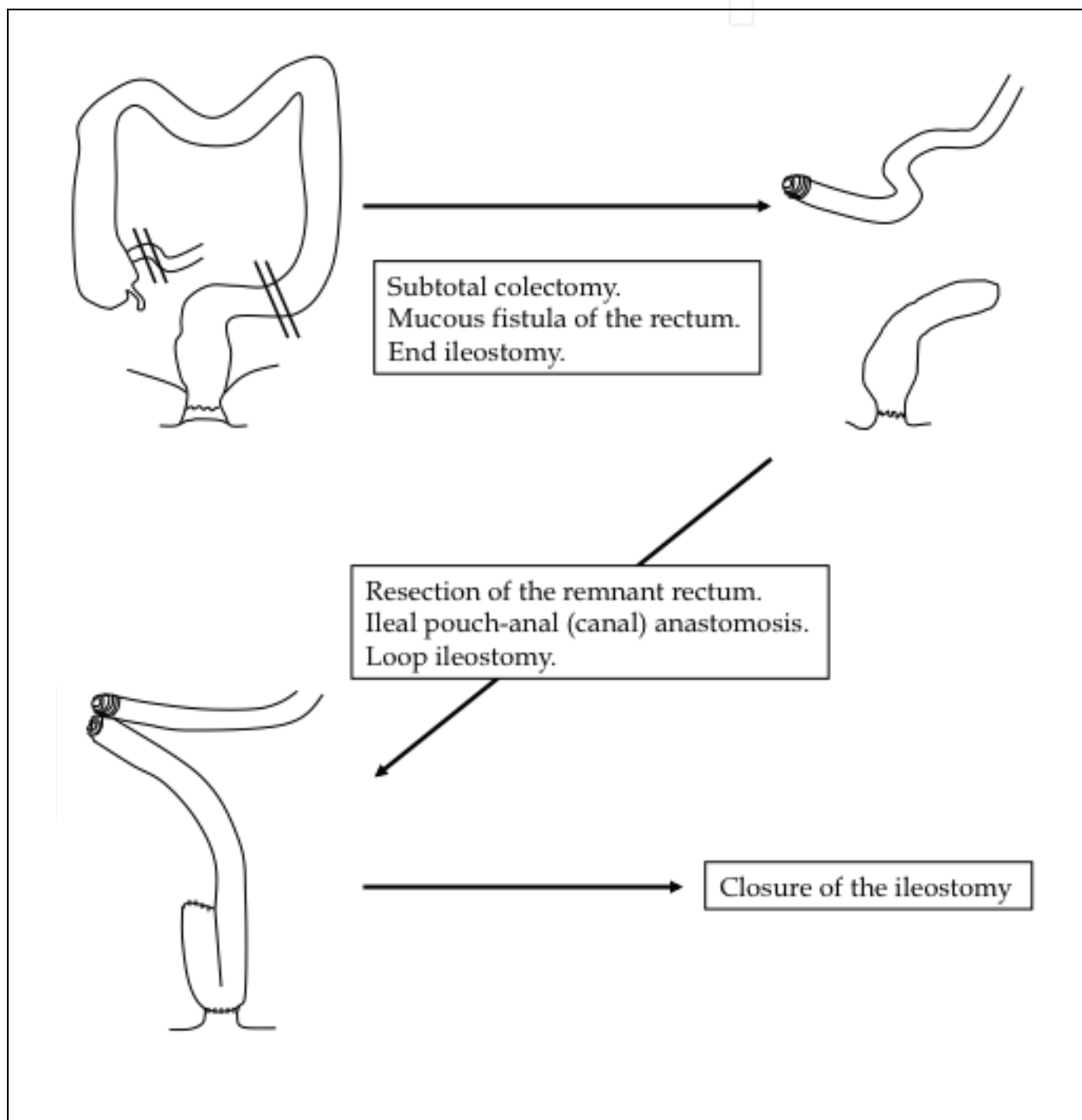


Fig. 1. Three-stage restorative proctocolectomy for severe ulcerative colitis

Author (year)	Number of patients		Operative time (min)			Conversion (%)
	Lap	Open	Lap	Open	<i>P</i> -value	Lap
Marcello (2000)	20 (UC;13 FAP;7)	20 (UC;13 FAP;7)	330	225	<0.001	0
Hashimoto (2001)	11 (UC;6 FAP;5)	13 (UC;6 FAP;7)	483	402	<0.05	0
Gill (2004)	14 (UC;13 FAP;1)	-	260	-	-	7
Kienle (2005)	50 (UC;23 FAP;27)	-	320	-	-	8
Larson (2005)	33 (UC;31 FAP;2)	33 (UC;31 FAP;2)	-	-	-	-

UC: ulcerative colitis, FAP: familial adenomatous polyposis

Table 2. Perioperative data from clinical trials treating laparoscopic-assisted restorative proctocolectomy and ileo-anal anastomosis in elective setting

Author	Hospital stay (days)			Morbidity (%)		
	Lap	Open	<i>P</i> -value	Lap	Open	<i>P</i> -value
Marcello	7	8	0.02	20	25	NS
Hashimoto	24.1	31.3	<0.05	55	38	0.453
Gill	7	-	-	29	-	-
Kienle	12	-	-	30	-	-
Larson	-	-	-	6	12	0.39

Table 2 (continued). Perioperative data from clinical trials treating laparoscopic-assisted restorative proctocolectomy and ileo-anal anastomosis in elective setting

Author	Conclusion
Marcello	Technically feasible and safe. Shorter hospital stay. Quicker return of bowel function. Complication rates were similar to open surgery.
Hashimoto	Better cosmetic results. Reduce the degree of postoperative pain. Shorter hospital stay.
Gill	Technically feasible. Operative time was acceptable.
Kienle	Technically feasible. LAP may reduce the need for perioperative blood transfusion.
Larson	The function and quality of life outcomes seemed to be equivalent to open surgery.

Table 2 (continued). Perioperative data from clinical trials treating laparoscopic-assisted restorative proctocolectomy and ileo-anal anastomosis in elective setting

2. Indication for minimally invasive surgery in severe ulcerative colitis

Patients are usually hospitalized and received intensive medical therapy when their severe colitis is diagnosed. The mainstay of treatment for severe ulcerative colitis is Truelove's intensive intravenous steroid regimen (Truelove & Jewell 1974). Immunosuppressive therapy, cytapheresis therapy, and/or steroid pulse therapy are considered as alternative treatment options (Lichtiger et al., 1994; Sawada et al., 1995; Sood et al., 2002). Total parenteral nutrition, albumin and blood transfusion, and/or antibiotic therapy are considered as supportive therapies. Surgery is indicated when the patients are unresponsive to medical therapy, or when massive hemorrhage, toxic megacolon, or perforation occurs. Patients with severe ulcerative colitis are often malnourished and anemic, and has received high dose of steroids, which increase the likelihood of postoperative complications.

Minimally invasive surgery for severe ulcerative colitis is technically difficult because of active inflammation and induration of the mesentery, fragile intestinal tissue, abscesses between intestinal loops, and dense adhesions. To date, there is no randomized controlled trial assessing minimally invasive surgery for severe ulcerative colitis. In most retrospective studies, the patients with complications such as toxic megacolon, intestinal perforation, peritonitis, or shock stage were excluded from the indication for minimally invasive surgery (Table 3).

(1) Toxic megacolon
(2) Intestinal perforation
(3) Peritonitis
(4) Shock status

Table 3. Exclusion criteria for minimally invasive surgery in severe ulcerative colitis

3. Laparoscopic-assisted subtotal colectomy for severe ulcerative colitis

Several recent studies have reported the outcome of laparoscopic-assisted subtotal colectomy in selected patients with severe ulcerative colitis (Table 4). In most of these

studies, patients with complications such as toxic megacolon, intestinal perforation, peritonitis, or shock status were excluded from the indication for minimally invasive surgery.

Author (year)	Number of patients		Operative time (min)			Conversion (%)
	Lap	Open	Lap	Open	P-value	Lap
Telem (2010)	29	61	216	170	<0.01	7
Maggiore (2010)	35 (UC;27 CD;8)	-	252	-	-	6
Fowkes (2008)	32	-	135	-	-	3
Maeceau (2007)	40 (UC;26CD;13 IC;1)	48 (UC;14 CD;29 IC;5)	253	231	NS	5
Bell (2002)	18	6	220 ~ 360	-	-	0
Dunker (2000)	10 (UC;8 CD;2)	22 (UC;27 CD;5)	271	150	<0.001	0

UC: ulcerative colitis, FAP: familial adenomatous polyposis

Table 4. Perioperative data from clinical trials treating laparoscopic-assisted subtotal colectomy for severe ulcerative colitis

Telem *et al* (Telem *et al.*, 2010) from the Mount Sinai Medical Center, New York City evaluated laparoscopic-assisted subtotal colectomy ($n=29$) versus open subtotal colectomy ($n=61$) in patients with ulcerative colitis requiring urgent or emergent operative intervention. Two (7%) patients in the laparoscopic group required conversion to open surgery. The mean operative time was significantly longer in the laparoscopic group (216.4 vs. 169.9 min, $P<0.01$). Intraoperative blood loss was significantly lower in the laparoscopic group (130.4 vs. 201.4 ml, $p<0.05$). The mean hospital stay was shorter in laparoscopic group (4.53 vs. 6 days, $p<0.001$). The rate of wound complication was significantly lower in laparoscopic group (0 vs. 21 percent, $p<0.01$).

Maggiore *et al* (Maggiore *et al.*, 2010) from Beaujon Hospital, France evaluated the outcome of laparoscopic-assisted subtotal colectomy with double end ileo-sigmoidostomy in patients with acute or severe colitis. The medical records of 35 patients (Ulcerative colitis, $n=27$; Crohn's disease, $n=8$) were reviewed. Two (6%) patients required conversion to open surgery because of intra-abdominal adhesions ($n=1$), and complicated case with perforated acute colitis ($n=1$). The mean operative time was 252 minutes. The mean hospital stay was 8 days. Five (15%) patients experienced postoperative complications and no reoperation was needed. With a mean delay of 80 ± 20 days (range: 43 to 129 days), intestinal continuity was restored in 100 percent of the cases.

Fowkes *et al* (Fowkes *et al.*, 2008) from Frenchay Hospital, United Kingdom analyzed surgical outcomes of fulminate and medically resistant ulcerative colitis carried out

laparoscopically. The medical records of 32 patients were reviewed. One (3%) patient required conversion to open surgery because of a small, localized perforation (unsuspected preoperatively). The median operative time was 135 minutes. The median hospital stay was 8 days. Twelve (38%) patients experienced postoperative complications. They concluded that laparoscopic-assisted subtotal colectomy in fulminant and medically resistant ulcerative colitis was feasible, safe and largely predictable operations that allow for early hospital discharge.

Author (year)	Hospital stay (days)			Morbidity (%)		
	Lap	Open	<i>P</i> -value	Lap	Open	<i>P</i> -value
Telem (2010)	4.5	6	<0.001	28 Wound complication 0	34 Wound complication 21	NS <0.01
Maggiori (2010)	8	-	-	15	-	-
Fowkes (2008)	8	-	-	38	-	-
Maeceau (2007)	9	12	NS (<0.10)	35	56	NS (<0.10)
Bell (2002)	5.1	8.8	<0.05	33	-	-
Dunker (2000)	14.6	18.0	0.05	Minor complication 10 Major complication 30	Minor complication 5 Major complication 8	0.41 1.00

Table 4 (continued). Perioperative data from clinical trials treating laparoscopic-assisted subtotal colectomy for severe ulcerative colitis

Marceau *et al* (Marceau *et al.*, 2007) from Beaujon Hospital, France conducted a case-matched study to assess the feasibility and safety of laparoscopic-assisted subtotal colectomy ($n=40$) (Ulcerative colitis, $n=14$; Crohn's disease, $n=29$; Indeterminate colitis, $n=5$) compared with open subtotal colectomy ($n=48$) (Ulcerative colitis, $n=26$; Crohn's disease, $n=13$; Indeterminate colitis, $n=1$) in patients with severe colitis. Two (5%) patients required conversion to open surgery because of intensive adhesions ($n=1$) and colonic fistula ($n=1$). Between the laparoscopic group and open group, the mean operative time (253 vs. 231 min), overall morbidity (35 vs. 56%), and hospital stay (9 vs. 12 days) were similar. After a follow-up of 3 ± 4 months after the first operation, 35 patients (88%) have had restorative intestinal continuity through laparoscopic approach or elective incision at the site of previous stoma. They concluded that laparoscopic-assisted subtotal colectomy was as safe and effective as open subtotal colectomy for patients with severe colitis complicating inflammatory bowel disease.

Bell *et al* (Bell & Seymour 2002) from Yale University School of Medicine, New Haven reported surgical outcomes of fulminant ulcerative colitis carried out laparoscopically. The medical records of 18 patients with poorly controlled fulminant ulcerative colitis on aggressive immunosuppressive therapy who underwent laparoscopic subtotal colectomy were reviewed. None of the laparoscopic procedures required conversion to an open operation, and there were no intraoperative complications. The total operative time ranged from 220 to 360 min. Procedure length diminished significantly over the course of the series; the operative time during the last six procedures was 244 vs. 275 minutes during the prior 12 patients. Postoperative hospital stay was 5.0 days vs. 8.8 days ($p<0.05$) for a group of 6 patients who had undergone open subtotal colectomy for the same indications. Postoperative complications occurred in 6 (33%) patients.

Author (year)	Conclusions
Telem (2010)	Technically feasible and safe. Improved cosmesis. Reduced intraoperative blood loss. Negligible wound complications. Shorter hospital stay.
Maggiori (2010)	Low morbidity. Facilitated second step of intestinal continuity restoration for both ileorectal and ileo-anal anastomosis.
Fowkes (2008)	Technically feasible and safe. Shorter hospital stay. Facilitated subsequent proctectomy and pouch construction.
Marceau (2007)	Operative time, overall morbidity, and hospital stay were similar to open surgery. 84% of the patients underwent restorative intestinal continuity
Bell (2002)	Technically feasible. Shorter hospital stay. Facilitated subsequent proctectomy and pouch construction.
Dunker (2000)	Technically feasible and safe. Shorter hospital stay. Longer operative time.

Table 4 (continued). Perioperative data from clinical trials treating laparoscopic-assisted subtotal colectomy for severe ulcerative colitis

Dunker *et al* (Dunker *et al.*, 2000) from Academic Medical Center, Netherlands evaluated the feasibility and safety of emergency laparoscopic-assisted subtotal colectomy in patients with severe acute colitis. The medical records of 42 consecutive patients (Laparoscopic group; $n=10$, Open group; $n=32$) were reviewed. No patients in laparoscopic group required conversion to open surgery. The mean operative time was longer in laparoscopic group than in the open group (271 vs. 150 minutes). Postoperative hospital stay was significantly shorter in the laparoscopic group than in the open group (14.6 vs. 18.0 days). Complications were similar for the two groups. They concluded that laparoscopic-assisted subtotal colectomy in patients with severe acute colitis was feasible and safe as open colectomy.

4. Hand-assisted laparoscopic subtotal colectomy for severe ulcerative colitis

Standard laparoscopic assisted subtotal colectomy for severe ulcerative colitis is still technically difficult because of bowel friability and hypervascularity, creating a high

likelihood of perforation and bleeding. Hand-assisted laparoscopic surgery is a technique in which laparoscopic procedures are performed with the aid of a hand inserted into the abdomen through a small incision. (Ballantyne & Leahy, 2004; Nakajima et al., 2004; Rivadeneira et al., 2004; Boushey et al., 2007). Surgeons are able to obtain tactile sensation, manual retraction, and digital vascular control, which could allow complex laparoscopic operations to be performed more effectively and satisfactorily. A few recent studies have reported hand-assisted laparoscopic subtotal colectomy for selected patients with severe ulcerative colitis (Watanabe et al., 2009; Holubar et al., 2009; Chung et al., 2009).

4.1 Surgical technique for hand-assisted laparoscopic subtotal colectomy

The patient was placed in the supine position with legs moderately opened. A 70-mm lower paramedian incision was made and the abdomen was entered (Fig. 2). The ascending and descending colon was manually mobilized through the incision. After the mobilization, the hand port was placed in the lower paramedian incision. A 12-mm trocar was inserted above the umbilicus for laparoscope and pneumoperitoneum. A 5-mm or 12-mm trocar was inserted in the lower left abdomen for dissection. If necessary, the third 5-mm or 12-mm trocar was inserted in the upper left abdomen. The greater omentum was dissected and splenicocolic and hepatocolic ligaments were taken down to mobilize the transverse colon by use of a Harmonic Scalpel™ (UltraCision, Smithfield, RI) or LigaSure™ (Tyco Healthcare Japan, Tokyo, Japan) (Fig.3, 4). The mesocolon was also dissected. The ileocolic artery was preserved in all patients to provide optimal blood supply to the distal ileum. After this, the laparoscopic procedure was ended. Transsection of the terminal ileum and proximal rectum were performed with a linear stapler, and the colon was taken out through the lower paramedian incision. A mucous fistula of the rectum was constructed in the left lower abdomen, and a standard Brooke ileostomy was fashioned in the right lower abdomen (Fig. 5).

4.2 Hand-assisted laparoscopic surgery for severe ulcerative colitis

A few recent studies have evaluated the outcome of hand-assisted laparoscopic subtotal colectomy in patients with severe ulcerative colitis.

The authors (Watanabe et al., 2009) from Tohoku University Graduate School of Medicine, Japan recently reviewed the medical records of 60 patients who underwent emergency subtotal colectomy with hand-assisted laparoscopic technique ($n=30$) or conventional open technique ($n=30$) for severe ulcerative colitis. One (3%) patient in the laparoscopic group required conversion to open surgery because of excessive inflammatory adhesion. The median operative time was significantly longer in the hand-assisted laparoscopic surgery group than in the open surgery group (242 vs. 191 minutes; $P<0.001$). The median time to first solid diet in the hand-assisted laparoscopic surgery group was significantly shorter than that in the open surgery group (4.8 vs. 5.9 days; $P=0.007$). The postoperative hospital stay in the hand-assisted laparoscopic surgery group was significantly shorter than in the open surgery group (23.0 vs. 33.0 days; $P=0.001$). The number of postoperative complications during the hospital stay in the hand-assisted laparoscopic surgery group was significantly less than in open surgery group (37 vs. 63%; $P = 0.041$). Four (13%) patients in the open surgery group required relaparotomy because of peritoneal abscess (two patients) or strangulation ileus (two patients), but no patients needed relaparotomy in the hand-assisted laparoscopic surgery group ($P=0.040$). In the open surgery group, 4 of 30 patients (13%) had surgical site infection and 2 patients among them developed wound dehiscence

and needed resuture of the wound. In the hand-assisted surgery group, 4 of 30 patients (13%) had surgical site infection, but no patient developed wound dehiscence. The authors concluded that hand-assisted laparoscopic surgery can be an alternative to conventional open surgery for severe ulcerative colitis.

conversion to open surgery was 2 (5.5%) in laparoscopic-assisted surgery group, and 1 (7.1%) in hand-assisted laparoscopic surgery group, respectively. The median operative time was 251 minutes. The median hospital stay was 4 days. Seventeen (34%) patients experienced postoperative complications and 2 (4%) patients required reoperation. The most frequent complications after each procedure were ileus (8%) and surgical site infections (4%).

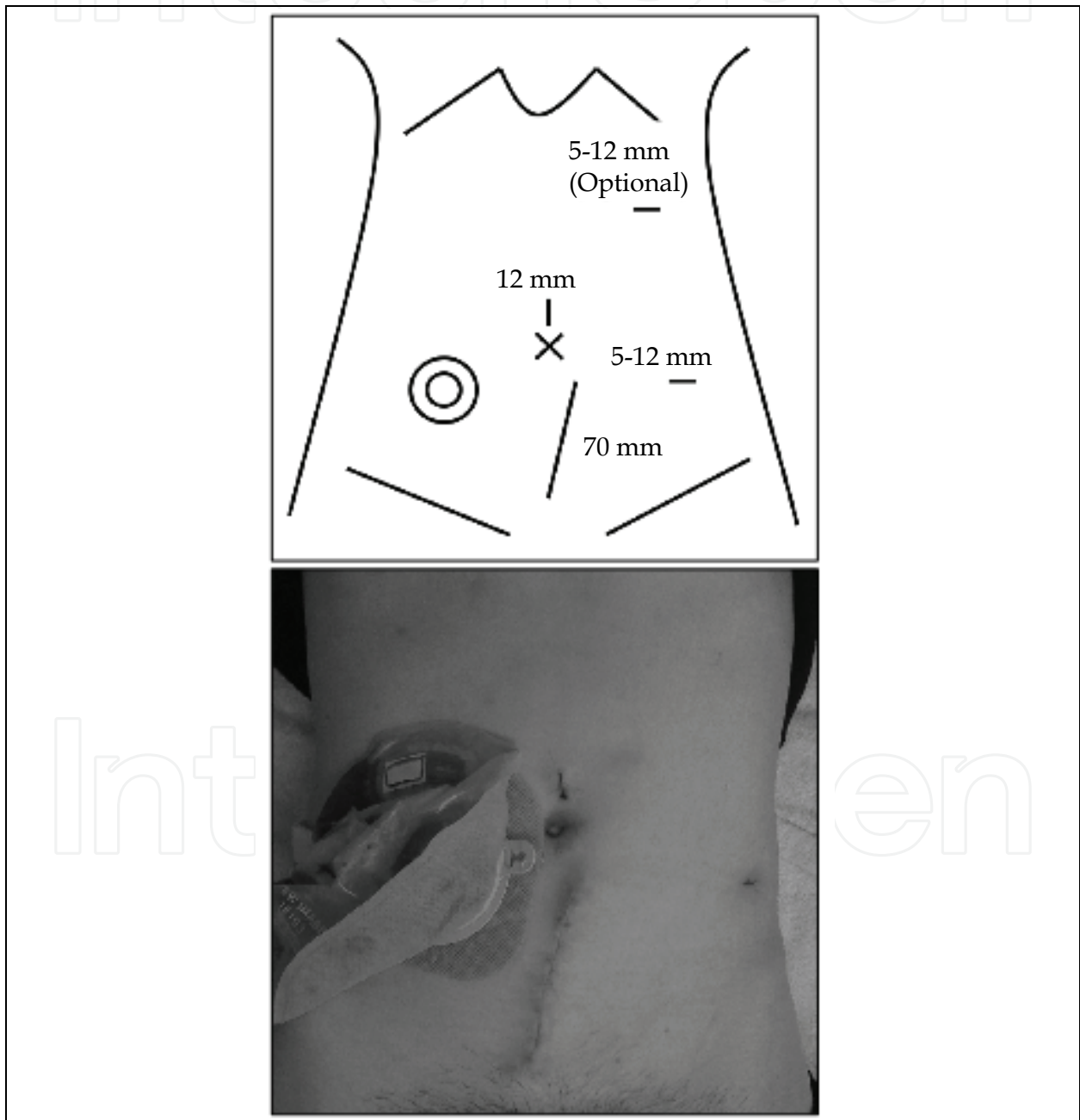


Fig. 2. Port and incision placement for hand-assisted laparoscopic subtotal colectomy (above). Operative scars after hand-assisted laparoscopic subtotal colectomy (below)

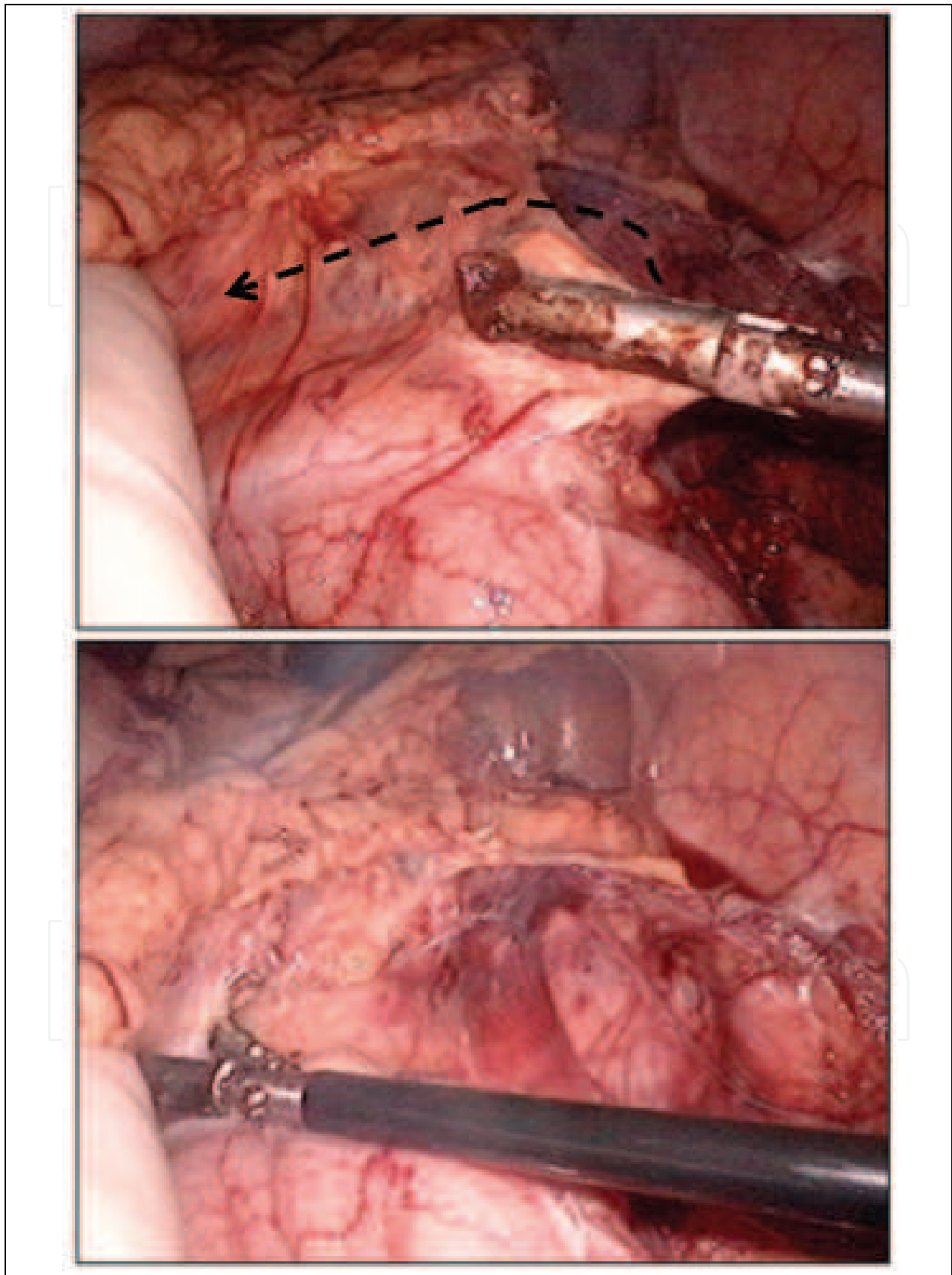


Fig. 3. Mobilization of the transverse colon using hand-assisted laparoscopic technique. Splenicocolic ligament was taken down from the descending colon to the transverse colon

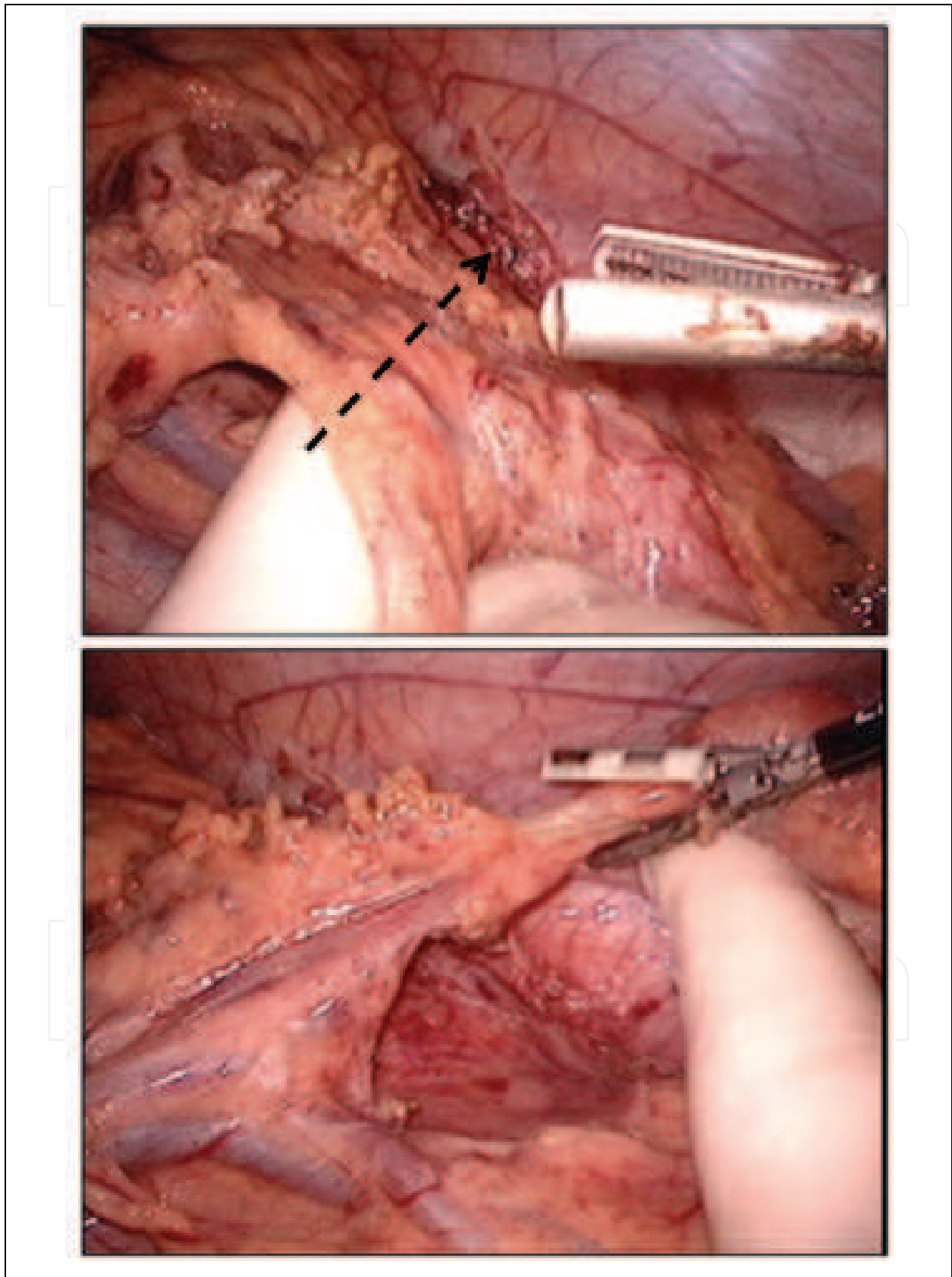


Fig. 4. Mobilization of the transverse colon using hand-assisted laparoscopic technique. Splenicocolic ligament was taken down from the transverse colon to the descending colon

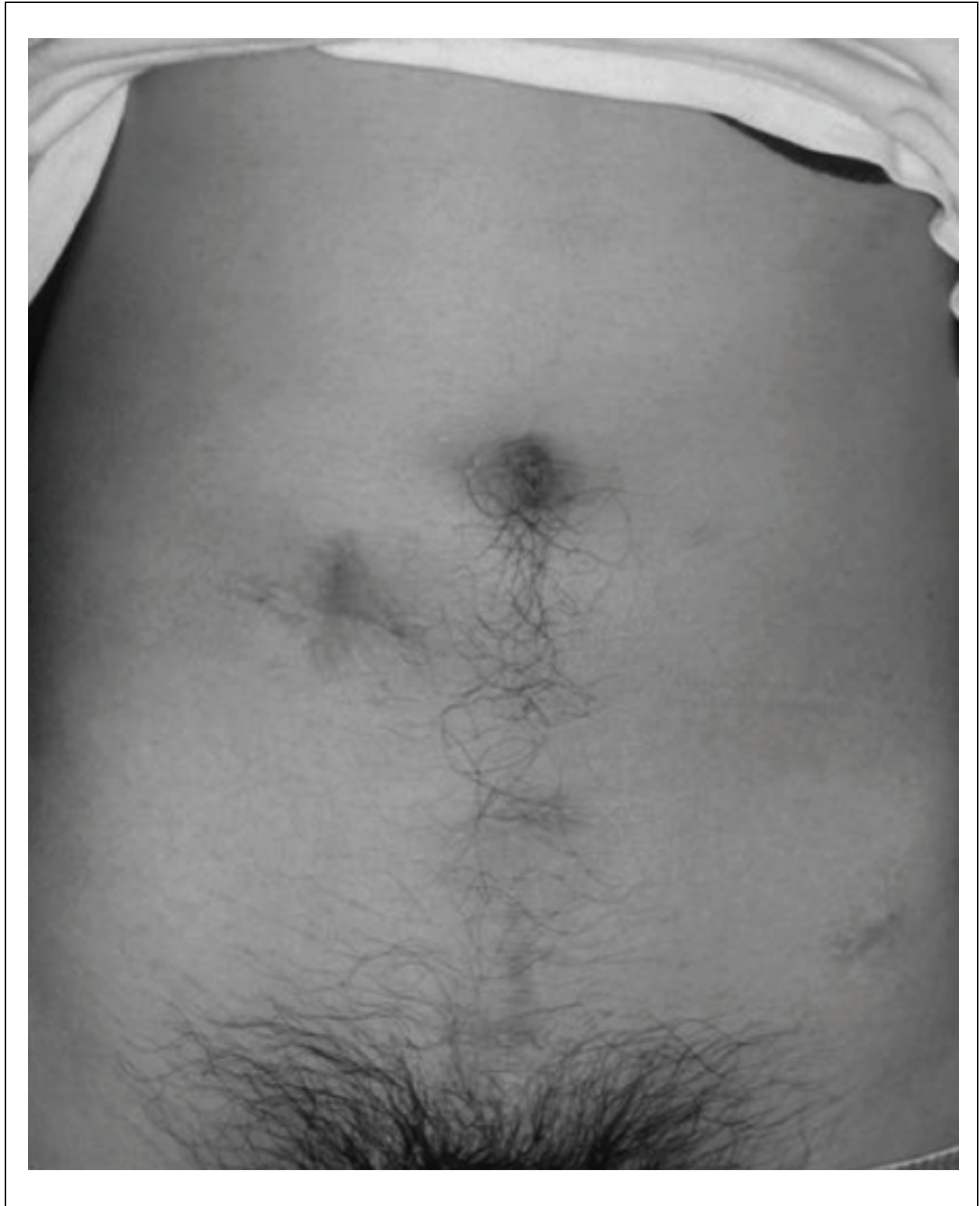

Fig. 5. Operative scars after three-stage hand-assisted laparoscopic proctocolectomy

Holubar *et al* (Holubar et al., 2009) from Mayo Clinic, Rochester evaluated the safety and feasibility of minimally invasive subtotal colectomy for fulminant ulcerative colitis. The medical records of 50 patients (Laparoscopic-assisted surgery; n=36, Hand-assisted laparoscopic surgery; n=14) were reviewed. The number of patients who required Chung *et*

al (Chung et al., 2009) from Washington University School of Medicine, St. Louis compared short-term outcomes of minimally invasive vs. open subtotal colectomy for severe ulcerative colitis. The medical records of 81 patients (Laparoscopic-assisted surgery; $n=17$, Hand-assisted laparoscopic surgery; $n=20$, Open surgery; $n=44$) were reviewed. Two (11.8%) patients in minimally invasive surgery group required conversion to open surgery because of bleeding from the middle colic vessels, and colonic injury with feculent spillage. Intraoperative intravenous fluid volume, operative time, and estimated blood loss were increased in the minimally invasive surgery group. Short-term recovery (return of bowel function, length of stay, inpatient narcotic use, and complication rate) was significantly lessened in the minimally invasive surgery group. The minimally invasive surgery group completed all three stages a mean of 66 days sooner than the open surgery group (188.9 vs. 255.36 days, $P = 0.0038$).

Author (year)	Number of patients		Operative time (min)			Conversion (%)
	MIS	Open	MIS	Open	<i>P</i> -value	MIS
Watanabe (2009)	HALS;30	30	242	191	<0.001	3
Holubar (2009)	HALS;14 LAP;36	-	251	-	-	HALS;7.1 LAP;5.5
Chung (2009)	HALS;20 LAP;17	44	223	140	<0.001	Overall; 11.8

MIS: minimally invasive surgery

Table 5. Perioperative data from clinical trials treating laparoscopic-assisted subtotal colectomy for severe ulcerative colitis

Author (year)	Hospital stay (days)			Morbidity (%)		
	MIS	Open	<i>P</i> -value	MIS	Open	<i>P</i> -value
Watanabe (2009)	23	33	0.001	37	63	0.041
Holubar (2009)	4	-	-	34	-	-
Chung (2009)	4.9	8.5	0.039	24	48	0.039

MIS: minimally invasive surgery

Table 5 (Continued). Perioperative data from clinical trials treating laparoscopic-assisted subtotal colectomy for severe ulcerative colitis

Author (year)	Conclusions
Watanabe (2009)	Technically feasible and safe. Longer operative time. Shorter hospital stay. Reduced postoperative complication rate.
Holubar (2009)	Technically feasible and safe. Shorter hospital stay.
Chung (2009)	Safe. Associated with short-term benefits that may lead to faster recovery and progression to completion of restorative proctocolectomy.

Table 5 (continued). Perioperative data from clinical trials treating laparoscopic-assisted subtotal colectomy for severe ulcerative colitis

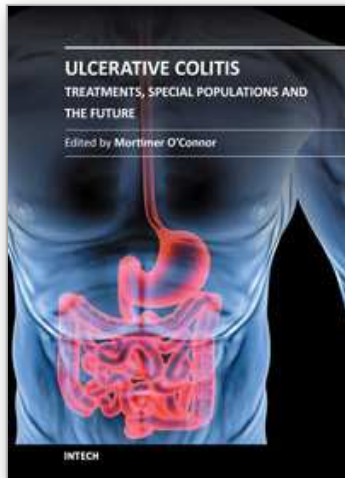
5. Conclusion

The earliest reports of the laparoscopic approach to ulcerative colitis in the elective setting provided little evidence of significant benefit over the standard open operative approach (Peters 1992; Wexner et al. 1992). However, with advances in technology and experience of laparoscopic surgery, more favourable results have been stated. Several studies have reported the feasibility and safety of laparoscopic assisted total colectomy for ulcerative colitis in the elective setting, and shown the advantages of laparoscopic assisted total colectomy such as reduced postoperative pain, earlier return of intestinal function, decreased length of hospital stay, and improved cosmesis (Marcello et al., 2000; Hashimoto et al., 2001; Seshadri et al., 2001; Gill et al., 2004; Kienle et al., 2005; Larson et al., 2005). On the basis of these results, several studies have evaluated the feasibility and safety of minimally invasive surgery for selected patients with severe ulcerative colitis (Dunker et al., 2000; Bell & Seymour, 2002; Marceau et al., 2007; Fowkes et al., 2008; Watanabe et al., 2009; Holubar et al., 2009; Chung et al., 2009; Maggiori et al., 2010; Telem et al., 2010). These retrospective trials indicated that minimally invasive subtotal colectomy for selected patients with severe ulcerative colitis associated with a marked reduction in wound complication rate, time to return of bowel function, and mean hospital stay, although most of these studies have reported that the mean operating time was longer than open surgery. The role of minimally invasive surgery for patients with severe ulcerative colitis is still not well defined because there is no randomized clinical trial; however, the reproducibility of the results among many institutions provides adequate evidence to demonstrate clear advantages of minimally invasive surgery for severe ulcerative colitis over a conventional open surgery. Laparoscopic assisted surgery for severe ulcerative colitis is still technically difficult because of bowel friability and hypervascularity, creating a high likelihood of perforation and bleeding. A few recent studies assessed hand-assisted laparoscopic surgery for selected patients with severe ulcerative colitis (Watanabe et al., 2009; Holubar et al., 2009; Chung et al., 2009). The use of this technique may be adequate for severe ulcerative colitis because hand-assisted surgery enables surgeons to obtain tactile sensation, manual retraction, and digital vascular control, which could allow complex laparoscopic operations to be performed more effectively and satisfactorily. Further evidence based study is needed to clarify the role of laparoscopic assisted or hand-assisted laparoscopic surgery for severe ulcerative colitis.

6. References

- Ballantyne, G. H. & Leahy, P.F. (2004). Hand-assisted laparoscopic colectomy: evolution to a clinically useful technique. *Dis Colon Rectum* 47(5): 753-765.
- Bell, R. L. & Seymour, N. E. (2002). Laparoscopic treatment of fulminant ulcerative colitis. *Surgical endoscopy* 16(12): 1778-1782.
- Boushey, R. P., Marcello, P. W., Martel, G., Rusin, L. C., Roberts, P. L., & Schoetz, D. J., Jr. (2007). Laparoscopic total colectomy: an evolutionary experience. *Dis Colon Rectum* 50(10): 1512-1519.
- Brown, S. R., Eu K. W., & Seow-Choen, F. (2001). Consecutive series of laparoscopic-assisted vs. minilaparotomy restorative proctocolectomies. *Dis Colon Rectum* 44(3): 397-400.
- Chen, H. H., Wexner, S. D., Weiss, E. G., Nogueras, J. J., Alabaz, O., Iroatulam, A. J., Nessim, A., & Joo, J. S. (1998). Laparoscopic colectomy for benign colorectal disease is associated with a significant reduction in disability as compared with laparotomy. *Surg Endosc* 12(12): 1397-1400.
- Chung, T.P., Fleshman, J.W., Birnbaum, E.H., Hunt, S.R., Dietz, D.W., Read, T.E., & Mutch, M.G., (2009). Laparoscopic vs. open total abdominal colectomy for severe colitis: impact on recovery and subsequent completion restorative proctectomy. *Dis Colon Rectum* 52(1): 4-10.
- Dunker, M. S., Bemelman, W. A., Slors, J. F., van Hogezaand, R. A., Ringers, J., & Gouma, D. J. (2000). Laparoscopic-assisted vs open colectomy for severe acute colitis in patients with inflammatory bowel disease (IBD): a retrospective study in 42 patients. *Surgical Endosc* 14(10): 911-914.
- Fowkes, L., Krishna, K., Menon, A., Greenslade, G. L., & Dixon, A. R. (2008). Laparoscopic emergency and elective surgery for ulcerative colitis. *Colorectal disease* 10(4): 373-378.
- Gill, T. S., Karantana, A., Rees, J., Pandey, S., & Dixon, A. R. (2004). Laparoscopic proctocolectomy with restorative ileal-anal pouch. *Colorectal disease* 6(6): 458-461.
- Gurland, B. H., & Wexner, S. D. (2002). Laparoscopic surgery for inflammatory bowel disease: results of the past decade. *Inflammatory bowel diseases* 8(1): 46-54.
- Hamel, C. T., Hildebrandt, U., Weiss, E. G., Feifelz, G., & Wexner, S. D. (2001). Laparoscopic surgery for inflammatory bowel disease. *Surg Endosc* 15(7): 642-645.
- Hashimoto, A., Funayama, Y., Naito, H., Fukushima, K., Shibata, C., Naitoh, T., Shibuya, K., Koyama, K., Takahashi, K., Ogawa, H., Satoh, S., Ueno, T., Kitayama, T., Matsuno, S., & Sasaki, I. (2001). Laparoscope-assisted versus conventional restorative proctocolectomy with rectal mucosectomy. *Surg Today* 31(3): 210-214.
- Holubar, S. D., Larson, D. W., Dozois, E. J., Pattana-Arun, J., Pemberton, J. H., & Cima, R. R. (2009). Minimally invasive subtotal colectomy and ileal pouch-anal anastomosis for fulminant ulcerative colitis: a reasonable approach? *Dis Colon Rectum* 52(2): 187-192.
- Kienle, P., Z'Graggen, K., Schmidt, J., Benner, A., Weitz, J., & Buchler, M. W. (2005). Laparoscopic restorative proctocolectomy. *Br J Surg* 92(1): 88-93.
- Ky, A. J., Sonoda, T., & Milsom, J. W. (2002). One-stage laparoscopic restorative proctocolectomy: an alternative to the conventional approach? *Diseases of the colon and rectum* 45(2): 207-210; discussion 210-201.
- Larson, D. W., Dozois, E. J., Piotrowicz, K., Cima, R. R., Wolff, B. G., & Young-Fadok, T. M. (2005). Laparoscopic-assisted vs. open ileal pouch-anal anastomosis: functional outcome in a case-matched series. *Dis Colon Rectum* 48(10): 1845-1850.

- Lichtiger, S., Present, D. H., Kornbluth, A., Gelernt, I., Bauer, J., Galler, G., Michelassi, F., & Hanauer, S. (1994). Cyclosporine in severe ulcerative colitis refractory to steroid therapy. *New Engl J Med* 330(26): 1841-1845.
- Maggiore, L., Bretagnol, F., Alves, A., & Panis, Y. (2010). Laparoscopic subtotal colectomy for acute or severe colitis with double-end ileo-sigmoidostomy in right iliac fossa. *Surg Laparosc Endosc Percutan Tech* 20(1): 27-29.
- Marceau, C., Alves, A., Ouaiissi, M., Bouhnik, Y., Valleur, P., & Panis, Y. (2007). Laparoscopic subtotal colectomy for acute or severe colitis complicating inflammatory bowel disease: a case-matched study in 88 patients. *Surgery* 141(5): 640-644.
- Marcello, P. W., Milsom, J. W., Wong, S. K., Hammerhofer, K. A., Goormastic, M., Church, J. M., & Fazio, V. W. (2000). Laparoscopic restorative proctocolectomy: case-matched comparative study with open restorative proctocolectomy. *Dis Colon Rectum* 43(5): 604-608.
- Nakajima, K., Lee, S. W., Cocilovo, C., Foglia, C., Kim, K., Sonoda, T., & Milsom, J. W. (2004). Hand-assisted laparoscopic colorectal surgery using GelPort. *Surg Endosc* 18(1): 102-105.
- Peters, W. R. (1992). Laparoscopic total proctocolectomy with creation of ileostomy for ulcerative colitis: report of two cases. *Journal of laparoendoscopic surgery* 2(3): 175-178.
- Rivadeneira, D. E., Marcello, P. W., Roberts, P. L., Rusin, L. C., Murray, J. J., Collier, J. A., & Schoetz, D. J., Jr. (2004). Benefits of hand-assisted laparoscopic restorative proctocolectomy: a comparative study. *Dis Colon Rectum* 47(8): 1371-1376.
- Sawada, K., Ohnishi, K., Fukui, S., Yamada, K., Yamamura, M., Amano, K., Wada, M., Tanida, N., & Satomi, M. (1995). Leukocytapheresis therapy, performed with leukocyte removal filter, for inflammatory bowel disease. *J Gastroenterol* 30(3): 322-329.
- Seshadri, P. A., Poulin, E. C., Schlachta, C. M., Cadeddu, M. O., & Mamazza, J. (2001). Does a laparoscopic approach to total abdominal colectomy and proctocolectomy offer advantages? *Surg Endosc* 15(8): 837-842.
- Sood, A., Midha, V., Sood, N., & Awasthi, G. (2002). A prospective, open-label trial assessing dexamethasone pulse therapy in moderate to severe ulcerative colitis." *J Clin Gastroenterol* 35(4): 328-331.
- Telem, D. A., Vine, A. J., Swain, G., Divino, C. M., Salky, B. Greenstein, A. J., Harris, M., & Katz, L. B. (2010). Laparoscopic subtotal colectomy for medically refractory ulcerative colitis: the time has come. *Surg Endosc* 24(7): 1616-1620.
- Truelove, S. & Witts L. (1955). Cortisone in ulcerative colitis; final report on a therapeutic trial. *British medical journal* 2(4947): 1041-1048.
- Truelove, S. C., & Jewell D. P. (1974). Intensive intravenous regimen for severe attacks of ulcerative colitis. *Lancet* 1(7866): 1067-1070.
- Watanabe, K., Funayama, Y., Fukushima, K., Shibata, C., Takahashi, K., & Sasaki, I. (2009). Hand-assisted laparoscopic vs. open subtotal colectomy for severe ulcerative colitis. *Dis Colon Rectum* 52(4): 640-645.
- Wexner, S. D., Johansen, O. B., Nogueras, J. J., & Jagelman, D. G. (1992). Laparoscopic total abdominal colectomy. A prospective trial. *Dis Colon Rectum* 35(7): 651-655.



Ulcerative Colitis - Treatments, Special Populations and the Future

Edited by Dr Mortimer O'Connor

ISBN 978-953-307-739-0

Hard cover, 178 pages

Publisher InTech

Published online 02, November, 2011

Published in print edition November, 2011

This book is intended to act as an up to date reference point and knowledge developer for all readers interested in the area of gastroenterology and in particular Ulcerative Colitis. All of the chapter authors are experts in their fields of publication and deserve individual credit and praise for their contributions to the world of Ulcerative Colitis. We hope that you will find this publication informative, stimulating and a reference point for the area of Ulcerative colitis as we move forward in our understanding of the field of medicine.

How to reference

In order to correctly reference this scholarly work, feel free to copy and paste the following:

Kazuhiro Watanabe, Hitoshi Ogawa, Chikashi Shibata, Koh Miura, Takeshi Naitoh, Masayuki Kakyou, Takanori Morikawa, Sho Haneda, Naoki Tanaka, Katsuyoshi Kudo, Shinobu Ohnuma, Hiyroyuki Sasaki and Iwao Sasaki (2011). Laparoscopic Surgery for Severe Ulcerative Colitis, *Ulcerative Colitis - Treatments, Special Populations and the Future*, Dr Mortimer O'Connor (Ed.), ISBN: 978-953-307-739-0, InTech, Available from: <http://www.intechopen.com/books/ulcerative-colitis-treatments-special-populations-and-the-future/laparoscopic-surgery-for-severe-ulcerative-colitis>

INTECH

open science | open minds

InTech Europe

University Campus STeP Ri
Slavka Krautzeka 83/A
51000 Rijeka, Croatia
Phone: +385 (51) 770 447
Fax: +385 (51) 686 166
www.intechopen.com

InTech China

Unit 405, Office Block, Hotel Equatorial Shanghai
No.65, Yan An Road (West), Shanghai, 200040, China
中国上海市延安西路65号上海国际贵都大饭店办公楼405单元
Phone: +86-21-62489820
Fax: +86-21-62489821

© 2011 The Author(s). Licensee IntechOpen. This is an open access article distributed under the terms of the [Creative Commons Attribution 3.0 License](#), which permits unrestricted use, distribution, and reproduction in any medium, provided the original work is properly cited.

IntechOpen

IntechOpen