

We are IntechOpen, the world's leading publisher of Open Access books Built by scientists, for scientists

4,800

Open access books available

122,000

International authors and editors

135M

Downloads

Our authors are among the

154

Countries delivered to

TOP 1%

most cited scientists

12.2%

Contributors from top 500 universities



WEB OF SCIENCE™

Selection of our books indexed in the Book Citation Index
in Web of Science™ Core Collection (BKCI)

Interested in publishing with us?
Contact book.department@intechopen.com

Numbers displayed above are based on latest data collected.

For more information visit www.intechopen.com



Hepatitis C Virus Associated Glomerulonephritis

Vincent Ho¹ and Jason Chen²

¹*Department of Medicine, Campbelltown Hospital and School of Medicine,
University of Western Sydney, Sydney,*

²*Department of Anatomical Pathology, Royal North Shore Hospital, Sydney,
Australia*

1. Introduction

Approximately 170 million persons worldwide are infected with the hepatitis C (HCV) virus. The incidence of glomerulonephritis in HCV-infected patients is unknown due to a lack of large-scale cross sectional surveys however subclinical renal involvement is believed to be highly prevalent among patients with HCV hepatitis. The most common HCV-associated glomerulonephritis is membranoproliferative glomerulonephritis (MPGN) type 1 with or without cryoglobulinaemia. MPGN typically presents several years, and often decades, after initial infection with HCV. Most patients have laboratory evidence of hypocomplementaemia, circulating rheumatoid factors, and cryoglobulinaemia. Other uncommon forms of glomerular disease that have been reported to be associated with HCV infection include membranous nephropathy, IgA nephropathy, focal segmental glomerulosclerosis, fibrillary glomerulonephritis/immunotactoid glomerulopathy, pauci-immune glomerulonephritis, and thrombotic microangiopathy.

The principal clinical manifestations of glomerular disease in HCV patients are the presence of proteinuria and microscopic haematuria with or without impaired kidney function. The clinical course of these HCV-associated glomerulopathies is generally characterised by remission and relapsing phases. The overall prognosis for HCV-associated glomerulonephritis remains poor, not only because of renal disease progression but because of the high incidence of cardiovascular disease, infection and hepatic failure.

The exact pathogenic sequence of injury that results in glomerulonephritis is not known. The prevailing theory is that glomerular injury results from deposition of circulating immune complexes that contain HCV antigens and anti-HCV antibody. Involvement of the innate immune system in HCV-associated MPGN has been suggested with demonstration of upregulation of Toll-like receptor 3.

In establishing a link between HCV infection and the immune response targeting the glomerulus, antiviral, plasma exchange and immunosuppressive therapies have been used in patients. The use of antiviral therapy in HCV-positive patients with glomerulonephritis is targeted at eliminating the virus and reducing the generation of HCV-related antibodies and immune complexes. The data to support antiviral treatment for HCV-associated glomerulonephritis is limited, however interferon therapy may be superior to

immunosuppressive agents in HCV-associated cryoglobulinaemic glomerulonephritis in lowering proteinuria. Agents such as rituximab have also been shown to be efficacious in the treatment of HCV-associated cryoglobulinaemic glomerulonephritis.

This chapter provides the reader with an overview of hepatitis C-associated glomerulonephritis that covers epidemiology, clinical manifestations, natural history, immunopathophysiology, and a review of the evidence underpinning current therapeutic approaches.

Hepatitis C virus (HCV) is a leading cause of chronic liver disease in the world. The World Health Organization estimates that there are 170 million individuals with HCV infection and an incidence of 3–4 million new cases per year (WHO, 2000). HCV infection leads to chronic liver disease, but also to extra-hepatic manifestations. These include mixed cryoglobulinaemia, lymphoproliferative disorders and renal disease. HCV infection has been reported in association with distinct histological patterns of glomerulonephritis.

In this review, we will canvass the epidemiology, clinical manifestations, natural history, immunopathophysiology, and current therapies of HCV-associated glomerulonephritis, as well as cover issues around renal transplantation.

2. Immunopathogenesis

HCV is a single-stranded enveloped RNA virus. Its genome codes for a nucleocapsid core protein, envelope proteins, and a number of non-structural proteins. Glomerular injury due to HCV occurs as a result of the direct interaction of viral RNA and proteins with glomerular cells, as well as indirectly through immunological mediators such as immune complex deposition.

The adaptive immune response to HCV infection includes both cellular and humoral pathways. Unlike the overt cytotoxic cellular T-cell response to infected hepatocytes in the liver, the mechanism of injury in glomerulonephritis appears predominantly due to circulating immune complex deposition. This humoral response to HCV infection includes the production of various antibodies against HCV protein antigens. To evade this, HCV displays antigenic variability resulting from lack of proofreading activity in the HCV RNA polymerase. Hypervariable regions are present particularly in the envelope protein E2 sequence. Combined with a high replication rate, this antigenic variability allows mutant virus strains to escape antibody binding. Thus in chronic HCV infection, HCV RNA persists in serum despite the presence of anti-HCV antibodies. The chronic simultaneous presence of both HCV antigens and anti-HCV antibodies is a fertile setting for the formation of circulating immune complexes. In addition, HCV-induced liver injury decreases the hepatic clearance of circulating immune complexes, prolonging their survival in the circulation.

Often the anti-HCV antibodies have the properties of cryoglobulins, that is they precipitate at low temperatures. Serum cryoglobulins are present at low levels in up to 50% of chronic HCV infected patients, however symptomatic cryoglobulinaemia occurs in 1% or less of patients and usually only after years of chronic infection (Meyers et al., 2003). In HCV infection, the cryoglobulins are almost always of mixed type, with type 2 (monoclonal rheumatoid factor usually IgM kappa) more common than type 3 (polyclonal rheumatoid factor) (Miller and Howell, 2000). Possibly, IgM directed against epitopes of the HCV envelope cross-reacts with IgG, forming the rheumatoid factor (Alpers and Kowalewska, 2007). Thus, the cryoglobulins in HCV infection are composed of HCV RNA and/or

proteins, complexed with anti-HCV IgG, in turn complexed to IgM rheumatoid factor. The concentration of HCV RNA in cryoprecipitates has been found to be around 1,000 times higher than in serum (Kamar et al., 2008). While symptomatic cryoglobulinaemia is relatively rare in HCV infected patients, conversely the vast majority (over 80%) of patients with mixed cryoglobulins have evidence of HCV infection (Kamar et al., 2008).

Circulating immune complexes, including cryoglobulins, deposit in glomeruli along the capillary walls and in the mesangium. IgM kappa rheumatoid factor has a particular affinity for cellular fibronectin in the mesangial matrix (Perico et al., 2009). While immunoglobulins are readily and routinely identified in glomerular tissues, the demonstration of HCV antigens in glomeruli is controversial and limited to relatively small numbers of studies. For example, Sansonno and colleagues (2005) used laser capture microdissection combined with PCR to identify HCV RNA in glomeruli, as well as immunohistochemistry to identify HCV core protein in glomeruli. Virus-like particles have been identified by electron microscopy in renal biopsies of patients with HCV infection (Sabry, 2002).

While much work has focused on humoral immunity and immune complex deposition, there has also been research on the innate immune response of the glomerulus to HCV. This innate immune response to microbes involves Toll-like receptors (TLRs), transmembrane proteins that recognise microbial antigens. Dolganiuc and colleagues (2004), using a variety of human and mouse cell types, found that HCV core protein and HCV non-structural protein 3 act via Toll-like receptor 2 (TLR2) to trigger inflammatory pathways. In the kidney, it is also hypothesized that HCV RNA is recognised by Toll-like receptor 3 (TLR3) expressed on mesangial cells. Using a microdissection technique, increased TLR3 mRNA expression has been demonstrated in glomeruli with HCV-associated glomerulonephritis, compared to glomeruli with non-HCV-associated glomerulonephritis (Wornle et al., 2006). Recognition of HCV by TLR3 with subsequent intracellular signalling activates mesangial cells to produce pro-inflammatory cytokines and growth factors. The cytokines involved include TNF α and the chemokine IP-10 (interferon gamma inducible protein-10), both of which are upregulated in HCV-associated glomerulonephritis (Merkle et al., 2011).

The innate immune response, together with the trapping and deposition of immune complexes, both contribute to generate activation of local inflammatory and complement cascades in glomeruli. These cascades induce glomerular cell proliferation and matrix production as well as the recruitment of inflammatory cells, which can be seen morphologically as the characteristic histological patterns of glomerulonephritis. While some morphological patterns are characteristic of HCV, none is specific, and the diagnosis of HCV-associated glomerulonephritis relies on correlation with clinical findings as well as the presence of serum anti-HCV antibody and HCV RNA. Evidence of HCV RNA and/or core protein in glomeruli has been identified irrespective of the histological pattern of glomerulonephritis (Sansonno et al., 2005).

Membranoproliferative glomerulonephritis (MPGN) type 1 with or without cryoglobulinaemia is the most characteristic pattern, comprising the large majority (roughly 80%) of all HCV-associated glomerulonephritis. Conversely, HCV is perhaps the most important cause of secondary MPGN. Histologically, the glomeruli have a membranoproliferative pattern with accentuated lobularity, mesangial hypercellularity, and mesangial interpositioning causing double contouring of the capillary walls. The glomeruli may have prominent inflammatory cell infiltration, particularly of monocytes (Alpers and Kowaleska, 2007). See Figure 1

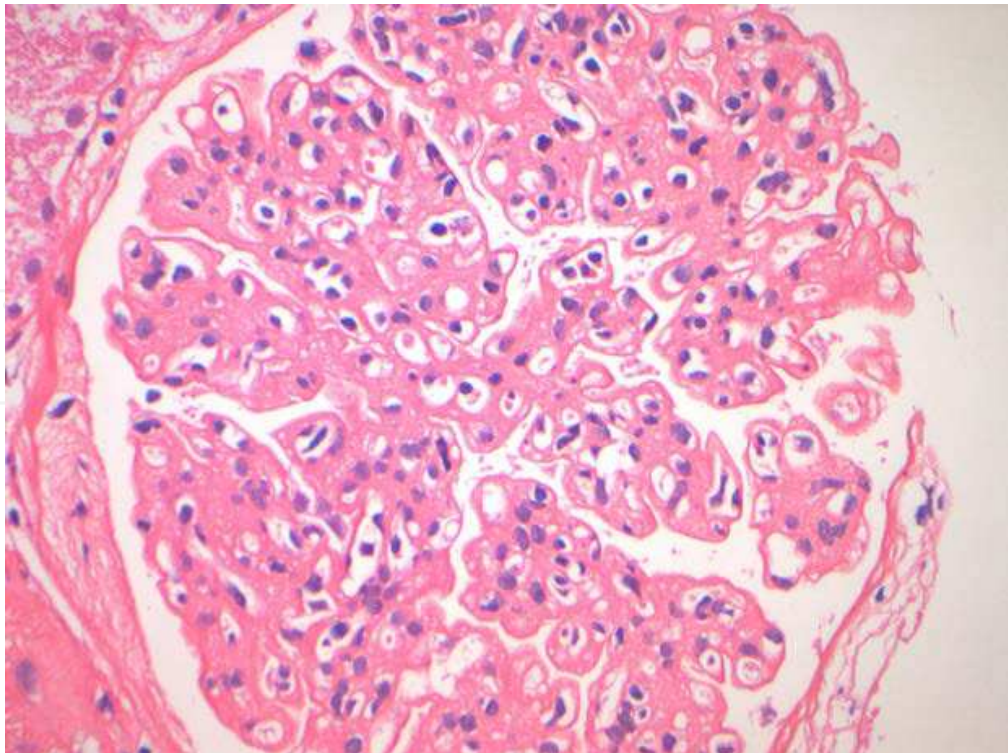


Fig. 1a. Membranoproliferative glomerulonephritis in a HCV-infected patient, with accentuated lobularity, mesangial hypercellularity and intracapillary mononuclear inflammatory cells (H&E, 400x).

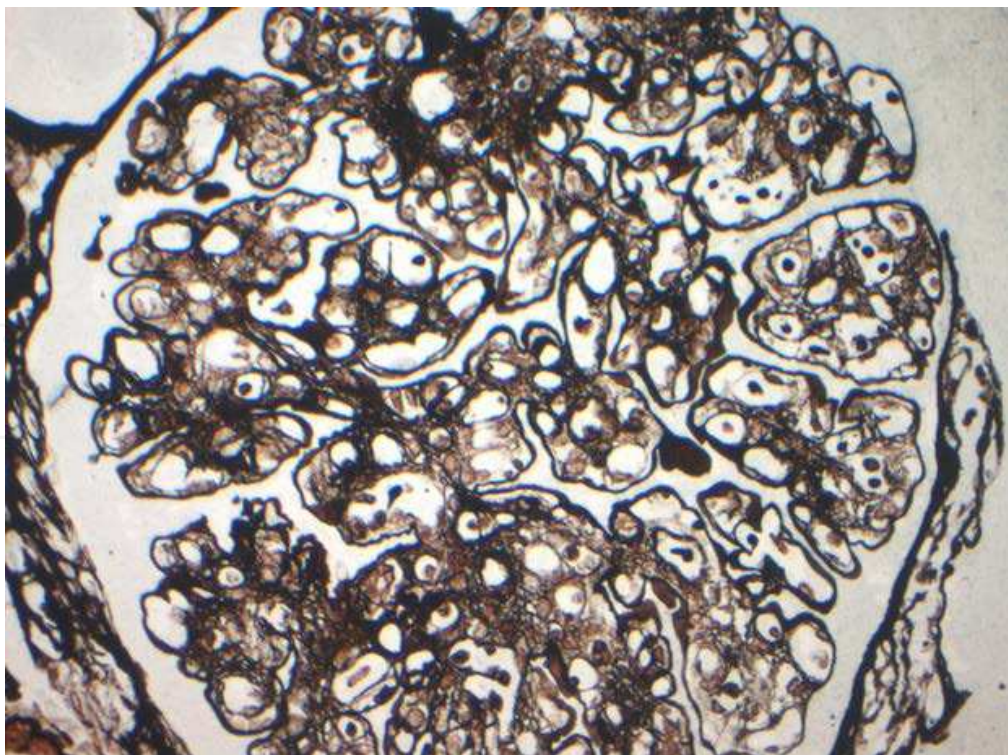


Fig. 1b. Double contouring of the capillary basement membranes is more evident on silver staining (Modified Wilder's silver stain, 400x).

Immunofluorescence staining highlights granular deposits of C3 and immunoglobulins (usually IgG and IgM) along capillary walls and in the mesangium, and electron microscopy confirms electron-dense immune complex deposits in subendothelial and mesangial locations. Cryoglobulin deposits themselves also produce a membranoproliferative pattern of injury. In these cases with cryoglobulinaemia, the deposits themselves may be seen histologically as eosinophilic glomerular capillary 'hyaline thrombi'. See Figure 2

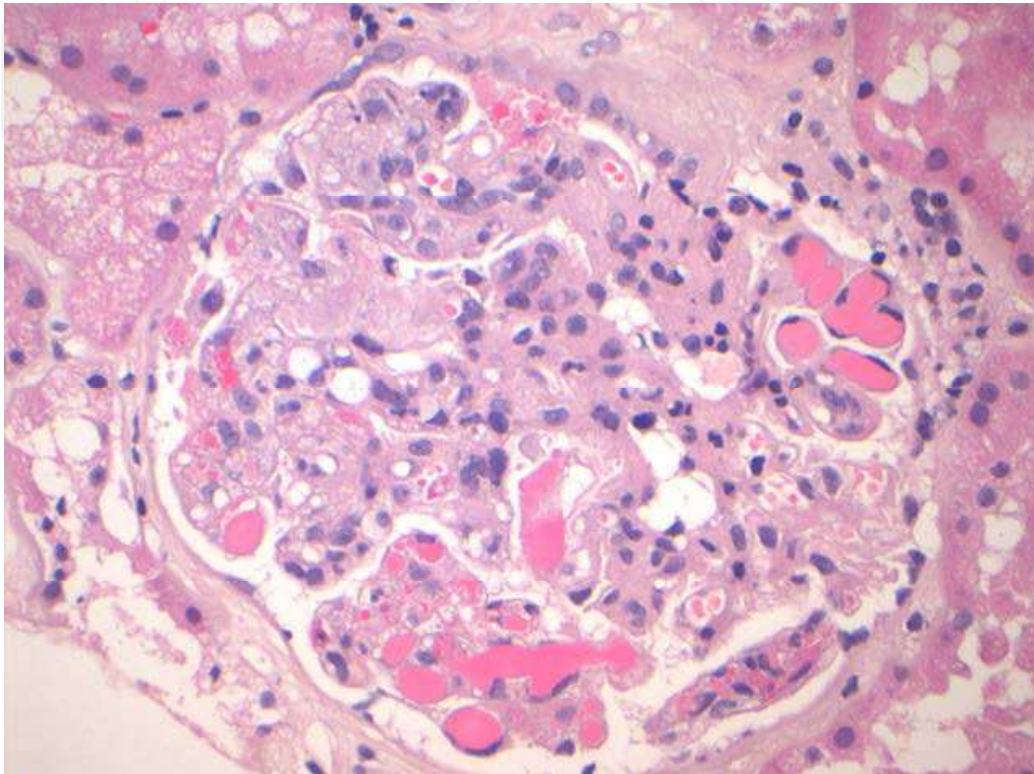


Fig. 2. Cryoglobulinaemic glomerulonephritis, with prominent intracapillary hyaline thrombi (H&E, 400x).

In a minority of cases, vasculitis of small vessels can also be seen on biopsy. Immunofluorescence staining reflects the composition of the usually mixed-type cryoglobulin precipitate, with strong staining for IgG, IgM and C3 as well as frequent kappa predominance. The cryoglobulin deposits by electron microscopy have variable morphology, but classically are seen as microtubular and/or annular organised structures (Iskanda and Herrera, 2002) . See Figure 3

MPGN type 3 has overlapping features of both MPGN type 1 in combination with membranous nephropathy, and has also been described as a pattern of HCV-associated glomerulonephritis.

The remaining patterns of glomerulonephritis are relatively uncommon and have been reported as small series and case reports, with varying degrees of strength in their association with HCV. Of these relatively uncommon forms of HCV-associated glomerulonephritis, membranous nephropathy is the most often quoted. In a study by Yamabe and colleagues (1995), 2 of 24 patients (8.3%) with membranous nephropathy had evidence of HCV infection. A separate Japanese study of 2 patients with membranous nephropathy demonstrated pathogenic linkage to HCV by detecting HCV core protein in the affected glomeruli using immunofluorescence (Okada et al., 1996). In contrast to HCV-associated MPGN, HCV-

associated membranous nephropathy does not appear associated with cryoglobulinaemia, rheumatoid factor or hypocomplementaemia (Uchiyama-Tanaka et al., 2004).

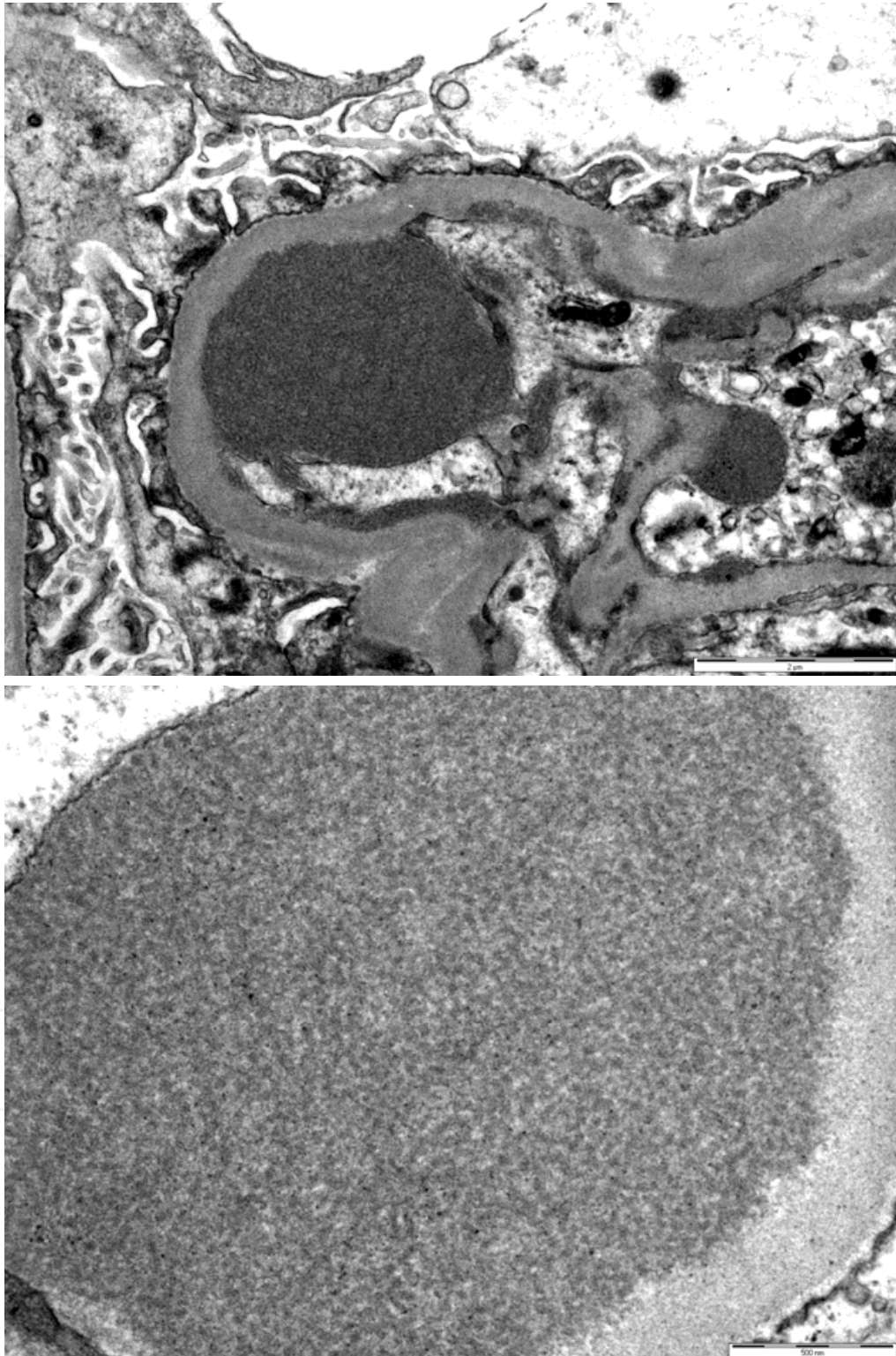


Fig. 3. (3a above and 3b below). Cryoglobulin deposits classically show organised substructure such as microtubular aggregates (EM; photos courtesy of Mr Paul Kirwan, EM unit Concord Repatriation General Hospital Sydney Australia).

A case series from the University of Alabama at Birmingham examined the kidney biopsies of 30 patients receiving liver transplants for HCV-induced cirrhosis at the time of liver engraftment (McGuire et al., 2006). Three types of disease were observed: membranoproliferative glomerulonephritis type 1, IgA nephropathy, and "mesangial glomerulonephritis". Cryoglobulins were not detected, even in rheumatoid factor-positive patients with urinary abnormalities.

Other rare, somewhat speculative, reported associations with HCV include focal segmental glomerulosclerosis (Stehman-Breen et al., 1999), fibrillary glomerulonephritis/immunotactoid glomerulopathy (Markowitz et al., 1998), pauci-immune glomerulonephritis (Usalan et al., 1998), and thrombotic microangiopathy (Herzenberg et al., 1998).

Lastly, it should be noted that the development of de novo immune complex glomerulonephritis in the transplanted kidney is one mechanism leading to the increased graft failure seen in HCV-infected renal transplant recipients (Scott et al., 2010).

3. Clinical manifestations

Glomerulonephritis can develop several years or even decades after initial infection with HCV. As described previously the principal renal manifestation of HCV infection is membranoproliferative glomerulonephritis (MPGN). This is usually accompanied by cryoglobulinaemia. Classically, HCV-associated MPGN is found in persons with long-standing infection and patients most often display mild subclinical liver disease. MPGN is rarely found in children. Clinically, patients may exhibit symptoms of cryoglobulinaemia, including palpable purpura, arthralgias, myalgias, neuropathy, and fatigue. The triad of purpura, peripheral neuropathy and arthralgia is evident in nearly 30% of cases (Monti et al., 1995). The majority of cryoglobulinaemic HCV-infected patients however have either no symptoms or nonspecific clinical manifestations. Cryoglobulins, or immunoglobulins (Igs) that precipitate at cold temperature, are detected in approximately 50–70% of patients. Cryoglobulinaemic vasculitis, predominantly involving the small vessels, is observed in less than 10% of patients (Lamprecht et al., 1999). The most frequently affected tissues/organs are skin, nerves, and kidney. Renal involvement has been reported in about one-third of cryoglobulinaemic patients (Meyers et al., 2003), but the predilection for renal involvement in certain patients is unclear. Renal signs of cryoglobulinaemia include nephrotic or non-nephrotic proteinuria and microscopic haematuria with mild to moderate renal insufficiency (Baid et al., 2000; Johnson et al., 1993; Markowitz et al., 1998). Glomerular disease may manifest acutely as oliguric acute renal failure in 5% of cases (Meyers et al., 2003). Around 80% of patients develop hypertension (Tarantino et al., 1995) which can be severe and difficult to control.

Usually, the diagnosis of HCV-associated MPGN is made by positive tests for serum HCV antibodies and HCV RNA. However patients with HCV-associated glomerulonephritis in whom HCV RNA were not detected in the blood have been reported (Yamabe et al., 2010).

Serum aminotransferase levels are increased in the majority of patients and often low serum concentrations of complement components (C1q, C4, and C3) are found (Meyers et al., 2003). Elevated levels of serum cryoglobulins can be divided by the Brouet classification into three types (Brouet et al., 1974). Type 2 and 3 cryoglobulins which are strongly associated with hepatitis C, have rheumatoid factor activity and bind to polyclonal immunoglobulins (Ferri et al., 2002). These two types are known as mixed cryoglobulinaemia.

4. Natural history

A large prospective cohort study conducted in Northern Norway on 1010 HCV-positive patients found elevated alanine aminotransferases in 27.4%, decompensated liver disease in 2.9%, hepatocellular carcinoma in 0.4% but only 2 patients (or 0.2%) with end-stage renal failure caused by membranoproliferative glomerulonephritis (Kristiansen et al., 2010). The median observation period from estimated acquisition of the disease to follow-up in these patients was 26 years.

The long-term outcome of HCV-associated nephropathies is nebulous. A retrospective cohort study of 474,369 adult veterans in the United States (Tsui et al., 2007) found that patients with HCV infection were more likely to develop end-stage renal disease (4.3 per 1000 person year) than HCV-seronegative patients (3.1 per 1000 person year). For patients aged 18 to 70 years with an estimated glomerular filtration rate of at least 30 mL/min per 1.73 m², HCV seropositivity was associated with a nearly threefold higher risk of developing ESRD (adjusted hazard rate, 2.80; 95% confidence interval, 2.43-3.23).

Another cross-sectional study (Dalrymple et al., 2007) showed that HCV-positive veterans after adjustment for age, race, gender, diabetes and hypertension, had 40% higher odds for renal insufficiency (odds ratio 1.40; 95% confidence interval 1.11 to 1.76) as compared with HCV-negative veterans.

An early literature review of patients with essential mixed cryoglobulinaemia (Ponticelli et al., 1986) found that of 11 patients with nephrotic syndrome and renal dysfunction who received supportive treatment alone, 4 patients (36%) died or exhibited progressive renal failure, 2 patients (18%) had stable renal disease, and spontaneous improvement occurred in the other 5 patients (45%).

Finally Tarantino and colleagues (1995) reported the overall poor clinical outcome of 105 essential mixed cryoglobulinaemia patients with renal involvement collected throughout 25 years in three renal units in Milan. Patient survival was 49% at 10 years after renal biopsy. Forty-two patients died primarily from cardiovascular disease, liver disease or infection, whereas 15 patients developed chronic renal failure. Two patients had a complete remission of the disease while 15 had a remission only of renal manifestations. Thirty-one patients were alive at the end of the study with persistent renal and extrarenal manifestations. Thus only a minority of patients eventually developed renal failure because most patients died from cardiovascular disease, liver disease or infection.

5. Therapy

5.1 Renoprotective therapies

As hypertension, proteinuria, and progressive renal failure are the main clinical manifestations of HCV-associated chronic renal disease, it is essential that renoprotective therapies be instituted. Diuretics, renin-angiotensin system inhibitors (angiotensin-converting enzyme inhibitors or angiotensin II receptor blockers), and lipid-lowering agents, have been proven to be beneficial in HCV patients with chronic renal disease (Chadban and Atkins, 2005; Ruggenenti et al., 2001; Ruggenenti et al., 2004).

5.2 Immunosuppressive therapy

High-dose methylprednisolone has been used to treat exacerbations of mixed cryoglobulinaemia for over 30 years (Tarantino et al., 1981; De Vecchi et al., 1983). In one of

the earlier studies (De Vecchi et al., 1983), 3 pulses of intravenous methylprednisolone (0.5-1 gm each) was given for 3 consecutive days during episodes of acute renal function deterioration in 16 patients with essential mixed cryoglobulinaemia. The intravenous administration was followed by oral prednisone 0.5 mg/kg per day with a slow taper until withdrawal of steroids after 4-6 months. Intravenous methylprednisolone pulse therapy did have a dramatic effect on renal function with cumulative mean plasma creatinine values decreasing from 3.3 ± 1.3 mg/dL to 2.2 ± 0.7 mg/dL ($p < 0.001$). Proteinuria levels were not found to be significantly changed as a result of therapy. The basal cryocrit level decreased after pulse therapy, however again this was not found to be significant.

In one case report of rapidly progressive MPGN type 1 with HCV and nephritic syndrome, intravenous pulsed methylprednisolone appeared to be useful in establishing rapid remission but as antiviral therapy was used concurrently it is impossible to ascertain the effect of methylprednisolone alone (Ahmed et al., 2008).

Unlike intravenous pulse steroid therapy, oral steroids however have not been found to be effective in the acute setting. Ponticelli and colleagues (1986) reported 27 patients with mixed cryoglobulinaemia and acute renal disease that were treated with oral corticosteroids alone or in combination with other cytotoxic agents. 10 patients (37%) died or showed progressively worsening renal function, 4 patients continued to have stable renal disease, and the other 13 patients (48%) had improved renal function. This does not appear to differ markedly from their reporting of the natural outcomes of such patients with supportive treatments alone.

Indeed there are conflicting results on the use of oral steroids for HCV-associated MPGN. A Japanese study (Komatsuda et al., 1996) found that only 2 out of 6 patients with MPGN responded to steroids but paradoxically found that the serum titre of HCV RNA decreased in 5 out of 7 treated patients.

Other studies have subsequently confirmed that HCV RNA levels increase with steroid exposure (Fong et al., 1994; Lake, 2003; McHutchinson et al., 1993).

Cyclophosphamide has been used successfully in the treatment of HCV-infected patients with cryoglobulinaemia and progressive loss of kidney function due to MPGN. In one case report a patient with HCV-associated MPGN and progressive renal failure displayed disappearance of serum cryoglobulins and a marked improvement in creatinine clearance with the institution of cyclophosphamide (Quigg et al., 1995). However cyclophosphamide treatment similar to steroids produces a rise in HCV RNA levels.

It is generally agreed that immunosuppressive medications do increase HCV RNA levels but their selective use does not appear to worsen the underlying hepatic disease (D'Amico and Fornaserieri, 2003). A review by D'Amico (1998) reported no evidence of acute liver damage in more than 100 treatment courses (steroids, cyclophosphamide, plasma exchange) in Italian patients with HCV-associated cryoglobulinaemic glomerulonephritis.

The expert consensus currently is that in patients with HCV-associated renal disease, treatment of acute flares does require immunosuppressive therapy to preserve renal function however prolonged therapy does not confer any additional benefit (Campise and Tarantino, 1999).

5.3 Antiviral therapy

Antiviral therapy in the form of alpha interferon was first used in a small pilot study of 7 patients with cryoglobulinaemic vasculitis in 1987, before the discovery of the critical role of HCV in its pathogenesis (Bonomo et al., 1987).

After a link was established between HCV infection and the occurrence of cryoglobulinaemic MPGN, a number of studies have examined the efficacy of antiviral treatment to achieve both sustained virological response (clearance of HCV from the serum for at least 6 months after completing an antiviral course) and to improve renal injury. The use of antiviral therapy in HCV-positive patients with glomerulonephritis is targeted at eliminating the virus and reducing the generation of HCV-related antibodies and immune complexes.

In the early 1990s, standard recombinant alpha interferon (α -IFN) was used by itself. The first prospective randomised controlled trial by Misiani and colleagues (1994) reported that 15 out of 25 patients with HCV-associated type II cryoglobulinaemia receiving recombinant alpha-interferon had a complete clearance of hepatitis C viral RNA and that all these patients reported improvements in cutaneous vasculitis and renal function. There was no effect on proteinuria. Unfortunately after treatment with interferon alpha-2a was discontinued, viraemia and cryoglobulinaemia recurred in all 15 HCV RNA-negative patients.

Johnson and colleagues (1994) reported the results of a prospective uncontrolled trial of fourteen patients receiving interferon alpha for 6 to 12 months. There was a significant reduction in proteinuria but no improvement in renal function. Although a good clinical response correlated with disappearance of HCV RNA from the serum during treatment, relapse of viraemia and renal disease was common after the completion of therapy.

It was clear at this stage that alpha-interferon was useful but the optimal treatment strategy was yet to be defined.

An advance came with the discovery that ribavirin played a synergistic role with an interferon-based regimen to increase the possibility that an on-treatment responder would become a sustained responder. Ribavirin monotherapy itself was found to be disappointing (Pham et al., 1998) although one case report referenced a patient with refractory nephritic syndrome secondary to HCV-associated membranous nephropathy who had a complete remission following the initiation of ribavirin monotherapy (Hu and Jaber, 2005).

Small scale studies examined the combination of standard interferon plus ribavirin for HCV-associated cryoglobulinaemic glomerulonephritis. Rossi and colleagues (2003) treated 3 patients with HCV-associated cryoglobulinaemic glomerulonephritis with standard interferon and ribavirin for 12 months and showed that all had sustained virological response, with reductions in daily proteinuria and rheumatoid factor at the end of follow-up. Bruchel and colleagues (2003) treated 7 patients with HCV and renal insufficiency (2 patients with cryoglobulinaemic vasculitis, 4 patients with MPGN, 1 patient with focal segmental glomerulosclerosis) with a combination of interferon and ribavirin. 4 of the 7 patients had maintained virological and renal remission. The frequency of haematuria and amount of proteinuria decreased after the course of antiviral treatment.

The next important clinical breakthrough was the introduction of a polyethylene glycol side chain (pegylation) to the interferon to give it a much longer bioavailability, allowing for weekly injections rather than three injections per week. Pegylated interferon was shown to double the sustained viral response rate in hepatitis C treatment (Lindsay et al., 2001).

Saadoun and colleagues (2006) carried out a study on 72 consecutive patients with HCV-associated mixed cryoglobulinaemic vasculitis receiving recombinant interferon or pegylated interferon, both in combination with oral ribavirin. A complete clinical response of the cryoglobulinaemic vasculitis occurred in 45 patients, a sustained virologic response occurred in 42 patients, and cryoglobulins cleared in 33 patients. Compared with patients

treated with IFN alpha-2b plus ribavirin, those receiving PEG-IFN alpha-2b plus ribavirin had a higher sustained clinical (67.5% versus 56.3%), virologic (62.5% versus 53.1%), and immunologic (57.5% versus 31.3%) response, regardless of HCV genotype and viral load. Fabrizi and colleagues (2007) then undertook a meta-analysis looking at clinical controlled trials of the 2 treatments (antiviral versus immunosuppressive) for HCV-associated glomerulonephritis. Six studies involving 145 patients with HCV-associated glomerulonephritis were identified (Alric et al., 2004; Beddhu et al., 2002; Johnson et al., 1994; Komatsuda et al., 1996; Mazzaro et al., 2000; Misiani et al., 1994). The primary endpoint was the frequency of patients with significant reduction in proteinuria (return of proteinuria to normal or decrease of >50%) at the conclusion of therapy. It was shown that standard interferon alpha therapy was more effective than immunosuppressive therapy in lowering proteinuria of patients with HCV-associated glomerulonephritis (OR 3.86, 95% CI 1.44-10.33; $P=0.007$). However renal dysfunction was not significantly improved with either therapy (Fabrizi et al., 2007).

This meta-analysis was methodologically flawed by the inclusion of studies where patients received immunosuppressive agents during antiviral treatment, making it difficult to ascertain the effect of each treatment alone.

A later meta-analysis (Feng et al., 2011) examined the results before and after stable regimens of antiviral therapy in subjects with HCV-associated glomerulonephritis and compared the results of those subjects who achieved sustained virological response (SVR) to those that did not. Improvement of proteinuria and serum creatinine levels after antiviral therapy were taken as the end points of interest. Eleven clinical trials involving 225 patients were included in the meta-analysis. At the end of antiviral therapy, the mean decrease in proteinuria was 2.71 g/24 h [95% confidence interval (CI) 1.38-4.04, $P < 0.0001$]. The pooled decrease in mean serum creatinine levels was 0.23 mg/dL (95% CI 0.02-0.44, $P = 0.03$). Comparison of nonsustained virological response (nonSVR) to SVR groups demonstrated a significant mean difference of proteinuria decrease in the SVR group of 1.04 g/24 h (95% CI 0.20-1.89, $P = 0.02$) but the serum creatinine decrease of 0.05 mg/dL was not significant (95% CI -0.33 to 0.43, $P = 0.80$).

A limitation of this meta-analysis is the small number of study subjects making it difficult to perform subgroup analysis on the basis of cryoglobulinaemia or baseline proteinuria. Another weakness is the lack of randomized controlled trials (RCTs) of interferon alpha-based therapy in HCV-associated glomerulonephritis. Indeed only 1 of the 11 studies in this analysis was an RCT (Misiani et al., 1994).

Thus antiviral therapy based on interferon alpha can significantly decrease proteinuria and hence should be undertaken in patients with HCV-associated glomerulonephritis.

It should be acknowledged that currently there are no long-term follow-up studies of antiviral therapy on HCV-associated glomerulonephritis patients. It is important to ascertain whether interferon alpha-based treatments can delay or halt the progression of chronic renal disease in the long term. This will require investment in large RCTs with longer durations of follow-up.

5.4 Rituximab

Treatment with interferon alpha in combination with ribavirin can suppress HCV RNA in 50-60% of patients with a subsequent decrease in cryoglobulins. Many patients however fail to respond to interferon therapy and half the responders relapse.

Rituximab is a monoclonal antibody against the CD20 antigen on the cell surface of B lymphocytes. Rituximab can thus reduce rheumatoid factor-producing B lymphocytes, resulting in a reduction in cryoglobulin production. In recent years the concept of anti-CD20 for mixed-type cryoglobulinaemia has emerged as an effective and safe treatment, inducing a rapid remission of disease activity (Sansonne et al., 2003; Zaja et al., 2003).

One study examined 20 HCV-positive patients with mixed-type cryoglobulinaemia (who were refractory to interferon therapy) that were treated with rituximab 375 mg/m² weekly for 4 weeks (Sansonne et al., 2003). Patients had a follow-up period of 12 months. Sixteen patients (80%) had a complete response defined as a 75% or greater reduction in cryoglobulins and resolution of at least 2 major clinical signs and symptoms. In these patients, rituximab treatment resulted in a reduction in both the IgM and IgG components of the cryoglobulin. Only 1 of the 20 patients had nephritis that did not respond to treatment.

Another study looked at the treatment of 15 patients with rituximab with a follow-up period of 9 to 31 months (Zaja et al., 2003). 12 patients were HCV-infected and 3 patients had mixed cryoglobulinaemia unrelated to HCV. All patients had early improvement in their cutaneous manifestations with rituximab however only 1 patient had complete resolution of the cryoglobulin at 6 months and only 3 lost their rheumatoid factor. It is worthwhile noting that in 7 of 8 patients, maintenance corticosteroids were successfully withdrawn by the second post-treatment month.

Quartuccio and colleagues (2006) carried out a study where 5 patients with HCV-associated mixed cryoglobulinaemia were treated with 4 weekly infusions of rituximab 375mg/m² without accompanying steroids. Renal function improved within 2 months in all 5 cases treated. There were no relevant short-term or delayed side effects reported. However 3 out of 5 patients showed a recurrence of disease at 5, 7 and 12 months. A repeated cycle of rituximab infusion induced rapid remission of disease activity in 2 of these patients. Only one patient achieved persistent remission after a single cycle and thus the results of the study suggest the need for repeated rituximab administrations for adequate control of nephritis. The optimal dosage and frequency of rituximab administrations in HCV-associated mixed cryoglobulinaemia remains unclear as all studies to date have been based on the rituximab prescribing regimen used in non-Hodgkin lymphoma (Coiffier et al., 1998).

6. Renal transplantation and HCV-related renal disease

It should be recognised that the most common cause of proteinuria and renal insufficiency after kidney transplantation in HCV-positive patients is not HCV-related damage but chronic allograft nephropathy (Cosio et al., 1996; Nampoory et al., 2001). Renal diseases that have been reported in HCV-infected patients after kidney transplantation include recurrent or *de novo* MPGN, membranous nephropathy, minimal change disease, thrombotic microangiopathy, acute transplant glomerulopathy, and chronic transplant glomerulopathy (Baid et al., 2000; Cruzado et al., 2001; Gallay et al., 1995; Gloor et al., 2007; Hammoud et al., 1996; Morales et al., 1997; Roth et al., 1995).

MPGN is the most commonly reported, with an incidence as high as 54% in HCV-positive renal transplant recipients (Cruzado et al., 2001; Hammoud et al., 1996; Roth et al., 1995). In these patients proteinuria or nephrotic syndrome is the commonest clinical presentation (Cruzado et al., 2001; Nampoory et al., 2001; Virgilio et al., 2001). Serum cryoglobulins are very often detected (Roth et al., 1995).

Early studies on patient and graft survival in HCV-positive renal transplant recipients have concentrated on recurrent liver disease as causes of morbidity and mortality rather than examining recurrent renal disease or graft loss (Batty et al., 2001; Meier-Kriesche, 2001; Pereira and Levy, 1997). Small single centre studies have shown that both graft and patient survival are lower for HCV-positive than HCV-negative patients (Batty et al., 2001; Pereira and Levy, 1997).

More recently two large population based studies have published long term results of patient and graft survival (Morales et al., 2010; Scott et al., 2010).

The outcomes of a large cohort of renal transplant patients was reviewed recently using the Australian and New Zealand Dialysis and Transplant registry (Scott et al., 2010). Survival outcomes, causes of mortality, and causes of graft failure were examined. 140 (1.8%) patients were HCV antibody positive. Patient survival among HCV antibody positive and HCV antibody negative groups was 77% versus 90% and 50% versus 79% at 5 and 10 years respectively. The adjusted hazard ratio for patient death was 2.38 (95% CI 1.69-3.37). Higher rates of death due to cardiovascular disease (adjusted hazard ratio 2.74), malignancy (adjusted hazard ratio 2.52) and hepatic failure (adjusted hazard ratio 22.1) were observed.

A large national study in Spain used data on 4304 renal transplant recipients, 587 of them with HCV antibody collected over a long period (1990-2002), to estimate graft and patient survival at 4 years (Morales et al., 2010). 4-year graft survival was found to be significantly better in HCV-negative versus HCV-positive patients (94.4% versus 89.5%, $P < 0.005$). Patient survival was 96.3% in the entire group with a demonstrable difference between HCV-negative and HCV-positive patients (96.6% vs 94.5%, $P < 0.05$). HCV-positive patients were characterised as having more episodes of acute rejection, a higher degree of proteinuria with impaired renal function and a greater need for renal graft biopsies. In particular *de novo* glomerulonephritis and transplant glomerulopathy rates in HCV-positive and HCV-negative renal graft biopsies was 9.3% versus 5.2% and 11.4% versus 5.0% respectively.

6.1 Hepatitis C treatment implications in renal transplantation

A meta-analysis of 12 trials of interferon alpha-based therapy in 102 kidney transplant patients showed that sustained virological response is extremely variable ranging from 0-50% with a variable and often extremely high drop-out rate (0% to 100%) (Fabrizi et al., 2006). HCV genotype is an important determinant of sustained virological response with genotype 1 being the most resistant (Lock et al., 1999). Any conferred benefit on the underlying disease is mitigated by a 15-60% increased risk of acute cellular or vascular rejection (Baid et al., 2003; Fabrizi et al., 2006; Weclawiack et al., 2008). Unfortunately graft rejection is often severe and resistant to steroid therapy (Fabrizi et al., 2006).

Cessation of standard interferon therapy leads to a surge in hepatitis C viral load (104,105). Avoidance of interferon in HCV-positive renal transplant patients has been recommended because of the potential to precipitate acute graft rejection. However combined therapy with ribavirin and pegylated interferon achieved sustained virological response in 5 out of 8 patients (62%) without unduly affecting renal function (Montalbano et al., 2007; Mukherjee and Ariyarantha, 2007; Schmitz et al., 2007). This suggests a therapeutic role in certain settings albeit with an appreciable risk of graft dysfunction.

Rituximab appeared to be safe in one study of 7 HCV RNA-positive kidney transplant patients with *de novo* cryoglobulinaemia-related MPGN. HCV infection remained stable

during and after rituximab therapy (Kamar et al., 2007). Larger long-term studies will be necessary to establish efficacy.

7. References

- Ahmed, M.S.; Wong, C.F., Shawki, H., Kapoor, N. and Pandya, B.K. (2008). Rapidly deteriorating renal function with membranoproliferative glomerulonephritis Type 1 associated with hepatitis C treated successfully with steroids and antiviral therapy: a case report and review of literature. *Clin Nephrol*, Vol. 69, No. 4, pp. 298-301.
- Alpers, C.E. and Kowalewska, J. (2007). Emerging paradigms in the renal pathology of viral diseases. *Clin J Am Soc Nephrol*, Vol. 2, Suppl 1, S6-12.
- Alric, L.; Plaisier, E., Thebault, S., Peron, J.M., Rostaing, L. and Pourrat, J. et al. (2004). Influence of antiviral therapy in hepatitis C virus-associated cryoglobulinaemic membranoproliferative glomerulonephritis. *Am J Kidney Dis*, Vol. 43, No. 4, pp. 617-623.
- Baid, S.; Cosimi, A.B., Tolkoff-Rubin, N., Colvin, R.B. Williams, W.W. Jr. and Pascual, M. (2000). Renal disease associated with hepatitis C infection after kidney and liver transplantation. *Transplantation*, Vol. 70, No. 2, pp. 255-261.
- Baid, S.; Tolkoff-Rubin, N., Saidman, S., Chung, R., Williams, W.W., Auchincloss, H. et al. (2003). Acute humoral rejection in hepatitis C infected renal transplant recipients receiving antiviral therapy. *Am J Transplant*, Vol. 3, No. 1, pp. 74-78.
- Batty, D.S. Jr.; Swanson, S.J., Kirk, A.D., Ko, C.W., Agodoa, L.Y., and Abbott, K.C. (2001). Hepatitis C virus seropositivity at the time of renal transplantation in the United States: Associated factors and patient survival. *Am J Transplant*, Vol. 1, No. 2, pp. 179-184.
- Beddhu, S.; Bastacky, S. and Johnson, J.P. (2002). The clinical and morphologic spectrum of renal cryoglobulinemia. *Medicine*, Vol. 81, No.5, pp. 398-409.
- Bonomo, L.; Casato, M., Afeltra, A. and Caccavo, D. (1987). Treatment of idiopathic mixed cryoglobulinemia with alpha interferon. *Am J Med*, Vol. 83, No.4, pp. 726-730.
- Brouet, J.C.; Clauvel, J.P., Danon, F., Klein, M. and Seligmann, M. (1974). Biologic and clinical significance of cryoglobulins. A report of 86 cases. *Am J Med*, Vol. 57, No. 5, pp. 775-88.
- Bruchfeld, A.; Lindahl, K., Stahle, L., Sodeberg, M. and Schvarcz, R. (2003). Interferon and ribavirin treatment in patients with hepatitis C-associated renal disease and renal insufficiency. *Nephrol Dial Transplant*. Vol. 18, No. 8, pp. 1573-1580.
- Campise, M.R. and Tarantino, A. (1999). Glomerulonephritis in mixed cryoglobulinemia: what treatment? *Nephrol Dial Transplant*, Vol. 14, No.2, pp. 281-283.
- Chadban, S.J. and Atkins, R.C. (2005). Glomerulonephritis. *Lancet*, Vol. 365, No. 9473, pp. 1797-1806.
- Coiffier, B.; Haioun, C., Ketterer, N., Engert, A., Tilly, H., Ma, D. et al. (1998). Rituximab (anti-CD20 monoclonal antibody) for the treatment of patients with relapsing or refractory aggressive lymphoma: a multicenter phase II study. *Blood*, Vol. 92, No.6, pp. 1927-32.

- Cosio, F.G.; Roche, Z., Agarwal, A., Falkenhain, M.E., Sedmak, D.D. and Ferguson, R.M. (1996). Prevalence of hepatitis C in patients with idiopathic glomerulopathies in native and transplant kidneys. *Am J Kidney Dis*, Vol. 28, No.5, pp. 752-758.
- Cruzado, J.M.; Carrera, M., Torras, J. and Grinyo, J.M. (2001). Hepatitis C virus infection and de novo glomerular lesions in renal allografts. *Am J Transplant*, Vol.1, No.2, pp. 171-178.
- Dalrymple, L.S.; Koepsell, T., Sampson, J., Louie, T., Dominitz, J.A., Young, B. et al. (2007). Hepatitis C virus infection and the prevalence of renal insufficiency. *Clin J Am Soc Nephrol*, Vol. 2, No.4, pp. 715-721.
- D'Amico, G. (1998). Renal involvement in hepatitis C infection: cryoglobulinemic glomerulonephritis. *Kidney Int*, Vol. 54, No. 2, pp. 650-671.
- D'Amico, G. and Fornasieri, A. (2003). Cryoglobulinemia. In: Brady, H.R. and Wilcox, C.S. eds. *Therapy in Nephrology and Hypertension.*, pp. 147-151, Saunders.
- De Vecchi, A.; Montagnino, G., Pozzi, C., Tarantino, A., Locatelli, F. and Ponticelli, C. (1983). Intravenous methylprednisolone pulse therapy in essential mixed cryoglobulinemia nephropathy. *Clin Nephrol*, Vol 19, No. 5, pp. 221-227.
- Dolganiuc, A.; Oak, S., Kodys, K., Golenbock, D.T., Finberg, R.W., Kurt-Jones, E. et al. (2004). Hepatitis C core and nonstructural 3 proteins trigger toll-like receptor 2-mediated pathways and inflammatory activation. *Gastroenterology*, Vol. 127, No. 5, pp. 1513-24.
- Fabrizi, F.; Lunghi, G., Dixit, V. and Martin, P. (2006). Meta-analysis: anti-viral therapy of hepatitis C virus-related liver disease in renal transplant patients. *Aliment Pharmacol Ther*, Vol. 24. No. 10, pp. 1413-1422.
- Fabrizi, F., Bruchfeld, A., Mangano, S., Dixit, V., Messa, P. and Martin, P. (2007). Interferon therapy for HCV associated glomerulonephritis: meta-analysis of controlled trials. *Int J Artif Organs*, Vol. 30, No.3, pp. 212-219.
- Feng, B.; Eknayan, G., Guo, Z., Jadoul, M., Rao, H., Zhang, W. et al. (2011). Effect of interferon-alpha-based antiviral therapy on hepatitis C virus-associated glomerulonephritis: a meta-analysis. *Nephrol. Dial. Transplant*, May 10. [Epub ahead of print]
- Ferri, C.; Zignego, A.L. and Pileri, S.A. (2002). Cryoglobulins. *J Clin Pathol*, Vol. 55, No. 1, pp. 4-13.
- Fong, T.L.; Valinluck, B., Govindarajan, S., Charboneau, F., Adkins, R.H. and Redeker, A.G. (1994). Short-term prednisone therapy affects aminotransferase activity and hepatitis C virus RNA levels in chronic hepatitis C. *Gastroenterology*, Vol. 107, No.1, pp. 196-199.
- Gallay, B.J.; Alpers, C.E., Davis, C.L., Schultz, M.F. and Johnson, R.J. (1995). Glomerulonephritis in renal allografts associated with hepatitis C infection: A possible relationship with transplant glomerulopathy in two cases. *Am J Kidney Dis*, Vol. 26, No.4, pp. 662-667.
- Gloor, J.; Sethi, S., Stegall, M.D., Park, W.D., Moore, S.B., DeGoey, S. et al. (2007). Transplant glomerulopathy subclinical incidence and association with alloantibody. *Am J Transplant*, Vol. 7, No.9, pp. 2124-2132.

- Hammoud, H.; Haem, J.; Laurent, B., Alamartine, E., Diab, N., Defilippis, J.P. et al. (1996). Glomerular disease during HCV infection in renal transplantation. *Nephrol Dial Transplant*, Vol. 11, Suppl 4, S54-S55.
- Herzenberg, A.M.; Telford, J.J., De Luca, L.G., Holden, J.K. and Magil, A.B. (1998). Thrombotic microangiopathy associated with cryoglobulinemic membranoproliferative glomerulonephritis and hepatitis C. *Am J Kidney Dis*, Vol. 31, No. 3, pp. 521-6.
- Hu, S.L. and Jaber, B.L. (2005). Ribavirin monotherapy for hepatitis C virus-associated membranous nephropathy. *Clin Nephrol*, Vol. 63, No. 1, pp. 41-45.
- Iskandar, S.S. and Herrera, G.A. (2002). Glomerulopathies with organized deposits. *Semin Diagn Pathol*, Vol. 19, No. 3, pp. 116-32.
- Johnson, R.J.; Gretch, D.R., Yamabe, H., Hart, J., Bacchi, C.E., Hartwell, P. et al. (1993). Membranoproliferative glomerulonephritis associated with hepatitis C virus infection *N Engl J Med*, Vol. 328, No. 7, pp. 465-470.
- Johnson, R.J.; Gretch, D.R., Couser, W.G., Alpers, C.E., Wilson, J., Chung, M. et al. (1994). Hepatitis C virus-associated glomerulonephritis. Effect of alpha-interferon therapy. *Kidney Int*, Vol. 46, No. 6, pp. 1700-1704.
- Kamar, N.; Sandres-Saune, K. and Rostaing, L. (2007). Influence of rituximab therapy on hepatitis C virus RNA concentration in kidney-transplant patients. *Am J Transplant*, Vol. 7, No. 10, pp. 2440.
- Kamar, N.; Izopet, J., Alric, L., Guilbeaud-Frugier, C. and Rostaing, L. (2008). Hepatitis C virus-related kidney disease: an overview. *Clin Nephrol*, Vol. 69, No. 3, pp. 149-60.
- Komatsuda, A.; Imai, H., Wakui, H., Hamai, K., Ohtani, H., Kodama, T. et al. (1996). Clinicopathological Analysis and Therapy in Hepatitis C Virus-Associated Nephropathy. *Internal Medicine*, Vol.35, No.7 pp. 529-533.
- Kristiansen, M.G.; Gutteberg, T.J., Mortensen, L., Berg, L.K., Goll, R. and Florholmen, J. (2010). Clinical outcomes in a prospective study of community-acquired hepatitis C virus infection in Northern Norway. *Scand J Gastroenterol*, Vol. 45, No. 6, pp. 746-51.
- Lake, J.R. (2003). The role of immunosuppression in recurrence of hepatitis C. *Liver Transpl*, Vol. 9, Suppl 3, S63-S66.
- Lamprecht, P.; Gause, A. and Gross, W.L. (1999). Cryoglobulinemic vasculitis. *Arthritis Rheum*, Vol. 42, No. 12, pp. 2507-2516.
- Lindsay, K.L.; Trepo, C., Heintges, T., Shiffman, ML., Gordon, SC., Hoefs, J.C. et al. (2001). A randomized, double-blind trial comparing pegylated interferon alfa-2b to interferon alfa-2b as initial treatment for chronic hepatitis C. *Hepatology*, Vol. 34, No. 2, pp. 395-403.
- Lock, G.; Reng, C.M., Graeb, C., Anthuber, M. and Wiedmann, K.H. (1999). Interferon-induced hepatic failure in a patient with hepatitis C. *Am J Gastroenterol*, Vol. 94, No. 9, pp. 2570-2571.
- Markowitz, G.S.; Cheng, J.T., Colvin, R.B., Trebbin, W.M. and D'Agati, V.D. (1998). Hepatitis C viral infection is associated with fibrillary glomerulonephritis and immunotactoid glomerulopathy. *J Am Soc Nephrol*, Vol 9, No. 12, pp. 2244-52.

- Mazzaro, C.; Panarello, G., Carniello, S., Faelli, A., Mazzi, G., Crovatto, M. et al. (2000). Interferon versus steroids in patients with hepatitis C virus-associated cryoglobulinaemic glomerulonephritis. *Digest Liver Dis*, Vol. 32, No. 8, pp. 708-715.
- McGuire, B.M.; Julian, B.A., Bynon, J.S., Cook, W.S., King, S.J., Curtis, J.J. et al. (2006). Brief communication: Glomerulonephritis in patients with hepatitis C cirrhosis undergoing liver transplantation. *Ann Intern Med*, Vol. 144, No.10, pp. 735-741.
- McHutchison, J.G.; Wilkes, L.B., Pockros, P.J., Chan, C.S., Neuwald, P., Urdea, M. et al. (1993). Pulse corticosteroid therapy increases viremia in patients with chronic HCV infection. *Hepatology*, Vol. 18, 87A.
- Meier-Kriesche, H.U.; Ojo, A.O., Hanson, J.A. and Kaplan, B. (2001). Hepatitis C antibody status and outcomes in renal transplant recipients. *Transplantation*, Vol. 72, pp. 241-244.
- Merkle, M.; Ribeiro, A. and Wörnle, M. (2011). TLR3 dependent regulation of cytokines in human mesangial cells: a novel role for IP-10 and TNF α in hepatitis C associated glomerulonephritis. *Am J Physiol Renal Physiol*, Mar 30. [Epub ahead of print]
- Meyers, C.M.; Seeff, L.B., Stehman-Breen, C.O. and Hoofnagle, J.H. (2003). Hepatitis C and renal disease: an update. *Am J Kidney Dis*, Vol 42, No. 4, pp. 631-57.
- Miller, S.E. and Howell, D.N. (2000). Glomerular diseases associated with hepatitis C virus infection. *Saudi J Kidney Dis Transpl*, Vol. 11, No. 2, pp. 145-60.
- Misiani, R.; Bellavita, P., Fenili, D., Vicari, O., Marchesi, D., Sironi, P.L. et al. (1994). Interferon alfa-2a therapy in cryoglobulinemia associated with hepatitis C virus. *N Engl J Med*, Vol. 330, No. 11, pp. 751-756.
- Montalbano, M.; Pasulo, L., Sonzogni, A., Remuzzi, G., Colledan, M. and Strazzabosco, M. (2007). Treatment with pegylated interferon and ribavirin for hepatitis C virus-associated severe cryoglobulinemia in a liver/kidney transplant recipient. *J Clin Gastroenterol*, Vol. 41, No. 2, pp. 216-220.
- Monti, G.; Galli, M., Invernizzi, F., Pioltelli, P., Saccardo, F., Monteverde, A. et al. (1995). Cryoglobulinaemias: A multi-centre study of the early clinical and laboratory manifestations of primary and secondary disease. Italian Group for the Study of Cryoglobulinaemias. *QJM*, Vol. 88, No.2, pp. 115-126.
- Morales, J.M.; Pascual-Capdevila, J., Campistol, J.M., Fernandez-Zatarain, G., Muñoz, M.A. Andres, A. et al. (1997). Membranous glomerulonephritis associated with hepatitis C virus infection in renal transplant patients. *Transplantation*, Vol. 63, No.11, pp. 1634-1639.
- Morales, J.M.; Marcén, R., Andres, A., Domínguez-Gil, B., Campistol, J.M., Gallego, R. et al. (2010). Renal transplantation in patients with hepatitis C virus antibody. A long national experience. *NDT Plus*, Vol. 3, Suppl 2, ii41-ii46.
- Mukherjee, S. and Ariyarantha, K. Successful hepatitis C eradication with preservation of renal function in a liver/kidney transplant recipient using pegylated interferon and ribavirin. (2007). *Transplantation*, Vol. 84, No. 10, pp. 1374-1375.
- Nampoory, M.R.; Johny, K.V., Costandi, J.N., Said, T., Abraham, M., Gupta, R.K. et al. (2001). High incidence of proteinuria in hepatitis C virus-infected renal transplant recipients is associated with poor patient and graft outcome. *Transplant Proc*, Vol. 33, No. 5, pp. 2791-2795.

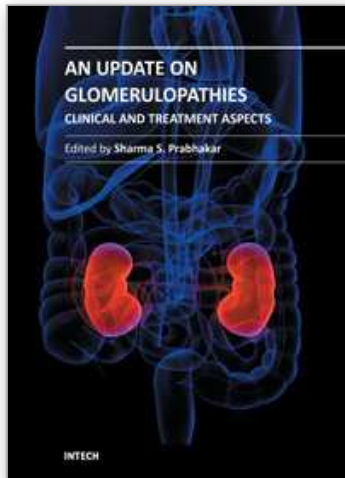
- Okada, K.; Takishita, Y., Shimomura, H., Tsuji, T., Miyamura, T., Kuhara, T. et al. (1996). Detection of hepatitis C virus core protein in the glomeruli of patients with membranous glomerulonephritis. *Clin Nephrol*, Vol. 45, No. 2, pp. 71-6.
- Pereira, B.J. and Levey, A.S. (1997). Hepatitis C virus infection in dialysis and renal transplantation. *Kidney Int*, Vol. 51, No.4, pp. 981-999.
- Perico, N.; Cattaneo, D., Bikbov, B. and Remuzzi, G. (2009). Hepatitis C infection and chronic renal diseases. *Clin J Am Soc Nephrol*, Vol. 4, No. 1, pp. 207-20.
- Pham, H.P. ; Feray, C., Samuel, D., Gigou, M., Azoulay, D., Paradis, V. et al. (1998). Effects of ribavirin on hepatitis C-associated nephrotic syndrome in four liver transplant recipients. *Kidney Int*, Vol. 54, No. 4, pp. 1311-1319.
- Ponticelli, C.; Montagnino, G., Campise, M.R., Baldassari, A. and Tarantino, A. (1986). Treatment of renal disease in essential mixed cryoglobulinemia. In: Minetti, L. and D'Amico, G. eds. *Antiglobulins, cryoglobulins, and glomerulonephritis.*, pp. 265-272, Martinus Nijhoff.
- Quartuccio, L.; Soardo, G., Romano, G., Zaja, F., Scott, C.A., De Marche, G. et al. (2006). Rituximab treatment for glomerulonephritis in HCV-associated mixed cryoglobulinemia: efficacy and safety in the absence of steroids. *Rheumatology*, Vol. 45, No. 7, pp. 842-6.
- Quigg, R.J.; Brathwaite, M., Gardner, D.F., Gretch, D.R. and Ruddy, S. (1995). Successful cyclophosphamide treatment of cryoglobulinemic membranoproliferative glomerulonephritis associated with hepatitis C virus infection. *Am J Kidney Dis*, Vol. 25, No.5, pp. 798-800.
- Rossi, P. ; Bertani, T., Baio, P., Caldara, R., Luliri, P., Tengattini, F. et al. (2003). Hepatitis C virus-related cryoglobulinemic glomerulonephritis: long-term remission after antiviral therapy. *Kidney Int*. Vol. 63, No. 6, pp. 2236-2241.
- Roth, D.; Cirocco, R., Zucker, K., Ruiz, P., Viciana, A., Burke, G. et al. (1995). De novo membranoproliferative glomerulonephritis in hepatitis C virus-infected renal allograft recipients. *Transplantation*, Vol. 59, No. 12, pp. 1676-1682.
- Ruggenenti, P.; Schieppati, A. and Remuzzi, G. (2001). Progression, remission, regression of chronic renal diseases. *Lancet*, Vol. 357, No. 9268, pp. 1601-1608.
- Ruggenenti, P.; Fassi, A., Ilieva, A.P., Bruno, S., Iliev, I.P., Brusegan, V. et al. (2004). Bergamo Nephrologic Diabetes Complications Trial (BENEDICT) Investigators: Preventing microalbuminuria in type 2 diabetes. *N Engl J Med*, Vol. 351, No.19, pp. 1941-1951.
- Saadoun, P.; Resche-Rigon, M., Thibault, V., Piette, K.C. and Cacoub, P. (2006). Antiviral therapy for hepatitis C virus-associated mixed cryoglobulinemia vasculitis. *Arthritis Rheum*. Vol. 54, No. 11, pp. 3696-3706.
- Sabry, A.A.; Sobh, M.A., Irving, W.L., Grabowska, A., Wagner, B.E., Fox, S. et al. (2002). A comprehensive study of the association between hepatitis C virus and glomerulopathy. *Nephrol Dial Transplant*, Vol. 17, No. 2, pp. 239-45.
- Sansonno, D.; De Re, V., Lauletta, G., Tucci, F.A., Boiocchi, M. and Dammacco, F. (2003). Monoclonal antibody treatment of mixed cryoglobulinaemia resistant to interferon alfa with an anti-CD20. *Blood* Vol. 101, No. 10, pp. 3818-26.
- Sansonno, D.; Lauletta, G., Montrone, M., Grandaliano, G., Schena, F.P. and Dammacco, F. (2005). Hepatitis C virus RNA and core protein in kidney glomerular and tubular

- structures isolated with laser capture microdissection. *Clin Exp Immunol*, Vol. 140, No. 3, pp. 498-506.
- Schmitz, V.; Kiessling, A., Bahra, M., Puhl, G., Kahl, A., Berg, T. et al. (2007). Peginterferon alfa-2b plus ribavirin for the treatment of hepatitis C recurrence following combined liver and kidney transplantation. *Ann Transplant*, Vol. 12, No.3, pp. 22-27.
- Scott, D.R.; Wong, J.K., Spicer, T.S., Dent, H., Mensah, F.K., McDonald, S. et al. (2010). Adverse impact of hepatitis C virus infection on renal replacement therapy and renal transplant patients in Australia and New Zealand. *Transplantation*, Vol. 90, No. 11, pp. 1165-71.
- Stehman-Breen, C.; Alpers, C.E., Fleet, W.P. and Johnson, R.J. (1999). Focal segmental glomerular sclerosis among patients infected with hepatitis C virus. *Nephron*, Vol. 81, No. 1, pp. 37-40.
- Tarantino, A.; De Vecchi, A., Montagnino, G., Imbasciati, E., Mihatsch, M.J. Zollinger, H.U. et al. (1981). Renal disease in essential mixed cryoglobulinemia nephropathy. *Q J Med*, Vol.50, No. 197, pp. 1-30.
- Tarantino, A.; Campise, M., Banfi, G., Confalonieri, R., Bucci, A., Montoli, A. et al. (1995). Long-term predictors of survival in essential mixed cryoglobulinemic glomerulonephritis. *Kidney Int*, Vol. 47, No. 2, pp. 618-623.
- Tsui, J.I.; Vittinghoff, E., Shlipak, M.G., Bertenthal, D., Inadomi, J., Rodriguez, R.A. et al. (2007). Association of hepatitis C seropositivity with increased risk for developing end-stage renal disease. *Arch Intern Med*, Vol. 167, No.12, pp. 1271-1276.
- Uchiyama-Tanaka, Y.; Mori, Y., Kishimoto, N., Nose, A., Kijima, Y., Nagata, T. et al. (2004). Membranous glomerulonephritis associated with hepatitis C virus infection: case report and literature review. *Clin Nephrol*, Vol. 61, No. 2, pp. 144-50.
- Usalan, C.; Erdem, Y., Altun, B., Nar, A., Yasavul, U, Turgan, C. et al. (1998). Rapidly progressive glomerulonephritis associated with hepatitis C virus infection. *Clin Nephrol*, Vol. 49, No. 2, pp. 129-31.
- Virgilio, B.; Palminteri, G., Maresca, M.C., Brunello, A., Calconi, G. and Vianello, A. (2001). Proteinuria at five years after kidney transplantation: The role of anti-HCV-positive state. *Transplant Proc*, Vol. 33, No. 7-8, pp. 3639-3640.
- Weclawiack, H.; Kamar, N., Mehrenberger, M., Guilbeau-Frugier, C., Modesto, A., Izopet, J. et al. (2008). Alpha-interferon therapy for chronic hepatitis C may induce acute allograft rejection in kidney transplant patients with failed allografts. *Nephrol Dial Transplant*, Vol. 23. No. 3, pp. 1043-1047.
- WHO Health Organization. Weekly Epidemiological Record. No. 49,10 December 1999, WHO; Hepatitis C fact sheet N0. 164, October 2000 <http://www.who.int/inf-fs/en/fact164.html> (May 2011, date last accessed)
- Wörnle, M.; Schmid, H., Banas, B., Merkle, M., Henger, A., Roeder, M. et al. (2006). Novel role of toll-like receptor 3 in hepatitis C-associated glomerulonephritis. *Am J Pathol*, Vol. 168, No. 2, pp. 370-85.
- Yamabe, H.; Johnson, R.J., Gretch, D.R., Fukushi, K., Osawa, H., Miyata, M. et al. (1995). Hepatitis C virus infection and membranoproliferative glomerulonephritis in Japan. *J Am Soc Nephrol*, Vol. 6, No. 2, pp. 220-23.

- Yamabe, H.; Nakamura, N., Shimada, M., Murakami, R., Fujita, T., Shimaya, Y. et al. (2010). Clinicopathological Study on Hepatitis C Virus-associated Glomerulonephritis without Hepatitis C Virus in the Blood. *Inter Med*, Vol. 49, No. 14, pp. 1321-1323.
- Zaja, F.; De Vita, S., Mazzaro, C., Sacco, S., Damiani, D., De Marchi, G. et al. (2003). Efficacy and safety of rituximab in type II mixed cryoglobulinaemia. *Blood*, Vol. 101, No.10, pp. 3827-34.

IntechOpen

IntechOpen



An Update on Glomerulopathies - Clinical and Treatment Aspects

Edited by Prof. Sharma Prabhakar

ISBN 978-953-307-673-7

Hard cover, 468 pages

Publisher InTech

Published online 02, November, 2011

Published in print edition November, 2011

An Update on Glomerulopathies - Clinical and Treatment Aspects is a systemic overview of recent advances in clinical aspects and therapeutic options in major syndromes of glomerular pathology. The book contains twenty four chapters divided conveniently into five sections. The first section deals with primary glomerulopathies, and the second section is devoted to glomerulopathies complicating infectious conditions. The third section deals with systemic autoimmune disorders and vasculitides which constitute major causes of glomerular disease and often renal failure. The fourth section includes chapters discussing the glomerular involvement in some major metabolic and systemic conditions. The final section has chapters which relate to some general aspects of glomerular diseases. This book will form an excellent reference tool for practicing and academic nephrology community.

How to reference

In order to correctly reference this scholarly work, feel free to copy and paste the following:

Vincent Ho and Jason Chen (2011). Hepatitis C Virus Associated Glomerulonephritis, An Update on Glomerulopathies - Clinical and Treatment Aspects, Prof. Sharma Prabhakar (Ed.), ISBN: 978-953-307-673-7, InTech, Available from: <http://www.intechopen.com/books/an-update-on-glomerulopathies-clinical-and-treatment-aspects/hepatitis-c-virus-associated-glomerulonephritis>

INTECH
open science | open minds

InTech Europe

University Campus STeP Ri
Slavka Krautzeka 83/A
51000 Rijeka, Croatia
Phone: +385 (51) 770 447
Fax: +385 (51) 686 166
www.intechopen.com

InTech China

Unit 405, Office Block, Hotel Equatorial Shanghai
No.65, Yan An Road (West), Shanghai, 200040, China
中国上海市延安西路65号上海国际贵都大饭店办公楼405单元
Phone: +86-21-62489820
Fax: +86-21-62489821

© 2011 The Author(s). Licensee IntechOpen. This is an open access article distributed under the terms of the [Creative Commons Attribution 3.0 License](#), which permits unrestricted use, distribution, and reproduction in any medium, provided the original work is properly cited.

IntechOpen

IntechOpen