

We are IntechOpen, the world's leading publisher of Open Access books Built by scientists, for scientists

4,800

Open access books available

122,000

International authors and editors

135M

Downloads

Our authors are among the

154

Countries delivered to

TOP 1%

most cited scientists

12.2%

Contributors from top 500 universities



WEB OF SCIENCE™

Selection of our books indexed in the Book Citation Index
in Web of Science™ Core Collection (BKCI)

Interested in publishing with us?
Contact book.department@intechopen.com

Numbers displayed above are based on latest data collected.

For more information visit www.intechopen.com



Membranous Nephropathy

Abdelaziz Elsanjak and Sharma S. Prabhakar
Department of Medicine, Texas Tech University Health Sciences Center
USA

1. Introduction

Membranous nephropathy (MN), a very common cause of nephrotic syndrome, is a glomerulopathy defined histopathologically by the presence of immune complexes on the extracapillary side of the glomerular basement membrane (GBM). Idiopathic membranous nephropathy (IMN) is an antibody-mediated glomerular disease with no defined etiology, histologically characterized by uniform thickening of glomerular basement membrane (GBM), caused by subepithelial immune complex deposits. Most cases of MN are idiopathic, for instance approximately 75% of the cases of MN in developed countries are idiopathic, or primary membranous nephropathy (IMN). MN can be secondary to a wide spectrum of infections, tumors, autoimmune diseases or exposure to drugs or toxic agents. Examples include systemic lupus erythematosus, hepatitis B antigenemia or other chronic infections, and historically graft vs. host disease, sickle cell anemia, a number of drugs and toxins such as therapeutic gold salts, penicillamine, tumors, and agents containing mercury

Idiopathic MN is a glomerulus-specific autoimmune disease and second only to focal glomerulosclerosis, is a leading primary cause of the nephrotic syndrome in adults. The name, '*membranous nephropathy*' reflects the pathological observation in light microscopy of thickening in the GBM between and around immune deposits that occur beneath the podocyte foot processes. The histological hallmarks of the disease were first described by Jones and Mellors and Ortega' over 60 years ago. These include "spikes," stained by methenamine silver, of normal GBM that extend between the immune deposits, a fine granular distribution of immunoglobulin (Ig) G and the complement component C3 in a capillary-loop pattern revealed by immunofluorescence, and the presence of electron-dense subepithelial immune deposits indicated by electron microscopy (EM). Idiopathic MN most commonly occurs in patients between the ages of 30 and 60 years, with men twice as likely to be affected as women. However, MN does occur in children as well as in the very elderly. Up to 70% of patients present with the nephrotic syndrome and the others garner clinical attention due to abnormalities in urine sediment such as proteinuria. Microscopic hematuria is observed in up to 50% of cases although red cell casts are rare. Hypertension and impaired renal function are uncommon at the outset of the disease and are more likely to occur with disease progression

2. Pathogenesis

Idiopathic membranous nephropathy (IMN) is an antibody-mediated glomerular disease that is histologically characterized by uniform thickening of glomerular basement membrane (GBM), caused by subepithelial immune complex deposits. The immune

deposits consist of IgG, mainly IgG4 and IgG1 of antigens that have long escaped identification, and the membrane attack complex of complement C5b-9 (MAC). The formation of subepithelial immune deposits and complement activation are responsible for functional impairment of the glomerular capillary wall, causing proteinuria. Most data on the pathogenesis of MN comes from an animal model, the Heymann model of experimental MN in rats, which suggests that the podocyte is the target of injury. Studies show that there is in-situ binding of a circulating antibody to antigen in the subepithelial space. In the Heymann nephritis model, megalin was identified as the antigenic target. However, megalin, which is a member of the low-density lipoprotein receptor family and is expressed with clathrin at the base of podocyte foot processes (the site of immune complex formation) in rats, is an unlikely antigen for human MN.

In Heymann nephritis model of MN, rats are immunized against an antigenic fraction derived from rat proximal tubular brush border and develop subepithelial deposits virtually identical to those observed in human disease. The target antigen is a large transmembrane endocytic receptor known as megalin. In the rat (but not in human beings) megalin is additionally present on the foot processes of podocytes, allowing circulating antimegaline antibodies to cross the GBM, bind megalin at the podocyte cell surface, and ultimately form subepithelial immune deposits in situ. Complement, activated by the immune deposits, leads to insertion of the terminal complement components C5b-9 (the membrane attack complex) into the podocyte cell membrane, causing cell injury, effacement of the foot processes, and proteinuria.

In 2002, Debiec and Ronco identified neutral endopeptidase (NEP) as the responsible antigen in a rare subset of patients with alloimmune antenatal membranous nephropathy. This discovery supplied proof of concept that a human podocyte antigen could serve as a target for nephritogenic antibodies, as shown some 20 years earlier for the rat podocyte megalin in Heymann nephritis, the well established experimental model of membranous nephropathy.

Debiec and Ronco studied the development of neonatal MN in infants born of mothers genetically lacking neutral endopeptidase (NEP), a membrane-associated podocyte antigen that digests peptides. Because the fetus did not lack NEP, fetomaternal alloimmunization occurred and anti-NEP antibodies (often in very high titers) developed in the mothers. These antibodies (often of the IgG4 or IgG1 subclasses, similar to human idiopathic MN) crossed the placental barrier and interacted with the NEP, heavily expressed on the normal fetal podocyte. In situ immune complexes (containing both IgG1 and IgG4) developed in the newborn infant (or soon after birth) and typical MN ensued, along with proteinuria and nephrotic syndrome. The finding of the C5b-C9 membrane attack complex in the deposits, suggesting that this spontaneous human alloimmune disease also might be complement-dependent, was similar to what had been proposed for Heymann nephritis.

In 2009 Beck and et al identified circulating autoantibodies reactive with the transmembrane glycoprotein M-type phospholipase A2 receptor (PLA2R) in the majority of cases of adult IMN. This protein is expressed by the human podocyte, again suggesting a mechanism of disease that fits the paradigm established in Heymann nephritis. These anti-PLA2R autoantibodies were highly specific for IMN, and were not present in normal individuals, in patients with other causes of the nephrotic syndrome, or in cases of secondary MN. Levels of circulating anti- PLA2R antibodies parallel the course of clinical disease, declining or disappearing before a partial or complete remission of proteinuria, and reappearing with recurrence of nephrotic syndrome.

T cells play a significant role in the pathogenesis. The presence of IgG4, which is a product of the type 2 response T helper cells (Th2) and an upregulation of cytokines, such as interleukins (IL) -4 and -10, suggest Th2 involvement. This CD4, T-cell dependent humoral response leads to subsequent Ig deposition and complement activation.

More recently Stanescu et al (2011) performed independent genome-wide association studies of single-nucleotide polymorphisms (SNPs) in patients with idiopathic membranous nephropathy from three populations of white ancestry (75 French, 146 Dutch, and 335 British patients). The patients were compared with racially matched control subjects; population stratification and quality controls were carried out according to standard criteria. In a joint analysis of data from the 556 patients studied (398 men), they identified significant alleles at two genomic loci associated with idiopathic membranous nephropathy. Chromosome 2q24 contains the gene encoding M-type phospholipase A₂ receptor (PLA₂R1) (SNP rs4664308, $P=8.6\times 10^{-29}$), previously shown to be the target of an autoimmune response. Chromosome 6p21 contains the gene encoding HLA complex class II HLA-DQ alpha chain 1 (HLA-DQA1) (SNP rs2187668, $P=8.0\times 10^{-93}$). The association with HLA-DQA1 was significant in all three populations ($P=1.8\times 10^{-9}$, $P=5.6\times 10^{-27}$, and $P=5.2\times 10^{-36}$ in the French, Dutch, and British groups, respectively). The odds ratio for idiopathic membranous nephropathy with homozygosity for both risk alleles was 78.5 (95% confidence interval, 34.6 to 178.2). They concluded that an HLA-DQA1 allele on chromosome 6p21 is most closely associated with idiopathic membranous nephropathy in persons of white ancestry. This allele may facilitate an autoimmune response against targets such as variants of *PLA2R1*, findings which suggest a basis for understanding this disease and illuminate how adaptive immunity is regulated by HLA.

2.1 Natural history and prognosis of idiopathic MN

MN is a chronic disease, with spontaneous remission and relapses. In the United States and Europe, MN remains the second or third leading cause of ESRD among the primary glomerulonephritis types. Spontaneous remissions occur in up to 30% of cases and usually occur within the first 2 yrs after presentation. The percentage of patients going into spontaneous remission is much lower in patients with higher grades of proteinuria at presentation (*e.g.*, proteinuria >8 g/24 h). The remaining two thirds are divided into those with persistent proteinuria who maintain renal function long term, or who progress to renal failure. In white patients with NS, 10-yr kidney survival of 70% has been reported. Although the percentage of the IMGN population that progresses to end-stage renal failure remains relatively small, the absolute numbers are large. It affects people predominantly in their 30s and 40s, and has an enormous long-term impact on their quality of life and productivity. Because they have single-organ disease rather than multisystem organ failure (as is seen in diabetes), they survive longer on dialysis and after renal transplantation. However, even though these patients survive longer, they continue to function at a lower level in comparison with the age and gender matched normal population, and rarely returns to the same level of productivity or quality of life as their peers. Even in patients who do not progress to ESRD, complications often occur, including life-threatening thromboembolic phenomena and accelerated vascular disease. These may be due to an underlying specific defect in coagulation and/or tissue repair and/or the long-term sequelae of their prolonged nephrotic condition.

Today, once the diagnosis is made, the management of edema, BP, and hyperlipidemia is effective in almost all IMGN patients. The impact of the control of these factors alone on the

natural history is expected to be positive but is currently unknown. This is partly due to the unusual phenomena of up to 30% of IMGN patients experiencing spontaneous remission. This wide variation in outcome is one of the factors that has led meta-analysis and systematic reviews of this disease to reach varying conclusions about the impact of immunosuppressive treatment on patient and renal survival and on proteinuria remission rates.

Female gender and low grade proteinuria is associated with good prognosis and associated with spontaneous remission. End-stage renal disease occurs at a 2-3:1 male:female ratio. Also, Asians with IMN appear to have a more favorable long-term prognosis than their non-Asian counterparts.

The Toronto Glomerulonephritis Registry created a model for identifying patients at risk for progression of renal insufficiency, taking into account the initial creatinine clearance (CrCl), the slope of the CrCl, and the lowest amount of proteinuria during a 6-month period. According to this model, patients who present with a normal CrCl (proteinuria <4 g/24 h), and stable renal function over 6 months are considered to be at low risk for progression. On the other hand, patients with persistent proteinuria (>8 g/24 h) have a 66–80% probability of progression to ESRD within 10 years, independent of the degree of renal dysfunction. Other factors associated with poor prognosis include older age, tubular interstitial changes on kidney biopsy and a high degree of glomerulosclerosis.

2.2 Clinical manifestations

MN affects patients of all ages and races, but is generally more common in men than women. It most commonly occurs in middle age, with peak incidence between the ages of 40-60. In contrast to primary MN, secondary forms of MN are most commonly encountered in young children and in individuals who are older than 60. At presentation, 60-70% of patients have nephrotic syndrome with the remaining 30-40% of patients presenting with subnephrotic range proteinuria (<3.5 g/24 h). 60 % of patients who present with subnephrotic range proteinuria will progress to full nephrotic syndrome in 1-2 years (Daniel Cattran 2006). Microscopic hematuria is common in MN (30 to 40%), but macroscopic hematuria and red cell casts are rare and should suggest other diagnoses. The majority of patients with MN are normotensive at presentation, however hypertension is present in 10-20 % of patients. Less than 20% present with renal insufficiency.

Serologic evaluation of all patients with MN should include anti-nuclear antibody HbsAg and hepatitis C virus antibody studies. Workup for malignancy is also warranted, to the extent that testing should be guided by the patient's age and whether there is a history of tobacco use.

2.3 Primary (idiopathic) vs. secondary forms of membranous nephropathy

In developed countries, MN is primarily idiopathic, implying that known secondary causes have been effectively ruled out. Secondary forms of MN have been linked to multiple different agents and conditions. MN occurring post-hematopoietic stem cell transplantation (HSCT) may be a humoral manifestation of chronic graft-versus-host disease; it is the most common cause of post-HSCT nephrotic syndrome, and like idiopathic, post-HSCT MN disproportionately affects males. MN may recur in up to 42% of renal allografts with slowly progressive proteinuria; it is also possible for *de novo* MN to occur, perhaps as an alloimmune reactivation to minor histocompatibility antigens on the allograft podocytes.

Finally, MN may briefly occur early in infancy as a result of feto-maternal alloimmunization. Idiopathic MN must be distinguished from the various secondary causes, since treating or eliminating those underlying conditions are often sufficient to cause nephrotic syndrome remission.

The most common secondary form of MN in the United States (US) is membranous lupus nephritis (LN), designated class V LN by the International Society of Nephrology-Renal Pathology Society, and is seen in ~10%-20% of LN cases (picture of LMN). The disease may occur in isolation and pre-date other symptoms or serological abnormalities suggestive of lupus. Thus, even in the absence of positive serological markers such as antinuclear antibodies (ANAs), membranous LN should remain a possibility in any young woman with a biopsy diagnosis of MN. Features that distinguish idiopathic MN from membranous LN and other secondary forms of MN include the glomerular location of the immune deposits, the predominance of a particular IgG subclass, and other pathological features. Clues to the diagnosis of membranous LN include the presence of subendothelial and mesangial deposits, in addition to the predominant subepithelial deposits, and a "full house" pattern of staining for IgG, IgA, IgM, C3, and C1q on immunofluorescence. In idiopathic MN the predominant IgG subclass found in the glomerular deposits is IgG4, whereas in many secondary forms, IgG1, IgG2, and IgG3 predominate. Finally, an ultrastructural finding of tubuloreticular structures in the glomerular endothelium suggests lupus, although these structures can also be found in other non-idiopathic forms of MN.

Currently, renal biopsy is the sole means for diagnosis of MN and distinguishing it from other causes of nephrotic syndrome. The results of routine serological studies, including complement levels, are all normal in idiopathic MN. Possibly, antibodies to the human phospholipase A2 receptor (PLA2R) found in many patients with idiopathic MN may allow a serological diagnosis of MN, but this test is only available in research settings. Secondary causes of MN may be suggested by the presence of ANA, hepatitis B virus (HBV)-antigenemia, or concurrent infection with schistosomiasis or secondary syphilis. Hypocomplementemia may occur in lupus or HBV-associated MN, but normal complement levels do not rule out these diagnoses. Associations of MN with malignancy have been found in older individuals seemingly more frequent than chance. Therefore, in older individuals with newly diagnosed MN, tests to exclude malignancy is reasonable.

A number of secondary processes can also cause MN that are clinically and histologically similar to IMN. Worldwide, chronic infections such as hepatitis B, malaria, syphilis, and schistosomiasis are the most important causes of secondary MN. Systemic lupus erythematosus can give rise to a membranous form of glomerular disease, classified as class V lupus nephritis. Other autoimmune diseases such as rheumatoid arthritis, autoimmune thyroid diseases, and Sjogren's syndrome can all be associated with MN. Historically, certain medications used for the treatment of rheumatoid arthritis such as gold salts, penicillamine, and some NSAIDs were causally linked to MN. Solid tumors are associated with secondary MN more often than chance alone would predict, and on rare occasions remissions and relapses of the glomerular disease have been noted to occur with removal or relapse of the malignancy.

Finally, MN can occur *de novo* after renal transplantation or allogeneic hematopoietic stem cell transplantation, perhaps reflecting alloimmunization to a minor histocompatibility antigen expressed in the glomerulus. Secondary forms of MN often exhibit histopathological clues that distinguish them from IMN, although this is not always the case. As opposed to the exclusively subepithelial and intra-membranous deposits seen in IMN, secondary forms,

especially membranous lupus nephritis, often have mesangial and subendothelial deposits. Tubuloreticular inclusions may also be seen within the glomerular endothelium on electron microscopy in lupus-associated MN. The IgG subclasses found within the glomerular deposits also differ. In contrast to the predominant IgG4 found in IMN, IgG2 and IgG3 are typically most abundant in secondary (lupus- and malignancy-associated) forms of MN. Finally, the nature of the electron dense material itself may herald a secondary cause. A form of MN characterized by spherular structures within the subepithelial deposits has been described that appears to be distinct from its idiopathic cousin.

Infectious	<ul style="list-style-type: none"> • Hepatitis B • Hepatitis C • Streptococcal Infections • Malaria • Schistosomiasis • Syphilis • Leprosy • Tuberculosis • Cytomegalovirus
Drugs	<ul style="list-style-type: none"> • Captopril • Clopidogrel • Mercury • Penicillamine • NSAIDs • Gold
Autoimmune Diseases	<ul style="list-style-type: none"> • Systemic Lupus erythematosus • Rheumatoid Arthritis • Thyroiditis • Sjogren's Disease • Psoriasis • Sarcoidosis • Mixed Connective Tissue Disease
Neoplasms	<ul style="list-style-type: none"> • Carcinomas of the bladder, breast, pancreas, prostate, stomach cancer, lung cancer. • Hematological malignancies: Lymphoma, Chronic Lymphocytic Leukemia
Others	<ul style="list-style-type: none"> • Sickle Cell • Diabetes Mellitus • Post-Transplant • Hematopoietic Stem-cell transplant

Table 1. Secondary Causes of MN

2.4 Post-transplantation membranous glomerulopathy

Idiopathic MN recurs in 10–30% of patients after kidney transplantation. De novo MN, which is the most common de novo glomerulopathy in renal allografts, affects 2–9% of renal allografts. De novo MN occurs 2–3 years post-transplantation, while recurrent MN occurs after 1–2 years. The exact pathogenesis of de novo MN is unknown. Recurrence of membranous nephropathy is preceded by nephrotic range proteinuria. Recurrent membranous nephropathy usually presents sooner after transplantation (within 2 years) than *de novo* membranous nephropathy (after 2 years). Some data suggests that the actual risk of recurrence reaches 29% 3 years after transplantation. Half of the cases of recurrent membranous nephropathy progressed to end-stage renal disease within a decade. There is one case report in literature where the de novo MN was linked to antibody mediated rejection: the patient had donor specific antibody-DQ7. Remission of proteinuria was associated with a fall in the anti-DQ7 titer. This raised the possibility that *de novo* membranous nephropathy could be a particular manifestation of chronic antibody - mediated rejection (Menon, Shina et al 2010)

2.5 Histopathologic considerations of membranous nephropathy

The subtle nature of the light microscopic findings in some cases of Membranous Glomerulonephritis (MGN) and presence of basement membrane thickening in other glomerular diseases lead to the uncertainty in the diagnosis of MGN in its earlier days of evolution as a pathologic entity (Heptinstall R). Only after the development of electron microscopy and immunologic techniques MGN was distinguished with certainty from other causes of the nephrotic syndrome including minimal change disease and its variants and certain forms of chronic glomerulonephritis (Heptinstall).

3. Light microscopy

3.1 Glomeruli

The characteristic changes of MGN are seen in glomerular capillary walls. The other compartments may have secondary changes but are usually minor until the advanced stages of disease. The light microscopic appearance may be subtle, especially in early cases; however, in these cases immunopathology and electron microscopy can easily establish the diagnosis. Capillary loops may appear round and rigid in more advanced stages on hematoxylin and eosin stain (Fig.1).

The earliest sign by light microscopy is “moth-eaten” appearance of the GBM on silver stains (fig.2).

3.2 Immunopathology

The immunofluorescence characteristic of MGN is granular capillary wall staining for immunoglobulins and complement. IgG is present in almost all cases, and C3 staining is seen in approximately three quarter of cases (Fig. 3). The most important and invariable deposit is IgG, and even when other immunoglobulin or complement reactants are seen, they have a weaker staining and only segmental presence (Jenette JC 1983).

Mesangial deposits are usually not seen. The presence of prominent mesangial deposits or full house positivity with other immunoglobulins or complements should suggest MGN secondary to systemic lupus erythematosus.

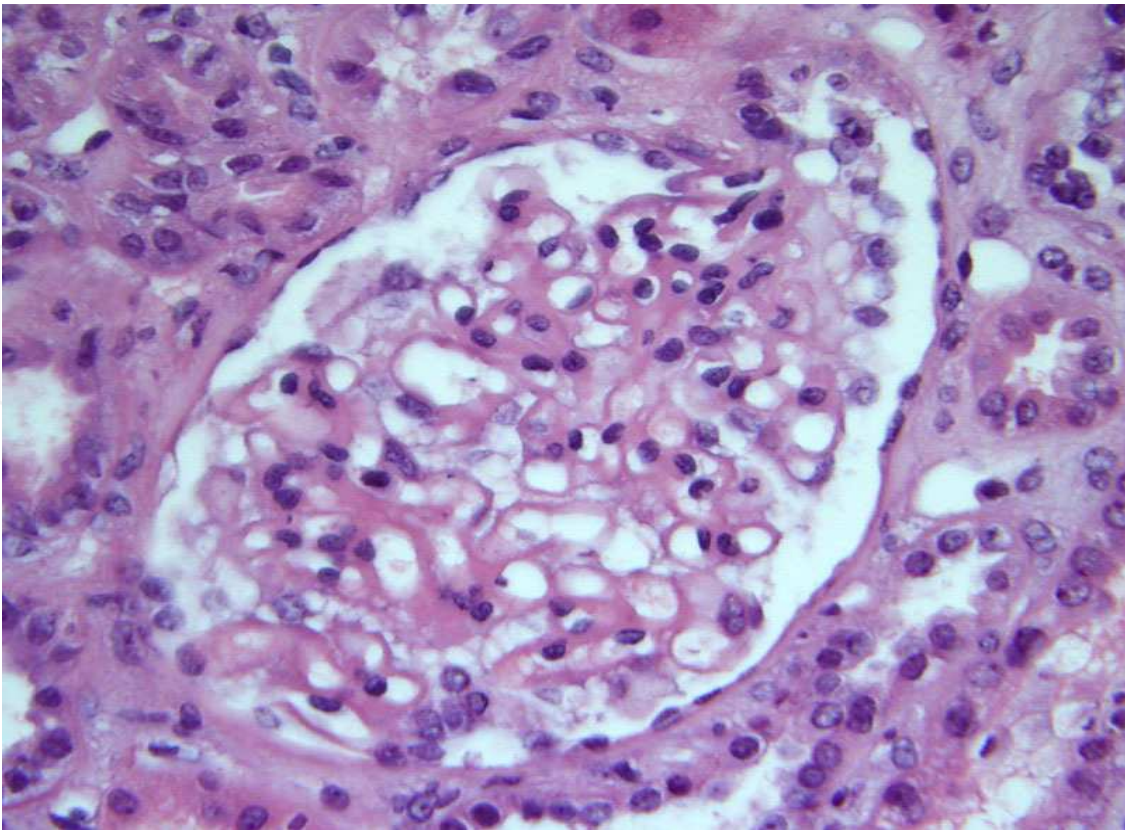


Fig. 1. Membranous glomerulonephropathy. Capillary loops may appear round and rigid in advanced cases. (H&E, 40X)

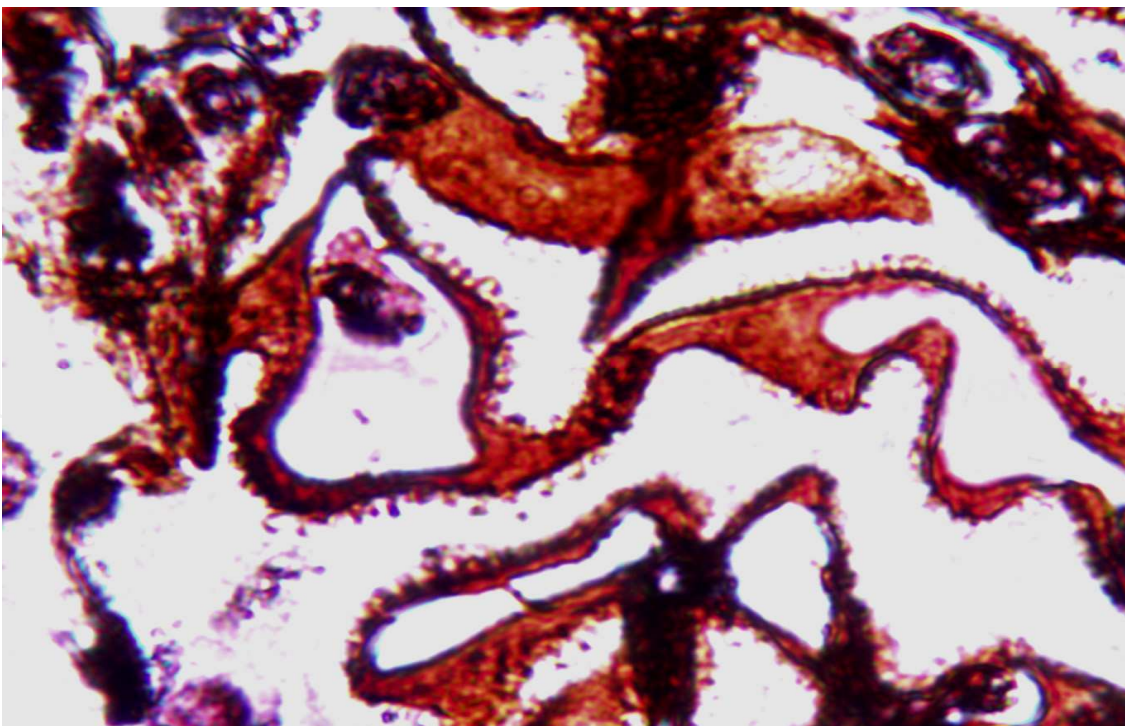


Fig. 2. Membranous glomerulonephropathy. Linear projections or "spikes" protrude from the outer surface of the GBM on silver stains (Periodic acid methenamine silver, 100X)

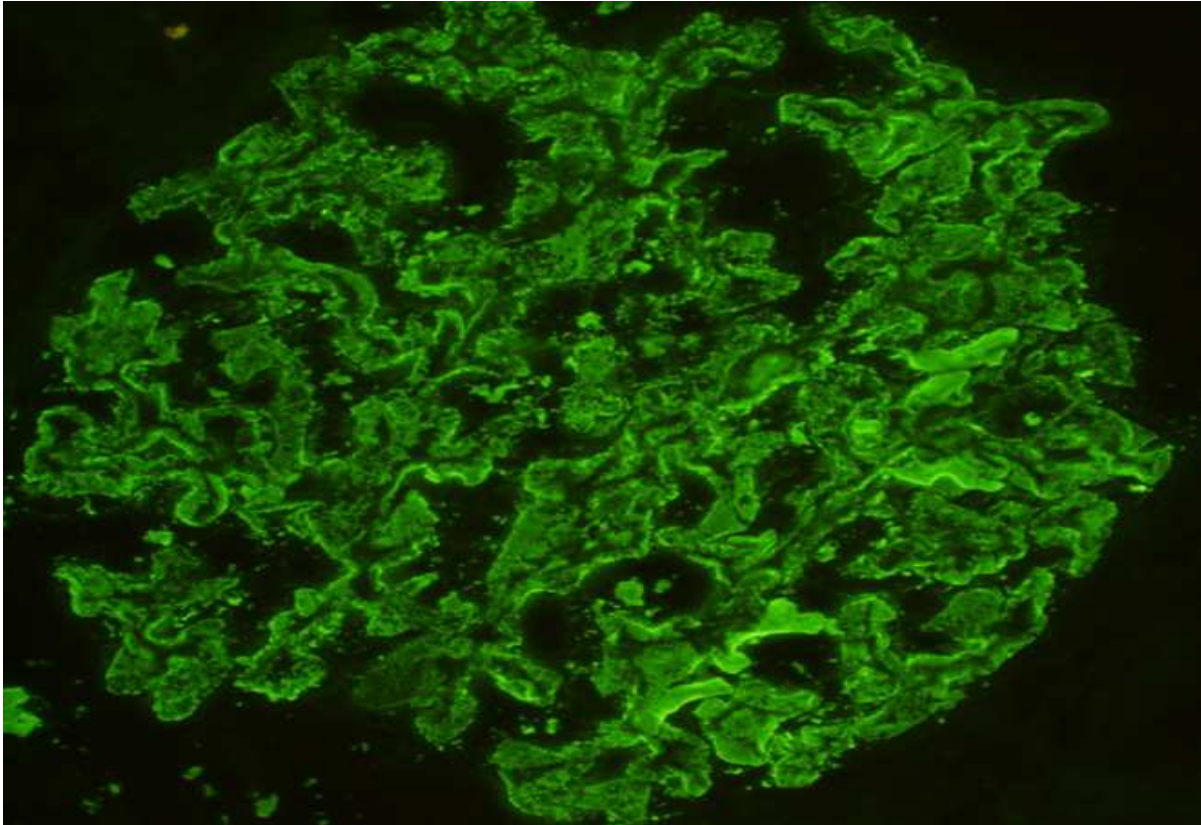


Fig.3. Membranous glomerulonephropathy. IgG is positive (2+) by immunofluorescence.

3.3 Electron microscopic findings

Electron microscopy findings helped define MGN by demonstrating the subepithelial and intramembranous (depending on the stage) location of electron-dense deposits (Gartner HV 1974). Electron-dense deposits are seen on the epithelial side of glomerular capillary loops (subepithelial). The location of electron-dense deposits at different levels in the GBM in the course of the disease led to the hypothesis that there is a sequence of changes in the GBM following initial subepithelial deposition (Ehrenreich T 1968).

3.4 Tubules

Tubular changes in MGN include progressive atrophy as the glomerular lesion progresses.

3.5 Interstitium

In uncomplicated cases, interstitial fibrosis may be seen without prominent inflammation or tubular atrophy. Development of interstitial fibrosis may reflect a progression of the glomerular lesion (Magill AB 1995).

3.6 Differential diagnosis

The light microscopic differential includes all glomerular diseases that have thickening of the glomerular basement membrane. In context of diseases associated with the nephrotic syndrome, the differential diagnosis includes minimal change disease, focal segmental glomerulosclerosis, membranoproliferative glomerulonephritis, diabetes mellitus and amyloidosis. In the past, before the development of electron microscopy and immunologic

techniques, many of these distinctions were made on clinical grounds or not at all. However, currently, characteristic histologic, immunopathologic, and ultrastructural findings can reliably distinguish it from other causes of nephrotic syndrome.

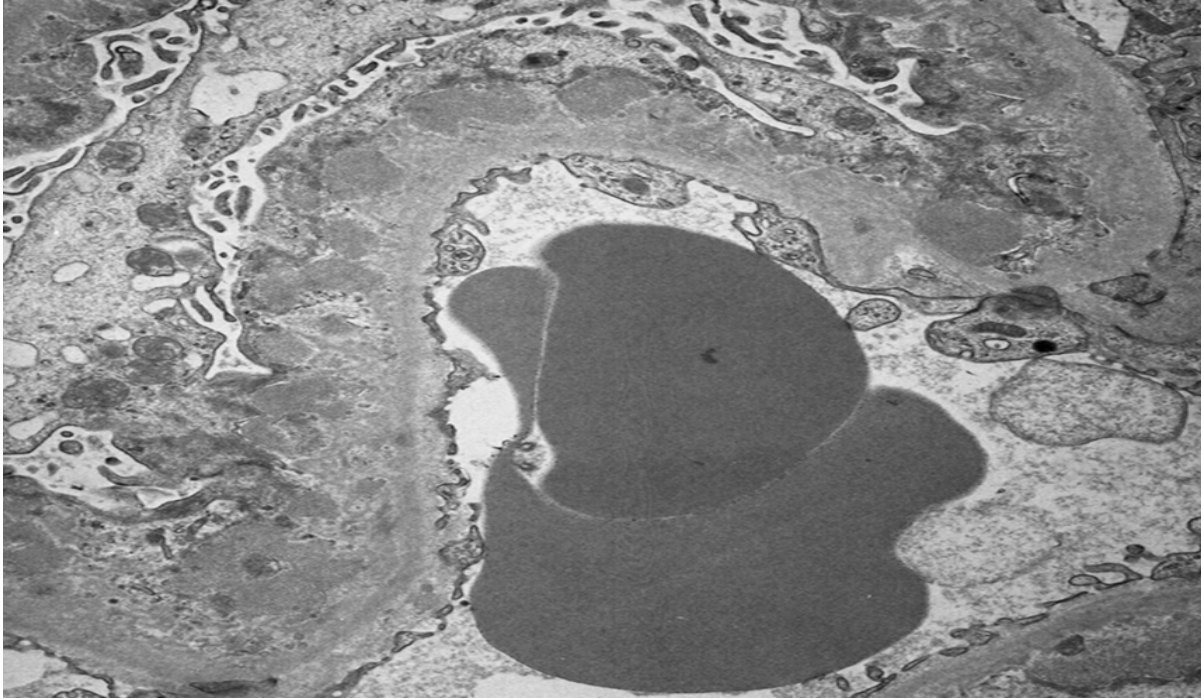


Fig. 4. Electron-dense deposits are present in subepithelial location.

3.7 Prognostic indicators

Ehrenreich and Churg (5) described the stages of membranous transformation as the morphologic representations of progression of the disease. Favorable outcomes are generally related to early stages (I and II) of membranous transformation. However, several later studies (Wahrmann 1989) did not find a relation between glomerular stage and outcome.

4. Natural history and prognosis of idiopathic MN

Although spontaneous remission of nephrotic syndrome occurs in about a third of patients, end-stage renal failure is observed in about 40% of patients after 10 years. Predicting the clinical course of a patient with MN at disease presentation is impossible given the variable and fluctuating disease course. A widely appreciated yet oversimplified view is that one-third of all patients will spontaneously remit without treatment, another third will remain proteinuric with preserved renal function and the final third will progress to end-stage renal disease (ESRD). Young females and those with subnephrotic levels of proteinuria are most likely to experience spontaneous remission, justifying several months of observation prior to any initiation of treatment in the absence of problematic clinical features. Baseline demographic differences in natural-history studies lead to a blurred prognostic picture. Several risk factors for MN progression have been proposed: older age at onset, male sex, nephrotic-range proteinuria (especially >8 g), and increased serum creatinine at presentation. As with most renal diseases, progression correlates with the amount of

tubulointerstitial disease on renal biopsy, and a tubulointerstitial disease score has been included as a prognostic variable in several studies. Although the rate of renal decline may not differ in comparison with MN patients having preserved renal function, patients with a higher serum creatinine or increased interstitial disease at presentation will reach ESRD in a shorter time; therefore, it is advisable to consider early treatment in these patients. Asians with IMN appear to have a more favorable long-term prognosis than their non-Asian counterparts.

Achieving complete remission predicts an excellent long-term renal prognosis and those patients have nearly universal renal survival at 10 years, whereas the number falls to 90% with partial remission, and 45% with no remission. Cattran and his colleagues (Cattran 2005) proposed a prognostic model dividing patients with into low-, moderate-, and high-risk groups based on their degree of proteinuria and clinical course over 6 months of observation. Those with normal renal function and lower amounts of proteinuria (<4 g daily) over 6 months constitute a group at low risk for developing progressive renal insufficiency from the disease. Intermediate levels of proteinuria (4-8 g daily) with stable renal function over 6 months define a group at moderate risk. The highest-risk patients are those with >8 g of daily proteinuria for 6 months, and/or reduced renal function at outset or deterioration of renal function over 6 months. The risk of further renal deterioration in this group is at least 75%.

A number of adult studies have allowed practitioners to characterize prognostic factors in adult patients with MN. Laluck et al. showed that low-grade, subnephrotic proteinuria and female gender were associated with spontaneous remission. Ideally, only patients unlikely to spontaneously remit and those at risk for significant renal deterioration should be treated. Male gender, age >50 years, persistent high-grade proteinuria, impaired renal function at onset, presence of segmental glomerular sclerosis, and tubulointerstitial damage on the kidney biopsy have been considered to be poor prognostic factors in adult idiopathic MN.

The Toronto Glomerulonephritis Registry created a model for identifying patients at risk for progression of renal insufficiency, taking into account the initial creatinine clearance (CrCl), the slope of the CrCl, and the lowest amount of proteinuria during a 6-month period. According to this model, patients who present with a normal CrCl, proteinuria <4 g/24 h, and stable renal function over 6 months are considered to be at low risk for progression. On the other hand, patients with persistent proteinuria (>8 g/24 h) have a 66–80% probability of progression to ESRD within 10 years, independent of the degree of renal dysfunction.

5. Treatment of idiopathic membranous nephropathy

5.1 General outlines

Treatment goals in IMN are to prevent loss of renal function and to prevent the complications of the nephrotic syndrome (eg, hyperlipidemia, volume overload hypertension, and thrombophilia). Opinions vary on how best to obtain the desired results, and the literature concerning the treatment of IMN is still unclear. The relatively low incidence of MN hampers recruitment into clinical trials, and the variable natural history of the disease adds further treatment complications. In addition, substantial risks for treatment are associated with established immunosuppressive agents and newer, potentially less toxic agents (eg, mycophenolate or rituximab) have been introduced for the treatment of MN without the benefit of long-term clinical trials. A meta-analysis on 1025 patients with MN from 18 randomized clinical trials concluded that immunosuppressive treatment had no

benefits in patient or renal survival; however some data suggest that the treatment is warranted. Because of the high rate of spontaneous remission in MN, newly diagnosed patients with nephritic syndrome and normal renal function should initially receive conservative therapy with an ACE inhibitor or ARB, diuretics, salt restriction, and statins. If a patient remains proteinuric with normal renal function, such conservative treatment can be continued, but those patients who remain frankly nephrotic after 6 months or who initially present with (or develop) renal dysfunction should be treated with an immunosuppressive agent.

The treatment of MN depends on patient presentation and disease progression after diagnosis is made by biopsy. The two leading immunomodulatory therapies used are alkylating agents (cyclophosphamide or chlorambucil) and calcineurin inhibitors (cyclosporine or tacrolimus), both typically given orally or intravenous with corticosteroids. Given the limited efficacy, high rate of relapse, and toxicities of alkylating agents, calcineurin inhibitors, and corticosteroids, other therapies for MN are needed. Recently, rituximab has surfaced as a potential treatment option for MN. This monoclonal antibody directed against the B cell antigen CD20 may be beneficial in MN on the basis of experimental evidence that B cell activation is a key step in the pathogenesis of MN. Furthermore, rituximab is generally well tolerated with a limited short-term toxicity profile. A significant amount of literature is emerging on the benefits of rituximab in MN as primary treatment and as treatment for IMN refractory to other immunosuppressant regimens.

The treatment of membranous nephropathy in patients with normal renal function remains controversial. However in patients with deteriorating renal function, a combination therapy with steroids and cytotoxic agents is considered beneficial. It remains unclear if therapy is effective in more advanced renal failure since there is no published data on such cases. There are some cases reported in literature with near end-stage renal failure in whom treatment resulted in clinical improvement. Thus therapy is effective in patients with primary membranous nephropathy and advanced azotemia especially in those who had never been treated. (Prabhakar S et al 1996)

5.2 Alkylating agents

Corticosteroids as monotherapy for treatment of IMN is not effective, instead, typical immunosuppressive regimens for idiopathic MN combine corticosteroids with alkylating agents for 6-12 months. Treatment with cyclophosphamide or chlorambucil in conjunction with corticosteroids is supported by randomized controlled trials (RCTs) cumulative data suggest that 30%-40% of those treated will achieve complete remission, with 30%-50% attaining partial remission and only 10% developing progressive renal disease," Relapse occurs in approximately 25%- 30% within 5 years of discontinuing the alkylating agent, but often responds to a repeat course of immunosuppressive therapy arm. A 6-month regimen consisting of alternating months of corticosteroids and alkylating agents has both short-term and long-term beneficial effects on proteinuria and renal survival. Ponticelli and colleagues found that this regimen increased remission rates at the final follow-up visit from 36% in untreated patients to 76%, and improved 10-year renal survival from 60% to 92%. The long-term outcomes of a randomized, controlled trial from India (Jha et al) found the same result. Some studies indicated that a delay in therapy did not lead to differences in efficacy. Studies showed immunosuppressive therapy markedly lessened the decline in renal function.

Despite the favorable results of alkylating agents in IMN, many physicians are reluctant to use these drugs, because of increased risk of infection and myelosuppression, particularly

those with reduced GFR. Cancer risk is increased when alkylating agents are used for a long time. There are some reports of increased risk of Wegener granulomatosis with cyclophosphamide when the dose is more than 36 g/m² (equivalent to 100 mg daily for one year) were associated with a 9.5-fold increased risk of bladder cancer. Use of cyclophosphamide for long time have also been associated with an increased risk of lympho-proliferative disorders. Relapses occur in 25–30% of patients within 5 years of discontinuation of therapy with alkylating agents. While this rate of relapse is lower than that observed after discontinuation of cyclosporine, it is still disconcerting since relapses generally necessitate increased immunosuppression. Despite reduction in proteinuria, these agents failed to show beneficial effects on overall mortality or risk of ESRD.

5.3 The calcineurin inhibitors (CNIs): Cyclosporine and tacrolimus

Cyclosporine is an alternative, clinically validated immunosuppressive agent used in the treatment of IMN. In one randomized clinical trial (RCT), 51 patients with steroid-resistant IMN, treatment with cyclosporine plus steroids for 6 months with tapering over 4 weeks resulted in a 75% complete or partial remission rate, versus only 22% in the placebo (steroids alone) group. Typically, many patients in cyclosporine based treatment regimens achieved partial remissions, and many relapsed after discontinuing treatment. Another similarly-sized trial compared 12 months of cyclosporine and corticosteroids to cyclosporine alone." Although both groups achieved ~80% remission rates at 12 months, the relapse rate was lower in the group receiving adjunctive corticosteroids from the beginning. Longer courses of cyclosporine (1-2 years) with a slow taper may be necessary to avoid a high rate of relapse. Other investigators demonstrated that treatment with tacrolimus in heavily nephrotic patients resulted in higher remission rates compared with conservative treatment alone; however, nearly half of these patients had a nephritic relapse within several months of tapering tacrolimus. Cyclosporine reduces proteinuria and the rate of decline in renal function in patients with IMN. These effects have been demonstrated in patients with preserved renal function, in those with declining or impaired renal function and also in patients resistant to other immunosuppressants. In some studies almost 50% of patients who had achieved remission relapsed within 1 year of cyclosporine withdrawal, especially in the first 6 months. In high-risk patients with declining renal function a 12 month treatment of cyclosporine led to a 50% reduction in proteinuria in half of the patients, and slowed the rate of renal deterioration compared with placebo. Notably, no prospective, randomized, head-to-head comparisons of cyclosporine and alkylating agents have been conducted in IMN.

On the basis of the available data, extended therapy seems to enhance the likelihood of remission. In one analysis, the majority of complete remissions occurred after at least 6 months of therapy, and the number increased as treatment continued for more than 12 months. Thereafter, the combination of low-dose cyclosporine (1.4–1.5 mg/kg per day; trough levels >100 ng/ml) and prednisolone (0.1 mg/kg per day) might be more beneficial than cyclosporin monotherapy for maintaining remission and preventing relapse.

Several investigators have evaluated whether tacrolimus could provide similar efficacy to cyclosporine in IMN. Tacrolimus is considered to be more potent than cyclosporine, has a more favorable cardiovascular risk profile and leads to better long-term renal function after renal transplantation. Studies showed the overall remission rate achieved with tacrolimus is similar to that reported with cyclosporine but the rate of complete remission is higher with tacrolimus. This difference might be, in part, related to the long duration of therapy used in

these studies (18 months, compared with 26 weeks in the study of cyclosporine by Cattran et al). The nephrotoxic effects of calcineurin inhibitors are of concern, particularly if long-term treatment is required as a result of relapses. Managing the use of these agents in patients with reduced GFR can be difficult. Due to this issue, Ponticelli and Villa recommend alternative agents in patients with impaired renal function (creatinine clearance <60 ml/min), severe hypertension or severe interstitial fibrosis and tubular atrophy. Finally, the extent to which calcineurin inhibitors affect the underlying immune process rather than merely modifying disease expression is unclear. In view of the broad range of toxic effects and the high rates of relapse associated with the use of steroids, alkylating agents and calcineurin inhibitors, alternative treatments have been investigated

6. Antimetabolites

6.1 Mycophenolate mofetil

Mycophenolate is another agent used for MN treatment with varying results. Initial studies suggested that mycophenolate could reduce proteinuria in patients with MN resistant to other conventional therapies. However, a recent RCT detected no effect of mycophenolate monotherapy in patients with normal renal function and nephrotic levels of proteinuria, when compared to conservative antiproteinuric therapy. Corticosteroid treatment with mycophenolate therapy achieved a 1-year cumulative remission rate of 66% in a group of MN patients with moderate renal dysfunction, but was inferior to alkylating agents and steroids in a historically treated control group and demonstrated a relapse rate of nearly 40%. However, a small RCT revealed similar effects from 6 months of mycophenolate and steroids compared with chlorambucil and steroids at 15 months of follow-up. Given these small studies and lack of consistently demonstrated superior efficacy, mycophenolate is not a first-line agent for the treatment of MN, but may be considered with adjunctive corticosteroids, if standard therapies are not effective or cannot be tolerated.

Clinical efficacy studies of mycophenolate mofetil (MMF) in IMN have produced mixed results in a multicenter study (Chan *et al.*) randomized 20 newly diagnosed patients with persistent proteinuria ≥ 3 g per day to undergo 6 months of treatment with either MMF plus prednisolone or with a regimen of chlorambucil alternating monthly with corticosteroids. The groups achieved similar remission rates (65%) and experienced few relapses, which suggests that MMF in conjunction with steroids has similar efficacy to a modified Ponticelli regimen. An open-label trial in the Netherlands evaluated the efficacy of MMF in patients considered to be at high risk of disease progression. The outcomes of 32 patients treated for 1 year with MMF 2 g per day and steroids were compared with those of historic matched controls treated with oral cyclophosphamide plus corticosteroids for 1 year. Patients in both groups had reduced GFR at baseline (median approximately 40 ml/min) and median proteinuria was >8 g/g creatinine. The two groups achieved similar remission rates (approximately 70%), but the relapse was higher in the MMF group such that by the end of follow-up, patients in the MMF arm were less likely to be in remission than those in the cyclophosphamide . Both treatments resulted in stabilization or improvement of renal function in the majority of patients, and infections and hospitalization occurred at a similar frequency in the two groups. Although the investigators concluded that MMF did not seem to be as effective as, or any better tolerated than cyclophosphamide, this study does suggest that a prolonged course of MMF might be of benefit even in patients with unfavorable baseline characteristics.

In contrast to the above-mentioned studies, responses to MMF in other multicenter randomized controlled trials have been poor. Firm recommendations regarding the use of this agent as initial therapy are difficult to make. MMF might be a reasonable option when the toxic effects of alkylating agents and high-dose steroids are of particular concern or when severe azotemia prohibits use of calcineurin inhibitors. Studies in large numbers of patients with prolonged follow-up are needed to determine the long-term effectiveness of MMF for maintenance of remission and preservation of renal function. Additional information is also needed to fully evaluate the adverse effect profile of MMF. MMF is also associated with pregnancy loss and congenital malformations and it can also increase the risk of lymphoma and infection. Cases of JC-virus-associated progressive multifocal leukoencephalopathy in patients with systemic lupus erythematosus receiving MMF have elicited concern. All these considerations must be weighed in the decision to use MMF in IMN,

6.2 Azathioprine

Before the use of MMF became widespread, azathioprine was tested as a treatment for IMN in several small studies, with mixed results. A combination of azathioprine and corticosteroids was reported to be beneficial in high-risk patients with declining renal function. Some patients experienced reduction in proteinuria and stabilization or improvement of renal function. However, these studies were case series with no control groups and the combined number of patients analyzed was small. In contrast to these favorable findings, a recent retrospective review indicated that azathioprine had no long-term benefit in IMN. Due to the conflicting evidence regarding the efficacy of azathioprine in IMN and the popularity of MMF, azathioprine is unlikely to be tested in future randomized trials in this setting.

7. Alternative agents

Due to the often severe adverse or nephrotoxic effects associated with cyclophosphamide and cyclosporine, several newer and potentially less toxic agents are under evaluation for the treatment of MN. Several small studies indicate the potential efficacy of rituximab, mycophenolate, or synthetic adrenocorticotrophic hormone (ACTH) in MN; unfortunately, none are large RCTs nor do they provide long-term follow-up data

7.1 Rituximab

Rituximab is a monoclonal anti-CD20 antibody that depletes B cells. Its rationale for use is provided by the suggested pathophysiological basis for MN of autoantibodies targeting a suspected glomerular antigen. Rituximab has been used in treatment of non-Hodgkin Lymphoma and other diseases. Although Rituximab appears to induce remission with an initial efficacy comparable to alkylating agents and corticosteroids, long-term data on dialysis-free survival have not been reported. In an open label trial of rituximab with a group of 15 high-risk idiopathic MN patients, there were 2 complete and 6 partial remissions at final follow-up. Others reported the effects of treatment with 4 weekly doses of rituximab on 50 consecutive patients with persistent nephrotic levels of proteinuria despite 6 months of conservative therapy." Ten patients achieved a full remission after treatment; however, they were more likely female and with lower baseline serum creatinine values, which is a population of high spontaneous remission. Recently, a small RCT study

conducted in Spain demonstrated that rituximab was of benefit in 13 Spanish patients with idiopathic MN and CNi dependence, allowing successful weaning of the nephrotoxic CN. A review of the published literature about rituximab describing the use of rituximab in MN highlights that, while promising, the existing literature consists of too few patients, heterogeneous populations, and insufficient follow-up to recommend the use of rituximab outside the research setting.

There may be potentially fatal mucocutaneous reactions, such as Stevens–Johnson syndrome and toxic epidermal necrolysis, can occur following rituximab exposure. Severe infections are infrequent, occurring in only 1–2% of patients. Of great concern, rare cases of progressive multifocal leukoencephalopathy have been reported with rituximab use, particularly as part of a multidrug immunosuppressive regimen. Physicians and patients need to be aware of the presenting features of this devastating demyelinating disease of the central nervous system, which include altered mental status, visual symptoms, motor deficits and ataxia. The preliminary results of rituximab treatment are encouraging, but concerns remain before this agent can be recommended for routine use in IMN. So far, no randomized, controlled trials have been conducted to clarify the role of rituximab in the treatment of IMN. Adequately powered, randomized, controlled trials with prolonged follow-up are needed to determine the long-term course of the disease following B-cell reconstitution; rates of relapse; subsequent redosing regimens; and effects on renal survival. Further studies must clarify whether rituximab should be used as monotherapy or in combination with other immunosuppressive drugs to achieve maximum anti proteinuric effect and durable remission. The preliminary small, uncontrolled study suggests that the addition of rituximab to tacrolimus can induce sustained remission of the nephrotic syndrome, allowing early tacrolimus withdrawal and thereby overcoming the issue of tacrolimus dependence.

7.2 Adrenocorticotrophic hormone (ACTH)

Several small, uncontrolled trials have reported beneficial effects of synthetic adrenocorticotrophic hormone ACTH in patients with IMN. One small, randomized, controlled trial by Ponticelli *et al.* compared treatment with ACTH for 1 year to a 6-month regimen of methylprednisolone alternating monthly with a cytotoxic agent in 32 (mostly medium-risk) patients with IMN. The probability of complete or partial remission did not differ substantially between the groups (87% versus 93%), and the number of remissions, mean time to response and number of relapses were also comparable between the groups. The results suggest that prolonged ACTH treatment could be equivalent to the combined use of cytotoxic drugs and steroids. The side effects of ACTH include glucose intolerance, fluid retention, hypertension, diarrhea, bronze discoloration of the skin, dizziness and fatigue, all of which resolve after discontinuation of treatment. Extensive studies with long follow-up are needed to confirm the preliminary data on the use of ACTH in IMN. Further investigation is also required to find the mechanisms by which ACTH seems to decrease proteinuria and alter apolipoprotein metabolism. These effects are probably not entirely attributable to an increase in endogenous cortisol synthesis, since steroid monotherapy has not been shown to be effective in IMN. ACTH therapy can be effective in patients who are unresponsive to steroids. On the other hand, the endogenous cortisol liberated by the actions of exogenous ACTH might act differently and perhaps more effectively than orally administered steroid.

7.3 Sirolimus

The role of sirolimus in IMN has been evaluated in two small pilot studies, with unfavorable results. No remissions occurred during therapy, but one patient achieved a partial remission after cessation of therapy. Severe adverse events, including pneumonitis, infection, persistent proteinuria and azotemia, necessitated discontinuation of the drug in the majority of cases. These trials were prematurely terminated owing to the unfavorable risk-benefit ratio. An open-label trial of sirolimus in 11 patients with a variety of chronic glomerulopathies and declining renal function, including three with membranous nephropathy, was associated with acute kidney injury in more than half of the patients; this event generally occurred within weeks of starting sirolimus. Thus, sirolimus does not seem to have a role in the treatment of IMN

7.4 Eculizumab

Eculizumab is a fully humanized monoclonal antibody directed against the complement protein C5, approved for the treatment of Paroxysmal Nocturnal Hematuria. Eculizumab inhibits C5a and C5b thus preventing complement activation. Treatment with eculizumab improves the quality of life and reduces the need of transfusions and the risk of thrombosis in patients with PNH. However, eculizumab can increase the risk of meningococcal infections perhaps due to the reduction in the levels of C5 activity. Patients should therefore be vaccinated or revaccinated with a meningococcal vaccine at least 2 weeks before receiving the first dose of eculizumab. Other side effects include headache, nasopharyngitis, back pain and cough; nausea may occur in the period following injection. The mechanism of action of eculizumab renders this monoclonal antibody potentially attractive for treating patients with IMN, as the terminal components of the complement C5b-C9 play a prominent role in mediating the inflammation and the damage of podocytes and glomerular basement membrane. However, a RCT conducted in IMN failed to show any advantage over placebo of eculizumab 8 mg/kg every other week or every 4 weeks. Further trials are needed to establish whether a different dosage or more prolonged treatment may obtain therapeutic results in IMN

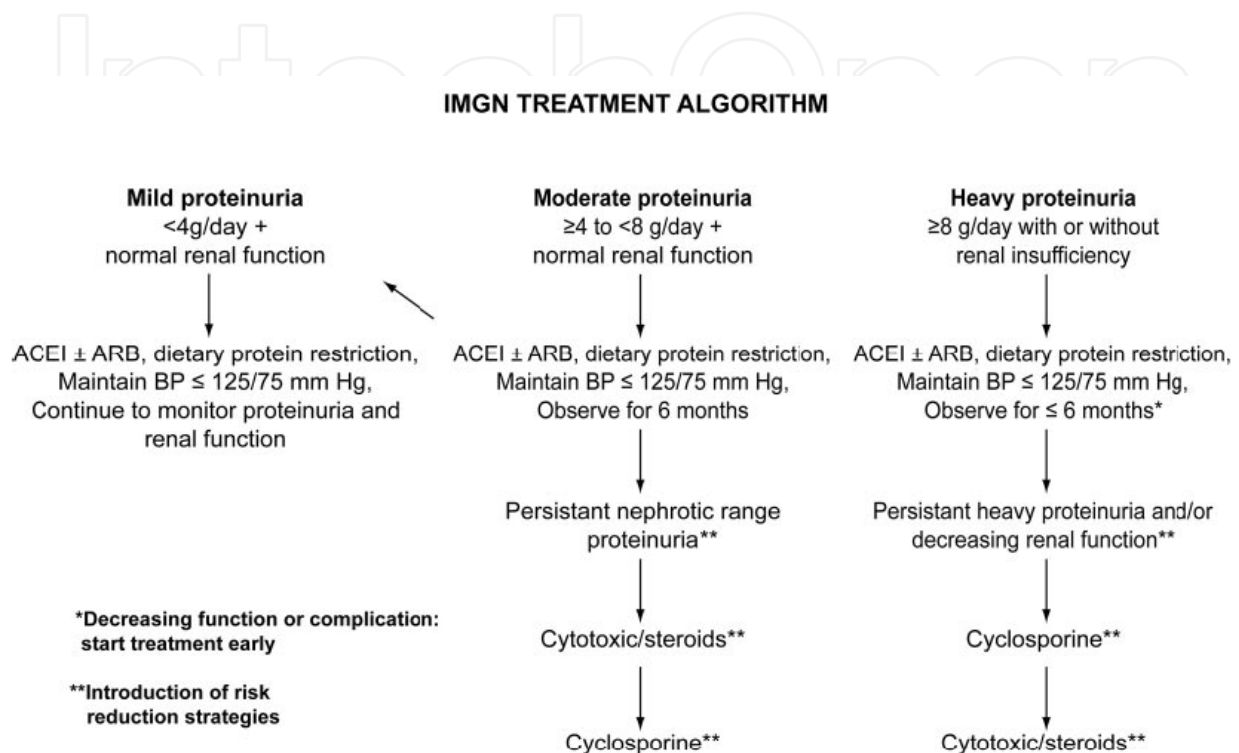
8. Intravenous high-dose immunoglobulins [IVIG]

IVIG have been used in high dose in treatment of IMN. IVIG interferes with complement-mediated immune damage by binding to C3b and C4b, by this mechanism preventing glomerular injury. This mechanism may be involved in IMN, as suggested by a study in passive Heymann nephritis, in which treatment with systemic immunoglobulin obtained a decrease in proteinuria, associated with a decreased glomerular deposition of C3c and C5b-9, without changes in the amount, size or distribution of the subepithelial immune complexes. A few anecdotal uncontrolled studies suggested a possible benefit of IVIG therapy in IMN.

8.1 Anticoagulation

Use of anticoagulation in nephrotic syndrome is a controversial issue. Nephrotic syndrome (NS) is associated with a high risk of thromboembolic complications, including deep venous thrombosis, renal vein thrombosis, and pulmonary embolism; this risk seems to be greater for IMN especially in patients with low albumin and previous history of thromboembolic disease. Analyses showed that in patients with IMN the benefits of oral

anticoagulation outweigh the risks. However, before prescribing anticoagulants the physician should take into account the severity of the NS (as assessed by serum albumin concentration), pre-existing thrombotic states, and the overall likelihood of serious bleeding events consequent to oral anticoagulation. The optimal duration of prophylactic anticoagulation is unknown but should probably last for as long as NS persists (Ponticelli C et al 2010).



[Cattran et al 2010].

9. Future directions

If anti-PLA2R or other MN-specific autoantibodies can be demonstrated to be tightly associated with immunological disease activity in idiopathic MN, a serologic immunoassay would have several potential applications. It could use the anti-PLA2R as an initial assay for the diagnosis of idiopathic MN without kidney biopsy. Serial assays for the presence and titer of anti-PLA2R prior to therapeutic intervention in clinical trials could help reduce uncertainty as to whether rapid responders represent a true therapeutic effect or a spontaneous remission. Anti-PLA2R could also be followed during treatment to assess the efficacy of immunosuppressive therapy and to determine the length of treatment. It could also be useful in partial remission, when residual proteinuria could be caused either by ongoing but attenuated immune activity or by structural glomerular changes without immune activity.

10. Summary

Membranous Nephropathy is a common cause of nephrotic syndrome in adults of all races and ethnicities. Its molecular pathogenesis is increasingly well understood, and identification of PLA2R as a target antigen may allow better diagnosis, better following of

the disease course, and improved decision-making regarding necessity and duration of treatment. Treatment should be provided to those at high risk of progression to ESRD, including patients with persistent severe proteinuria or a documented loss of renal function. At present, alkylating agents and cyclosporine are the only clinically validated treatments with sufficient follow-up data; however, as the roles of tacrolimus, rituximab, mycophenolate, and ACTH grow, these agents may become the new treatments of choice for idiopathic MN.

11. Acknowledgements

We sincerely thank Dr. Irfan Warraich, Department of Pathology, Texas Tech University Medical Center for providing the photomicrographs from biopsies in subjects with membranous nephropathy for inclusion in this chapter.

12. References

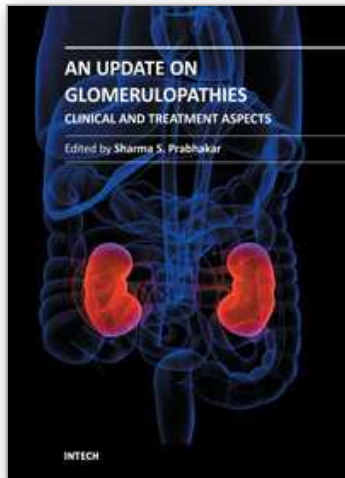
- Ahmed M, Wong C .Rituximab and nephrotic syndrome: a new therapeutic hope? *Nephrol Dial Transplant* (2008) 23: 11-17
- Alexopoulos E, Papagianni A, Tsamelashvili M. Induction and long-term treatment with cyclosporine in membranous nephropathy with the nephrotic syndrome *Nephrol Dial Transplant* (2006) 21: 3127-3132
- Beck L, Salant D. Membranous nephropathy: recent travels and new roads ahead *Kidney International* (2010) 77, 765-770
- Beck L. Membranous Nephropathy and Malignancy, *Seminars in Nephrology*, Vol 30, No 6, November 2010, pp 635-644
- Bomback A , Derebail V, McGregor JG, Kshirsagar AJ, Falk RJ ,Patrick H. Rituximab Therapy for Membranous Nephropathy: A Systematic Review *Clin J Am Soc Nephrol* 4: 734-744, 2009. doi:10.2215/CJN.05231008
- Branten A, du Buf-Vereijken PW. Mycophenolate Mofetil in Idiopathic Membranous Nephropathy: A Clinical Trial With Comparison to a Historic Control Group Treated With Cyclophosphamide. *Clin J Am Soc Nephrol* 2: 932-937, 2007
- Cattran D, Management of Membranous Nephropathy: When and What for Treatment: *J Am Soc Nephrol* 16: 1188-1194, 2005
- Cattran DC . Idiopathic membranous glomerulonephritis *Kidney International*, Vol. 59 (2001), pp. 1983-1994
- Chan T M ,Lin AW, Tang SC, Prospective controlled study on mycophenolate mofetil and prednisolone in the treatment of membranous nephropathy with nephrotic syndrome. *Nephrology* 2007; 12, 576-581
- Chen A, Frank R, Vento S, Crosby V, Chandra M, Gauthier B, Valderrama E and Trachtman H Idiopathic membranous nephropathy in pediatric patients: presentation, response to therapy, and long-term outcome. *BMC Nephrology* 2007, 8:11
- Chen, M, Li H, MD, Li XY, Lu FM, Ni Z, Xu FF. Tacrolimus Combined With Corticosteroids in Treatment of Nephrotic Idiopathic Membranous Nephropathy: A Multicenter Randomized Controlled Trial. *The American Journal of the Medical Sciences* • Volume 339, Number 3, March 2010

- Cravedi P, Ruggenti P, Sghirlanzoni MC. Titrating Rituximab to Circulating B Cells to Optimize Lymphocytolytic Therapy in Idiopathic Membranous Nephropathy. *Clin J Am Soc Nephrol* 2: 932-937, 2007
- Deegens J, Wetzels JF. Membranous Nephropathy in the Older Adult: Epidemiology, Diagnosis and Management. *Drugs Aging* 2007; 24 (9): 717-732
- Du Buf-Vereijken P.W.G., Branten AJ, Wetzels JF. Idiopathic Membranous Nephropathy: Outline and Rationale of a Treatment Strategy. *American Journal of Kidney Diseases*, Vol 46, No 6 (December), 2005: pp 1012-1029.
- Dusso B, Morange S, Burtay S. Mycophenolate Mofetil Monotherapy in Membranous Nephropathy: A 1-Year Randomized Controlled Trial. *American Journal of Kidney Diseases*, Vol 52, No 4 (October), 2008: pp 699-705
- Ehrenreich T, Churg J. Pathology of membranous nephropathy. *Pathol Ann* 1968;3:145.
- Ehrenreich T, Churg J. Pathology of membranous nephropathy. *Pathol Ann* 1968;3:145.
- Fervenza FC, Sethi S and Specks U, Idiopathic Membranous Nephropathy: Diagnosis and Treatment. *Clin J Am Soc Nephrol* 3: 905-919, 2008
- Fervenza FC, Cosio FG, Erickson SB, Specks U, Herzenberg AM. Rituximab treatment of idiopathic membranous nephropathy. *Kidney International* (2008) 73, 117-125
- Floccari VF, Cosentini M, Giacobbe G, Coppolino S, Campo D, Bolignano A. Case-by-Case Protocol of Membranous Nephropathy Treatment with Endovenous Infusion of High Doses of Human Immunoglobulins
- Gartner HV, Fischbach H, Wehner H, et al. Comparison of clinical and morphological features of peri(epi-extra) membranous glomerulonephritis. *Nephron* 1974;13:288
- Glassock R. The Pathogenesis of Idiopathic Membranous Nephropathy: A 50-Year Odyssey. *American Journal of Kidney Diseases*, Vol 56, No 1 (July), 2010: pp 157-167-
- Heptinstall's Pathology of the Kidney, 6th Edition Lippincott Williams & Wilkins
- Heptinstall RH, Idiopathic membranous, membranoproliferative, and lobular glomerulonephritis. In: Heptinstall RH, ed. *The Pathology of the Kidney*. Boston: Little, Brown and Company, 1974:393
- Hofstra J, Wetzels JF. Alkylating agents in membranous nephropathy: efficacy proven beyond doubt. *Nephrol Dial Transplant* (2010) 25: 1760-1766
- Hofstra J, Branten AJ, Wirtz JJ, Noordzij TC, du Buf-Vereijken PW, Wetzels JF. Early versus late start of immunosuppressive therapy in idiopathic membranous nephropathy: a randomized controlled trial. *Nephrol Dial Transplant* (2010) 25: 129-136
- Idasiak-Piechocka I, Katarzyna AO, Łochyńska B, Skrobańska B. Efficacy and Safety of Low-Dose Chlorambucil in Nephrotic Patients with Idiopathic Membranous Nephropathy. *Kidney Blood Press Res* 2009;32:263-267
- Ivanyi A. A primer on recurrent and *de novo* glomerulonephritis in renal allografts. *Nature Clinical Practice Nephrology*, August 2008 vol 4 no 8
- Jennette JC, Iskanal SS, Dalldorf FG. Pathologic differentiation between lupus and nonlupus membranous glomerulopathy. *Kidney Int* 1983;24:377.
- Jha V, Ganguli A, Saha TA. Randomized, Controlled Trial of Steroids and Cyclophosphamide in Adults with Nephrotic Syndrome Caused by Idiopathic Membranous Nephropathy. *Journal*
- Kosmadakis G, Filiopoulos V, Smirloglou D, Skarlas P, Georgoulas C, Michail S. Comparison of immunosuppressive therapeutic regimens in patients with nephrotic syndrome due to idiopathic membranous nephropathy. *Renal Failure*, 32, 566-571, 2010

- Laluck BJ Jr, Cattran DC. Prognosis after a complete remission in adult patients with idiopathic membranous nephropathy. *Am J Kidney Dis.* ;33(6):1026-32. 1999.
- Lefaucheur C, Stengel B, Nochy D, Martel P, Hill GS, Jacquot C and Rosser J for the GN-PROGRESS Study Group. Membranous nephropathy and cancer: Epidemiologic evidence and determinants of high-risk cancer association. *Kidney International* (2006) 70, 1510–1517
- Lionaki I, Siamopoulos K, Theodorou I. Inhibition of tumour necrosis factor alpha in idiopathic membranous nephropathy: a pilot study *Nephrol Dial Transplant* (2009) 24: 2144–2150
- Magil AB. Tubulointerstitial lesions in human membranous glomerulonephritis: Relationship to proteinuria. *Am J Kidney Dis* 1995;25:375.
- Menon S, Valentini RP. Membranous nephropathy in children: clinical presentation and therapeutic approach. *Pediatric Nephrology* (2010) 25:1419–1428 DOI 10.1007/00467-009-1324-5
- Mok CC. Membranous nephropathy in systemic lupus erythematosus: a therapeutic enigma: *Nat. Rev. Nephrol.* 5, 212–22(2009)doi:10.1038/nrneph.2009.14
- Mok CC, Ying KY, Yim CW, Ng WL, Wong WS. Very long-term outcome of pure lupus membranous nephropathy treated with glucocorticoid and azathioprine. *Lupus* (2009) 18, 1091–1095
- Nayagam L, Ganguli SA. Mycophenolate mofetil or standard therapy for membranous nephropathy and focal segmental glomerulosclerosis: a pilot study *Nephrol Dial Transplant* (2008) 23: 1926–1930
- Pantelista K, Koutroulia E, Sotsiou F, Vlachiojannis JG., Oumenos DS: Benefit and cost from the long-term use of cyclosporine-A in idiopathic membranous nephropathy *Nephrology* 15 (2010) 762–767 *Expert Opin. Pharmacother.* (2010) 11(13):2163–2175
- Polanco N, Gutierrez E: Spontaneous Remission of Nephrotic Syndrome in Idiopathic Membranous Nephropathy. *J Am Soc Nephrol* 21: 697–704, 2010.
- Ponticelli C, Passerini P. Can prognostic factors assist therapeutic decisions in idiopathic membranous nephropathy. *J Nephrology* 2010 ; 23 (02): 156-163
- Ponticelli C. Membranous nephropathy *J. Nephrol* 2007 May-Jun;20(3):268-87
- Prabhakar Kahn. Therapy of membranous nephropathy with severe azotemia. *Clinical Nephrology*, v.45 .No.6 - 1996
- Praga M, Passerini P. Management of idiopathic membranous nephropathy *Expert Opin. Pharmacotherapy.* (2010) 11(13):2163-2175
- Praga M, Barrio V, Fernandez J G, J Lun. Tacrolimus monotherapy in membranous nephropathy: A randomized controlled trial. *Kidney International* (2007) 71, 924–930
- Ronco P, Debiec H. Target antigens and nephritogenic antibodies in membranous nephropathy: of rats and men: *Semin Immunopathol* (2007) 29:445–458 DOI 10.1007/s00281-007-0091-2
- Ronco P, Debiec H. Membranous glomerulopathy: the evolving story *Curr Opin Nephrol Hypertens* 2010, 19:254–259
- Ruggenti P, Cravedi P, Remuzzi G. Rituximab for membranous nephropathy and immune disease: less might be enough: *Piero nature clinical practice Nephrology* february 2009 vol 5 no 2

- Ruggenti P, Cravedi P. Effects of Rituximab on Morphofunctional Abnormalities of Membranous Glomerulopathy, *Clin J Am Soc Nephrol* 3: 1652-1659, 2008.
- Salant D. In Search of the Elusive Membranous Nephropathy Antigen Nephron Physiol 2009;112:p11-p12
- Segara A, Praga M, Ramos N. Successful treatment of membranous glomerulonephritis with rituximab in calcineurin inhibitor-dependent patients *Clin J Am Soc Nephrol*. 2009 Jun;4(6):1083-8. Epub 2009 May 28
- Sepe V, Libetta C, Giuliano MG, Adamo G, Canton AD. Mycophenolate mofetil in primary glomerulopathies. *Kidney International* (2008) 73, 154-162
- Stanescu HC, Arcos-Burgos M, Medlar A, et al. Risk HLADQA1 and PLA2R1 alleles in idiopathic membranous nephropathy. *N Engl J Med* 2011;364:616-26.
- Troyanov S, Wall CA, Miller JA, Scholey JW, Cattran DC. Idiopathic membranous nephropathy: Definition and relevance of a partial remission. *Kidney International*, Vol. 66 (2004), pp. 1199-1205
- Waldman M, Austin HA. Controversies in the treatment of idiopathic membranous nephropathy *Nat. Rev. Nephrol.* 5, 469-479 (2009); published online 7 July 2009
- Wehrmann M, Bohle A, Bogenschutz O, et al. Long-term prognosis of chronic idiopathic membranous glomerulonephritis: An analysis of 334 cases with particular regard to tubulointerstitial changes. *Clin Nephrol* 1989;3:67.

IntechOpen



An Update on Glomerulopathies - Clinical and Treatment Aspects

Edited by Prof. Sharma Prabhakar

ISBN 978-953-307-673-7

Hard cover, 468 pages

Publisher InTech

Published online 02, November, 2011

Published in print edition November, 2011

An Update on Glomerulopathies - Clinical and Treatment Aspects is a systemic overview of recent advances in clinical aspects and therapeutic options in major syndromes of glomerular pathology. The book contains twenty four chapters divided conveniently into five sections. The first section deals with primary glomerulopathies, and the second section is devoted to glomerulopathies complicating infectious conditions. The third section deals with systemic autoimmune disorders and vasculitides which constitute major causes of glomerular disease and often renal failure. The fourth section includes chapters discussing the glomerular involvement in some major metabolic and systemic conditions. The final section has chapters which relate to some general aspects of glomerular diseases. This book will form an excellent reference tool for practicing and academic nephrology community.

How to reference

In order to correctly reference this scholarly work, feel free to copy and paste the following:

Abdelaziz Elsanjak and Sharma S. Prabhakar (2011). Membranous Nephropathy, An Update on Glomerulopathies - Clinical and Treatment Aspects, Prof. Sharma Prabhakar (Ed.), ISBN: 978-953-307-673-7, InTech, Available from: <http://www.intechopen.com/books/an-update-on-glomerulopathies-clinical-and-treatment-aspects/membranous-nephropathy>

INTECH
open science | open minds

InTech Europe

University Campus STeP Ri
Slavka Krautzeka 83/A
51000 Rijeka, Croatia
Phone: +385 (51) 770 447
Fax: +385 (51) 686 166
www.intechopen.com

InTech China

Unit 405, Office Block, Hotel Equatorial Shanghai
No.65, Yan An Road (West), Shanghai, 200040, China
中国上海市延安西路65号上海国际贵都大饭店办公楼405单元
Phone: +86-21-62489820
Fax: +86-21-62489821

© 2011 The Author(s). Licensee IntechOpen. This is an open access article distributed under the terms of the [Creative Commons Attribution 3.0 License](#), which permits unrestricted use, distribution, and reproduction in any medium, provided the original work is properly cited.

IntechOpen

IntechOpen