

We are IntechOpen, the world's leading publisher of Open Access books Built by scientists, for scientists

4,800

Open access books available

122,000

International authors and editors

135M

Downloads

Our authors are among the

154

Countries delivered to

TOP 1%

most cited scientists

12.2%

Contributors from top 500 universities



WEB OF SCIENCE™

Selection of our books indexed in the Book Citation Index
in Web of Science™ Core Collection (BKCI)

Interested in publishing with us?
Contact book.department@intechopen.com

Numbers displayed above are based on latest data collected.

For more information visit www.intechopen.com



Neurological Manifestations in Behcet Disease

E. Ait Ben Haddou, A. Benomar, W. Regragui, M. Yahyaoui
*Department of Neurology B and Neurogenetic, Hopital des Spécialités, Rabat,
 Mohammed V Souissi University, Faculty of Medicine of Rabat,
 Morocco*

1. Introduction

Behçet disease is a multisystem disease of unknown cause in which an inflammatory perivasculitis can arise in almost any tissue (Sakane *et al.*, 1999). Neurologic involvement in Behçet disease was first reported by Knapp in 1941. It represented between 4-49% of manifestations of BD (Haghighi *et al.*, 2005). There is one of the most serious causes of long term morbidity and mortality in Behçet's Disease. As well as, involvement of the central nervous system occurs late in the course of the disease (10-25%) (Ildan *et al.*, 1996; Nakasu *et al.*, 2001). It is caused by primary neural parenchymal lesions or is secondary to major vascular involvement (Adnan *et al.*, 2009).

Treatment of the most cases of NB should be given as infusion of intravenous methyl prednisolone followed by a slowly tapering course of oral steroids. (Adnan *et al.*, 2000,). Immunopressives agents should be used in its severity forms of NB such as meningoencephalitis, deep veins thrombosis and myelopathy. In this Review, we summarise and describe the clinicals manifestations of neurobehcet disease.

2. Epidemiology

Epidemiological, Clinical characterization and pattern of neurological involvement of Behcet's disease have been reported in different series (Hentati *et al.*, 1993; bohlega *et al.*, 1993; nakamura *et al.*, 1994; Farah *et al.*, 1998; Kidd *et al.*, 1999; Akman *et al.*, 1999; Al fahad *et al.*, 1999).

Retrospective and prospective studies found that the prevalence of Neurobehcet disease (NBD) is very variable. Neurologic involovement were occurred in 2-49% of cases, other authors estimated their prevalence of 3-50% of cases (Borhani *et al.*, 2009). The age of onset of NBD is usually 20-40 years with an average age of 39 years. In two the last decade, Neurological complications have also been described in children. (Adnan *et al.*, 2005 ; Araji *et al.*, 2009).

The highest incidence is in the Middle East, the Mediterranean basin, and the Far East regions, but it is rare in Europe and North America. The frequency was 13% in men and 5.6% in women. Neurological manifestations commonly develop a few years after the onset of the other systemic features of BD; The mean duration between onset of BD and development of NBD ranged from 3 to 6 years. (Siva *et al.*, 2001). However, neurological syndrome might coincide or come in advance (~6% of patients) with other systemic

symptoms features of BD, in that case diagnosis can be difficult and causes ambiguity with other systemic diseases (Akman *et al.*, 1999).

3. Classification

There are two categories of neurological involvement in BD that have been generally accepted: parenchymal involvement and non-parenchymal involvement, also called cerebral angio-Behçet's syndrome. The most syndromes often involved in NBD were meningoencephalitis, myelopathy and deep veins thrombosis which presented 80% in retrospective series (Tohme *et al.*, 2008).

4. Neuropathology

NBD is considered as an inflammatory perivasculitis disease, in an acute meningoencephalitis the most common neuropathologic findings are Severe and acute inflammation consisting mainly of lymphocytic, eosinophils, macrophages, and neutrophilic infiltrations of the perivascular spaces and parenchyma. These lesions can lead to necrotizing and disseminated encephalitis involving the basal ganglia, brainstem, cerebellum and diencephalon.

In the progressive phase, authors found the inflammatory infiltration of lymphocytes and cytokines remains and cuts down. (Hirohata *et al.*, 2008; Heo *et al.*, 2008; Hadfi *et al.*, 1996; Arai *et al.*, 2006; Scardamaglia *et al.*, 2001).

5. Clinical characteristics

In order to the accumulated data, it's now obvious that it is necessary to handle parenchymal CNS involvement and non parenchymal CNS involvement in Behçet's disease separately.

5.1 Parenchymal CNS involvement

About 70 à 80% CNS involvement

First of all, Subacute meningoencephalitis accounts for 75% of cases in parenchymal NBD, which performs adverse symptoms, depending on the topography of lesions.

It's and often associated with exacerbation of the systemic features of BD, including fever, malaise, orogenital ulcers, skin lesions, or uveitis (Akman *et al.*, 2003; Joseph *et al.*, 2007).

The onset of signs is in the most cases acute or subacute. More rarely, the onset is chronic (Akman *et al.*, 1999). Onset is usually with an attack of headache, hemiparesis and / or gradual behavioural changes. The symptoms and signs are taking a few days to attempt Summit and during several weeks, rely on depending on the extent of the lesion and on how rapidly treatment is initiated. However, spontaneous remissions of symptoms could be taken before initiation of therapy as it has been reported (Hirohata *et al.*, 2007).

Different syndromes might be encountered during the course of parenchymal NBD.

The patient may frequently show brainstem signs, including pyramidal bilateral and cerebellar syndromes, ophthalmoparesis and cranial neuropathy. Moreover, there is evidence for additional cerebral or spinal cord involvement like a day time sleeping with or without hyperphagia and which might be indicative of hypothalamic dysfunction (Wechsler *et al.*, 2002; Houmana *et al.*, 2009)

Second a progressive form of the disease which represents 10% of cases of NBD, including, a worsening subcortical dementia, were usually accompanied by ataxia.

Third, symptoms and signs suggestive of cerebral hemispheric involvement include encephalopathy, hemiparesis, Hemisensory loss, seizures, dysphasia, and mental changes with cognitive dysfunction and psychosis.

Fourth, symptoms and signs of spinal cord involvement include pyramidal signs in the limbs, sensory level dysfunction, and, commonly, sphincter dysfunction.

Finally, asymptomatic (silent) parenchymal NBD is diagnosed if there are no neurological symptoms, but neurological signs on examination (usually pyramidal signs). Recognition of these clinical syndromes might help clinicians dealing with BD to predict the pattern of involvement. They might also help neurologists to remember BD in the differential diagnosis of a patient who presents with one of these neurological syndromes. In addition, other clinical syndromes might arise in BD, and although uncommon, it is important that these syndromes are recognized.

5.1.1 Epilepsy

Neuro-BD-related epileptic disorder has been previously reported in a large series of Behçet disease. Generalized seizures are the predominant type (Aykutlu et al., 2002). Convulsions were observed in 2 - 5% of large series (Al-Fahad et al., 2001). Behçet's syndrome may present with partial seizure and epilepsy partialis continua (Aktekin et al., 2006). Partial seizures were a presenting feature of NBD in one report (Chroni et al., 2008).

5.1.2 Brain tumour

Since the first described case in 1987; Focal necrotic lesions in the cerebral cortex; only a few cases have been published. (Litvan et al., 2005; Matsuo et al., 2005; Appenzeller et al., 2005; Kusters et al., 2006; Bennett et al., 2004; Park et al., 2002).

The regions usually affected are, brainstem, diencephalon, basal ganglia, and internal capsule. The clinical presentation depends on the localizations of brain tumors; usually include intracranial hypertension syndrome and/or impaired of consciousness. These lesions cause a diagnosis problem with the brain tumor and a multiple metastatic tumors.

5.1.3 Movement disorders

Extrapyramidal manifestations which are indicating basal ganglion excessive dysfunction, are rare in most series of patients with NBD.

5.1.4 Acute meningeal syndrome

Aseptic meningitis commonly exists with many parenchymal CNS manifestations of BD. The signs and symptoms are relatively common in parenchymal NBD. However, isolated meningitis might only rarely be the presenting feature of NBD (Kidd et al., 1999; Akman et al., 1999; Al-Fahad et al., 1999).

5.1.5 Optic neuropathy

Optic neuropathy is rare in BD, it has been described only in 0.4% of the main series of behçet disease. It can be bilateral and can be recurrent over many years. The severity of the

visual loss and its recovery can be very variable, even in the same patient (Voros et al., 2006; Tarzi et al., 2005).

5.1.6 Spinal cord involvement

Involvement of the spinal cord as part of the diffuse type of parenchymal NBD pattern is rare, represent 11% as reported by the most studies, thurly the spinal cord is commonly found to be involved in autopsy series of Behcet's disease. More frequently a combination of spinal cord symptoms with other syndromes of parenchymal NBD, However isolated acute transverse myelitis is an exceptional presentation of NBD (Joseph, 2007).

Most commonly patients presented with sensory-motor symptoms, sphincter and/or sexual dysfunction evolving over days. Although spinal cord involvement has a n worse prognosis compared with other types of p-NBD. The myelopathy can have a severe primary progressive course, a secondary progressive course after initial attack(s), or an acute attack with severe residual sequela after attacks (Houman et al., 2007; Moskau et al., 2003).

14% had predominantly spinal cord involvement (10 with isolated spinal cord involvement and 13 with additional brainstem and/or hemispheric involvement. The cervical and/or dorsal areas can be involved (Kocer, 1999; Kizilkilic, 1998; Tunc et al., 2003; Calguneri et al., 2005).

5.2 Non-parenchymal NBD

5.2.1 Cerebrovascular involvement

Also called cerebral angio-Behcet's syndrome, encompassing mainly those instances with dural sinus thrombosis. Cerebrovascular complications include strokes, carotid aneurysm formation and cerebral venous thrombosis (Hadfield et al, 1996; Tunc et al., 2004; B'chir-Hamzaoui et al., 2009)

5.2.1.1 Cerebral venous thrombosis

In 1959, with headache and bilateral papilloedema. CVT constituted about 18% of NBD cases in the studies included, it's reported to affect men more often than women and occurs at an earlier age. Clinical onset is acute or subacute in most patients. Chronic onset is less frequent. Patient has an intracranial hypertension. a focal deficits, seizures and /or counciousness impairment (Yesilot et al., 2006; Bousser et al., 2007; Akman et al., 1999).

The superior sagittal sinus is the most common site of thrombosis, followed by transverse sinuses, deep cerebral veins and cavernous sinuses, respectively (Mossadeq et al., 2004).

Deep cerebral vein thrombosis is a specific clinical pattern of neuroBehçet. The clinical features of Rosenthal or internal cephalic vein thrombosis predominate. The clinical presentation is highly suggestive of diagnosis confirmed by Imaging ; it's a mesencephalic diencephalitis syndroma combining hemiparesis, hémiataxie and / or movement disorders and ophthalmoplegia by damage of III (Mossadeq et al., 2004).

5.2.1.2 Ischemic stroke and cerebral vasculitis

are unusual manifestations during the course of BD, it was reported in 1-5% of major series in the literature (1999; Al-Araji et al., 2003; Al-Fahad et al., 1999; Barros et al., 2007; Benamour et al., 2006; Borhani-Haghighi et al., 2006; Houman et al., 2007; Joseph et al., 2007; Monaco et al., 2006; Turker et al., 2008).

5.2.1.3 Aneurysm formation

Aneurysm formation is common in the visceral arteries in BD, but extremely rare in the intracranial. vasculitis may be involved in the etiology of intracranial aneurysms in patients with BD (Kaku et al., 2007).

5.2.2 Intracranial hypertension

Hypertension manifests as an acute or, more commonly, subacute evolution of headache (92%), papilledema (80%), focal neurologic deficits (32%), seizures (20%), sixth-nerve palsy (16%) and/or altered consciousness (8%). Intracranial hypertension with or without cerebral vein thrombosis appears in 11–35% of all patients. Dural sinus thrombosis, more frequently the superior sagittal sinus; is the main cause of raised intracranial pressure.

In the other side, intracranial without sinus thrombosis or MRI abnormalities have been reported in NBD (Pamiret al., 1981; Akman et al., 1996).

5.3 Others

5.3.1 Psychiatric and cognitive disorders

Psychiatric or cognitive symptoms might be the earliest presentation of NBD, a patient can have a dementia as a sole presentation of the disease. Patients have usually a special pattern of cognitive decline in with impaired memory, attention, and frontal lobe functions, and poor motivation and personality change, by contrast with relatively preserved linguistic, arithmetic, visuospatial, abstraction, and problem-solving abilities (Akman et al., 1999).

Psychosomatic symptoms, such as anxiety and depression, are the most commonly encountered, in BD. These symptoms are mostly related to the underlying systemic disease, fatigue, functional deterioration, and sociological handicap, but are only rarely due to direct involvement of the CNS (Taner et al., 2007). Behavioural changes were common; whereas major psychiatric symptoms were less common in large series (Akman et al., 1999; Al-Fahad et al., 1999; Siva, 2001).

It is possible that psychiatric symptoms could be the first manifestation of the disease. To our knowledge, this is the first case report of Neuro-Behçet's Syndrome that presents with an acute psychotic attack (Orhan, 2009).

Abnormal cognitive performances were present in 87.8% of the patients, with the most commonly and most severely affected function being long term memory for both verbal and visual modalities, followed by attention, and executive functioning, whereas only 9% of BD patients also showed cognitive deficits in visuospatial functions (Roberto, 2004) found that the main cognitive domain. Previous papers reporting cognitive dysfunction in BD patients included participants with neurological involvement (Akman et al., 1999; Oktem et al., 1999).

However the recent studies reported that BD patients without overt neurological involvement are more likely to have cognitive impairment (Al-Arajiet al., 2009; Wechsler et al., 2002; Taner et al., 2007).

5.3.2 Peripheral nervous system involvements

Peripheral nervous system manifestations are relatively rare in BD. Isolated cases of peripheral neuropathy or myopathy have been reported in Behçet's disease, they are essentially a case of multiple neuropathies, sensorimotor peripheral neuropathy, neuropathy autonomic dysfunction a Guillain Barré syndrome and hearing loss (Namer et al., 1987). Causes of

sensorineural hearing loss include central and peripheral nerve disorders. In particular, sensorineural hearing loss due to peripheral neuropathy was reported to be very rare (AK, 2004). Few series have described the clinical manifestations (Namer *et al.*, 1987; Worthmann *et al.*, 1996; Ben Ghorbel *et al.*, 2005).

Muscle involvement seems to be exceedingly rare in adults but more common in children. Patients present with a myositis, occasionally localised, that can be detected by electromyography. The rarity of these reports should encourage clinicians to investigate extensively for alternatives before accepting BD as the diagnosis.

5.3.3 Headache

The study has revealed a very high prevalence of headache in an unselected population of patients with Behçet's syndrome. The majority of headaches is of neurovascular type and the prevalence of visual or sensory aura is higher than that seen in the general population of migraine sufferers (Kidd *et al.*, 2006). Headache is the most common neurological symptom in patients with BD, and occurs in about 70% of patients. . The frequency of headache in BD was similar to the prevalence of headache

Headache syndromes (e.g., migraine and tension-type headache) affect about 50% of patients with BD, and account for 70% of all causes of headaches in BD. The characteristics of these primary symptoms in BD did not differ when compared with a headache clinic population (Aykutlu *et al.*, 2006).

The features of this headache varied between migraine, migraine like, and tension type (Borhani-Haghighi *et al.*, 2008; Aykutlu *et al.*, 2006; Saip *et al.*, 2005).

The most widely accepted criteria for the diagnosis of BD are the International BD Study Group criteria (panel 1).

Panel 1: International Behçet's Disease Study Group criteria for the diagnosis of Behçet's disease⁵

For diagnosis, patient must have had the following symptoms:

Recurrent oral ulceration—minor aphthous, major aphthous, or herpetiform ulceration observed by physician or patient that recurred at least three times in one 12-month period

Plus two of the following:

Recurrent genital ulceration—aphthous or scarring, observed by physician or patient

Eye lesions—anterior uveitis, posterior uveitis, or cells in vitreous on slit lamp examination; or retinal vasculitis observed by ophthalmologist

Skin lesions—erythema nodosum observed by physician or patient, pseudofolliculitis, papulopustular lesions; or acneiform nodules observed by physician in post-adolescent patients not on corticosteroids

Positive pathergy test—read by physician at 24–48 h

Findings applicable only in the absence of other clinical explanations.

6. Diagnosis

The diagnosis of neurological involvement in BD is done mainly by clinical means; the ancillary investigations noted below help to suggest alternatives, and especially infective complications of treatment, but there is no diagnostic test for NBD (Adnan *et al.*, 2009). No validated criteria for the diagnosis of NBD exist. Blood count and biochemical screening is used to identify the nature and severity of the systemic disorder and to identify signs of a superimposed infective complication. (Yazici *et al.*, 2007).

6.1 Blood test

Blood count and biochemical screening is used to identify the nature and severity of the systemic disorder and to identify signs of a superimposed infective complication (Yazici *et al.*, 2007). Erythrocyte sedimentation rate has been found to be associated with disease activity.

HLA type B51 has been reported to be present in 60–70% of Turkish and Japanese patients, although in only 10–20% of European patients (Borhani *et al.*, 2009). Patients with HLAB51 have a six-time increased risk of BD, and the disease is usually more severe in such patients (Yazici *et al.*, 2007).

In the case of cerebral venous thrombosis (CVT), a thrombophilia screen should be undertaken. Early reports suggested a higher prevalence of antiphospholipid antibodies and factor V Leiden mutations, but these findings have not been confirmed (Adnan *et al.*, 2009).

6.2 Cerebrospinal fluid (CSF)

CSF constituents are altered in around 70–80% of patients with parenchymal complications. CSF protein is modestly raised in most cases, sometimes to over 1 g/dL, and oligoclonal bands are usually absent (Akman *et al.*, 1999). The CSF cell count is often prominently raised. (Borhani *et al.*, 2008; Houman *et al.*, 2007).

In Hamzaoui *et al.* study, elevated CSF levels of IL-15 were seen in patients with NBD in comparison with the patients with non-inflammatory neurological disease (Hamzaoui *et al.*, 2006).

CSF levels of some major pro-inflammatory (IL-6, 8, TNF- α and interferon) and anti-inflammatory (IL-10) cytokines in patients with different subtypes of NBD, In Niino *et al.* study, the concentration of macrophage migration inhibitory factor in CSF was significantly elevated in patients with NBD compared with control group and correlated well with CSF cell count (Niino *et al.*, 2000).

Significance of elevation of interleukin 6 in patients with parenchymal NBD was found (A. Borhani *et al.*, 2009).

The level of interleukin-6 dropped when the disease activity subsided.

These changes were in parallel with IgM isotype of anticardiolipin antibodies (Wong *et al.*, 1992). In Hirohata *et al.* study 11 patients with progressive NBD showed significant elevation of CSF interleukin-6 activities in comparison with patients with active BD without progressive neurological manifestations.

Serum interleukin-6 activities of these groups did not revealed significant difference (Hirohata *et al.*, 1997).

CSF interleukin-6 levels were used as a parameter for investigation of response of six patients with NBD to low dose methotrexate.

After 12 months trial CSF interleukin-6 levels were significantly decreased. However six months after discontinuation of methotrexate, all patients showed significant exacerbation evidenced by a decrease in verbal intelligence quotients along with the marked elevation of CSF interleukin 6 (Hirohata et al., 1998).

6.3 MRI

However, there were still limitations in differential diagnosis with tumor, abscess, multiple sclerosis, and other vasculitis (Joseph et al., 2007; Miller et al., 1987.; Litvan et al., 1987; Mnif et al., 2006; Neudorfer et al., 1993; Imoto et al., 2002; Tuzgen et al., 2002; Bennet et al., 2004; A. Tourba et al., 2011).

In Neurobehçet's disease, the most common site was brainstem and the next most common sites were basal ganglia and white matter.

Cerebellar lesion was reported in a few cases (Kocer et al., 1999; Jae-Hyeok et al., 2008).

Patients with a more diffuse meningoencephalitis show hyper intense T2 lesions within the subcortical white matter of the temporal, frontal, and hypothalamic regions, but the scan might also be normal.

Patients with spinal cord involvement show a single lesion, which might look like a demyelinating plaque, but might extend over two or three segments.

Venous sinus thrombosis is readily seen on magnetic resonance venography and brain CT venography. Patients who present with idiopathic intracranial hypertension have normal imaging studies (Ak man et al., 2003; Coban et al., 1999; Siva et al., 2009).

7. Treatment

The severe nature of the neurological involvement in BD obligates the innovation of markers of disease activity or prognosis that can be determined early in the disease course (Guls et al., 2008). There have no controlled or comparative trials of treatment of any aspect of neurological involvement in BD. Based on scattered evidence, corticosteroids and immunosuppressive have proved effective in improving clinical symptoms of NBD. Remission can be defined as complete or nearly complete absence of symptoms.

Corticosteroids should be given as infusions of intravenous methylprednisolone: 1g IV daily for 3 to 5 days followed by prednisone 0.5 to 1 mg/kg/d for acute attacks. Therefore prevention treatment for early relapses consists of prednisone which must be very gradually tapered over 2 to 3 months (Siva et al., 2000), followed by a slowly tapering course of oral steroids (Adnan et al., 2009).

However, there is controversy about the choice of immunosuppressant therapy as an adjuvant to corticosteroids; immunosuppressive agents or tumor necrosis antagonists should be used at the same time or later depends on the nature of the disease, its severity, the response to steroids, and whether the patient has had previous attacks. In the retrospective series, immunosuppressive therapy not be used until the second attack occurs, or if the disease is aggressive. Similarly, no treatment trial has been undertaken CVT.

For dural sinus thrombosis associated with Behçet disease, concurrent use of corticosteroids and anticoagulants is suggested (Bank et al., 1984). Either intravenous unfractionated heparin or subcutaneous low-molecular-weight heparin can be used (Siva et al., 2001).

Some neurologists do not use anticoagulants at all, choosing instead to give steroids and immunosuppressants alone.

Other neurologists prefer to use anticoagulants, but recent data show that immunosuppressants are underused (Adnan *et al.*, 2009).

In the literature, several immunosuppressive agents were previously reported, such as Azathioprine, Cyclophosphamide, Chlorambucil, thalidomide and Methotrexate. In most series, the most used immunosuppressant were Azathioprine and methotrexate. Cyclophosphamide (CPM) is only reported in only sporadic cases, and used in second intention (Homan *et al.*, 2008; Hatemi *et al.*, 2008; Kotter *et al.*, 2005).

More recently, some immunomodulators such as interferon, infliximab and thalidomide have been used successfully in treating some cases of Neurobehçet, but their effectiveness has been proven with any controlled study (Siva *et al.*, 2009).

In the study by O'Duffy *et al.*, Chlorambucil with or without corticosteroids was more effective than corticosteroids alone for meningoencephalitis or recurrent meningitis (O'Duffy *et al.*, 1984). In the Hirohata *et al.* study, low-dose methotrexate reduced the CSF interleukin-6 level and seemed to ameliorate the course of neuropsychiatric manifestations (Hirohata, 1998).

For patients with parenchymal Neurobehçet's disease without any poor prognostic factor, Azathioprine or methotrexate and corticosteroids are recommended as the first line treatment. For high risk patients, intravenous Cyclophosphamide and corticosteroids are recommended (Borhani *et al.*, 2009).

8. Prognosis

Neurobehçet's disease has a high mortality rate, up to 25% within the first year after developing neurological manifestations (Wolf *et al.*, 1965).

Most patients who have an acute parenchymal inflammatory episode recover well after steroid treatment. Retrospective series from 10–15 years ago reported a mean of 20–30% of patients with residual neurological impairments, and a high 10-year mortality of 10%. However, non-parenchymal CNS involvement is prominently associated with a better prognosis than parenchymal CNS involvement (Wechsler *et al.*, 1992; Akman-Demir *et al.*, 1996; Siva *et al.*, 1997). It should be noted that certain factors influence the course and prognosis of Neurobehçet cases. In a previous reported the most important of these is the correlation between the acute-stage CSF findings and the clinical course (Akman-Demir *et al.*, 1996) normal CSF at the acute stage is associated with a better prognosis, stable course and less disability, while high cellular and/or protein content is significantly associated with a worse prognosis (Gu'lsen Akman-Demir *et al.*, 1999)

9. Conclusion

Neurological involvements are actually classified in two categories; a parenchymal and non parenchymal diseases. Their manifestations come many years after the outset of BD. The diagnosis is based according to the international criteria of a group study of Behçet disease.

Moreover, clinical manifestations are critical and should be diagnosed earlier. The most serious involvements are parenchymal and vascular diseases because they engage vital and functional prognosis.

Therefore intensive therapy based on corticosteroids anticoagulation therapy and immunosuppressive only guarantees of improving their prognosis.

10. References

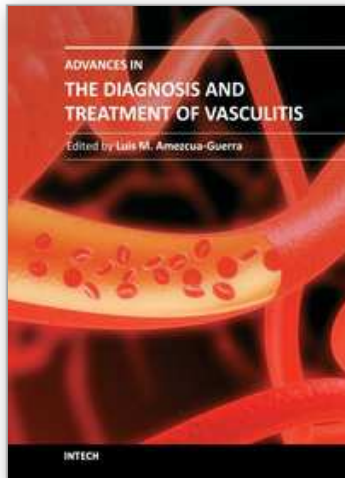
- A.Tohme, S.Koussa, S.Haddad-Zébouni, B.El-Rassi,E.Ghayad (2008). Etude de 22 observations de Neurobehçet dans une série de 170 maladies de Behçet, *Presse médicale*.
- Adnan al Araji, Kidd P Desmond. (2009). Neuro-Behçet's disease: epidemiology, clinical characteristics, and management. *Lancet Neurol*, 8: 194-204.
- AK E, Harputluoglu U, Oghan F, Baykal B. (2004). Behçet's disease and hearing loss. *Auris Nasus Larynx*, 31, 29-33.
- Akman Demir G, Bahar S, Baykan-Kurt B, Gurvit IH, Serdaroglu P. (1996). Intracranial hypertension in Behçet's disease. *Eur J Neurol*, 3, 66-70.
- Akman-Demir G, Bahar S, Coban O, Tasci B, Serdaroglu P. (2003). Cranial MRI in Behçet's disease: 134 examinations of 98 patients. *Neuroradiology*; 45:851-9.
- Akman-Demir G, Baykan-Kurt B, Serdaroglu P, Gurvit H, Yurdakul S, Yazici H, et al. (1996). Seven-year follow-up of neurologic involvement in Behçet syndrome. *Arch Neurol*, 53: 691-4.
- Akman-Demir G, Serdaroglu P, Tasci B. (1999). Clinical patterns of neurological involvement in Behçet's disease: evaluation of 200 patients. The Neuro-Behçet Study Group. *Brain*; 122: 2171-82.
- Al-Araji A, Sharquie K, Al-Rawi Z. Prevalence and patterns of neurological involvement in Behçet's disease: a prospective study from Iraq. *J Neurol Neurosurg Psychiatry*, 74, 608-13.
- Al-Fahad S, Al-Araji A. Neuro-Behçet's disease in Iraq: a study of 40 patients. (1999). *J Neurol Sci*, 170, 105-11.
- Appenzeller S, de Castro R, de Souza Queiroz L, et al. (2005). Brain Schmolck H. Large thalamic mass due to neuro-Behçet disease. *Neurology*, 65, 436.
- Appenzeller S, de Castro R, Queiroz Lde S, Madegan L, Soledade C, Zanardi Vde A, et al. (2006). Brain tumor-like lesion in Behçet disease. *Rheumatol Int*, 26(6): 577-80.
- Arai Y, Kohno S, Takahashi Y, Miyajima Y, Tsutusi Y (2006). Autopsy case of neuro-Behçet's disease with multifocal neutrophilic perivascular inflammation. *Neuropathology*, 26, 579-85.
- Aykutlu E, Baykan B, Akman-Demir G, Topcular B, Ertas M. Headache in Behçet's disease (2006). *Cephalalgia*, 26, 180-86.
- Aykutlu E, Baykan B, Serdaroglu P, Gokyigit A, Akman-Demir G (2002). Epileptic seizures in Behçet disease. *Epilepsia*, 43, 832-35
- B. Pourabbas, M.A. Nazariniaf, Z. Habibagahif, M.J. Fattahig, A. Ghaderig. (2009). CSF levels of cytokines in Neurobehçet's disease. *Clinical Neurology and Neurosurgery*; 111, 507-510.
- Bank I, Weart C. (1984). Dural sinus thrombosis in Behçet's disease. *Arthritis Rheum*; 27: 816-818.
- Barros R, Santos E, Moreira B, et al. (2007). Clinical characterization and pattern of neurological involvement of Behçet's disease in fifteen Portuguese patients. *Clin Exp Rheumatol*, 24(Suppl. 42), S31.

- Ben Ghorbel I, Ibnelhadj Z, Zouari M, Nagi S, Khanfir M, Hentati F, et al. (2005). Behçet's disease associated with peripheral neuropathy. *Rev Neurol*, 161, 218–20.
- Benamour S, Naji T, Alaoui F-Z, Kabli H, El Aidouni S. (2006). Manifestation neurologiques de la maladie de Behçet. *Rev Neurol*, 162, 1084–90.
- Bennett DL, McCabe DJ, Stevens JM, Mifsud V, Kitchen ND, Giovannoni G. (2004). Tumefactive Neurobehçet disease. *Neurology* Aug 24; 63(4):709.
- Borhani Haghighi A. (2008). Comment on "histopathology of central nervous system lesions in Behçet's disease". *J Neurol Sci*; 270: 211.
- Borhani Haghighi A. (2009). Treatment of Neuro-Behçet's disease: an update. *Expert Rev Neurother*. Apr; 9(4):565-74.
- Borhani-Haghighi A, Aflaki E, Ketabchi L. (2008). The prevalence and characteristics of different types of headache in patients with Behçet's disease, a case-control study. *Headache*; 48, 424–29.
- Borhani-Haghighi A, Samangoie S, Ashjazadeh N, et al. (2006). Neurological manifestations of Behçet's disease. *Saudi Med Journal*, 1542–6.
- Bousser MG, Ferro JM. (2007). Cerebral venous thrombosis: an update. *Lancet Neurol*, 6, 162–70.
- Calguneri M, Onat AM, Ozturk MA, et al. (2005). Transverse myelitis in a patient with Behçet's disease: favourable outcome with a combination of interferon-alpha. *Clin Rheumatol*, 24, 64–66.
- Chroni E, Monastirli A, Polychronopoulos P, Pasmazi E, Georgiou S, Tsambaos D. (2008). Epileptic seizures as the sole manifestation of Neurobehçet's disease: complete control under interferon-alpha treatment. *Seizure*; Dec, 17(8): 744-7.
- Coban O, Bahar S, Akman-Demir G, Tasçi B, Yurdakul S, Yazici H, et al. (1999). Masked assessment of MRI findings: is it possible to differentiate Neurobehçet's disease from other central nervous system diseases? *Neuroradiology*; 41: 255–60.
- D. Kidd (2006). The prevalence of headache in Behçet's syndrome. *Rheumatology*, 45, 621–623
- Ebru Aykutlu, Betül Baykan, Piraye Serdarolu, Aysen Gökyiit, Gülsen Akman-Demir (2002). Epileptic seizures in Behçet disease. *Epilepsia*, 43, 832–35.
- Gülsen Akman-Demir, Piraye Serdaroglu, Banu Tasc and the Neuro-Behçet Study Group*. (1999). Clinical patterns of neurological involvement in Behçet's disease: evaluation of 200 patients *Brain*; 122, 2171–218.1
- Guak TH, Kim YI, Park SM, Kim JS. (2002). Paroxysmal focal dystonia in neuro-Behçet by a small ipsilateral thalamic lesion. *Eur Neurol*, 47, 183–84.
- Gülsen Akman-Demir, Erdem Tuzun, Sema İcoz, Nilufer Yesilol, Sibel P. Yentur, Murat Kurtuncu, Melike Mutlu, Guher Saruhan-Direskeneli. (2008). Interleukin-6 in neuro-Behçet's disease: Association with disease subsets and long-term outcome. *Cytokine* 44; 373–376.
- Hadfi eld MG, Aydin F, Lippman HR, Kubal WS, Sanders KM. (1996). Neuro-Behçet's disease. *Clin Neuropathol*, 15, 249–55.
- Hamzaoui K, Hamzaoui A, Ghorbel I, Khanfir M, Houman H. (2006). Levels of IL-15 in serum and cerebrospinal fluid of patients with Behçet's disease. *Scand J Immunol*; 64(December (6): 655–60.
- Hatemi G, Silman A, Bang D, Bodaghi B, Chamberlain AM, et al. (2008). Management of Behçet's disease: a systematic literature review for the EULAR evidence-based recommendations EULAR Expert Committee. *Ann Rheum Dis*; 67:1656-62.

- Hirohata S, Isshi K, Oguchi H, Ohse T, Haraoka H, Takeuchi A, et al. (1997). Cerebrospinal fluid interleukin-6 in progressive NeuroBehçet's syndrome. *Clin Immunol Immunopathol*; 82(January (1):12-7.
- Hirohata S, Suda H, Hashimoto T. (1998). Low dose weekly methotrexate for progressive neuropsychiatric manifestations in Behçet's disease. *J Neurol Sci*; 159:181-5.
- Hirohata S.(2007). Potential new therapeutic options for involvement of central nervous system in Behcet's disease (neuro-Behcet's syndrome). *Curr Rheumatol Rev*, 3, 297-303.
- Hirohata S.(2008). Histopathology of central nervous system lesions in Behcet's disease. *J Neurol Sci*, 267, 41-47
- Houman MH, Neffati H, Braham A, et al. Behçet's disease in Tunisia.(2007). Demographic, clinical and genetic aspects in 260 patients. *Clin Exp Rheumatol*; 25(Suppl. 45):S58-64.
- Houman MH, Smiti-Khanfir M, Hamzaoui K. (2008). Traitements actuels et perspectives thérapeutiques dans la maladie de Behçet. *Presse Med*; 37: 25-35
- Imoto H, Nishizaki T, Nogami K, Sakamoto K, Nomura S, Akimura T, et al. (2002). Neuro-Behcet's disease manifesting as a neoplasm-like lesion case report. *Neurol Med Chir (Tokyo) Sep*; 42(9):406-9)
- Jae-Hyeok Heo, Soon-Tae Lee, Kon Chu, Manho Kim. (2008) Neuro-Behcet's disease mimicking multiple brain tumors: Diffusion-weighted MR study and literature review *Journal of the Neurological Sciences* 264; 177-181
- Joseph FG, Scolding NJ. (2007). Neurobehçet's disease in Caucasians: a study of 22 patients. *Eur J Neurol Feb*; 14(2):174-80.
- Kaku Y, Hamada JI, Kuroda JI, Kai Y, Morioka M, Kuratsu JI. (2007). Multiple peripheral middle cerebral artery aneurysms associated with Behçet's disease. *Acta Neurochir (Wien)*, 149: 823-27.
- Kidd D, Steuer A, Denman AM, Rudge P (1999). Neurological complications of Behcet's syndrome. *Brain*, 122: 2183-94.
- Kizilkilic O, Albayram S, Adaletli I, Ak H, Islak C, Kocer N. Mascalchi M, Cosottini M, Cellerini M, Paganini M, Arnetoli G.(1998). MRI of spinal cord involvement in Behçet's disease: case report. *Neuroradiology*, 40, 255-57.
- Kocer N, Islak C, Siva A, Saip S, Akman C, Kantarci O, et al. (1999). CNS involvement in neuro-Behcet syndrome: an MR study. *AJNR Am JNeuroradiol Jun-Jul*; 20(6):1015-24.
- Kosters K, Bos MM, Wesseling P, Smeets SM, van der Ven AJ, Bredie SJ.(2006). An unusual cause of a cerebral tumour in a young patient. Behçet's disease. *Neth J Med*, 64: 152.
- Kotter I, Gunaydin I, Batra M, Vonthein R, Stubiger N, Fierlbeck G, et al. (2005). CNS involvement occurs more frequently in patients with Behçet's disease under cyclosporin A (CSA) than under other medications-results of a retrospective analysis of 117 cases. *Clin Rheumatol*; 1-5.
- Kuriwaka R, Kunishige M, Nakahira H, et al. (2004). Neuro-Behcet's disease with chorea after remission of intestinal Behcet's disease. *Clin Rheumatol*, 23: 364-67.
- Lee SH, Yoon PH, Park SJ, Kim DI. (2001). MRI findings in neuro-Behcet's disease. *Clin Radiol*, 56, 485-94.
- Litvan I, Roig C, Rovira A, Rusalleda J. (1987). Behçet's syndrome masquerading as tumor. *Neuroradiology*; 29:103.

- Lo Monaco A, La Corte R, Caniatti L, Borrelli M, Trotta F (2006). Neurological involvement in North Italian patients with Behçet disease. *Rheumatol Int*, 26, 1113–9.
- M.H. Houmana, R. Salem, T. Ben Salem (2009). Neurological involvement in Behçet disease Les manifestations neurologiques de la maladie de Behçet. *La Revue de médecine interne*.
- Matsuo K, Yamada K, Nakajima K, Nakagawa M. (2005). Neuro-Behçet disease mimicking brain tumor. *Am J Neuroradiol*, 26, 650–73.
- Miller HD, Ormerod IEC, Gibson A, du Boulay EP, Rudge P, McDonald WI. (1987). MR brain scanning in patients with vasculitis: differentiation from multiple sclerosis. *Neuroradiology*; 29:226–31.
- Mnif N, Rajhi H, Mlika N, Kechaou S, BenAbdallah N, Hamza R. (2006). Aspect En IRM du Neurobehçet. *J Neuroradiol*; 33:250–4.
- Moskau S, Urbach H, Hartmann A, Schmidt S. Multifocal myelitis in Behçet's disease (2003). *Neurology*, 60: 517.
- Mossadeq R, Karouache A, Bouraza A, et al. (2004). Neuro-Behçet's syndrome and thrombosis of Rosenthal's basilar vein: a report of twelve cases. *Rev Neurol*, 160, 935–8.
- Namer IJ, Karabudak R, Zileli T, et al. (1987). Peripheral nervous system involvement in Behçet's diseases. *Eur Neurol*; 26:235–40.
- Namer IJ, Karabudak R, Zileli T, Ruacan S, Ku'c,u'kali T, KansuE. (1987). Peripheral nervous system involvement in Behçet's disease. *EurNeurol*, 26, 235–40.
- Neudorfer M, Feiler-Ofri V, Geyer O, Reider I. (1993). Behçet's disease presenting as a cerebral tumour. *Neuroradiology*; 35:145.
- Niino M, Ogata A, Kikuchi S, Tashiro K, Nishihira J.(2000). Macrophage migration inhibitory factor in the cerebrospinal fluid of patients with conventional and optic-spinal forms of multiple sclerosis and neuro-Behçet's disease. *JNeurol Sci*; 179(October (Suppl. 1–2)):127–31.
- O'Duffy JD, Robertson DM, Goldstein NP. (1984). Chlorambucil in the treatment of uveitis and meningoencephalitis of Behçet's disease. *Am J Med*; 76:75– 84.
- Oktem-Tanor O, Baykan-Kurt B, Gurvit IH, Akman-Demir G, Serdaroglu P.(1999). Neuropsychological follow-up of 12 patients with neuro-Behçet disease. *J Neuro*, 246, 113– 9.
- Orhan Deniza, Ali C, aykoylub, Gonul Vural a, Yakup Albayrakb,, S , adiyeye Temela. (2009). A case study of Neuro-psycho-Behçet's Syndrome presenting with psychotic attack. *Clinical Neurology and Neurosurgery*; 111 877 - 879
- Pamir MN, Kansu T, Erbiengi A, Zileli T. (1981). Papilloedema in Behçet's syndrome. *Arch Neurol*, 38, 643–45.
- S. B'chir-Hamzaoui, T. Larbi, M. Abdallah, A. Harmel, M. Ennafaa, K. Bouslama, M. Ben Dridi, S.M'rad (2009). Pour le groupe Behçet Maghreb Behçet's disease in Maghreb: Behçet Maghreb study about 1460 cases *La Revue de médecine interne*, 30S S229–S231
- Saip S, Siva A, Altintas A, et al.(2005). Headache in Behçet's syndrome. *Headache*, 45, 911–19.
- Scardamaglia L, Desmond PM, Gonzales MF, Bendrups A, Brotdmann A, Kay TWH. (2001). Behçet's disease with cerebral vasculitis. *Int Med J*, 31, 560–61.
- Schmolck H. (2005). Large thalamic mass due to Neurobehçet disease. *Neurology Aug 9*; 65(3):436.
- Siva A, Fresco I. (2000). Behçet's disease. *Curr Treat Options Neurol*; 2: 435– 448.

- Siva A, Kantarci OH, Saip S, et al. (2001) Behçet's disease: diagnostic and prognostic aspects of neurological involvement. *J Neurol*; 248: 95-103.
- Siva A, Saip S, Kantarci O, Hamuryudan V, Kocer N, Islak C, et al. (1997). Neuro-Behçet syndrome (NBS): clinical and imaging features. *Neurology*; 48 (3 Suppl): A362.
- Siva A, Saip S. (2009). The spectrum of nervous system involvement in Behçet's syndrome and its differential diagnosis. *J Neurol*; 256:513-29.
- Siva A. (2001). Vasculitis of the nervous system. *J Neurol.*; 248: 451- 468.
- Taner E, Coşar B, Burhanoğlu S, Calikoğlu E, Onder M, Arikan Z. (2007). Depression and anxiety in patients with Behçet's disease compared with that in patients with psoriasis. *Int J Dermatol*, 46, 1118-24.
- Tarzi MD, Lightman S, Longhurst HJ. (2005). An exacerbation of Behçet's syndrome presenting with bilateral papillitis. *Rheumatology (Oxford)*, 44, 953-54.
- Tunc R, Saip S, Siva A, et al. (2004). Cerebral venous thrombosis is associated with major vessel disease in Behçet's syndrome. *Ann Rheum Dis*;63, 1693-4.
- Tunc R, Saip S, Siva A, Yazici H. (2003). Cerebral venous thrombosis Moskau S, Urbach H, Hartmann A, Schmidt S. Multifocal myelitis in Behçet's disease. *Neurology*, 60, 517.
- Turker H, Terzi M, Bayrak O, Cengiz N, Onar M, Us O.(2008). Visual evoked potentials in differential diagnosis of multiple sclerosis and neuro-behçet's disease. *Tohoku J Exp Med*, 216, 109-16.
- Tuzgen S, Kaya AH, Erdinçler D, Oguzoglu SA, Ulu O, Saip S. (2003). Two cases of neuro-Behçet's disease mimicking cerebral tumor. *Neurol India Sep*; 51(3):376-8.
- Voroos Gm, Sandhu SS, Pandit R.(2006). Acute optic neuropathy in patients with Behçet's disease. Report of two cases. *Ophthalmologica*, 220, 400-05.
- Wang CR, Chuang CY, Chen CY. (1992). Anticardiolipin antibodies and interleukin-6 in cerebrospinal fluid and blood of Chinese patients with Neurobehçet's syndrome. *Clin Exp Rheumatol*; 10: 599-602.
- Wechsler B, Sbaï A, Du-Boutin LT, Duhaut P, Dormont D, Piette JC. (2002). Manifestations neurologiques de la maladie de Behçet. *Rev Neurol*, 158, 926-33.
- Wechsler B, VidailhetM, Piette JC, BousserMG, Dell Isola B, BlétryO, et al. (1992). Cerebral venous thrombosis in Behçet's disease. *Neurology*; 42: 614-8.
- Wolf SM, Schotland DL, Phillips LL. (1965). Involvement of nervous system in Behçet's syndrome. *Arch Neurol*; 12:315-25.
- Worthmann F, Bruns J, Turker T, Gosztonyi G. (1996). Muscular involvement in Behçet's disease. [Review]. *Neuromuscul Disord*, 6, 247-53.
- Yazici H, Fresko I, Yurdakul S. (2007). Behçet's syndrome: disease manifestations, management, and advances in treatment. *Nat Clin Pract Rheumatol*; 3: 148-55.
- Yesilot N, Celiktas S, Mutlu M, et al. (2006). Cerebral venous and dural sinus thrombosis associated with Behçet's disease. *Clin Exp Rheumatol*, 24 (suppl 42): S30.
- Yesilot N, Mutlu M, Gungor O, Baykal B, Serdaroglu P, Akman-Demir G. (2007). Clinical characteristics and course of spinal cord involvement in Behçet's disease. *Eur J Neurol*, 14, 729-37.



Advances in the Diagnosis and Treatment of Vasculitis

Edited by Dr. Luis M Amezcua-Guerra

ISBN 978-953-307-786-4

Hard cover, 366 pages

Publisher InTech

Published online 09, November, 2011

Published in print edition November, 2011

This book represents the culmination of the efforts of a group of outstanding experts in vasculitis from all over the world, who have endeavored to draw themselves into this volume by keeping both the text and the accompanying figures and tables lucid and memorable. The book provides practical information about the screening approach to vasculitis by laboratory analysis, histopathology and advanced image techniques, current standard treatment along with new and more specific interventions including biologic agents, reparative surgery and experimental therapies, as well as miscellaneous issues such as the extra temporal manifestations of "temporal arteritis" or the diffuse alveolar hemorrhage syndrome. The editor and each of the authors invite you to share this journey by one of the most exciting fields of the medicine, the world of Vasculitis.

How to reference

In order to correctly reference this scholarly work, feel free to copy and paste the following:

E. Ait Ben Haddou, A. Benomar, W. Regragui and M. Yahyaoui (2011). Neurological Manifestations in Behcet Disease, *Advances in the Diagnosis and Treatment of Vasculitis*, Dr. Luis M Amezcua-Guerra (Ed.), ISBN: 978-953-307-786-4, InTech, Available from: <http://www.intechopen.com/books/advances-in-the-diagnosis-and-treatment-of-vasculitis/neurological-manifestations-in-behcet-disease>

INTECH
open science | open minds

InTech Europe

University Campus STeP Ri
Slavka Krautzeka 83/A
51000 Rijeka, Croatia
Phone: +385 (51) 770 447
Fax: +385 (51) 686 166
www.intechopen.com

InTech China

Unit 405, Office Block, Hotel Equatorial Shanghai
No.65, Yan An Road (West), Shanghai, 200040, China
中国上海市延安西路65号上海国际贵都大饭店办公楼405单元
Phone: +86-21-62489820
Fax: +86-21-62489821

© 2011 The Author(s). Licensee IntechOpen. This is an open access article distributed under the terms of the [Creative Commons Attribution 3.0 License](#), which permits unrestricted use, distribution, and reproduction in any medium, provided the original work is properly cited.

IntechOpen

IntechOpen