

# We are IntechOpen, the world's leading publisher of Open Access books Built by scientists, for scientists

**4,800**

Open access books available

**122,000**

International authors and editors

**135M**

Downloads

Our authors are among the

**154**

Countries delivered to

**TOP 1%**

most cited scientists

**12.2%**

Contributors from top 500 universities



**WEB OF SCIENCE™**

Selection of our books indexed in the Book Citation Index  
in Web of Science™ Core Collection (BKCI)

Interested in publishing with us?  
Contact [book.department@intechopen.com](mailto:book.department@intechopen.com)

Numbers displayed above are based on latest data collected.

For more information visit [www.intechopen.com](http://www.intechopen.com)



# Treatment of Different Types of Vasculitis

Hisayoshi Imanishi<sup>1,3</sup> and Daisuke Tsuruta<sup>2,3</sup>

<sup>1</sup>The Department of Dermatology, Saiseikai Tondabayashi Hospital, Osaka,

<sup>2</sup>The Department of Dermatology, Kurume University School of Medicine,  
and Kurume Institute of Cutaneous Cell Biology, Fukuoka,

<sup>3</sup>The Department of Dermatology, Osaka City University Graduate  
School of Medicine, Osaka,  
Japan

## 1. Introduction

Vasculitis is classified by the size of the blood vessels affected by inflammatory reactions. In vasculitis of skin, many patients show obvious purpura and ulceration. Because many vasculitides can be noticed by these skin manifestations, dermatologists should be well informed about vasculitis. It is difficult to manage vasculitis after the diagnosis has been performed, and it is particularly difficult to treat systemic vasculitides, because they are potentially life threatening. The purpose of this chapter is to provide treatment guidelines for the primary vasculitic diseases.

## 2. Giant cell arteritis

Giant cell arteritis is an inflammation of medium- and large-sized arteries that characteristically affects one or more branches of the carotid artery, particularly the temporal artery (Salvarani C et al., 2002), but it is a systemic disease that can affect arteries in multiple locations, particularly the aorta and its main branches. Polymyalgia rheumatica, which is characterized by stiffness, aching, and pain in the muscles of the neck, shoulders, lower back, hips, and thighs, can occur with giant cell arteritis (Langford CA, 2010).

It is very important for patients who are strongly suspected of having giant cell arteritis to be treated immediately in order to protect their vision. When patients show ischemic symptoms, treatment should be started before checking the results of a temporal artery biopsy. A temporal artery biopsy after treatment has begun is exceedingly useful for making a diagnosis (Langford CA, 2010).

The aim of treatment is to improve the symptoms such as headache, jaw claudication, tenderness of scalp, and polymyalgia rheumatica and to prevent complications occurring as a result of vascular occlusion causing tissue infarction.

Glucocorticoids rapidly improve cranial and systemic symptoms and prevent visual complications in patients with giant cell arteritis rapidly. Aiello et al. reported that the probability of loss of vision developing after initiating oral glucocorticoid treatment was determined to be 1% (Aiello PD et al., 1993). The initial dose of prednisone is usually 40 to 60 mg/day (Langford CA, 2010), but the other report has stated that a dose under

40 mg/day is effective in more than 90% of patients (Hashimoto et al., 1999). After an initial dose of 60 mg/day, the dose can usually be decreased to 50 mg/day after 2 weeks and to 40 mg/day after 4 weeks (Langford CA, 2010). After clinical symptoms and laboratory data improve, the dose of prednisone was decreased by approximately 10% of the total daily dose every 1 to 2 weeks (Salvarani C et al., 2002).

Patients with recent or impending visual loss may be treated with initial pulsed intravenous doses of methylprednisolone (1,000 mg every day for three days) (Salvarani C et al., 2002). Corticosteroids may prevent but usually do not reverse visual loss.

Polymyalgia rheumatica can occur in 40% to 60% of patients with giant cell arteritis as a complication. Treatment with 10 to 20 mg/day prednisone can be effective in isolated polymyalgia rheumatica.

If the treatment does not result in improvement of symptoms, giant cell arteritis is suggested as an underlying disease (Langford CA, 2010).

To reduce significant steroid side effects or relapse on tapering the steroid dose, methotrexate is often added to the steroid (Hoffman GS et al., 2002; Jover JA et al., 2001; Mahr AD et al., 2007). A dose of 81 mg/day of aspirin has been reported to decrease the risk of cranial ischemic complications and all patients without a contraindication should be treated by aspirin together with prednisone (Lee MS et al., 2006; Neshor G et al., 2004).

Other drugs, such as cyclophosphamide, azathioprine, and etanercept, have been applied with variable success, although the success rates were generally less than hoped for success.

### 3. Takayasu arteritis

Takayasu arteritis, which has also been known as the *aortic arch syndrome*, is an inflammatory and stenotic disease of medium- and large-sized arteries characterized by a strong predilection for the aortic arch and its branches (Langford CA & Fauci AS, 2008).

For the first 1 to 3 months, patients are treated with 1 mg/kg/day prednisone as an initial dose. After that, the dose is tapered to withdrawal over a 6- to 12-month period (Langford CA, 2010).

If the disease activity persists in spite of treatment with glucocorticoids or the dose of glucocorticoids cannot be tapered, cytotoxic therapy is primarily administered (Langford CA, 2010). Doses of 15 to 25 mg/week methotrexate in combination with glucocorticoids may induce remission and minimize glucocorticoid therapy and toxicity in most of these patients (Hoffman GS et al., 1994). Azathioprine is used for the patients who are steroid-resistant or have severe side effects by glucocorticoids. Cyclophosphamide has been used in patients with Takayasu arteritis refractory to glucocorticoids (Shelhamer JH et al., 1985). In the patients with intractable Takayasu arteritis, anti-TNF therapy may lead to durable remission in a majority of patients and facilitate dose reduction or discontinuation of prednisone and other immunosuppressive therapy (Molloy ES et al., 2008).

Vascular reconstructive surgery or angioplasty are adjunctive therapeutic options in some patients (Gota CE & Mandell BF, 2008).

### 4. Polyarteritis nodosa

Polyarteritis nodosa constitutes a necrotizing inflammation of medium-sized or small arteries (Cox NH et al., 2010; Jennette JC et al., 1994). Polyarteritis nodosa does not show

glomerulonephritis or vasculitis in arterioles, capillaries or venules (Cox NH et al., 2010). Affected patients may have several signs and symptoms involving multiple organ systems (Cox NH et al., 2010). Ischaemia, infarcts and haemorrhage result from the vasculitis and lead to end-organ damage in patient with polyarteritis nodosa (Cox NH et al., 2010).

Therapy for polyarteritis nodosa is still somewhat empiric. If patients have critical organ involvement, such as renal insufficiency, gastrointestinal ischemia, cardiomyopathy, dense peripheral neuropathy, or central nervous system involvement, they should be treated with 2 mg/kg/day cyclophosphamide and glucocorticoids (Gayraud M et al., 2001). In patients who do not have immediate critical organ involvement, glucocorticoids alone may be sufficient therapy. Patients who cannot taper glucocorticoids and are unresponsive to other therapy may be treated by cyclophosphamide with glucocorticoids (Langford CA, 2010).

In patients whose disease is strongly suspected to be caused by streptococcal infection and repeat recurrence, penicillin antibiotics may be given as preventive treatment. But it has not been reported that penicillin antibiotics alone are effective and the efficacy of this therapy has not been proved in randomized trials (Katsuoka K et al., 2008).

Nonsteroidal anti-inflammatory drugs may be administered to polyarteritis nodosa patients with little or no evidence of systemic disease (Katsuoka K et al., 2008).

Vasodilator and antithrombotic agents may be used together with other drugs and have been especially promoted to be used in patients with skin ulcers and necrosis (Choi SW et al., 2006; Gonzalez-Fernandez MA & Garcia-Consuegra J, 2007; Lim MJ et al., 2006; Zulian F et al., 2004; Zulian F et al., 1998).

Dapsone and colchicines may be given to patients who are refractory to other therapy (Guillevin L, 1986; Thompson DM et al., 1976; Vignes S et al., 2005).

When active hepatitis B or C infection is present, an antiviral agent should be part of the treatment regimen, with the goal of containing viral replication and cause seroconversion (Langford CA, 2010).

Glucocorticoids, alone or combined with cyclophosphamide, might be given to patients in combination with apheresis (Guillevin L et al., 2005).

The possibility of drug-induced polyarteritis nodosa syndromes should always be considered. Propylthiouracil, hydralazine, leukotriene inhibitors, sulfasalazine, minocycline, D-penicillamine, ciprofloxacin, phenytoin, and allopurinol are included among the drugs that may cause these symptoms (Gota CE & Mandell BF, 2008).

## 5. Wegener granulomatosis

Wegener granulomatosis is a relatively uncommon, potentially lethal, and multisystem disease characterized by clinical disease involving the upper and lower respiratory tracts and kidneys with histological evidence of granulomatous inflammation, vasculitis of the small- to medium-sized vessels, and a pauci-immune glomerulonephritis (Hoffman GS et al., 1992).

Active Wegener granulomatosis is potentially life-threatening, therefore glucocorticoids combined with a cytotoxic agent are required as initial treatment. Patients with active severe Wegener granulomatosis should initially be treated with 2 mg/kg/day cyclophosphamide and simultaneously with prednisone at 1 mg/kg/day (Langford CA, 2010). After 4 weeks of

treatment, the prednisone is tapered and withdrawn by 6 to 12 months, if the treatment improves the patient's condition. Cyclophosphamide treatment for 3 to 6 months is performed, and then, cyclophosphamide is discontinued and the treatment is switched to a less toxic medication for remission maintenance (Langford CA, 2010). If patients have active but non-severe disease, the treatment by prednisone together with 20 to 25 mg/week methotrexate is effective at inducing and then maintaining remission (De Groot K et al., 2005).

It has been reported that the withdrawal of cyclophosphamide and the substitution of azathioprine after remission did not increase the rate of relapse (Jayne D et al., 2003).

Treatment with trimethoprim-sulfamethoxazole (co-trimoxazole) reduces the incidence of relapse in patients with Wegener's granulomatosis in remission (Stegeman CA et al., 1996).

Plasma exchange increased the rate of renal recovery in patients that presented with renal failure (Jayne DR et al., 2007).

## 6. Microscopic polyangiitis

Microscopic polyangiitis was originally considered to be a branch of polyarteritis nodosa; it includes glomerulonephritis and occasionally pulmonary hemorrhage. According to the Chapel Hill Consensus Conference in 1994, the definition of primary systemic vasculitis (PSV) has become clear, and the disease group included microscopic polyangiitis. Microscopic polyangiitis is a systemic necrotizing vasculitis affecting the small blood vessels or small- to medium-sized arteries.

2 mg/kg/day cyclophosphamide and 1 mg/kg/day prednisone should be given as initial therapy to patients who have life-threatening disease including lung, kidney, and nerve involvement (Langford CA, 2010). The therapy follows the schedule outlined for Wegener granulomatosis. It was reported that the combination therapy with cyclophosphamide and prednisone decreased the frequency of renal failure and recurrence (Hogan SL et al., 1996), and improved survival rates (Gayraud M et al., 2001). However, infectious events were strongly associated with the combination of corticosteroid and cyclophosphamide, and were more frequent in patients older than 65 years (Gayraud M et al., 2001). Moreover, cyclophosphamide increases the incidence rate of bladder cancer and induces gonadal failure dose-dependently. Therefore the remission induction should be followed by azathioprine or methotrexate administration for remission maintenance. Patients with active non-severe disease may be treated with methotrexate for remission and maintenance.

Mychophenolate mofetil (Villiger PM & Guillevin L, 2010), rituximab (Villiger PM & Guillevin L, 2010), trimethoprim-sulfamethoxazole (Jennette JC et al., 2001), plasma exchanges (Villiger PM & Guillevin L, 2010), intravenous immunoglobulins (Villiger PM & Guillevin L, 2010) can also be effective in microscopic polyangiitis, and etanercept has been recommended as well (Keogh KA et al., 2005).

## 7. Churg-strauss syndrome

Churg-Strauss syndrome is a rare systemic necrotizing vasculitis of small- to medium-sized vessels that was first described in the early 1950s. In patients with late-onset asthma it is characterized by vasculitic manifestations, such as fever, cutaneous purpura and

mononeuritis multiplex (Pagnoux C, 2010). In ANCA-associated vasculitides, the prognosis of Churg-Strauss syndrome is better than those of Wegener granulomatosis and microscopic polyangiitis (Guillevin L et al., 1999; Keogh KA & Specks U, 2006).

Systemic administration of steroids is effective in Churg-Strauss syndrome, and many cases show remission by this therapy. Patients are treated by administration of 1 intravenous pulse of methylprednisolone (15 mg/kg) at the start of treatment (Ribi C et al., 2008). Oral prednisone (1 mg/kg/day) is given to patients for 3 weeks. After that, the dose is tapered slowly as the symptoms and laboratory data, especially the eosinophil count, are improving.

Cases that are steroid-resistant or relapse repeatedly by steroid treatment alone are additionally given 2 mg/kg/day cyclophosphamide or 50 to 100 mg/day azathioprine (Gayraud M et al., 2001). However, cyclophosphamide with glucocorticoids should be given early to patients with life-threatening disease (Gayraud M et al., 1997; Guillevin L et al., 1999; Guillevin L & Pagnoux C, 2003; Keogh KA & Specks U, 2006; Noth I et al., 2003; Solans R et al., 2001). To decrease the side effect of cyclophosphamide, cyclophosphamide pulse therapy is recommended (Cohen P et al., 2007; Gayraud M et al., 1997; Guillevin L & Pagnoux C, 2003).

## 8. Cutaneous vasculitis

Cutaneous vasculitis is a frequent and often significant component of many systemic vasculitic syndromes such as lupus or rheumatoid vasculitis and ANCA-associated primary vasculitic syndromes (Carlson JA et al., 2006). It is manifested as urticaria, purpura, hemorrhagic vesicles, ulcers, nodules, livedo, infarcts, or digital gangrene. In most instances, cutaneous vasculitis shows the features of a self-limiting, single-episode phenomenon.

If the primary diseases or exposures are clarified, those are treated first.

If the patients have idiopathic cutaneous vasculitis, glucocorticoids are frequently used.

Other drugs, such as nonsteroidal anti-inflammatory agents, antihistamines, dapsone, hydroxychloroquine, colchicines, and cyclophosphamide, may also be given to the patients. But there is no optimal dosage schedule.

## 9. Cryoglobulinemic vasculitis

Cryoglobulins are cold-precipitable monoclonal or polyclonal immunoglobulins in serum. In the majority of cases of cryoglobulinaemia, the disease remains asymptomatic but immune complexes can form and be deposited in tissues, causing cryoglobulinemic vasculitis (Braun GS et al., 2007; Lamprecht P et al., 1999).

Asymptomatic cryoglobulinemia does not need to be treated. In symptomatic cryoglobulinemia, the treatment of the underlying disease can then proceed. If the underlying disease cannot be determined, it is idiopathic and symptomatic treatment is performed. It is important to determine the particular type of cryoglobulinemia, because the underlying disease may be associated with a particular type.

Because type I cryoglobulins usually are associated with haematological disorders, these disorders are treated preferentially.

Types II and III (mixed) cryoglobulinemias have strong connection with HCV infection (Braun GS et al., 2007). Aggressive antiviral therapy with Peg-IFN $\alpha$  and ribavirin provide

the best opportunity for improvement of HCV-associated cryoglobulinemic vasculitis (Langford CA, 2010; Saadoun D et al., 2008).

Plasmapheresis is performed together with administration of corticosteroids and immunosuppressive drugs in order to prevent production of abnormal protein or to treat primary disease. But it is impractical for long-term treatment (Langford CA, 2010; Siami GA & Siami FS, 1999).

Rituximab, a chimeric monoclonal anti-CD20 antibody, is suitable as a rescue therapy in resistant cryoglobulinemia associated with HCV (Ahmed MS & Wong CF, 2007). Immunosuppressive agents are typically applied in patients with severe disease symptoms such as membranoproliferative glomerulonephritis, severe peripheral or central nervous system neuropathy, severe cutaneous disease, and vasculitis involving vital organs such as the heart or gastrointestinal tract (Vassilopoulos D & Calabrese LH, 2002). Immunosuppressive agents such as cyclophosphamide, azathioprine, cyclosporine, melphalan, chlorambucil, and fludarabine are usually used together with corticosteroids (Vassilopoulos D & Calabrese LH, 2002).

## 10. Henoch-schönlein purpura

Henoch-Schönlein purpura is an acute, self-limited, systemic, small-vessel vasculitis. It predominantly affects children. Clinical presentation of Henoch-Schönlein purpura nephritis in adults is severe and the prognosis is relatively poor, worse than in children (Blanco R et al., 1997; Narchi H, 2005; Pillebout E et al., 2002). Therefore, more active treatment and careful follow up are needed in adults.

The treatment is not required in many cases of Henoch-Schönlein purpura because Henoch-Schönlein purpura is typically characterized by its self-limiting condition (Langford CA, 2010). Treatment with systemic application of glucocorticoids to patients with severe gastrointestinal symptoms is strongly recommended (Gunasekaran TS et al., 2000; Leung SP, 2001; Reinehr T et al., 2000; Ronkainen J et al., 2006). Prednisone does not prevent the development of renal symptoms but treats them effectively (Ronkainen J et al. reported that renal symptoms resolved in 61% of the prednisone-treated patients 80-100 mg/kg/day, compared with 34% of the placebo-receiving patients) (Ronkainen J et al., 2006). Moreover, methylprednisolone pulse therapy is effective in patients at risk of progression of nephropathy, particularly in the cases that started therapy early during the course of the disease before the crescents became fibrous (Niaudet P & Habib R, 1998).

The efficacy of immunosuppressive agents (e.g. cyclophosphamide, cyclosporin A), plasmapheresis, anticoagulant agents and antiplatelet agents is controversial.

Glucocorticoids in combination with each of these treatments can be effective in patients with severe nephritis (Flynn JT et al., 2001; Hattori M et al., 1999; Kawasaki Y et al., 2004; Ronkainen J et al., 2003; Scharer K et al., 1999; Someya T et al., 2004; Tanaka H et al., 2003; Tarshish P et al., 2004; Wyatt RJ & Hogg RJ, 2001; Zaffanello M et al., 2007).

Administration of Factor XIII, tonsillectomy, and dapsone may be useful for the patients with Henoch-Schönlein purpura, but the evidence concerning efficacy is insufficient. Factor XIII concentrate may contribute to abdominal pain relief in Henoch-Schönlein purpura patients (Shimomura N et al., 2005; Utani A et al., 1991).

Tonsillectomy may be useful for alleviating Henoch-Schönlein purpura nephropathy (Hotta O et al., 1996; Inoue CN et al., 2007; Sugiyama H et al., 2005; Tomioka S et al., 1996).

Dapsone therapy may be useful for improving purpura and arthritis (Hoffbrand BI, 1991; Iqbal H & Evans A, 2005; Ramelli GP & Bianchetti MG, 1997; Sarma PS, 1994; Shimomura N et al., 2005).

## 11. Kawasaki disease

Kawasaki disease is an acute multisystem vasculitis of infants and young children. This disease represents the primary cause of acquired heart disease (Barron KS et al., 1999).

For patients in the acute stage of the disease, a single high-dose intravenous immunoglobulin (2 g/kg) in combination with high-dose aspirin (80-100 mg/kg/day) is given (Muta H et al., 2004; Rowley AH & Shulman ST, 2010; Terai M & Shulman ST, 1997). However, patients in Asia are often treated with 80-100 mg/kg/day, because it is believed that 80-100 mg/kg/day of aspirin is excessively toxic in Asian children (Rowley AH & Shulman ST, 2010). Whether it is an advantage to add corticosteroid to this combination therapy is controversial (Inoue Y et al., 2006; Jibiki T et al., 2004; Newburger JW et al., 2007).

About 5-15% of Kawasaki disease patients do not respond to this therapy. A second 2 g/kg dose of intravenous immunoglobulin and a 3-day course of intravenous pulsed methylprednisolone (30 mg/kg/day) can be effective in nonresponders (Freeman AF & Shulman ST, 2004; Rowley AH & Shulman ST, 2010; Sundel RP et al., 1993).

Administration of infliximab to these patients has been reported, but the efficacy is unclear (Burns JC et al., 2008; Burns JC et al., 2005).

Low-dose aspirin (3-5 mg/kg/day) is given to the patients after the acute stage (Rowley AH & Shulman ST, 2010). In order to check the development of coronary aneurysms, an echocardiogram should be performed at 2, 6, and 8 weeks after illness onset (Langford CA, 2010). Close follow-up using ultrasonographic monitoring is needed for the patients with multiple aneurysms, giant aneurysms, or coronary artery obstruction.

## 12. Behçet disease

Behçet disease is a multisystem inflammatory disease with an unknown etiology that affects all types and sizes of blood vessels (Calamia KT & Kaklamanis PG, 2008; Langford CA, 2010; Yazici Y et al., 2010). Treatment of Behçet disease is adjusted depending on the type and severity of symptoms, sex, and age (Yazici Y et al., 2010).

Colchicine, 1.0-2.0 mg/day, can be effective for genital ulcers, erythema nodosum, and arthritis among women, although merely for arthritis in men (Yurdakul S et al., 2001).

Azathioprine, 2.5 mg/kg/day, is able to prevent the progression of Behçet disease, particularly the eye disease (Yazici H et al., 1990).

Cyclosporine is useful in treating ocular manifestations, oral aphthous ulcer, dermal lesions, and genital ulceration (Masuda K et al., 1989). Thalidomide, 100 mg/day, is effective for the oral and genital ulcers and papulopustular lesions (Hamuryudan V et al., 1998).

Interferon alpha-2a improves the duration and pain of oral ulcers and the frequency of genital ulcers and papulopustular lesions (Alpsoy E et al., 2002).

It was reported that tumor necrosis factor  $\alpha$  (TNF  $\alpha$ ) antagonists, which are infliximab, etanercept, and adalimumab, improve symptoms in patients with eye, mucocutaneous, and gastrointestinal involvement, as well as neurological disease, and even pulmonary artery aneurysms (Sfikakis PP et al., 2007).

Corticosteroids are widely used in the treatment of Behçet disease (Yazici Y et al., 2010).



Topical therapy, including glucocorticoids and sucralfate suspension, can be effective for aphthous lesions and mucocutaneous disease (Alpsoy E et al., 1999; Hatemi G et al., 2009). For patients in the early disease stages of pulmonary and peripheral arterial aneurysms, cyclophosphamide pulse therapy and corticosteroids are especially effective (Yazici Y et al., 2010).

### 13. Acknowledgment

We thank for Dr. Koichi Nakagawa, MD, Dr. Yasuhiko Yoshida, MD, Dr. Masaru Kishida, MD, Dr. Aya Kumei, MD, Dr. Takashi Hashimoto, MD, Dr. Hiromi Kobayashi, MD, PhD, and Dr. Masamitsu Ishii, MD, PhD for helping with the preparation of the paper.

### 14. References

- Ahmed, M.S. & Wong, C.F. (2007) Should rituximab be the rescue therapy for refractory mixed cryoglobulinemia associated with hepatitis C? *J Nephrol*, Vol. 20, No. 3, pp. 350-356, ISSN 1121-8428
- Aiello, P.D., Trautmann, J.C., McPhee, T.J., Kunselman, A.R. & Hunder, G.G. (1993) Visual prognosis in giant cell arteritis. *Ophthalmology*, Vol. 100, No. 4, pp. 550-555, ISSN 0161-6420
- Alpsoy, E., Durusoy, C., Yilmaz, E., Ozgurel, Y., Ermis, O., Yazar, S. & Basaran, E. (2002) Interferon alfa-2a in the treatment of Behcet disease: a randomized placebo-controlled and double-blind study. *Arch Dermatol*, Vol. 138, No. 4, pp. 467-471, ISSN 0003-987X
- Alpsoy, E., Er, H., Durusoy, C. & Yilmaz, E. (1999) The use of sucralfate suspension in the treatment of oral and genital ulceration of Behcet disease: a randomized, placebo-controlled, double-blind study. *Arch Dermatol*, Vol. 135, No. 5, pp. 529-532, ISSN 0003-987X
- Barron, K.S., Shulman, S.T., Rowley, A., Taubert, K., Myones, B.L., Meissner, H.C., Peters, J., Duffy, C.E., Silverman, E. & Sundel, R. (1999) Report of the National Institutes of Health Workshop on Kawasaki Disease. *J Rheumatol*, Vol. 26, No. 1, pp. 170-190, ISSN 0315-162X
- Blanco, R., Martinez-Taboada, V.M., Rodriguez-Valverde, V., Garcia-Fuentes, M. & Gonzalez-Gay, M.A. (1997) Henoch-Schonlein purpura in adulthood and childhood: two different expressions of the same syndrome. *Arthritis Rheum*, Vol. 40, No. 5, pp. 859-864, ISSN 0004-3591
- Braun, G.S., Horster, S., Wagner, K.S., Ihrler, S. & Schmid, H. (2007) Cryoglobulinaemic vasculitis: classification and clinical and therapeutic aspects. *Postgrad Med J*, Vol. 83, No. 976, pp. 87-94, ISSN 1469-0756
- Burns, J.C., Best, B.M., Mejias, A., Mahony, L., Fixler, D.E., Jafri, H.S., Melish, M.E., Jackson, M.A., Asmar, B.I., Lang, D.J., Connor, J.D., Capparelli, E.V., Keen, M.L., Mamun, K., Keenan, G.F. & Ramilo, O. (2008) Infliximab treatment of intravenous immunoglobulin-resistant Kawasaki disease. *J Pediatr*, Vol. 153, No. 6, pp. 833-838, ISSN 1097-6833

- Burns, J.C., Mason, W.H., Hauger, S.B., Janai, H., Bastian, J.F., Wohrley, J.D., Balfour, I., Shen, C.A., Michel, E.D., Shulman, S.T. & Melish, M.E. (2005) Infliximab treatment for refractory Kawasaki syndrome. *J Pediatr*, Vol. 146, No. 5, pp. 662-667, ISSN 0022-3476
- Calamia, K.T. & Kaklamanis, P.G. (2008) Behcet's disease: recent advances in early diagnosis and effective treatment. *Curr Rheumatol Rep*, Vol. 10, No. 5, pp. 349-355, ISSN 1534-6307
- Carlson, J.A., Cavaliere, L.F. & Grant-Kels, J.M. (2006) Cutaneous vasculitis: diagnosis and management. *Clin Dermatol*, Vol. 24, No. 5, pp. 414-429, ISSN 0738-081X
- Choi, S.W., Lew, S., Cho, S.D., Cha, H.J., Eum, E.A., Jung, H.C. & Park, J.H. (2006) Cutaneous polyarteritis nodosa presented with digital gangrene: a case report. *J Korean Med Sci*, Vol. 21, No. 2, pp. 371-373, ISSN 1011-8934
- Cohen, P., Pagnoux, C., Mahr, A., Arene, J.P., Mouthon, L., Le Guern, V., Andre, M.H., Gayraud, M., Jayne, D., Blockmans, D., Cordier, J.F. & Guillevin, L. (2007) Churg-Strauss syndrome with poor-prognosis factors: A prospective multicenter trial comparing glucocorticoids and six or twelve cyclophosphamide pulses in forty-eight patients. *Arthritis Rheum*, Vol. 57, No. 4, pp. 686-693, ISSN 0004-3591
- Cox, N.H., Jorizzo, J.L., Bourke, J.F., Savage, C.O.S. (2010) Vasculitis, Neutrophilic Dermatoses and Related Disorders. In: *Rook's Textbook of Dermatology*, Tony Burns, Stephan Breathnach, Neil Cox, Christopher Griffiths, pp. 50. 1, Blackwell Publishing, ISBN 9781405161695, New Jersey
- De Groot, K., Rasmussen, N., Bacon, P.A., Tervaert, J.W., Feighery, C., Gregorini, G., Gross, W.L., Luqmani, R. & Jayne, D.R. (2005) Randomized trial of cyclophosphamide versus methotrexate for induction of remission in early systemic antineutrophil cytoplasmic antibody-associated vasculitis. *Arthritis Rheum*, Vol. 52, No. 8, pp. 2461-2469, ISSN 0004-3591
- Flynn, J.T., Smoyer, W.E., Bunchman, T.E., Kershaw, D.B. & Sedman, A.B. (2001) Treatment of Henoch-Schonlein Purpura glomerulonephritis in children with high-dose corticosteroids plus oral cyclophosphamide. *Am J Nephrol*, Vol. 21, No. 2, pp. 128-133, 0250-8095
- Freeman, A.F. & Shulman, S.T. (2004) Refractory Kawasaki disease. *Pediatr Infect Dis J*, Vol. 23, No. 5, pp. 463-464, ISSN 0891-3668
- Gayraud, M., Guillevin, L., Cohen, P., Lhote, F., Cacoub, P., Deblois, P., Godeau, B., Ruel, M., Vidal, E., Piontud, M., Ducroix, J.P., Lassoued, S., Christoforov, B. & Babinet, P. (1997) Treatment of good-prognosis polyarteritis nodosa and Churg-Strauss syndrome: comparison of steroids and oral or pulse cyclophosphamide in 25 patients. French Cooperative Study Group for Vasculitides. *Br J Rheumatol*, Vol. 36, No. 12, pp. 1290-1297, ISSN 0263-7103
- Gayraud, M., Guillevin, L., le Toumelin, P., Cohen, P., Lhote, F., Casassus, P. & Jarrousse, B. (2001) Long-term followup of polyarteritis nodosa, microscopic polyangiitis, and Churg-Strauss syndrome: analysis of four prospective trials including 278 patients. *Arthritis Rheum*, Vol. 44, No. 3, pp. 666-675, ISSN 0004-3591

- Gonzalez-Fernandez, M.A. & Garcia-Consuegra, J. (2007) Polyarteritis nodosa resistant to conventional treatment in a pediatric patient. *Ann Pharmacother*, Vol. 41, No. 5, pp. 885-890, ISSN 1542-6270
- Gota, C.E. & Mandell, B.F. (2008) Systemic Necrotizing Vasculitis. In: *Fitzpatrick's Dermatology in General Medicine* (Wolff K., Goldsmith L., Katz S. I., Gilchrest B. A., S.Paller A. & Leffell D. J.), (Ed), Vol. 2, pp. 1606-1616. McGraw-Hill, New York.
- Guillevin, L. (1986) Treatment of polyarteritis nodosa with dapsone. *Scand J Rheumatol*, Vol. 15, No. 1, pp. 95-96, ISSN 0300-9742
- Guillevin, L., Cohen, P., Gayraud, M., Lhote, F., Jarrousse, B. & Casassus, P. (1999) Churg-Strauss syndrome. Clinical study and long-term follow-up of 96 patients. *Medicine (Baltimore)*, Vol. 78, No. 1, pp. 26-37, ISSN 0025-7974
- Guillevin, L., Mahr, A., Callard, P., Godmer, P., Pagnoux, C., Leray, E. & Cohen, P. (2005) Hepatitis B virus-associated polyarteritis nodosa: clinical characteristics, outcome, and impact of treatment in 115 patients. *Medicine (Baltimore)*, Vol. 84, No. 5, pp. 313-322, ISSN 0025-7974
- Guillevin, L. & Pagnoux, C. (2003) When should immunosuppressants be prescribed to treat systemic vasculitides? *Intern Med*, Vol. 42, No. 4, pp. 313-317, ISSN 0918-2918
- Gunasekaran, T.S., Berman, J. & Gonzalez, M. (2000) Duodenojejunitis: is it idiopathic or is it Henoch-Schonlein purpura without the purpura? *J Pediatr Gastroenterol Nutr*, Vol. 30, No. 1, pp. 22-28, ISSN 0277-2116
- Hamuryudan, V., Mat, C., Saip, S., Ozyazgan, Y., Siva, A., Yurdakul, S., Zwingenberger, K. & Yazici, H. (1998) Thalidomide in the treatment of the mucocutaneous lesions of the Behcet syndrome. A randomized, double-blind, placebo-controlled trial. *Ann Intern Med*, Vol. 128, No. 6, pp. 443-450, ISSN 0003-4819
- Hatemi, G., Silman, A., Bang, D., Bodaghi, B., Chamberlain, A.M., Gul, A., Houman, M.H., Kotter, I., Olivieri, I., Salvarani, C., Sfikakis, P.P., Siva, A., Stanford, M.R., Stubiger, N., Yurdakul, S. & Yazici, H. (2009) Management of Behcet disease: a systematic literature review for the European League Against Rheumatism evidence-based recommendations for the management of Behcet disease. *Ann Rheum Dis*, Vol. 68, No. 10, pp. 1528-1534, ISSN 1468-2060
- Hattori, M., Ito, K., Konomoto, T., Kawaguchi, H., Yoshioka, T. & Khono, M. (1999) Plasmapheresis as the sole therapy for rapidly progressive Henoch-Schonlein purpura nephritis in children. *Am J Kidney Dis*, Vol. 33, No. 3, pp. 427-433, ISSN 0272-6386
- Hoffbrand, B.I. (1991) Dapsone in Henoch-Schonlein purpura--worth a trial. *Postgrad Med J*, Vol. 67, No. 793, pp. 961-962, ISSN 0032-5473
- Hoffman, G.S., Cid, M.C., Hellmann, D.B., Guillevin, L., Stone, J.H., Schousboe, J., Cohen, P., Calabrese, L.H., Dickler, H., Merkel, P.A., Fortin, P., Flynn, J.A., Locker, G.A., Easley, K.A., Schned, E., Hunder, G.G., Sneller, M.C., Tuggle, C., Swanson, H., Hernandez-Rodriguez, J., Lopez-Soto, A., Bork, D., Hoffman, D.B., Kalunian, K., Klashman, D., Wilke, W.S., Scheetz, R.J., Mandell, B.F., Fessler, B.J., Kosmorsky, G., Prayson, R., Luqmani, R.A., Nuki, G., McRorie, E., Sherrer, Y., Baca, S., Walsh, B., Ferland, D., Soubrier, M., Choi, H.K., Gross, W., Segal, A.M., Ludivico, C. & Puechal, X. (2002) A multicenter, randomized, double-blind, placebo-controlled

- trial of adjuvant methotrexate treatment for giant cell arteritis. *Arthritis Rheum*, Vol. 46, No. 5, pp. 1309-1318, ISSN 0004-3591
- Hoffman, G.S., Kerr, G.S., Leavitt, R.Y., Hallahan, C.W., Lebovics, R.S., Travis, W.D., Rottem, M. & Fauci, A.S. (1992) Wegener granulomatosis: an analysis of 158 patients. *Ann Intern Med*, Vol. 116, No. 6, pp. 488-498, ISSN 0003-4819
- Hoffman, G.S., Leavitt, R.Y., Kerr, G.S., Rottem, M., Sneller, M.C. & Fauci, A.S. (1994) Treatment of glucocorticoid-resistant or relapsing Takayasu arteritis with methotrexate. *Arthritis Rheum*, Vol. 37, No. 4, pp. 578-582, ISSN 0004-3591
- Hogan, S.L., Nachman, P.H., Wilkman, A.S., Jennette, J.C. & Falk, R.J. (1996) Prognostic markers in patients with antineutrophil cytoplasmic autoantibody-associated microscopic polyangiitis and glomerulonephritis. *J Am Soc Nephrol*, Vol. 7, No. 1, pp. 23-32, ISSN 1046-6673
- Hotta, O., Taguma, Y., Yoshizawa, N., Oda, T., Nishiyama, J., Yusa, N., Chiba, S., Horigome, I., Sudo, K. & Tomioka, S. (1996) Long-term effects of intensive therapy combined with tonsillectomy in patients with IgA nephropathy. *Acta Otolaryngol Suppl*, Vol. 523, No. pp. 165-168, ISSN 0365-5237
- Inoue, C.N., Chiba, Y., Morimoto, T., Nishio, T., Kondo, Y., Adachi, M. & Matsutani, S. (2007) Tonsillectomy in the treatment of pediatric Henoch-Schonlein nephritis. *Clin Nephrol*, Vol. 67, No. 5, pp. 298-305, ISSN 0301-0430
- Inoue, Y., Okada, Y., Shinohara, M., Kobayashi, T., Tomomasa, T., Takeuchi, K. & Morikawa, A. (2006) A multicenter prospective randomized trial of corticosteroids in primary therapy for Kawasaki disease: clinical course and coronary artery outcome. *J Pediatr*, Vol. 149, No. 3, pp. 336-341, ISSN 0022-3476
- Iqbal, H. & Evans, A. (2005) Dapsone therapy for Henoch-Schonlein purpura: a case series. *Arch Dis Child*, Vol. 90, No. 9, pp. 985-986, ISSN 1468-2044
- Jayne, D., Rasmussen, N., Andrassy, K., Bacon, P., Tervaert, J.W., Dadoniene, J., Ekstrand, A., Gaskin, G., Gregorini, G., de Groot, K., Gross, W., Hagen, E.C., Mirapeix, E., Pettersson, E., Siegert, C., Sinico, A., Tesar, V., Westman, K. & Pusey, C. (2003) A randomized trial of maintenance therapy for vasculitis associated with antineutrophil cytoplasmic autoantibodies. *N Engl J Med*, Vol. 349, No. 1, pp. 36-44, ISSN 1533-4406
- Jayne, D.R., Gaskin, G., Rasmussen, N., Abramowicz, D., Ferrario, F., Guillevin, L., Mirapeix, E., Savage, C.O., Sinico, R.A., Stegeman, C.A., Westman, K.W., van der Woude, F.J., de Lind van Wijngaarden, R.A. & Pusey, C.D. (2007) Randomized trial of plasma exchange or high-dosage methylprednisolone as adjunctive therapy for severe renal vasculitis. *J Am Soc Nephrol*, Vol. 18, No. 7, pp. 2180-2188, ISSN 1046-6673
- Jennette, J.C. Falk, R.J., Andrassy, K., Bacon, P. A., Churg, J., Gross, W. L., Hagen, E. C., Hoffman, G. S., Hunder, G. G., Kallenberg, C. G. (1994). Nomenclature of systemic vasculitides. Proposal of an international consensus conference, *Arthritis Rheum*, Vol. 37, No. 2, pp. 187-92, ISSN 0004-3591
- Jennette, J.C., Thomas, D.B. & Falk, R.J. (2001) Microscopic polyangiitis (microscopic polyarteritis). *Semin Diagn Pathol*, Vol. 18, No. 1, pp. 3-13, ISSN 0740-2570

- Jibiki, T., Terai, M., Kurosaki, T., Nakajima, H., Suzuki, K., Inomata, H., Terashima, I., Honda, T., Yasukawa, K., Hamada, H. & Kohno, Y. (2004) Efficacy of intravenous immune globulin therapy combined with dexamethasone for the initial treatment of acute Kawasaki disease. *Eur J Pediatr*, Vol. 163, No. 4-5, pp. 229-233, ISSN 0340-6199
- Jover, J.A., Hernandez-Garcia, C., Morado, I.C., Vargas, E., Banares, A. & Fernandez-Gutierrez, B. (2001) Combined treatment of giant-cell arteritis with methotrexate and prednisone. a randomized, double-blind, placebo-controlled trial. *Ann Intern Med*, Vol. 134, No. 2, pp. 106-114, ISSN 0003-4819
- Katsuoka, K., Kawakami, T., Ishiguro, N., Sawada, Y., Chen, K., Aiba, S., Kawana, S., Izaki, S., Furukawa, F., Masuzawa, M., Sato, S. & Morita, E. (2008) *The Japanese Journal of Dermatology*, Vol. 118, No. 11, pp. 2095-2187, ISSN 0021-499X.
- Kawasaki, Y., Suzuki, J. & Suzuki, H. (2004) Efficacy of methylprednisolone and urokinase pulse therapy combined with or without cyclophosphamide in severe Henoch-Schoenlein nephritis: a clinical and histopathological study. *Nephrol Dial Transplant*, Vol. 19, No. 4, pp. 858-864, ISSN 0931-0509
- Keogh, K.A. & Specks, U. (2006) Churg-Strauss syndrome. *Semin Respir Crit Care Med*, Vol. 27, No. 2, pp. 148-157, ISSN 1069-3424
- Keogh, K.A., Wylam, M.E., Stone, J.H. & Specks, U. (2005) Induction of remission by B lymphocyte depletion in eleven patients with refractory antineutrophil cytoplasmic antibody-associated vasculitis. *Arthritis Rheum*, Vol. 52, No. 1, pp. 262-268, ISSN 0004-3591
- Lamprecht, P., Gause, A. & Gross, W.L. (1999) Cryoglobulinemic vasculitis. *Arthritis Rheum*, Vol. 42, No. 12, pp. 2507-2516, ISSN 0004-3591
- Langford, C.A. (2010) Vasculitis. *J Allergy Clin Immunol*, Vol. 125, No. 2 Suppl 2, pp. S216-225, ISSN 1097-6825
- Langford, C.A. & Fauci, A.S. (2008) The Vasculitis Syndromes. In: *Harrison's PRINCIPLES OF INTERNAL MEDICINE Seventeenth Edition* (Fauci A. S., Braunwald E., Kasper D. L., Hauser S. L., Longo D. L., Jameson J. L. & Loscalzo J.), (Ed), Vol. 1, pp. 2119-2131. McGraw-Hill, New York.
- Lee, M.S., Smith, S.D., Galor, A. & Hoffman, G.S. (2006) Antiplatelet and anticoagulant therapy in patients with giant cell arteritis. *Arthritis Rheum*, Vol. 54, No. 10, pp. 3306-3309, ISSN 0004-3591
- Leung, S.P. (2001) Use of intravenous hydrocortisone in Henoch-Schonlein purpura. *J Paediatr Child Health*, Vol. 37, No. 3, pp. 309-310, ISSN 1034-4810
- Lim, M.J., Kwon, S.R., Lee, S. & Park, W. (2006) Rapid improvement of distal vasculitis in PAN related to hepatitis B with alprostadil infusion: a case report. *Rheumatol Int*, Vol. 26, No. 10, pp. 928-932, ISSN 0172-8172
- Mahr, A.D., Jover, J.A., Spiera, R.F., Hernandez-Garcia, C., Fernandez-Gutierrez, B., Lavalley, M.P. & Merkel, P.A. (2007) Adjunctive methotrexate for treatment of giant cell arteritis: an individual patient data meta-analysis. *Arthritis Rheum*, Vol. 56, No. 8, pp. 2789-2797, ISSN 0004-3591
- Masuda, K., Nakajima, A., Urayama, A., Nakae, K., Kogure, M. & Inaba, G. (1989) Double-masked trial of cyclosporin versus colchicine and long-term open study of

- cyclosporin in Behcet's disease. *Lancet*, Vol. 1, No. 8647, pp. 1093-1096, ISSN 0140-6736
- Molloy, E.S., Langford, C.A., Clark, T.M., Gota, C.E. & Hoffman, G.S. (2008) Anti-tumour necrosis factor therapy in patients with refractory Takayasu arteritis: long-term follow-up. *Ann Rheum Dis*, Vol. 67, No. 11, pp. 1567-1569, ISSN 1468-2060
- Muta, H., Ishii, M., Egami, K., Furui, J., Sugahara, Y., Akagi, T., Nakamura, Y., Yanagawa, H. & Matsuishi, T. (2004) Early intravenous gamma-globulin treatment for Kawasaki disease: the nationwide surveys in Japan. *J Pediatr*, Vol. 144, No. 4, pp. 496-499, ISSN 0022-3476
- Narchi, H. (2005) Risk of long term renal impairment and duration of follow up recommended for Henoch-Schonlein purpura with normal or minimal urinary findings: a systematic review. *Arch Dis Child*, Vol. 90, No. 9, pp. 916-920, ISSN 1468-2044
- Nesher, G., Berkun, Y., Mates, M., Baras, M., Rubinow, A. & Sonnenblick, M. (2004) Low-dose aspirin and prevention of cranial ischemic complications in giant cell arteritis. *Arthritis Rheum*, Vol. 50, No. 4, pp. 1332-1337, ISSN 0004-3591
- Newburger, J.W., Sleeper, L.A., McCrindle, B.W., Minich, L.L., Gersony, W., Vetter, V.L., Atz, A.M., Li, J.S., Takahashi, M., Baker, A.L., Colan, S.D., Mitchell, P.D., Klein, G.L. & Sundel, R.P. (2007) Randomized trial of pulsed corticosteroid therapy for primary treatment of Kawasaki disease. *N Engl J Med*, Vol. 356, No. 7, pp. 663-675, ISSN 1533-4406
- Niaudet, P. & Habib, R. (1998) Methylprednisolone pulse therapy in the treatment of severe forms of Schonlein-Henoch purpura nephritis. *Pediatr Nephrol*, Vol. 12, No. 3, pp. 238-243, ISSN 0931-041X
- Noth, I., Streck, M.E. & Leff, A.R. (2003) Churg-Strauss syndrome. *Lancet*, Vol. 361, No. 9357, pp. 587-594, ISSN 0140-6736
- Pagnoux, C. (2010) Churg-Strauss syndrome: evolving concepts. *Discov Med*, Vol. 9, No. 46, pp. 243-252, ISSN 1944-7930
- Pillebout, E., Thervet, E., Hill, G., Alberti, C., Vanhille, P. & Nochy, D. (2002) Henoch-Schonlein Purpura in adults: outcome and prognostic factors. *J Am Soc Nephrol*, Vol. 13, No. 5, pp. 1271-1278, ISSN 1046-6673
- Ramelli, G.P. & Bianchetti, M.G. (1997) Dapsone in cutaneous Henoch-Schonlein syndrome--worth a trial. *Acta Paediatr*, Vol. 86, No. 3, pp. 337, ISSN 0803-5253
- Reinehr, T., Burk, G. & Andler, W. (2000) Does steroid treatment of abdominal pain prevent renal involvement in Henoch-Schonlein purpura? *J Pediatr Gastroenterol Nutr*, Vol. 31, No. 3, pp. 323-324, ISSN 0277-2116
- Ribi, C., Cohen, P., Pagnoux, C., Mahr, A., Arene, J.P., Lauque, D., Puechal, X., Letellier, P., Delaval, P., Cordier, J.F. & Guillevin, L. (2008) Treatment of Churg-Strauss syndrome without poor-prognosis factors: a multicenter, prospective, randomized, open-label study of seventy-two patients. *Arthritis Rheum*, Vol. 58, No. 2, pp. 586-594, ISSN 0004-3591
- Ronkainen, J., Autio-Harmainen, H. & Nuutinen, M. (2003) Cyclosporin A for the treatment of severe Henoch-Schonlein glomerulonephritis. *Pediatr Nephrol*, Vol. 18, No. 11, pp. 1138-1142, ISSN 0931-041X

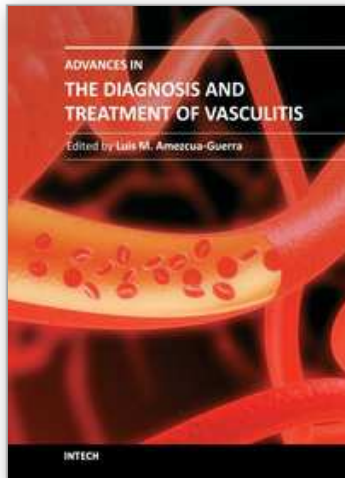
- Ronkainen, J., Koskimies, O., Ala-Houhala, M., Antikainen, M., Merenmies, J., Rajantie, J., Ormala, T., Turtinen, J. & Nuutinen, M. (2006) Early prednisone therapy in Henoch-Schonlein purpura: a randomized, double-blind, placebo-controlled trial. *J Pediatr*, Vol. 149, No. 2, pp. 241-247, ISSN 0022-3476
- Rowley, A.H. & Shulman, S.T. (2010) Pathogenesis and management of Kawasaki disease. *Expert Rev Anti Infect Ther*, Vol. 8, No. 2, pp. 197-203, ISSN 1744-8336
- Saadoun, D., Delluc, A., Piette, J.C. & Cacoub, P. (2008) Treatment of hepatitis C-associated mixed cryoglobulinemia vasculitis. *Curr Opin Rheumatol*, Vol. 20, No. 1, pp. 23-28, ISSN 1040-8711
- Salvarani, C., Cantini, F., Boiardi, L. & Hunder, G.G. (2002) Polymyalgia rheumatica and giant-cell arteritis. *N Engl J Med*, Vol. 347, No. 4, pp. 261-271, ISSN 1533-4406
- Sarma, P.S. (1994) Dapsone in Henoch-Schonlein purpura. *Postgrad Med J*, Vol. 70, No. 824, pp. 464-465, ISSN 0032-5473
- Scharer, K., Krmar, R., Querfeld, U., Ruder, H., Waldherr, R. & Schaefer, F. (1999) Clinical outcome of Schonlein-Henoch purpura nephritis in children. *Pediatr Nephrol*, Vol. 13, No. 9, pp. 816-823, ISSN 0931-041X
- Sfikakis, P.P., Markomichelakis, N., Alpsy, E., Assaad-Khalil, S., Bodaghi, B., Gul, A., Ohno, S., Pipitone, N., Schirmer, M., Stanford, M., Wechsler, B., Zouboulis, C., Kaklamanis, P. & Yazici, H. (2007) Anti-TNF therapy in the management of Behcet's disease--review and basis for recommendations. *Rheumatology (Oxford)*, Vol. 46, No. 5, pp. 736-741, ISSN 1462-0324
- Shelhamer, J.H., Volkman, D.J., Parrillo, J.E., Lawley, T.J., Johnston, M.R. & Fauci, A.S. (1985) Takayasu's arteritis and its therapy. *Ann Intern Med*, Vol. 103, No. 1, pp. 121-126, ISSN 0003-4819
- Shimomura, N., Kawai, K., Watanabe, S., Katsuumi, K. & Ito, M. (2005) Adult Henoch-Schonlein purpura with severe abdominal pain treated with dapsone and factor XIII concentrate. *J Dermatol*, Vol. 32, No. 2, pp. 124-127, ISSN 0385-2407
- Siami, G.A. & Siami, F.S. (1999) Plasmapheresis and paraproteinemia: cryoprotein-induced diseases, monoclonal gammopathy, Waldenstrom's macroglobulinemia, hyperviscosity syndrome, multiple myeloma, light chain disease, and amyloidosis. *Ther Apher*, Vol. 3, No. 1, pp. 8-19, ISSN 1091-6660
- Solans, R., Bosch, J.A., Perez-Bocanegra, C., Selva, A., Huguet, P., Alijotas, J., Orriols, R., Armadans, L. & Vilardell, M. (2001) Churg-Strauss syndrome: outcome and long-term follow-up of 32 patients. *Rheumatology (Oxford)*, Vol. 40, No. 7, pp. 763-771, ISSN 1462-0324
- Someya, T., Kaneko, K., Fujinaga, S., Ohtaki, R., Hira, M. & Yamashiro, Y. (2004) Cyclosporine A for heavy proteinuria in a child with Henoch-Schonlein purpura nephritis. *Pediatr Int*, Vol. 46, No. 1, pp. 111-113, ISSN 1328-8067
- Stegeman, C.A., Tervaert, J.W., de Jong, P.E. & Kallenberg, C.G. (1996) Trimethoprim-sulfamethoxazole (co-trimoxazole) for the prevention of relapses of Wegener's granulomatosis. Dutch Co-Trimoxazole Wegener Study Group. *N Engl J Med*, Vol. 335, No. 1, pp. 16-20, ISSN 0028-4793

- Sugiyama, H., Watanabe, N., Onoda, T., Kikumoto, Y., Yamamoto, M., Maeta, M., Ohara, N., Maeshima, Y., Yamasaki, Y. & Makino, H. (2005) Successful treatment of progressive Henoch-Schonlein purpura nephritis with tonsillectomy and steroid pulse therapy. *Intern Med*, Vol. 44, No. 6, pp. 611-615, ISSN 0918-2918
- Sundel, R.P., Burns, J.C., Baker, A., Beiser, A.S. & Newburger, J.W. (1993) Gamma globulin re-treatment in Kawasaki disease. *J Pediatr*, Vol. 123, No. 4, pp. 657-659, ISSN 0022-3476
- Tanaka, H., Suzuki, K., Nakahata, T., Ito, E. & Waga, S. (2003) Early treatment with oral immunosuppressants in severe proteinuric purpura nephritis. *Pediatr Nephrol*, Vol. 18, No. 4, pp. 347-350, ISSN 0931-041X
- Tarshish, P., Bernstein, J. & Edelmann, C.M., Jr. (2004) Henoch-Schonlein purpura nephritis: course of disease and efficacy of cyclophosphamide. *Pediatr Nephrol*, Vol. 19, No. 1, pp. 51-56, ISSN 0931-041X
- Terai, M. & Shulman, S.T. (1997) Prevalence of coronary artery abnormalities in Kawasaki disease is highly dependent on gamma globulin dose but independent of salicylate dose. *J Pediatr*, Vol. 131, No. 6, pp. 888-893, ISSN 0022-3476
- Thompson, D.M., Heaf, P.J. & Robinsin, T.W. (1976) Australia antigen polyarteritis treated with prednisone and dapsone. *Proc R Soc Med*, Vol. 69, No. 6, pp. 389-390, ISSN 0035-9157
- Tomioka, S., Miyoshi, K., Tabata, K., Hotta, O. & Taguma, Y. (1996) Clinical study of chronic tonsillitis with IgA nephropathy treated by tonsillectomy. *Acta Otolaryngol Suppl*, Vol. 523, No. pp. 175-177, ISSN 0365-5237
- Utani, A., Ohta, M., Shinya, A., Ohno, S., Takakuwa, H., Yamamoto, T., Suzaki, T. & Danno, K. (1991) Successful treatment of adult Henoch-Schonlein purpura with factor XIII concentrate. *J Am Acad Dermatol*, Vol. 24, No. 3, pp. 438-442, ISSN 0190-9622
- Vassilopoulos, D. & Calabrese, L.H. (2002) Hepatitis C virus infection and vasculitis: implications of antiviral and immunosuppressive therapies. *Arthritis Rheum*, Vol. 46, No. 3, pp. 585-597, ISSN 0004-3591
- Vignes, S., Stoyanova, M., Vasseur, E., Haicault de la Regontais, G. & Hanslik, T. (2005) [Reversible lower limb lymphedema as the first manifestation of cutaneous periarthritis nodosa]. *Rev Med Interne*, Vol. 26, No. 1, pp. 58-60, ISSN 0248-8663
- Villiger, P.M. & Guillevin, L. (2010) Microscopic polyangiitis: Clinical presentation. *Autoimmun Rev*, Vol. 9, No. 12, pp. 812-819, ISSN 1873-0183
- Wyatt, R.J. & Hogg, R.J. (2001) Evidence-based assessment of treatment options for children with IgA nephropathies. *Pediatr Nephrol*, Vol. 16, No. 2, pp. 156-167, ISSN 0931-041X
- Yazici, H., Pazarli, H., Barnes, C.G., Tuzun, Y., Ozyazgan, Y., Silman, A., Serdaroglu, S., Oguz, V., Yurdakul, S., Lovatt, G.E. & et al. (1990) A controlled trial of azathioprine in Behcet's syndrome. *N Engl J Med*, Vol. 322, No. 5, pp. 281-285, ISSN 0028-4793
- Yazici, Y., Yurdakul, S. & Yazici, H. (2010) Behcet's syndrome. *Curr Rheumatol Rep*, Vol. 12, No. 6, pp. 429-435, ISSN 1534-6307



- Yurdakul, S., Mat, C., Tuzun, Y., Ozyazgan, Y., Hamuryudan, V., Uysal, O., Senocak, M. & Yazici, H. (2001) A double-blind trial of colchicine in Behcet's syndrome. *Arthritis Rheum*, Vol. 44, No. 11, pp. 2686-2692, ISSN 0004-3591
- Zaffanello, M., Brugnara, M. & Franchini, M. (2007) Therapy for children with henoch-schonlein purpura nephritis: a systematic review. *ScientificWorldJournal*, Vol. 7, No. pp. 20-30, ISSN 1537-744X
- Zulian, F., Corona, F., Gerloni, V., Falcini, F., Buoncompagni, A., Scarazatti, M., Martini, G. & Zacchello, F. (2004) Safety and efficacy of iloprost for the treatment of ischaemic digits in paediatric connective tissue diseases. *Rheumatology (Oxford)*, Vol. 43, No. 2, pp. 229-233, ISSN 1462-0324
- Zulian, F., Costantini, C., Montesco, M.C., Schiavon, F. & Zacchello, F. (1998) Successful treatment of gangrene in systemic necrotizing vasculitis with iloprost. *Br J Rheumatol*, Vol. 37, No. 2, pp. 228-230, ISSN 0263-7103

IntechOpen



## **Advances in the Diagnosis and Treatment of Vasculitis**

Edited by Dr. Luis M Amezcua-Guerra

ISBN 978-953-307-786-4

Hard cover, 366 pages

**Publisher** InTech

**Published online** 09, November, 2011

**Published in print edition** November, 2011

This book represents the culmination of the efforts of a group of outstanding experts in vasculitis from all over the world, who have endeavored to draw themselves into this volume by keeping both the text and the accompanying figures and tables lucid and memorable. The book provides practical information about the screening approach to vasculitis by laboratory analysis, histopathology and advanced image techniques, current standard treatment along with new and more specific interventions including biologic agents, reparative surgery and experimental therapies, as well as miscellaneous issues such as the extra temporal manifestations of "temporal arteritis" or the diffuse alveolar hemorrhage syndrome. The editor and each of the authors invite you to share this journey by one of the most exciting fields of the medicine, the world of Vasculitis.

### **How to reference**

In order to correctly reference this scholarly work, feel free to copy and paste the following:

Hisayoshi Imanishi and Daisuke Tsuruta (2011). Treatment of Different Types of Vasculitis, *Advances in the Diagnosis and Treatment of Vasculitis*, Dr. Luis M Amezcua-Guerra (Ed.), ISBN: 978-953-307-786-4, InTech, Available from: <http://www.intechopen.com/books/advances-in-the-diagnosis-and-treatment-of-vasculitis/treatment-of-different-types-of-vasculitis>

**INTECH**  
open science | open minds

### **InTech Europe**

University Campus STeP Ri  
Slavka Krautzeka 83/A  
51000 Rijeka, Croatia  
Phone: +385 (51) 770 447  
Fax: +385 (51) 686 166  
[www.intechopen.com](http://www.intechopen.com)

### **InTech China**

Unit 405, Office Block, Hotel Equatorial Shanghai  
No.65, Yan An Road (West), Shanghai, 200040, China  
中国上海市延安西路65号上海国际贵都大饭店办公楼405单元  
Phone: +86-21-62489820  
Fax: +86-21-62489821

© 2011 The Author(s). Licensee IntechOpen. This is an open access article distributed under the terms of the [Creative Commons Attribution 3.0 License](#), which permits unrestricted use, distribution, and reproduction in any medium, provided the original work is properly cited.

IntechOpen

IntechOpen