

# We are IntechOpen, the world's leading publisher of Open Access books Built by scientists, for scientists

4,800

Open access books available

122,000

International authors and editors

135M

Downloads

Our authors are among the

154

Countries delivered to

TOP 1%

most cited scientists

12.2%

Contributors from top 500 universities



WEB OF SCIENCE™

Selection of our books indexed in the Book Citation Index  
in Web of Science™ Core Collection (BKCI)

Interested in publishing with us?  
Contact [book.department@intechopen.com](mailto:book.department@intechopen.com)

Numbers displayed above are based on latest data collected.

For more information visit [www.intechopen.com](http://www.intechopen.com)



# Alternative Surgical Management of Ascending Aorta Aneurysm

Sossio Perrotta<sup>1</sup> and Salvatore Lentini<sup>2</sup>

<sup>1</sup>*Department of Cardiothoracic Surgery, Sahlgrenska University Hospital, Gothenburg*

<sup>2</sup>*Department of Cardiothoracic Surgery, University Hospital "G Martino",  
University of Messina, Messina*

<sup>1</sup>*Sweden*

<sup>2</sup>*Italy*

## 1. Introduction

The standard treatment for an ascending aorta aneurysm is radical resection and interposition of a tubular prosthesis.

Involvement of other adjacent structures has dictated the employment of more complex surgical techniques. The surgical treatment of concomitant disease of the aortic valve, aortic root and ascending aorta started in 1968 with Bentall and De Bono (Bentall & De Bono, 1968), who applied a new surgical technique bearing their names and that represents the standard surgical technique for this pathology. With this technique, the valve, aortic root and ascending aorta are resected, replaced with a prosthetic valvular conduit, and the coronary vessels are anastomosed to the tubular prosthesis. Nowadays, this represents a widely accepted surgical strategy to treat concomitant disease at the three mentioned structures. Minimally invasive procedures have been reported in the treatment of these patients as well (Perrotta et al., 2008; Perrotta & Lentini, 2009).

In contrast, treatment of moderate ascending aorta dilatation associated with aortic valvular disease and with or without mild involvement of the aortic root is still controversial, especially in high risk patients (Bahnsen, 1982; Prenger et al., 1994; Svensson et al., 1992).

While it is usually accepted that ascending aorta dilatation beyond 5 cm should be surgically replaced, opinions on the treatment below this limit are divided (Ergin et al., 1999). In older and high surgical risk patients, several conservative surgical techniques on the ascending aorta have been proposed, such as the "waistcoat" aortoplasty, the simple aortoplasty, the "S" shape aortoplasty and the "wrap" aortoplasty (Robicsek & Thubrikar, 1994; Mueller et al., 1997).

Radical resection of the ascending aortic aneurysm is needed in order to eliminate all the pathologic tissue of the aorta damaged by degenerative processes, such as cystic medionecrosis, atherosclerosis, and inflammatory processes. Lack of resecting part of the degenerative tissue may predispose to new aneurysmatic dilatation.

## 2. Histology and pathophysiology in aortic aneurysms

In the presence of mild to moderate dilatation of the ascending aorta associated with aortic valve disease, it may be difficult to ascertain if the dilatation is secondary to the hemodynamic alterations produced by the valvulopathy or by a disease of the aortic wall.

Preoperative and intraoperative studies may help to evaluate the structure of the aortic wall in relation to its thickness, elasticity and endothelium continuity. This can be done through a macroscopic analysis or through an intraoperative histopathologic evaluation on a cryostatic section of the aortic wall (Roman et al., 1989; Imaizumi et al., 1982).

The most frequent histological finding in patients with dilatation of the ascending aorta is cystic medionecrosis. However, results from histology may be very different and it is often difficult to distinguish the primary cause of dilatation (Mueller et al., 1997; Schlatmann & Becker, 1997a, 1997b; Hirst & Gore, 1976). In cystic medionecrosis it is possible to observe necrosis of the smooth muscular cells and a mucoid degeneration of the media, with accumulation of amorphous mucopolysaccharidic material in the vessel wall. Several authors (Schlatmann & Becker, 1997a; Klima et al., 1983) have observed that this is not a specific finding in patients with aortic ectasia and that positive-alcian basophile material is also present in the media of normal aortas. Furthermore, they noticed that the aortic alterations and their entities are mostly related to the patient's age and that there are more quantitative than qualitative differences between the analysed sections of normal aortas and the aneurysmatic or dissected ones. With aging, in normal aortas it is possible to observe fragmentation of the elastine, fibrosis, reduction of muscular cells and mucopolysaccharides. This may suggest that histological alterations in the aortic wall are not the expression of a degenerative disease, but the consequence of the metabolic activity of the media as a response to hemodynamic stress. With time, the hemodynamic stress prevails on the metabolic reparative processes. This process happens faster in patients with hereditary connective diseases (i.e. Marfan syndrome), in which the metabolic reparative mechanism is genetically malfunctioning.

Giving strength to the theory of hemodynamic stress, is the observation that the dilatation is more frequently localized on the lateral segment of the ascending aorta and on the aortic arch. The hemodynamic stress can be associated with an aortic valve disease. In these patients, a dilatation of the ascending aorta of various entities has been observed regardless of the presence of degenerative disease (Carrel et al., 1991).

Patients with a mild or moderate dilatation of the ascending aorta in association with an aortic valve disease often undergo only aortic valve replacement (Prenger et al., 1994; Natsuaki et al., 1998), believing it is not necessary to replace the ascending aorta. In patients with aortic valve stenosis, the replacement of the aortic valve, reducing systolic blood flow produced by the valve stenosis, eliminates the hemodynamic turbulence in the ascending aorta (Yearwood et al., 1989; Jarchow & Kincaid, 1961; Stein & Sabbah, 1976). Similarly, the surgical correction of an aortic valve insufficiency reduces the systolic hypertension and the diastolic ventricular turbulences, restoring the normal blood pressure and blood flow (Stein & Sabbah, 1976; Laske et al., 1996). In both situations the hemodynamic stress on the aortic wall is reduced (Schlatmann & Becker, 1997b; Crawford et al., 1988).

However, the removal of hemodynamic factors may not be sufficient to prevent further dilatation of the ascending aorta, and further dilatation may slowly progress according to the Laplace law (Natsuaki et al., 1998; Milano et al., 1998). For this reason, several surgical techniques of aortoplasty have been proposed in order to prevent this occurrence; some techniques modify only the aortic diameter without reinforcing (McCready & Pluth, 1979) the vessel, others instead reinforce (Robicsek, 1982) the vessel to prevent redilatation.

The efficacy of this technique is still under question since complications and redilatation may occur at follow up. These controversial results may be related to the extreme heterogeneity of the enrolled patients in the literature reports; some had aneurysms of the

ascending aorta without aortic valve disease, others ascending aorta dissection or Marfan disease (Robicsek & Thubrikar, 1994; Carrel et al., 1991; Natsuaki et al., 1998; Barnett et al., 1995). These last clinical conditions are usually associated with a high frequency of redilatation (Kouchoukos et al., 1986; Carrel et al., 1993; Lawrie et al., 1993). For this reason, an accurate selection of patients and a correct surgical indication is mandatory in patients who are candidates for aortoplasty surgery.

### 3. Conservative treatment of an ascending aorta aneurysm

The conservative surgical treatment for an ascending aorta aneurysm takes its origin not as an elective treatment of mild or moderate dilatation of the ascending aorta, but as a surgical alternative to the traditional radical technique of resection with a tubular (Wheat et al., 1964; Ggoves et al., 1964) or a tubular valvular graft (Bentall & De Bono, 1968; Cabrol et al., 1986) (Figure 1).

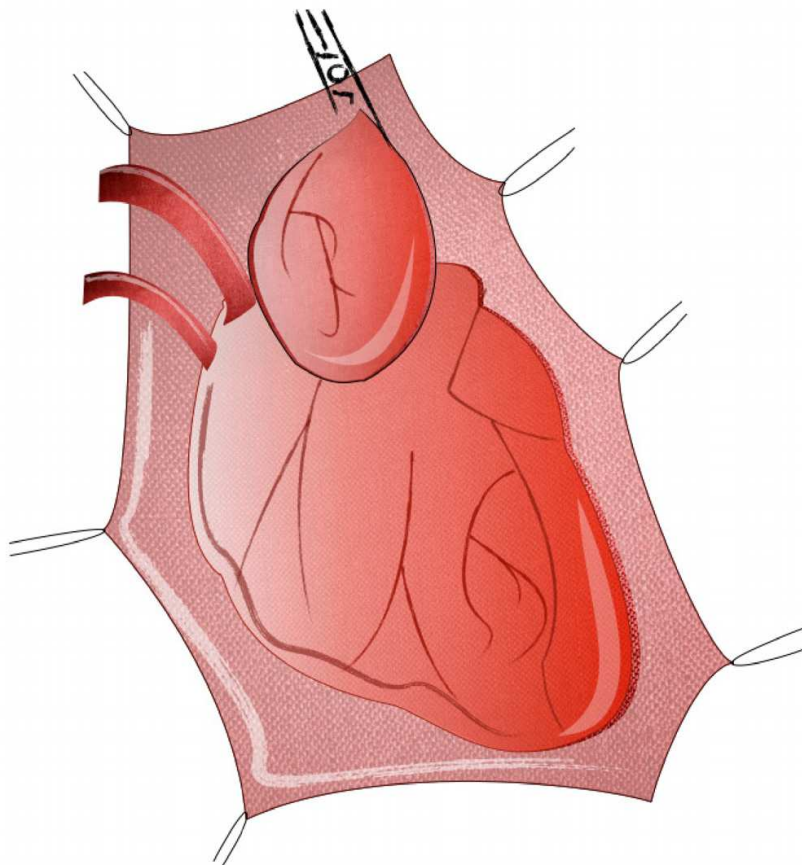


Fig. 1. Dilatation of the ascending aorta. The patient is cannulated according to standard technique; the arterial cannula is placed into the ascending aorta or aortic arch, while the venous cannula is in the right atrium. The ascending aorta is clamped before the brachiocephalic truncus. The aortic vent can be positioned according to the surgeon's preference.

It was McCready and Pluth (McCready & Pluth, 1979), who in 1979 reported the first conservative surgical technique for the treatment of an aneurysm of the ascending aorta, the so-called "simple aortoplasty" (Figure 2). They proposed an oval and longitudinal resection of the anterior wall of the ascending aorta. The aortotomy was sutured with a continuous double layer suture and in some cases reinforced by Teflon strips. In 1982, Robicsek (Robicsek, 1982) suggested his technique of aortoplasty, the so-called "external grafting" or "aortic wrap" (Figure 3), for the treatment of small aneurysms of the abdominal and thoracic aorta, and fusiform dilatation of the ascending aorta with associated valvular disease. The surgical procedure is similar to the one proposed by McCready, with an oval and longitudinal resection of the ascending aorta. The aorta is then reinforced by the application of a tubular prosthesis around the ascending aorta. The prosthesis is incised longitudinally and shaped around the vessel. The prosthesis is then stabilized by placing three sutures.

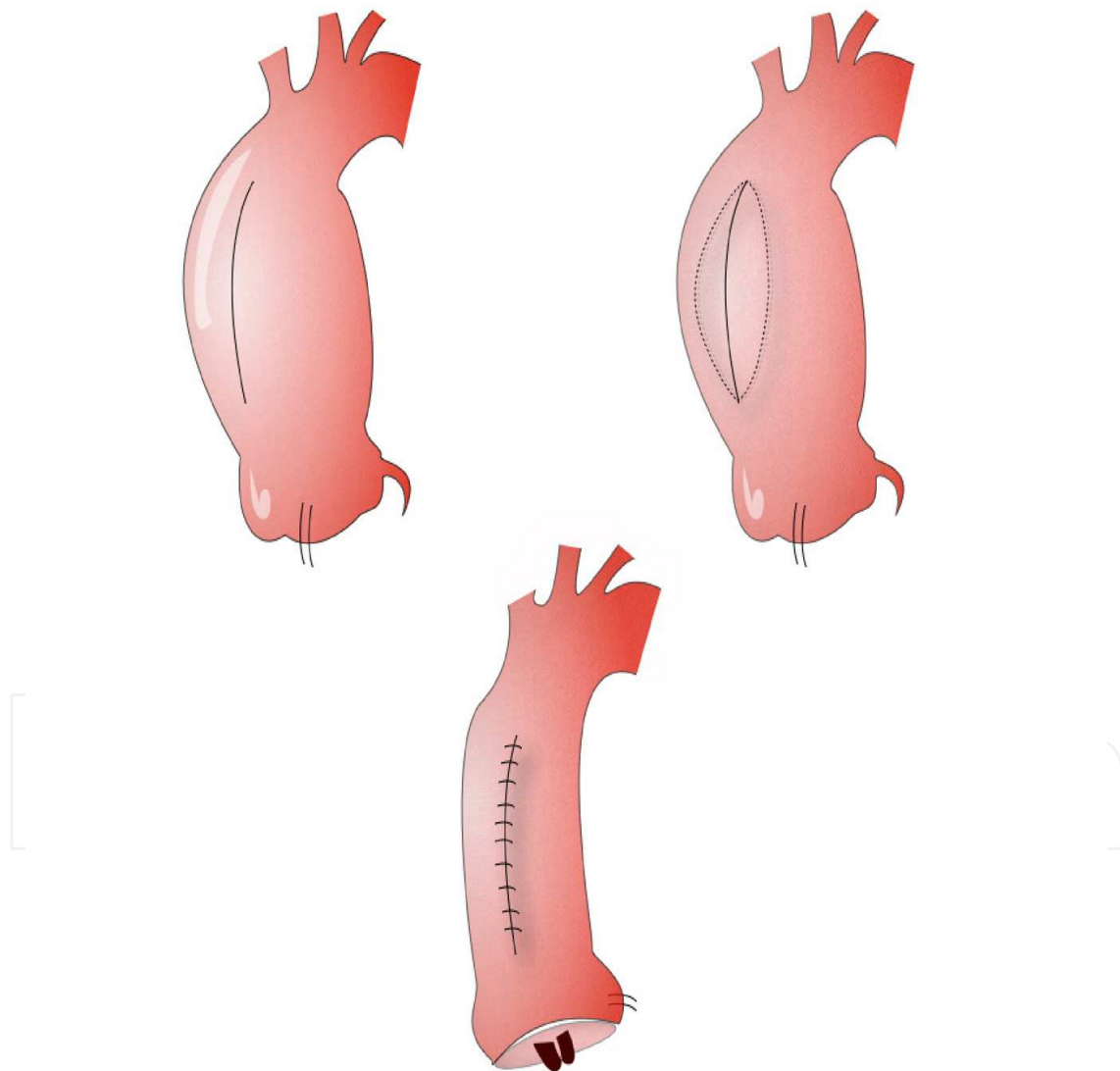


Fig. 2. "Simple aortoplasty". The ascending aorta is incised longitudinally and then an oval and longitudinal resection of the anterior wall of the ascending aorta is performed. The aortotomy can be sutured with a continuous double layer suture, or can be reinforced with Teflon felts.

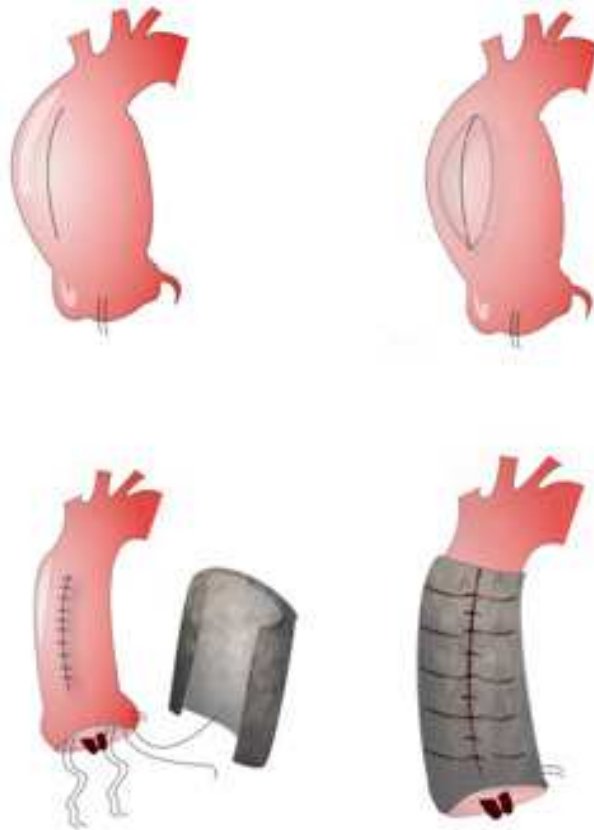


Fig. 3. “Aortic wrap aortoplasty”. The surgical procedure is similar to the “simple aortoplasty”. The aorta is then reinforced by the application of a tubular prosthesis around the ascending aorta. The prosthesis is incised longitudinally and shaped around the vessel. The prosthesis is then stabilized by placing three sutures at the level of the three commissures.

The results reported in the literature, both for the simple aortoplasty and for the aortic wrapping, are heterogeneous. However, most report advantages in using a conservative approach rather than radical surgery in selected cases (Carrel et al., 1991; Barnett et al., 1995).

The aortic cross clamp time and the extracorporeal circulation time are usually shorter, and this may represent an important factor in older patients requiring additional cardiac surgical procedures (Robicsek & Thubrikar, 1994; Mueller et al., 1997; Baumgartner et al., 1998).

Results from studies reporting on conservative treatment of the ascending aorta are summarized in the next paragraph.

#### 4. Results from previous published studies

Egloff (Egloff et al., 1982), in his study, compared the results of aortoplasty surgery (both simple aortoplasty and wrapping technique) with radical surgery. He found that the incidence of cerebrovascular thromboembolic events is higher in patients undergoing radical surgery than in those undergoing conservative surgery. However, it should be mentioned that in his report, Egloff included a heterogeneous study population. Half of the

patients had an acute or chronic ascending aorta dissection, while the other half had a dilatation of the ascending aorta of various entities and not always associated with an aortic valve disease. In 15% of the patients the aneurysm was related to Marfan syndrome, while in 4% of the population the aneurysm was related to syphilitic disease. There was not a specific indication for the type of surgery performed in relation to the specific pathology. This lack of specific indication may partly explain the higher incidence of redilatation of the ascending aorta after aortoplasty than after radical surgery.

Carrel (Carrel et al., 1991) reported the results of 291 patients who underwent cardiac surgery and concomitant surgery on the ascending aorta. The surgical procedures employed were aortic remodeling and external wall support in 164 patients, composite graft replacement in 81 patients and supracoronary graft in 46 patients. Elective, urgent and emergent operations were included in the study. The overall mortality was 4.8%, and he showed good results, at both medium and long term. Compared to the graft replacement and supracoronary graft, the aortoplasty group had the lowest early mortality rates (1.8% vs 9.8% vs 6.4%). The 5 and 10 year survival in the groups of patients undergoing aortic remodelling and external wall support, supracoronary graft and composite graft were, respectively, 93.5%, 82% and 80% and 83.8%, 73% and 67%. The incidence of reoperation at 10 years was 3.6% versus 2.4 %, respectively, in the group of patients that underwent conservative surgery and in the group with composite graft. The incidence of postoperative bleeding was higher in patients undergoing radical surgery rather than conservative surgery.

Barnett (Barnett et al., 1995) in 1995 evaluated the effectiveness of tailoring aortoplasty used to treat fusiform aneurysms of the ascending aorta. He reviewed results on 17 patients, of which nine had tailoring aortoplasty alone, and eight patients had aortoplasty and Dacron wrapping. In his study the author included patients with aortic valve disease associated with an aneurysm of the ascending aorta, with sizes ranging from 5 to 8 cm, confined to the tubular portion of the ascending aorta that narrowed to a normal diameter in the distal ascending aorta and with a normal diameter of the sinuses of Valsalva. All the patients underwent concomitant cardiac surgery procedures. The actuarial survival at 1 and 10 years was 81% and 63%, respectively. He concluded that in selected cases, tailoring aortoplasty can achieve long-term results comparable to those of resection and graft replacement of fusiform ascending aortic aneurysms. At the follow up (mean 4.4 years), the ascending aorta was studied with chest radiography alone without reporting any redilatation of the ascending aorta. This represents a limiting factor of the study, since the diagnosis of redilatation is important for defining the technique efficacy.

Mueller (Mueller et al., 1997), in 1997, reported on 17 consecutive patients treated by unsupported aortoplasty for an aneurysm of the ascending aorta associated with aortic valve disease. Twelve patients had predominantly regurgitation of the aortic valve, and 5 patients had stenosis. The ascending aorta diameter ranged from 5 to 5.5 cm. In 6 elderly and high-risk patients, the aorta was between 5.5 and 6 cm in diameter. He reported a hospital mortality of 12%. Survival at 7 years was 86.7%. Recurring aortic aneurysms, requiring reoperation, developed in 4 patients after a mean time of 63 months, with an event-free survival at 7 years of 41%. All of these 4 patients had aortic valve regurgitation and cystic medial necrosis. The author concludes that the high recurrence of aorta ascending aneurysm after aortoplasty in patients with aortic valve regurgitation is due to an intrinsic deficiency of the aortic wall.

In 1998 Baumgartner (Baumgartner et al., 1998) developed a modification of the reduction aortoplasty procedure as a modified “Z-plasty” (Figure 4) without the use of additional external prosthetic wrapping material. The aortoplasty was performed when moderately sized ascending aortic aneurysms were encountered during concomitant cardiac operations. The incision was S-shaped and on the lateral aspect of the ascending aorta, with biased excision of tissue predominantly in the bends of the “S”. The aorta was then sutured using a double running suture. The procedure was performed in 23 patients with moderate ascending aorta aneurysms, the mean diameter being  $5.0 \pm 0.7$  cm, and not involving the sinuses of Valsalva; none had Marfan syndrome. Sixteen patients were studied with echocardiography at a mean follow-up of  $9.9 \pm 12.6$  months. Their mean intraoperative postreduction diameter was  $2.9 \pm 0.65$  cm, at the follow-up the aorta was  $3.1 \pm 0.45$  cm ( $p = \text{NS}$ ). Of these, seven had a mean follow-up of  $22.1 \pm 9.2$  months. Their mean postreduction diameter of  $2.9 \pm 0.5$  cm increased to  $3.1 \pm 0.35$  cm (NS). The author says that this simple technique places stress on the suture line in a favorable orientation, it appears to have good mid-term results and it is best suited to moderately sized aneurysms.

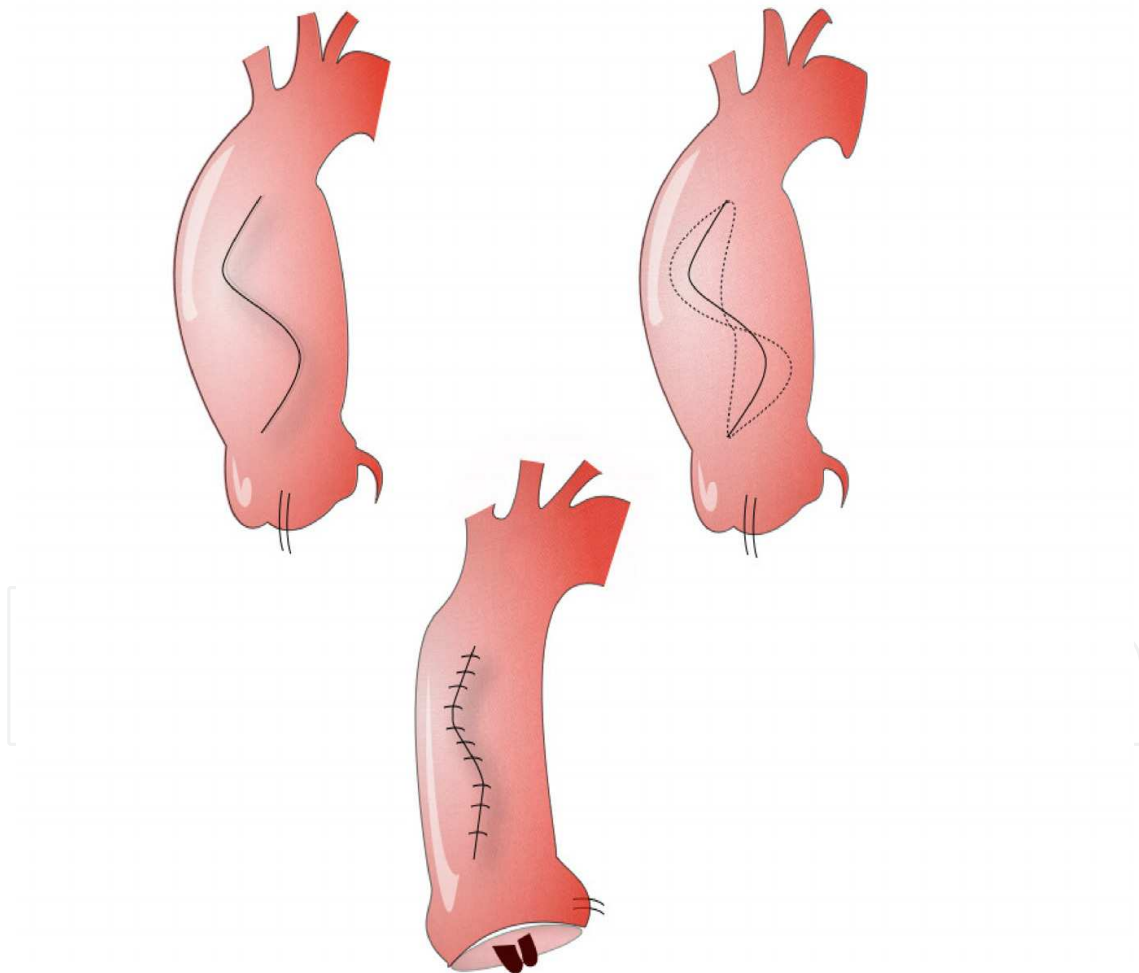


Fig. 4. “Z-plasty” aortoplasty. The incision of the ascending aorta is based on an “S-shape incision” and on the lateral aspect of the ascending aorta, with biased excision of tissue predominantly in the bends of the “S”. The aorta is then sutured using a double running suture.



In 2002 Bauer (Bauer et al., 2002) reported of a total of 115 patients (36 female, 79 male) with bicuspid aortic valve and dilatation of the ascending aorta who underwent reduction aortoplasty alone or in combination with another cardiac procedure. In 106 patients (group I), reduction aortoplasty, "simple aortoplasty", was performed without additional external prosthetic support of the aortic wall. In the remaining 9 patients (group II), the aorta was externally supported by wrapping the ascending aorta with a prosthetic graft. None of the patients had characteristics of Marfan syndrome, as this surgical technique should be considered contraindicated in patients with this syndrome. The patients were postoperatively studied with CT and echocardiography during a mean follow-up time of 40 months (range 12 to 144 months). No reoperations on the ascending aorta or aortic valve during the follow-up period were reported. The 5-year survival rate was  $94\% \pm 3.1\%$ . During the late follow-up, a significant increase ( $> 4$  mm) of the ascending aortic diameter was found in 9 patients (8.9%) from group I and in none from group II. The author observed that a factor that influenced the redilatation was the early postreduction diameter. He suggested that to avoid redilatation, the diameter of the ascending aorta should be reduced to 35 mm or less or the aorta should be supported externally by a tubular graft.

Viganó (Viganó et al., 2002), in 2002, reported the description of a different conservative surgery on the ascending aorta, named "end-to-end anastomosis" (Figure 5), designed for patients undergoing a ministernotomy approach for ascending aortic aneurysm with minor involvement of the sinotubular junction. He reported on 45 patients with a diagnosis of chronic ascending aorta aneurysm, including also patients with type A aortic dissection. To reduce the aneurysmatic section of the aorta he suggested performing two circumferential aortotomies: the first at the level of the sinotubular junction and the second at the distal border of the aneurysm. At this stage aortic valve surgery could be performed, if needed. The resulting resected wall is a cuneiform segment of the ascending aorta, that if opened on its anterior aspect, assumes a typical butterfly shape. Finally the two ends of the ascending aorta are sutured together with a running suture, eventually reinforced by Teflon strips. Patients were studied with computed tomography and echocardiography. During the follow-up period ( $23.7 \pm 12.3$  months) a very low redilatation rate (1 of 43; 2.3%) and no incidence of pseudoaneurysm were reported; 1 patient required reoperation.

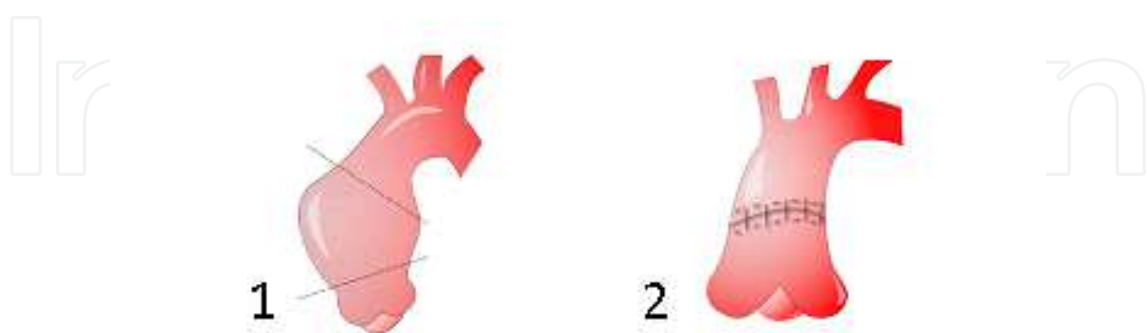


Fig. 5. After clamping the ascending aorta, distally to the aneurysm, the aorta is opened and then resected between two circumferential aortotomies: first at level of sinotubular junction and second at distal edge of aneurysm (1). Two ends of aorta, without tension, are finally sutured with a continuous (2).

Later, Masetti (Masetti et al., 2004), in a smaller series of patients undergoing “end-to-end anastomosis” suggested a modification of the previously described technique with the aim to facilitate the surgical approach. The horizontal aorta is largely mobilized, mainly by dissecting the first portion of supra-aortic trunks and by dissecting pericardial reflections adjacent to the inferior vena cava and left atrium. Then, after clamping the ascending aorta and resecting the aneurysm by two circumferential aortotomies, the two aortic ends may be sutured together with a reduced tension. The patients were postoperatively studied with CT scan during a median follow-up time of 72 months per patient ( $10.5 \pm 102.7$  months). At the follow-up, the mean aortic diameters showed no statistically significant enlargement when compared with the findings of aortic contrast CT scan at discharge. The author concludes that cuneiform resection of the aorta ascendens and end-to-end anastomosis provides effective long-term outcomes. This technique should be used only in patients with ascending aorta aneurysm associated with structural aortic valve disease. Patients with Marfan syndrome or other inherited connective tissue disorders should be not considered for this treatment.

Gaeta (Gaeta et al., 2009), in a recent report focused on some surgical details of the “end to end technique”, reported on specific anatomic indications for this type of surgery. He recommended a preoperative CT scan spatial reconstruction of the thoracic aorta. The ideal candidate for this technique has “an elongated aorta in the antero-lateral wall; the postero-medial wall is usually restrained by the pulmonary artery and it maintains the original length”.

Cotrufo (Della Corte et al., 2003; Cotrufo et al., 2003), in 2003, reported the results of 73 patients with a non-complicated dilatation of the ascending aorta associated with aortic valve structural disease, who underwent aortic valve replacement and “waistcoat aortoplasty”; some of these patients underwent plication of the sinuses of Valsalva as well. The surgical indication for associated aortoplasty was an aortic ratio  $>1.5$  at either sinus, tubular, or both levels. The aorta was incised longitudinally, starting from the aortic clamp towards the commissure between the right coronary sinus and the non-coronary sinus. At above 2 cm before reaching the commissure, the incision was deflected at an angle of  $90^\circ$  and continued towards the commissure between the left coronary and the non-coronary sinus. A triangular resection of the dilated aortic wall was then obtained by extending the incision from above the commissure to the distal end of the incision. At this point, surgery on the aortic valve was performed according the surgeon’s preference. In patients with associated dilatation of the aortic sinuses, in order to treat the dilatation of the aortic sinuses and to remodel the aortic root geometry, each stitch bite placed on the aortic annulus, included the redundant subcoronary portion of the aortic wall. When implanting the prosthesis, and drawing the stitches tight, a bidimensional, longitudinal and radial plication of the three sinuses was achieved, thereby reducing the distance between the coronary ostia and the aortic annulus. The aorta was reconstructed using a double layer technique termed a “waistcoat aortoplasty”. A first suture line fixed the right posterolateral free edge of the resection to the inner surface of the anterior wall, leaving a 1 to 2 cm wide anterior lap. The anterior lap was then used to cover and reinforce the neo-aortic wall, and its free margin was sutured on the right posterior wall (Figure 6 to 8). At follow-up, the ascending aorta was studied with echocardiography. The author reports that a significant postoperative reduction of Valsalva sinuses, sinustubular and ascending aorta diameters were found compared to the preoperative values. In 53 patients at a mean follow-up of  $33.8 \pm 10.2$  months, there was no significant enlargement of the aorta compared to 48 h postoperatively ( $P=0.32$ ,  $P=0.15$ ,  $P=0.38$  respectively). Furthermore, no cases of postoperative aneurysm or

aortic valve complications were recorded and the sinus plication did not interfere with the prosthesis leaflet movements. The author assesses that the “waistcoat aortoplasty”, reducing the diameter of the ascending aorta and reinforcing the aortic wall, is indicated only in asymmetric dilatation of the ascending aorta associated with primary structural aortic valve disease; while in symmetrical dilatation a radical surgery is recommended.

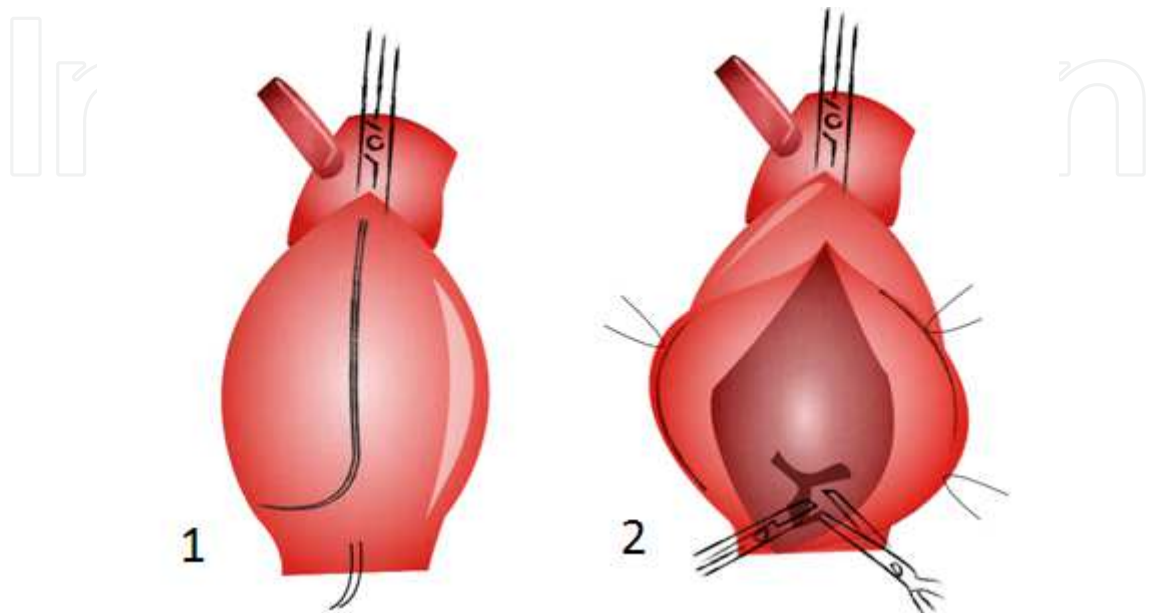


Fig. 6. “Waistcoat aortoplasty”. The aorta is longitudinally incised, starting from the clamp towards the commissure between the right coronary sinus and the non-coronary sinus. At above 2 cm before reaching the commissure, the incision is deflected at an angle of 90° and continued towards the commissure between the left coronary and the non-coronary sinus (1). The native aortic valve is excised (2).

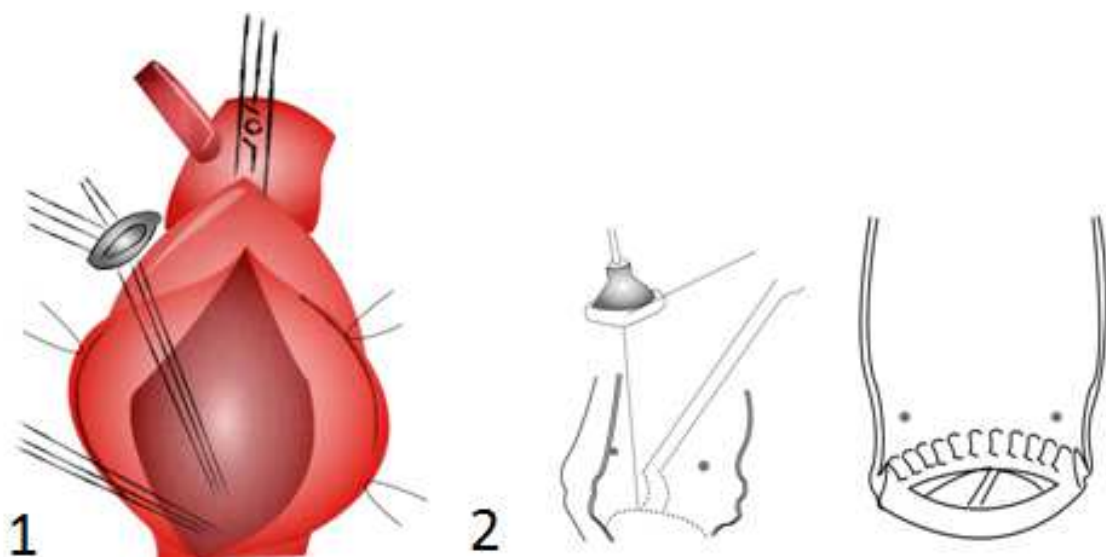


Fig. 7. The prosthetic valve is implanted (1). The sutures to anchor the aortic valve are driven in through the subcoronary aortic wall and out through the annulus. When implanting the prosthesis, there is a longitudinal plication of the sinuses (2).

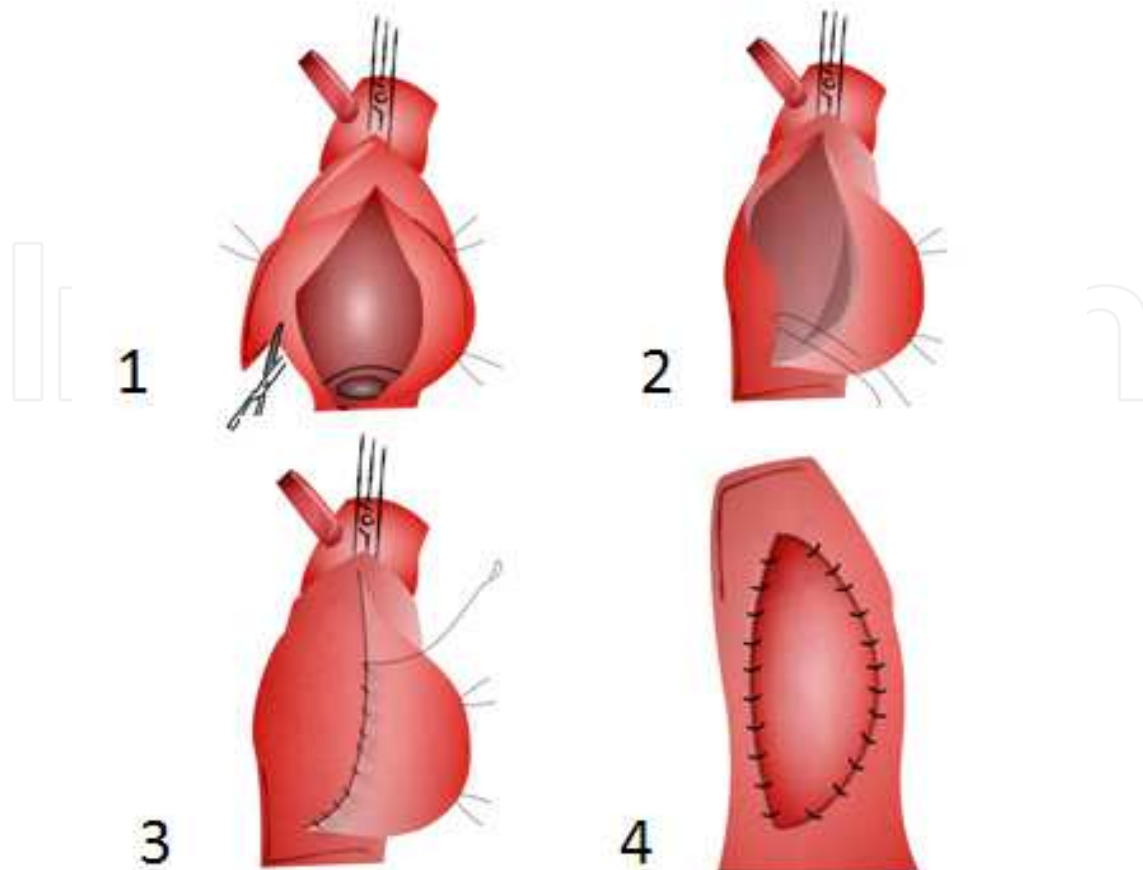


Fig. 8. A triangular resection of the dilated aortic wall is obtained by extending the incision from above the commissure to the distal end of the incision (1). The right edge of the aortotomy is sutured to the inner surface of the anterior wall with a suture line starting from the right coronary ostium (2). The suture line continues longitudinally leaving a 2 cm wide anterior lap (3). The remaining anterior lap is sutured to cover and to reinforce the aortic wall (4).

In 2004, Arsan (Arsan et al., 2004) reported on 62 consecutive patients that underwent treatment for ascending aorta aneurysm by reduction aortoplasty and external wrapping during cardiac concomitant procedures. The mean preoperative aortic diameter was  $52.7 \pm 0.5$  mm and the diameter of the ascending aorta was greater than 45 mm in all patients. Mean follow-up time was  $39.6 \pm 18.0$  months (range 8 to 78 months). No mortality was registered during a 30-day period. The hospital mortality was 1.6%, one patient died as result of septic multiple-organ failure. Comparing the aortic diameter before surgery (AD1), aortic diameter in early postoperative (AD2) and aortic diameter during the late postoperative period (AD3), reduction aortoplasty of the ascending aorta with external wrapping resulted in a significant reduction of the ascending aorta diameter in all patients (AD1 versus AD2 and AD3,  $p=0.000$ ). There was also a statistically significant difference between the ascending aortic diameters measured during early and late follow-up (AD2 versus AD3,  $p=0.000$ ). Although this increase was statistically significant, all measurements of the follow-up period in groups AD2 and AD3 were still within the normal range. The author concluded that external wrapping of the aorta offers excellent results with very low mortality and morbidity, and it can be regarded as a safe and effective method for the treatment of ascending aortic aneurysm in selected patients. However, the patients should be carefully monitored for redilatation after the procedure.

The same author (Arsan, 2004) reported as well on 4 high-risk patients who underwent off-pump reduction aortoplasty and concomitant myocardial revascularization. In these patients, the diameter of the ascending aorta was less than 6 cm and there were no calcification, atherosclerotic penetrating ulcers, or suspicion of dissection. The author routinely performs an external wrapping technique without incising or excising the diseased aorta, a "sandwich technique". The tubular graft is tailored to the diseased aorta longitudinally using separate, full-thickness U sutures. This technique can be performed easily even on the beating heart in high risk patients in order to prevent complications. According to the author, this technique could be the procedure of choice in selected high-risk cases for the treatment of borderline ascending aortic aneurysms in patients undergoing coronary revascularization.

Polvani (Polvani et al., 2006), in 2006, published a study where he evaluated the midterm follow-up of unsupported aortoplasty and determined predictors of redilatation. He reported on 68 patients with dilatation of the ascending aorta treated by unsupported reduction aortoplasty in combination with other cardiac procedures. Indication for surgery was an aortic diameter between 40 and 50 mm for younger patients and up to 60 mm for older patients or in high risk patients, with the aim to reduce aortic cross-clamp and perfusion times. Mean follow-up time was  $2.9 \pm 1.7$  years. The overall perioperative mortality rate was 1.5%. Overall survival estimates at 3 and 6 years were  $93.3 \pm 4.5\%$  and  $89.3 \pm 5.9\%$ , respectively. Ascending aorta redilatation occurred in 5 patients (7.5%). The actuarial freedom from redilatation at 3 and 6 years was  $97.7 \pm 2.3\%$  and  $79.8 \pm 8.4\%$ , respectively. The actuarial freedom from reoperation at 3 and 6 years was 100% and  $86.3 \pm 7.5\%$ , respectively. Only preoperative diameter was a significant predictor of redilatation, using multivariate stepwise logistic regression analysis. In the author's experience, unsupported aortoplasty resulted in a safe and effective technique with low mortality, low morbidity, and few late complications for selected chronic aneurysm of the ascending aorta with diameters less than 55 mm. A diameter greater than 55 mm is an independent risk factor for redilatation, and it should be considered a contraindication to this procedure and may be considered an indication to the Dacron graft support.

Walker (Walker et al., 2007), in 2007, investigated the postoperative stability and preservation of the physiologic elasticity of the reconstructed ascending aorta (Windkessel function). He collected the results of 97 patients who underwent aortoplasty without external stabilization, for a moderate enlargement of the ascending aorta up to 5 cm, as a concomitant procedure during cardiac surgery. Patients with Marfan syndrome, aneurysms of the sinus of Valsalva, aneurysms of the aortic arch and patients with an infective origin of the aneurysm were excluded. Hospital mortality was 3%. At 32 months follow-up, fifty-four patients agreed to be examined by computed tomographic scan (determination of the aortic diameter) and transthoracic echocardiography (determination of the Windkessel function). Mean dilatation during the time from early postoperative measurement to follow-up was 0.17 cm ( $\pm 0.27$  cm; CI 0.09 to 0.25 cm). In six patients with a follow-up of 60 months who had both early and late postoperative diameter assessment, the mean postoperative dilatation was 0.04 cm ( $\pm 0.15$  cm; CI 0.11 to 0.20 cm). By transthoracic echography, the diastolic-systolic augmentation (Windkessel function) of the ascending aorta was confirmed, with a median amplitude value of 0.25 cm (range, 0 to 1.1 cm). These results were compared with data from patients who received a tubular graft on the ascending aorta. They had only minor diameter changes during systole and diastole: median 0.06 cm (range, 0 to 0.12 cm). The systolic augmentation of patients with aortoplasty was 250% in comparison with those who received a tubular graft on

the ascending aorta (CI 157% to 375%). The author concludes that aortoplasty without external support is a valid treatment in patients with moderate dilatation of the ascending aorta and preserves the Windkessel function of the ascending aorta.

In 2007, Feindt (Feindt et al., 2007), in a retrospective study, analyzed the results of a cohort of 50 patients who underwent size-reducing ascending aortoplasty with external wrapping. The maximum diameter of the ascending aorta in this group was measured between 45 and 65 mm without dilatation of the sinotubular junction and aortic arch. Aortoplasty was associated with other cardiac procedures such as aortic valve replacement in 47 cases. The procedure was performed with low hospital mortality (2%) and a low postoperative morbidity. Computer tomographic and echocardiographic diameters were significantly smaller after reduction ( $55.8 \pm 9$  mm down to  $40.51 (\pm 6.2)$  mm (CT),  $p < 0.002$ ;  $54.1 \pm 6.7$  mm preoperatively down to  $38.7 \pm 7.1$  mm (echocardiography),  $p < 0.002$ ), with stable performance at follow-up (mean follow-up time: 70 months, complete in 31 patients). The authors concluded that ascending aorta aortoplasty with external reinforcement is a safe procedure with excellent long-term results and that it is a therapeutic option in patients with poststenotic dilatation of the aorta, without dilatation of the sinotubular junction.

Belov (Belov et al., 2009), in 2009, compared the early results and late outcome in two groups of patients. Group 1 had prosthetic ascending aorta replacement, while group 2 had reduction aortoplasty and external wrapping. All had a diameter of the ascending aorta  $\geq 5$  cm and a sinus of Valsalva diameter  $< 4.5$  cm. Group 1 had longer cardiopulmonary bypass time, higher reoperation for bleeding and higher mortality. None of the patients in group 2 needed reoperation due to ascending aorta redilatation nor significant enlargement of the Valsalva sinuses during the follow-up. According to Belov, the main criterion for performing or not performing an aortoplasty with external wrapping on the ascending aorta should only be the diameter at the level of the Valsalva sinuses, rather than the ascending aorta maximal diameter. He considered a diameter  $< 4.5$  cm at the Valsalva sinuses as an appropriate condition for performing a reduction aortoplasty. On the other hand, important enlargement of the ascending aorta usually leads to aortic root dilatation; reduction aortoplasty with external wrapping may be impossible in these circumstances.

In the same year, Zhang (Zhang et al., 2010) published his report of 71 patients with fusiform ascending aortic aneurysms and aortic valve disease who underwent reinforced reduction aortoplasty associated with aortic valve replacement (RRA group,  $n = 32$ ) or ascending aortic replacement combined with aortic valve replacement (AAR group,  $n = 39$ ). Patients requiring other concomitant cardiac procedures were excluded, as well patients with Marfan syndrome. The mean follow-up time was 3 years and 4 months. The cardiopulmonary bypass time, the aortic cross clamp time and the length of stay were higher in the AAR group than in the RRA group. The overall survival rate in all patients was  $88.6\% \pm 4.5\%$  at 5 years. The 5-year survival rate was  $90.7\% \pm 6.4\%$  in the RRA group and  $87.0\% \pm 6.3\%$  in the AAR group. There were no reoperations on the aorta or aortic valve in all patients during follow-up. In both groups, the aorta was studied at the level of the aortic sinuses and proximal aortic arch, and no significant differences between the postoperative and late follow-up diameters were found in the RRA and in the AAR groups.

In 2009, Haddad (Haddad et al., 2009) published an article in which he analyzed the results of 6 high risk patients, with a Euroscore between 11 and 19, with ascending aortic aneurysm and aortic valve disease, who underwent reduction aortoplasty with external wrapping associated with the aortic valve replacement. The inclusion criteria were: patients with aortic valve disease with surgical indication, ascending aortic diameter  $> 5.5$  cm, EuroSCORE  $> 6$

and age over 60 years; the mean diameter of the sinotubular junction was 36 mm. The exclusion criteria were: presence of dissections of the ascending aorta and Marfan syndrome. At follow-up (28 months), the actuarial survival rate was 100%, and none of patients needed reoperation. The author concludes that, despite the limitations of the study (small sample of patients, mid-term follow-up, selected and not random population), the reduction aortoplasty associated with external wrapping and aortic valve replacement is a therapeutic option with promising midterm results in high surgical risk patients with ascending aortic aneurysm and aortic valve disease.

In a recent article published in 2010, Hwang (Hwang et al., 2010), in his series of 88 patients, evaluates the long-term results of aortoplasty performed with aortic valve surgery and compared the results in patients with bicuspid aortic valve with those in patients with tricuspid aortic valve. Indication for aortoplasty was a moderately dilated ascending aorta with a diameter between 40–50 mm. Patients with combined aortic root dilatation (diameter of the sinus of Valsalva greater than 5 cm and/or displaced coronary ostia distal to the sinotubular junction), and patients with systemic connective tissue disease were excluded. Operative mortality was 1.1%. The overall 10-year survival rate was 91.1%. No patients suffered from aorta-related complications such as aortic dissection, rupture or aortic reoperation. At follow-up of 74 months per patient, a CT scan was performed to evaluate the ascending aorta. The mean diameter of the repaired aorta was  $37.8 \pm 4.3$  mm and none had a diameter greater than 5 cm. The author assesses that the reduction ascending aortoplasty for a moderate ascending aortic aneurysm combined with aortic valve disease can be performed with low periprocedural risks and good long-term results.

Recently, Ang (Ang et al., 2010) reported on the early impact of aortic wrapping in patients undergoing aortic valve replacement with mild to moderate ascending aorta dilatation. An important finding of this study refers to “the reduction of the diameter and reversed remodeling of the aorta not only at the site of dilatation but also proximally and distally to the aortic wrapping”. These results suggest that “correction of dimensions of a dilated ascending aorta at an early stage, and before irreversible anatomical changes take place, results in the rapid reversed remodeling of the rest of the aorta, probably due to the restoration of normal blood flow haemodynamics”.

## 5. Discussion and conclusions

From the above mentioned studies we see that aortoplasty with or without external wrapping or simple wrapping alone may represent a surgical alternative for mild to moderate ascending aorta dilatation in high risk patients. However, some points should be addressed.

The aortoplasty reduces the diameter of the ascending aorta and therefore reduces the tension on the aortic wall, but it does not reinforce the wall in itself. Blood ejected by the left ventricle hits an area of the ascending aorta, which after aortoplasty is less elastic and rather more fibrotic due to the formation of a scar on the suture line. Areas of the ascending aorta previously involved in the dilatation are still weakened by the hemodynamic stress trauma (Mueller et al., 1997; Robicsek, 1995). This mechanism could explain aneurysm recurrence observed after “simple aortoplasty” (Mueller et al., 1997; Egloff et al., 1982). Therefore, aortoplasty, even if it eliminates the aneurysm, may sometimes prove insufficient to prevent recurrence.

Furthermore, simple aortoplasty may not be appropriate to treat patients with concomitant aortic root aneurysm (Mueller et al., 1997; Barnett et al., 1995). In order to reconstruct

physiologically the ascending aorta, the wall of the ascending aorta is incised longitudinally and an elliptical portion of the aortic wall is then removed. From its nature, the edges of the elliptical shape progressively reduce their width at the extremities. Using this technique, it could be difficult to extend the reductive aortoplasty to the sinuses of Valsalva. These limitations are not overcome by the technique suggested by Baumgartner (Baumgartner et al., 1998); this technique is applicable to reduce the diameter of the ascending aorta, but it does not reinforce the aortic wall and it cannot be used to reduce a dilatation of the sinuses of Valsalva. Not unanimous is the consensus regarding the "external grafting technique" suggested by Robicsek. Incertitude is raised by the use of a prosthetic graft to reinforce the aortic root (Cooley, 1982; Gott, 1994). Gott (Gott, 1994) has observed that this technique does not offer an adequate reinforcement of the aortic root, although Robicsek has indicated the dilatation of the sinuses of Valsalva and dilatation of the ascending aorta in patients with Marfan syndrome as pathologies treatable by external grafting.

The tubular prosthetic graft should be adequately positioned in order to not compress the coronary ostia and compromise cardiac perfusion (Robicsek & Thubrikar, 1994; Robicsek, 1982; Barnett et al., 1995). Often, when a dilatation of the aortic root is present, the coronary ostia are dislocated distally and away from the annulus (Bahnon, 1982; Barnett et al., 1995; Gott, 1994; Lewis et al., 1992). They take origin from the distal part of the aneurysm. The remaining section of the aortic root under the coronary ostia remains, in these cases, unsupported.

An adequate anchoring of the tubular graft is important to prevent complications. Neri and colleagues (Neri et al., 1999) reported on 2 patients who developed false aneurysm of the ascending aorta after 7 and 11 years, respectively. Histological examination of the aortic wall underlying the reinforcement cuff revealed extensive wall degeneration. Dhillon and associates (Dhillon et al., 1986) observed late ruptures after wrapping of aortic aneurysms. In all 3 cases, the aortic wall had been eroded. Usually the border between the wrapped segment and the native aortic wall might be under high pressure, resulting in dissection and erosion of the native intima, producing a weakening of the aortic wall both proximally and distally. Akgun (Akgun et al., 2010) reported an aortic root aneurysm in a patient who 7 years earlier underwent a reduction aortoplasty with external wrapping. Bauer (Bauer et al., 2003) found, in 1 patient, that the dacron wrapping had become dislocated by moving to the distal part of the ascending aorta, creating a sharp fold at the inner curve of the vessel. In this region he noted an extreme rarefaction of the aortic wall with impending rupture. To prevent late complications such as coronary compression, redilatation of the ascending aorta due to dislocation of the wrap, secure anchoring of the prosthetic wrap to the aorta is mandatory. Furthermore, to avoid alterations of the aortic wall, the prosthetic wrapping has to be well fitted to prevent the creation of folds, which may become areas of high mechanical stress.

Limitations of the wrapping technique without aortoplasty, the "sandwich technique", are that the available vascular graft prostheses may be insufficient in diameter to fit a large ascending aorta (Ergin et al., 1999; Carrel et al., 1991). The vascular prostheses have a crimped fabric, which allows the prostheses to be moderately bent without angulations. When trying to fit a straight prosthesis in a curvilinear aorta, the prosthesis develops wrinkles in the aortic concavity. The wrinkles of the prosthesis may be responsible for erosion of the aortic wall with a resulting risk of rupture. Thus aortic wrapping could become more dangerous than dilatation itself. Tappainer (Tappainer et al., 2007) suggested a new technique for wrapping of the ascending aorta in association with aortic valve replacement. Usually, the aortic wrap



is constructed before aortic cross-clamping. The vascular dacron prosthesis is cut into two halves of 6 cm length. Both halves are opened longitudinally with a curved cut. Thus two dacron sheets are obtained from the prosthesis, each of them having one concave and one convex side. Finally, the sheets are joined by suturing the two convex sides together and the two concave sides together. A curved dacron hose 5 cm in diameter is obtained for external wrapping of the ascending aorta (Figure 9). After surgery on the aortic valve, the posterior aspect of the ascending aorta is freed completely from the pericardial reflection up to the innominate artery. In this way, the custom-built prosthesis is easily inserted for wrapping the ascending aorta. After closing the aortotomy and releasing the aortic clamp, the prosthesis is pulled down to cover the suture line and fixed with few adventitial stitches. No solid transmural stitches are usually needed with this technique because the curved prosthesis fits the curved ascending aorta. Similarly, after decannulation, the prosthesis is pulled up to cover the cannulation site. With this technique, the whole ascending aorta is covered by the prosthesis without wrinkles or bends.

Thus, reduction aortoplasty seems to be a safe procedure and to give good postoperative outcomes. It could be a viable alternative to conventional aortic root replacement or interposition tube grafting in some selected patients. The underground wall disorder should be an aortic valve stenosis. Patients with cystic medial necrosis, connective disorders and ascending aorta dissections are not candidates for reduction aortoplasty; furthermore no calcifications or atherosclerotic penetrating ulcers should affect the aortic wall; aneurysms with an infective origin are to be excluded from this type of treatment. The dilatation should be localized only on the ascending aorta, between the sinotubular junction and not extending beyond the innominate artery and the aortic arch. The ascending aorta should be moderately dilated with a diameter of up to 5.5 cm. Patients with an ascending aorta larger than 5.5 cm could benefit from a reduction aortoplasty if they are older and at high surgical risk. As an appropriate condition for reduction aortoplasty, the diameter at the sinus of Valsalva should be up to 4.5 cm. The intra-operative reduction of the aorta should be to <3.5 cm. The external wrapping should be anchored to minimize the risk of dislocation and it should be shaped anatomically on the ascending aorta.




Fig. 9. Drawing of custom-made prosthesis preparation (1). Custom-made prosthesis before insertion (2).


## 6. References

- Akgun S, Atalan N, Fazlioğullari O, Kunt AT, Basaran C, Arsan S. 2010. Aortic root aneurysm after off-pump reduction aortoplasty. *Ann Thorac Surg*. Vol 90, N 5, Nov 2010, pp 69-70.
- Ang KL, Raheel F, Bajaj A, Sosnowski A, Galiñanes M. 2010. Early impact of aortic wrapping on patients undergoing aortic valve replacement with mild to moderate ascending aorta dilatation. *J Cardiothorac Surg*. Vol 6, N 5, Aug 210, pp 58.
- Arsan S, Akgun S, Kurtoglu N, Yildirim T, Tekinsoy B. 2004. Reduction aortoplasty and external wrapping for moderately sized tubular ascending aortic aneurysm with concomitant operations. *Ann Thorac Surg*. Vol 78, N 3, Sep 2004, pp 858-61.
- Arsan S. 2004. Off-pump reduction aortoplasty and concomitant coronary artery bypass grafting. *Ann Thorac Surg*. Vol 78, N 1, Jul 2004, pp 316-9.
- Bahnson HT. 1982. The dilemma of the ascending aortic aneurysm. *Ann Thorac Surg*. Vol 34, N 2, Aug 1982, pp 115-6.
- Barnett MG, Fiore AC, Vaca KJ, Milligan TW, Barner HB. 1995. Tailoring aortoplasty for repair of fusiform ascending aortic aneurysms. *Ann Thorac Surg*. Vol 59, N 2, Feb 1995, pp 497-51.
- Bauer M, Pasic M, Schaffarzyk R, Siniawski H, Knollmann F, Meyer R, Hetzer R. 202. Reduction aortoplasty for dilatation of the ascending aorta in patients with bicuspid aortic valve. *Ann Thorac Surg*. Vol 73, N 3, Mar 2002, pp 720-3.
- Bauer M, Grauhan O, Hetzer R. 2003. Dislocated wrap after previous reduction aortoplasty causes erosion of the ascending aorta. *Ann Thorac Surg*. Vol 75, N 2, Feb 2003, pp 583-4.
- Baumgartner F, Omari B, Pak S, Ginzton L, Shapiro S, Milliken J. 1998. Reduction aortoplasty for moderately sized ascending aortic aneurysms. *J Card Surg*. Vol 13, N 2, Mar 198, pp 129-32.
- Belov IV, Stepanenko AB, Gens AP, Savichev DD, Charchyan ER. 2009. Reduction aortoplasty for ascending aortic aneurysm: a 14-year experience. *Asian Cardiovasc Thorac Ann*. Vol 17, N 2, Apr, 2009, pp 162-6.
- Bentall H, De Bono A. 1968. A technique for complete replacement of the ascending aorta. *Thorax*. Vol 23, N 4, Jul 1968, pp 338-9.
- Cabrol C, Pavie A, Mesnildrey P, Gandjbakhch I, Laughlin L, Bors V, Corcos T. 1986. Long-term results with total replacement of the ascending aorta and reimplantation of the coronary arteries. *J Thorac Cardiovasc Surg*. Vol 91, N 1, Jan 1986, pp 17-25.
- Carrel T, von Segesser L, Jenni R, Gallino A, Egloff L, Bauer E, Laske A, Turina M. 1991. Dealing with dilated ascending aorta during aortic valve replacement: advantages of conservative surgical approach. *Eur J Cardiothorac Surg*. Vol 5, N 3, 1991, pp 137-43.
- Carrel T, Pasic M, Jenni R, Tkebuchava T, Turina MI. 1993. Reoperations after operation on the thoracic aorta: etiology, surgical techniques, and prevention. *Ann Thorac Surg*. Vol 56, N 2, Aug 1993, pp 259-68.
- Cooley DA. Discussion on: Egloff L, Rothlin M, Kugelmeier J, Senning A, Turina M. 1982. The ascending aortic aneurysm: replacement or repair? *Ann Thorac Surg*. Vol 34, N 2, Aug 1982, pp 117-24.

- Cotrufo M, Della Corte A, De Santo LS, De Feo M, Covino FE, Dialetto G. 2003. Asymmetric medial degeneration of the ascending aorta in aortic valve disease: a pilot study of surgical management. *J Heart Valve Dis.* 2003 Mar; Vol 12, N 2, Mar 2003, pp 127-33.
- Crawford ES, Svensson LG, Coselli JS, Safi HJ, Hess KR. 1988. Aortic dissection and dissecting aortic aneurysms. *Ann Surg.* Vol 208, N 3, Sep 1988, pp 254-73.
- Della Corte A, De Santo LS, Amarelli C, Romano G, De Feo M, Torella M, Scardone M, Cotrufo M. 2003. Surgical experience with "waistcoat aortoplasty": an update. *Ital Heart J.* Vol 4, N 12, Dec 2003, pp 875-9.
- Dhillon JS, Randhawa GK, Straehley CJ, McNamara JJ. 1986. Late rupture after dacron wrapping of aortic aneurysms. *Circulation.* Vol 74, N 3, Sep 1986, pp 11-4.
- Egloff L, Rothlin M, Kugelmeier J, Senning A, Turina M. 1982. The ascending aortic aneurysm: replacement or repair? *Ann Thorac Surg.* Vol 34, N 2, Aug 1982, pp 117-24.
- Ergin MA, Spielvogel D, Apaydin A, Lansman SL, McCullough JN, Galla JD, Griep RB. 1999. Surgical treatment of the dilated ascending aorta: when and how? *Ann Thorac Surg.* Vol 67, N 6, Jun 1999, pp 1834-9.
- Feindt P, Litmathe J, Börgens A, Boeken U, Kurt M, Gams E. 2007. Is size-reducing ascending aortoplasty with external reinforcement an option in modern aortic surgery? *Eur J Cardiothorac Surg.* Vol 31, N 4, Apr 2007, pp 614-7.
- Gaeta R, Savasta M, Tancredi F, Monaco F, Lentini S. 2009. Resection and end-to-end anastomosis for ascending aortic aneurysm: surgical technique. *Minerva Chir.* Vol 64, N 6, Dec 2009, pp 665-8.
- Ggoves LK, Effler DB, Hawk WA, Gulati K. 1964. Aortic insufficiency secondary to aneurysmal changes in the ascending aorta: surgical management. *J Thorac Cardiovasc Surg.* Vol 48, Sep 1964, pp 362-79.
- Gott VL. Invited commentary on: Robicsek F, Thubrikar MJ. 1994. Conservative operation in the management of annular dilatation and ascending aortic aneurysm. *Ann Thorac Surg.* Vol 57, N 6, Jun 1994, pp 1672-4.
- Haddad R, Fagundes WV, Pinheiro BB. 2009. Reduction aortoplasty with external wrapping associated with aortic valve replacement in high-risk patients. *Rev Bras Cir Cardiovasc.* Vol 24, N 2, Jun 2009, pp 194-9.
- Hirst AE, Gore I. 1976. Editorial: Is cystic medionecrosis the cause of dissecting aortic aneurysm? *Circulation.* Vol 53, N 6, Jun 1976, pp 915-6.
- Hwang HY, Shim MS, Park EA, Ahn H. 2011. Reduction Aortoplasty for the Ascending Aortic Aneurysm With Aortic Valve Disease. *Circ J.* Vol 75, N 2, Feb 2011, pp 322-8.
- Imaizumi T, Orita Y, Koiwaya Y, Hirata T, Nakamura M. 1982. Utility of two-dimensional echocardiography in the differential diagnosis of the etiology of aortic regurgitation. *Am Heart J.* Vol 103, N 5, May 1982, pp 887-96.
- Jarchow BH, Kincaid OW. 1961. Poststenotic dilatation of the ascending aorta: Its occurrence and significance as a roentgenologic sign of aortic stenosis. *Proc Staff Meet Mayo Clin.* Vol 18, N 36, Jan 1961, pp 23-33.
- Klima T, Spjut HJ, Coelho A, Gray AG, Wukasch DC, Reul GJ Jr, Cooley DA. 1983. The morphology of ascending aortic aneurysms. *Hum Pathol.* Vol 14, N 9, Sep 1983, pp 810-7.

- Kouchoukos NT, Marshall WG Jr, Wedige-Stecher TA. 1986. Eleven-year experience with composite graft replacement of the ascending aorta and aortic valve. *J Thorac Cardiovasc Surg.* Vol 92, N 4, Oct 1986, pp 691-705.
- Laske A, Jenni R, Maloigne M, Vassalli G, Bertel O, Turina MI. 1996. Pressure gradients across bileaflet aortic valves by direct measurement and echocardiography. *Ann Thorac Surg.* Vol 61, N 1, Jan 1996, pp 48-57.
- Lawrie GM, Earle N, DeBakey ME. 1993. Long-term fate of the aortic root and aortic valve after ascending aneurysm surgery. *Ann Surg.* Vol 217, N 6, Jun 1993, pp 711-20.
- Lewis CT, Cooley DA, Murphy MC, Talledo O, Vega D. 1992. Surgical repair of aortic root aneurysms in 280 patients. *Ann Thorac Surg.* Vol 53, N 1, Jan 1992, pp 38-45.
- Massetti M, Veron S, Neri E, Coffin O, le Page O, Babatasi G, Buklas D, Maiza D, Gerard JL, Khayat A. 2004. Long-term durability of resection and end-to-end anastomosis for ascending aortic aneurysms. *J Thorac Cardiovasc Surg.* Vol 127, N 5, May 2004, pp 1381-7.
- McCready RA, Pluth JR. 1979. Surgical treatment of ascending aortic aneurysms associated with aortic valve insufficiency. *Ann Thorac Surg.* Vol 28, N 4, Oct 1979, pp 307-16.
- Milano A, Pratali S, De Carlo M, Borzoni G, Tartarini G, Bortolotti U. 1998. Ascending aorta dissection after aortic valve replacement. *J Heart Valve Dis.* Vol 7, N 1, Jan 1998, pp 75-80.
- Mueller XM, Tevaearai HT, Genton CY, Hurni M, Ruchat P, Fischer AP, Stumpe F, von Segesser LK. 1997. Drawback of aortoplasty for aneurysm of the ascending aorta associated with aortic valve disease. *Ann Thorac Surg.* 1997 Mar; Vol 63, N 3, Mar 1997, pp 762-6.
- Natsuaki M, Itoh T, Rikitake K, Okazaki Y, Naitoh K. 1998. Aortic complications after aortic valve replacement in patients with dilated ascending aorta and aortic regurgitation. *J Heart Valve Dis.* Vol 7, N 5, Sep 1998, pp 504-9.
- Neri E, Massetti M, Tanganelli P, Capannini G, Carone E, Tripodi A, Tucci E, Sassi C. 1999. Is it only a mechanical matter? Histologic modifications of the aorta underlying external banding. *J Thorac Cardiovasc Surg.* Vol 118, N 6, Dec 1999, pp 1116-8.
- Perrotta S, Lentini S, Rinaldi M, D'armini AM, Tancredi F, Raffa G, Gaeta R, Viganó M. 2008. Treatment of ascending aorta disease with Bentall-De Bono operation using a mini-invasive approach. *J Cardiovasc Med (Hagerstown).* Vol 9, N 10, Oct 2008, pp 1016-22.
- Perrotta S, Lentini S. 2009. Ministernotomy approach for surgery of the aortic root and ascending aorta. *Interact Cardiovasc Thorac Surg.* Vol 9, N 5, Nov 009, pp 849-58.
- Polvani G, Barili F, Dainese L, Topkara VK, Cheema FH, Penza E, Ferrarese S, Parolari A, Alamanni F, Biglioli P. 2006. Reduction ascending aortoplasty: midterm follow-up and predictors of redilatation. *Ann Thorac Surg.* Vol 82, N 2, Aug 2006, pp 586-91.
- Prenger K, Pieters F, Cheriex E. 1994. Aortic dissection after aortic valve replacement: incidence and consequences for strategy. *J Card Surg.* Vol 9, N 5, Sep 1994, pp 495-8.
- Robicsek F. 1982. A new method to treat fusiform aneurysms of the ascending aorta associated with aortic valve disease: an alternative to radical resection. *Ann Thorac Surg.* Vol 34, N 1, Jul 1982, pp 92-4.
- Robicsek F, Thubrikar MJ. 1994. Conservative operation in the management of annular dilatation and ascending aortic aneurysm. *Ann Thorac Surg.* Vol 57, N 6, Jun 1994, pp 1672-4.

- Robicsek F. Invited commentary on: Barnett MG, Fiore AC, Vaca KJ, Milligan TW, Barner HB. 1995. Tailoring aortoplasty for repair of fusiform ascending aortic aneurysms. *Ann Thorac Surg.* Vol 59, N 2, Feb 1995, pp 497-51.
- Roman MJ, Devereux RB, Kramer-Fox R, O'Loughlin J. 1989. Two-dimensional echocardiographic aortic root dimensions in normal children and adults. *Am J Cardiol.* Vol 64, N 8, Sep 1989, pp 507-12.
- Schlatmann TJ, Becker AE. 1977a. Histologic changes in the normal aging aorta: implications for dissecting aortic aneurysm. *Am J Cardiol.* Vol 39, N 1, Jan 1977, pp 13-20.
- Schlatmann TJ, Becker AE. 1977b. Pathogenesis of dissecting aneurysm of aorta. Comparative histopathologic study of significance of medial changes. *Am J Cardiol.* Vol 39, N 1, Jan 1977, pp 21-6.
- Stein PD, Sabbah HN. 1976. Turbulent blood flow in the ascending aorta of humans with normal and diseased aortic valves. *Circ Res.* Vol 39, N 1, Jul 1976, pp 58-65.
- Svensson LG, Crawford ES, Hess KR, Coselli JS, Safi HJ. 1992. Composite valve graft replacement of the proximal aorta: comparison of techniques in 348 patients. *Ann Thorac Surg.* Vol 54, N 3, Sep 1992, pp 427-37.
- Tappainer E, Fiorani V, Nocchi A, Likaj E, Memishaj S, Zogno M. 2007. Safe wrapping of the borderline dilated ascending aorta during aortic valve replacement. *J Cardiothorac Surg.* Vol 22, N 2, Feb 2007, pp 15.
- Viganò M, Rinaldi M, D'Armini AM, Boffini M, Zattera GF, Alloni A, Dore R. 2002. Ascending aortic aneurysms treated by cuneiform resection and end-to-end anastomosis through a ministernotomy. *Ann Thorac Surg.* Vol 74, N 5, Nov 2002, pp 1789-91.
- Walker T, Bail DH, Gruler M, Vonthein R, Steger V, Ziemer G. 2007. Unsupported reduction ascending aortoplasty: fate of diameter and of Windkessel function. *Ann Thorac Surg.* Vol 83, N 3, Mar 2007, pp 1047-53.
- Wheat MW Jr, Wilson JR, Bartley TD. 1964. Successful replacement of the entire ascending aorta and aortic valve. *JAMA.* Vol 25, N 188, May 1964, pp 717-9.
- Yearwood TL, Misbach GA, Chandran KB. 1989. Experimental fluid dynamics of aortic stenosis in a model of the human aorta. *Clin Phys Physiol Meas.* Vol 1, N 1, Feb 1989, pp 11-24.
- Zhang H, Lu F, Qu D, Han L, Xu J, Ji G, Xu Z. 2011. Treatment of fusiform ascending aortic aneurysms: A comparative study with 2 options. *J Thorac Cardiovasc Surg.* Vol 141, N 3, Mar 2011, pp 738-43.



## **Aneurysmal Disease of the Thoracic and Abdominal Aorta**

Edited by Dr. Ruth Bush

ISBN 978-953-307-578-5

Hard cover, 226 pages

**Publisher** InTech

**Published online** 16, December, 2011

**Published in print edition** December, 2011

The first successful open surgical repair of an abdominal aortic aneurysm was in 1951 by Dubost and represented a tremendous milestone in the care of this challenging disease. The introduction of endovascular repair in 1991 by Parodi furthered the care of these patients by allowing for lower morbidity and mortality rates and also, enabling surgeons to extend surgical treatment to patients traditionally deemed too high of a surgical risk. This new book on Aortic Disease covers many interesting and vital topics necessary for both the practicing surgeon as well as a student of vascular disease. The book starts with background information on the evolution of aortic management from traditional open surgical repair to modern endovascular therapies. There is also a chapter covering the data supporting current treatment modalities and how these data have supported modern management. Also, the use of endovascular means for care of the challenging situation of ruptured aneurysms is discussed. In addition to management of abdominal aneurysm, there is a chapter on treatment of aneurysms of the ascending aorta. Along with surgical treatment, one must also understand the molecular basis for how blood vessels remodel and thus, the role of cathepsins in aortic disease is elucidated. Lastly, chapters discussing the perioperative management of radiation exposure and ultrasound-guided nerve blocks as well as the need for high-quality postoperative nutrition will lend well to a full understanding of how to management patients from presentation to hospital discharge. We hope you enjoy this book, its variety of topics, and gain a fuller knowledge of Aneurysmal Disease of the Thoracic and Abdominal Aorta.

### **How to reference**

In order to correctly reference this scholarly work, feel free to copy and paste the following:

Sossio Perrotta and Salvatore Lentini (2011). Alternative Surgical Management of Ascending Aorta Aneurysm, Aneurysmal Disease of the Thoracic and Abdominal Aorta, Dr. Ruth Bush (Ed.), ISBN: 978-953-307-578-5, InTech, Available from: <http://www.intechopen.com/books/aneurysmal-disease-of-the-thoracic-and-abdominal-aorta/alternative-surgical-management-of-ascending-aorta-aneurysm>

**INTECH**  
open science | open minds

### **InTech Europe**

University Campus STeP Ri  
Slavka Krautzeka 83/A  
51000 Rijeka, Croatia  
Phone: +385 (51) 770 447

### **InTech China**

Unit 405, Office Block, Hotel Equatorial Shanghai  
No.65, Yan An Road (West), Shanghai, 200040, China  
中国上海市延安西路65号上海国际贵都大饭店办公楼405单元  
Phone: +86-21-62489820

[www.intechopen.com](http://www.intechopen.com)

Fax: +385 (51) 686 166  
www.intechopen.com

Fax: +86-21-62489821

IntechOpen

IntechOpen

© 2011 The Author(s). Licensee IntechOpen. This is an open access article distributed under the terms of the [Creative Commons Attribution 3.0 License](#), which permits unrestricted use, distribution, and reproduction in any medium, provided the original work is properly cited.

IntechOpen

IntechOpen