

We are IntechOpen, the world's leading publisher of Open Access books Built by scientists, for scientists

4,800

Open access books available

122,000

International authors and editors

135M

Downloads

Our authors are among the

154

Countries delivered to

TOP 1%

most cited scientists

12.2%

Contributors from top 500 universities



WEB OF SCIENCE™

Selection of our books indexed in the Book Citation Index
in Web of Science™ Core Collection (BKCI)

Interested in publishing with us?
Contact book.department@intechopen.com

Numbers displayed above are based on latest data collected.

For more information visit www.intechopen.com



Fertility-Preserving Surgery for Cervical Ectopic Pregnancy, from Past to Present

Seiryu Kamoi, Nao Iwasaki and Toshiyuki Takeshita
Department of Obstetrics and Gynecology, Nippon Medical School, Tokyo, Japan

1. Introduction

Cervical pregnancy is a rare form of ectopic pregnancy in which implantation occurs in the cervical mucosa below the level of the internal os of the uterus. In the past, especially when diagnostic tools like ultrasonography or MRI were unavailable, many patients frequently encountered life-threatening, uncontrollable hemorrhage either spontaneously or when the implant was evacuated by curettage with a presumptive diagnosis of incomplete or inevitable abortion[1]. Hysterectomy was the only measure that could save those patients [2, 3], although some surgeons challenged surgical methods to preserve fertility [4-8].

Many successful cases of fertility preservation have been reported since anti-chorionic villi drugs like methotrexate (MTX) became available and interventional radiology techniques were improved to reduce hemorrhage during curettage or evacuation. However, hysterectomy is still considered the final measure.

This chapter first describes the history of cervical ectopic pregnancy, followed by the history of its treatment in the past. Then, we present our novel fertility-preserving surgical technique in addition to a review of the uterine-conservation techniques which have been reported in the past.

2. Historical review of cervical ectopic pregnancy

According to Thomsen and Johansen, the first case of cervical pregnancy was reported in 1817 by Sir Everard Home, who found an early ovum in the cervical canal during post-mortem examination. Thereafter, more and more cases were reported soon after Karl Freiherr von Rokitansky described two cases in 1860 in the German literature. The maternal mortality rate early in the 1900s was exceptionally high mainly due to hemorrhage and sepsis (66% according to Hofsatter; 43% according to Zangemeister and Schilling; 13% according to Concetti), and was estimated to be an average of 30%[9].

However, this rate is not considered to have actually been this high, because of the limited ability of exact diagnosis in those days. That is, patients underwent evacuation of the uterus based on incorrect diagnosis, consequently suffering from massive hemorrhage, which was treated by hysterectomy. In 1946, Schneider defined “distal ectopic pregnancy” as a pregnancy in which the fetus resides in the cervical canal. He classified it into three categories by implantation site: (1) ‘pure’ cervical ectopic pregnancy; (2) isthmico-cervical pregnancy; and (3) endometrio-isthmico-cervical pregnancy[10]. With the probable

inclusion of distal ectopic pregnancy other than true cervical pregnancy or other unconfirmed cases, Baptisti estimated the mortality rate to be only 6% of cases published between 1945 and 1953 and stated that this remarkable decline in the mortality rate was due to the development of blood transfusion in modern obstetrics[11].

Shinagawa, in his 10 years of experience, reported in 1969 about 19 cervical pregnancy cases, all of which resulted in abdominal hysterectomy after attempted vaginal treatment to save the uterus. He expressed his surprise for the discrepancy in the frequency of cases between the United States and Japan[12]. In the United States, a little over 80 cases had been reported up until 1967[13]. Sheldon et al. experienced two cases at the Mayo Clinic over a 15-year period, an incidence of approximately 1 in 16,000 pregnancies[7], while Paalman and McElin found only five cases in a series of 47,974 pregnancies at two American hospitals over a 10-year period—an incidence of 0.01%[14]. On the other hand, in Japan, in addition to Shinagawa's 19 cases of approximately 19,000 pregnancies reported at his university hospital and affiliated hospitals between 1958 and 1967, at least 119 cases had been reported throughout Japan between 1953 and 1967[12], suggesting the estimated incidence of the cervical ectopic pregnancy in Japan to be 0.1% (1:1000 pregnancies). Considering that no nulliparous woman was in his series and in 13 of the 19 cases of antecedent pregnancy were interrupted artificially, Shinagawa supposed that the difference in incidence was due to the higher number of legal abortions at that time in Japan. Therefore, the true incidence of cervical ectopic pregnancy is unknown, and comparison between countries is difficult because of the differences in cultures and eras.

Summarizing the past treatments in the literature, Thomsen and Johansen stated that most of the cases were treated based on incorrect original diagnosis[15]. Attempts to evacuate the uterus digitally or instrumentally usually produced violent hemorrhage, and in many cases it was so severe as to necessitate hysterectomy. Several authors reportedly controlled the bleeding by packing, sometimes with fibrin foam, or by amputating the cervix. Although utero-tonic agents are generally used against bleeding after delivery, Danforth pointed out that such agents are ineffective against hemorrhage as the open vessels could not be closed by contraction of the thin-walled, distended cervix, which contains few contractile elements[16]. Schneider and Drezin[17] and Steinbiss[18] also noted that tamponade may provide initial success of hemostasis, but a severe secondary hemorrhage may nevertheless occur up to six weeks later necessitating hysterectomy. By the 1950s, clinicians attempted to conserve the uterus during the treatment of cervical ectopic pregnancy with the establishment of blood transfusion methods[11].

3. Cases of cervical ectopic pregnancy with successful uterine conservation

In 1963, Sheldon and his colleagues reported two cases of cervical pregnancy[7]. One patient was a 42-year-old woman (gravida 3, para 2) who was treated with vigorous curettage when massive genital bleeding began. The pregnancy was terminated with little bleeding during the operation and with an uneventful postoperative follow-up. She had no further pregnancies.

The second patient was a 33-year-old woman (gravida 5, para 4) who underwent excision of the implantation site by sharp dissection and several sutures in the cervix; after curettage had caused heavy bleeding (>1000 ml), bleeding was controlled with tight packing by iodoform gauze. She was dismissed from the hospital on the fourth day and successfully gave birth to a girl.

In addition to these two cases, few cases have addressed efforts to determine a successful conservative therapy – one case by Whittle in 1976[8], four cases by Materacaru in 1968[19], and one case by Farghaly et al. in 1980[6].

The summary of the procedures for these cases are as follows. 1) The approach is vaginal. 2) The urinary bladder is moved upwards through a transverse incision of the anterior vaginal wall to make visible the whole anterior cervix. 3) Bleeding is controlled by clamping each side of the cervix to occlude the lateral cervical blood vessel. 4) The anterior cervical wall is incised longitudinally upwards from the external os to the internal os. 5) If the conceptive products have been implanted in the anterior wall, the local cervical wall is excised with the ectopic fetus, and both sides are sutured; if the implantation site is posterior, complete curettage is performed under direct visualization, usually requiring several sutures for the torn sites of the thin wall. 6) The procedure is achieved by removing the hemostasis clamp and packing the vaginal and cervical canal with gauze. During the procedure, blood transfusion of >1000 ml is usually necessary to maintain the patient's circulation.

Although such procedures involve a vaginal approach, abdominal surgery was also attempted during the same period. In 1969, Nelson applied ligation of the bilateral internal iliac arteries in two cases to perform successful curettage[20], following the idea of Dodeck[21].

The first case was a 17-year-old woman (gravida 1, para 0) who consulted a doctor because of low abdominal pain and abnormal vaginal bleeding. Although a 12-week pregnancy-sized pelvic mass was confirmed, the pregnancy test was negative. Therefore, exploratory laparotomy was indicated and it showed normal sized uterine corpus that had elevated out of the pelvis by a 10-cm soft cystic enlargement of the cervix. Cervical pregnancy was diagnosed. A large amount of necrotic placental tissue and an old clot was removed by vaginal curettage with 250 ml of blood loss after bilateral internal iliac artery ligation under laparotomy. Three years later, she became pregnant which ended in incomplete infected abortion. The following year, she received total abdominal hysterectomy and bilateral salpingo-oophorectomy because of a recurrent tubo-ovarian abscess.

The second case was a 33-year-old woman (gravida 3, para 2) who consulted a doctor with profuse vaginal bleeding at week 11 of gestation. With a diagnosis of threatened abortion, curettage was attempted. The first introduction of forceps into the cervical canal caused sudden loss of over 300 ml of blood, and further evacuation brought on uncontrollable hemorrhage. Laparotomy confirmed cervical pregnancy and bilateral internal iliac artery ligation was applied, followed by evacuation of the placental tissue by curettage. Estimated blood loss was 1200 ml, necessitating whole-blood transfusion.

Shinagawa stated that satisfactory hemostasis could not be achieved by internal iliac artery ligation, based on his reports of 19 cases which all received a hysterectomy after attempts to save the uterus; he did not indicate the number of cases that underwent this procedure.

As an alternative method to bilateral internal iliac artery ligation, Akashi et al. applied bilateral uterine artery ligation by the vaginal approach to stop bleeding in a case of massive hemorrhage. Akashi et al. further reviewed 29 successful cases of uterine conservation in Japan until 1976. These cases included curettage only in eight patients, curetting plus removal of the gestational sac in one, conservative treatment only in one (the method was not specified), curettage plus internal artery ligation in one, curettage plus cervical cerclage in one, cervicotomy only in one (the approach was not specified), abdominal cervicotomy in

six, removal of a vaginal portion in one, and vaginal cervicotomy in eight, to one of which was applied bilateral uterine artery ligation with a successful result.

These surgical treatments were less common following new methods of safe termination of cervical pregnancy by administration of MTX or application of interventional radiology [5, 22-24]. In 1994, Kudo et al. introduced vaginal surgery to conservatively treat cervical ectopic pregnancy in Japan[25]. This method is similar to those performed in the era without MTX. The only difference is that to reduce blood supply to the cervix, the main branches of both uterine arteries are identified and ligated by absorbable threads instead of being clamped by instruments. For the blood supply of subsequent pregnancies, these absorbable threads could be untied later. On the other hand, both main branches could be cut, as blood to the uterine corpus is supplied through ovarian arteries, or bypassed circulation could be established. This method may be less invasive and even superior if the surgeon is experienced and has good skills with the vaginal approach. Indications may not be favorable, however, when there is poor surgical visibility with heavy and massive bleeding. Therefore, surgical methods are needed that can be performed under any condition, with or without bleeding.

4. Recent surgical treatment: partial trachelectomy

We have recently experienced a case in which the size or blood supply of the gestational sac was increased despite MTX treatment[26]. In this case, curettage with angiographic occlusion of bilateral uterine arteries caused temporal hemorrhagic shock, and fertility was preserved by a novel surgical procedure referred to as “partial trachelectomy”[26]. In the past, the term partial trachelectomy was used for the procedure in which the whole vaginal portion of the uterine cervix was vaginally removed as an extension of deep conization [27, 28]. However, we would like to stress that our method of “partial trachelectomy” is completely different from those reported in the past.

We previously reported a 26-year-old woman (0-0-2-0) who was introduced to our hospital at 8 weeks of pregnancy, with suspected cervical ectopic pregnancy. On ultrasound, the gestational sac was located in the swollen cervix and a heart-beating fetus was visible (Fig. 1). Her serum β -human chorionic gonadotropin (β -hCG) level was 187,497 mIU/mL. We therefore started administration of MTX 20 mg daily for 5 days every 2 weeks, while checking her general condition including liver function. Fetal heart beat stopped after one course of administration, and her serum β -hCG level started to decline (Fig. 2).

Following chemotherapy, the gestational sac showed deformation but its size never decreased on B-mode scanning or MR imaging (Fig. 3a). The blood supply around the gestational sac appeared to increase on color flow mapping showing numerous dilated or pulsating vessels. Although her serum β -hCG level had declined to 4 mIU/mL after six courses of MTX administration, intermittent hemorrhaging occurred, sometimes being massive, necessitating blood transfusion. Spontaneous discharge of the conceptus content was expected but did not occur, resulting in only bleeding. Therefore, surgical evacuation was indicated with both internal iliac arteries temporally occluded angiographically using a balloon catheter. Even with these measures, instrumental evacuation caused uncontrollable hemorrhage and shock. Then, the curettage was interrupted and she received a blood transfusion shortly thereafter, for preparation of a new approach to preserve fertility by partial trachelectomy; informed consent was obtained before the procedure.

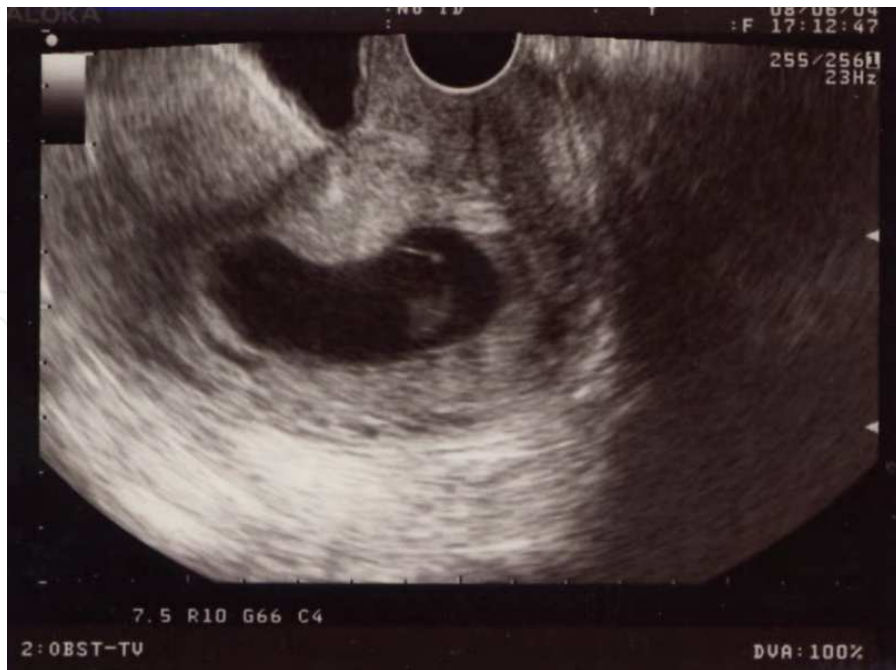

Fig. 1. B-mode ultrasound findings at admission. The gestational sac in the swollen cervix and a heart-beating fetus are visible.

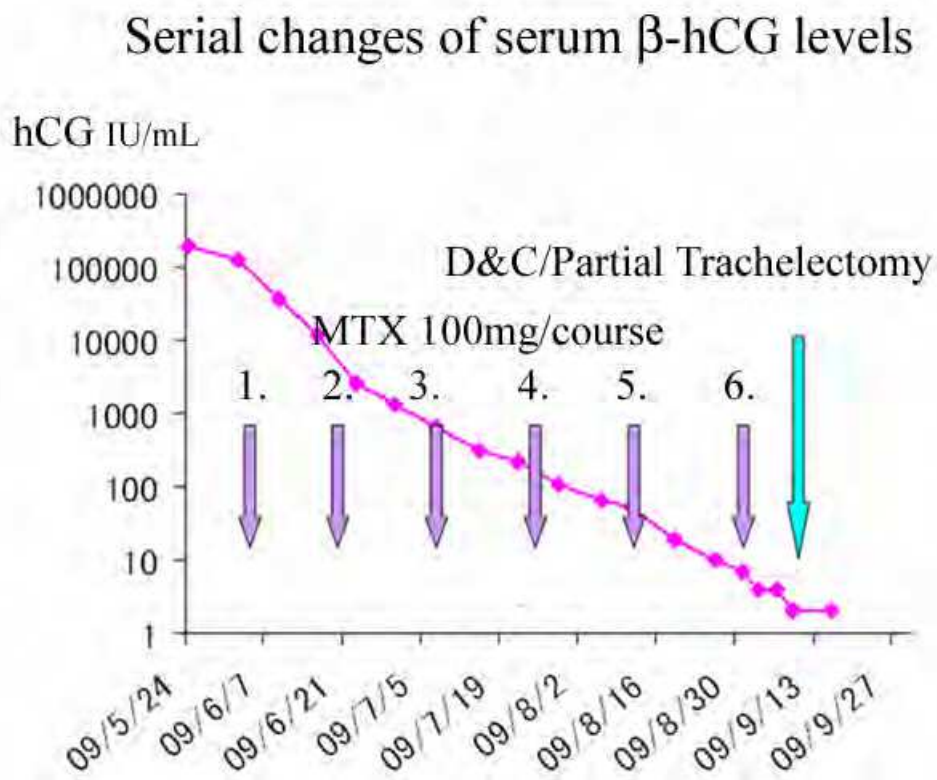


Fig. 2. Serial changes in serum β -hCG levels after admission
 Serum β -hCG levels of the patient reduced from 187,497 to 4 U/mL by six courses of systemic administration of MTX (20 mmg/day \times 5 days). After five courses of MTX treatment, frequent sporadic genital bleeding up to 500 ml occurred, indicating partial trachelectomy following dilatation and curettage (D&C).

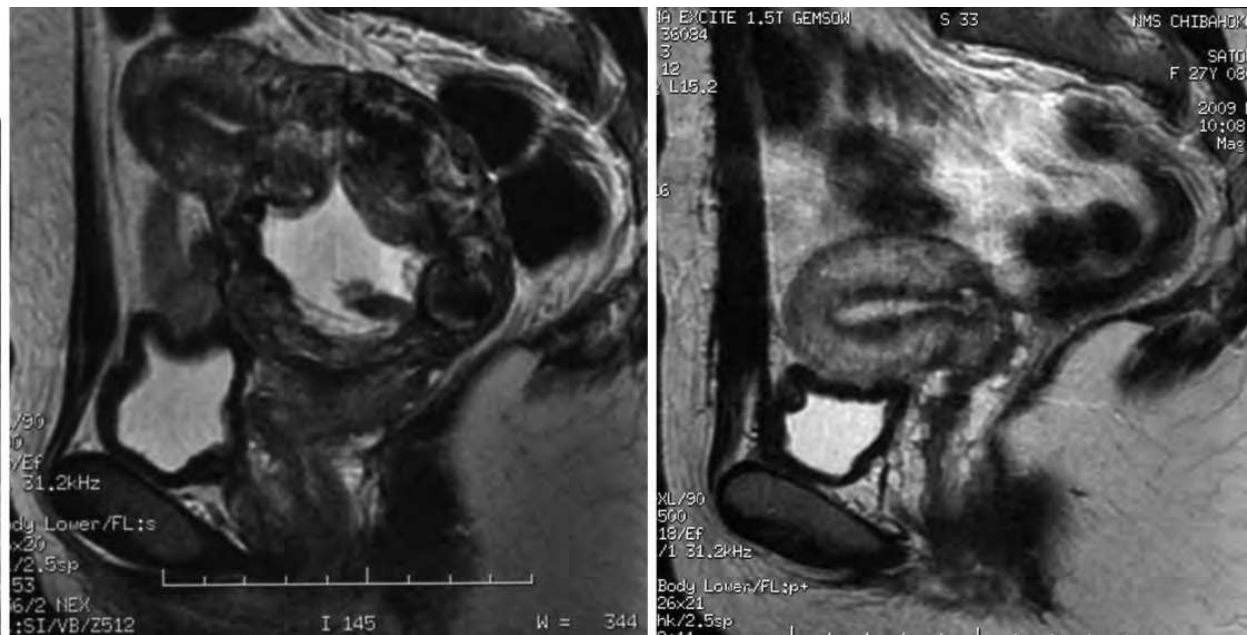


Fig. 3. MRI immediately prior to surgery and one year and two months post-surgery
 a. MR image just before curettage showing a swollen cervix and an unclear border between the gestational sac and cervical wall. b. MR image one year and two months after fertility-preserving surgery showing a normal uterine corpus and small cervix.

The procedure was conducted under general anesthesia with an operation time of 6 h and 1300 ml of blood loss, most of which was considered to be from the vagina, not the surgical area. The postoperative surgical state was fairly good and she was discharged from the hospital on the tenth postoperative day. Her serum β -hCG level was undetectable immediately after surgery, and normal menstruation returned one month later. Six months later, the uterine shape appeared almost normal, and one year later, T2-weighted MRI findings (sagittal view) were completely normal, presenting three zonal patterns of the corpus and clearer shape of the retained cervix (Fig. 3b).

For partial trachelectomy, the abdomen is opened with a median vertical subumbilical incision, confirming a normal-sized uterine corpus and a swollen cervix (Fig. 4a). The left round ligament is divided and the broad ligament is opened to enter the retroperitoneal space. The same procedure is performed on the right side. The uterovesical fold of the peritoneum is cut and the urinary bladder is displaced downwards to directly view the swollen cervix. The left uterine artery is identified following anterior division of the left hypogastric artery with special attention of the ureter. A careful dissection is made around the bifurcation into both ascending and descending branches of the uterine artery. The descending branch is ligated and cut just distal to the bifurcation to stop the blood supply into the cervix. The opposite side is ligated and cut in the same manner (Fig. 5). Circumcision of the vagina is then completed at the fornix using a translucent vaginal cylinder to distinguish between the vaginal vault and the uterus (Fig. 4b). In this state, the uterine corpus is attached to both adnexae and the blood supply maintained by both bilateral ovarian arteries and the bilateral ascending branches of the uterine arteries (Fig. 5). This procedure allows mobility of the cervix upwards to visualize the external os (Fig. 4c). If the implantation site is considered to be posterior, the anterior wall of the cervical canal is cut longitudinally upwards from the external cervical opening to view the ectopic

gestational sac. The part of the posterior wall including the implantation site is excised in a spindle shape following the border from the normal structure (Figs. 4d and 6). If the implantation site is anterior, the posterior wall is excised in the same manner. Both the posterior and anterior walls are closed by vicryl (Ethicon, Inc., Somerville, NJ) -interrupted sutures (Fig. 4e), and the reconstructed cervix and amputated vaginal vault are connected again by vicryl-interrupted sutures. Finally, the procedure is completed by pelvic peritonealization including reconnection of both round ligaments (Fig. 4f).

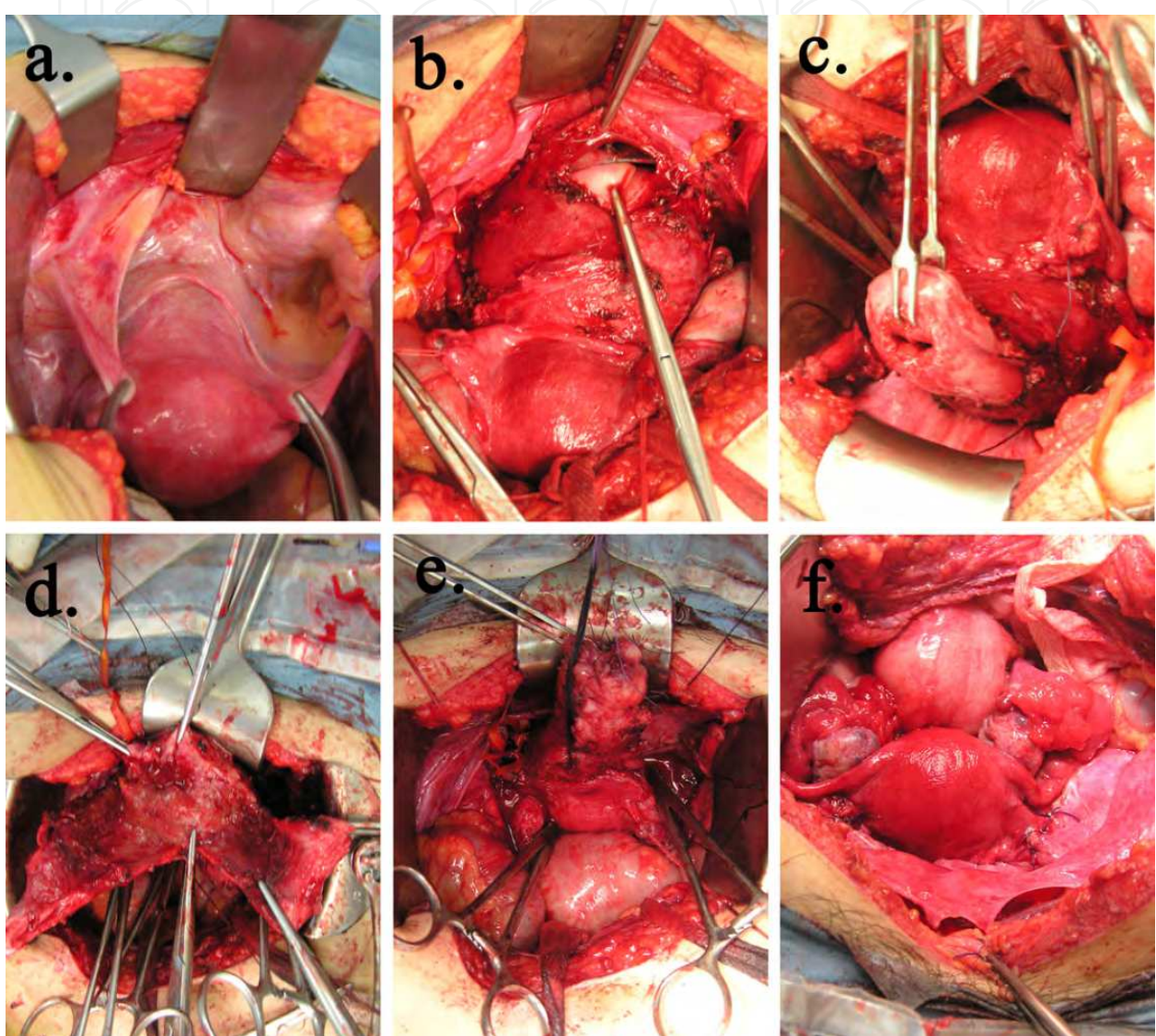


Fig. 4. Intraoperative photographs

a. Anterior view of the swollen cervix and corpus of the uterus when the abdomen was just opened. b. Anterior vaginal wall partially opened at the fornix after the blood supply was stopped by ligation of both descending branches of the uterine artery, guided by a translucent cylinder that had been inserted into the vagina. c. Whole ectocervix after circumcision of the vagina. d. Opened left and right bilateral flaps of the intact cervical wall after fusiform excision of the cervical wall with the ectopic pregnancy. e. Re-construction of the cervical canal by suturing both flaps at the anterior and posterior. f. Pelvic cavity after the cervix was anastomosed with the vagina.

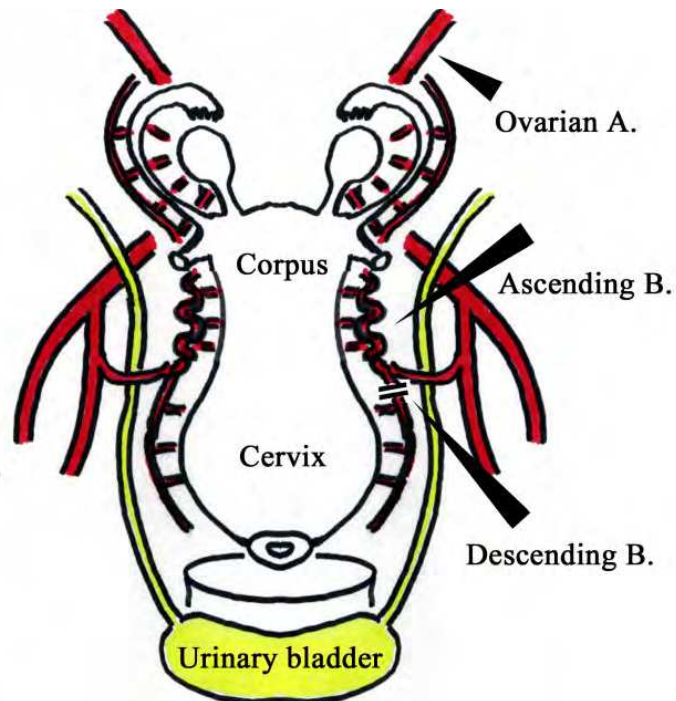


Fig. 5. Vascular anatomy of partial trachelectomy for cervical ectopic pregnancy
 Each descending branch of the bilateral uterine artery is tied and cut just distal to the bifurcation indicated by the long arrowhead. The vagina is amputated at the fornix. The blood supply is provided by both uterine and ovarian arteries. B.: branch; A.: artery




Fig. 6. Schematic of direct visualization of the conceptive product
 The conceptus mass is directly visible by the opening of the longitudinal incision of the anterior cervical wall. The internal cervical os is also visible. The expected line of the fusiform incision at the posterior wall is indicated by the dashed line.

Figure 7a shows the product of conception removed by curettage and Fig. 7b shows the excised vaginal wall in a spindle shape. Histological examination of the excised specimen showed necrotic villi with hemorrhage at the surface and intermediate trophoblast invasion deeply in the cervix.




Fig. 7. Macroscopic findings of resected specimen

a. The gestational sac (the product of conception) broken into pieces by curettage. b. The vaginal wall with the implantation site excised in a spindle shape. The right side of the specimen is directed toward the internal os.

Our partial trachelectomy method was developed based on radical trachelectomy which is an established method for removal of the whole cervix with part of the vaginal wall in cervical cancer patients who hope to preserve their fertility[29, 30]. For patients with cervical pregnancy, but not cervical cancer, wide resection of the uterine cervix is unnecessary and only a small part, at the implantation site, should be excised from the cervix. This approach may thus be less invasive from the viewpoint of fertility.

Many precise diagnostic tools such as MRI, ultrasound and color flow mapping; villocidal agents such as MTX and actinomycin D with local or systemic delivery; and interventional radiology techniques such as transarterial embolization and balloon occlusion are currently available. These advances in medicine allow clinicians to treat patients conservatively and specifically by combining these methods. However, conservative treatment of patients with cervical ectopic pregnancy is still limited. Analysis of prognostic factors affecting the outcome of conservative MTX treatment showed that MTX therapy is generally associated with higher failure rates for cases of cervical pregnancy with 1) serum β -hCG levels greater than 10,000 IU/L, 2) gestational age > 9 weeks amenorrhea, 3) positive fetal cardiac activity or, 4) crown-rump length > 10 mm[31]. In our experience, we have successfully treated two patients with cervical ectopic pregnancy: one case with systemic MTX alone or another case with MTX and curettage (unpublished). However, in the present case, we experienced for the first time a case in which MTX was insufficient as a safe and conservative treatment. Leeman et al. divided treatment choices for cervical ectopic pregnancy conceptually into five categories: 1) tamponade (cervical/vaginal packing or Foley balloon), 2) reduction of blood supply (cervical cerclage, angiographic embolization, or large vessel ligation), 3) excision of trophoblastic tissue (dilation and curettage, hysteroscopic resection, or hysterectomy), 4) intra-amniotic feticide (potassium chloride or MTX), and 5) systemic chemotherapy (MTX intramuscularly or other chemotherapy regimens) and proposed one possible treatment algorithm. [32] In the case of hemorrhaging, hysterectomy is selected if bleeding cannot be

stabilized by the measures such as Foley balloon tamponade, large vessel ligation, or angiographic embolization. In the clinically stable cases, measures are categorized into three groups by ultrasound examination. 1) Systemic MTX is recommended at less than 9 weeks of gestation with no cardiac activity. 2) Intra-amniotic potassium chloride with systemic MTX is chosen at 9 to 12 weeks or less than 9 weeks with cardiac activity. 3) Primary hysterectomy is indicated at more than 12 weeks. That is, at an advanced gestational age or after treatment failure, pregnancy should be terminated by hysterectomy.

In our case, serum β -hCG levels were over 10,000 IU/L and ultrasound examination showed positive fetal cardiac activity. Therefore, systemic MTX administration was chosen to treat the patient.

With regards to MTX administration, Barnhart pointed out that mainly two protocols were used for medical management for unruptured ectopic pregnancy: "single dose" regimen and "multidose" regimen. MTX can be given using a "multidose" regimen of 1mg/kg intramuscularly, alternating with 0.1 mg/kg of leucovorin intramuscularly for up to four daily doses of each drug[33]. Alternatively, methotrexate can be administered using a "single dose" method, based on body surface area, at 50 mg/m² without the need for leucovorin rescue. It is concluded that "single dose" regimen is milder than in side effect but has higher failure rate than "multidose" regimen. This "multidose" regimen has been used for a long time as MTX-leucovorin rescue regimen for the patients with low-risk gestational trophoblastic disease and it has slightly lower remission rate than 5-days MTX regimen[34]. Five-days MTX regimen, in which MTX is administered in a dose of 0.4mg/kg intramuscularly for five days with cycles repeated every 14 days, is another protocols that is frequently used for low-risk gestational trophoblastic disease[35]. With above consideration, we applied 5 days MTX regimen for our patient. The serum β -hCG level fell slowly to 4 mIU/mL before surgery, just as following the normal regression curve of β -hCG after molar evacuation[36]. However, it became undetected at the next day after surgery. According to Kamrava, the serum clearance of hCG by radioimmunoassay may take place at least up to 24 days after surgery if the lesion can be removed completely and the initial titer of hCG is a significant factor in determining the length of time that it can be detected in the serum postoperatively[37]. In this means, the surgical excision of the trophoblastic tissue was considered to be complete with this procedure.

Although the surgery in our case was considered to be fairly long, i.e., 6 h (it was initiated as an emergency operation, late at night (21:00), due to continuous bleeding from the vagina), partial trachelectomy could be completed in less time upon improved techniques. In consideration of the new treatment option of partial trachelectomy, the treatment algorithm should be revised to include more chances to preserve fertility, especially in difficult cases. Indications for partial trachelectomy include: 1) when measures for massive hemorrhage such as Foley balloon tamponade, large vessel ligation, and/or angiographic embolization are ineffective; 2) when MTX is ineffective indicating primary hysterectomy for cases at gestational age > 12 weeks; or 3) when systemic MTX plus intra-amniotic potassium is ineffective as a complete cure and additional surgical measures like curettage or suction evacuation are necessary. However, this surgical option might be accompanied with various risks, including relapse, premature delivery, and surgical wound rupture, although the risk should be less than that for radical trachelectomy indicated for the increasing number of cases of cervical cancer patients. Further studies are needed to determine the benefits and risks of partial trachelectomy before establishing it as a treatment for patients with cervical ectopic pregnancy.

5. Conclusions

In conclusion, “partial trachelectomy” is a new procedure that shares many similarities to previous procedures. It differs in the following two respects: 1) exact ligation or cut of the descending branch of the bilateral uterine artery and 2) excision of the spindle shaped-cervical wall of the implantation site under direct vision by temporally detaching the vaginal wall and cervix. This procedure preserves fertility under any condition although with more risk of complication for future pregnancies compared to previous methods in which fertility preservation is not always successful. However, it is less invasive compared to radical trachelectomy which is a common method of fertility preservation for cancer patients with non-cervical pregnancy.


6. Acknowledgments

The authors thank Drs. Michiaki Watanabe, Kenji Igarashi, Takashi Yamada, and Tadashi Asakura for help in treating this patient; Dr. Hiroshi Kawamata for angiographic management; and the late Dr. Yoshiharu Ohaki for his pathologic diagnosis.

7. References

- [1] Flanagan, J.F. and C.R. Walsh, *Cervical pregnancy; report of a case*. *Obstet Gynecol*, 1954. 4(5): p. 511-3.
- [2] Haans, L.C., P.H. van Kessel, and H.C. Kock, *Treatment of ectopic pregnancy with methotrexate*. *Eur J Obstet Gynecol Reprod Biol*, 1987. 24(1): p. 63-7.
- [3] Kim, T.J., et al., *Clinical outcomes of patients treated for cervical pregnancy with or without methotrexate*. *J Korean Med Sci*, 2004. 19(6): p. 848-52.
- [4] Akashi, E., N. Kawase, and M. Hashimoto, *The diagnosis and therapy for cervical pregnancy*. *Sanfujinka no jissai*, 1976. 33: p. 659-667.
- [5] Cepni, I., et al., *Conservative treatment of cervical ectopic pregnancy with transvaginal ultrasound-guided aspiration and single-dose methotrexate*. *Fertil Steril*, 2004. 81(4): p. 1130-2.
- [6] Farghaly, S.A. and J.G. Mathie, *Cervical pregnancy managed by local excision*. *Postgrad Med J*, 1980. 56(661): p. 789.
- [7] Sheldon, R.S., L.A. Aaro, and J.S. Welch, *Conservative Management of Cervical Pregnancy*. *Am J Obstet Gynecol*, 1963. 87: p. 504-6.
- [8] Whittle, M.J., *Cervical pregnancy managed by local excision*. *Br Med J*, 1976. 2(6039): p. 795-6.
- [9] Studdiford, W., *Cervical Pregnancy*. *Amer.J.Obstet.gynecol*, 1945. 49: p. 169.
- [10] Schneider, P., *Distal ectopic pregnancy; implantation of the ovum in the cervical mucosa*. *Am J Surg*, 1946. 72: p. 526-39.
- [11] Baptisti, A., Jr., *Cervical pregnancy*. *Obstet Gynecol*, 1953. 1(3): p. 353-8.
- [12] Shinagawa, S. and M. Nagayama, *Cervical pregnancy as a possible sequela of induced abortion. Report of 19 cases*. *Am J Obstet Gynecol*, 1969. 105(2): p. 282-4.
- [13] Price, J.J. and A. Webster, *Cervical pregnancy*. *Am J Obstet Gynecol*, 1967. 99(1): p. 134-7.
- [14] Paalman, R.J. and E.T. Mc, *Cervical pregnancy; review of the literature and presentation of cases*. *Am J Obstet Gynecol*, 1959. 77(6): p. 1261-70.
- [15] Thomsen, M. and F. Johansen, *Two cases of cervical pregnancy*. *Acta obstet gynec scandinav*, 1961. 40: p. 99.
- [16] Danforth, D.N., *The fibrous nature of the human cervix, and its relation to the isthmic segment in gravid and nongravid uteri*. *Am J Obstet Gynecol*, 1947. 53: p. 541-60.

- [17] Schneider, P. and D.H. Dreizin, *Cervical pregnancy*. Am.J. Surg., 1957. 93: p. 27-40.
- [18] Steinbiss, W., *Tod infolge einer Placenta cervicalis accreta unter falschem Verdacht auf Kriminalem Abort*. Deutsch. Ztschr. f. ges. gericht. Med., 1938. 12: p. 234.
- [19] Matracaru, G., *A new method for the operative management of the cervical pregnancy*. Centralblatt for Gynecology, 1968. 37: p. 1264.
- [20] Nelson, R.M., *Bilateral internal iliac artery ligation in cervical pregnancy: conservation of reproductive function*. Am J Obstet Gynecol, 1979. 134(2): p. 145-50.
- [21] Dodeck, S.M., *Cervical Pregnancy: diagnosis and Management*. South. Med.J, 1965. 58: p. 167-70.
- [22] Honey, L., A. Leader, and P. Claman, *Uterine artery embolization--a successful treatment to control bleeding cervical pregnancy with a simultaneous intrauterine gestation*. Hum Reprod, 1999. 14(2): p. 553-5.
- [23] Trambert, J.J., et al., *Uterine artery embolization in the management of vaginal bleeding from cervical pregnancy: a case series*. J Reprod Med, 2005. 50(11): p. 844-50.
- [24] Yang, J.H., et al., *Combined treatment with temporary intraoperative balloon occlusion of common iliac arteries and hysteroscopic endocervical resection with postoperative cervical balloon for intractable cervical pregnancy in an infertile woman*. Fertil Steril, 2007. 88(5): p. 1438 e11-3.
- [25] Kudo, R., et al., *A conservative surgical treatment of cervical pregnancy through vagina. Sanfujinka Chiryō (in Japanese) (gynecological management)*, 1994. 69: p. 8-21.
- [26] Kamoi, S., et al., *Partial Trachelectomy :A New and Final Option for Fertility-Preserving Management of Cervical Ectopic Pregnancy*. J Gynecol Surg, 2009. 25: p. 139-146.
- [27] Jeng, C.J., J. Shen, and S.H. Huang, *Partial trachelectomy: a new treatment choice for persistent or recurrent high grade cervical intraepithelial neoplasia*. Gynecol Oncol, 2006. 100(2): p. 231-2.
- [28] Krebs, H.B., M.A. Wilstrup, and J.B. Wheelock, *Partial trachelectomy in the elderly patient with abnormal cytology*. Obstet Gynecol, 1985. 65(4): p. 579-84.
- [29] Abu-Rustum, N.R., et al., *Fertility-sparing radical abdominal trachelectomy for cervical carcinoma: technique and review of the literature*. Gynecol Oncol, 2006. 103(3): p. 807-13.
- [30] Smith, J.R., et al., *Abdominal radical trachelectomy: a new surgical technique for the conservative management of cervical carcinoma*. Br J Obstet Gynaecol, 1997. 104(10): p. 1196-200.
- [31] Hung, T.H., et al., *Prognostic factors for an unsatisfactory primary methotrexate treatment of cervical pregnancy: a quantitative review*. Hum Reprod, 1998. 13(9): p. 2636-42.
- [32] Leeman, L.M. and C.L. Wendland, *Cervical ectopic pregnancy. Diagnosis with endovaginal ultrasound examination and successful treatment with methotrexate*. Arch Fam Med, 2000. 9(1): p. 72-7.
- [33] Barnhart, K.T. and A.C. Hummel, *Pitfalls of partial meta-analysis: single- versus multidose for the treatment of ectopic pregnancy*. Am J Obstet Gynecol, 2007. 196(1): p. e22; author reply e22-3.
- [34] Bagshawe, K.D., et al., *The role of low-dose methotrexate and folinic acid in gestational trophoblastic tumours (GTT)*. Br J Obstet Gynaecol, 1989. 96(7): p. 795-802.
- [35] Hammond, C.B., et al., *Primary chemotherapy for nonmetastatic gestational trophoblastic neoplasms*. Am J Obstet Gynecol, 1967. 98(1): p. 71-8.
- [36] Morrow, C.P., et al., *Clinical and laboratory correlates of molar pregnancy and trophoblastic disease*. Am J Obstet Gynecol, 1977. 128(4): p. 424-30.
- [37] Kamrava, M.M., et al., *Disappearance of human chorionic gonadotropin following removal of ectopic pregnancy*. Obstet Gynecol, 1983. 62(4): p. 486-8.



Ectopic Pregnancy - Modern Diagnosis and Management

Edited by Dr. Michael Kamrava

ISBN 978-953-307-648-5

Hard cover, 248 pages

Publisher InTech

Published online 26, October, 2011

Published in print edition October, 2011

Ectopic pregnancy is the second major cause of maternal mortality in the United States and a leading cause of maternal morbidity and mortality in the world. This book contains the practical methods to early diagnosis of various forms of ectopic pregnancies and their modern management. Ectopic Pregnancy - Modern Diagnosis and Management is a comprehensive book which guides the reader through all features of ectopic pregnancy, both practical and academic, covering all aspects of diagnosis and management of ectopic pregnancy in a clear, concise, and practical fashion. The book is organized so that it can either be read cover to cover for a comprehensive tutorial or be kept desk side as a reference to the ectopic pregnancies. Each chapter introduces a number of related ectopic pregnancy and its diagnosis, treatment and co-morbidities supported by examples. Included chapters bring together valuable materials in the form of extended clinical knowledge from practice to clinic features.

How to reference

In order to correctly reference this scholarly work, feel free to copy and paste the following:

Seiryu Kamoi, Nao Iwasaki and Toshiyuki Takeshita (2011). Fertility-Preserving Surgery for Cervical Ectopic Pregnancy, from Past to Present, Ectopic Pregnancy - Modern Diagnosis and Management, Dr. Michael Kamrava (Ed.), ISBN: 978-953-307-648-5, InTech, Available from: <http://www.intechopen.com/books/ectopic-pregnancy-modern-diagnosis-and-management/fertility-preserving-surgery-for-cervical-ectopic-pregnancy-from-past-to-present>

INTECH
open science | open minds

InTech Europe

University Campus STeP Ri
Slavka Krautzeka 83/A
51000 Rijeka, Croatia
Phone: +385 (51) 770 447
Fax: +385 (51) 686 166
www.intechopen.com

InTech China

Unit 405, Office Block, Hotel Equatorial Shanghai
No.65, Yan An Road (West), Shanghai, 200040, China
中国上海市延安西路65号上海国际贵都大饭店办公楼405单元
Phone: +86-21-62489820
Fax: +86-21-62489821

© 2011 The Author(s). Licensee IntechOpen. This is an open access article distributed under the terms of the [Creative Commons Attribution 3.0 License](#), which permits unrestricted use, distribution, and reproduction in any medium, provided the original work is properly cited.

IntechOpen

IntechOpen