

We are IntechOpen, the world's leading publisher of Open Access books Built by scientists, for scientists

4,800

Open access books available

122,000

International authors and editors

135M

Downloads

Our authors are among the

154

Countries delivered to

TOP 1%

most cited scientists

12.2%

Contributors from top 500 universities



WEB OF SCIENCE™

Selection of our books indexed in the Book Citation Index
in Web of Science™ Core Collection (BKCI)

Interested in publishing with us?
Contact book.department@intechopen.com

Numbers displayed above are based on latest data collected.

For more information visit www.intechopen.com



Hysteroscopic Endometrial Embryo Delivery (HEED)

MM Kamrava, L Tran and JL Hall

¹West Coast IVF Clinic

²LA Center for Embryo Implantation

³UCLA, the Geffen School of Medicine

USA

1. Introduction

It has been over 30 years since the first successful pregnancy using in vitro fertilization (IVF). There have been major advancements in the different components of IVF such as ovulation induction protocols, oocyte retrieval techniques, and culture medium tailored to improving embryo quality (Gardner 1998). However, the discrepancy between women undergoing IVF with normal embryo development and live pregnancy rates continues to exist. It is estimated that up to 85% of replaced embryos fail to implant despite the selection of apparently normal embryos for transfer (Sallam 2002). This failure rate suggests that the embryo transfer stage is a key step to successful live pregnancy rates in assisted reproductive technology (ART) (Meldrum 1987).

Embryo transfer is traditionally performed by “blindly” replacing the embryos into the uterine cavity utilizing a transcervical catheter at approximately 2-5 days of development. This technique relies highly on the skill and tactile senses of the clinician. Many clinicians will transfer the embryos at a fixed distance (6 cm) from the external os; however, with varying cervical lengths and uterine anatomy, this often does not ensure optimal placement (Brown 2007). Recently, there have been many studies proposing potential embryo transfer related factors to the low success rate in pregnancy outcomes such as uterine contractions, expulsion of embryos, blood or mucus on the catheter tip, bacterial contamination of the catheter, and retained embryos (Schoolcraft 2001). Ultrasound guided embryo transfer (UGET) is currently suggested as the standard clinical practice and appears to improve the chances of live/ongoing and clinical pregnancies compared with clinical touch methods (Brown 2007). However, controversies still remain regarding the actual benefit of UGET in successful clinical pregnancy rates (Kosmas 1999). The subendometrial embryo delivery (SEED) technique has been previously reported to increase pregnancy rates and eliminate ectopic pregnancies associated with ART (KAMRAVA 2010). In this study, we set out to use a similar technique which utilized a mini-hysteroscope with a flexible catheter for direct delivery of embryo(s) at the 4-12 cell stage onto the endometrium under direct visualization. The hysteroscopic visual guidance ensures more precise and reliable placement at the desired location of the endometrium.

2. Materials and methods

Patients. 35 patients between 22 and 46 years of age undergoing IVF were included in this report. Informed consent was obtained prior to the start of the cycle. Controlled ovarian hyperstimulation was initiated with Follitropin β (Follistim[®], Organon Pharmaceuticals, Inc.). Endogenous gonadotropins surge (i.e., the prevention of an LH surge) was controlled with ganirelix acetate (Antagon[™], Organon Pharmaceuticals, Inc.). Oocyte retrieval was carried out in an office setting under local anesthesia and mild sedation. Oocytes were fertilized and cultured in a human tubal fluid formulated medium at 37 degrees C and 5% CO₂ in air". Embryos were transferred at 48-72 hours post fertilization (Figure 1a). All women received some type of luteal support, be it progesterone or hCG (3000 IU of hCG at 3 and 6 days post retrieval) (Figure 1b, c). Serum hCG was quantified at 10 days after the last hCG; a concentration of 5 IU/ml with a delayed menses was used as confirmation of pregnancy.

Description of Hysteroscopic Endometrial Embryo Delivery (HEED):

A transvaginal ultrasound of the uterus is performed and the direction and thickness of the endometrial lining is ascertained. With patient in dorsolithotomy position, a bivalved speculum is placed in the vagina and the cervix exposed. Vagina and cervix are washed with modified HAM's solution. Subsequently, 10 cc of 1% xylocaine is injected bilaterally in the utero-sacral nerve endings.



Fig. 1. Mini flexible hysteroscope (Storz[®], LA, CA USA)

The cervix is grasped with an allis clamp and stabilized. Nitrogen gas is used as the distention media throughout the procedure via a hysteroscopic insufflator. A 3 mm flexible hysteroscope (Figure 1) loaded with embryo catheter containing the embryos (Figure 2) is then gently inserted through the cervical os under direct visualization of the cervical canal into the uterine cavity. Once the cavity is visualized, it is then further advanced to the fundus of the uterus. The loaded embryo transfer catheter (Precision Reproduction, LA, CA USA) is then advanced to 1.5 cm from the tip of the hysteroscope and placed over the point of embryo deposition, half way between the lowest point of the fundus in the midline and the tubal opening into the uterus (Figure 3). The embryos are then gently released by the embryologist. Our results show that hysteroscopic guided early embryo transfer results in a high pregnancy outcome, 2-3x greater than "blind" transfer technique rates. Direct visualization provides an objective, visually confirmed, replicable technique for embryo transfer. The end result is less operator dependent and in contrast to routine ET techniques in which operator experience may account for the variable overall pregnancy rates (Garcia 2002). Hysteroscopic direct embryo delivery may circumvent many of the known and previously reported embryo transfer related factors associated with poor outcomes. Many of our patients had failed prior IVF-ET attempts due to multiple etiologies.

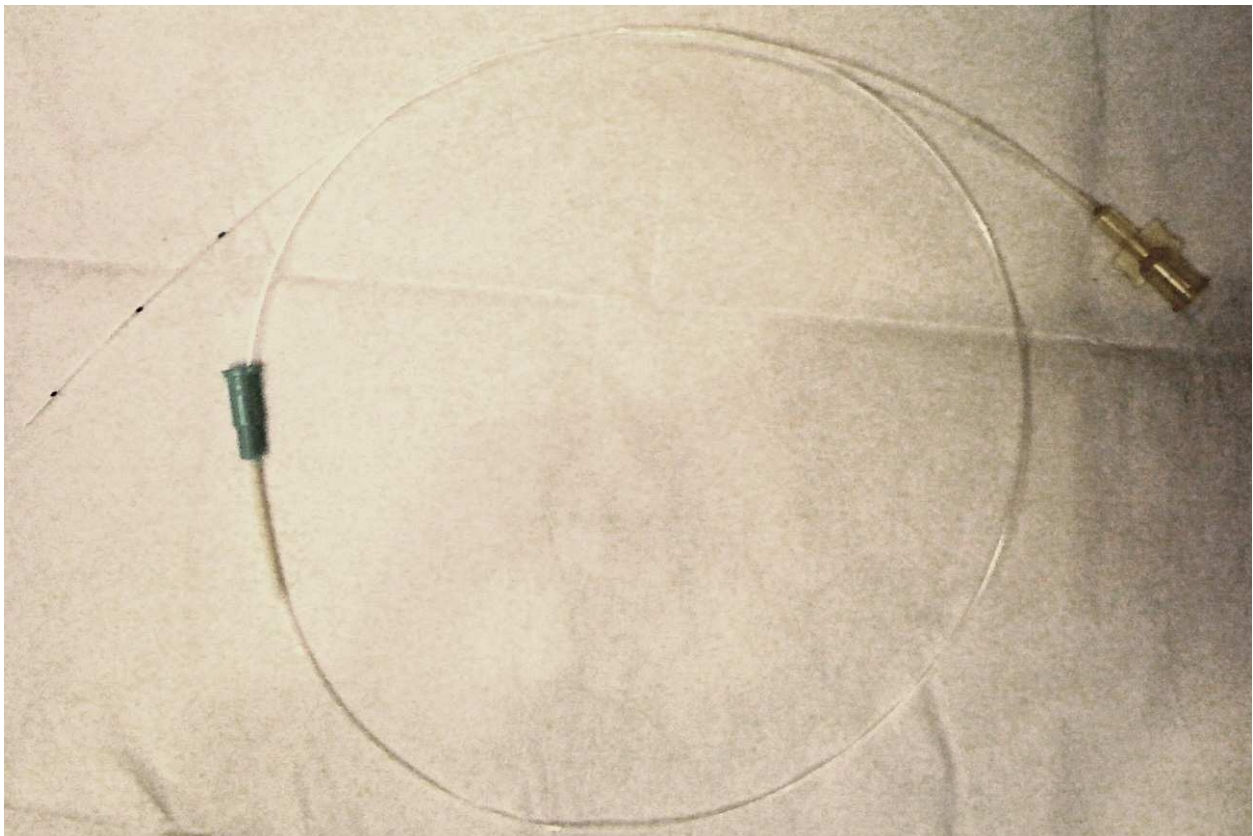


Fig. 2. The flexible catheter for embryo delivery (Precision Reproduction, LLC. LA, CA USA)

A light weight flexible minihysteroscope was used for visualization of the endometrial cavity (Figure 1d) (Storz®, LA, CA USA). The scope incorporates a flexible distal end of 3mm in diameter with a straight through operating channel. In addition, the optic filter is directly connected to a light source, decreasing the weight of the scope and giving a better

“feel” for the scope. The transfer catheter (Precision Reproduction, LLC, LA, CA USA) is polycarbonate based with a tapered tip (to 500 μm), beveled to 60°.

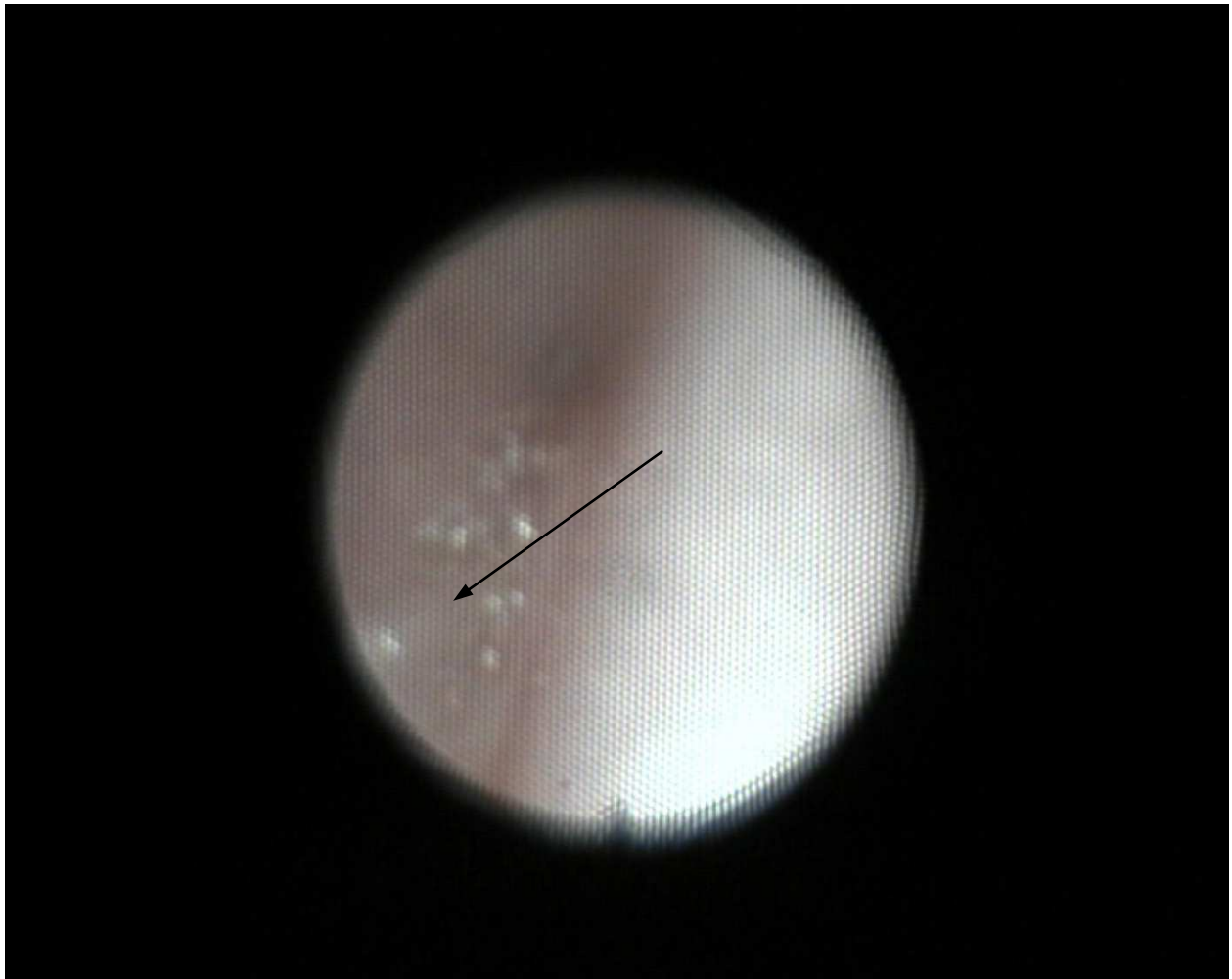


Fig. 3. Placement of embryo(s) under hysteroscopic guidance; arrow points to the tip of the catheter; catheter entry at 8 o'clock position.

3. Results

35 cycles were started and all had retrievals. 22 cycles involved use of intra-cytoplasmic sperm injection (ICSI) due to male factor problems. Endometrial thickness varied between 7 and 16 mm. 22 cycles had transfers on day 2 and 13 cycles had transfers on day 3. There were 16 positive β hCG's greater than 5 IU/ml twelve days after embryo transfer. Of these, 2 had biochemical pregnancies, and 12 had clinical pregnancies as evidenced by presence of gestational sac by ultrasound examination at five weeks of gestation and presence of the fetus and a heart beat at six weeks of gestation. There were 5 first trimester spontaneous abortions at 7-8 weeks of gestation. Seven(7) patients have delivered healthy babies at term; there were 2 ectopic pregnancies (Table 1).

	Day 2 Transfer average age 38.35	Day 3 Transfer average age 38
Total Start	22	13
Cancelled	0	0
Retrievals	22	13
Transfers	22	13
Total + Beta	9	7
Chemical Preg	2	0
Spontaneous ab	3	2
Multiple Preg	3	1
Ectopic preg	1	1
LiveBorn	3(13%)	4(30%)

Table 1. Results from HEED on day2 and day 3 transfers

4. Discussion

As may have been expected, the average age of patients for transfers on day 3 versus day 2 was lower (35 vs. 38 years of age), as they had better quality embryos which made it more feasible to continue embryo culture 1 day longer. Interestingly enough, the live pregnancy rate was also higher in day 3 transfers (31% vs. 15%).

Advantages of hysteroscopic guided direct embryo delivery include objectivity and replicability of the procedure. This unique and significant aspect of the procedure increases the reliability of correct entry into the uterine cavity with direct visual confirmation. Furthermore, placement and subsequent implantation at a precise location, with minimal volume of transfer media, provides an obvious benefit to patients with distorted uterine cavities, myomas, and adenomyosis and uterine adhesions. Visualization also provides the advantage of maneuvering along the contours of the uterus, thus decreasing the rate of trauma to the endometrial lining. In addition, performing gas distension of the uterus by an inert gas (N₂), the catheter tip is less likely to come into contact with the uterine fundus which has been associated with

stimulating uterine contractions and creating an unfavorable environment for implantation (Kovacs 1999, Lesny 1998). It has been reported that high frequency uterine contractions are associated with a lower ongoing clinical pregnancy rate and complete expulsion of the embryo (Fanchin 1998). It has also been postulated that the expulsion of the embryo into the lower uterine segment may result in higher rates of cervical ectopic pregnancy and placenta previas (Romundstad 2006; Schoolcraft 2001).

Witnessing uterine contractions hysteroscopically can also guide the clinician to abort and defer the procedure, thus decreasing costs, multiple failed attempts of ET, embryo loss, and risk of cervical ectopics and placenta previas. Direct visualization of the catheter tip ensures that the embryos are not retained in the catheter or lost. Viser et al. found a lower pregnancy rate when retained embryos were present (3% vs. 20.3%). In addition, catheter tip visualization allowed us to deliver smaller aliquot volumes for ET (5µl) as opposed to routine volumes (30µl). Smaller volume allows better handling of the embryo for proper orientation to the uterine lining, stabilizing the position and has been reported to increase pregnancy and implantation rates (Meldrum 1987). It may also contribute to the reduced

ectopic pregnancy rates, as larger volumes have been associated with increased ectopic pregnancy risk (Marcus 1995). Expulsion of this low volume of transfer media, carrying the embryo(s), from the tip of the catheter can only now be verified under direct visualization. In the “blind” procedure there is a real concern that this tiny droplet can be dragged into the lower uterine segment or into the cervical canal or out of the uterus along with the catheter during the final withdrawal of the catheter after embryo transfer.

The potential disadvantage and risk of this technique is disruption of the uterine lining, however the risk is postulated to be less than “blind” and ultrasound guided transfers due to the advantage of direct visualization of the uterine lining and not requiring movement of the catheter to facilitate identification during ultrasound (Garcia-Velasco 2002). In addition, visualization allows one to place the embryo at a different location if trauma ensues. The major drawback to its acceptance is that hysteroscopy is an invasive procedure. However, as opposed to rigid endoscopes which may cause trauma to the uterus, the hysteroscope used in this study is a mini hysteroscope with a 3 mm diameter and flexible tip that allows one to easily follow the curvature of the uterus. The catheter used is semi-rigid to prevent kinkage as it passes through the endoscope yet with flexibility to bend with the endoscope. In our study, no disruption to the uterine lining or uterine bleeding occurred. Increased cost is another drawback, however utilizing a hysteroscope will decrease the costs from multiple failed IVF-ET attempts and improve patient satisfaction.

5. Conclusion

Hysteroscopic endometrial embryo delivery (HEED) is a beneficial technique in increasing clinical pregnancy rates, especially in patients with repeated failed IVF-ET attempts. Due to the objective and replicable nature of the hysteroscopic procedure along with increased accuracy of placement of embryo(s), efforts in reducing multiple pregnancies should now be more focused on increasing our knowledge of selecting embryo(s) with high survival potential for embryo transfer. Ectopic pregnancies from IVF will be minimized by using lower transfer volumes of 5 μ l and visually confirmed positional placement of embryos away from the uterine cornu. Ectopics are almost eliminated when using the SEED technique for blastocyst embryo transfer.

6. Acknowledgment

Supported by: West Coast IVF Clinic, Inc. and LA IVF LAB, LLC. LA, CA USA

7. References


- Baba K, Ishihara O, Hayashi N, Saitoh M, Taya J, Kinoshita K. Where does the embryo implant after embryo transfer in humans? *Fertil Steril* 2001;73:123-5
- Brown JA, Buckingham K, Abou-Setta A, Buckett W. Ultrasound versus 'clinical touch' for catheter guidance during embryo transfer in women. *Cochrane Database of Systematic Reviews* 2007, Issue 1. Art. No.: CD006107. DOI: 10.1002/14651858.CD006107.pub2.
- Coroleu et al., 2002 Increased risk of placenta previa in pregnancies following IVF/ICSI; a comparison of ART and non-ART pregnancies in the same mother. *Romundstad*

- LB, Romundstad PR, Sunde A, von Düring V, Skjaerven R, Vatten LJ. Hum Reprod. 2006 Sep;21(9):2353-8. Epub 2006 May 25.
- Fanchin R, Righini C, Olivennes F, Taylor S, de Ziegler D, Frydman R. Uterine contractions at the time of embryo transfer alter pregnancy rates after in-vitro fertilization. Hum Reprod 1998;13:1968-74.
- Garcia-Velasco J, Isaza V, Martinez-Salazar J, Landazabal A, Requena A, Remohi J, Pellicer A, Simon C. Transabdominal ultrasound-guided embryo transfer does not increase pregnancy rates in oocyte recipients. Fertility and Sterility 2002;78(3):534-539
- Gardner DK, Lane M. Culture of viable human blastocysts in defined sequential serum-free media. Hum Reprod 1998;13(suppl 3):148-59
- Ghazzawi IM, Al-Hasani S, Karaki R, Sousa S. Transfer technique and catheter choice influence the incidence of transcervical embryo expulsion and the outcome of IVF. Hum Reprod 1999;14:677-82.
- Kamrava M, Yin M. Hysteroscopic Subendometrial Embryo Delivery (SEED), Mechanical Embryo Implantation. IJFS, Vol 4, No 1, Apr-Jun 2010
- Knutzen V., Scoto-Albors C.E., Fuller D., Sher G., Shynock K. and Behr B. (1989) Mock embryo transfer (MET) in early luteal phase, the cycle prior to in-vitro fertilisation and embryo transfer. Presented at the 45th Annual Meeting of the American Fertility Society, San Francisco, California, 13-16 November 1989. Published by the American Fertility Society in the program supplement, p. S152 (Abstract P. 229).
- Kosmas IP, R. Janssens R, De Munck L, Al Turki H, Van der Elst J, Tournaye H and Devroey P. Ultrasound-guided embryo transfer does not offer any benefit in clinical outcome: a randomized controlled trial. Human Reproduction Vol.22, No.5 pp. 1327-1334, 2007
- Kovacs GT. What factors are important for successful embryo transfer after in-vitro fertilization?. Human Reproduction 1999;14:590-592.
- Marcus S, Brinsden P. Analysis of the incidence and risk factors associated with ectopic pregnancy following in-vitro fertilization and embryo transfer. Hum Reprod 1995;10:199-203.
- Meldrum DR, Chetkowski R, Steingold KA, de Ziegler D, Cedars MI, Hamilton M. Evolution of a highly successful in vitro fertilization embryo transfer program. Fertil Steril 1987;48:86-93
- Liv Bente Romundstad, Pal R. Romundstad, Arne Sunde, Vidar von Düring, Rolv Skjærven and Lars J. Vatten. Increased risk of placenta previa in pregnancies following IVF/ICSI; a comparison of ART and non-ART pregnancies in the same mother. Human Reproduction Vol.21, No.9 pp. 2353-2358, 2006
- Sallam HN, Saad-el-Din S. Performing embryo transfer under ultrasound guidance- A meta analysis of randomized trials. Fertility and Sterility. 2002; Vol. 78, issue 3 (Suppl 1):S46
- Schoolcraft WB, Surrey ES, Gardner DK. Embryo transfer: techniques and variables affecting success. Fertil Steril 2001;76:863-70.
- Sieck UV, Jaroudi KA, Hollanders JM, Hamilton CJ. Ultrasound guided embryo transfer does not prevent ectopic pregnancies after in-vitro fertilization. Hum Reprod 1997;12:2081-2
- Strandell, J. Thorburn and L. Hamberger, Risk factors for ectopic pregnancy in assisted reproduction, Fertil Steril 71 (1999), pp. 282-286.

Visser DS, Fourie FL, Kruger HF. Multiple attempts at embryo transfer: effects on pregnancy outcome in an in vitro fertilization and embryo transfer program. *J Assist Reprod Genetics* 1993;10:37–43.

IntechOpen

IntechOpen



Ectopic Pregnancy - Modern Diagnosis and Management

Edited by Dr. Michael Kamrava

ISBN 978-953-307-648-5

Hard cover, 248 pages

Publisher InTech

Published online 26, October, 2011

Published in print edition October, 2011

Ectopic pregnancy is the second major cause of maternal mortality in the United States and a leading cause of maternal morbidity and mortality in the world. This book contains the practical methods to early diagnosis of various forms of ectopic pregnancies and their modern management. Ectopic Pregnancy - Modern Diagnosis and Management is a comprehensive book which guides the reader through all features of ectopic pregnancy, both practical and academic, covering all aspects of diagnosis and management of ectopic pregnancy in a clear, concise, and practical fashion. The book is organized so that it can either be read cover to cover for a comprehensive tutorial or be kept desk side as a reference to the ectopic pregnancies. Each chapter introduces a number of related ectopic pregnancy and its diagnosis, treatment and co-morbidities supported by examples. Included chapters bring together valuable materials in the form of extended clinical knowledge from practice to clinic features.

How to reference

In order to correctly reference this scholarly work, feel free to copy and paste the following:

M.M. Kamrava, L. Tran and J.L. Hall (2011). Hysteroscopic Endometrial Embryo Delivery (HEED), Ectopic Pregnancy - Modern Diagnosis and Management, Dr. Michael Kamrava (Ed.), ISBN: 978-953-307-648-5, InTech, Available from: <http://www.intechopen.com/books/ectopic-pregnancy-modern-diagnosis-and-management/hysteroscopic-endometrial-embryo-delivery-heed->

INTECH
open science | open minds

InTech Europe

University Campus STeP Ri
Slavka Krautzeka 83/A
51000 Rijeka, Croatia
Phone: +385 (51) 770 447
Fax: +385 (51) 686 166
www.intechopen.com

InTech China

Unit 405, Office Block, Hotel Equatorial Shanghai
No.65, Yan An Road (West), Shanghai, 200040, China
中国上海市延安西路65号上海国际贵都大饭店办公楼405单元
Phone: +86-21-62489820
Fax: +86-21-62489821

© 2011 The Author(s). Licensee IntechOpen. This is an open access article distributed under the terms of the [Creative Commons Attribution 3.0 License](#), which permits unrestricted use, distribution, and reproduction in any medium, provided the original work is properly cited.

IntechOpen

IntechOpen