

We are IntechOpen, the world's leading publisher of Open Access books Built by scientists, for scientists

4,800

Open access books available

122,000

International authors and editors

135M

Downloads

Our authors are among the

154

Countries delivered to

TOP 1%

most cited scientists

12.2%

Contributors from top 500 universities



WEB OF SCIENCE™

Selection of our books indexed in the Book Citation Index
in Web of Science™ Core Collection (BKCI)

Interested in publishing with us?
Contact book.department@intechopen.com

Numbers displayed above are based on latest data collected.
For more information visit www.intechopen.com



Spinal Cord Sarcoidosis Accompanied with Compressive Cervical Myelopathy

Yoshihito Sakai¹, Yukihiro Matsuyama² and Shiro Imagama³

¹*Department of Orthopaedic Surgery, National Center for Geriatrics and Gerontology,*

²*Department of Orthopaedic Surgery, Hamamatsu University School of Medicine,*

³*Department of Orthopaedic Surgery, Nagoya University School of Medicine,
Japan*

1. Introduction

Spinal cord Sarcoidosis was first described by Longcope in 1941 (Longcope, 1941), and since then, spinal cord involvement has been reported in less than 10% of patients with neurosarcoidosis (Bogousslavsky et al., 1982, Fried et al., 1993) Spinal cord sarcoidosis is a chronic, granulomatous, systemic inflammatory disease, although precise understanding of the pathogenesis remains unclear, and most commonly occurs at the cervical level, presenting with subacute or chronic myelopathy frequently progressing to paraplegia (Sauter et al., 1991, Morita et al., 1992). The mainstay of treatment of spinal cord sarcoidosis is high-dose corticosteroid therapy, and surgery is undertaken when suggested by biopsy results and histopathological diagnosis (Jallo et al., 1997). However, since the lower middle cervical segments are more frequently affected (Nagai et al., 1985), it is difficult to differentiate cervical spinal cord sarcoidosis from cervical spondylotic myelopathy when gradually occurring in elderly patients. Magnetic resonance imaging (MRI) findings with high signal intensity on T2 weighted images and vagueness of diffuse enlargement of the spinal cord due to spinal canal stenosis often leads to the surgeons to diagnose spinal cord sarcoidosis only after decompressive surgery has been performed for compressive cervical myelopathy.

More than 80 cases of spinal cord sarcoidosis have been reported, most of which were studied using MRI (Kanzaki et al., 2004). There are no papers on the coexistence of compressive cervical myelopathy and cervical spinal cord sarcoidosis, and it is uncertain not only whether compressive cervical myelopathy triggers the development of inflammatory granuloma in spinal cord sarcoidosis but also the effect of decompressive surgery. In this chapter, the outcome of decompressive surgery performed for cervical spinal cord sarcoidosis accompanied with compressive cervical myelopathy and the effect of steroid therapy provided after decompressive surgery is expressed, comparing the outcome of the treatment of spinal cord sarcoidosis with no compressive cervical myelopathy shown by MRI.

2. Diagnosis

Nagoya Spine Group (NSG) was established since April 2006 by the spine surgeons of Nagoya University Hospital and 15 referral hospitals to evaluate the outcome of surgical treatment of spinal disorders in a prospective and/or retrospective multicenter clinical series. The NSG

database included 6,187 cases of patients who underwent spinal surgery, of which 1,560 cases were of compressive cervical myelopathy treated with cervical laminectomy or laminoplasty from January 2001 to December 2005. Of the 1,560 patients, a total of 12 (0.08%) patients were identified with spinal cord sarcoidosis, which was treated with decompressive surgery during the study period. The medical records of these 12 patients were retrieved, and the demographic data collected included age, sex, duration of disease, surgical outcome, and effectiveness of steroid therapy. The study was independently reviewed and approved by the institutional review boards at all participating institutions.

The medical records of the patients were reviewed. The patients comprised 5 men and 7 women, in the age range of 47 to 74 years (median, 57.8 years). Postoperative follow-up period ranged from 1 to 5 years (median, 2.0 years). Preoperative MRI was performed in all the cases and all lesions were observed to be present in the cervical region. Surgical outcome was evaluated using the Japanese Orthopaedic Association (JOA) scoring system, the JOA score was established prospectively at the time of treatment. This score comprises a total of 17 points; 4 points each for motor dysfunction of the upper and lower extremities, respectively; 2 points each for sensory dysfunction of the upper and lower extremities and the trunk, respectively; and 3 points for bladder dysfunction. The recovery rate was calculated using Hirabayashi's method.

Zajicek's diagnostic criteria (Zajicek et al., 1999), those of "definite", "probable", and "possible" were adopted for neurosarcoidosis. In brief, neurosarcoidosis was defined as "definite" when histopathological findings showed sterile, noncaseating granuloma in the spinal cord tissue. Neurosarcoidosis was defined as "probable" in the case of presence of spinal cord inflammation (elevated cerebrospinal fluid (CSF) protein level and/or increased cell number or spinal cord MRI findings comparable with those indicating neurosarcoidosis). Neurosarcoidosis was defined as "possible" when suggested by clinical presentation. After surgery, the diagnosis of neurosarcoidosis was confirmed, and the duration between the diagnosis and surgery ranged from 0 to 6 months (median, 3.9 weeks).

3. Treatment

3.1 Surgical treatment

All the 12 patients underwent decompressive surgery, including laminectomy (2 patients) and laminoplasty (10 patients). Preoperative diagnosis was intramedullary spinal cord tumor with compressive cervical myelopathy in 8 cases and cervical spondylotic myelopathy in 4 cases. That is all patients had compressive cervical myelopathy and spinal canal stenosis, with intramedullary T2 hyperintensity extending to the cervical level on MRI. The duration between the onset of initial symptoms and the operation ranged from 3 weeks to 1.5 years (median 7.3 months). Spinal cord biopsy was performed with the intraoperative motor-evoked potential (MEP) monitoring in 8 cases because intramedullary lesion was suspected on preoperative MRI or intraoperative ultrasonography; in the other 4 cases, only decompressive surgery was performed owing to the preoperative diagnosis of cervical spondylotic myelopathy. Radical surgical removal of the intramedullary sarcoid granuloma was possible only in 1 case.

3.2 Steroid therapy

All the 12 patients were provided high-dose corticosteroid therapy postoperatively. The duration between the operation and initiation of steroid administration ranged from 1 week

to 3 months (median, 31.3 days). The effect of the steroid administered was evaluated on the basis of the JOA score. As control subjects, 8 patients with spinal cord sarcoidosis but showing no compressive lesion on MRI and who received high-dose steroid therapy from a neurologist without surgery were recruited to compare the effectiveness of the steroid and the outcome of spinal cord sarcoidosis. Their demographic data are presented in Table 1. The JOA score assigned of the non-surgery group was calculated on the basis of the retrospective review of the charts of the patients. There were no significant differences in the initial dose of the corticosteroid between the surgery and the non-surgery groups.

	Surgery group (N=12)	Non-surgery group (N=8)
Age (years)	57.8±9.8	62.4±8.2
Gender (M/F)	5/7	2/6
Follow-up period (month)	24.0±15.2	30.2±15.0
Period from onset to surgery (week)	17.6±5.7	—
Period from onset to steroid (day)	44.9±15.9	43.5±12.8
Initial dose of steroid (mg/day)	54.0±7.0	51.3±4.2
JOA score before treatment (point)	8.2±2.4	8.9±2.4

Table 1. Demographics of surgery and non-surgery group

Non-surgery group indicates the patients with spinal cord sarcoidosis without compressive cervical myelopathy on MRI finding who underwent steroid therapy without operation.

3.3 Statistical analysis

StatView 5.0 software (ABACUS, Berkeley, CA) was used to calculate the statistical difference. Equality of means for continuous variables was assessed by using the Mann-Whitney test. A *P* value of 0.05 or less was considered to be statistically significant.

4. Results

In the surgery group, 8 and 4 patients were identified with definite and probable neurosarcoidosis, respectively after decompressive surgery. The diagnosis in all the 8 cases of definite neurosarcoidosis was confirmed by biopsy results. The other 4 cases of probable neurosarcoidosis were diagnosed by a neurologist on the basis of laboratory data for inflammation of the spinal cord and biopsy of the lung, skin or eye. Spinal cord sarcoidosis was preoperatively suspected in 4 patients; however, they all showed negative results on clinical examination and other tissue biopsies. In the non-surgery group, all the 8 patients were diagnosed by a neurologist as having probable neurosarcoidosis without performing spinal cord biopsy.

4.1 Clinical presentation

There were no acute spinal cord symptoms that progressed within 1 month in both the surgery and the non-surgery groups. The characteristic spinal cord symptoms included chronic symptoms, which progressed over 3 months in 7 (58.3%) and 6 patients (75.0%) in the surgery and non-surgery groups, respectively, and subacute symptoms, which progressed within 3 months in 5 (41.7%) and 2 patients (25%) in the surgery and non-surgery groups, respectively. All the patients in both the groups presented with insidious paresthesias in the extremities. In the surgery group, a discrepancy was observed between the narrowest portion and the neurological findings in the case of 7 (58.3%) patients. Other presentations such as hand

clumsiness, gait disturbance, and bladder dysfunction in both the groups are shown in Fig. 1. The surgery group exhibited a slight tendency to show serious neurological findings; however, there were no significant differences between the 2 groups.

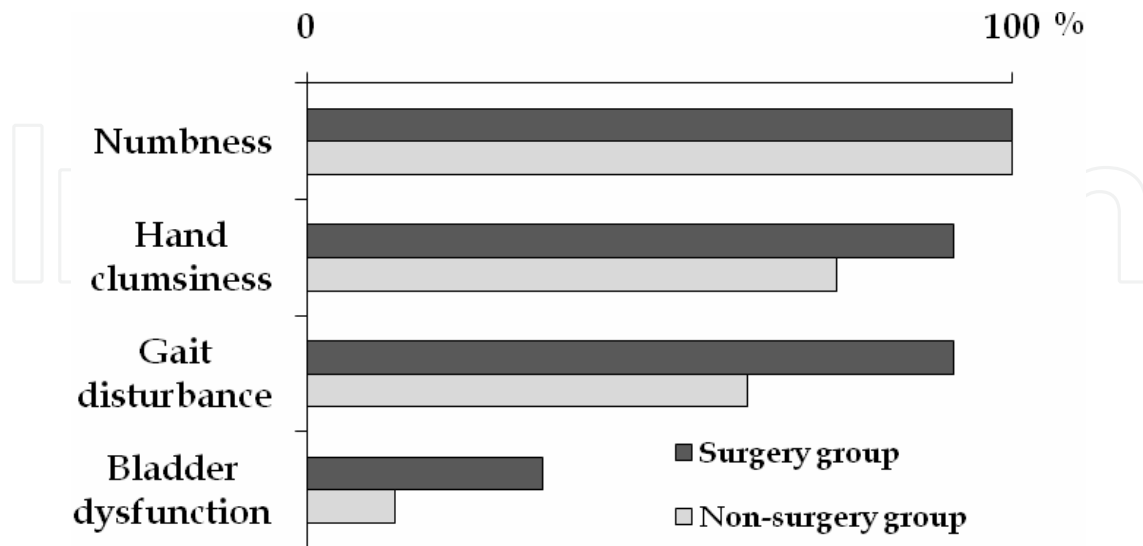


Fig. 1. Neurological symptoms

4.2 MRI findings

All the patients had fusiform enlargement of the spinal cord with high signal intensity on T2-weighted images and enhancing lesions in the spinal cord. Meningeal patchy enhancement occurred in 4 cases (33.3%) and 3 cases (37.5%) in the surgery and non-surgery groups, respectively. In the surgery group, high signal intensity on T2-weighted images extended from C2 to Th1, and the maximum compression levels were present in the high signal intensity area. Enhancing lesions were observed at C5-6 in 7 cases, C6-7 in 2 cases, C4/5 in 1 case, C2/3-Th1 in 1 case and C3/4-C6 in 1 case, which coincided with the maximum compression levels observed in all the cases. (Fig.2)

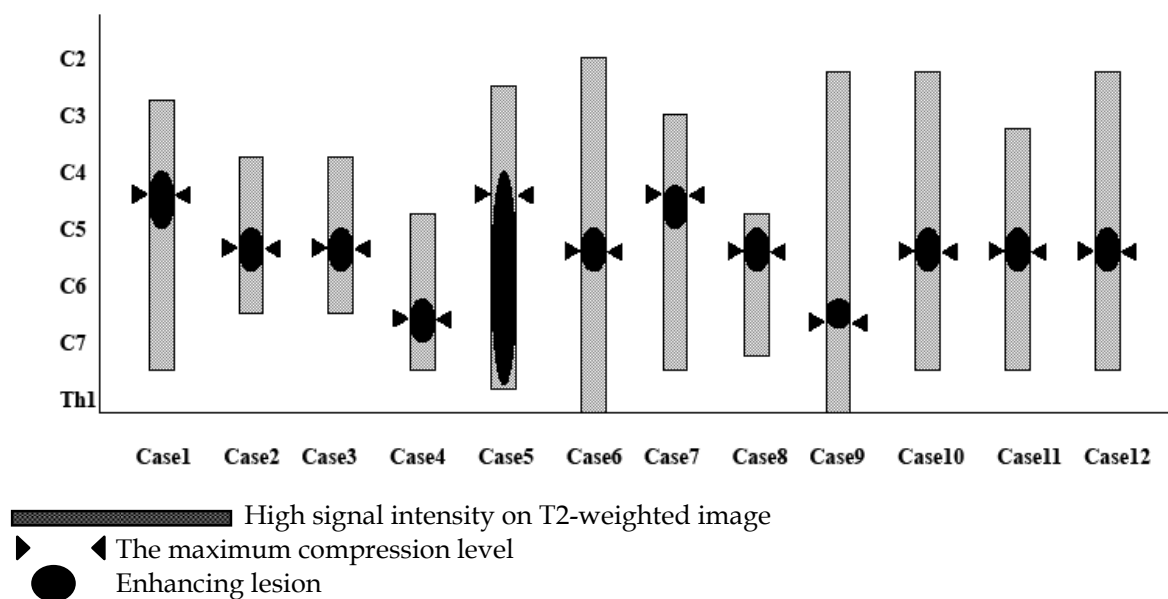


Fig. 2. The distribution of the affected spinal segments.

4.3 Surgical outcome

Preoperative JOA score in the surgery group was 8.2 points (2.0-11.0 points), and that in the non-surgery group was 9.0 points (5.0-13.0 points), with no significant differences. ($p=0.52$) Postoperative JOA score in the surgery group slightly decreased at 1 week and 4 weeks, and postoperative recovery rates in the surgery group at 1 week and 4 weeks were -7.4% (from -52.9% to 25.0%) and -1.1% (from -41.2% to 25.0%), respectively (Fig.3). Only 5 of the 12 patients showed clinical improvement after decompressive surgery, but their condition worsened again at an average of 7.4 weeks (2-12 weeks) after surgery. The average postoperative recovery rate of these 5 patients at 4 weeks was in 17.4% (9.5%-25.0%). After surgery, these 5 patients showed reduction in high signal intensity on T2-weighted images and enhancing lesions in the spinal cord; however, the improvement in MRI findings was not always consistent with neurological improvement. Only 2 of the 5 patients who showed temporary neurological improvement showed regression of the intramedullary sarcoid lesions. There was no correlation between the MRI findings after decompressive surgery and the clinical results.

As postoperative complications, C5 palsy and infection were seen in 1 patient each. Sensory deterioration was seen in 4 of the 8 patients who underwent spinal cord biopsy. No motor deterioration was seen immediately after surgery except in 1 case of C5 palsy. No abnormal wave patterns on MEP monitoring were observed during biopsy as well as the whole procedure in any patient who underwent spinal cord biopsy.

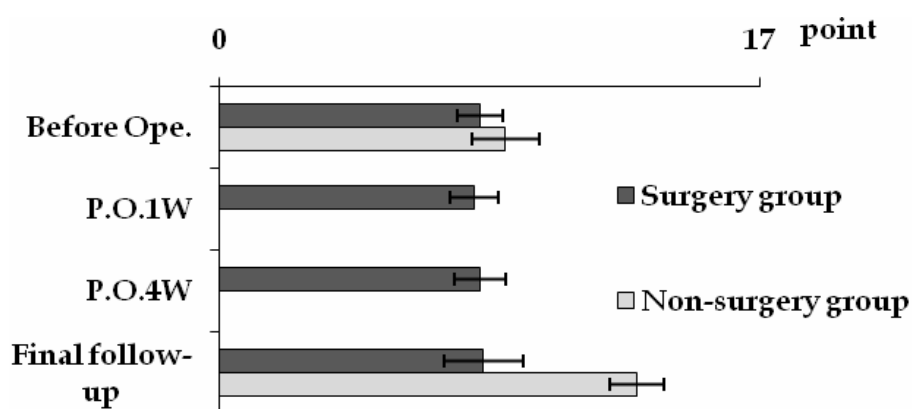


Fig. 3. JOA scores before and after each treatment

4.4 Effect of steroid therapy

Postoperative diagnosis of spinal cord sarcoidosis was made on the basis of pathological findings of the spinal cord in 8 patients, lung biopsy results in 2 patients, skin biopsy findings in 1 patient, and eye biopsy results in 1 patient at an average of 3.9 weeks (1-24 weeks). Postoperative oral steroid therapy was initiated at an average of 6.4 weeks (2-25 weeks), and the average initial dose was 54.0 mg (40-60 mg) in the surgery group and 51.3 mg (30-60 mg) in the non-surgery group. There was no statistical significance in the initiated dose between the 2 groups. No patients were provided steroid therapy before decompressive surgery in the surgery group. Two patients in the surgery group died of another disease irrelevant to spinal cord sarcoidosis at 1 year and 22 months. The JOA score before steroid therapy, at 4 weeks and 1 year after steroid therapy and the recovery rate at the final follow-up are shown in Fig. 4 and Fig.5. Significant differences were observed in the JOA scores at 4 weeks and 1 year after steroid therapy. ($p<0.05$) At the final follow-up,

the recovery rate of the JOA score, which increased after steroid therapy, was significantly higher in the non-surgery group (62.5%) than in the surgery group (18.6%) ($p<0.01$).

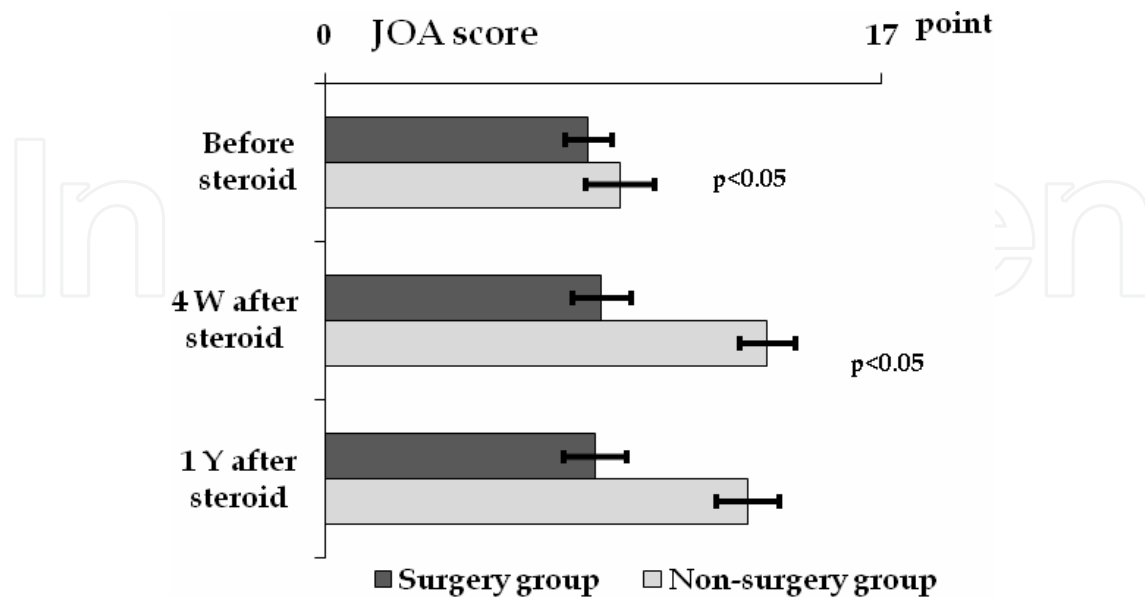


Fig. 4. JOA score before and after steroid administration.

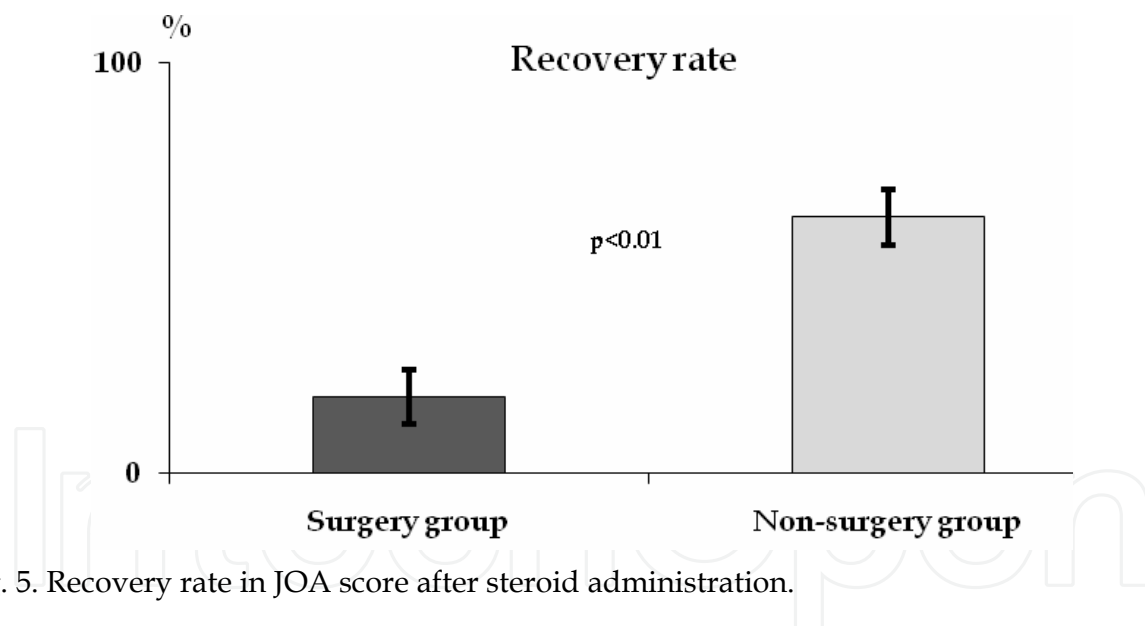


Fig. 5. Recovery rate in JOA score after steroid administration.

4.5 Representative case (Fig.6)

A 63-year-old woman presented with an 8 year history of gradual progression of numbness in the upper and lower extremities, bilateral hand clumsiness, gait disturbance and bladder dysfunction. MRI showed spinal cord compression and T2 hyperintensity extending from C4/5 to C5/6. Gadolinium enhancement was seen at the same levels as those of compression in sagittal slice and of multiple white-matter lesions in axial slice. Spinal cord sarcoidosis was suspected but other investigations including lymph node biopsy and bronchoalveolar lavage fluid analysis showed no abnormality. Anterior decompression/corpectomy should be reasonable for anterior compression and slight

kyphosis at C4/5 observed on MRI; however, posterior approach was adopted. After laminoplasty from C3 to C7 and spinal cord biopsy, the patient's numbness and motor dysfunction were slightly reduced for 2 weeks, but T2 hyperintensity and gadolinium enhancement increased. After diagnosis of spinal cord sarcoidosis on the basis of pathological findings of the spinal cord, high-dose corticosteroid therapy (60mg) was initiated. Improvement was observed in the symptoms and MRI findings, but motor dysfunction persisted in the hands.

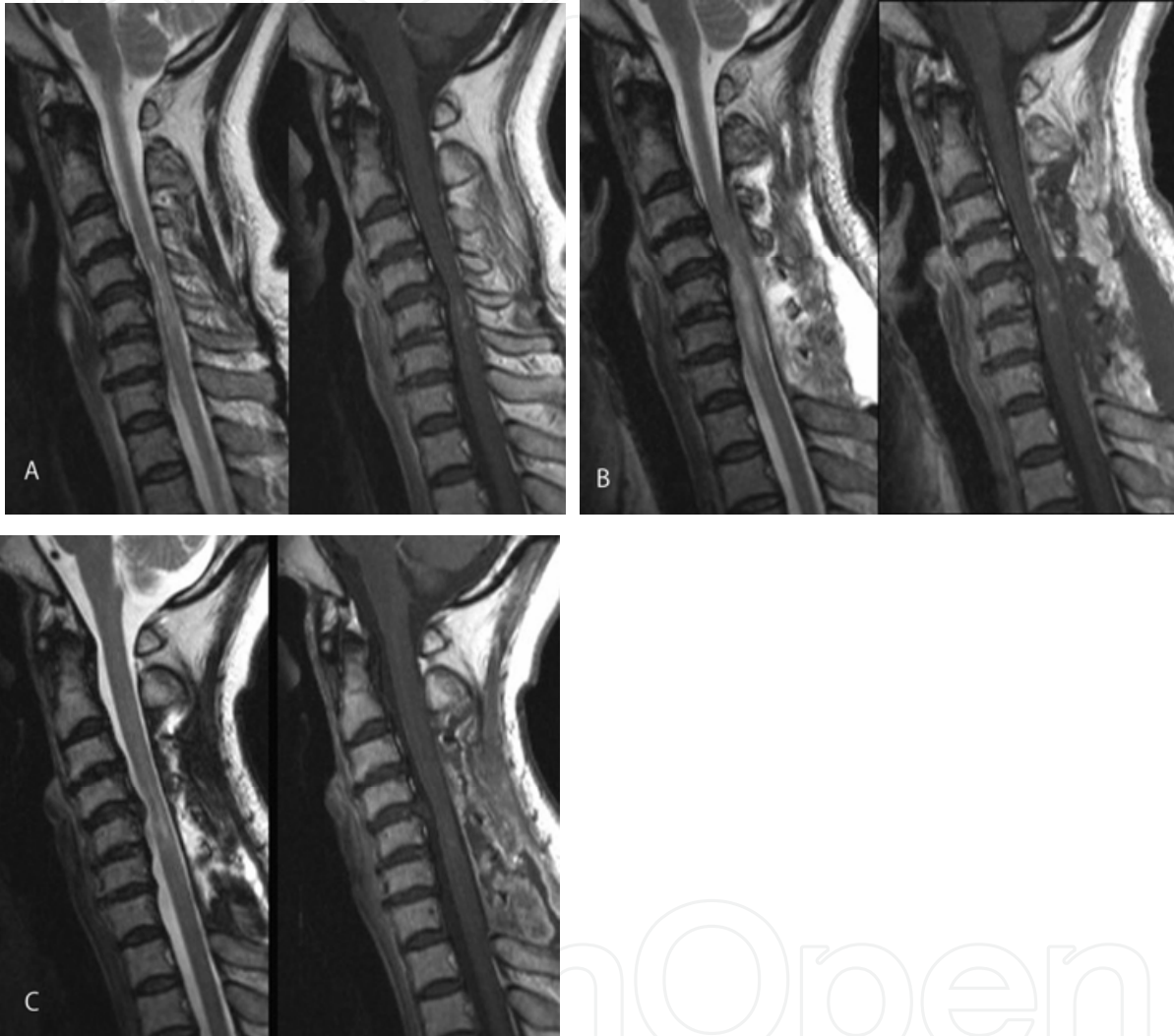


Fig. 6. Representative case (63 years, female). A. Preoperative MRI showing spinal cord compression at C4/5 and T2 hyperintensity and gadolinium enhancement at C5. B. Postoperative MRI showing extended T2 hyperintensity and gadolinium enhancement. C. After administration of corticosteroid, T2 hyperintensity and gadolinium enhancement remarkably improved.

5. Discussion

Histopathogenesis of sarcoidosis of the central nervous system is considered as the flow of primary leptomeningeal inflammatory exudate from the subarachnoid space along the Virchow-Robin spaces into the brain parenchyma (Mirfakhraee et al., 1986). It remains

unknown if this hypothesis applies to spinal cord sarcoidosis; however, inflammatory granuloma formation and progressive fibrosis caused by immunological reaction play an important role (Newman et al., 1997). Clinical diagnosis of spinal cord sarcoidosis is often difficult since the nervous system is a relatively uncommon site for the occurrence of the disease. Biopsy of the nervous system tissue is required for definite diagnosis of neurosarcoidosis, and Zajicek et al. proposed definite diagnosis of the disease on the basis of positive histological findings of the nervous system (Zajicek et al., 1999). Unfortunately, biopsy is not possible or desirable in many cases because of the site of involvement. A presumptive diagnosis of sarcoidosis can be made on the basis of clinical or imaging evidence such as MRI findings, CSF angiotensin-converting enzyme (ACE) level, increased lysosome count and raised beta 2-microglobulin level, an increased helper-suppressor T-lymphocyte ratio, or a CD4/CD8 ratio of >5 (Joseph et al., 2007). A comprehensive search for any systematic feature is required for the diagnosis of sarcoidosis after clinical confirmation of neurological involvement.

On the other hand, it is well known that while increased pressure within the spinal cord and sequential hypoxia and ischemic changes play important roles in the progression of lesions in cervical spondylotic myelopathy (Ito et al., 1996), involvement of inflammatory processes has also been indicated (Frank et al., 1995, Demircan et al., 2007). It is uncertain whether compressive cervical myelopathy triggers the development of inflammatory granuloma in spinal cord sarcoidosis. In the present study, MRI findings showed that area of enhancing sarcoid lesions coincided with the maximum compression levels. However, further study should be conducted to identify the relation between compressive myelopathy and lesions in sarcoidosis.

Diagnosis of sarcoidosis is expected to be difficult when the disease is accompanied with spinal cord compression due to cervical spondylosis; however, in this regard, a few reports are available. Ando et al. mentioned that spinal cord swelling without serious compression and disagreement between the level of compression and the extent of T2 hyperintensity challenge the presence of sarcoidosis (Ando et al., 2006). The present study demonstrated that the maximum compression levels in cervical spondylotic myelopathy coincided with the area of enhancing lesions, resulting in the inability to identify as sarcoidosis on the basis of MRI findings. Another study reported that inconsistency between the area with sensory disturbance and the affected level in cervical spondylotic myelopathy responsible for the main functional disorder enables differentiation (Oe et al., 2006). The fact that a discrepancy was observed between the narrowest portion and neurological findings in 58.3% patients indicates the difficulty in discriminating the affected levels in spinal cord sarcoidosis, especially in cases with multilevel stenosis. In addition, MRI findings concerning clinically silent compression of the spinal cord in elderly patients and the difficulties encountered in determining the exact responsible level in multisegmental compression (Boden et al., 1990) prompt many surgeons to perform multisegmental decompression by laminoplasty (Yonenobu et al., 1992, Satomi et al., 1994, Seichi et al., 2001). Neurological findings would not be reliable for diagnosis when spinal cord sarcoidosis develops at the level of stenosis.

Decompressive surgery produced temporary improvement in the condition of one-third of the patients with spinal cord sarcoidosis accompanied with compressive cervical myelopathy. However, the neurological symptoms relapsed postoperatively after a few months, and all the patients were provided steroid therapy. Spinal cord biopsy would have affected sensory deterioration immediately after surgery. In the previous study, neurological changes secondary to spinal cord biopsy occurred in 6 of 38 patients who

underwent biopsy; further, all postoperative complications were all mild and completely resolved in most cases at 3 months after surgery (Cohen-Gadol et al., 2003). Gradual neurological deterioration after decompressive surgery indicates insufficient decompression for lesions in sarcoidosis. In general surgical results of laminoplasty for cervical spondylotic myelopathy have been shown to be good, helping to prevent neurological deterioration and resulting in 50%-70% recovery rates (Sakai et al., 2005, Yukawa et al., 2007). The present study demonstrated that the average recovery rate of the patients who showed neurological improvement after surgery was 17.4%, which was extremely lower than that observed in cervical spondylotic myelopathy; further, the improvement was only transitory.

While steroid administration after decompressive surgery was shown to be effective for spinal cord sarcoidosis accompanied with compressive cervical myelopathy, the outcome was poorer than that of the treatment of spinal cord sarcoidosis without compressive cervical myelopathy. This may be ascribed to the irreversible change produced in the spinal cord due to mechanical compression. In spinal cord sarcoidosis accompanied with compressive cervical myelopathy, decompressive surgery including laminoplasty should not be the first choice of treatment except for cases with appropriate differentiation of intramedullary spinal cord tumor and early diagnosis of sarcoidosis. Although there are no distinct signal characteristics for spinal cord sarcoidosis, diffuse increase in intramedullary T2 hyperintensity, presence of enhancing nodules, and leptomeningeal involvement suggest the disease. The mainstay of medical treatment of spinal cord sarcoidosis is steroid therapy, thus, it should be preferred after early diagnosis rather than decompressive surgery. Postoperative neurological deterioration after resection of sarcoid granulomas has been reported (Day et al., 1977, Baruah et al., 1978). Mathieson et al demonstrated that among 31 cases of histologically proven intramedullary sarcoidosis, postoperative deterioration in neurological function occurred in 50% cases (Mathieson et al., 2004). Thus, several reports suggest that the first surgery should be limited to decompression of the spinal cord and biopsy without complete extirpation in cases of suspected spinal cord sarcoidosis (Rubinstein et al., 1984, Vighetto et al., 1985, Kayama et al., 1993, Jallo et al., 1997, Yukawa et al., 1999). However, there has been no report describing the effects of spinal cord decompression on lesions in sarcoidosis. In spinal cord sarcoidosis accompanied with compressive cervical myelopathy such as in our series, it is difficult to determine which lesion is responsible for the neurological symptoms. Early treatment with a suitable steroid decreases inflammation in sarcoidosis (Soucek et al., 1993) and MRI findings are dramatically improved by corticosteroid therapy (Koike et al., 2000). A long interval between the onset of the disease and the initiation of steroid therapy contributes to poor functional recovery (Stern et al., 1985). Decompressive surgery should be undertaken when steroid therapy proves to be insufficient for the treatment of spinal cord sarcoidosis accompanied with cervical compressive myelopathy. In addition in cases with unsatisfactory results of decompressive surgery for compressive cervical myelopathy, presence of spinal cord sarcoidosis should be considered, if spinal cord swelling and/or increase in intramedullary T2 hyperintensity are observed after decompression. In some cases, enlarged spinal cord appears unclear with coexisting compressive cervical lesions. Spinal cord enlargement is occasionally underestimated when cervical spondylotic compression coexists. Spinal cord biopsy is indispensable if the diagnosis of sarcoidosis is not proved; however, the risks involved in performing biopsies for nonspecific spinal cord lesions may lead to the preference for generalized screening and diagnosis of sarcoidosis on the basis of less invasive procedures before subjecting the patient to surgery. The patients

should be informed that the prognosis of surgery is guarded in any case of spinal cord sarcoidosis.

6. Conclusions

The effectiveness of decompressive surgery for spinal cord sarcoidosis accompanied with compressive cervical myelopathy is transitory and not adequate. Steroid therapy after decompressive surgery is also less effective for spinal cord sarcoidosis accompanied with compressive cervical myelopathy, compared with the treatment of spinal cord sarcoidosis without compressive cervical myelopathy. Early diagnosis of sarcoidosis and steroid therapy is preferred.


7. References

- Ando, T.; Kameyama, T.; Suzuki, K.; Yoshida, A. & Kurahashi, T. (2006) Spinal cord sarcoidosis: A clinical dilemma and informed consent. *Spine & Spinal Cord (Japanese)* Vol. 19, No. 6, pp. 694-701.
- Boden, SD.; McCowin, PR.; Davis, DO.; Dina, TS.; Mark, AS. & Wiesel S. (1990) Abnormal magnetic-resonance scans of the cervical spine in asymptomatic subjects. A prospective investigation. *J Bone Joint Surg [Am]* Vol. 72-A, pp. 1178-1184, ISSN 0021-9335
- Baruah, JK.; Glasauer, FE.; Sil, R. & Smith BH. (1978) Sarcoidosis of the cervical spinal canal: case report. *Neurosurgery* Vol. 3, No. 2, pp. 216-218, ISSN 0148-396X
- Bogousslavsky, J.; Hungerbühler, JP.; Regli, F. & Graf, HJ. (1982) Subacute myelopathy as the presenting manifestation of sarcoidosis. *Acta neurochirurgica* Vol. 65, No. 3, pp. 193-197, ISSN 0001-6268
- Cohen-Gadol, AA.; Zikel, OM.; Miller, GM.; Aksamit, AJ.; Scheithauer, BW. & Krauss WE. (2003) Spinal cord biopsy: A review of 38 cases. *Neurosurgery* Vol. 52, No. 4, pp. 806-816, ISSN 0148-396X
- Day, AL. & Sybert, GW. (1977) Spinal cord sarcoidosis. *Annals of Neurology* Vol. 1, No. 1, pp. 79-85, ISSN 0364-5134
- Demircan, MN.; Asir, A.; Cetinkal, A.; Gedik, N.; Kutlay, AM.; Çolak, A.; Kurtar, S. & Simsek, H. (2007) Is there any relationship between proinflammatory mediator levels in disc material and myelopathy with cervical disc herniation and spondylosis? A non-randomized, prospective clinical study. *European Spine Journal* Vol. 16, No. 7, pp. 983-986, ISSN 0940-6719
- Frank, E. (1995) HLA-DR expression on arachnoid cells. A role in the fibrotic inflammation surrounding nerve roots in spondylotic cervical myelopathy. *Spine* Vol. 20, No. 19, pp. 2093-2096, ISSN 0887-9869
- Fried, ED.; Landau, AJ.; Sher, JH. & Rao C. (1993) Spinal cord sarcoidosis: A case report and review of the literature. *Journal of the Association for Academic Minority Physicians* Vol. 4, No. 4, pp. 132-137, ISSN 1048-9886
- Ito, T.; Oyanagi, K.; Takahashi, H.; Takahashi, HE. & Ikuta, F. (1996) Cervical spondylotic myelopathy: Clinicopathologic study on the progression pattern and thin myelinated fibers of the lesions of seven patients examined during complete autopsy. *Spine* Vol. 21, No.7, pp. 827-833, ISSN 0887-9869.
- Jallo, GI.; Zagzag, D.; Lee, M.; Deletis, V.; Morota, N. & Epstein, FJ. (1997) Intraspinal

- sarcoidosis: diagnosis and management. *Surgical Neurology* Vol. 48, No. 5, pp. 514-521, ISSN 0090-3019
- Joseph, FG. & Scolding, NJ. (2007) Sarcoidosis of the nervous system. *Pract Neurol* Vol. 7, No. 4, pp. 234-244, ISSN 1590-1874
- Kanzaki, M.; Mochizuki, H.; Kobayashi, H.; Motoyoshi, K. & Kamakura, K. (2004) Intraspinal sarcoidosis: Clinical features, MR imaging and electrophysiological study. *Neurol Sci* Vol. 25, No. 2, pp. 91-94.
- Kayama, S. & Kikuchi, S. (1993) Intramedullary sarcoidosis of the spinal cord. *Spine* Vol. 18, No. 14, pp. 2118-2120, ISSN 0887-9869
- Koike, H.; Misu, K.; Yasui, K.; Kameyama, T.; Ando, T.; Yanagi, T. & Sobue G. (2000) Differential response to corticosteroid therapy of MRI findings and clinical manifestations in spinal cord sarcoidosis. *Journal of Neurology* Vol. 247, No. 7, pp. 544-549, ISSN 0340-5354
- Longcope, WT. (1941) Sarcoidosis, or Besnier-Boeck-Schaumann disease. Frank Billings lecture. *JAMA* Vol.117, pp. 1321-1327, ISSN 0002-9955
- Mathieson, CS.; Mowle, D.; Ironside, JW. & O'riordan, R. (2004) Isolated cervical intramedullary sarcoidosis- a histological surprise. *British Journal of Neurosurgery* Vol. 18, No. 6, pp. 632-635
- Mirfakhraee, M.; Crofford, MJ.; Guinto, FC.; Nauta HJW. & Weedon, VW. (1986) Virchow-Robin space: a path of spread in neurosarcoidosis. *Radiology* Vol.158, No.3, pp. 715-720, ISSN 0033-8419
- Morita, H.; Hayashi, R.; Tako, K.; Tsukada, N. & Yanagisawa N. (1992) Spinal cord sarcoidosis: MRI findings in response to treatment. *European Neurology*, Vol.32, No.3, pp. 126-129, ISSN 0302-2838
- Nagai, H.; Ohtsubo, K. & Shimada, H. (1985) Sarcoidosis of the spinal cord: Report of an autopsy case and review of the literature. *Acta Patholo Jpn* Vol. 35, No. 4, pp. 1007-1022, ISSN 0001-6632
- Newman, LS.; Rose, CS. & Maier, LA. (1997) Sarcoidosis *New England Journal of Medicine* Vol. 336, No. 17, pp. 1224-1234, ISSN 0028-4793
- Oe, K.; Miyamoto, H.; Doita, M.; Sumi, M. & Kanda F. (2006) Differentiation between cervical spondylotic myelopathy and spinal cord sarcoidosis. *Bessatsu Seikeigeka (Japanese)* Vol.50, pp. 2-8.
- Rubinstein, I.; Hiss, J. & Baum, GL. (1984) Intramedullary spinal cord sarcoidosis. *Surgical Neurology* Vol. 21, No.3, pp. 272-274, ISSN 0090-3019
- Sakai, Y.; Matsuyama, Y.; Inoue, K. & Ishiguro, N. (2005) Postoperative instability after laminoplasty for cervical myelopathy with spondylolisthesis. *Journal of Spinal Disorder & Technique* Vol. 18, No. 1, pp. 1-5, ISSN 1536-0652
- Sakai, Y.; Matsuyama, Y.; Imagama, S.; Ito, X.; Wakao, N.; Ishiguro, N.; Watanabe, H.; Kato, F.; Yukawa, Y.; Ito, K.; Suzuki, K.; Tsuboi, a.; Kanemura, T. & Yoshida, G. (2010) Is decompression surgery effective for spinal cord sarcoidosis accompanied with compressive cervical myelopathy? *Spine* Vol. 35, No.23, 1290-1297, ISSN 0887-9869
- Satomi, K.; Nishi, Y.; Kohno, T. & Hirabayashi K. (1994) Long-term follow-up studies of open-door expansive laminoplasty for cervical stenotic myelopathy. *Spine* Vol. 19, No. 5, pp. 507-510, ISSN 0887-9869
- Seichi, A.; Takeshita, K.; Ohishi, I.; Kawaguchi, H.; Akune, T.; Anamizu, Y.; Kitagawa, T. &

- Nakamura K. (2001) Long-term results of double-door laminoplasty for cervical stenotic myelopathy. *Spine* Vol. 26, No.5, pp. 479-487, ISSN 0887-9869
- Sauter, MK.; Panitch, HS. & Kristt DA. (1991) Myelopathic neurosarcoidosis: Diagnostic value of enhanced MRI. *Neurology* Vol. 41, No. 1, pp. 150-151, ISSN 0028-3878
- Soucek, D.; Prior, C.; Luef, G.; Birbamer, G. & Bauer G. (1993) Successful treatment of spinal sarcoidosis by high-dose intravenous methylprednisolone. *Clin Neuropharmacology* Vol. 16, No. 5, pp. 464-467, ISSN 0362-5664
- Stern, BJ.; Krumholz, A.; Johns, C.; Scott, P. & Nissim J. (1985) Sarcoidosis and its neurological manifestations. *Arch Neurol* Vol. 42, No. 9, pp. 909-917, ISSN 0003-9942
- Vighetto, A.; Fischer, G.; Collet, P.; Bady, B. & Trillet M. (1985) Intramedullary sarcoidosis of the cervical spinal cord. *Journal of Neurology, Neurosurgery, and Psychiatry* Vol. 48, No. 5, pp. 477-479, ISSN 0022-3050
- Yonenobu, K.; Hosono, N.; Iwasaki, M.; Asano, M. & Ono K. (1992) Laminoplasty versus subtotal corpectomy: A comparative study of results in multisegment cervical spondylotic myelopathy. *Spine* Vol. 17, No. 11, pp. 1281-1284, ISSN 0887-9869
- Yukawa, Y. & Kato, F. (1999) Isolated spinal cord sarcoidosis mimicking an intramedullary tumor. *Journal of Spinal Disorder* Vol. 12, No. 6, pp. 530-533, ISSN 1536-0562
- Yukawa, Y.; Kato, F.; Ito, K.; Horie, Y.; Hida, T.; Ito Z. & Matsuyama, Y. (2007) Laminoplasty and skip laminectomy for cervical compressive myelopathy. *Spine* Vol. 32, No. 18, pp. 1980-1985, ISSN 0887-9869
- Zajicek, JP.; Scolding, NJ.; Foster O.; Rovaris, M.; Evanson, J.; Moseley, IF.; Scadding, JW.; Thompson, EJ.; Chamoun, V.; Miller, DH.; McDonald, WI. & Mitchell, D. (1999) Central nervous system sarcoidosis- diagnosis and management. *The Quarterly Journal of Medicine* Vo.92, 103-117, ISSN 0033-5622

IntechOpen



Sarcoidosis Diagnosis and Management

Edited by Prof. Mohammad Hosein Kalantar Motamedi

ISBN 978-953-307-414-6

Hard cover, 280 pages

Publisher InTech

Published online 17, October, 2011

Published in print edition October, 2011

Sarcoidosis is a type of inflammation that occurs in various locations of the body for no known reason. Normally, when foreign substances or organisms enter the body, the immune system will fight back by activating an immune response. Inflammation is a normal part of this immune response, but it should subside once the foreign antigen is gone. In sarcoidosis, the inflammation persists, and some of the immune cells form abnormal clumps of tissue called granulomas. The disease can affect any organ in the body, but it is most likely to occur in the lungs. It can also affect the skin, eyes, liver, or lymph nodes. Although the cause of sarcoidosis is not known, research suggests that it may be due to an extreme immune response or extreme sensitivity to certain substances. It also seems to have a genetic component as well, and tends to run in families. Sarcoidosis most commonly develops in people between 20 and 50 years of age. African Americans are somewhat more likely to develop sarcoidosis than Caucasians, and females are somewhat more likely to develop sarcoidosis than males. The symptoms of sarcoidosis depend on the organ involved. This book deals with the diagnosis and treatment of this mysterious disease of unknown etiology.

How to reference

In order to correctly reference this scholarly work, feel free to copy and paste the following:

Yoshihito Sakai, Yukihiro Matsuyama and Shiro Imagama (2011). Spinal Cord Sarcoidosis Accompanied with Compressive Cervical Myelopathy, Sarcoidosis Diagnosis and Management, Prof. Mohammad Hosein Kalantar Motamedi (Ed.), ISBN: 978-953-307-414-6, InTech, Available from:
<http://www.intechopen.com/books/sarcoidosis-diagnosis-and-management/spinal-cord-sarcoidosis-accompanied-with-compressive-cervical-myelopathy>

INTECH
open science | open minds

InTech Europe

University Campus STeP Ri
Slavka Krautzeka 83/A
51000 Rijeka, Croatia
Phone: +385 (51) 770 447
Fax: +385 (51) 686 166
www.intechopen.com

InTech China

Unit 405, Office Block, Hotel Equatorial Shanghai
No.65, Yan An Road (West), Shanghai, 200040, China
中国上海市延安西路65号上海国际贵都大饭店办公楼405单元
Phone: +86-21-62489820
Fax: +86-21-62489821

© 2011 The Author(s). Licensee IntechOpen. This is an open access article distributed under the terms of the [Creative Commons Attribution 3.0 License](#), which permits unrestricted use, distribution, and reproduction in any medium, provided the original work is properly cited.

IntechOpen

IntechOpen