

We are IntechOpen, the world's leading publisher of Open Access books Built by scientists, for scientists

4,800

Open access books available

122,000

International authors and editors

135M

Downloads

Our authors are among the

154

Countries delivered to

TOP 1%

most cited scientists

12.2%

Contributors from top 500 universities



WEB OF SCIENCE™

Selection of our books indexed in the Book Citation Index
in Web of Science™ Core Collection (BKCI)

Interested in publishing with us?
Contact book.department@intechopen.com

Numbers displayed above are based on latest data collected.

For more information visit www.intechopen.com



Myocarditis in Childhood: An Update on Etiology, Diagnosis and Management

Vedide Tavli and Baris Guven

*Izmir Dr Behcet Uz Children's Hospital, Department of Pediatric Cardiology
Izmir*

1. Introduction

Myocarditis is the term used to describe acute or chronic inflammation of the myocardium. For two decades, there has been increasing confrontations concerning the diagnosis, management and clinical outcome of the myocarditis. The cause of myocarditis frequently remains unknown. However, infections, systemic diseases, toxins and drugs have been reported being associated with inflammation of the myocardium (Kearney et al., 2001 & Mahrholdt H et al, 2006). The majority of cases are supposed to be due to infectious agents and it was recognized that any infectious agents could initiate myocarditis (Brodison & Swann, 2001). In North America and Europe, viral infection is the most common causes of myocarditis (Magnani & Dec, 2006). The true overall incidence of myocarditis remain obscure due to inconsistency of its definition and clinical manifestation in the paediatric population. Post-mortem study from Sweden reported incidence of myocarditis to be 1.06 % in 12.747 consecutive autopsies (Gravanis & Sternby, 1991). Since the clinical presentation of myocarditis is so variable, high index of suspicion is essential. Patients are asymptomatic and diagnosis is incidental in the majority of cases. The spectrum of disease ranges from nonspecific findings (chest pain, fever, myalgia, atrial or ventricular tachycardia) to acute heart failure and sudden death. Myocarditis as a cause of sudden death has been reported in up to 12% of young adults (Doolan et al., 2004). However, population based study from Finland (Kyto et al, 2007) documented that the incidence of fatal myocarditis (1.59 per 100000) was highest in infants under one year of age and incidence was lowest in young adults (5-24 years, 0.12-0.17/100000). Recently, Weber et al have also suggested that myocarditis is an infrequent, corresponding to approximately 2% of paediatric deaths (Weber et al., 2008).

Previous researches (Felker et al, 1999 & Lipshultz et al, 2003) strongly suggested that acute myocarditis may proceed to dilated cardiomyopathy. Diagnostic evaluation of a series of 1.278 patients (mean age: 50 years, range 15-87 years) with cardiomyopathy revealed that 9.8% of cases was diagnosed with myocarditis (Felker et al, 1999). In a paediatric study assessing the incidence of cardiomyopathy, viral myocarditis was found to be responsible for 27% of cases with dilated cardiomyopathy (Lipshultz et al, 2003). Moreover, in a prospective cohort study (Towbin et al, 2006), it has been shown that most common known cause of dilated cardiomyopathy is myocarditis (46%). Several mechanisms were postulated for progression of myocarditis to dilated cardiomyopathy, including direct viral injury,

autoimmune response of body through the effects of lymphocytes, natural killer cells, cytokines and apoptotic cell death (Kawai, 1999).

Diagnosis of acute myocarditis can be difficult owing to the lack of accepted and standardized criteria in addition to the nonspecific pattern of clinical presentation. The other issue hampered agreement on the most proper diagnostic criteria and documentation of cases, is broad diversity of aetiologies associated with myocarditis (Dec et al, 1985). At present, diagnosis has been made by use of pathological classification, commonly referred to as Dallas criteria (Aretz et al, 1987). The identification of inflammatory infiltrate with or without myocardial cell necrosis on conventionally stained myocardial tissue biopsy specimens is essential for histological diagnosis. On the basis of these criteria, myocarditis is described as active or borderline myocarditis in accordance with the presence or absence, respectively, of myocardial necrosis. The inflammatory infiltrate should be further identified as lymphocytic, eosinophilic or granulomatous (Figure 1). Sampling error, low sensitivity and specificity, discrepancy in expert interpretation remain limitations to the use of endomyocardial biopsy for diagnosis of acute myocarditis (Hauck et al, 1989 & Shanes et al, 1987). Inflammation in acute myocarditis may be focal, therefore it is challenging to biopsy the inflamed area of myocardium (Robinson et al, 2005). Additionally, it is invasive and potentially dangerous procedure, particularly in the paediatric patient (Checchia & Kulik, 2006). According to the some researchers (Parillo, 2001), this histopathological criteria could not be considered the gold standard for diagnosing acute myocarditis. Molecular pathological analyses, such as polymerase chain reaction (PCR) and in-situ hybridization allows rapid detection and documentation of the viral genetic material in the myocardium (Angelini et al, 2002 & Bock et al, 2010). In 2008, it was reported that immunohistological signs of myocarditis has been associated with poor outcome in myocarditis (Kindermann et al, 2008).

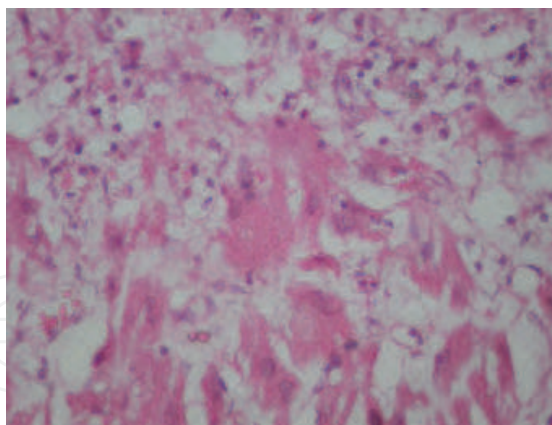


Fig. 1. The pathological diagnosis of viral myocarditis necessitates the manifestation of a inflammatory infiltrate associated with myocyte necrosis. The infiltrate consists of predominantly mononuclear cells (Stained by hematoxylin and eosin, magnification X 400; Text and image courtesy of Ragip Ortac, Gulden Diniz, Malik Ergin)

Therapy of myocarditis in children with inotropes and afterload reduction is usually sufficient. Although the long-term sequels are rare, dilated cardiomyopathy and sudden cardiac death may develop in clinical course. Extracorporeal membrane oxygenation and mechanical ventilations are other options for severe cases (Vashist & Singh, 2009). Newer therapeutic strategies such as intravenous immunoglobulin and immunosuppressive agents

have been investigated with the improvements in understanding pathogenesis of the myocarditis (Drucker et al, 1994 & Camargo et al 2009). It is the aim of this review to give a brief and complete discussion of pathogenesis, diagnosis and management of myocarditis.

2. Etiology

The vast majority of myocarditis in the developed countries result from viral infections (Table 1). The causes other than infections are autoimmune-systemic diseases, toxins and hypersensitivity to drugs (Brodison & Swann, 2001). Enteroviruses (particularly Coxsackie) and adenovirus were recognized as the major cause of viral myocarditis (Baboonian & Treasure, 1997; Pauschinger et al, 1999). During the last decade, parvovirus B19 (PVB19) and human herpesvirus 6 (HHV6) have been described as new pathogens (Kuhl et al, 2003). Moreover, investigators from Germany found that PVB19 and HHV6 are the most common causes of biopsy-confirmed viral myocarditis (Kuhl et al, 2005 & Mahrholdt et al, 2006). An investigation analysing the potential role of PVB19 in the clinical setting of acute myocarditis revealed that PVB19 was the most common agent. Kuhl et al had also noticed that Dallas criteria was frequently negative in patients with positive PVB19 PCR and macrophages were augmented in virus positive cases (Kuhl et al, 2003). These findings support the postulation of Bowles et al that different viruses have various pathogenic mechanisms such as lymphocyte-dependent vs. macrophage-dependent (Bowles et al, 2005). Nevertheless, PVB19 DNA has also been revealed in the myocardium of healthy donors (Donosa et al, 2005), in hearts of adults with dilated cardiomyopathy (Lotze et al, 2004), and in hearts of the patients with lupus and amyloidosis (Kuethe et al, 2007), despite the number of subjects studies was small. From these results, the question arises whether PVB19 certainly cause the underlying heart disease or whether it is just spectator attending in the heart as a result of former infection which is usual in young adults or children. A study by Kuethe et al was conducted to investigate this question. They suggested that PVB19 displays lifelong persistence, identification of PVB19 DNA was not correlated with clinical symptoms and serological analysis should be standardized procedure for future studies considering prevalence of PVB19 (Kuethe et al, 2009).

Polymerase chain reaction (PCR) analyses of myocardium in children and adult patients have showed the existence of adenoviral genome in cases with myocarditis and dilated cardiomyopathy with a larger frequency than enterovirus (Pauschinger et al, 1999 & Bowles et al, 2003). Geographical variation in viral etiology is also remarkable that hepatitis C virus has been more commonly documented in Japanese patients and parvovirus B19 is more frequently detected by PCR in German population (Magnani & Dec, 2006). Matsumori et al found that hepatitis C virus infection is often found in cases with dilated cardiomyopathy and that hepatitis C virus have an crucial role in the pathogenesis of cardiomyopathy (Matsumori et al, 1995). It was also suggested that antiviral therapeutics against hepatitis C virus could be indicated in these cases. Other viruses linked with myocarditis include Epstein-Barr virus, cytomegalovirus, herpes simplex virus, influenza A-B and HIV (Magnani & Dec, 2006). Multiple infections with different viruses have also been detected in cases (approximately one quarter of all cases) with systolic left ventricular dysfunction (Kuhl et al, 2005). Influenza A and B may also involve a combined myocarditis risk, particularly in patients with pre-existing cardiovascular diseases (Friman et al, 1995). From the study (Bowles et al, 2003) conducted in 624 patients with myocarditis (116 neonates, 191 infants), it was concluded that most common amplified viral genomes in myocardial tissues

included are adenovirus, cytomegalovirus, parvovirus and influenza A (ordered in decreasing frequency). It has been known that HIV may cause myocarditis and dilated cardiomyopathy (Breuckman et al, 2005). Direct viral injury, antiretroviral agents, coinfections and inhibition of contractility through HIV glycoprotein type I 120 play a role in the pathogenesis of myocarditis and dilated cardiomyopathy (Chen et al, 2002). The introduction of highly active antiretroviral therapy (HAART) has significantly reduced the incidence of HIV related- myocarditis. On the other hand, in developing countries where the supply of HAART is limited, researchers have observed increase in prevalence of HIV associated cardiomyopathy (Pugliese et al, 2000).

Viral			
Coxsackie virus	Respiratory syncytial virus		
Adenovirus	Vaccinia (smallpox vaccine)		
Human herpes virus	HIV		
Parvovirus B19	Influenza A and B		
Hepatitis C virus	Cytomegalovirus		
Epstein-Barr virus			
Bacterial			
Borrelia Burgdorferi	Streptococcus pneumoniae		
Mycobacterial	Treponema pallidum		
Mycoplasma pneumonia	Neisseria Meningitides		
Corynebacterium diphtheria	Rickettsia sp.		
Hemophilus influenza	Vibrio cholerae		
Parasitic-Fungal-Protozoal			
Ascaris sp.	Schistosomiasis		
Echinococcus granulosus	Larva migrans		
Aspergillus sp.	Candida		
Taenia Solium	Coccidioides		
Cryptococcus	Histoplasma		
Toxoplasma gondium	Trypanosoma cruzi		
Immunologic			
Rheumatic fever	Polymyositis, rheumatic arthritis		
Chagas disease	Sarcoidosis		
Systemic lupus erythamatosus	Thyrotoxicosis		
Diabetes Mellitus	Wegener's Granulomatosis		
Ulcerative colitis	Scleroderma		
Hypersensitivity-Drugs			
Amitriptyline	Amphotericin B	Arsenic	Scorpion envenomation
Anthracyclines	Electric shock	Penicilline	
Digoxin	Phenytoin	Copper	
Dobutamine	Colchicine	Isoniazide	
Cephalosporins	Iron	Lead	

Table 1. Main etiologies observed in myocarditis.

During the pandemic of influenza A (H1N1), myocarditis was documented in four children (80 children with H1N1 influenza) within a 30-day period (Bratinscak et al, 2010). In their retrospective review, three children had fulminant myocarditis, 1 with fatal outcome and 2

required extracorporeal membrane oxygenation support. From these findings, they assumed that new H1N1 influenza A virus is more frequently associated with a severe form of myocarditis that formerly encountered influenza strains. A study from Spain have also emphasized the importance of myocarditis as a risk factor for mortality.

Numerous bacterial infections may cause myocarditis, involvement of myocardium may have insidious course (electrocardiography changes) or may present with significant signs and symptoms. Fulminant septicaemia may result in myocarditis with fatal course. Most common causes of myocarditis associated with bacteraemia included are meningococcus, streptococcus and *Listeria* (Brodison&Swann, 1998). *Borrelia burgdorferi* causes Lyme carditis with acute or chronic course. Recently, a study o 207 children with early disseminated Lyme disease conducted by Costello et al found that 33 children (16%) had mild to fulminant myocarditis, 14 of whom had advanced atrioventricular block (none required permanent pacemaker). Lyme disease may rarely present with cardiomyopathy (Costello et al, 2009).

Various drugs implicated in the development of myocarditis including; anthracyclins, cyclophosphamide, cisplatin, 5-fluorourasil, Lithium, aminophylline, catecholamines, antibiotics (penicillines,), phenytoine and trastuzumab (Ellis&Disalvo, 2007). Myocyte injury may occur by direct toxic effect on heart or by provoking hypersensitivity reactions. Hypersensitivity reaction may be indicated fever, sinus tachycardia, peripheral eosinophilia and a rash that follows days to weeks after administration formerly well-accepted agent. Actually, it is not the drugs that heralds the reaction, but its metabolites (haptens) in the cases of hypersensitivity myocarditis. The pathological findings are indistinguishable and are independent of the drug involved. The inflammatory infiltrate predominantly consists of eosinophils, and can be located in focal areas, or diffusely within the myocardium with slight or no sign of necrosis, or substitute fibrosis. If the grade of myocardial inflammation or necrosis is severe, arrhythmias or hemodynamic collapse may likely occur. Eosinophilic necrotising myocarditis is an extreme form of hypersensitivity myocarditis that promptly cause cardiovascular collapse. Eosinophilic myocarditis has been documented following administration dobutamine and vaccines (Tetanus, small pox).

Systemic diseases that are related with active myocarditis include connective tissue diseases such as systemic lupus erythematosus, mixed connective tissue disease, systemic sclerosis, Churg-Strauss syndrome; celiac disease and Whipple's disease. Protozoal, helminthic and parasitic infections may also present with eosinophilic myocarditis. Myocardial abnormalities in SLE is multifactorial with coronary vasculitis, valvulopathy, hypertension, immune injury and drugs are the major contributors. Myocardial abnormalities are common in autopsy patients. However, clinically apparent myocarditis occurs in < 10 % of cases suggesting that the subclinical form is more frequent (Magnani&Dec, 2006).

Further understanding the etiology of myocarditis will illicit more direct therapeutic approaches such as vaccine and antiviral agents. Although some antiviral agents as ribavirin, oseltamivir and acyclovir have had moderate effect on influenza, RSV pneumonitis and CMV disease, currently there is no specific therapy approved for Enteroviruses, parvovirus B 19 and adenovirus. But, other options may be worth considering. A historical example of a promising therapy for viral myocarditis and prevention of dilated cardiomyopathy is that of decline in the incidence of endocardial fibroelastosis in children after initiation of mumps virus vaccine. It has been known that endocardial fibroelastosis is associated with congestive heart failure and death. Evidence from myocardial samples of patients with EFE supported the hypothesis that it is sequela of

viral myocarditis, in particular of that due to mumps virus. Based on the chronology of the fading of the disease, Ni et al. suggested that it is likely that vaccination was responsible for the remarkable decrease in documented case of EFE. So it is logical to think that vaccination against parvovirus B19, echovirus and adenovirus could diminish cases of myocarditis and dilated cardiomyopathy.

3. Pathogenesis

Special attention to understanding the mechanism and pathogenesis of myocarditis have been increased since Gore and Saphir showed in 1947 that diphtheric and rheumatic carditis separately comprised only 10% of a series of 1402 patients of myocarditis (Gore & Saphir, 1947). In 1970's, several investigators demonstrated the persistence of neutralizing antibodies to coxsackie B (CVB) in cases with cardiomyopathy than healthy subjects (Kawai, 1971, Kawai et al., 1978, Toshima et al., 1979). This finding supported the hypothesis of a viral cause underlying the pathogenesis of cardiomyopathy. Evidence from murine models helped understanding pathogenesis of myocarditis (Liu&Mason, 2001). Myocarditis in susceptible mice is characterized by 3 separate disease processes, direct viral or other infectious agent access to myocardium tissue rapidly evolves into the second phase (Figure 2). In second phase, also called autoimmune phase of disease, immunological activation is the main feature. During the last phase, signs of myocarditis usually disappear and the damaged myocytes are substituted by diffuse fibrosis. Misdiagnosis and inappropriate therapy are especially possible at the time of transitional period among the 3 phases. In the case of reinfection and autoimmune recurrence, confusion can be compounded.

3.1 Viremia

Currently, there are two models of coxsackie B virus 3 induced myocarditis. The first one provokes acute viral myocarditis with a significant damage to myocytes and sudden death of animals within a week of infection (Fuse et al., 2005). In the second model, some degree of mice seemed to advance acute viral myocarditis following an infection with a cardiotropic strain of CVB3 (Fairwather&Rose, 2007). There also models with CMV, HIV and adenovirus (O'Donoughe et al., 1990, Salone et al., 2003, Beischel et al., 2004). During the time of active viremia, cardiotropic RNA virus (Coxsackie B) is taken into cells by receptor mediated endocytosis and are directly translated interior to the cells to produce protein (Huber, 1993). The virus enters the cell by endothelial receptors, particularly coxsackie-adenovirus receptor (CAR). Additionally, coxsackie B1, B3 and B5 uses decay accelerating factor (Shafren et al., 1995); adenoviruses uses α integrin as coreceptors for viral entry (Wickham et al., 1994). It has been shown that CAR is highly expressed in the heart and brain, peaking in the perinatal period with subsequently declining with age and it is identified on the entire surface of the myocardium (Kashimura et al., 2004). Therefore, one can explain the susceptibility of neonates and infants to coxsackie B 3 myocarditis on the basis of expression level and the location of CAR. Titers of viral antigens in the myocardium is highest on the fourth day of inoculation of virus (Tomioka et al., 1986). No neutralizing antibodies to the virus were present until day 4. The antibody titers elevate promptly on day 8 and 10 reach the highest level on day 14 (Kawai, 1999). The emergence of a rising antibody titers is closely linked to elimination of the virus from the myocardium.

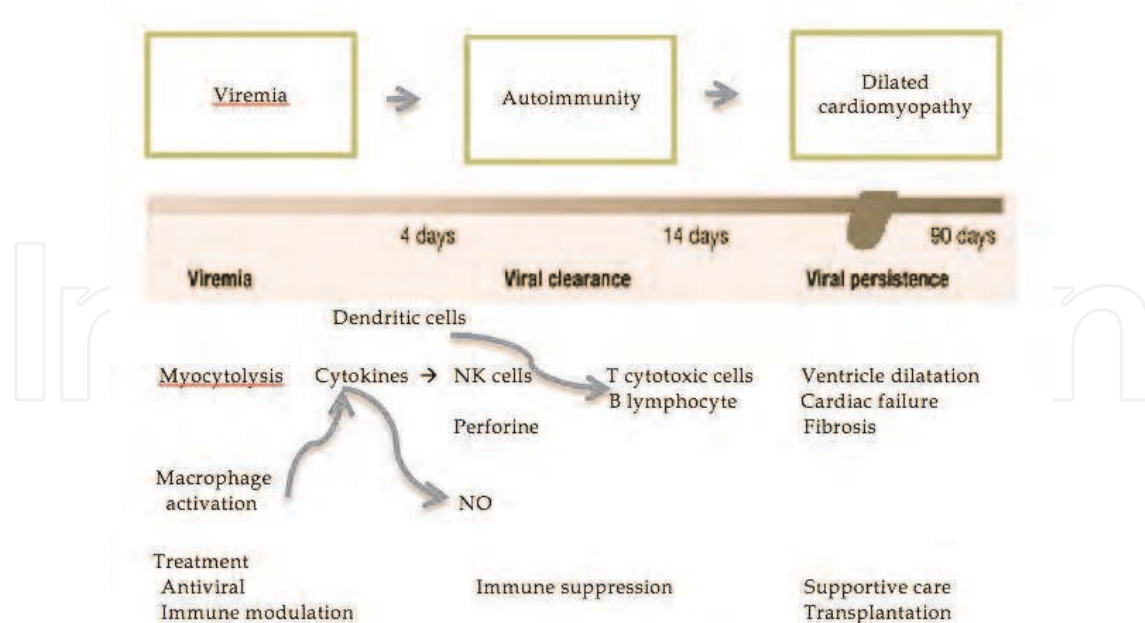


Fig. 2. Schematic drawings of pathophysiological processes of viral myocarditis. NO: Nitric oxide, NK: Natural killer cells.

3.2 Autoimmunity

First phase terminates with the stimulation of the host immune response that weakens viral proliferation but may also augment viral entry. Under ideal circumstances, immune system should normalize to a resting state once viral proliferation is limited. However, if host immune system stimulation persists unrestricted even with the elimination of the virus, autoimmune disease may develop, activating the second phase. This phase is distinguished by inflammatory cellular infiltration with natural killer cells and macrophages, then consequent expression of proinflammatory cytokines, especially interleukin-1, interleukin-2, TNF and interferon γ (Kawai, 1999, Matsumori et al., 1994). It has been shown that TNF triggers endothelial cells, recruits further inflammatory cells, more enhances cytokine production and has direct negative inotropic effects (Feldman&McNamara, 2000). Cytokines can also induce macrophages to express inducible nitric oxide synthase (NOS) in heart cells (Zaragoza et al., 1998). The role of NO in myocarditis is complicated. NO can reduce viral replication, and peroxynitrate production has strong antiviral effects (Zaragoza et al., 1997). Mice deficient in NOS were found to have greater viral titers and more widespread myocyte injury (Padalko et al., 2004). Alternatively, myosin induced autoimmune myocarditis animal model showed us that NOS expression in myocytes and macrophages is related with more severe inflammation, where NOS inhibitors can have potential to reduce myocarditis severity (Zaragoza et al., 1998, Mikami et al., 1997). Furthermore, improvement in myocarditis of the mouse model has been demonstrated by blocking IL-1b or TNF-a at the onset of the disease (Fairweather et al., 2004). Cihakova et al. also showed that the severity of CVB3 induced myocarditis as well as myosin-induced myocarditis is associated with the levels of IL-1b and IL-18 in the myocardium (Cihakova et al., 2008). T cells are activated in viral myocarditis by classical cell-mediated immunity. Viral peptide fragments are processed in the Golgi apparatus of the myocyte and presented to the cell. These prepared T-cells are capable of identifying the viral antigen and destroy the infected myocyte by

means of cytokine and perforine secretion (Ayach et al., 2003). But, persistent excited stimulation of the T cells is eventually harmful to the host, due to both direct T-cell mediated and cytokine-mediated cell damage diminish the number of contractile elements. Continuous T-cell activation is induced through antigens intrinsic to the myocardium that share molecular mimicry with viral peptides. The virus may also prompt a TH2 reaction, stimulating more CD8 killer cells in the process. It can be explained partially by the presence of evidence that CD4/CD8 or p56lck knockout animals have a much better survival following coxsackie infection (Liu et al., 1995). Recently, it has been shown that CD4+ Th cell subset, referred as Th17 cells, are involved in several inflammatory diseases, including experimental autoimmune myocarditis and collagen induced arthritis (Aggarwal et al., 2003, Chen et al., 2006). In addition to the proinflammatory effects, evidence from previous works suggested that Th17 cells may facilitate the production of autoantibodies in the development of acute viral myocarditis (Yuan et al., 2009). In experimental study published last year (Yuan et al., 2010), they showed that IL-17 produced by Th17 may take part in the regulation of the equilibrium between antiviral immunity and autoimmunity in CAVB3-induced acute viral myocarditis and IL-17 will be a new therapeutic goal for viral myocarditis in future (Milenkovic et al., 2010).

Although the activation of CD4 cells also leads to B-cell clonal expansion and antibody production, antibodies might not be the critical initiating factor that directs the advancing of the myocarditis. The severity of myocarditis was also found to be dependent on the responding T-cell subset in T-cell knockout mice (Opavsky et al., 1999). But, it has been shown that antibodies are a significant modifier of the disease phenotype. In a study conducted in 1982, it was found that among 30% of cases with suspected myocarditis, as well as in 18/19 patients with proven viral infection due to coxsackie, influenza A or mumps virus (Maisch et al., 1982). They also showed that antimyolemmal antibodies was correlated with the degree of *in vitro* induced cytolysis of rat myocytes.

Adenoviral myocarditis differs from coxsackie virus in the setting of pathogenesis (Hayder&Müllbacher, 1996). The amount of CD2, CD3 and CD45RO α lymphocytes detected in the adenovirus-infected cases was decreased compared with those patients who had myocarditis with other pathogens (Pauschinger et al., 1999). It was also demonstrated that 71% of PCR-positive adenoviral did not have inflammation histologically (Martin et al., 1994). One of the strategies of adenovirus for modulating immune response is that interaction of adenoviral encoded proteins with host immune components. These proteins may protect cells from tumor necrosis factor mediated lysis, as well as downregulation of major histocompatibility complex class I antigen expression. On the other side, adenoviral E1a encoded proteins are able to encourage the induction of apoptosis and inhibition of interleukin-6 (IL-6) expression (Davison et al., 2003). Besides this, it restricts IL-6 signal transduction pathways. These functions of E1A may be relevant to the occurrence of dilated cardiomyopathy. HIV has been identified within myocytes and is related with interference of myocyte integrity and replacement of endocardial fibrosis. Therefore, it was suggested that HIV myocarditis may share similar pathogenic mechanism of those of coxsackie (d'Amati et al., 2001).

It should be underlined that the natural killer (NK) cells is also important in the pathogenesis of myocardial inflammation. These finding corroborate those observed in a prior animal study, in which animals depleted of their NK cells previous to infection with coxsackievirus develop a more severe myocarditis (Godeny et al., 1987). The NK cells particularly reduce the nonenveloped virus infection by destroying the infected cells.

3.3 Dilated cardiomyopathy

Several remodelling mechanisms leading to dilated cardiomyopathy may be particular to myocarditis. The association of myocarditis to dilated cardiomyopathy has been moderately elucidated by molecular techniques. Badorff and Knowlton, demonstrated that dystrophin is cellular target for coxsackie B3 viral protease (Badorff&Knowlton, 1999). It may provide one of the molecular mechanisms clarifying the significant ventricular dilatation that may develop immediately following viral infection. Furthermore, it was found that dystrophin deficiency augments host vulnerability to coxsackie virus infection (Xiong et al., 2002). This conclusion may result from the findings that more efficient liberation of the virus from the infected myocytes and is related with an increase in virus-mediated cytopathic effects. Proteases from other viruses (adenovirus and HIV) may also cleave cytoskeletal proteins (Chen et al., 1999, Shoeman et al., 1993).

Identification of viral RNA at early, intermediate and late stages of myocarditis has been demonstrated in animal models. That persistent myocyte viral gene expression may be a cause of progressive dilated cardiomyopathy. Some findings propose that the persisting viral RNA seems to be capable of replication. In 172 patients with biopsy-confirmed viral infection, persistent viral genome of enterovirus, parvovirus B19, and HHV-6 was found to be associated with on-going impairment in ejection fraction (Kuhl et al., 2005); But, in the lack of measurable virus titers, it appears likely that the replication can be done in a limited or transformed manner (Klingel et al., 1992). All the more so, such replication might produce novel antigenic non-infectious or defective interfering viral elements, sufficient to cause evolving myocardial injury (Kawai, 1999). Cytokines possibly will participate in the development of dilated cardiomyopathy (Ono et al., 1998). During the second phase, they stimulate the matrix metalloproteinases, such as elastase, collagenases and gelatinase. Moreover, various reports suggest that several different viruses perform as a trigger for apoptosis. In addition to an immune-mediated mechanism activated by viral infection and persistent viral RNA in the myocardium, apoptosis may provide the third mechanism to elucidate the development of dilated cardiomyopathy.

3.4 Host factors

It is not fully understood which factors may define susceptibility to viral myocarditis and the development of cardiomyopathy. There are still remaining issues to be answered as why is it that who are in proximity to each other may be infected with the identical virus, but all do not develop myocardial injury? Why do certain infected cases continue to develop mild versus severe myocarditis or cardiomyopathy. But, up to date, the presence of genetic and environmental factors have been documented that influence particularly to viral myocarditis. Risk factors associated with severe myocarditis include age, viral variant, exercise, mouse strain and sex (Woodruff, 1980). Biochemical alterations such as selenium deficiency, vitamin E deficiency (Beck et al., 2003) and mercury exposure (Illback et al., 1996) have been documented to increase the viral virulence. Host genetic configuration not only influences the pathogenic mechanism of disease but also affects the severity of myocarditis. HLA-DQ locus and CD45 polymorphisms were to found to be essential determinants for early viral infection (Tchilian et al., 2006). Several investigations documented the significant association between dilated cardiomyopathy and MHC class II antigens, primarily HLA DR4 (Carlquist et al., 1991, Limas&Limas, 1989). In the study published in the *Annals of Human Genetics*, it is documented that HLA-DQA1* 0501 and DQB1*0303 are related to genetic susceptibility to idiopathic dilated cardiomyopathy (IDC), while DQA1* 0201, DQB1*

0502 and DQB1* 0504 present protection from IDC (Liu et al., 2005). However, associations of MHC class II alleles with dilated cardiomyopathy are possibly affected by ethnicity, sex, age and geographical variations. Besides the MHC haplotype, non-MHC genes should be considered (Neu et al., 1987). Two non-MHC loci on murine chromosomes 1 and 6, referred as Eam1 and Eam2, respectively, might influence autoimmune myocarditis (Guler et al., 2005). These loci intersect with loci implicated in other autoimmune diseases, such as lupus and diabetes, might give a clue that various autoimmune disease could be controlled by related genetic mechanisms. Initial antiviral response by the host has been recognized to be mediated at least in part by Toll-like receptors. TLR3 was found to play a significant role in the host innate immune response to infection with several cardiotropic viruses. Recent data suggests that variations in TLR3 alter the innate immune response and might change host susceptibility to increased cardiovascular pathology (Gorbea et al., 2010).

4. Clinical features

As stated previously, clinical picture of myocarditis is extremely variable, ranging from asymptomatic ECG abnormalities to heart failure (Dec et al., 1985, Bowles et al., 2003). The term "*Acute fulminant myocarditis*" is used for cases with severe congestive heart failure or cardiogenic shock (Amabile et al., 2006). Age of child influences clinical presentation of myocarditis (Dec et al., 1985). Viral prodrome of flu-like illness, respiratory symptoms or gastroenteritis may precede symptoms of heart failure. Neonates and infants present with poor feeding, irritability or listlessness, diaphoresis, apnea and episodic pallor. Usual symptoms of congestive heart failure, as well as mild cyanosis and pallor are observed on physical examination. It should be emphasized that neonates and affected younger infants may have intrauterine myocarditis with chronic course (Bowles et al., 2003). For very young infants acquiring myocarditis in the periparturient period, the prognosis is very poor, with more than 90% of children dying. Previous studies have implicated the myocarditis as the cause of sudden death (Friedman et al., 1998, Bowles et al., 2003). In the retrospective study of Krous et al., they evaluated the infants who died of sudden death infant syndrome in a safe sleep environment, accidental suffocation or myocarditis were assessed, and they have noticed the manifestation of scattered inflammatory cells and necrotic myocyte were noticed (Krous et al., 2009). From this observation, they suggested that few scattered inflammation and necrotic myocyte were normal finding in the developing heart exposed to new environmental pathogens. However, degree of cardiac infiltration was found to be greater in infants who died of myocarditis. In German study published in 2004, researchers found that viral myocardial affection is the cause of death in cases with SIDS (Dettmeyer et al., 2004). Besides, it was proposed by authors that PVB19 seems to play a more significant role than presumed so far.

Recent history of viral disease 10 to 14 days preceding presentation typically occurs in older children and adolescents (Friedman et al., 1998). Nonspecific gastrointestinal and respiratory complaints are more common than chest pain (Vashist&Singh, 2009). Jugular venous distension and pulmonary rales may be seen, and the resting tachycardia may be obvious, unlike in neonates. Since symptoms of myocarditis vary considerably in children, diagnosis can be challenging. Durani and colleagues, documented that most patients present with complaints of shortness of breath having tachypnea at presentation (Durani et al., 2009). Vomiting (48%) and poor feeding (40%) are also commonly seen in myocarditis. The authors also observed that the diagnosis of myocarditis was missed on the first presentation

to a physician in 83% of cases. In a retrospective review, of 31 children with probable and definite myocarditis, 57% were initially diagnosed as suffering pneumonia or asthma (Freedman et al., 2007). One point that deserves attention in these studies is the absence of other signs of congestive heart failure in the majority of cases with myocarditis. Only 50% of children had hepatomegaly and 34% had abnormal chest radiography. The electrocardiographic changes include sinus tachycardia with low voltage QRS complexes, inverted T waves—typically occur in the clinical setting of myocarditis (Durani et al., 2009). Wide Q waves and ST segment changes as a pattern of myocardial infarction also may be observed. Supraventricular tachycardia, ventricular tachycardia or atrial fibrillation, as well as atrioventricular block may occur (Friedman et al., 1994). Of note, the sensitivity of electrocardiography in myocarditis is only 47% (Morgera et al., 1992). However, Freedman and colleagues found that sensitivity of electrocardiography as a screening test was 93% (Freedman et al., 2007). Additional interesting finding that is worth to mentioning that the presence of axis deviation (37%) in children with myocarditis. Although ventricular tachycardia is a rare initial manifestation of myocarditis, it may often develops in long-term follow up and may occasionally result in sudden death (Drory et al., 1991).

Myocarditis imitating an acute coronary syndrome has also been defined. Viral genomes were demonstrated in 71% of adult cases with normal coronary anatomy, clinically mimicking myocardial infarction. Parvovirus B19 was most common agent identified in this study (Kuhl et al., 2003). ECG criteria (wide Q waves in I, aVL, V5 and V6, ST segment change > 2 mm, ventricular arrhythmias) was described for the diagnosis of myocardial infarction in children (Towbin et al., 1992). However, similar ECG findings can occur in myocarditis (Durani et al., 2009). Most common ECG findings in adult patients with myocarditis include ST segment elevation (55%), T wave inversion (27%), ST segment depression (27%) and pathological Q waves (18%) (Dec et al., 1992, Angelini et al., 2000). Myocardial infarction and myocarditis in neonates overlap and mimic each other (deVetten et al., 2011). Despite angiographically normal coronary anatomy, global or segmental wall motion abnormalities are commonly obvious (Angelini et al., 2000). Physicians should always bear in mind the possibility of acute myocarditis in younger cases who present with acute coronary syndromes when coronary risk factors are lacking, global rather than segmental left ventricular dysfunction is evident on echocardiography or ECG abnormalities encompass beyond a single coronary artery zone (Magnani&Dec, 2006).

5. Diagnosis

Although the misdiagnosis of the myocarditis is common, several diagnostic methods can aid physicians in making diagnosis of the myocarditis.

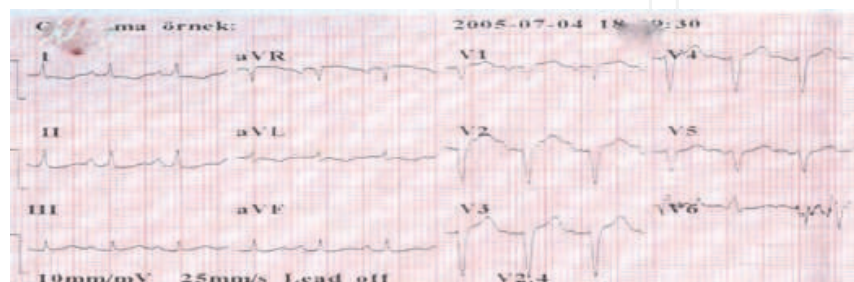


Fig. 3. 12 lead ECG in children with myocarditis. Negative T wave in DI, aVL, ST-T changes were noted in precordial leads.

5.1 Electrocardiography and chest radiography

Chest radiography and electrocardiography (ECG) can be used as first line diagnostic modality (Figure 3). Most common ECG changes are sinus tachycardia, axis deviation, ventricular hypertrophy and ST-T wave changes (Freedman et al., 2007). Moreover, evidence from previous studies suggests that the presence of northwest axis deviation, new left bundle branch block and abnormal QRS complexes is correlated with higher rates of transplantation or death (Magnani et al., 2006, Morgera et al., 1992, Nakashima et al., 1998, Greenwood et al. 1976). A recent adult study have shown that QRS prolongation is an independent predictor for transplantation or death in patients with suspected myocarditis (Ukena et al., 2011). In the majority of cases of myocarditis (up to 90%), abnormal chest radiography was documented (Durani et al., 2009, Freedman et al., 2007). Most common chest radiography finding is cardiomegaly, followed by pulmonary edema and pulmonary infiltrate (Figure 4).

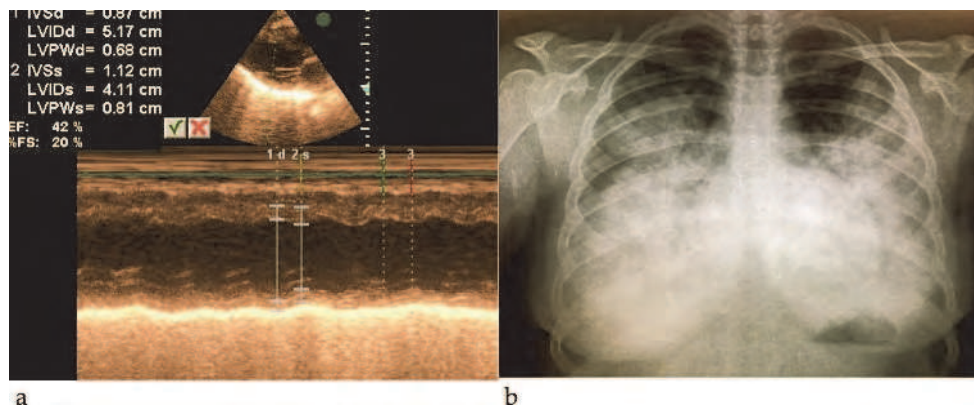


Fig. 4. M-mode echocardiography (a) and chest x-ray (b) of an adolescent girl with presumed viral myocarditis. M-mode echocardiography demonstrating systolic dysfunction with flattened interventricular septum. In chest radiography, there was prominent diffuse vascular congestion that is compatible with pulmonary edema. 13 year old girl admitted our hospital with dyspnea and tachycardia. She had a history of preceding viral upper respiratory infection. The patient intubated and connected to mechanical ventilation on day one of emergency room admission. She died within 72 hours after initial presentation.

5.2 Laboratory finding

General markers for inflammation such as erythrocyte sedimentation rate and C-reactive protein in serum are commonly elevated. However, their usage in diagnosis of myocarditis is limited. Freedman et al. demonstrated that the most sensitive marker for myocarditis was an increased aspartate transaminase (AST). AST elevation was found in 85% of probable and definite cases of myocarditis (Freedman et al., 2007). On the other hand, C-reactive protein and erythrocyte sedimentation rate have been elevated in cases of myocarditis with a range of 27 to 56%. Cardiac troponin t (cTnT) has also been investigated as a diagnostic marker for acute myocarditis since 1990's. cTnT, a contractile protein unique to cardiac muscle, is vastly concentrated in the myocytes and will be released into the blood within hours after heart muscle injury. Following myocardial cell necrosis an increased concentration of cTnT is noticeable in blood for more than a week. Cardiac troponin T measurements are especially useful in clinical settings in which traditional enzyme determinations fail to diagnose myocardial cell damage effectively. Likewise, cTnT is not reliably corresponded to increases

in blood of cardiac enzymes or myoglobin in all cases of Wolff-Parkinson-White syndrome undergoing radiofrequency ablation. Cardiac troponin I, subunit of thin filament of contractile element of the myocardium, has high specificity (89%) and low sensitivity (34%) in adult patients with acute myocarditis, whereas cTnT has been documented to have a specificity of 83% and sensitivity of 71% in children. Moreover, higher levels of cTnT have been demonstrated to be a prognostic marker for poor outcome in adults presenting with acute myocarditis. Elevated levels of interleukin-10 (IL-10) and TNF appears to be predictor of fulminant myocarditis. Besides this, increase of serum Fas and Fas ligand levels, as well as immunohistological signs of inflammation (CD3 and/or CD68) on initial presentation are associated with fatal outcome in patients with acute myocarditis.

5.3 Echocardiography

Echocardiographic features of myocarditis are nonspecific. Patterns of echocardiography in myocarditis could mimic hypertrophic, dilated or right ventricular cardiomyopathy and as well as ischemic heart disease (Checcia&Kulik, 2006). Echocardiography can be used for assessing wall thickness, cardiac chamber size together with systolic and diastolic functions. Right ventricular dysfunction is relatively unusual. However, right ventricular dysfunction was found to be predictor of adverse outcome in patients with active myocarditis (Mendes et al., 1994). Left ventricular diastolic dysfunction with a restrictive pattern is also observed in most cases of myocarditis. Left ventricular wall thickening was found to be highest on days 1-3 after onset of acute myocarditis. It has also been noted that left ventricular thickening was more marked in the fulminant myocarditis (Felker et al., 2006). On the contrary to adult patients, echocardiographic findings of pediatric patients revealed that relatively thicker posterior wall was correlated with better prognosis and recovery (Carvalho et al., 1996). Segmental wall motion abnormalities are relatively frequent, but global hypokinesis is prevalent. Pericardial effusion commonly occurs. The presence of thrombi in ventricle has also been documented in up to 25% of cases (Daly et al., 1983).

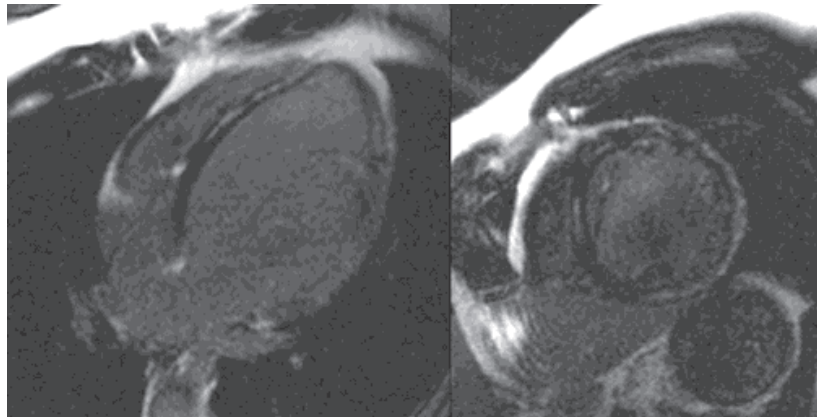


Fig. 5. Cardiac magnetic resonance imaging of acute myocarditis in a adolescent. In four chamber and short axis view, subepicardial late enhancement are noted. Text and image courtesy of Alper Yuksel, Yigit Goktay.

5.4 Magnetic resonance imaging

Current practice has focused on the use of cardiac magnetic resonance imaging (CMR) for the diagnosis of acute myocarditis (Gutberlet et al., 2008, Friedrich et al., 1998). CMR with a

unique potential for tissue characterization, particularly with the utilization of T1 and T2 weighted images, can assess 3 markers of tissue injury, which is, hyperemia and capillary leakage, necrosis and fibrosis and intracellular and interstitial edema (Friedrich et al., 2009). CMR visualizes the entire myocardium, recognizing borders of inflammation from later modeling. Thus, it can be used to monitor lesions and be used to show the execution of endomyocardial biopsy, as well as it may be useful in the quantification of the magnitude of damage (Danti et al., 2009, Mahroldt et al., 2004). Goitein et al. demonstrated that cardiac MRI have a larger impact than echocardiography in verifying the existence of myocarditis and evaluating the extent of disease (Goitein et al., 2009). It has been shown that echocardiography is useful in revealing wall motion abnormalities, whereas cardiac MRI could actually identify the often subtle patchy myocardial inflammation (Friedrich et al., 1998). Gadolinium is used as a contrast agent due to ability to penetrate cells whose membranes ruptured and allows contrast agent to diffuse into the cells (Weinmann et al., 1984). Myocardial blood flow and edema, that is likely to be increased in tissues which are inflamed, could augment signal enhancement in MRI. But, cardiac MRI features can be missed on the first pass perfusion (Skouri et al., 2006). Delayed enhancement MRI permits visualization of necrotic and fibrotic myocardium (Friedrich et al., 2009). The observations obtained from the studies using contrast media-enhanced cardiac MRI indicate that pattern of myocarditic lesions occur predominantly in the lateral free wall and get localized to the subepicardial or intramyocardial regions (Mahroldt et al., 2004, Friedrich et al., 1998). The finding of lateral free wall involvement (subepicardial region) partially explain why some young patients with acute myocarditis can present with only ST elevation on ECG (Figure 5). Postmortem studies also showed that lateral wall was the preferred location in myocarditis (Theleman et al., 2001, Shirani et al., 1993). Subendocardial region involvement pattern which is typical for myocardial infarction was never seen in patients with acute myocarditis (Mahroldt et al., 2004). Mahroldt et al. also demonstrated that in the right ventricle half of septum, that is common location of EMB, had relatively low density of inflammatory cells. Apart from lateral free wall pattern, Marhold et al showed that HHV6 myocarditis had pattern that was located in midwall area of the interventricular septum. Pericardial effusion has also been reported in 32 to 57% of cases with myocarditis (Friedrich et al., 2009). Its presence, although not specific for myocarditis, is a supportive evidence for active inflammation.

Recently, International Consensus Group on Cardiovascular Magnetic Resonance suggested the diagnostic criteria, known as "Lake Louis Consensus Criteria" (Friedrich et al., 2009). Cardiac MRI should be made in the setting of clinically suspected myocarditis according to these criteria. It was also stated that maximum diagnostic accuracy can be accomplished with the presence of any two or more of the following criteria: Regional or global myocarditis signal increases in T2 weighted images, increased global myocardial early gadolinium enhancement ratio between myocardium and skeletal muscle (T1 weighted images) or presence of at least one focal lesion with nonischemic regional distribution (late gadolinium enhancement).

In a retrospective study published in 2009, researchers found that myocarditis in children is characterized mainly by subepicardial and transmural enhancement. Global hypokinesia, left ventricular dilatation, ejection fraction less than 30% and transmural myocardial involvement were discovered to be associated with poor outcome (Vashist et al., 2009).

5.5 Biopsy

Despite its limitations, EMB is the gold standard for diagnosis of myocarditis. Together with simultaneous PCR and immunohistology, rapid detection of the viral genome is possible (Checcia&Kulik, 2006). The Dallas criteria have regulated the definition of myocarditis (Aretz et al., 1987). Active myocarditis is considered if light microscopy shows infiltrating lymphocytes and cytolysis. One of the potential advantage of this procedure it may aid physician in determining the management of myocarditis. Children with viral myocarditis may benefit from therapy with immune suppression while patients with cardiomyopathy may not (Liu et al., 2001). Several issues have to be considered before making a decision about biopsy. As stated earlier, some complications such as pneumothorax, dysrhythmia, perforation and death, may occur during the procedure, and it can be hazardous for particularly pediatric patients (Pophal et al., 1999). Limited sensitivity of EMB that is related with sampling error should also be evaluated (Hauck et al., 1989). Substantial controversy exist with respect to diagnostic criteria for examining tissue specimens. Poor interobserver variability may limit the utility of Dallas criteria (Shanes et al., 1987). A scientific statement from the American Heart Association, The American College of Cardiology and European Society of Cardiology published in 2007, has evaluated the role of EMB in myocarditis (Cooper et al., 2007). Various clinical scenarios have been described. Of these only two have received class I recommendation for EMB (Table). In a retrospective review analyzing the morbidity and mortality of EMB in children, highest risk was found in children with suspected myocarditis on inotropic support (Pophal et al., 1999). Authors also found that risk of biopsy in small children (< 10 kg) or sick infants was extreme. Compared with established risk of EMB in adults, there is an increased risk in children. Thus, careful risk-benefit analysis should be therefore undertaken for each patient.

6. Treatment

In spite of the significant progress in understanding the mechanisms of myocarditis pathogenesis in last two decades, advances in treatment strategies are still limited and the supportive care is the principal therapy. Most patients with acute myocarditis presenting with dilated cardiomyopathy respond favorably to standard anticongestive therapy including afterload reduction, diuretics, angiotensin converting enzyme inhibitors and the introduction of β blockers such as carvedilol or metoprolol succinate once the acute phase is controlled. Various experimental studies with β adrenoreceptor inhibitors or agonists showed different effects in acute myocarditis. Treatment with propranolol in mice infected with encephalomyocarditis virus (EMCV) reduced the severity of myocarditis and mortality (Wang et al., 2005). On the other hand, carvedilol, non-selective β blocker, improved the survival and decreased the virus replication of mice infected with EMCV through the enhancement of IL-12 and IFN- γ production, whereas metoprolol had no effect on this murine model (Nishio et al., 2003). Despite the lack of extensive studies in pediatric patients, administration of carvedilol has been found to be associated with improvement of left ventricle function and clinical symptoms and normalization of antioxidant enzyme activity (Bajcetic et al., 2008). Similar to effects of β blockers, ACE inhibitors and angiotensin receptor blockers have been documented to lessen viral myocardial injury in murine models (Yamamoto et al., 2003). It is also proposed that early introduction of beta-blockers and ACE inhibitors might prevent the remodelling that advances to dilated cardiomyopathy (Ellis&DiSalvo, 2007). Phosphodiesterase inhibitors such as milrinone, if well tolerated, can

be really helpful. A recent multi-institutional analysis revealed that milrinone was used most often for vasoactive support in children (Klugman et al., 2009). Anticoagulants should be considered if ejection fraction is severely decreased or in the setting of atrial arrhythmia (Gunthard et al., 2009). Digoxin should be used in low dose and with caution in patients with viral myocarditis since high dose digoxin was proven to increase mortality in animals with EMVC induced myocarditis as well as elevate intracardiac production of cytokines (Matsumori et al., 1999). Ventilation and oxygenation could be best achieved with continuous positive airway pressure (CPAP) or other non-invasive methods. CPAP, unloads inspiratory muscles and leads to decreased left ventricular afterload without compromising cardiac index via increasing intrathoracic pressure. Medications used for intubation can cause hypotension and acute cardiovascular collapse, thus CPAP also avoids this and is an outstanding adjunctive therapy for cardiac failure and myocarditis (Bradley et al., 1992, Naughton et al., 1995).

Extracorporeal membrane oxygenation support and ventricular assist device might be particularly useful for patients with fulminant myocarditis. Extracorporeal membrane oxygenation may also be considered in those who are in the recovery phase from acute myocarditis (Sezai et al., 2007). For patients with cardiogenic shock because of the acute myocarditis who worsen despite ideal medical therapy, extracorporeal membrane oxygenation and ventricular assist device may help as a bridge to transplant (Moloney et al., 2005). The full mobilization, survival rates up to 90% for fulminant myocarditis and decreased anticoagulation make these pulsatile ventricular assist device systems as the alternative choice of therapy for children (Patopov et al., 2007). Cardiac transplantation is reserved only for patients who are intractable with medical management and mechanical circulatory support. Almost half of the annual cardiac transplantation cases are performed for idiopathic dilated cardiomyopathy, at least 10% of which represent as myocarditis (Ellis&DiSalvo, 2007).

6.1 Immune therapy

It is well known that the long term morbidity and mortality following viral myocarditis seem to be dependent on cellular and humoral immunity abnormalities. Therefore, many investigations have been conducted to search the use of immunosuppressants and immune-modulator agents for treatment of acute myocarditis and dilated cardiomyopathy. However, debate still persists on whether immune therapy for acute myocarditis is useful or not. Initial adult studies investigating the effect of prednisone with or without azathioprine and cyclosporine demonstrated a slight improvement in left ventricular function. But, this improvement was temporary (Mason et al., 1995, Parillo et al., 1989). In a study conducted by Parillo et al., patients were grouped as reactive or nonreactive on the basis of histopathology, immunoglobulin deposition on EMB, an increased erythrocyte sedimentation rate or a positive gallium scan. At three months, reactive patients who were treated with prednisone (60 mg daily) had a statistically significant increase in ejection fraction compared with controls. After six months, improvement seen earlier was no longer present. In 1995, the Myocarditis Treatment Trial failed to show neither an improvement in left ventricle ejection fraction at 28 weeks nor an improvement in survival up to 4.3 years (Mason et al., 1995). Although a few uncontrolled studies showed benefit with several immune suppressive agents, meta analysis of adult studies did not confirm a significant favourable effect of immunosuppression (Garg et al., 1998, Maisch et al., 1998). There were also investigations to evaluate the results of immune suppressive regime in children with

acute myocarditis (Chan et al., 1991, Camargo et al., 1995). However, studies in children are inadequate and yet, no randomized controlled trials are present. In a study (Camargo et al., 1995) conducted among 68 children with severe dilated cardiomyopathy, patients were classified into either conventional treatment or given one of three immune suppressive agents, prednisolone, prednisolone plus azathioprine and prednisolone with cyclosporine. Children taking immunosuppression treatment with a second agent, demonstrated enhanced hemodynamic parameters, as well as histological improvement in inflammation. A meta analysis (Hia et al., 2004) assessing the impact of immunosuppression on the outcome of acute myocarditis in children was published in 2004. Better outcome was observed among children who received immunosuppressive therapy. On the other hand, the findings were not statistically significant. Randomized large controlled studies are needed to conclude that immunosuppressive therapy is beneficial for outcome of children with acute myocarditis. On the contrary, one trial published in 1997, demonstrated that survival was improved with the treatment of cyclosporine and corticosteroids in patients with giant cell myocarditis (Cooper et al., 1997). A different approach has also been investigated, in which Wojnicz et al. used HLA expression on endomyocardial specimens to classify inflammatory cohort (Wojnicz et al., 2001). Of 202 patients with dilated cardiomyopathy, 84 patients with increased HLA expression were randomized to receive either placebo or immunosuppression for 3 months. After 2 years, significant improvement in ejection fraction and end diastolic diameter were noted only among the immunosuppressive group.

It was suggested that intravenous immunoglobulin (IVIG) may be an useful therapy for acute myocarditis due to its both antiviral and immunomodulating effects. Previously, it has been shown that IVIG may be used in several autoimmune disorders, including idiopathic thrombocytopenic purpura, systemic vasculitis and Kawasaki disease (Rosen et al., 1993, Wolf et al., 1996). Up to date, there are no randomized controlled studies evaluating the use of IVIG to treat the children with acute myocarditis. A systemic review conducted by Robinson et al., evaluated the use of intravenous immunoglobulin therapy in acute myocarditis in both adults and children (Robinson et al., 2005). They determined that intravenous immunoglobulin might be useful in the presence of ongoing or active infection which may be causing obstinate cardiac failure. In a study conducted in children with presumed viral myocarditis, high dose IVIG treatment was found to be associated with improved recovery of left ventricular function and with a tendency of better survival (Drucker et al., 1994). In adults, the results of a randomized clinical trail suggested that for patients with recent onset dilated cardiomyopathy, IVIG did not enhance an improvement in ejection fraction (McNamara et al., 2001). However, in this cohort, ejection fraction was increased considerably during follow-up and short term prognosis remained favourable. Despite the presence of several case reports indicating that adults treated with intravenous immunoglobulin reveal better cardiac function, Cochrane review of IVIG administration in myocarditis and dilated cardiomyopathy demonstrated no benefit in adults (McNamara et al., 1997, Tedeschi et al., 2002). On the other hand, little is known about the exact mechanisms responsible for potential benefits of IVIG in the therapy of patients with acute myocarditis. Several studies both in the clinical setting and experimental models propose that immunoglobulin may reduce inflammatory cytokines that have direct negative inotropic effects and decrease the oxidative stress (Kishimoto et al., 2003).

Numerous cases with myocarditis recover spontaneously. It is hard to know if the noted improvement is a consequence of therapy with IVIG or immunosuppression versus natural

course of the disease. Therefore, studies assessing immunomodulation and immune suppressive agents were problematic to decode into an applicable, routine treatment for children and adults with acute myocarditis. One should also consider that initiating agents for acute myocarditis and following clinical course may change from time to time and by geographic site. Although such a controversy remains to be settled, IVIG may be used only in selected pediatric patients with acute myocarditis.

6.2 Antiviral treatment & vaccines

While viral infection is the most frequent cause of myocarditis, it might be possible to think that vaccines and antiviral agents might be helpful in the treatment of myocarditis. It is obvious that studies using polymerase chain reaction identified viral genomes in patients with acute myocarditis (Bowles et al., 2003). But, there are a few studies which demonstrated that requirement for transplantation and mortality was not dependent on the presence of viral genome (Kindermann et al., 2008, Kuhl et al., 2005). So, many investigators suggested that the presence of viral antigens or nucleotides in the myocardium alone is not satisfactory to prove that the virus is the cause of myocarditis (Matsumori et al., 2007). Since the diagnosis of viral myocarditis is frequently challenging and the diagnostic approaches have not been established or standardised, the number of clinical trials for virus proven myocarditis is limited. For that reason, in order to investigate therapeutic and preventative methods for myocarditis, various animal models have been developed. Several promising new agents including peroxisome proliferator activated gamma receptor activator, rapamycin, pycogenol, SUNC8079 and mycophenol mofetil have been studied in murine models of myocarditis during the last decade (Komiyoshi et al., 2005, Ellis&DiSalvo, 2007, Matsumori, 2007). It has been demonstrated that these agents decrease the severity of myocarditis and improve cardiac function, blocks activation of NF- κ , blocks mRNA expression of key cytokines (IL-1, IL-6 and TNF) and stabilizes mast cell (Matsumori, 2007). Synergistic effect of IFN- α and ribavirin has been demonstrated against both EMCV and coxsackie virus infection (Okada et al., 1992, Matsumori, 2007). IFN- β has reported to be effective in studies including small number of patients with left ventricular dysfunction whose biopsy specimens were positive for adenovirus or enterovirus (Kuhl et al., 2003).

Although various strategies for the prevention of acute myocarditis have been studied in murine models, up to now, there have been no vaccination trial in humans. Vaccination against mumps, rubella, poliomyelitis, measles and influenza has made myocarditis consequent to these infections quite rare and increases the arguments on whether vaccination against other cardiotropic viruses might prevent myocarditis in the future. A classical example in this regard was supported by the study of EFE described previously (Ni et al., 1997). The mumps virus vaccine has entirely eliminated this form of dilated cardiomyopathy. It is unlikely that antiviral vaccines to battle this disease will be improved in the near future due to low incidence of the disease.

6.3 Physical activity

Recommendations concerning physical activity affirm that all patients with presumed or definite myocarditis discontinue competitive sports and undergo a prudent convalescence period around six months after the onset of clinical manifestations. Athletes may return to sports activity if LV function, dimensions and wall motions return to normal, markers of inflammation in blood have resolved, 12-lead ECG has normalized and clinically relevant arrhythmias are absent on Holter ECG or graded exercise testing (Maron et al., 2005).

7. Outcome

Prognosis of myocarditis is as changed as its clinical presentations. Although the fewer data are available on the natural history of myocarditis in children, it is proposed that the outcomes in pediatric patients presenting with acute heart failure secondary to acute myocarditis tends to be more positive than the prognosis with dilated cardiomyopathy (Drucker et al., 1994, Lee et al., 1999). In a retrospective analysis of 36 children with histologically proven lymphocytic myocarditis (Lee et al., 1999), excellent outcomes have been demonstrated in children with myocarditis, especially those surviving 72 hours after presentation. Gagliardi and colleagues, classified 114 children into three groups as acute myocarditis, borderline myocarditis and non-inflammatory cardiomyopathy according to histological analysis (Gagliardi et al., 2004). Best survival rate (97%) was found in acute myocarditis group. They suggested that this high long term survival rate of this cohort may be due to effect of short term immunosuppressive therapy. On the other hand, in a multi-center study including children and adults, difference in outcomes between age groups was noted (Bowles et al., 2003). Survival rate for neonates and infants (33 and 45%, respectively) were significantly lower than the other groups. Survival rate was noted to be greatest in adolescent age group. A retrospective study involving 28 children with acute myocarditis, analysed the predictors of outcome. It was observed that ejection fraction < 30%, shortening fraction < 15%, left ventricle dilatation and moderate to severe mitral regurgitation at admission were associated with poor outcome (Kuhn et al., 2004). However, it was understood from the findings of adult trials that syncope, right ventricle dysfunction, elevated pulmonary artery pressure and advanced New York Heart Association functional class were predictors of increased probability of death or requirement for transplantation (Mendes et al, 1994, McCarthy et al., 2000, Magnani&Dec, 2006, Kindermann et al., 2008). Histological classification and severity of symptoms may also give a clue about prognosis. Giant cell myocarditis has a chance of 89% of death or transplantation. Surprisingly, acute fulminant myocarditis may have a better prognosis (Ellis & DiSalvo, 2007).

In general, transplantation is needed in 1-8% of patients with acute myocarditis (Ellis & DiSalvo, 2007). In spite of severe disease at presentation, there is a probability of improvement. Patients should not be listed promptly unless recovery is believed extremely unlikely despite judicious management.

8. Conclusion

Myocarditis in children is challenging given a variety of clinical manifestations that may share common pediatric illnesses such as respiratory infections and gastrointestinal disorders. A high index suspicion is so vital in the diagnosis. With the introduction of new additional diagnostic modalities including cardiac magnetic resonance imaging and biomarkers, cases will be identified easily in the future that would have been formerly missed. Myocarditis causes dilated cardiomyopathy in a significant portion of children. Prognosis for cases with acute viral myocarditis is much better than cases with established cases of dilated cardiomyopathy. Therefore, prompt diagnosis and early effective supportive care are crucial. Even if, much improvement has been achieved in pathogenesis, diagnosis and treatment of myocarditis, many questions remain to be answered and indicate the necessity for additional investigations.

9. References

- Aggarwal, S., Ghilardi, N., Xie, M. H., de Sauvage, F. J., and Gurney, A. L. (2003). Interleukin-23 promotes a distinct CD4 T cell activation state characterized by the production of interleukin-17. *J. Biol. Chem.* 278, 1910-1914.
- Amabile N, Fraisse A, Bouvenot J, et al: Outcome of acute fulminant myocarditis in children. *Heart (British Cardiac Society)* 2006;92:1269-1273.
- Angelini A, Calzolari V, Calabrese F, Boffa GM, Maddalena F, Chioin R, Thiene G. Myocarditis mimicking acute myocardial infarction: role of endomyocardial biopsy in the differential diagnosis. *Heart.* 2000;84:245-250.
- Angelini A, Crosato M, Boffa GM, Calabrese F, Calzolari V, Chioin R, Daliento L, Thiene G. Active vs. borderline myocarditis: clinicopathological correlates and prognostic implications. *Heart* 2002;87:210-215.
- Aretz HT, Billingham ME, Edwards WD, Parker MM, Factor SM, Fallon JT & Fenoglio JJ. Myocarditis: a histopathologic definition and classification. *Am J Cardiovasc Pathol.* 1987;1:3-14.
- Ayach B, Fuse K, Martino T, Liu P. Dissecting mechanisms of innate and acquired immunity in myocarditis. *Curr Opin Cardiol.* 2003 May;18(3):175-81.
- Baboonian C, Treasure T. Meta-analysis of the association of enteroviruses with human heart disease. *Heart.* 1997;78:539-543.
- Badorff C, Knowlton K. Role of CVB protease 2A in dystrophin destruction. *Nat Med.* 1999;5:320 -326.
- Bajcetic M, Kokic Nikolic A, Djukic M, Kosutic J, Mitrovic J, Mijalkovic D, Jovanovic I, Simeunovic S, Spasic MB, Samardzic R. Effects of carvedilol on left ventricular function and oxidative stress in infants and children with idiopathic dilated cardiomyopathy: a 12-month, two-center, open-label study. *Clin Ther.* 2008 Apr;30(4):702-14.
- Balaji S, Wiles HB, Sens MA, et al. Immunosuppressive treatment for myocarditis and borderline myocarditis in children with ventricular ectopic rhythm. *Br Heart J* 1994; 72: 354-359.
- Beck MA, Levander OA, Handy J: Selenium deficiency and viral infection. *J Nutr* 2003;133(5 Suppl 1):1463S-1467S.
- Beischel J, Larson DF, Yu Q, Yang B, Sepúlveda RT, Kelley T, Watson RR. Dilated cardiomyopathy in retrovirally infected mice: a novel model for silent viral DCM? *Cardiovasc Toxicol.* 2004;4(4):317-25.
- Bock CT, Klingel K, Kandolf R. (2010) Human parvovirus B19-associated myocarditis. *N Engl J Med* 362:1248-1249.
- Bowles NE, Ni J, Kearney DL, Pauschinger M, Schultheiss HP, McCarthy R, Hare J, Bricker JT, Bowles KR & Towbin JA. Detection of viruses in myocardial tissues by polymerase chain reaction: evidence of adenovirus as a common cause of myocarditis in children and adults. *J Am Coll Cardiol.* 2003;42:466-472.
- Bowles NE, Bowles KR, Towbin JA. Viral genomic detection and outcome in myocarditis. *Heart Fail Clin* 2005; 1:407-417.
- Bradley TD, Holloway RM, McLaughlin PR, et al. Cardiac output response to continuous positive airway pressure in congestive heart failure. *Am Rev Respir Dis* 1992; 145: 377-382.

- Bratincsak A, El-Said HG, Bradley JS, Shayan K, Grossfeld PD, Cannavino CR. Fulminant Myocarditis Associated With Pandemic H1N1 Influenza A Virus in Children. *J Am Coll Cardiol* 2010; 55:928–929.
- Breuckmann F, Neumann T, Kondratieva J, et al: Dilated cardiomyopathy in two adult human immunodeficiency positive(HIV+) patients possibly related to highly active antiretroviral therapy (HAART). *Eur J Med Res* 2005;10:395-399
- Brodison A, Swann JW. Myocarditis: a review. *The Journal of infection*. 1998 Sep;37(2):99-103.
- Camargo PR, Snitcowsky R, da Luz PL, et al: Favorable effects of immunosuppressive therapy in children with dilated cardiomyopathy and active myocarditis. *Pediatr Cardiol* 1995;16:61-68.
- Camargo PR, Okay TS, Yamamoto L, et al. Myocarditis in children and detection of viruses in myocardial tissue: implications for immunosuppressive therapy. *Int J Cardiol* 2009.
- Carlquist, J. F., Menlove, R. L., Murray, M. B., O'Connell, J. B., and Anderson, J. L. (1991). HLA class II (DR and DQ) antigen associations in idiopathic dilated cardiomyopathy. Validation study and meta-analysis of published HLA association studies. *Circulation* 83,515–522.
- Chan KY, Iwahara M, Benson LN, et al: Immunosuppressive therapy in the management of acute myocarditis in children: a clinical trial. *J Am Coll Cardiol* 1991;17:458-460.
- Checchia PA, Kulik TJ. Acute viral myocarditis: diagnosis. *Pediatr Critical Care Med* 2006; 7: S8-S11.
- Chen F, Shannon K, Ding S, et al: HIV type 1 glycoprotein 120 inhibits cardiac myocyte contraction. *AIDS Res Hum Retrovir* 2002;18:777-784.
- Chen, P.H., Ornelles, D.A. & Shenk, T. The adenovirus L3 23-kilodalton proteinase cleaves the amino-terminal head domain from cytokeratin 18 and disrupts the cytokeratin network of HeLa cells. *J. Virol.* 67, 3507–3514 (1993).
- Chen, Y., Langrish, C. L., McKenzie, B., Joyce-Shaikh, B., Stumhofer, J. S., McClanahan, T., Blumenschein, W., Churakovsa, T., Low, J., Presta, L., Hunter, C. A., Kastelein, R. A., et al. (2006). Anti-IL-23 therapy inhibits multiple inflammatory pathways and ameliorates autoimmune encephalomyelitis. *J. Clin. Invest.* 116, 1317–1326.
- Cihakova, D., Barin, J. G., Afanasyeva, M., Kimura, M., Fairweather, D., Berg, M., Talor, M. V., Baldeviano, G. C., Frisancho, S., Gabrielson, K., Bedja, D., and Rose, N. R. (2008). Interleukin-13 protects against experimental Autoimmune myocarditis by regulating macrophage differentiation. *Am. J. Pathol.* 172, 1195–1208.
- Cooper LT Jr, Berry GJ, Shabetai R. Idiopathic giant-cell myocarditis – natural history and treatment. Multicenter Giant Cell Myocarditis Study Group Investigators. *N Engl J Med*. 1997;336:1860 -1866.
- Cooper LT, Baughman KL, Feldman AM, et al: The role of endomyocardial biopsy in the management of cardiovascular disease: a scientific statement from the American Heart Association, the American College of Cardiology, and the European Society of Cardiology. *Circulation* 2007;116:2216-2233.
- Costello JM, Alexander ME, Greco KM, et al: Lyme carditis in children: presentation, predictive factors, and clinical course. *Pediatrics* 2009;123:e835-e841.
- d'Amati G, di Gioia CR, Gallo P. Pathological findings of HIV associated cardiovascular disease. *Ann NY Acad Sci*. 2001;946:23– 45.

- Daly K, Monaghan M, Richardson P, et al: Significant incidence of mural thrombi in acute myocarditis – indications for early anticoagulation (abstract). *J Am Coll Cardiol* 1983;1:584.
- Danti M, Sbarbati S, Alsadi N, et al. Cardiac magnetic resonance imaging: diagnostic value and utility in the follow-up of patients with acute myocarditis mimicking myocardial infarction. *Radiol Med* 2009; 114:229–238.
- Davison AJ, Benko M, Harrach B. Genetic content and evolution of adenoviruses. *J Gen Virol* 2003;84:2895–2908.
- de Vetten L, Bergman KA, Elzenga NJ, van Melle JP, Timmer A, Bartelds B. Neonatal myocardial infarction or myocarditis? *Pediatr Cardiol*. 2011 Apr;32(4):492-7. Epub 2011 Jan 8.
- Dec GW, Palacios IF, Fallon JT, Aretz HT, Mills J, Lee DC, Johnson RA. Active myocarditis in the spectrum of acute dilated cardiomyopathies: clinical features, histologic correlates, and clinical outcome. *New England Journal of Medicine*. 1985;312:885–890.
- Dec GW, Waldman H, Southern J, Fallon JT, Hutter AM, Palacios I. Viral myocarditis mimicking acute myocardial infarction. *J Am Coll Cardiol*. 1992;20:85–89.
- Dettmeyer R, Baasner A, Schlamann N, Padosch SA, Haag R, Kandolf R, Madea B. Role of virus-induced myocardial infections in sudden infant death syndrome: a prospective postmortem study. *Ped Research* 2004;55:947–52.
- Donoso Mantke O, Meyer R, Prosch S, et al. High prevalence of cardiotropic viruses in myocardial tissue from explanted hearts of heart transplant recipients and heart donors: a 3-year retrospective study from a German patients' pool. *J Heart Lung Transplant* 2005; 24:1632–8.
- Doolan A, Langlois N, Semsarian C. Causes of sudden cardiac death in young Australians. *Med J Aust*. 2004;180:110–112.
- Drory Y, Turetz Y, Hiss Y, Lev B, Fishman EZ, Pines A, Kramer MR. Sudden unexpected death in persons less than 40 years of age. *Am J Cardiol*. 1991;68:1388–1392.
- Drucker NA, Colan SD, Lewis AB, et al. Gamma-globulin treatment of acute myocarditis in the pediatric population. *Circulation* 1994; 89:252–257.
- Durani Y, Egan M, Baffa J, et al. Pediatric myocarditis: presenting clinical characteristics. *Am J Emerg Med* 2009; 27:942–947.
- Ellis CR, Di Salvo T. Myocarditis: basic and clinical aspects. *Cardiol Rev* 2007; 15: 170–177.
- Fairweather, D., Afanasyeva, M., and Rose, N. R. (2004). Cellular immunity: A role for cytokines. In "Handbook of Systemic Autoimmune Diseases: The Heart in Systemic Autoimmune Diseases" (A. Doria, and P. Pauletto, Eds.), pp. 3–7. Elsevier, Amsterdam.
- Fairweather, D., and Rose, N. R. (2007). Coxsackievirus-induced myocarditis in mice: A model of autoimmune disease for studying immunotoxicity. *Methods* 41, 118–122.
- Feldman AM, McNamara D. Myocarditis. *N Engl J Med*. 2000;343:1388–1398.
- Felker GM, Hu W, Hare JM, Hruban RH, Baughman KL, Kasper EK. The spectrum of dilated cardiomyopathy: the Johns Hopkins experience with 1,278 patients. *Medicine (Baltimore)*. 1999;78:270–283

- Felker GM, Boehmer JP, Hruban RH, et al: Echocardiographic findings in fulminant and acute myocarditis. *J Am Coll Cardiol* 2000;36:227-232.
- Freedman SB, Haladyn JK, Floh A, et al. Pediatric myocarditis: emergency department clinical findings and diagnostic evaluation. *Pediatrics* 2007;120:1278-1285.
- Friedman RA, Kearney DL, Moak JP, et al. Persistence of ventricular arrhythmia after resolution of occult myocarditis in children and young adults. *J Am Coll Cardiol* 1994;24:780-783.
- Friedman RA, Schowengerdt KO, Towbin JA. Myocarditis. In: Bricker JT, Garson A Jr, Fisher DJ, et al., eds. *The Science and Practice of Pediatric Cardiology*. 2nd ed. Baltimore: Williams & Wilkins, 1998: 1777-1794.
- Friedrich MG, Strohm O, Schulz-Menger J, et al: Contrast media enhanced magnetic resonance imaging visualizes myocardial changes in the course of viral myocarditis. *Circulation* 1998;97:1802-1809.
- Friedrich MG, Sechtem U, Schulz-Menger J, et al: Cardiovascular magnetic resonance in myocarditis: A JACC White Paper. *J Am Coll Cardiol* 2009;53:1475-1487.
- Friman G, Wesslen L, Fohlman J et al. The epidemiology of infectious myocarditis, lymphocytic myocarditis and dilated cardiomyopathy. *Eur Heart J* 1995; 16 (Suppl. O): 36-41.
- Fuse, K., Chan, G., Liu, Y., Gudgeon, P., Husain, M., Chen, M., Yeh, W. C., Akira, S., and Gagliardi MG, Bevilacqua M, Bassano C, et al. Long term follow up of children with myocarditis treated by immunosuppression and of children with dilated cardiomyopathy. *Heart* 2004; 90: 1167-1171.
- Garg A, Shiau J, Guyatt G. The ineffectiveness of immunosuppressive therapy in lymphocytic myocarditis: an overview. *Ann Intern Med* 1998; 129: 317-322.
- Godeny EK, Gauntt CJ. Murine natural killer cells limit coxsackievirus B3 replication. *J Immunol* 1987;139:913-918.
- Goitein O, Matetzky S, Beinart R, et al. Acute myocarditis: noninvasive evaluation with cardiac MRI and transthoracic echocardiography. *AJR Am J Roentgenol* 2009; 192:254-258.
- Gorbea C, Makar KA, Pauschinger M, Pratt G, Bersola JL, Varela J, David RM, Banks L, Huang CH, Li H, Schultheiss HP, Towbin JA, Vallejo JG, Bowles NE. A role for Toll-like receptor 3 variants in host susceptibility to enteroviral myocarditis and dilated cardiomyopathy. *J Biol Chem*. 2010 Jul 23;285(30):23208-23. Epub 2010 May 14.
- Gore I, Saphir O. Myocarditis: a classification of 1402 cases. *Am Heart J*. 1947;34:827-830.
- Gravanis, MB. ; Sternby, NH. (1991) Incidence of myocarditis. A 10-year autopsy study from Malmö, Sweden. *Archives of Pathology & Laboratory Medicine*, Vol.115 No. 5, (April 1991), pp. 390-392, ISSN 1543-2165.
- Greenwood RD, Nadas AS, Fyler DC: The clinical course of primary myocardial disease in infants and children. *Am Heart J* 1976;92:549-560.
- Guler, M. L., Ligons, D. L., Wang, Y., Bianco, M., Broman, K. W., and Rose, N. R. (2005). Two autoimmune diabetes loci influencing T cell apoptosis control susceptibility to experimental autoimmune myocarditis. *J. Immunol*. 174, 2167-2173.
- Gunthard J, Stocker F, Bolz D, et al. Dilated cardiomyopathy and thrombo-embolism. *Eur J Pediatr* 1997; 156: 3-6.

- Gutberlet M, Spors B, Thoma T, et al: Suspected chronic myocarditis at cardiac MR: diagnostic accuracy and association with immunohistologically detected inflammation and viral persistence. *Radiology* 2008;246:401-409.
- Hampton TG, Crumpacker CS, Abelman WH, Amende I, Morgan JP. 2005. Propranolol ameliorates and epinephrine exacerbates progression of acute and chronic viral myocarditis. *Am J Physiol Heart Circ Physiol* 289:H1577-H1583.
- Hauck AJ, Kearney DL, Edwards WD. Evaluation of postmortem endomyocardial biopsy specimens from 38 patients with lymphocytic myocarditis: implications for role of sampling error. *Mayo Clin Proc.* 1989;64:1235-1245.
- Hayder H, Müllbacher A. Molecular basis of immune evasion strategies by adenoviruses. *Immunol Cell Biol.* 1996 Dec;74(6):504-12.
- Hia CP, Yip WC, Tai BC, et al. Immunosuppressive therapy in acute myocarditis: an 18 year systematic review. *Arch Dis Child* 2004; 89: 580-584.
- Huber SA. Animal models: immunological aspects. In: Banatvala JE, ed. *Viral Infections in the Heart*. London, UK: Edward Arnold; 1993: 82-109.
- Ilback NG, Wesslen L, Fohlman J, et al: Effects of methyl mercury on cytokines, inflammation and virus clearance in a common infection (coxsackie B3 myocarditis). *Toxicol Lett* 1996;89:19-28.
- Kamiyoshi Y, Takahashi M, Yokoseki O, et al. Mycophenolate mofetil prevents the development of experimental autoimmune myocarditis. *J Mol Cell Cardiol.* 2005;39:467- 477.
- Kashimura T, Kodama M, Hotta Y, et al: Spatiotemporal changes of coxsackievirus and adenovirus receptor in rat hearts during postnatal development and in cultured cardiomyocytes of neonatal rat. *Virchows Arch* 2004;444:283-292.
- Kawai C, Matsumori A, Kitaura Y, Takatsu T. Viruses and the heart: viral myocarditis and cardiomyopathy. *Prog Cardiol.* 1978;7:141-162.
- Kawai C. From myocarditis to cardiomyopathy: mechanisms of inflammation and cell death: learning from the past for the future. *Circulation.* 1999;99:1091-1100.
- Kawai C. Idiopathic cardiomyopathy: a study on the infectious-immune theory as a cause of the disease. *Jpn Circ J.* 1971;35:765-770.
- Kearney MT, Cotton JM, Richardson PJ & Shah AM. Viral myocarditis and dilated cardiomyopathy: mechanisms, manifestations, and management. *Postgrad Med J* 2001; 77:4-10.
- Kindermann I, Kindermann M, Kandolf R, Klingel K, Bultmann B, Müller T, Lindinger A, Böhm M. Predictors of outcome in patients with suspected myocarditis. *Circulation* 2008;118:639-648.
- Kishimoto C, Shioji K, Kinoshita M, Iwase T, Tamaki S, Fujii M, Murashige A, Maruhashi H, Takeda S, Nonogi H, Hashimoto T. Treatment of acute inflammatory cardiomyopathy with intravenous immunoglobulin ameliorates left ventricular function associated with suppression of inflammatory cytokines and decreased oxidative stress. *Int J Cardiol.* 2003 Oct;91(2-3):173-8.
- Klingel K, Hohenadl C, Canu A, Albrecht M, Seemann M, Mall G, Kandolf R. Ongoing enterovirus-induced myocarditis is associated with persistent heart muscle infection: quantitative analysis of virus replication, tissue damage, and inflammation. *Proc Natl Acad Sci U S A.* 1992;89:314 -318.

- Klugman D, Berger JT, Sable CA, He J, Khandelwal SG, Slonim AD. Pediatric patients hospitalized with myocarditis: a multi-institutional analysis. *Pediatr Cardiol*. 2010 Feb;31(2):222-8.
- Krous HF, Ferandos C, Masoumi H, et al. Myocardial inflammation, cellular death, and viral detection in sudden infant death caused by SIDS, suffocation, or myocarditis. *Pediatr Res* 2009; 66:17–21.
- Kuethe F, Lindner J, Matschke K, Wenzel JJ, Norja P, Ploetze K, Schaal S, Kamvissi V, Bornstein SR, Schwanebeck U & Modrow S. Prevalence of parvovirus B19 and human bocavirus DNA in the heart of patients with no evidence of dilated cardiomyopathy or myocarditis. *Clin Infect Dis*. 2009 Dec 1;49(11):1660-6.
- Kuethe F, Sigusch HH, Hilbig K, et al. Detection of viral genome in the myocardium: lack of prognostic and functional relevance in patients with acute dilated cardiomyopathy. *Am Heart J* 2007; 153:850–8.
- Kuhl U, Pauschinger M, Schwimmbeck PL, et al. Interferon-beta treatment eliminates cardiotropic viruses and improves left ventricular function in patients with myocardial persistence of viral genomes and left ventricular dysfunction. *Circulation*. 2003;107:2793–2798
- Kuhl U, Pauschinger M, Bock T, et al. Parvovirus B19 infection mimicking acute myocardial infarction. *Circulation* 2003; 108:945–950.
- Kuhl U, Pauschinger M, Seeberg B, et al. Viral persistence in the myocardium is associated with progressive cardiac dysfunction. *Circulation* 2005;112:1965–70.
- Kuhn B, Shapiro ED, Walls TA, et al. Predictors of outcome of myocarditis. *Pediatr Cardiol* 2004; 25: 379–384.
- Kyto V, Saraste A, Voipio-Pulkki LM, et al. Incidence of fatal myocarditis: a population-based study in Finland. *Am J Epidemiol* 2007;165:570–4.
- Lee KJ, McCrindle BW, Bohn DJ, et al. Clinical outcomes of acute myocarditis in childhood. *Heart* 1999; 82: 226–233.
- Limas, C. J., and Limas, C. (1989). HLA antigens in idiopathic dilated cardiomyopathy. *Br.Heart. J.* 62, 379–383.
- Lipshultz SE, Sleeper LA, Towbin JA, et al. The incidence of pediatric cardiomyopathy in two regions of the United States. *N Engl J Med* 2003;348:1647-55.
- Liu P, Penninger J, Aitken K, Sole M, Mak T. The role of transgenic knockout models in defining the pathogenesis of viral heart disease. *Eur Heart J*. 1995 Dec;16 Suppl O:25-7.
- Liu PP, Mason JW. Advances in the understanding of myocarditis. *Circulation*. 2001;104:1076–1082.
- Liu W, Li WM, Sun NL. HLA-DQA1, -DQB1 polymorphism and genetic susceptibility to idiopathic dilated cardiomyopathy in Hans of northern China. *Ann Hum Genet*. 2005 Jul;69(Pt 4):382-8.
- Liu, P. P. (2005). Myeloid differentiation factor-88 plays a crucial role in the pathogenesis of coxsackievirus B3-induced myocarditis and influences type I interferon production. *Circulation* 112, 2276–2285.
- Lotze U, Egerer R, Tresselt C, et al. Frequent detection of parvovirus B19 genome in the myocardium of adult patients with idiopathic dilated cardiomyopathy. *Med Microbiol Immunol* 2004; 193:75–82.

- Magnani JW, Danik HJ, Dec Jr GW, et al: Survival in biopsy proven myocarditis: a long-term retrospective analysis of the histopathologic, clinical, and hemodynamic predictors. *Am Heart J* 2006;151:463-470.
- Magnani JW, Dec GW: Myocarditis: current trends in diagnosis and treatment. *Circulation* 2006;113:876-890.
- Mahrholdt H, Goedecke C, Wagner A, et al: Cardiovascular magnetic resonance assessment of human myocarditis: a comparison to histology and molecular pathology. *Circulation* 2004;109: 1250-1258.
- Mahrholdt H, Wagner A, Deluigi CC, Kispert E, Hager S, Meinhardt G, Vogelsberg H, Fritz P, Dippon J, Bock CT, Klingel K, Kandolf R & Sechtem U. Presentation, patterns of myocardial damage, and clinical course of viral myocarditis. *Circulation* 2006;114:1581-1590.
- Maisch B, Trostel-Soeder R, Strechemesser E, et al. Diagnostic relevance of humoral and cell-mediated immune reactions in patients with acute viral myocarditis. *Clin Exp Immunol* 1982;48:533-545
- Maisch B, Herzum M, Hufnagel G, et al. Immunosuppressive treatment for myocarditis and dilated cardiomyopathy. *Eur Heart J* 1995; 16 Suppl O: 153-161.
- Maron BJ, Ackerman MJ, Nishimura RA, et al: Task Force 4: HCM and other cardiomyopathies, mitral valve prolapse, myocarditis, and Marfan syndrome. *J Am Coll Cardiol* 2005;45:1340-1345.
- Martin AB, Webber S, Fricker FJ, Jaffe R, Demmler G, Kearney D, Zhang YH, Bodurtha J, Gelb B, Ni J, et al. Acute myocarditis. Rapid diagnosis by PCR in children. *Circulation*. 1994 Jul;90(1):330-9.
- Mason JW, O'Connell JB, Herskowitz A, et al. A clinical trial of immunosuppressive therapy for myocarditis. The myocarditis treatment trial investigators. *N Engl J Med* 1995; 333: 269-275.
- Matsumori A, Igata H, Ono K, et al: High doses of digitalis increase the myocardial production of proinflammatory cytokines and worsen myocardial injury in viral myocarditis: a possible mechanism of digitalis toxicity. *Jpn Circ J* 1999;63:934-940.
- Matsumori A, Matoba Y, Sasayama S. Dilated cardiomyopathy associated with hepatitis C virus infection. *Circulation*. 1995;92:2519 -2525.
- Matsumori A, Yamada T, Suzuki H, Matoba Y, Sasayama S. Increased circulating cytokines in patients with myocarditis and cardiomyopathy. *Br Heart J*. 1994;72:561-566.
- Matsumori A. Treatment options in myocarditis: what we know from experimental data and how it translates to clinical trials. *Herz*. 2007 Sep;32(6):452-6.
- McCarthy III RE, Boehmer JP, Hruban RH, et al: Long-term outcome of fulminant myocarditis as compared with acute (nonfulminant) myocarditis. *N Engl J Med* 2000;342:690-695.
- McNamara DM, Rosenblum WD, Janosko KM, et al. Intravenous immune globulin in the therapy of myocarditis and acute cardiomyopathy. *Circulation* 1997; 95: 2476-2478.
- McNamara DM, Holubkov R, Starling RC, et al: Controlled trial of intravenous immune globulin in recent-onset dilated cardiomyopathy. *Circulation* 2001;103:2254-2259.
- Mendes LA, Dec GW, Picard MH, et al. Right ventricular dysfunction: an independent predictor of adverse outcome in patients with myocarditis. *Am Heart J* 1994; 128: 301-307.

- Mikami S, Kawashima S, Kanazawa K, Hirata K, Hotta H, Kayashi Y, Itoh H, Yokoyama M. Low-dose N omega-nitro-L-arginine methyl ester treatment improves survival rate and decreases myocardial injury in a murine model of viral myocarditis induced by Coxsackievirus B3. *Circ Res.* 1997;81:504 -511.
- Milenkovic M, Arsenović-Ranin N, Stojić-Vukanić Z, Bufan B, Vučićević D, Jančić I. Quercetin ameliorates experimental autoimmune myocarditis in rats. *J Pharm Pharm Sci.* 2010;13(3):311-9.
- Moloney ED, Egan JJ, Kelly P, et al. Transplantation for myocarditis: a controversy revisited. *J Heart Lung Transplant.* 2005;24:1103-1110.
- Moncada S, Liew FY, Lowenstein CJ. The role of inducible nitric oxide synthase in the host response to coxsackievirus myocarditis. *Proc Natl Acad Sci U S A.* 1998;95:2469 - 2474.
- Morgera T, Di Lenarda A, Dreas L, et al: Electrocardiography of myocarditis revisited: clinical and prognostic significance of electrocardiographic changes. *Am Heart J* 1992;124:455-467.
- Nakashima H, Katayama T, Ishizaki M, et al: Q wave and non-Q wave myocarditis with special reference to clinical significance. *Jpn Heart J* 1998;39:763-774.
- Naughton MT, Rahman MA, Hara K, et al. Effect of continuous positive airway pressure on intrathoracic and left ventricular transmural pressures in patients with congestive heart failure. *Circulation* 1995; 91: 1725-1731.
- Neu, N., Rose, N. R., Beisel, K. W., Herskowitz, A., Gurri-Glass, G., and Craig, S. W. (1987). Cardiac myosin induces myocarditis in genetically predisposed mice. *J. Immunol.* 139, 3630-3636.
- Ni J, Bowles NE, Kim YH, et al. Viral infection of the myocardium in endocardial fibroelastosis. Molecular evidence for the role of mumps virus as an etiologic agent. *Circulation* 1997;95:133-9.
- Nishio R, Shioi T, Sasayama S, Matsumori A. 2003. Carvedilol increases the production of interleukin-12 and interferon-gamma and improves the survival of mice infected with the encephalomyocarditis virus. *J Am Coll Cardiol* 41:340-345.
- O'Donoghue HL, Lawson CM, Reed WD. Autoantibodies to cardiac myosin in mouse cytomegalovirus myocarditis. *Immunology.* 1990 Sep;71(1):20-8.
- Okada I, Matsumori A, Matoba Y, et al. Combination treatment with ribavirin and interferon for coxsackievirus B3 replication. *J Lab Clin Med* 1992;120:569-73.
- Ono K, Matsumori A, Shioi T, et al. Cytokine gene expression after myocardial infarction in rat hearts: possible implication in left ventricular remodeling. *Circulation.* 1998;98:149 -156.
- Opavsky MA, Penninger J, Aitken K, Wen WH, Dawood F, Mak T, Liu P. Susceptibility to myocarditis is dependent on the response of T lymphocytes to coxsackieviral infection. *Circ Res.* 1999;85:551-558.
- Padalko E, Ohnishi T, Matsushita K, Sun H, Fox-Talbot K, Bao C, Baldwin WM, Lowenstein CJ. Peroxynitrite inhibition of coxsackievirus infection by prevention of viral RNA entry. *Proc Natl Acad Sci U S A.* 2004;101:11731-11736.
- Parrillo JE, Cunnion RE, Epstein SE, et al. A prospective, randomized, controlled trial of prednisone for dilated cardiomyopathy. *N Engl J Med* 1989; 321: 1061-1068.
- Parrillo JE. Inflammatory cardiomyopathy (myocarditis): which patients should be treated with anti-inflammatory therapy? *Circulation.* 2001; 104:4-6.

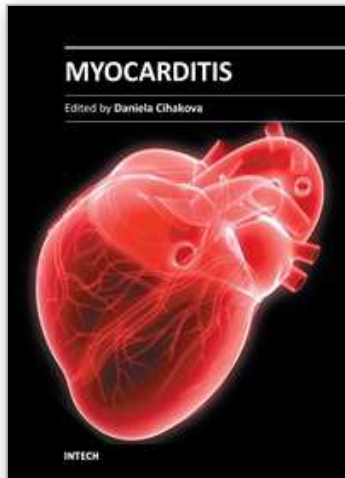
- Pauschinger M, Bowles NE, Fuentes-Garcia FJ, et al. Detection of adenoviral genome in the myocardium of adult patients with idiopathic left ventricular dysfunction. *Circulation*. 1999;99:1348-1354.
- Pophal SG, Sigfusson G, Booth KL, et al. Complications of endomyocardial biopsy in children. *J Am Coll Cardiol* 1999; 34: 2105-2110.
- Potapov EV, Stiller B, Hetzer R. Ventricular assist devices in children: current achievements and future perspectives. *Pediatr Transplant* 2007; 11: 241-255.
- Pugliese A, Isnardi D, Saini A, et al: Impact of highly active antiretroviral therapy in HIV positive patients with cardiac involvement. *J Infect* 2000;40:282-284.
- Robinson J, Hartling L, Vandermeer B, et al. Intravenous immunoglobulin for presumed viral myocarditis in children and adults. *Cochrane Database Syst Rev* 2005:CD004370.
- Robinson JL, Hartling L, Crumley E, et al. A systematic review of intravenous gamma globulin for therapy of acute myocarditis. *BMC Cardiovasc Disord* 2005; 5: 12.
- Rosen FS. Putative mechanisms of the effect of intravenous gamma- globulin. *Clin Immunol Immunopathol* 1993;67:S41-3.
- Salone B, Martina Y, Piersanti S, et al: Integrin alpha3beta1 is an alternative cellular receptor for adenovirus serotype 5. *J Virol* 2003;77:13448-13454.
- Sezai A, Hata M, Niino T, et al. Mechanical circulatory support for fulminant myocarditis. *Surg Today* 2008; 38: 773-777.
- Shafren DR, Bates RC, Agrez MV, et al: Coxsackieviruses B1, B3, and B5 use decay accelerating factor as a receptor for cell attachment. *J Virol* 1995;69:3873-3877.
- Shanes JG, Ghali J, Billingham ME, Ferrans VJ, Fenoglio JJ, Edwards WD, Tsai CC, Saffitz JE, Isner J, Forner S. Interobserver variability in the pathologic interpretation of endomyocardial biopsy results. *Circulation*. 1987;75:401- 405.
- Shirani J, Freant LJ, Roberts WC. Gross and semiquantitative histologic findings in mononuclear cell myocarditis causing sudden death, and implications for endomyocardial biopsy. *Am J Cardiol*. 1993;72:952-957.
- Shoeman, R.L. et al. Cleavage of human and mouse cytoskeletal and sarcomeric proteins by human immunodeficiency virus type 1 protease. Actin, desmin, myosin, and tropomyosin. *Am. J. Pathol.* 142, 221-230 (1993).
- Skouri HN, Dec GW, Friedrich MG, Cooper LT. Noninvasive imaging in myocarditis. *J Am Coll Cardiol* 2006; 48:2085-2093.
- Tchilian, E. Z., Gil, J., Navarro, M. L., Fernandez-Cruz, E., Chapel, H., Misbah, S., Ferry, B.,Renz, H., Schwinzer, R., and Beverley, P. C. (2006). Unusual case presentations associated with the CD45 C77G polymorphism. *Clin. Exp. Immunol.* 146, 448-454.
- Tedeschi A, Airaghi L, Giannini S, et al. High-dose intravenous immunoglobulin in the treatment of acute myocarditis. A case report and review of the literature. *J Intern Med* 2002; 251:169-173.
- Theleman KP, Kuiper JJ, Roberts WC. Acute myocarditis sudden death without heart failure. *Am J Cardiol*. 2001;88:1078-1083.
- Tomioka N, Kishimoto C, Matsumori A, Kawai C. Effects of prednisolone on acute viral myocarditis in mice. *J Am Coll Cardiol*. 1986;7:868-872.

- Toshima H, Ohkita Y, Shingu M. Clinical features of acute coxsackie B viral myocarditis. *Jpn Circ J*. 1979 May;43(5):441-4.
- Towbin JA, Bricker JT, Garson A Jr. Electrocardiographic criteria for diagnosis of acute myocardial infarction in childhood. *Am J Cardiol* 1992;69:1545-1548.
- Ukena C, Mahfoud F, Kindermann I, Kandolf R, Kindermann M, Böhm M. Prognostic electrocardiographic parameters in patients with suspected myocarditis. *Eur J Heart Fail*. 2011 Apr;13(4):398-405. Epub 2011 Jan 14.
- Vashist S, Singh GK. Acute myocarditis in children: current concepts and management. *Curr Treat Options Cardiovasc Med* 2009; 11:383-391.
- Vashist S, Woodard PK, Grady M, Singh G. MRI characteristics of acute myocarditis in pediatric patients: patterns and predictors of outcomes [abstract]. St Louis Washington University School of Medicine; 2009.
- Wang JF, Meissner A, Malek S, Chen Y, Ke Q, Zhang J, Chu V, Hampton TG, Crumpacker CS, Abelmann WH, Amende I, Morgan JP. Propranolol ameliorates and epinephrine exacerbates progression of acute and chronic viral myocarditis. *Am J Physiol Heart Circ Physiol*. 2005 Oct;289(4):H1577-83. Epub 2005 May 27.
- Weinmann HJ, Brasch RC, Press WR, Wesbey GE. Characteristics of gadolinium-DTPA complex: a potential NMR contrast agent. *Am J Roentgenol*. 1984;142:619-624.
- Wickham TJ, Filardo EJ, Cheresch DA, et al: Integrin alpha v beta 5 selectively promotes adenovirus mediated cell membrane permeabilization. *J Cell Biol* 1994;127:257-264.
- Wojnicz R, Nowalany-Kozielska E, Wojciechowska C, Glanowska G, Wilczewski P, Niklewski T, Zembala M, Polonski L, Wodniecki J, Rozek MM. Randomized, placebo-controlled study for immunosuppressive treatment of inflammatory dilated cardiomyopathy: two-year follow-up results. *Circulation*. 2001;104:39-45.
- Wolf HM, Eibl MM. Immunomodulatory effect of immunoglobulins *Clin Exp Rheum* 1996;14(Suppl 15):S17-25.
- Woodruff JF. Viral myocarditis: A review. *Am J Pathol* 1980;101:427-484.
- Xiong D, Lee GH, Badorff C, Dorner A, Lee S, Wolf P, Knowlton KU. Dystrophin deficiency markedly increases enterovirus-induced cardiomyopathy: a genetic predisposition to viral heart disease. *Nat Med*. 2002 Aug;8(8):872-7. Epub 2002 Jul 15.
- Yamamoto K, Shioi T, Uchiyama K, et al. Attenuation of virus-induced myocardial injury by inhibition of the angiotensin II type 1 receptor signal and decreased nuclear factor-kappa B activation in knockout mice. *J Am Coll Cardiol*. 2003;42:2000 - 2006
- Yuan J, Yu M, Lin QW, Cao AL, Yu X, Dong JH, Wang JP, Zhang JH, Wang M, Guo HP, Liao YH. Neutralization of IL-17 inhibits the production of anti-ANT autoantibodies in CVB3-induced acute viral myocarditis. *Int Immunopharmacol*. 2010 Mar;10(3):272-6. Epub 2009 Nov 20.
- Yuan J, Yu M, Lin QW, Cao AL, Yu X, Dong JH, Wang JP, Zhang JH, Wang M, Guo HP, Cheng X, Liao YH. Th17 cells contribute to viral replication in coxsackievirus B3-induced acute viral myocarditis. *J Immunol*. 2010 Oct 1;185(7):4004-10. Epub 2010 Aug 27.

- Zaragoza C, Ocampo C, Saura M, Leppo M, Wei XQ, Quick R, Moncada S, Liew FY, Lowenstein CJ. The role of inducible nitric oxide synthase in the host response to Coxsackievirus myocarditis. . Proc Natl Acad Sci U S A. 1998 Mar 3;95(5):2469-74.
- Zaragoza C, Ocampo CJ, Saura M, McMillan A, Lowenstein CJ. Nitric oxide inhibition of Coxsackie replication in vivo. J Clin Invest. 1997; 100:1760 -1767.

IntechOpen

IntechOpen



Myocarditis

Edited by Dr. Daniela Cihakova

ISBN 978-953-307-289-0

Hard cover, 428 pages

Publisher InTech

Published online 19, October, 2011

Published in print edition October, 2011

Myocarditis, the inflammation of the heart muscle, could be in some cases serious and potentially fatal disease. This book is a comprehensive compilation of studies from leading international experts on various aspects of myocarditis. The first section of the book provides a clinical perspective on the disease. It contains comprehensive reviews of the causes of myocarditis, its classification, diagnosis, and treatment. It also includes reviews of Perimyocarditis; Chagas's™ chronic myocarditis, and myocarditis in HIV-positive patients. The second section of the book focuses on the pathogenesis of myocarditis, discussing pathways and mechanisms activated during viral infection and host immune response during myocarditis. The third, and final, section discusses new findings in the pathogenesis that may lead to new directions for clinical diagnosis, including use of new biomarkers, and new treatments of myocarditis.

How to reference

In order to correctly reference this scholarly work, feel free to copy and paste the following:

Vedide Tavli and Baris Guven (2011). Myocarditis in Childhood: An Update on Etiology, Diagnosis and Management, Myocarditis, Dr. Daniela Cihakova (Ed.), ISBN: 978-953-307-289-0, InTech, Available from: <http://www.intechopen.com/books/myocarditis/myocarditis-in-childhood-an-update-on-etiology-diagnosis-and-management>

INTECH
open science | open minds

InTech Europe

University Campus STeP Ri
Slavka Krautzeka 83/A
51000 Rijeka, Croatia
Phone: +385 (51) 770 447
Fax: +385 (51) 686 166
www.intechopen.com

InTech China

Unit 405, Office Block, Hotel Equatorial Shanghai
No.65, Yan An Road (West), Shanghai, 200040, China
中国上海市延安西路65号上海国际贵都大饭店办公楼405单元
Phone: +86-21-62489820
Fax: +86-21-62489821

© 2011 The Author(s). Licensee IntechOpen. This is an open access article distributed under the terms of the [Creative Commons Attribution 3.0 License](#), which permits unrestricted use, distribution, and reproduction in any medium, provided the original work is properly cited.

IntechOpen

IntechOpen