

We are IntechOpen, the world's leading publisher of Open Access books Built by scientists, for scientists

4,800

Open access books available

122,000

International authors and editors

135M

Downloads

Our authors are among the

154

Countries delivered to

TOP 1%

most cited scientists

12.2%

Contributors from top 500 universities



WEB OF SCIENCE™

Selection of our books indexed in the Book Citation Index
in Web of Science™ Core Collection (BKCI)

Interested in publishing with us?
Contact book.department@intechopen.com

Numbers displayed above are based on latest data collected.

For more information visit www.intechopen.com



Clinical Features of Epilepsy Secondary to Neurocysticercosis at the Insular Lobe

Humberto Foyaca-Sibat and Lourdes de Fátima Ibañez Valdés
*Division of Neurology, Nelson Mandela Academic Hospital,
School of Medicine, Faculty of Health Sciences,
Walter Sisulu University, Mthatha,
South Africa*

1. Introduction

1.1 Background

Neurocysticercosis is eradicable parasitic zoonoses of the brain if it is managed by public health sector and agricultural sector with the dedicated support of veterinarian doctors. Neurocysticercosis is the only zoonotic infection which has been considered as eradicable by the World Health Assembly. Therefore, we will focus on that, and other parasitic zoonoses causing epilepsy will be discussed in another chapter. In this chapter new aspect about insular epilepsy secondary to NC will be introduced as well.

Like other pathological disorders, early diagnosis and treatment can significantly decrease morbidity and mortality rates of parasitic infections. Diseases that have their origins in infected animals, such as H1N1 influenza or SARS have highlighted the need for a better understanding of their origin on an affected animal.

The ease and speed of modern travel facilitates the spread of diseases once confined to specific geographic areas, as recently occurred with the widely publicized H1N1 influenza. Animal migration and trade pose a similar threat, as was shown by the outbreaks in the United States of West Nile fever, and monkey-pox, two diseases haven't previously known in the Western Hemisphere. Each of these examples highlights the need for accurate, up-to-date information and ongoing research on those public health problems. (Carabin, personal communication, 2010)

Pig farming has increased considerably during the past decade in Eastern and Southern Africa (ESA); especially in rural, resource-poor, smallholder communities where sanitation is poor. Hence, it is highly suspected that the frequency of epilepsy secondary to NC in the region may further increase in the foreseeable future. We see a lot of pigs affected by cysticercosis free of neurological signs but when there is a sign it can indicate the etiology of human's disease. Let us to address it in a better way, for example pigs with NC do not suffer of epilepsy, however presence of cysticercosis of pigs (intermediate host) indicates that NC is the most likely cause of epilepsy of peoples living around, being yet another reason to support that health worker and agriculture worker should work together in this field. In places where there are not clinical health laboratory facilities and CT/MR images or simply patients have not free to these investigations and the prevalence of epilepsy is considerably high we do suggest to confirm diagnosis of cysticercosis on pig's population by physical inspection of the tongue (Figure 1).

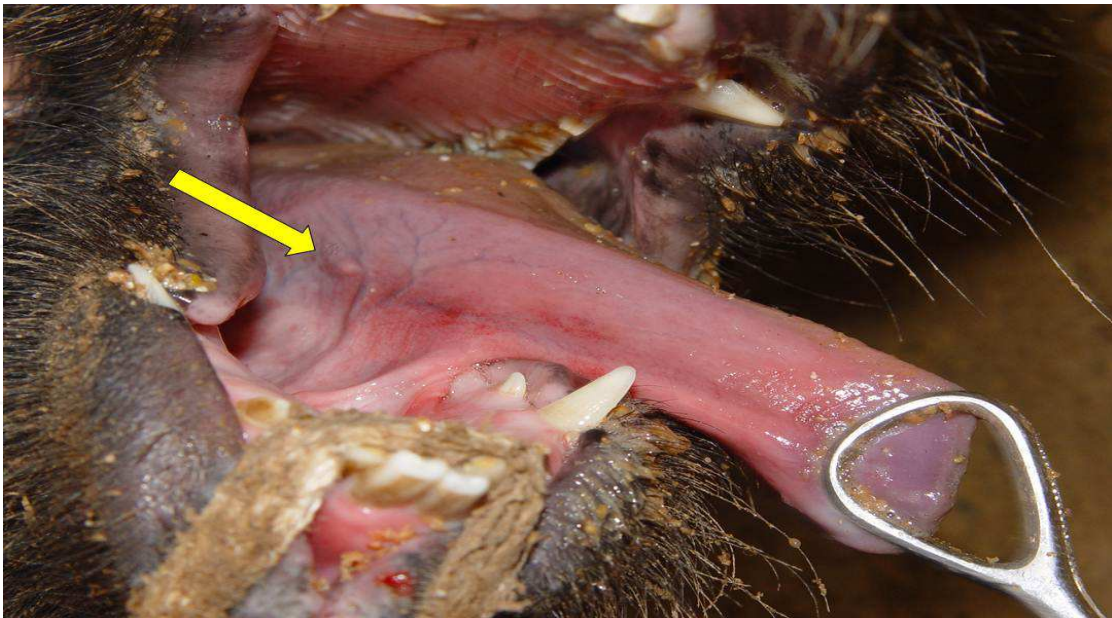


Fig. 1. A cystic lesion on the tongue in a pig affected by cysticercosis is pointed by the yellow arrow. Photo taken by Prof. RC Krecek (CWGESA)

The other choice is to take blood samples from jugular veins (Figure 2) and request ELISA for cysticercosis at the nearest veterinarian laboratory. It may help suspecting the etiological diagnosis of epilepsy in these patients and to support their treatment.



Fig. 2. Shows agricultural workers and Prof. Foyaca taken a blood sample from the jugular veins in infected pig. (Photo taken by Prof RC Krecek)

Taenia solium cysticercosis' life cycle starts when humans become infected by eating undercooked pork containing cysticerci (See figure 3) and later they develop taeniosis. People with taeniosis pass eggs with their faeces which are ingested by humans and pigs.

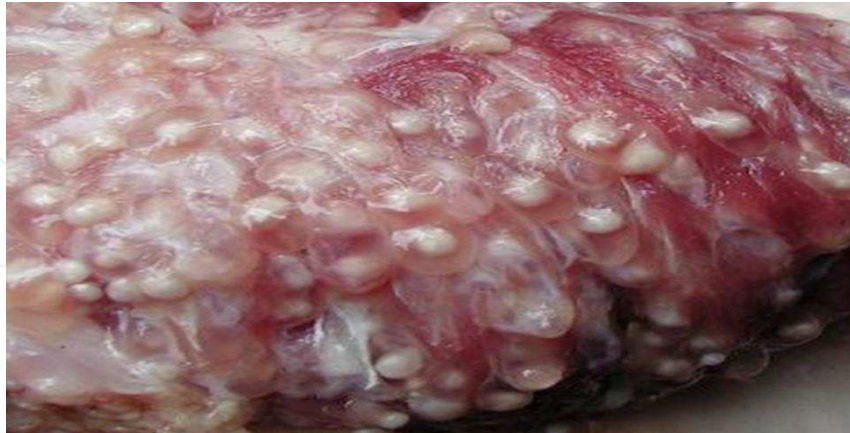

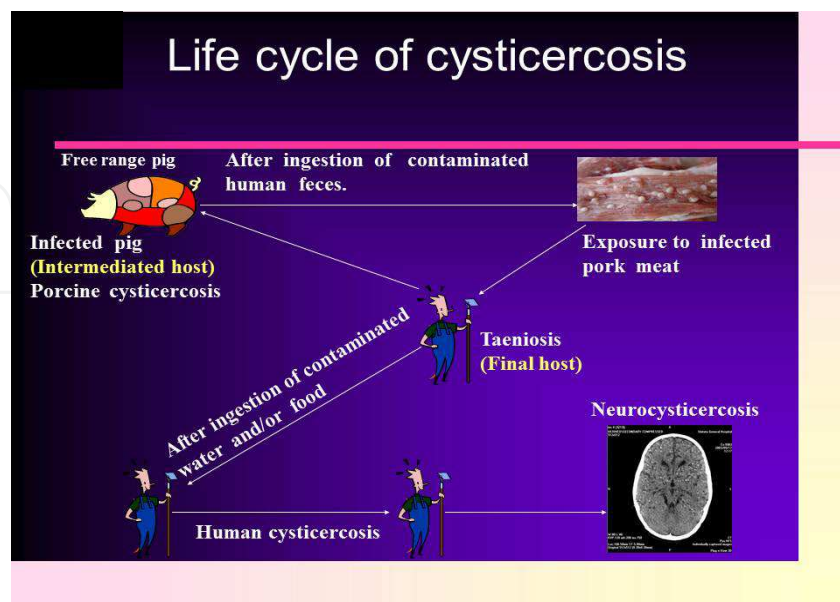
Fig. 3. Shows a masseter muscle from infected pig containing numerous cysticerci. Photo taken by Prof. A Lee (CWGESA).

Seems to be that measly pork meat has been described long ago according to this sentence found in ancient documents:

In 384-323 BC, Aristotle said:

When only a few measles are found the meat is sweet, but when numerous, the meat becomes watery and unpalatable."

Eggs develop into larval cysts causing human and porcine cysticercosis. Risk factors for taeniosis include the consumption of undercooked infected pork meat and inadequate meat inspection. Risk factors of cysticercosis include free-range pig farming, poor sanitation, close contact of humans and pigs and inadequate hygiene of food handlers. (See graphic 1)



Graphic 1. Shows the life cycle of *T Solium* cysticercosis and the path toward to NC. Graphic modified from by Prof. Carabin. (CWGESA)

Cysticercosis is thus strongly associated with poverty and other socio-economic-cultural problems (Del Rio & Foyaca-Sibat, 2005, 2005a, 2007, 20008; Foyaca-Sibat & Del Rio, 2004, 2005, 2005a). In both humans and pigs, cysts migrate mostly to the subcutaneous tissue, skeletal muscle, the eye, and the central nervous system (CNS). Currently, NC is not only the major cause of acquired epilepsy in many developing countries, but is also of growing concern in northern/western countries due to globalization and immigration of infected people as before-cited.

In South Africa, epilepsy secondary to NC is quite common in ECP particularly in the poor, former black homeland, rural areas of the former Transkei, where pigs are allowed to roam freely and sanitation facilities are inadequate or nonexistent. Pig keeping and pork consumption have increased significantly during the past decade especially in rural smallholder communities, primarily due to the lack of grazing land for ruminants and the recognition of farmers of a quicker and more impressive return on their investment from raising pigs contact of humans and pigs and inadequate hygiene of food handlers.

Consumption of uninspected pork meat is undoubtedly a major source of human taeniasis. The transmission of *T. solium* to pigs, the essential partner in the pig-man-pig cycle, requires that pigs have access to human feces and that people consume improperly cooked pork.

The major risk factors related to transmission of eggs to pigs can be summarized as follows:

Extensive or free-range pig rearing
Outdoor human defecation near or in pig rearing areas
Use of pigs to scavenge and eat human feces (“sanitary policeman”)
Deliberate use of human feces as pig feed
Connection of pig pens to human latrines (“pig sty privies”);
Use of sewage effluent, sludge or “night soil” to irrigate and/or fertilize pig pastures and food crops
Involvement of humans’ carriers in pig rearing and care.

The diagnostic assessment for NC was proposed by Del Brutto et al., (2001), and we used an abbreviated set of these criteria for the definition of NC in our studies.

Absolute criteria include:

cystic lesions showing the scolex on CT or MRI (See figure 4)
visualization of <i>T solium</i> on fundoscopy
demonstration of <i>T solium</i> from biopsied specimens

Other criteria are:

Major criteria:

cystic lesions without scolex, enhancing lesions
typical parenchyma brain calcifications
positive serum Ag-ELISA for cysticercosis

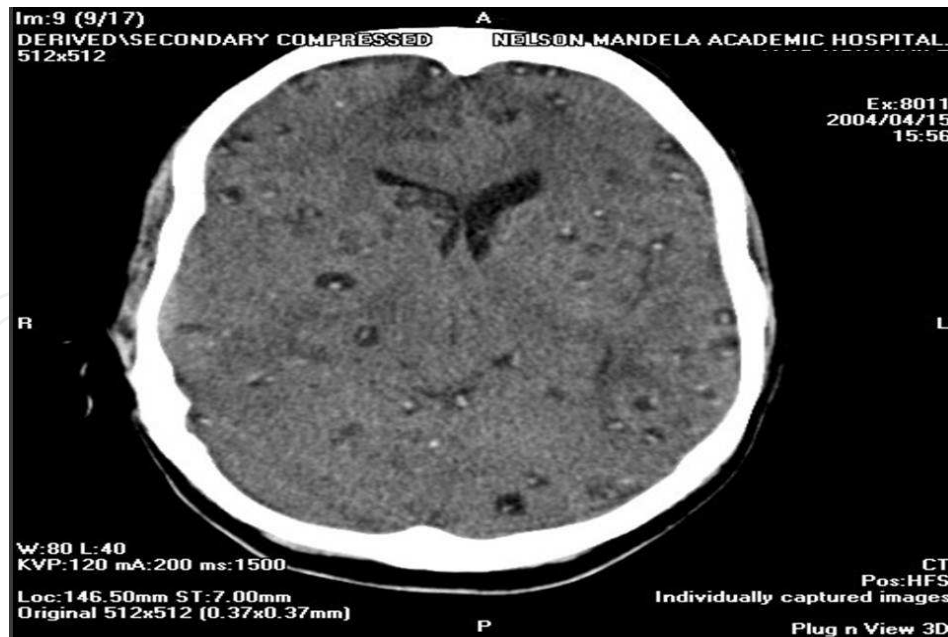


Fig. 4. CT scan of the brain showing multiple active cystic lesions and their scolex inside. Patient presenting tonic-clonic generalize and recurrent frontal lobe seizures.

Minor criteria:

lesions compatible with NC on neuroimaging studies
clinical manifestations of NC
cysticercosis outside the CNS

Epidemiological criteria:

evidence of household contact with peoples with cysticercosis
residence in a cysticercosis endemic area
visiting an endemic area for cysticercosis

For the present study, definite NC will be defined as: 1 absolute criteria or 2 major criteria or 1 major, 2 minor and 1 epidemiologic criterion; probable NC as: 1 major and 2 minor criteria or 1 major, 1 minor and 1 epidemiologic criterion or three minor and one epidemiologic criterion; and possible NC as: 1 major criteria or 2 minor criteria or 1 minor and 1 epidemiologic criterion.

The pilot study conducted by us at the Nelson Mandela Academic Hospital consisted of asking 57 epilepsy patients with confirmed NC, 52 epileptic patients without NC and 61 patients from the dermatology and ophthalmology clinics to answer a questionnaire interview about epilepsy and pig raising and management. A very preliminary analysis suggests that, using dermatology and ophthalmology clinic patients as the reference group, the POR of owning pigs and having NC was 6.8 (95% CI: 2.1-21.7) and the POR for consuming pork compared to never consume pork and having NC was 2.1 (0.7-6.2). Using the epilepsy patients without NC as the reference group, the POR of consuming pork in those with NC was 14.2 (5.1-39.5) and of owning pigs was 17.5 (5.4-56.2). Why the association between owning pigs and NC was stronger when the epilepsy patients were

used as a reference group needs further investigation, but it is possible that the NC and 2the non-epilepsy groups came from rural areas whereas the epilepsy non-NC group came from more urban areas with less exposure to infected pigs. Further analyses will determine whether these results are confounded by the age of the patients or where they live (i.e. Persons who only had epilepsy may be more likely to live in more urbanized areas). We also participated in the pilot study conducted at the St-Elisabeth hospital from ECP in SA. We studied 433 consecutive patients consulting the outpatient clinic for suspected new-onset seizures or existing epilepsy cases. (Foyaca-Sibat et al., 2009)

Of these, 281 were diagnosed as recurrent focal or generalized motor seizures due to secondary epilepsy. Each consenting participant was administered the questionnaire and asked to provide a blood sample for a serological analysis of antibodies to and antigens of the larval stage of *T. solium*. Additionally, each week for consenting, randomly selected patients with the confirmed diagnosis of seizures disorder were transported to Mthatha for a CT scan of the brain and EEG. Among these 281 patients, the prevalence of seropositivity of antibodies to the larval stage of *T. solium* was 33% (95% CI: 27%-38%) in the 273 tested. Serological antigens were available for 189 patients with confirmed seizures or epilepsy. In this group the prevalence of seropositivity to antigens to *T. solium* was 8% (95%CI: 4.5%-13%). Modified from the original one done by Prof. Carabin. A total of 92 patients with recurrent seizures and who also completed a questionnaire were referred to Mthatha for a CT-scan. Of these, 34 (37.0%, 95%CI: 27.1%-47.7%) had a definite diagnosis of NC, 14 of whom had active lesions visible on CT, 39 (42%) had no CT abnormality, and 19 (21%) had other, undefined non-NC calcifications. The age of the NC cases ranged from 5 to 67 years old whereas the epilepsy cases ranged from 5 to 76 years old. Antibody ELISA results were available for 33 of the 34 patients classified as probable NC and for all 39 without NC. The predictive value of a positive antibody test in identifying NC in persons with epilepsy was 60% (95% CI: 41%-77%). Serological results for antigen ELISA were available for 23 confirmed NC cases and 22 non-NC cases. The predictive value of a positive antigen test in identifying NC in persons with epilepsy was 67% (95% CI: 22%-96%). Thus, it is clear that serology alone cannot be used to diagnose NC in this population. HIV status was available from 50 patients with epilepsy. Among the 47 patients with antibody ELISA results available, the antibody seroprevalence of *T. solium* was 30.0% among HIV positive patients and 48.1% among HIV negative patients. Interestingly, among the 33 patients with antigen ELISA results, the antigen seroprevalence of *T. solium* was 16.7% among the HIV positive patients but only 9.5% among the HIV negative patients. Even though these results are based on a very small sample, it does suggest that HIV patients may be less able to mount a detectable antibody response to cysticercosis but might be more likely to be infected with active cysts. A total of 22 of these patients (13 HIV negative and 9 HIV positive) were referred for a CT-scan. Of these, five HIV negative and seven HIV positive patients had CT evidence of NC with two HIV negative and five HIV positive patients harboring active cysts. These very preliminary and imprecise results do suggest that there may be an association between NC and HIV infection. (Foyaca-Sibat et al., 2009)

2. Other types of epilepsy secondary to neurocysticercosis

2.1 Occipital lobe epilepsy secondary to neurocysticercosis

In our series patients presenting occipital lobe epilepsy usually is reporting

Structured visual hallucinations and moving colored shapes
Flashes light and transitory cortical blindness
Forced blinking and eyelid flutter follow by horizontal gaze deviation.

Calcified NC with or without perilesional edema is the most common cause. This presentation is uncommon despite it has been underestimated importantly. It can be associated to insula epilepsy or other types of epilepsy mainly in multiple calcified NC. Seems to be that measly pork meat has been described long ago according to this sentence. The medication of choice is carbamazepine.

Menon (2007) reported two young patients with symptomatic occipital lobe epilepsy due to discrete lesions of cysticercosis were misdiagnosed and treated for 2 years as migraine with visual aura. The patients suffered from frequent visual seizures often followed by migraine-like headache. Seizures manifested with colored and mainly circular elementary visual hallucinations of up to 1 minute duration. Headache, often severe and of long duration, was frequently associated with nausea, photophobia, and phonophobia. Both patients became seizure-free with appropriate treatment of the underlying disease and epileptic seizures.

2.2 Frontal lobe epilepsy secondary to neurocysticercosis

Clinical features of epileptic seizures may help to identify the specific frontal region of onset. (So, 1998; Kotagal & Arunkumar, 1998) as follow:

<i>Dominant hemisphere involvement</i> = Prominent speech disturbances
<i>Supplementary motor area</i> = Unilateral or asymmetric bilateral tonic posturing and facial grimacing, vocalization, or speech arrest; somatosensory aura; and complex automatisms such as kicking, laughing, or pelvic thrusting
<i>Primary motor cortex</i> = focal simple motor seizures with clonic or myoclonic movements
<i>Medial frontal, cingulate gyrus, orbitofrontal, or frontopolar regions</i> =Complex behavioural events (motor agitation and gestural automatisms) ; viscerosensory symptoms and strong emotional feelings; pelvic thrusting, pedalling, or thrashing, vocalizations, laughter, or crying.
<i>Dorsolateral cortex</i> =- Tonic posturing or clonic movements often associated with either contralateral head and eye deviation, or less commonly, ipsilateral head turn
<i>Operculum</i> = Swallowing, salivation, mastication, epigastric aura, fear, and speech arrest often associated with clonic facial movements and gustatory hallucinations.

This modality of seizures often bizarre and diagnosed incorrectly as psychogenic and can be associated to insular seizures. Despite calcified NC is the commonest cause no always locations of the lesions cause same clinical manifestations and quite often some lesions remain silent for years.

2.2.1 Nocturnal frontal lobe epilepsy

Patients presenting nocturnal occipital lobe epilepsy (NFLE) usually report

Seizure clusters occurring only during sleep
The history of similar events with other family members (Autosomal dominant)
The frenetic or agitated appearance of onset and normal intelligent
Dystonic posturing, jerking, bending, and rocking; difficult to distinguish from parasomnias

With nocturnal frontal lobe epilepsy, seizures begin shortly after falling asleep or in the early hours before awakening with a gasp, grunt, hums, moan or word, and are followed by sudden thrashing movements. Patients remain conscious but can neither control the movements nor speak. Thrashing can be vigorous enough to throw the patient out of bed, which can result in possible injury. Nocturnal frontal lobe epilepsy is typically treated with carbamazepine and, in some cases, surgery. We did not identify this type of seizures in our series. If there is evidence of NC on imagenology then a diagnosis of NFLE is ruled out.

2.3 Parietal lobe epilepsy

Parietal lobe epilepsy is the least common of syndromes defined by the area of brain affected. Parietal seizures spread rapidly, producing a range of symptoms that are also seen with other syndromes. A few signs are typical but appear in less than half of children who have this syndrome. Among the symptoms are:

Tingling, pricking or crawling sensations upon the skin
The feeling of burning, itching or pain
Pain occurs in the extremities and sometimes in the abdomen

Patients can present an acute confusional state (delirium) and the commonest affected parts of the body are: upper limbs and face. Partial seizures are divided into two major categories, simple and complex. Simple partial seizures occur in full consciousness; complex partial seizures occur with impaired awareness that ranges from slight to complete unconsciousness. (Epileptic Foundation)

2.4 Mesial temporal lobe epilepsy

Seizures often begin with auras or conscious feelings of a rising sensation from the stomach and of fear
One of the sensory perceptions may also be triggered
Impaired awareness follows, typically with staring and movements of the lips, tongue or jaw
Fumbling, picking or gesturing may also occur

3. Insular lobe

Remembering the lost island of Atlantis, this lobe remains hidden and lies submerged beneath the parietal, frontal, and temporal opercular cortices, buried under a tangled web of middle cerebral artery branches. The insula is not visible from the surface of the brain, it's the best protected region of the whole cerebral cortex, and the poorest studied region all over the brain; IL represents a remarkable challenge for further researchers among new generations of neurologists, neurophysiologists, neuroimmunologists, and neuropathologist among others. Some functions of the right insular lobe are a little bit known such as its role in taste perception its intensity and recognition for the ipsilateral tongue (rostradorsal insula) and some functions of the left insular cortex for the intensity of the stimulus ipsilateral to the tongue and taste recognition bilaterally, gustatory mechanism, movements

of the mouth, and oropharyngeal swallowing (anterior insular) are not well known neither, and almost nothing has been demonstrated about the role of the insular lobe over the amygdala complex and emotional behavior. The human IL is also considered as paralimbic cortex, because of its connections with limbic and sensorimotor cortices, the IL is believed to play a role in affective and attention aspects of human behavior as well. Paralimbic insular regions have functional specialization for behaviors requiring integration between extra personal stimuli and the internal milieu. Based on these connections, one might expect that lesions of the insular cortex may result in disorders of neglect (Foyaca-Sibat & Ibañez-Valdés, 2006).

3.1 Insula lobe epilepsy

3.1.1 Background

Insular lobe epilepsy (ILE) and insular lobe seizures (ILS) are still not included in the current classification for epileptic seizures, epilepsy or epileptic syndromes belong to "The International League Against Epilepsy" therefore most of neurologists, epileptologists, clinician pediatrician, and general practitioner do not include this entity in their list of differential diagnosis in patients presenting "aberrant" types of temporal lobe epilepsy (TLE), "stereotype" simple focal seizures and others. Insular seizures may mimic temporal, parietal or frontal lobe seizures and may coexist with seizures from other lobes.

The electroencephalographic (EEG) studies of the insula lobe (IL) are not confident because it is the only cortical part of the brain that is not accessible at the surface of the cerebral hemisphere, because it is totally covered by the fronto-parietal and temporal opercula, therefore accuracy of EEG made by surface electrode is uncertain.

The insula is one of the five cerebral lobes and its cortex is situated deep within each hemisphere. It is overlaid by the frontal and temporal neocortex and this explains how difficult it should be to get a reliable EEG sampling from the insular cortex and to define an "insular epileptic syndrome" as has been done with temporal lobe epilepsy. Adequate sampling from the insula can only be obtained by depth or subdural electrodes' implantation or acute intraoperative electrocorticography. Depth or subdural electrodes implantation of the insular faces some technical problems. There is substantial evidence that the insula is involved as a somesthetic area, including a major role in the process of nociceptive input. The role of the insula in some epileptic patients was recently investigated by means of depth electrode recordings made following Talairach's stereoelectroencephalography (SEEG) methodology. It appears that ictal signs associated with an insular discharge is very similar to those usually attributed to mesial temporal lobe seizures (Robles et al, 2009) others authors reported: sensation of laryngeal constriction and paresthesiae, often unpleasant, affecting large cutaneous territories, most often at the onset of a complex partial seizure (five of the six patients) as a common presentation [Isnard J, et al., 2004] while other said: the most common clinical feature associated with damage to the insula is the complex partial seizures with involvement of the visceral sensations (Duffau H, et al., 2002). Different authors reported ictal symptoms associated with insular discharges mainly made up of respiratory, viscerosensitive (chest or abdominal constriction), or oroalimentary (chewing or swallowing) manifestations. Unpleasant somatosensory manifestation always opposite the discharging side, are also frequent and they concluded that Ictal signs arising from the insula occur in full consciousness; these are always simple

partial seizures. Seizures arising from the temporal lobe always invade the insular region, but in approximately 10% of cases, the seizures originate in the insular cortex itself (Isnard, 2004; Guenot, 2008). In 2005, Isnard studied 50 patients using intrainsular electrodes and found that the clinical presentation of insular lobe seizures was a simple partial seizures occurring in full consciousness patient, beginning with a sensation of laryngeal constriction followed by paresthesiae that were often unpleasant affecting large cutaneous territories. These initial symptoms were eventually followed by dysarthric speech and/or elementary auditory hallucinations, and seizures often ended with focal dystonic postures. Four years later he studied 164 patients in whom 472 insular electrodes were implanted, he again found that clinical presentation of insular lobe seizures are that of simple partial seizures occurring in full consciousness, beginning with a sensation of laryngeal constriction followed by paresthesia that were often unpleasant on extensive cutaneous territories. These initial symptoms were eventually followed by dysarthric speech and/or elementary auditory hallucinations, and seizures often ended with focal dystonic postures. He was able to reproduce several of the spontaneous ictal symptoms in the six patients with insular seizures. (Isnard, 2009). Looking into other ways to check clinical features of IL due to focal lesions, we reviewed what happen in patients presenting NC on the IL.

According to the publications made in the last decade, very little is known about NC on the IL (Foyaca-Sibat & Ibañez-Valdés, 2006). It is important to highlight that it is a dangerous location of NC because apart from epilepsy other complications such as: autonomic dysfunction (Oppenheimer et al., 2001), neurogenic heart (Tamayo & Hachinski, 2003), electrocardiographic changes (Blumhardt et al., 1986) and sudden unexpected death in epilepsy [SUDEP] (Leestma, 1984; Mc Guban, 1999; Langan Y, 2000) can occur

The main aim of our study was to identify ictal manifestations in patients presenting focal lesions (NC) on the IL proved by imagenology. To our knowledge, it is the first time that results from ILE secondary to focal NC in a case-control study are reported in the medical literature.

3.2 Material and method

3.2.1 Participants and study area

This is an epidemiological descriptive study of patients diagnosed as NC from Umtata General Hospital and Nelson Mandela Academic Hospital (South Africa) from January 2004 to January 2010 who were selected for a case control study in the project Neurocysticercosis protocol. (Database, n=3015). All selected patients were included in group A or group B.

3.2.2 Inclusion criteria:

Group A: fulfilled the following selected criteria:

1.-Positive serology ELISA test for cysticercosis
2.-CT/MRI images of the brain with intravenous contrast or gadolinium enhancement, consistent with definitive evidence of active and calcified NC on the insula lobe suitable to evaluate: ictal manifestations.
3.-Positive serology ELISA test for cysticercosis
4.-ELISA test for HIV/AIDS

Group B:

1.-NC on the temporal lobe and similar age group
2.-CT/MRI images of the brain with intravenous contrast or gadolinium enhancement, consistent with definitive evidence of active and calcified NCC on the temporal lobe suitable to evaluate: ictal manifestation.
3.-Positive serology ELISA test for cysticercosis
4.-ELISA test for HIV/AIDS

Demographic and clinical data were obtained through interviews with the patients and their relatives.

The differences between groups A and B were evaluated for statistical significance with the use of Statistical Package for the Social Sciences version 16.0 for windows (SPSS Inc., Chicago, Ill)

All patients received 800 mg of albendazole and 40 mg of prednisone per os daily for a week as part of treatment for NC and 200mg of carbamazepine orally every 8 hour to control epileptic seizures.

All images were acquired on the same CT scan and MR images using a three-dimensional T1-fast field echo sequence providing an isotropic voxel size of 1 mm³. Images underwent correction for non uniform intensity and were linearly registered into a standardized stereotaxic space. The interval between the first and last scan was 31 ± 21 months (range = 10 to 52).

3.2.3 Exclusion criteria

Epilepsy due to other causes
Terminal diseases, serious psychological illnesses, active addictions to psychoactive substances
Patients younger than 13 years old, pregnant ladies, patients on HAART
No written consent.

3.2.4 Withdrawal criteria

Any event that may lead to a situation that discourages the intervention or that may prevent communication with the healthcare professional.
--

3.2.5 Ethical aspects

Written informed consent was obtained in the first assessment of eligible patients for participation. All patients received information on the study's objective and procedures in addition to ethical considerations, including and the participant's right to intimacy, anonymity, confidentiality, withdrawal, and information. Both investigators completed CITI training-course on the Protection of Human Research and sworn to the Hippocratic Oath and committed to respecting the norms of good clinical practice, as well as the requirements of the Helsinki Declaration.

Methods for patient selection and information processing was accepted by clinical governance at Mthatha General Complex, and approval From the University of Transkei, and Walter Sisulu University IRB and the respective Ethical Committees (UNITRA:0018/05, and WSU:0068/009) were obtained.

3.3 Results and comments

The total number of patients with ILE due to unilateral calcified and active NC on the IL in our database is 21 and its prevalence is 0.69%. Four patients (19%) from this group presented an associated ischemic stroke due to infectious vasculitis. Three of them were HIV-positive (See figure 5)

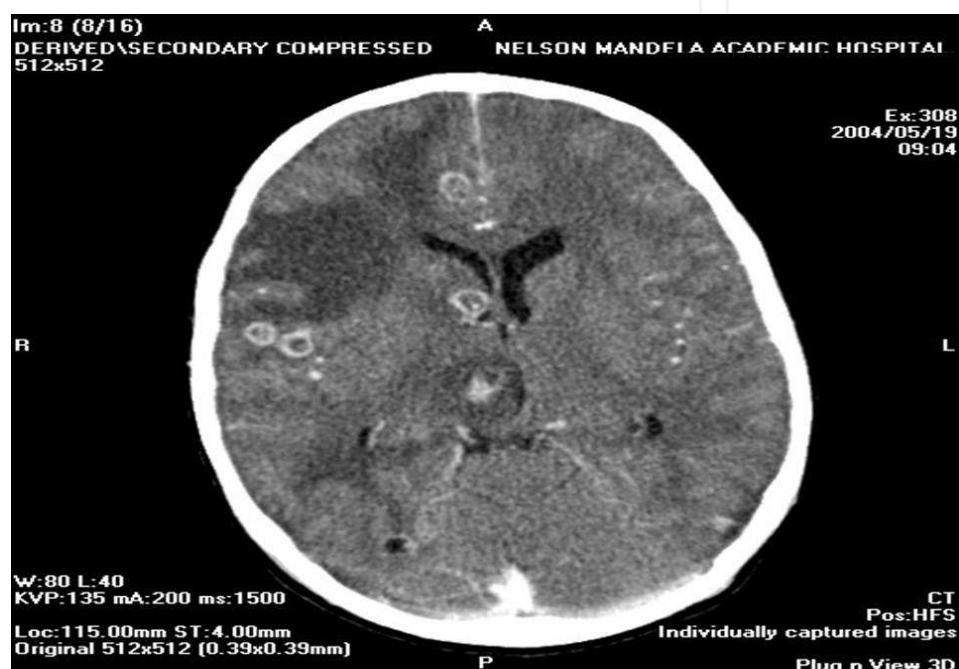

Fig. 5. CT scan of the brain shows calcified and active NC, some ring enhancing lesion is seen. Hypodensity lesion secondary to ischemic stroke on the right frontal and insular lobes with partial compression of the right lateral ventricle is also observed.

Demographic features are summarized in Table 1 and no remarkable differences among both groups including HIV status were found.

Groups	Age	Gender (%)		HIV (%)		
	Mean (Std)	Male	Female	+	-	Unknown
A (n=21)	32.2 (16.9)	49.1	50.9	13.9	31.2	54.9
B (n=22)	31.9 (15.3)	47.9	52.1	15.7	28.8	55.6

Table 1. Demographics characteristics

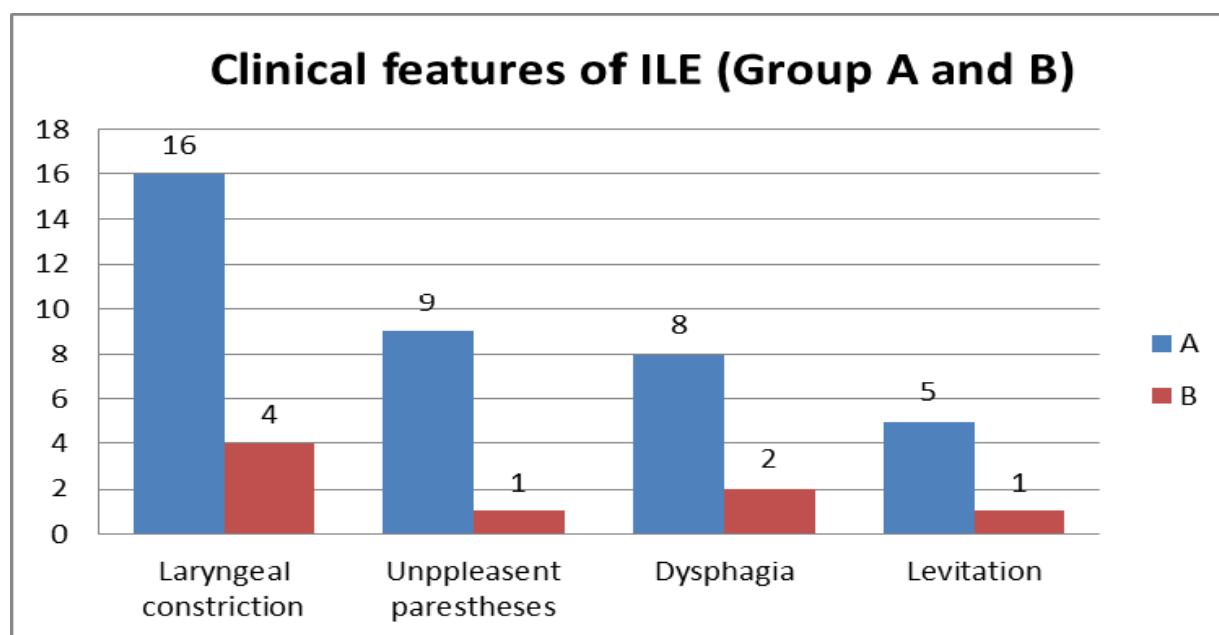
Commonest ictal manifestations with statistical significance ($p > 0.0001$) were: sensation of laryngeal constriction (n=16) and unpleasant paresthesia (n=9) in fully conscious patients. See Table 2 and Graphic 1.

Less common problems without statistical value were: dysphagia, levitation and mild chest oppression.

Group	A	B	Fisher test χ^2	OR (CI=95.0 %)
Laryngeal constriction	76% (n=16)	18.4% (n=3)	$P < 0.0001$ 21.390	20.26 (Wolf=4.18)
Unpleasant paresthesia	42.8% (n=9)	4.54% (n=1)	$P < 0.0001$ 8.836	15.75 (Wolf=1.77)
Dysphagia	38.09% (n=8)	9.09% (n=2)	$P = 0.0281$ 5.064	6.15 (Wolf=1.12)
Levitation	23.80% (n=5)	4.54% (n=1)	$P = 0.0918$ 3.321	6.25 (Wolf=0.61)

Table 2. Clinical features commonest found

Patients with NC on the temporal lobe presented TLE or partial secondary to generalized motor seizures except one who complained of a sensation of laryngeal constriction, perioral parestheses and sense of levitation and later loss of consciousness and tonic-clonic secondary generalized seizures.



Source: Table 2

Graphic 1. Clinical features of insula lobe epilepsy

We tried to correlate the location of the lesion and ictal manifestation considering NC lesion small enough to produce non additional damage on surrounding tissue avoiding situations reported by Roper et al. in 1993 and Duffau in 2003. They described insular epilepsy in patients presenting seizures involved visceral sensory hallucinations followed by motor automatism and motor seizures with somatic sensory hallucinations and then produced visceral motor effects. Unfortunately, they studied patients with mass lesion (low-grade astrocytoma) big enough to involve the temporal lobe region. In our series, lesions of NC active or calcified measured less than 15 mm in both groups to assure that no surrounding tissue was affected. Fortunately, we also had previous information about insular NC from a

pilot study made five years back (Foyaca-Sibat & Ibañez-Valdés, 2006) and based on those results we refined our selecting criteria. Our prevalence of ILE is low because it is an uncommon epileptic disorder.

Previous studies based on video ictal recordings, and direct electric insular stimulation of the insular cortex for presurgical evaluation of temporal lobe epilepsy described clinical features of ictal manifestation on IL eventually followed by dysarthric speech and focal motor convulsive symptoms no present in our series. Other clinical manifestation in our series including speech problems, neurogenic heart and sudden unexpected death were not included for statistical analysis at this time because were not considered in our objectives.

Some patients became a little bit surprised when we asked for some symptoms that they did not expressed before because these symptoms did not recall attention from patients and relatives which may contribute to an underestimate prevalence of this type of seizures mainly in patients presenting it sporadically . A fully conscious patient with laryngeal discomfort, dyspnea, unpleasant perioral or somatic paresthesia, and dysarthric speech, followed by somatomotor symptoms, implies an insular onset and a good respond to antiepileptic treatment can help to confirm it.

Antiparasitic treatment for NC at the IL should be prescribed with caution because the risk of developing complications such as: the neurogenic heart and/or SUDEP. One patient from this series died because subendocardial hemorrhage probable due to active and calcified NC on the right insula cortex documented by postmortem examination (See figure 6)

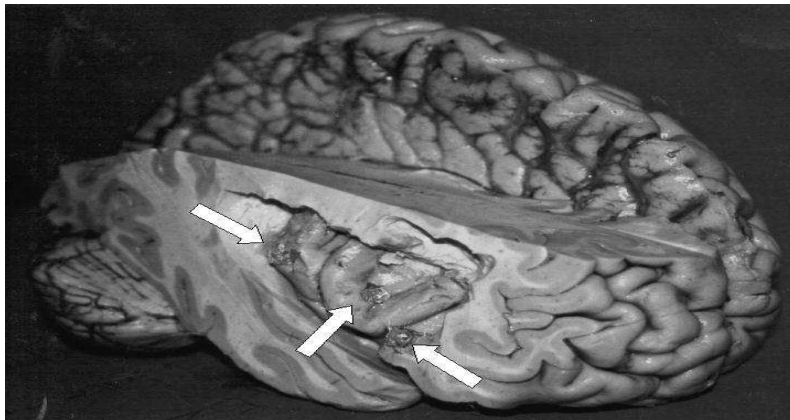


Fig. 6. Lateral view of the right insular lobe fixed in formalin. One cyst with the scolex inside (in vesicular stage) on anterior insula is seen, another cyst without scolex with turbid fluid-filled oval cysts and local inflammatory reaction on the middle-anterior (agranular) insula is observed. Left insula was normal and no other cysts were found all over the brain. Cause of death: SUDEP/Neurogenic heart (subendocardial hemorrhage)

3.3.1 Sudden unexpected death in epilepsy secondary to neurocysticercosis

Although largely neglected in earlier literature, sudden unexpected death in epilepsy (SUDEP) is the most important epilepsy-related mode of death, and is the leading cause of death in people with chronic uncontrolled epilepsy. Research during the past two to three decades has shown that incidence varies substantially depending on the epilepsy population studied, ranging from 0–09 per 1000 patients-years in newly diagnosed patients to 9 per 1000 patient-years in candidates for epilepsy surgery. (Tomson et al., 2008)

By definition, the cause of death in SUDEP is currently unknown, but it is very probable that cardiac arrhythmia during and between seizures plays a potential role. It has been suggested on postmortem studies and interictal cardiac abnormalities observed (Falconer & Rajs, 1976; Leestma, 1989; Ryvlin et al., 2006; Stollberger & Finsterer, 2004). Several suggestions have been made concerning the mechanisms behind SUDEP, most involving speculations on the possible role of autonomic effects such as cardiorespiratory disturbances. Clinical and experimental studies have shown that physical activity can decrease seizure frequency, as well as lead to improved cardiovascular and psychological health in patients with epilepsy (Arida et al., 2007). Information concerning risk factors for SUDEP is conflicting, but potential risk factors include: cold temperatures (Scorza et al., 2007), certain seizure types (Foyaca-Sibat & Ibañez-Valdés, 2006; Kloster & Engelskojón, 1999), early adulthood (Leestma, 1997) early onset of epilepsy (Nilsson, 1999), long duration of epilepsy (Walczak et al., 2001), uncontrolled TLE (Walczak et al., 2001; Speling et al., 1999), high seizure frequency (Lagan & Nashef, 2005), and higher numbers of AED (Nilsson et al., 2001) and. Additionally, potential pathomechanisms for SUDEP are unknown, but it is very probable that cardiac arrhythmias during and between seizures, electrolyte disturbances, arrhythmogenic drugs or transmission of epileptic activity to the heart via the autonomic nervous system potentially play a role (Stollberger & Finsterer, 2004). An increasing number of reports about SUDEP secondary to NC are seen on the medical literature gradually (Holmes, 2010) more details about SUDEP can be found in the other chapters of this book.

Mortality due to epilepsy is a significant concern. Patients with epilepsy have a mortality rate significantly higher compared with the general population. The standardized mortality rate (SMR) is shown to be 1.6-9.3 times higher in this group (Nouri, 2011). Based on our observations we consider that ILE can be differentiated from TLE if patients remain fully conscious during the attack. When epileptic activity spread from IL to temporal lobe or vice versa then clinical differentiation can be almost impossible to perform.

If the above-cited features are not keeping in mind, diagnosis of ILE never going to be made and cardiac complications or SUDEP may happen.

We have hypothesized that NC on the temporal lobe can cause ictal manifestations which can be spread to the IL leading to a combination of TLE and ILE but most symptoms from IL are masked by those from TLE even before patients become unconscious. Further investigation should be made to reach final conclusions. In our experience, this sequence of ictal symptoms: laryngeal constriction, perioral paresthesia, dysphagia, and sense of levitation look reliable enough to characterize insular lobe epileptic seizures secondary to NC. To our knowledge, it is the first time that results from ILE secondary to focal NC in a case-control studies are reported.

4. Acknowledgment

We like to express our gratitude to all veterinarian doctors working in this field particularly: Professors Rosina Tammi Krecek, Albert Lee Willingham, Linda Cowan, Samson Mukaratiwua and other members of the Cysticercosis Working Group for Eastern and Southern Africa (CWGESA) for their dedications and commitment.

Special thanks to Professor Helen Carabin from the Department of Biostatistics and Epidemiology College of Public Health University of Oklahoma Health Sciences Center for her invaluable enthusiasm, persistence, and leadership in our research team.

We want to thank to all radiologists and radiographers from Nelson Mandela Academic Hospital and Inkhosi Albert Luthuli Central Hospital in South Africa for their contribution to this study.

Special thanks are due to the Cuban Ministry of Health, the Institute of Tropical Medicine Pedro Kouri, authorities of Faculty of Health Sciences and Directorate: Research Development from Walter Sisulu University and Nelson Mandela Academic Hospital for their unconditional support.

We also acknowledge financial support from, Directorate of Research Development from Walter Sisulu University in South Africa, and South African Medical Research Council.

The founder had no role in study design, data collection and analysis, decision to publish, or the preparation of manuscript.

Finally, we wish to declare our eternal and deepest gratitude to our family, relatives, and colleagues for their unconditional and permanent support.

Finally, we wish to declare our eternal, deepest love and gratitude to Lorna María Foyaca García, Thabo Humberto Jorge Foyaca Ibañez and Fátima Susana Adolfinia Foyaca Ibañez, because without their love and unconditional support this chapter would not have been written.

5. References


- Arida RM, Cavalheiro EA, Silva AC, Colugnati DB, Pansani AP, Albuquerque M, Scorza FA. Sudden unexpected death in epilepsy: sudden death risk decreased by physical activity. *Einstein*. 2007; 5(3):281-286
- Carabin H, Krecek RC, Cowan LD, Michael L, Foyaca-Sibat H, Nash T, Willingham AL "Estimation of the monetary burden of *Taenia solium* cysticercosis in the Eastern Cape, South Africa". *Trop. Med. Int. Health.*(ISSN: 1360-2276). 2006;11: 906-916.
- Del Rio A, Foyaca-Sibat H, Ibañez-Valdés LdeF: Epidemiological Survey About Socio-Economic Characteristic Of Mpindweni Location, South Africa . *The Internet Journal of Neurology*. 2005 Volume 4 Number 2
http://www.ispub.com/journal/the_internet_journal_of_neurology/volume_4_number_2_27/article/epidemiological_survey_about_socio_economic_characteristic_of_mpindweni_location_south_africa.html
- Del Rio-Romero AH, Foyaca-Sibat H, Ibañez-Valdés LdeF, Vega-Novoa E. Prevalence Of Epilepsy And General Knowledge About Neurocysticercosis At Nkalukeni Village, South Africa *The Internet Journal of Neurology*.2005 3(2)
http://www.ispub.com/journal/the_internet_journal_of_neurology/volume_3_number_2_31/article/prevalence_of_epilepsy_and_general_knowledge_about_neurocysticercosis_at_nkalukeni_village_south_africa.html
- Del Rio-Romero A, Foyaca-Sibat H, Ibañez-Valdés LdeF: :Neuroepidemiological Survey For Epilepsy, Knowledge About Epilepsy, Neurocysticercosis And HIV/Aids At The Makaula Village In South Africa". *The Internet Journal of Neurology.*(ISSN: 1531-295X). 2007;7(3):41-49
http://www.ispub.com/journal/the_internet_journal_of_neurology/volume_7_number_2_5/article/neuroepidemiological_survey_for_epilepsy_knowledge_about_epilepsy_neurocysticercosis_and_hiv_aids_at_the_makaula_village_in_south_africa.html
- Del Rio-Romero AI, Foyaca-Sibat H, Ibañez-Valdés LdeF: "Neuroepidemiology Findings As Contributors For Epilepsy Due To Neurocysticercosis At Mngceleni Location, South Africa". *The Internet Journal of Neurology.*(ISSN: 1531-295X). 2008;9(1):33-40

- http://www.ispub.com/journal/the_internet_journal_of_neurology/volume_9_number_1_6/article/neuroepidemiology_findings_as_contributors_for_epilepsy_due_to_neurocysticercosis_at_mngceleni_location_south_africa.html
- Dobesberger J, Ortler M, Unterberger I, Walser G, Falkenstetter T, Bodner T, Benke T, Bale R, Fiegele T, Donnemiller E, Gotwald T, Trinkka E. Successful surgical treatment of insular epilepsy with nocturnal hypermotor seizures. *Epilepsia*, 49(1):159-162, 2008
- Duffau H, Capelle L, Lopes M, Bitar A, Sichez AP, van Effenterre R. Medically intractable epilepsy from insular low-grade gliomas: improvement after an extended lesionectomy *Acta Neurochir*. 2002;144(6):563-573
- Epileptic Foundation. Full free article available at the URL:
<http://www.epilepsyfoundation.org/infants/partialpilepsy.html> (last review on Mach 09, 2011)
- Falconer B, Rajs J. Post-mortem findings of cardiac lesions in epileptics: a preliminary report. *Forensic Sci*. 1976;8:63-71.
- Foyaca-Sibat H, Ibañez-Valdés LdeF. "Clinical trial of praziquantel and prednisone in rural patients with neurocysticercosis presenting recurrent epileptic attacks" *The Internet Journal of Neurology* 2002;2):41-50
http://www.ispub.com/journal/the_internet_journal_of_neurology/volume_1_number_2_39/article/clinical_trial_of_praziquantel_and_prednisone_in_rural_patients_with_neurocysticercosis_presenting_with_recurrent_epileptic_attacks.html
- Foyaca-Sibat H, "Tapeworm and the brain" *Journal of Sciences of Africa* 2002;1:5-12
<http://www.scienceofafrica.co.za/2002/june.worn.htm>
- Foyaca-Sibat H, Ibañez-Valdés LdeF, Awotedu A, Fernandez-Mena C, "Neurocysticercosis in the former Transkei" 7th Internet World Congress for Biomedical Sciences. Inabis2002 Conference Proceeding ISBN 2002-WX54-4689
<http://www.inabis2002.org/poster-congress/area-01/01011/010117.pdf>
- Foyaca-Sibat H, Ibañez-Valdés LdeF. "Intraventricular neurocysticercosis in HIV patients. Should be approaching surgically?" II International Congress of Neurosurgery on Internet. 2003 Conference Proceeding
<http://www.neuroc.sld.cu/paper/TL-neurocys.htm>
- Foyaca-Sibat H, Ibañez-Valdés LdeF & A. A. Awotedu : Effect Of Prednisone On Guillain-Barré Syndrome In HIV Positive Patients . *The Internet Journal of Neurology*. 2003 Volume 2 Number 1
http://www.ispub.com/journal/the_internet_journal_of_neurology/volume_2_number_1_37/article/effect_of_prednisone_on_guillain_barre_syndrome_in_hiv_positive_patients.html
- Foyaca-Sibat H, Ibañez-Valdés LdeF "Enfermedad de Binswanger en pacientes con neurocysticercosis" III International Congress of Psychiatry on Internet. Conference Proceeding. <http://www.psiquiatria.com/interpsiquis2003/9638>
- Foyaca-Sibat H, Ibañez-Valdés LdeF "Neuro-Behçet syndrome treated with herbal medication" *Electron J Biomed* 2003;1:1-9
http://www.ispub.com/journal/the_internet_journal_of_neurology/volume_2_number_2_34/article/neuro_behcet_s_syndrome_a_case_report.html
- Foyaca-Sibat H, Ibañez-Valdés LdeF "Intraventricular neurocysticercosis in HIV patients" *The Internet Journal of Neurology* 2003;2(1):23-31
http://www.ispub.com/journal/the_internet_journal_of_neurology/volume_2_number_1_37/article/intraventricular_neurocysticercosis_in_hiv_positive_patients.html
- Foyaca-Sibat H, Ibañez-Valdés LdeF. "Pseudoseizures and Epilepsy in neurocysticercosis" *Electron J Biomed* 2003;2(2):20-29

- <http://www.uninet.edu/reb/2003/n2/2foyaca.html>
- Foyaca-Sibat H, Ibañez-Valdés LdeF. "Neurocysticercosis in HIV-positive patients" *The Internet Journal of Infectious Diseases* 2003;2(2):15-23
<http://www.ispub.com/ostia/index.php?xmlFilePath=journals/ijn/current.xml>
- Foyaca-Sibat H, Ibañez-Valdés LdeF. "Binswanger's disease and neurocysticercosis" *The Internet Journal of Neurology* 2003;2(1):11-21
http://www.ispub.com/journal/the_internet_journal_of_neurology/volume_2_number_1_37/article/binswanger_s_disease_and_neurocysticercosis.html
- Foyaca-Sibat H, Ibañez-Valdés LdeF. Vascular demential type binswager's disease in patients with active neurocysticercosis. *Electron Biomed / Electron J Biomed* 2003;1(1):32-42
<http://biomed.uninet.edu/2003/n1/foyaca.html>
- Foyaca-Sibat H, Ibañez-Valdés LdeF. "Pseudoseizures and Epilepsy in neurocysticercosis: some advices to Family Doctors" *The Internet Journal of Neurology* 2004;2(2):4-17
http://www.ispub.com/journal/the_internet_journal_of_neurology/volume_2_number_2_34/article/pseudoseizures_and_epilepsy_in_neurocysticercosis_some_advice_for_family_doctors.html
- Foyaca-Sibat H, Del Rio AR, Ibañez-Valdés LdeF, Vega-Novoa EC, Awotedu A. "Neuroepidemiological survey for Epilepsy and knowledge about neurocysticercosis at the Sidwadweni location, South Africa" *Electron J Biomed* 2004;2(1):40-48
<http://www.biomed.edu/2004/n1/foyaca.html>
- Foyaca-Sibat H, Del Rio-Romero AH, Ibañez-Valdés LdeF, Vega-Novoa E. Neuroepidemiological Survey For Epilepsy And Knowledge About Neurocysticercosis At the Ngqwala Location, South Africa. *The Internet Journal of Neurology* 2005 3(2)
http://www.ispub.com/journal/the_internet_journal_of_neurology/volume_3_number_2_31/article/neuroepidemiological_survey_for_epilepsy_and_knowledge_about_neurocysticercosis_at_ngqwala_location_south_africa.html
- Foyaca-Sibat H, Del Rio-Romero A, Ibañez-Valdés LdeF : Prevalence Of Epilepsy And General Knowledge About Neurocysticercosis At the Ngangelizwe Location, South Africa . *The Internet Journal of Neurology*. 2005 Volume 4 Number 1
http://www.ispub.com/journal/the_internet_journal_of_neurology/volume_4_number_1_30/article/prevalence_of_epilepsy_and_general_knowledge_about_neurocysticercosis_at_ngangelizwe_location_south_africa.html
- Foyaca-Sibat H, Ibañez-Valdés LdeF. Insular Neurocysticercosis: Our Finding and Review of the Medical Literature. *The Internet Journal of Neurology* 2006 vol 5 Number 2
http://www.ispub.com/journal/the_internet_journal_of_neurology/volume_5_number_2_19/article/insular_neurocysticercosis_our_findings_and_review_of_the_medical_literature.html
- Foyaca-Sibat H, Ibañez-Valdés LdeF : Occipital Lobe Syndrome Due To Giant Intraparenchymal Neurocysticercosis . *The Internet Journal of Neurology*. 2006 Volume 5 Number 2
http://www.ispub.com/journal/the_internet_journal_of_neurology/volume_5_number_2_19/article/occipital_lobe_syndrome_due_to_giant_intraparenchymal_neurocysticercosis.html
- Foyaca-Sibat H, RIA Del Rio: "Epilepsy, Neurocysticercosis and, Poverty at Mphumaze and Marhambeni Locations, in South Africa". *The Internet Journal of Neurology* (ISSN: 1531-295X). 2007;7(1):8-14

- http://www.ispub.com/journal/the_internet_journal_of_neurology/volume_7_number_1_7/article/epilepsy_neurocysticercosis_and_poverty_at_mphumaze_and_marhambeni_locations_in_south_africa.html
- Foyaca-Sibat H, Ibañez-Valdés LdeF: "Generalized Cysticercosis With Cardiac Involvement". The Internet Journal of Neurology.(ISSN: 1531-295X). 2007;7(2):6-11
http://www.ispub.com/journal/the_internet_journal_of_neurology/volume_7_number_2_5/article/generalized_cysticercosis_with_cardiac_involvement.html
- Foyaca-Sibat H, Ibañez-Valdés LdeF, Del Rio IA: "Prevalence of Epilepsy and General Knowledge about Neurocysticercosis at Ngangelizwe Location, South Africa". The Internet Journal of Neurology.(ISSN: 1531-295X). 2005; 4(1):23-37
http://www.ispub.com/journal/the_internet_journal_of_neurology/volume_4_number_1_30/article/prevalence_of_epilepsy_and_general_knowledge_about_neurocysticercosis_at_ngangelizwe_location_south_africa.html
- Foyaca-Sibat H, Ibañez-Valdés LdeF: "Co-morbidity of Spinal Cord Neurocysticercosis And Tuberculosis In A HIV-Positive Patient". The Internet Journal of Neurology. (ISSN: 1531-295X). 2007;7(3):5-10
http://www.ispub.com/journal/the_internet_journal_of_neurology/volume_7_number_2_5/article/comorbidity_of_spinal_cord_neurocysticercosis_and_tuberculosis_in_a_hiv_positive_patient.html
- Foyaca-Sibat H, Del Rio- Romero AI: "Prevalence Of Epilepsy In An Endemic Area For Neurocysticercosis In South Africa". The Internet Journal of Neurology.(ISSN: 1531-295X). 2008;9(1):8-18
http://www.ispub.com/journal/the_internet_journal_of_neurology/volume_9_number_1_6/article/prevalence_of_epilepsy_in_an_endemic_area_for_neurocysticercosis_in_south_africa.html
- Foyaca-Sibat H, Cowan LD, Carabin H, Serrano-Ocaña G, Krecek RC, Willingham A. "Accuracy of the serological exam for the diagnosis of neurocysticercosis in outpatients with epilepsy, Eastern Cape Province, South Africa" *PLOS Neglected Trop.Dis.* Dec.2009;3(3):1-7
- Foyaca-Sibat H, Ibañez-Valdés LdeF & J. Moré-Rodríguez : Parasitic Zoonoses Of The Brain: Another Challenger?. The Internet Journal of Neurology. 2010 Volume 12 Number 2
http://www.ispub.com/journal/the_internet_journal_of_neurology/volume_12_number_2_4/article/parasitic-zoonoses-of-the-brain-another-challenger.html
- Geier S, Bancaud J, Talairach J, Bonis A, Szikla G, Enjelvin M. The seizures of frontal lobe epilepsy. A study of clinical manifestations. *Neurology*1997; 27:951-958.
- Guenot M, Isnard J. Epilepsy and insula. *Neurochirurgie*. 2008;54(3):374-378
- Holmes N, Iles L, Andrew D, Korman T Neurocysticercosis Causing Sudden Death. *Amer J Forensic Med & Pathology*. 2010;31(2):117-119
- Ibañez-Valdés LdeF & Foyaca-Sibat H. Refractory epilepsy in neurocysticercosis. The Internet Journal of Neurology. 2006;5(2):34-41
http://www.ispub.com/journal/the_internet_journal_of_neurology/volume_5_number_2_19/article/refractory_epilepsy_in_neurocysticercosis.html
- Ibañez-Valdés LdeF & Foyaca-Sibat H. "Neurogenic heart secondary to insular stroke and neurocysticercosis" *International Journal of Stroke* (ISSN 1747-4949). 2006;1(1):68.
- Isnard J, Guenot M, Sindou M, Mauquiere F. Clinical Manifestations of Insular Lobe Seizures: A Stereo-electroencephalographic Study. *Epilepsia*. 2004;45:1079-1090.
- Isnard J, Mauquiere F. The insula in partial epilepsy. *Rev Neurol (Paris)*. 2005;16(1):17-26
- Isnard J. Insular epilepsy: A model of cryptic epilepsy. The Lyon experience. *Rev Neurol (Paris)*. 2009;165(10):746-749

- Kloster R, Engelskjon T. Sudden unexpected death in epilepsy (SUDEP): a clinical perspective and a search for risk factors. *J Neurol Neurosurg Psychiatr.* 1999;67:439-44.
- Kotagal P, Arunkumar GS. Lateral frontal lobe seizures. *Epilepsia.* 1998;39(4):62-68
- Langan Y, Nashef L, Sander JW. Case-control study of SUDEP. *Neurology.* 2005;64:1131-1133.
- Leestma JE, Walczak T, Hughes JR, Kalelkar MB, Teas SS. A prospective study on sudden unexpected death in epilepsy. *Ann Neurol.* 1989;26:195-203.
- Leestma JE, Annegers JF, Brodie MJ, Brown S, Schraeder P, Siscovick D, Wannamaker BB, Tennis PS, Cierpial MA, Earl NL. Sudden unexplained death in epilepsy: observations from a large clinical development program. *Epilepsia.* 1997;38:47-55.
- Menon B. Symptomatic occipital epilepsy misdiagnosed as migraine. *Headache* 2007;47(2):287-289
- Nilsson L, Farahmand BY, Persson PG, Thiblin I, Tomson T. Risk factors for sudden unexpected death in epilepsy: a case-control study. *Lancet.* 1999;353:888-93.
- Nilsson L, Bergman U, Diwan V, Farahmand BY, Persson PG, Tomson T. Antiepileptic drug therapy and its management in sudden unexpected death in epilepsy: a case-control study. *Epilepsia.* 2001;42:667-73.
- Nouri S. Sudden Unexpected Death in Epilepsy. *eMedicine Specialties* Jan 2011. Full text available at the URL: <http://emedicine.medscape.com/article/1187111-overview>
- Provini F, Plazzi G, Tinuper P, Vandi S, Lugaresi E, Montagna P. Nocturnal frontal lobe epilepsy. A clinical and polygraphic overview of 100 consecutive cases. *Brain* 1999;122:1017-1031.
- Ryvlin P, Montavont A, Kahane P. Sudden unexpected death in epilepsy: from mechanisms to prevention. *Curr Opin Neurol.* 2006;19:194-99.]
- Robles SG, Gelisse P, El Fertit H, Tancy C, Duffau H, Crespel A, Coubes P. Parasagittal transinsular electrodes for stereo-EEG in temporal and insular lobe epilepsies. *Stereotact Funct Neurosurg.* 2009;87(6):368-372
- Roper SN, Lévesque MF, Sutherland WW, Engel J Jr. Surgical treatment of partial epilepsy arising from the insular cortex. Report of two cases *Neurosurg.* 1993 ;79(2):266-269.
- Scheffer IE, Bhatia KP, Lopes-Cendes I, Fish DR, Marsden CD, Andermann E, Andermann F, Desbiens R, Keene D, Cendes F, Manson JI, Constantinou JEC, McIntosh A, Berkovic SF. Autosomal dominant nocturnal frontal lobe epilepsy. A distinctive clinical disorder. *Brain* 1995; 118:61-73.
- Scorza FA, de Albuquerque M, Arida RM, Cavalheiro EA. Sudden unexpected death in epilepsy: Are winter temperatures a new potential risk factor? *Epilepsy Behav.* 2007;10:509-10.
- Scorza F, Cysneiros R, Arida R, Terra-Bustamante V, Albuquerque M, Cavalheiro A. The other side of the coin: Beneficiary effect of omega-3 fatty acids in sudden unexpected death in epilepsy. *Epilepsy & Behavior.* 2008;13(20):279-283.
- So NK. Mesial frontal epilepsy. *Epilepsia.* 1998;39(4):49-61.
- Sperling MR, Feldman H, Kinman J, Liporace JD, O'Connor MJ. Seizure control and mortality in epilepsy. *Ann Neurol.* 1999;46:45-50.
- Stollberger C, Finsterer J. Cardiorespiratory findings in sudden unexplained/unexpected death in epilepsy (SUDEP). *Epilepsy Res.* 2004;59:51-60.
- Tamayo A, Hachinski V. Central nervous system the neurogenic heart. *CAR* 2003;3:1-8
- Tomson T, Nashef L, Ryvlin P. Sudden unexpected death in epilepsy: current knowledge and future directions. *The Lancet Neurology* 2008;7(1):1021-1031.
- Walczak TS, Leppik IE, D'Amelio M, Rarick J, So E, Ahman P, Ruggles K, Cascino GD, Annegers JF, Hauser WA. Incidence and risk factors in sudden unexpected death in epilepsy: a prospective cohort study. *Neurology.* 2001;56:519-25.



Novel Aspects on Epilepsy

Edited by Prof. Humberto Foyaca-Sibat

ISBN 978-953-307-678-2

Hard cover, 338 pages

Publisher InTech

Published online 12, October, 2011

Published in print edition October, 2011

This book covers novel aspects of epilepsy without ignoring its foundation and therefore, apart from the classic issues that cannot be missing in any book about epilepsy, we introduced novel aspects related with epilepsy and neurocysticercosis as a leading cause of epilepsy in developing countries. We are looking forward with confidence and pride in the vital role that this book has to play for a new vision and mission. Therefore, we introduce novel aspects of epilepsy related to its impact on reproductive functions, oral health and epilepsy secondary to tuberous sclerosis, mitochondrial disorders and lisosomal storage disorders.

How to reference

In order to correctly reference this scholarly work, feel free to copy and paste the following:

Humberto Foyaca-Sibat and Lourdes de Fátima Ibañez Valdés (2011). Clinical Features of Epilepsy Secondary to Neurocysticercosis at the Insular Lobe, Novel Aspects on Epilepsy, Prof. Humberto Foyaca-Sibat (Ed.), ISBN: 978-953-307-678-2, InTech, Available from: <http://www.intechopen.com/books/novel-aspects-on-epilepsy/clinical-features-of-epilepsy-secondary-to-neurocysticercosis-at-the-insular-lobe>

INTECH

open science | open minds

InTech Europe

University Campus STeP Ri
Slavka Krautzeka 83/A
51000 Rijeka, Croatia
Phone: +385 (51) 770 447
Fax: +385 (51) 686 166
www.intechopen.com

InTech China

Unit 405, Office Block, Hotel Equatorial Shanghai
No.65, Yan An Road (West), Shanghai, 200040, China
中国上海市延安西路65号上海国际贵都大饭店办公楼405单元
Phone: +86-21-62489820
Fax: +86-21-62489821

© 2011 The Author(s). Licensee IntechOpen. This is an open access article distributed under the terms of the [Creative Commons Attribution 3.0 License](#), which permits unrestricted use, distribution, and reproduction in any medium, provided the original work is properly cited.

IntechOpen

IntechOpen