

We are IntechOpen, the world's leading publisher of Open Access books Built by scientists, for scientists

4,800

Open access books available

122,000

International authors and editors

135M

Downloads

Our authors are among the

154

Countries delivered to

TOP 1%

most cited scientists

12.2%

Contributors from top 500 universities



WEB OF SCIENCE™

Selection of our books indexed in the Book Citation Index
in Web of Science™ Core Collection (BKCI)

Interested in publishing with us?
Contact book.department@intechopen.com

Numbers displayed above are based on latest data collected.
For more information visit www.intechopen.com



Prevention of Spinal Cord Injury After Thoracoabdominal Aortic Aneurysm Repair

Takashi Kunihara, Suguru Kubota, Satoru Wakasa,
Norihiko Shiiya and Yoshiro Matsui
*Hokkaido University Hospital, Sapporo
Japan*

1. Introduction

Thoracoabdominal aortic aneurysm (TAAA) repair still remains a challenging operation since it necessitates extended exposure of the aorta and reimplantation of the vital aortic branches. Among possible postoperative complications, spinal cord injury (SCI) seems one of the most formidable morbidities. Even by experts who have championed in TAAA repair the incidence of SCI remained as high as 16% in the early 1990s (Svensson et al., 1993). Thanks to numerous experimental investigations and technical advances or modifications, it has improved up to 3.6%-4.6% in the worldwide largest centers with a contemporary strategy (i.e. aggressive use of distal aortic perfusion) (Safi et al., 2003, Coselli et al., 2007, Zoli et al., 2010). However, this incidence of SCI should vary according to the extent of aortic involvement. In 1986, Crawford and his colleagues proposed classification of TAAA into four groups according to the extent of aortic involvement and clearly showed that this classification could predict late death and neurological deficit (Crawford et al., 1986). Their classification is as following; group I involves most of the descending thoracic and upper abdominal aorta. Group II involves most of the descending thoracic aorta and most or all of the abdominal aorta. Group III involves the distal descending thoracic aorta and varying segments of abdominal aorta. Group IV involves most or all of the abdominal aorta including the segment from which the visceral vessels arise. Later, Safi and his co-workers advocated additional group V that involves below the sixth intercostal space to just above the renal arteries (Safi et al., 1998, 1999, 2003) (Figure 1). As shown later in Table 3, this classification correlates well with postoperative SCI still in contemporary era, thus it has been used widely to date. In the most extended type of TAAA (type II), SCI still occurs in 4.2-15.8% despite with experienced hands in the last decade (Safi et al., 2003, Jacobs et al., 2006, Coselli et al., 2007, Conrad et al., 2007, Acher et al., 2008, Zoli et al., 2010). Thus spinal cord protection during TAAA repair has emerged as great clinical importance. The primary aim of this review is to provide a better appreciation and understanding of the mechanisms and pathophysiology of SCI after TAAA repair.

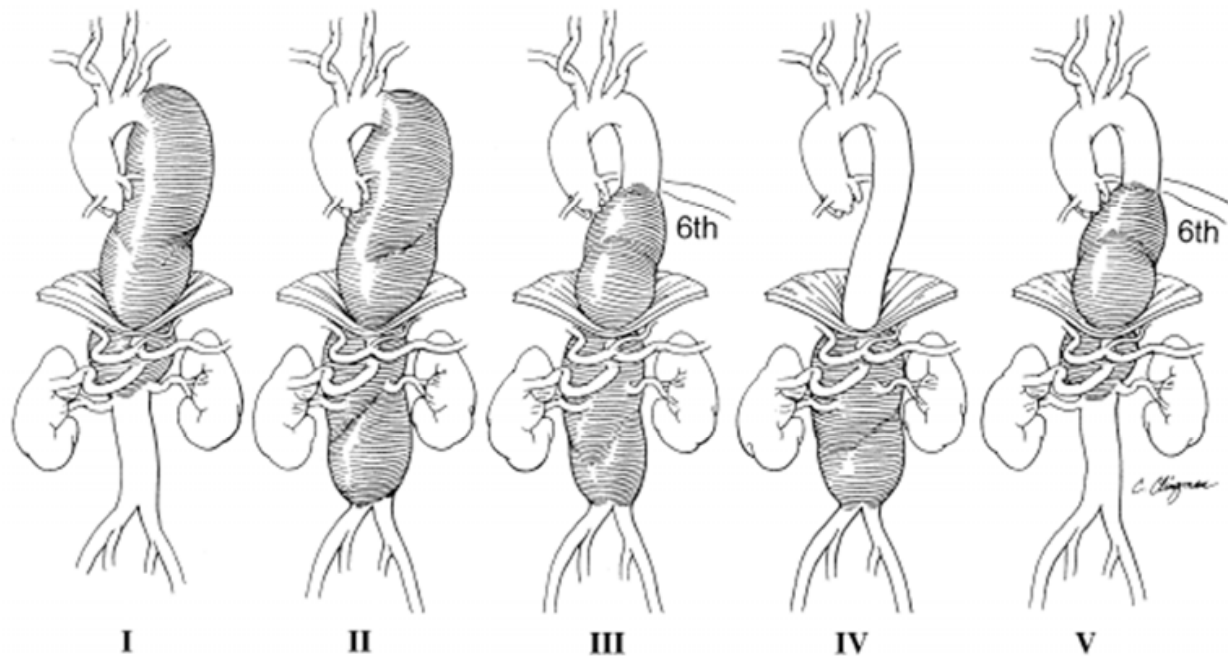


Fig. 1. Crawford/Safi's classification of the extent of aortic involvement (From; Safi, et al., 1999).

2. Mechanisms of spinal cord injury

Underlying mechanisms of SCI after TAAA repair are multifactorial, however, they can be primarily summarized into three key processes; 1) the duration and degree of ischemia, 2) failure to re-establish blood flow to the spinal cord after repair, and 3) a biochemically mediated reperfusion injury (Svensson 1997).

2.1 The duration and degree of ischemia

To reduce the duration and degree of spinal cord ischemia, either oxygen supply should be enhanced or oxygen demand attenuated. For these purposes, multi-segmental sequential clamping technique combined with mild hypothermic distal aortic perfusion has favorably been used in many institutions. When sequential clamping is not feasible, deep hypothermic circulatory arrest should be applied.

2.1.1 Distal aortic perfusion

Pioneers have used simple cross-clamping technique and reported acceptable outcomes (Crawford et al., 1986) (Schepens et al., 1994). Nowadays, majority of surgeons use distal aortic perfusion to reduce ischemia of the distal organs and cardiac afterload. Surprisingly, distal shunt was already used in a half century ago and has been applied with some modifications (Etheredge et al., 1955, Gott 1972, Cambria et al., 1998). Distal shunt has some advantages such as its simplicity and mild heparinization, but has also some disadvantages. Distal blood flow depends largely on proximal blood pressure and it is difficult to manage massive bleeding. On the other hand, left heart bypass using a centrifugal pump can provide flexible control of distal blood flow, thus it is currently used widely. Many experts have demonstrated that left heart bypass could significantly reduce the incidence of SCI

especially in extended TAAA (type II) repair (Safi et al., 1997) (Coselli et al., 1999, 2003). We have favorably used a partial cardiopulmonary bypass (CPB) through the femoral artery and vein. This alternative has some advantages in case with cardiopulmonary instability or massive bleeding. Some disadvantages such as acceleration of bleeding tendency has been resolved by reduction of heparin dosage using a fully heparin-coated closed-loop CPB system with a soft reservoir bag (Shiyya et al., 2005, 2006).

2.1.2 Multi-segmental sequential clamping

Blood flow of the anterior spinal artery is primarily supplied by some radicular arteries. The radicular artery has a rich collateral network between adjacent intercostal/lumbar arteries. Therefore it may be beneficial to maintain this collateral blood flow during reattachment of the intercostals/lumbar arteries. Especially in patients with degenerative aortic aneurysm, occlusion or stenosis of the intercostals/lumbar arteries may alter and complicate this collateral pathway, which may emphasize the importance to preserve it. In addition, during reattachment of the intercostals/lumbar arteries, back bleeding from adjacent one may accelerate steal phenomenon (Christiansson et al., 2001). The Mount Sinai group emphasized importance of avoiding steal phenomenon. They sacrificed all involved intercostals/lumbar arteries outside of the aorta to avoid steal phenomenon in 100 cases and experienced only 2% SCI (Etz et al., 2006). Their findings have a great implication for extensive deployment of endovascular stentgraft.

On the other hand, the anterior spinal artery has a narrow critical zone at around T4 level, where the spinal cord is susceptible to ischemia (Dommissse 1974, Svensson et al., 1986). Thus an ascending blood flow through the anterior spinal cord artery alone is not enough to feed this area. These mechanisms may explain why distal aortic perfusion alone was not beneficial to prevent SCI in the early era (Crawford et al., 1988). Therefore segmental sequential clamping seems advantageous to preserve collateral blood flow to the spinal cord during reattachment of the critical intercostals/lumbar arteries (Kuniyoshi et al., 2003). Trend has become toward clamping shorter segments (multi-segmental sequential clamping). We experienced no postoperative SCI when less than two pairs of intercostals/lumbar arteries were involved between segmental clamping. We identified that multi-segmental sequential clamping in combination with distal aortic perfusion was the only significant predictor for SCI after type I and II TAAA repair in multivariate analysis (Shiyya et al., 2005). The fact that a previous abdominal aortic aneurysm repair is a significantly high risk for postoperative SCI may support this collateral network concept (Svensson 2005).

2.1.3 Hypothermia

It has been widely accepted that mild hypothermia is clinically effective to prevent SCI. A reduction in temperature of 3°C provides a 2-fold increase of the tolerable ischemic interval in rabbit (Vacanti et al., 1984) and a 5°C reduction does a 2.5-fold increase in pig (Strauch et al., 2004). Therefore almost all aortic surgeon currently use mild hypothermia (32-34°C) using heat-exchanger or permissively in combination of distal aortic perfusion. Whenever the aorta cannot be safely clamped, use of deep hypothermic circulatory arrest should be warranted. Clinically, moderate to profound hypothermia was proved to prolong tolerable ischemic interval, which enables secure reconstruction of the aorta for aortic surgeons (Svensson et al., 2003) (Fig. 2).

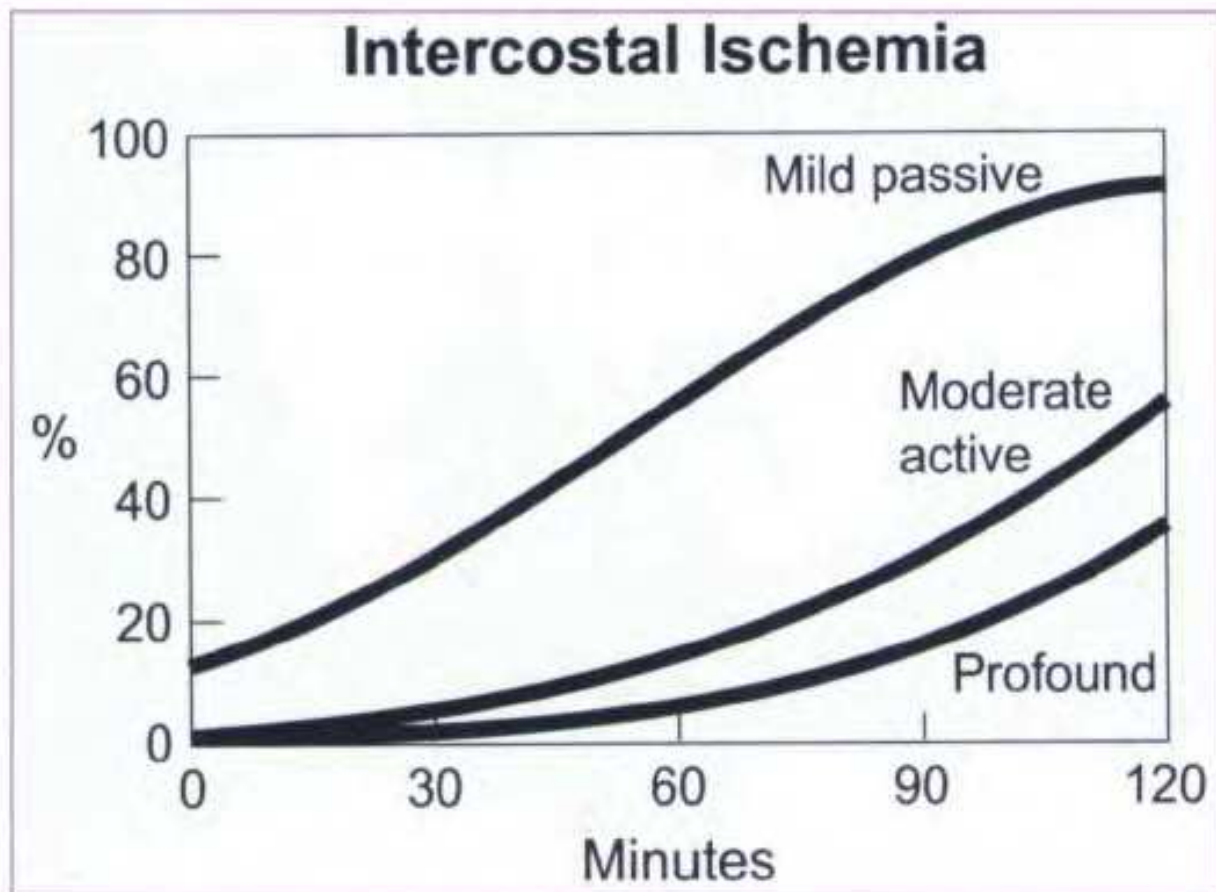


Fig. 2. Relationship between interval of spinal cord ischemia and risk of neurological deficit stratified by systemic temperature (Svensson 2005).

Kouchoukos and his colleagues have aggressively performed TAAA repair under profound hypothermia and reported its substantial protective effect against SCI (2.9% paraplegia) (Kouchoukos et al., 2003). Using deep hypothermic circulatory arrest Coselli and his co-workers could reduce the incidence of SCI up to 1%, however on the other hand, it increased morbidity and mortality rate (Coselli et al., 2008). Therefore this alternative is currently limited to selected cases (large or extensive aneurysm, friable aortic tissue, high risk of embolization, complex repair, redo cases), principally due to risk of coagulopathy, pulmonary dysfunction, and massive fluid shift. Accordingly some experts have proposed regional epidural or intrathecal cooling (Black et al., 2003, Shimizu et al., 2010). Although conceptually promising, this alternative currently lacks the support of prospective randomized data in larger cohort.

2.2 Failure to re-establish blood flow to the spinal cord after repair

2.2.1 Preoperative identification of critical intercostals artery

There are some surgeons who will blindly re-attach every intercostal/lumbar arteries to secure spinal cord protection (so-called onlay patch methods) (DeAnda et al., 2005). However, this technique seems unrealistic because longer ischemic time is definitively associated with higher risk of SCI (Safi et al., 1998). In addition, considerable extent of aneurismal aortic wall remains to exist. To re-establish blood flow to the spinal cord,

therefore, it is crucial to identify critical intercostals artery to the spinal cord. This is normally the largest radiculomedullary artery; so-called “the Adamkiewicz artery”. Preoperatively, it used to be identified by angiography, however, it appears rather invasive and difficult in case with large, thrombosed, or kinky aorta (Kiefer et al., 2002). Since we have visualized Adamkiewicz artery using multi-detector row computed tomography in 2003 (Maruyama et al., 2003), numerous reports have demonstrated that it is feasible in over 80% of cases by both computed tomography and magnetic resonance angiography (Yoshioka et al., 2006, Uotani et al., 2008) (Fig 3) (Table 1).

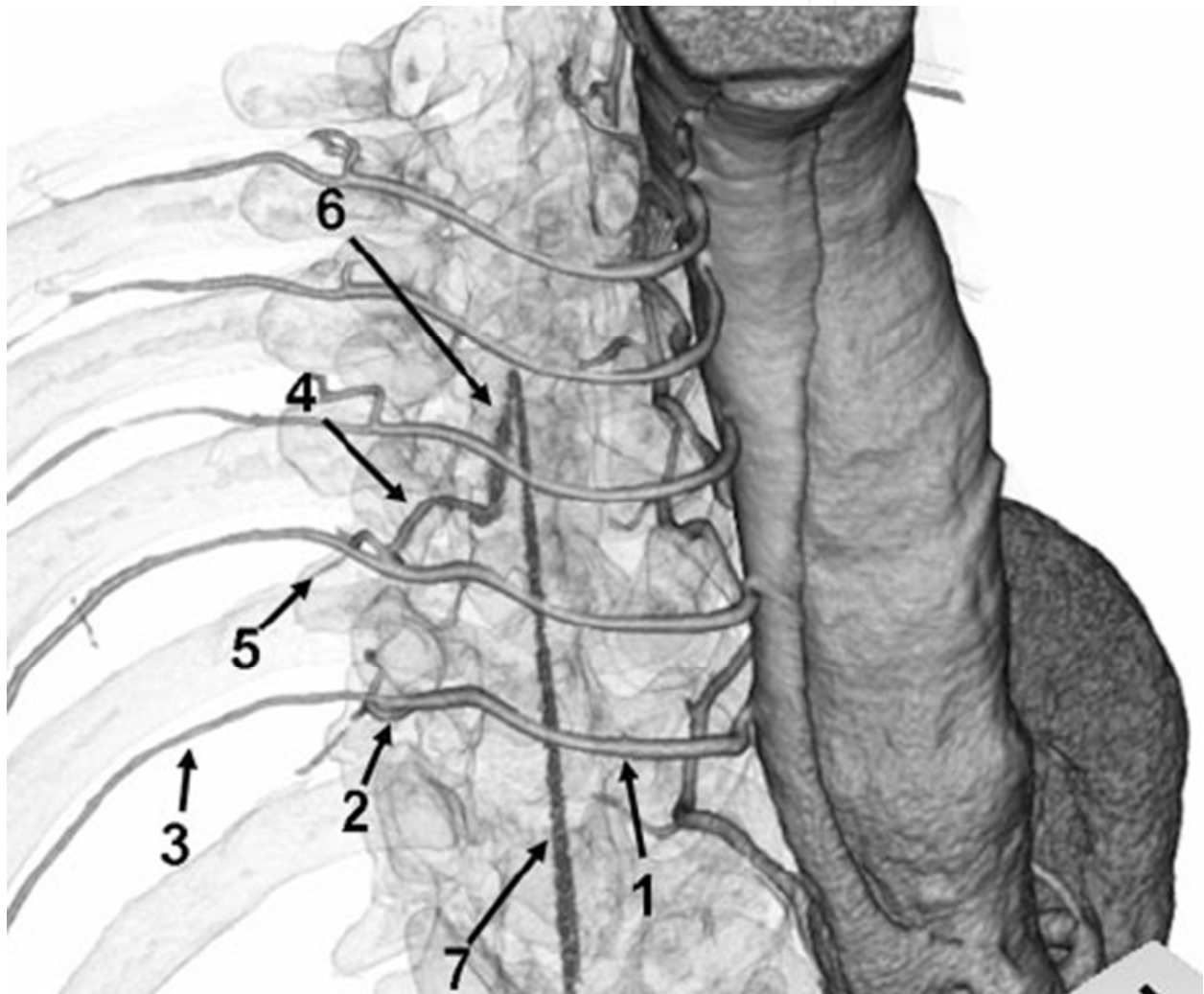


Fig. 3. Identification of the Adamkiewicz artery by 3D volume-rendered computer tomography. 1: Intercostal and lumbar arteries with their posterior (2) and anterior (3) branches, 4: Radiculomedullary artery and muscular branch (5), 6: the Adamkiewicz artery, 7: the anterior spinal artery. (Uotani et al., 2008)

The majority of the Adamkiewicz artery proved to originate from T8-L1 level with left dominance, which was consistent with angiographic findings and cadaver study (Koshino et al., 1999, Kiefer et al., 2002) (Table 2, Fig 4-5).

MRA

Nijenhuis RJ.	J Vasc Surg. 2007;45:677.	97%
Yoshioka K.	Radiographics. 2006;26:S63-73.	93%
Mell MW.	J Surg Res. 2008 Jun 20.	85%
Hyodoh H.	J Magn Reson Imaging. 2007;26:359.	82.4%
Ogino H.	Ann Thorac Surg. 2006;82:592.	70.7%

CT

Nojiri J.	Eur J Cardiothorac Surg. 2007;31:249.	100% (I.A.)
Boll DT.	Am J Roentgenol. 2006;187:1054.	100%
Ou P.	Am J Neuroradiol. 2007;28:216.	95%*
Uotani K.	Am J Neuroradiol. 2008;29:314.	94% (I.A.) 60% (I.V.)
Yoshioka K.	Radiographics. 2006;26:S63-73.	83%
Utsunomiya D.	Eur Radiol. 2008;18:2684.	80%
Takase K.	J Comput Assist Tomogr. 2006;30:716.	80%
Nijenhuis RJ.	J Vasc Surg. 2007;45:677.	71%
Kudo K.	Am J Neuroradiol. 2003;24:13.	68%
Von Tengg-Kobligk H.	J Endovasc Ther. 2007;14:639.	59%

Angiography

Kieffer E.	J Vasc Surg 2002;35:262.	86%
Heinemann MK.	Ann Thorac Surg. 1998;65:346.	65%
Williams GM.	J Vasc Surg. 2004;39:314.	43%

Table 1. Preoperative identification rate of the Adamkiewicz artery using different modalities. *child cases (7.5 +/- 5 years old), I.A. or I.V.: intra arterial or venous injection of contrast materials, respectively.

	Rt	Lt	Total
Th7	-	1	1
Th8	2	3	5
Th9	1	4	5
Th10	1	6	7
Th11	2	1	3
TH12	3	4	7
L1	-	4	4
L2	-	2	2
L3	-	1	1
L4~	1	-	1
	10	27	37
	(27%)	(73%)	

Table 2. Our experience to detect the Adamkiewicz artery in 48 cases using a computer tomography between 2001 and 2004. Detection rate was 77% and 86% of the Adamkiewicz artery originated from T8-L1

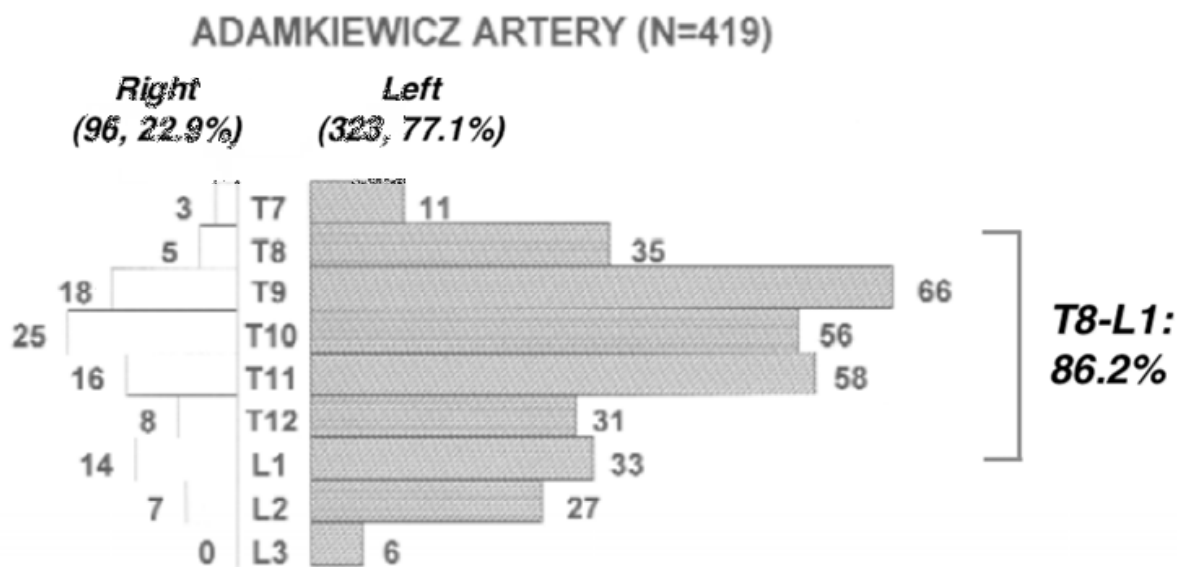


Fig. 4. Identification of the origin of the Adamkiewicz artery using an angiography (Kiefer et al., 2002 with modification)

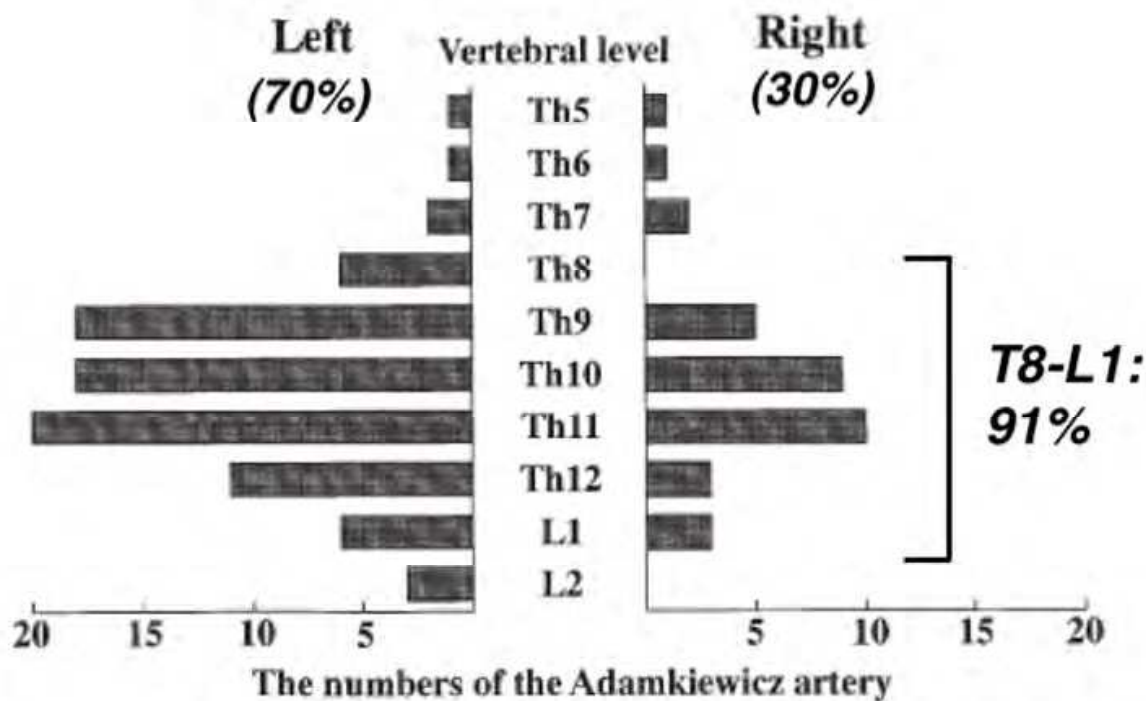


Fig. 5. Identification of the origin of the Adamkiewicz artery from 90 cadavers. (Koshino et al., 1999 with modification)

2.2.2 Intraoperative identification of critical intercostals artery

To identify the Adamkiewicz artery intraoperatively, traditionally we used to apply evoked spinal cord potential, which required two electrodes placed in the epidural space and

published its usefulness to prevent SCI (Matsui et al., 1994, Shiiya et al., 1995). However, this method is more or less invasive and technical demanding, and although rare, complications related to epidural catheter are catastrophic. Therefore majority of surgeon are currently using motor evoked potentials (Jakobs et al., 2006). Nonetheless, these electrophysiological examinations have some disadvantages such as time delay or effect of electric noise, anesthetic agents, peripheral ischemia, and hypothermia. Therefore we have tried to measure immediate information of spinal cord oxygenation noninvasively using transcutaneous or transesophageal near-infrared spectrophotometry (Kunihara et al., 1998, Kunihara et al., 2004). Further studies and technical advance will be essential toward its clinical use.

2.3 A biochemically mediated reperfusion injury

2.3.1 Clinical significance of cerebrospinal fluid drainage

Cerebrospinal fluid (CSF) drainage (CSFD) may be one of the most promising procedures to prevent SCI. Its usefulness has already advocated in 1960 (Miyamoto et al., 1960). Acher and associates have reported that combined use of CSFD and naloxone hydrochloride (naloxone), an opioid receptor antagonist, reduces the risk of SCI in patients undergoing TAAA repair in 1994 (Acher et al., 1994). In 2002, CSFD itself proved to be beneficial to reduce the risk of SCI after TAAA repair in prospective randomized clinical trial (Coselli et al., 2002). Meta-analysis of three randomized controlled trials and five cohort studies revealed beneficial effect of CSFD on paraplegia (Fig 6) (Cinà et al., 2004). Although rare (0.2%), CSFD-associated complications are catastrophic (subdural hematoma, intracranial bleeding, meningitis), so that CSFD should currently be reserved for extended aneurysm (type I and II) or patient at high risk (Cinà et al., 2004, Wynn et al., 2009).

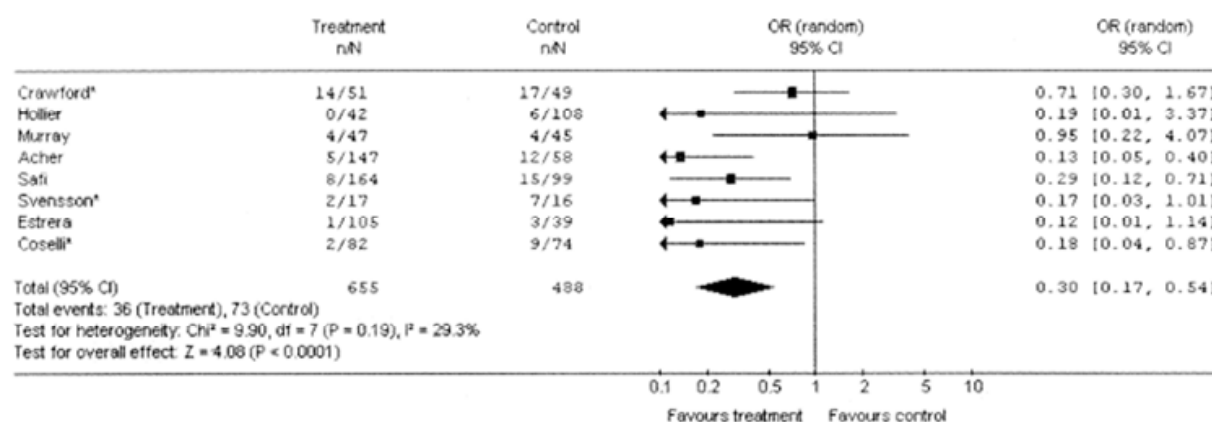


Fig. 6. Meta-analysis showing beneficial effect of cerebrospinal fluid drainage on paraplegia (Cinà et al., 2004).

2.3.2 Clinical significance of cerebrospinal fluid drainage

However, underlying mechanisms of CSFD to reduce SCI seems still unclear and it has not been investigated whether naloxone can alone attenuate the risk of SCI clinically like CSFD. Experimental studies have revealed that CSF pressure rises during aortic clamping, leading to decrease of spinal cord perfusion pressure (mean distal aortic pressure - CSF pressure) (Kaplan et al., 1995) (Fig. 7).

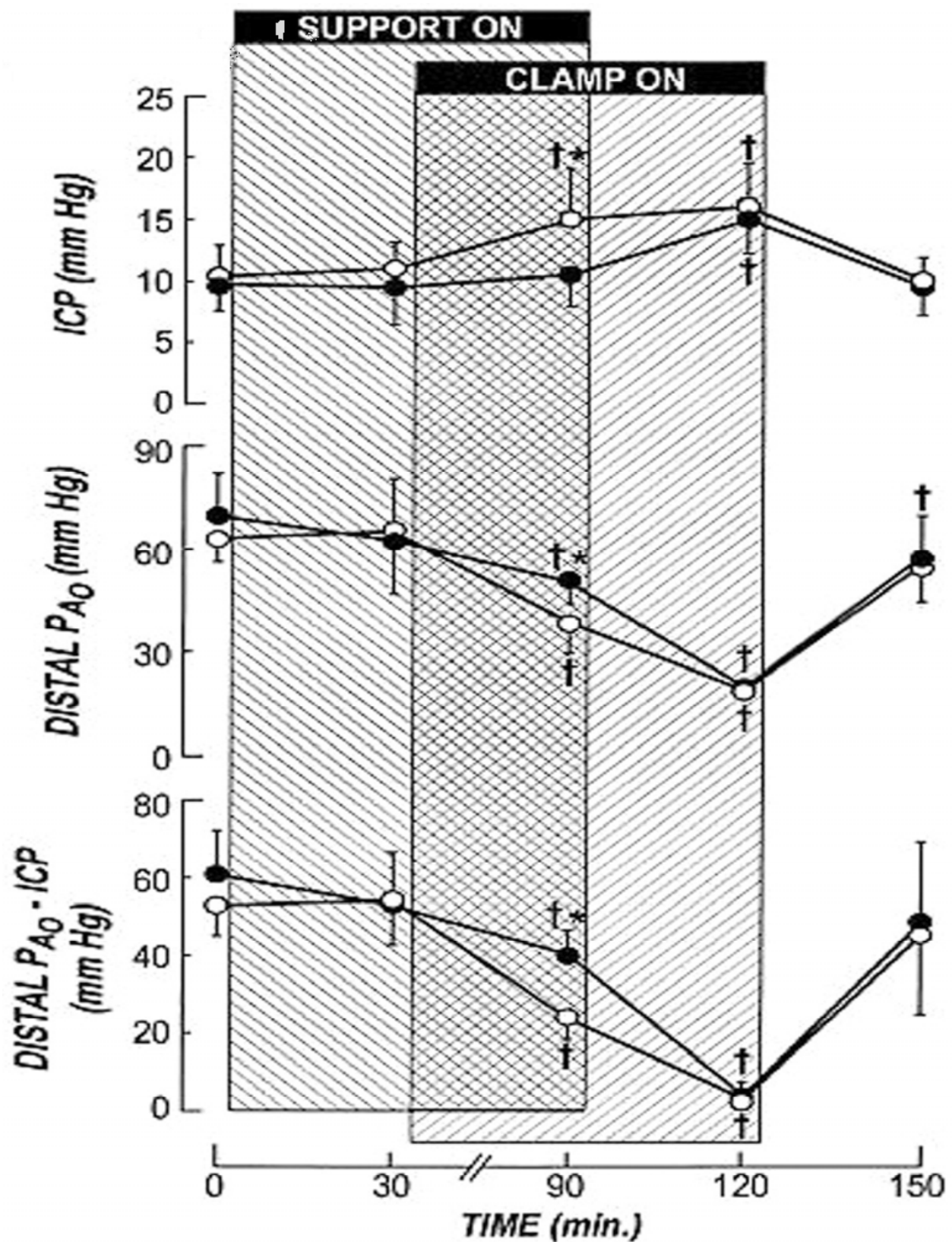


Fig. 7. Relationship between intracranial pressure (ICP), mean distal aortic pressure (DISTAL P_{A0}), and spinal cord perfusion gradient (DISTAL P_{A0} - ICP) during aortic clamping (Kaplan et al., 1995).

It has been believed that CSFD may restore spinal cord blood flow by decompressing spinal compartment syndrome caused by spinal cord edema in relation to ischemia-reperfusion injury (Safi et al., 1997) (Fig. 8). This speculation is supported by the clinical consequence that delayed-onset paraplegia could be successfully reversed by reducing CSF pressure (Cheung et al., 2002).

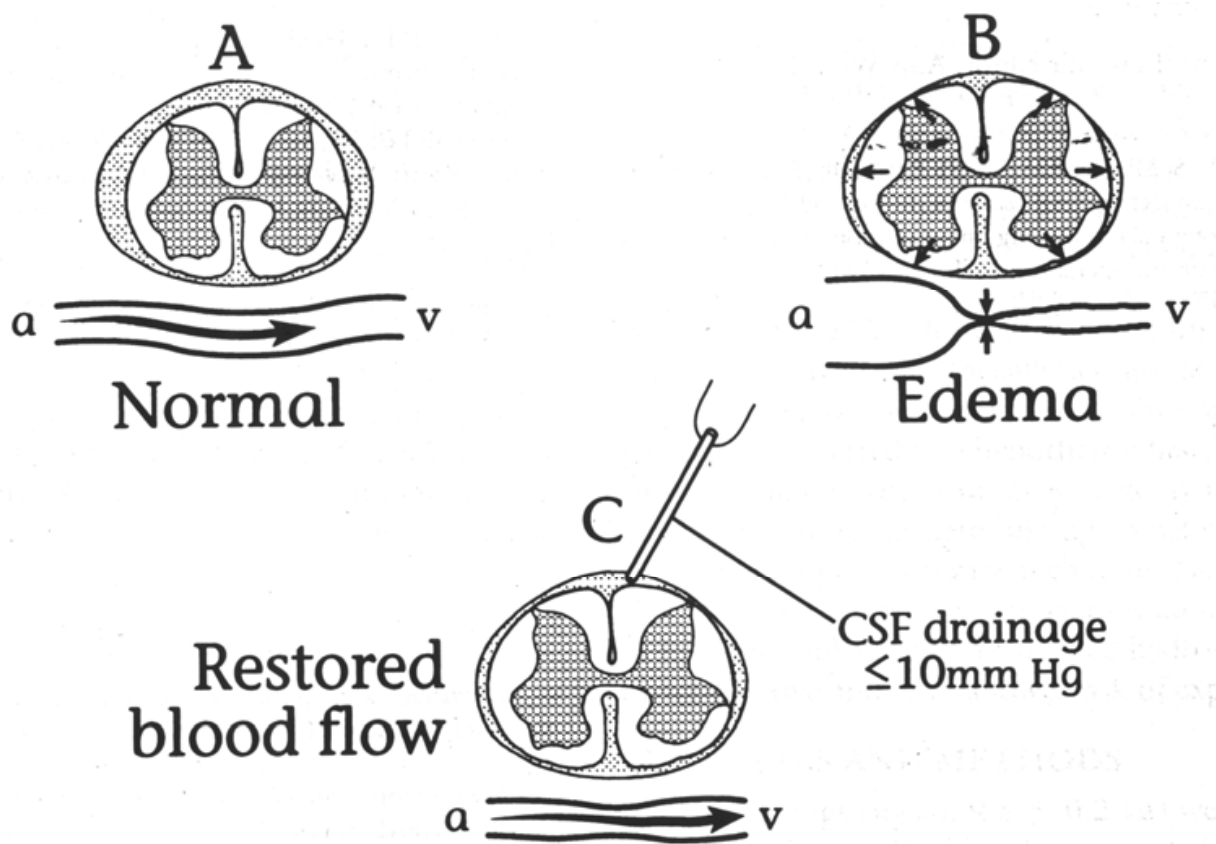


Fig. 8. Speculated mechanism of beneficial effect of cerebrospinal fluid drainage on spinal cord injury (Safi et al., 1997).

2.3.3 Role of cerebrospinal fluid drainage in ischemia-reperfusion injury

On the other hand, it has been well known that ischemia-reperfusion injury mediates some negative neurotrophic substances. Indeed, we showed that pro- and anti-inflammatory cytokines were generated in the rabbit spinal cord after ischemic SCI and they were clearly reversed by 21-aminosteroids (lazaroids) (Kunihara et al., 2000). Thus we have speculated that another key role of CSFD might be removal of negative neurotrophic substances. Actually, we revealed pro-inflammatory cytokines and S-100 β protein were predominantly generated in CSF than in serum after TAAA repair and their levels were more pronounced and prolonged in patients with SCI (Kunihara et al., 2001, Kuniharat et al., 2001) (Fig. 9, 10). Moreover, CSF levels of excitatory amino acids in patients with postoperative SCI was significantly higher than those in patients without SCI. These elevated CSF levels of excitatory amino acids could be significantly antagonized by intraoperative continuous intravenous administration of naloxone (Kunihara et al., 2004) (Fig. 11).

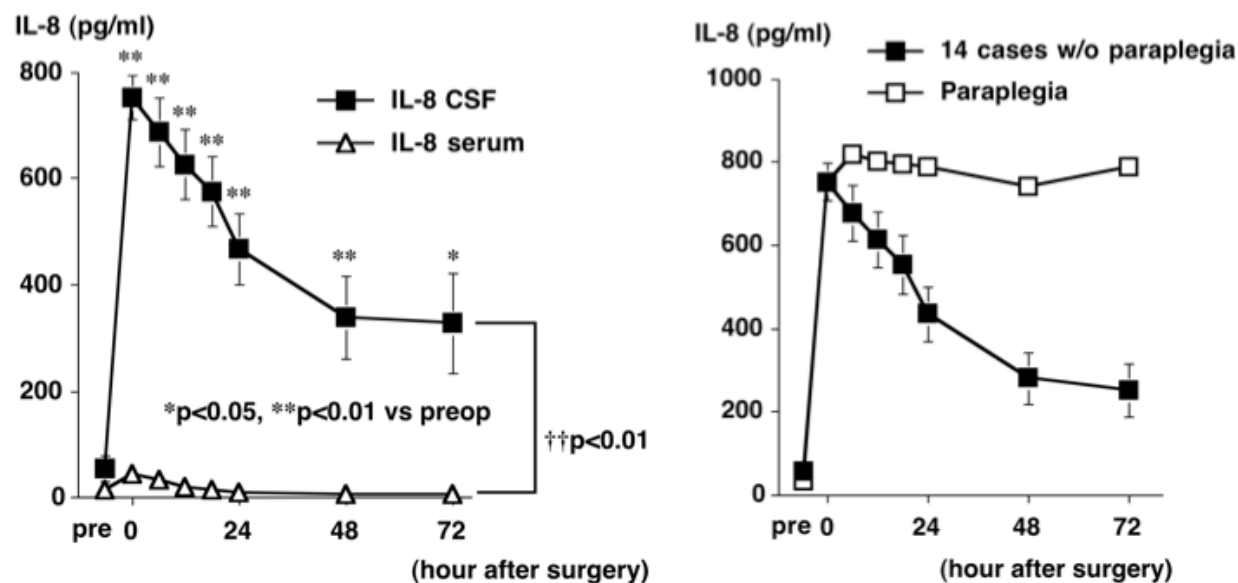


Fig. 9. Changes in serum and cerebrospinal fluid (CSF) interleukin-8 (IL-8) levels in overall patients (left). Changes in CSF IL-8 levels in patients with or without (w/o) paraplegia (right). (Kunihara et al., 2001)




Fig. 10. Postoperative time course of S-100β protein levels in the serum and CSF (Kunihara et al., 2001).

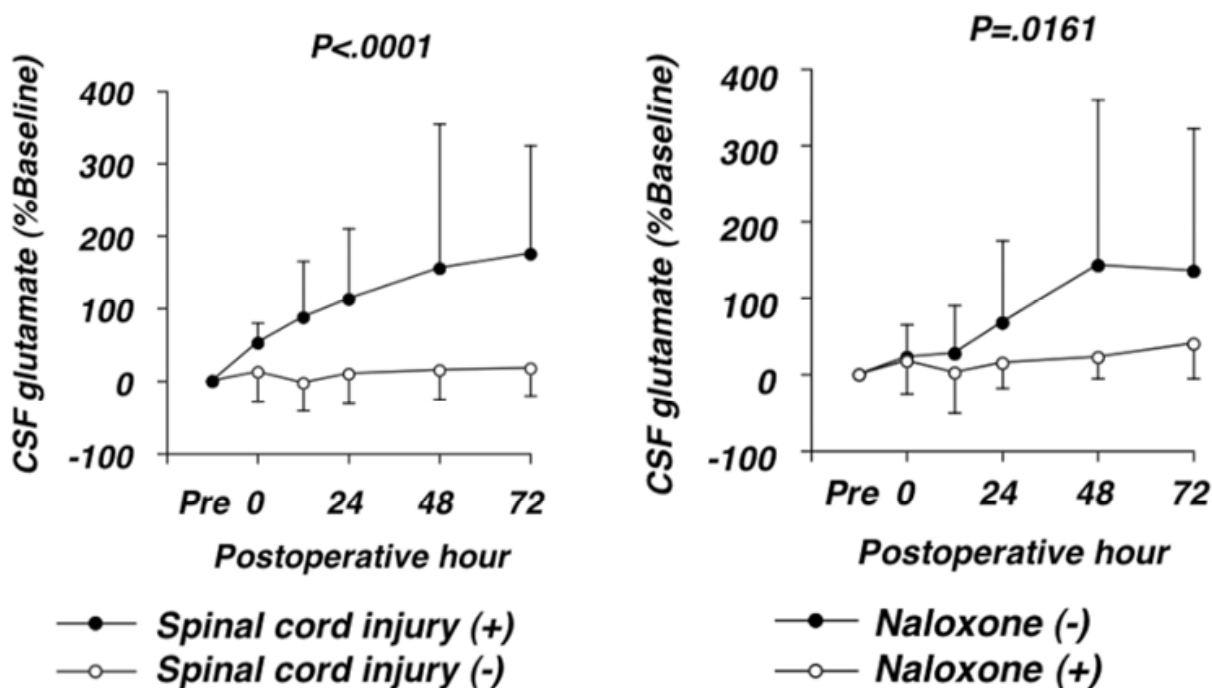


Fig. 11. Postoperative time course of CSF glutamate levels (Kunihara et al., 2004).

2.3.4 Pharmacological intervention

2.3.4.1 Naloxone hydrochloride

Numerous pharmacological interventions have been tried to attenuate postoperative SCI, however, no compound has become popular for a wide standardized clinical use. Above all, naloxone, the opiate antagonist, has gained increased attention since a report by Acher and associates was published in 1994, as described before (Acher et al., 1994). In general, excessive synaptic accumulation of excitatory amino acids during ischemia is associated with neuronal cell damage, which is mediated through overactivation of their receptors (i.e. N-methyl-D-aspartate receptor) followed by excessive influx of calcium. It has been shown that high concentration of naloxone attenuates N-methyl-D-aspartate-mediated neurotoxicity in an animal model (Kim et al., 1987). Clinically, Acher and his colleagues disclosed that the addition of naloxone resulted in a 30% reduction in the SCI rate (Acher et al., 2010). The important findings of our study that CSF excitatory amino acids were significantly suppressed by naloxone up to 72 hours after TAAA repair may have great implication because neurotoxicity mediated by excitatory amino acids is supposed to be a late-onset process (Nakamura et al., 1994) (Fig. 11). Therefore Acher and his colleagues recommended intravenous continuous administration of naloxone up to 48 hours postoperatively (Acher et al., 2010). We have experienced no side effect of naloxone at a rate of $1\mu\text{g}/\text{kg}/\text{h}$ even at postoperative period.

2.3.4.2 Other glutamate inhibitors

With the same mechanism, beneficial effects of other glutamate antagonists have been reported. Rokkas and his colleagues reported that Dextrorphan, a noncompetitive N-methyl-D-aspartate receptor antagonist, inhibited the release of excitatory amino acids in the spinal cord during ischemia (Rokkas et al., 1994). However, this agent is no longer used

clinically because of an unfavorable tolerance profile (Albers et al., 1995, Rokkas & Kouchoukos, 2001). Instead, other antiglutamate compounds such as Riluzole (Lang-Lazdunski et al., 2000), Memantine (Ehrlich et al., 1999), MK-801 (Cho et al., 2005) or Magnesium sulfate (Lang-Lazdunski et al., 2000) have been evaluated to have a neuroprotective effect after ischemia reperfusion of the spinal cord, although further evaluation should be necessary for their wide clinical use.

2.3.4.3 Steroid

In the early 1980's, beneficial effects of intravenous methylprednisolone (30 mg/kg) on experimental SCI have been confirmed (Hall & Braughler, 1982, Braughler & Hall, 1983, Laschinger et al., 1984). It has been believed that steroid act as cellular and lysosomal membrane stabilizers. Since the Second National Acute Spinal Cord Injury Study reported in 1990 that methylprednisolone improved neurologic recovery after acute SCI when it was given in the first eight hours, methylprednisolone has become a clinical mainstay in the treatment of acute SCI (Bracken et al. 1990). In the field of aortic surgery, methylprednisolone has been given in many institutions with various dosages (7 mg/kg: kouchoukos et al., 2003, 30 mg/kg: Hollier et al., 1992, Acher C. 2010) although its effect is still controversial. We have routinely administered 1g methylprednisolone intravenously prior to aortic cross-clamping and another 1g into CPB circuit (Kunihara et al., 2004). A drawback of steroid use such as postoperative hyperglycemia, disadvantageous to spinal cord protection, should be aggressively normalized. Recently, a new series of 21-aminosteroids (i.e. Lazaroids) have emerged as remarkable protective compounds against various ischemia-reperfusion injury model through the inhibition of irondependent lipid peroxidation (Sasaki et al., 1996, Holzgrefe et al., 1990, Johnson & Lefer, 1990). As was written above, these agents have also been shown beneficial effects of attenuating postischemic SCI (Fowl et al., 1990, Kunihara et al., 2000). Further examination will be required for clinical application.

2.3.4.4 Vasodilators

The other beneficial mechanisms against postischemic SCI include enhancing collateral blood flow to the jeopardized spinal cord. Systemic administration of vasodilators (i.e. nitroprusside) has been believed to decrease spinal cord perfusion pressure by reducing distal aortic pressure and increasing cerebrospinal fluid pressure, thus it should be avoided or combination with CSFD is recommended (Shine & Nugent, 1990, Marini et al., 1997). On the other hand, local use (i.e. intrathecal) of vasodilators can avoid reducing distal aortic pressure, thus may be beneficial for spinal cord protection. Svensson and his colleagues administered papaverine intrathecally and showed significant increase in spinal cord blood flow (Svensson 2005) and significant reduction of SCI clinically (Svensson et al., 1998) (Figure 12).

Prostaglandin E1 (PGE1) has also emerged as one of the promising compounds to enhance collateral blood flow to the spinal cord (Grabitz et al., 1993), however, it has also a dilemma to reduce distal aortic pressure. To avoid PGE1-induced hypotension in clinical use, Alprostadi, PGE1 incorporated in lipid microspheres to minimize metabolism and inactivation in the lung (Yone et al., 1999), has been examined to have the beneficial effect on ischemic SCI. In an experimental spinal cord ischemia model, we detected beneficial pharmacological effect of intravenous Alprostadi on the spinal cord oxygenation using

near-infrared spectrophotometry, which was not detected by spinal cord evoked potentials (Figure 13) (Kunihara et al., 2008). Thus Alprostadil can be given systemically, which may facilitate intraoperative management.

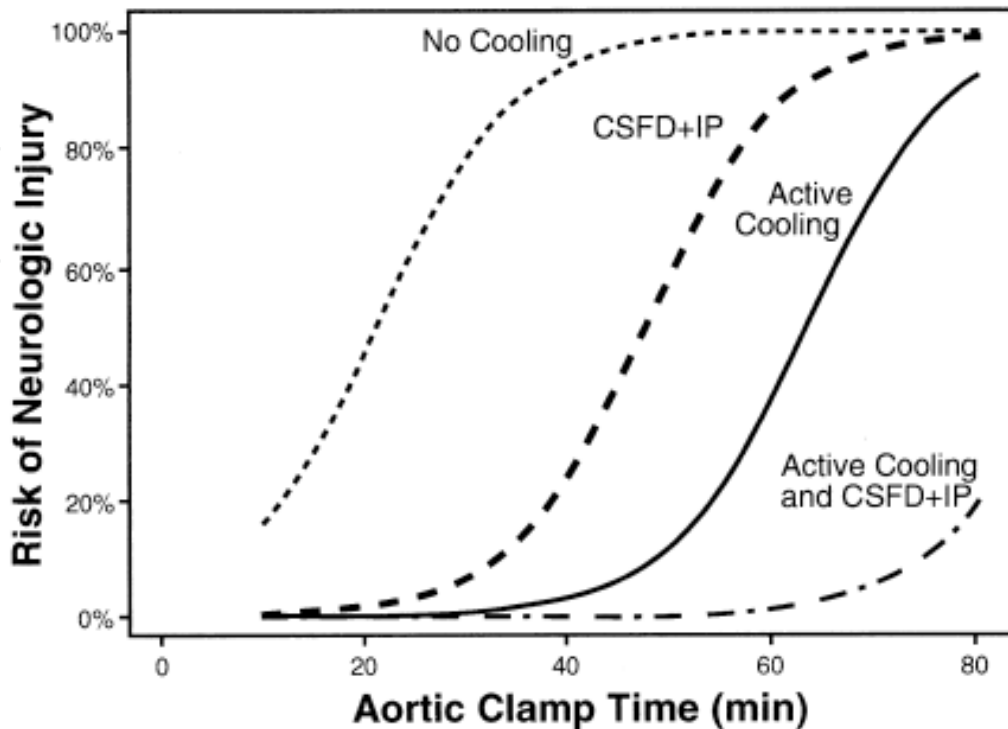


Fig. 12. Risk of spinal cord injury according to aortic cross-clamp time with no cooling or papaverine, cerebrospinal fluid drainage with intrathecal papaverine (CSFD+IP), active cooling with the combination. (Svensson et al., 1998)

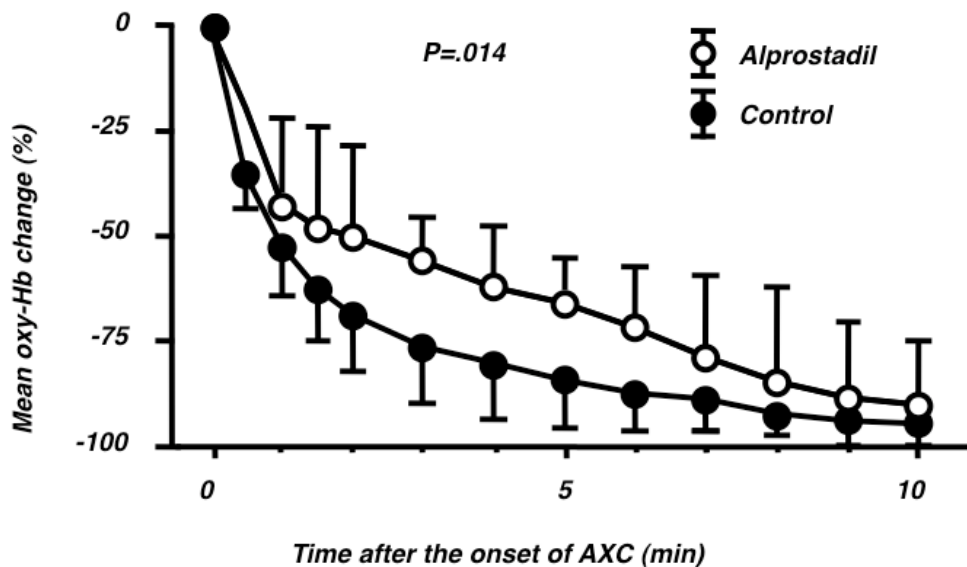


Fig. 13. Time course of mean % change of oxygenated hemoglobin (oxy-Hb) in the spinal cord measured by near-infrared spectrophotometry. AXC: aortic cross-clamping. (Kunihara et al., 2008)

2.3.4.5 Other drugs

Other numerous promising pharmacological interventions such as superoxide dismutase (Agee et al., 1991), allopurinol (Qayumi et al., 1994), calcium-channel blockers (Schitteck et al., 1992), Adenosine (Seibel et al., 1993) or Adenosine A2A agonist (ATL-146e) (Reece et al., 2004) have been tested. We have seriously published beneficial effects of nicorandil (an adenosine triphosphate-sensitive potassium channel opener) (Wakamatsu et al., 2001), immunophilin ligands FK506 or cyclosporine A (Tachibana et al., 2005) on transient spinal cord ischemia in rabbits. However, their protective effects on SCI seem still controversial and may require further evaluations.

3. Clinical results

With a better appreciation and understanding of the mechanisms and pathophysiology of SCI and with many clinical evidences the neurological outcomes after TAAA repair have dramatically improved. Table 3 illustrated postoperative SCI stratified by the extent of aortic involvement reported from institutions with large case volume.

Author	Year	Cases	Crawford/Safi's classification					Total	DAP
			I	II	III	IV	V		
Svensson	1993	1509	15%	31%	7%	4%		16%	17%
Safi	2003	1004	0.5%	10.7%	6.0%	0.7%	2.0%	3.6%	73.8%
Jacobs	2006	112	0%	4.2%					100%
Coselli	2007	2286	3.3%	6.3%	2.6%	1.4%		3.8%	39.8%
Conrad/Cambria*	2007	455	9.1%	14.5%	11.6%	2.9%		9.5%	8%
Acher	2008	516	6.9%	15.8%	3.8%	0%		6.8%	no
Zoli/Griep	2010	305	2.5%	11.5%	3.9%	2.2%		4.6%	95%

Table 3. Spinal cord injury after thoracoabdominal aortic aneurysm repair stratified by the extent of aortic involvement reported from institutions with large case volume. DAP: distal aortic perfusion. Conrad/Cambria*: only major paraplegia is demonstrated.

In spite of a contemporary and multidisciplinary approach with large experience, type II TAAA is still associated with high incidence of SCI as shown in table 3. Using a multivariate analysis, many authors have also emphasized that type II TAAA emerges as an independent predictor for postoperative SCI (Safi et al., 2005, Conrad et al., 2007, Schepens et al., 2009, Acher et al., 2010). Other preoperative independent predictors for postoperative SCI have been reported such as an emergent setting (Conrad et al., 2007, Acher 2010), aortic dissection (Schepens et al., 2009, Acher 2010), age >75 years old (Schepens et al., 2009), and renal dysfunction (Safi et al., 2005, 2008).

4. Conclusions

The underlying mechanisms and pathophysiology of SCI after TAAA repair may be multifactorial. We have thus reviewed the latest information with regard to this issue in this

manuscript briefly. From these considerable experimental and clinical evidences, we have evolved our strategy for TAAA repair over time as shown in Table 4 (Shiyya et al., 2005). We believe this may be the best and reasonable approach to prevent SCI after TAAA repair at the present moment. Nonetheless, Jacobs and his colleagues described; “despite all available measures, complete prevention of paraplegia in type II aneurysms seems to be unrealistic” (Jacobs et al. 2006). Our multidisciplinary effort to prevent SCI after extensive TAAA repair may be never ending

Mild hypothermic distal aortic perfusion or deep hypothermic circulatory arrest
Multi-segmental sequential clamping
Preoperative identification of the Adamkiewicz artery and reimplantation of responsible intercostal arteries
Without information, reconstruction of the intercostal arteries at Th8-L1 left
Avoidance of steal phenomenon during reconstruction of the intercostal arteries
Electrophysiological monitoring of the spinal cord function
Cerebrospinal fluid drainage
Intravenous administration of naloxone and methylprednisolone.

Table 4. Our strategy to prevent spinal cord injury.

5. References

- Acher CW, Wynn MM, Hoch JR, Popic P, Archibald J, Turnipseed WD. (1994). Combined use of cerebral spinal fluid drainage and naloxone reduces the risk of paraplegia in thoracoabdominal aneurysm repair. *J Vasc Surg* Vol. 19, No. 2, 236-48.
- Acher CW, Wynn MM, Mell MW, Tefera G, Hoch JR. (2008). A quantitative assessment of the impact of intercostal artery reimplantation on paralysis risk in thoracoabdominal aortic aneurysm repair. *Ann Surg*. Vol. 248, No. 4, 529-40.
- Acher C. (2010). It is not just assisted circulation, hypothermic arrest, or clamp and sew. *J Thorac Cardiovasc Surg*. Vol. 140, No. 6, S136-41.
- Agee JM, Flanagan T, Blackbourne LH, Kron IL, Tribble CG. (1991). Reducing postischemic paraplegia using conjugated superoxide dismutase. *Ann Thorac Surg*. Vol. 51, No. 6, 911-4.
- Albers GW, Atkinson RP, Kelley RE, Rosenbaum DM. (1995). Safety, tolerability, and pharmacokinetics of the N-methyl-D-aspartate antagonist dextrorphan in patients with acute stroke. Dextrorphan Study Group. *Stroke*. Vol. 26, No. 2, 254-8.
- Black JH, Davison JK, Cambria RP. (2003) Regional hypothermia with epidural cooling for prevention of spinal cord ischemic complications after thoracoabdominal aortic surgery. *Semin Thorac Cardiovasc Surg*. Vol. 15, No. 4, 345-52.
- Bracken MB, Shepard MJ, Collins WF, Holford TR, Young W, Baskin DS, Eisenberg HM, Flamm E, Leo-Summers L, Maroon J, et al. (1990). A randomized, controlled trial of methylprednisolone or naloxone in the treatment of acute spinal-cord injury. Results of the Second National Acute Spinal Cord Injury Study. *N Engl J Med*. Vol. 322, No. 20, 1405-11.
- Braughler JM & Hall ED. (1983). Lactate and pyruvate metabolism in injured cat spinal cord before and after a single large intravenous dose of methylprednisolone. *Journal of Neurosurgery*. Vol. 59, No. 2, 256-261.

- Cambria RP, Davison JK, Giglia JS, Gertler JP. (1998). Mesenteric shunting decreases visceral ischemia during thoracoabdominal aneurysm repair. *J Vasc Surg.* Vol. 27, No 4, 745-9.
- Cheung AT, Weiss SJ, McGarvey ML, Stecker MM, Hogan MS, Escherich A, Bavaria JE. (2002). Interventions for reversing delayed-onset postoperative paraplegia after thoracic aortic reconstruction. *Ann Thorac Surg.* Vol. 74, No. 2, 413-9.
- Cho Y, Ueda T, Mori A, Shimizu H, Haga Y, Yozu R. (2005). Protective use of N-methyl-D-aspartate receptor antagonists as a spinoplegia against excitatory amino acid neurotoxicity. *J Vasc Surg.* Vol. 42, No. 4, 765-71.
- Christiansson L, Ulus AT, Hellberg A, Bergqvist D, Wiklund L, Karacagil S. (2001). Aspects of the spinal cord circulation as assessed by intrathecal oxygen tension monitoring during various arterial interruptions in the pig. *J Thorac Cardiovasc Surg* Vol. 121, No. 4, 762-72.
- Cinà CS, Abouzahr L, Arena GO, Laganà A, Devereaux PJ, Farrokhyar F. (2004). Cerebrospinal fluid drainage to prevent paraplegia during thoracic and thoracoabdominal aortic aneurysm surgery: a systematic review and meta-analysis. *J Vasc Surg.* Vol. 40, No. 1, 36-44.
- Conrad MF, Crawford RS, Davison JK, Cambria RP. (2007). Thoracoabdominal aneurysm repair: a 20-year perspective. *Ann Thorac Surg.* Vol. 83, No. 2, S856-61.
- Coselli JS, LeMaire SA (1999). Left heart bypass reduces paraplegia rates after thoracoabdominal aortic aneurysm repair. *Ann Thorac Surg* Vol. 67, No. 6, 1931-4
- Coselli JS, Lemaire SA, Koksoy C, Schmittling ZC, Curling PE. (2002). Cerebrospinal fluid drainage reduces paraplegia after thoracoabdominal aortic aneurysm repair: results of a randomized clinical trial. *J Vasc Surg* Vol. 35, No. 4, 631-9.
- Coselli JS. (2003). The use of left heart bypass in the repair of thoracoabdominal aortic aneurysms: current techniques and results. *Semin Thorac Cardiovasc Surg.* Vol. 15, No. 4, 326-32
- Coselli JS, Bozinovski J, LeMaire SA (2007). Open surgical repair of 2286 thoracoabdominal aortic aneurysms. *Ann Thorac Surg.* Vol. 83, No. 2, S862-4.
- Coselli JS, Bozinovski J, Cheung C. (2008) Hypothermic circulatory arrest: safety and efficacy in the operative treatment of descending and thoracoabdominal aortic aneurysms. *Ann Thorac Surg.* Vol. 85, No. 3, 956-63.
- Crawford ES, Crawford JL, Safi HJ, Coselli JS, Hess KR, Brooks B, Norton HJ, Glaeser DH (1986). Thoracoabdominal aortic aneurysms: preoperative and intraoperative factors determining immediate and long-term results of operations in 605 patients. *J Vasc Surg.* Vol. 3, No. 3, 389-404.
- Crawford ES, Mizrahi EM, Hess KR, Coselli JS, Safi HJ, Patel VM. (1988). The impact of distal aortic perfusion and somatosensory evoked potential monitoring on prevention of paraplegia after aortic aneurysm operation. *J Thorac Cardiovasc Surg.* Vol. 95, No. 3, 357-67.
- DeAnda A, Philpott JM, Kasirajan V. (2005). Onlay patch for complete intercostal artery preservation during thoracic and thoracoabdominal aortic aneurysm repair. *J Card Surg.* Vol. 20, No. 6, 578-81.
- Domisse GF. (1974). The blood supply of the spinal cord. A critical vascular zone in spinal surgery. *J Bone Joint Surg Br.* Vol. 56, No. 2, 225-35.

- Ehrlich M, Knolle E, Ciovica R, Böck P, Turkof E, Grabenwöger M, Cartes-Zumelzu F, Kocher A, Pockberger H, Fang WC, Wolner E, Havel M. (1999). Memantine for prevention of spinal cord injury in a rabbit model. *J Thorac Cardiovasc Surg.* Vol. 117, No. 2, 285-91.
- Etheredge SN, Yee J, Smith JV, Schonberger S, Goldman MJ. (1955) Successful resection of a large aneurysm of the upper abdominal aorta and replacement with homograft. *Surgery.* Vol. 38, No. 6, 1071-81.
- Etz CD, Halstead JC, Spielvogel D, Shahani R, Lazala R, Homann TM, Weisz DJ, Plestis K, Griep RB. (2006). Thoracic and thoracoabdominal aneurysm repair: is reimplantation of spinal cord arteries a waste of time? *Ann Thorac Surg.* Vol. 82, No. 5, 1670-7.
- Fowl RJ, Patterson RB, Gewirtz RJ, Anderson DK. (1990). Protection against postischemic spinal cord injury using a new 21-aminosteroid. *J Surg Res.* Vol. 48, No. 6, 597-600.
- Gott VL. (1972). Heparinized shunts for thoracic vascular operations. *J Thorac Cardiovasc Surg.* Vol 14, No 2, 219-20
- Grabitz K, Freye E, Stuhmeier K, Sandmann W. (1993). Spinal evoked potential in patients undergoing thoracoabdominal aortic reconstruction: a prognostic indicator of postoperative motor deficit. *J Clin Monit.* Vol. 9, No. 3, 186-90.
- Hall ED & Braugher JM. (1982). Glucocorticoid mechanisms in acute spinal cord injury: a review and therapeutic rationale. *Surg Neurol* Vol. 18, No. 5, 320-327
- Hollier LH, Money SR, Naslund TC, Proctor CD Sr, Buhrman WC, Marino RJ, Harmon DE, Kazmier FJ. (1992). Risk of spinal cord dysfunction in patients undergoing thoracoabdominal aortic replacement. *Am J Surg.* Vol. 164, No. 3, 210-3.
- Holzgreffe HH, Buchanan LV, Gibson JK. (1990). Effects of U74006F, a novel inhibitor of lipid peroxidation, in stunned reperfused canine myocardium. *J Cardiovasc Pharmacol* Vol. 15, No. 2, 239-48.
- Jacobs MJ, Mess W, Mochtar B, Nijenhuis RJ, Stadius van Eps RG, Schurink GW. (2006). The value of motor evoked potentials in reducing paraplegia during thoracoabdominal aneurysm repair. *J Vasc Surg.* Vol. 43, No. 2, 239-46.
- Johnson G & Lefer AM. (1990). Protective effects of a novel 21-aminosteroid during splanchnic artery occlusion shock. *Circ Shock* Vol. 30, No. 2, 155- 64.
- Kaplan DK, Atsumi N, D'Ambra MN, Vlahakes GJ. (1995). Distal circulatory support for thoracic aortic operations: effects on intracranial pressure. *Ann Thorac Surg.* Vol. 59, No. 2, 448-52.
- Kieffer E, Fukui S, Chiras J, Koskas F, Bahnini A, Cormier E. (2002). Spinal cord arteriography: a safe adjunct before descending thoracic or thoracoabdominal aortic aneurysmectomy. *J Vasc Surg.* Vol. 35, No. 2, 262-8.
- Kim JP, Goldberg MP, Choi DW. (1987). High concentrations of naloxone attenuate N-methyl-D-aspartate receptor-mediated neurotoxicity. *Eur J Pharmacol.* Vol. 138, No. 1, 133-6.
- Koshino T, Murakami G, Morishita K, Mawatari T, Abe T. (1999). Does the Adamkiewicz artery originate from the larger segmental arteries? *J Thorac Cardiovasc Surg.* Vol. 117, No. 5, 898-905.


- Kouchoukos NT, Masetti P, Murphy SF. (2003). Hypothermic cardiopulmonary bypass and circulatory arrest in the management of extensive thoracic and thoracoabdominal aortic aneurysms. *Semin Thorac Cardiovasc Surg.* Vol. 15, No. 4, 333-9.
- Kunihara T, Miyatake T, Kubota T, Suto Y, Shiiya N, Sasaki S, Murashita T, Matsui Y, Sakuma M, Yasuda K (1998). An Evaluation of Spinal Cord Ischemia of Rabbit by Near-infrared Spectrophotometry. *Ther Res.* Vol. 19, No. 7, 2155-60.
- Kunihara T, Sasaki S, Shiiya N, Ishikura H, Kawarada Y, Matsukawa A, Yasuda K. (2000). Lazaroid reduces production of IL-8 and IL-1 receptor antagonist in ischemic spinal cord injury. *Ann Thorac Surg.* Vol. 69, No. 3, 792-8.
- Kunihara T, Sasaki S, Shiiya N, Miyatake T, Mafune N, Yasuda K. (2001). Proinflammatory cytokines in cerebrospinal fluid in repair of thoracoabdominal aorta. *Ann Thorac Surg.* Vol. 71, No. 3, 801-6.
- Kunihara T, Shiiya N, Yasuda K. (2001). Changes in S-100 β proteins in the cerebrospinal fluid after thoracoabdominal aortic surgery. *J Thorac Cardiovasc Surg.* Vol. 122, No. 5, 1019-20.
- Kunihara T, Shiiya N, Matsui Y, Yasuda K. (2004). Preliminary Report of Transesophageal Monitoring of Spinal Cord Ischemia Using Near-Infrared Spectrophotometry. *J Cardiovasc Surg (Torino).* Vol. 45, No. 1, 95-6.
- Kunihara T, Matsuzaki K, Shiiya N, Saijo Y, Yasuda K. (2004). Naloxone lowers cerebrospinal fluid levels of excitatory amino acids after thoracoabdominal aortic surgery. *J Vasc Surg.* Vol. 40, No. 4, 681-90.
- Kunihara T, Shiiya N, Yasuda K. (2004). Strategy for spinal cord protection during thoracoabdominal aortic surgery. *Kyobu Geka.* Vol. 57, No. 4, 319-24.
- Kunihara T, Shiiya N, Matsuzaki K, Sata F, Matsui Y. (2008). Near-infrared spectrophotometry is useful to detect the beneficial pharmacological effects of alprostadil on spinal cord deoxygenation. *Ann Thorac Cardiovasc Surg.* Vol. 14, No. 6, 376-81.
- Kuniyoshi Y, Koja K, Miyagi K, Shimoji M, Uezu T, Arakaki K, Yamashiro S, Mabuni K, Senaha S, Nakasone Y. (2003) Prevention of postoperative paraplegia during thoracoabdominal aortic surgery. *Ann Thorac Surg.* Vol. 76, No. 5, 1477-84.
- Lang-Lazdunski L, Heurteaux C, Dupont H, Widmann C, Lazdunski M. (2000). Prevention of ischemic spinal cord injury: comparative effects of magnesium sulfate and riluzole. *J Vasc Surg.* Vol. 32, No. 1, 179-89.
- Laschinger JC, Cunningham JN Jr, Cooper MM, Krieger K, Nathan IM, Spencer FC. (1984). Prevention of ischemic spinal cord injury following aortic cross-clamping: use of corticosteroids. *Ann Thorac Surg.* Vol. 38, No. 5, 500-7.
- Marini CP, Nathan IM, Efron J, Cohen JR. (1997). Effect of nitroglycerin and cerebrospinal fluid drainage on spinal cord perfusion pressure and paraplegia during aortic cross-clamping. *J Surg Res.* Vol. 70, No. 1, 61-5.
- Maruyama R, Kamishima T, Shiiya N, Asano T, Matsuzaki K, Miyasaka K, Yasuda K. (2003). MDCT scan visualizes the Adamkiewicz artery. *Ann Thorac Surg.* Vol. 76, No. 4, 1308.
- Matsui Y, Goh K, Shiiya N, Murashita T, Miyama M, Ohba J, Gohda T, Sakuma M, Yasuda K, Tanabe T. (1994). Clinical application of evoked spinal cord potentials elicited by direct stimulation of the cord during temporary occlusion of the thoracic aorta. *J Thorac Cardiovasc Surg.* Vol. 107, No. 6, 1519-27.

- Miyamoto K, Ueno A, Wada T, Kimoto S (1960). A new and simple method of preventing spinal cord damage following temporary occlusion of the thoracic aorta by draining the cerebrospinal fluid. *J Cardiovasc Surg (Torino)*. Vol. 1, 188-97.
- Nakamura R, et al., (1994). Late-onset selective neuronal damage in the rat spinal cord induced by continuous intrathecal administration of AMPA. *Brain Res*. Vol. 654, No. 2, 279-85.
- Qayumi AK, Janusz MT, Dorovini-Zis K, Lyster DM, Jamieson WR, Poostizadeh A, Feeley EJ, Nikbakht-Sangari M. (1994). Additive effect of allopurinol and deferoxamine in the prevention of spinal cord injury caused by aortic crossclamping. *J Thorac Cardiovasc Surg*. Vol. 107, No. 5, 1203-9.
- Reece TB, Okonkwo DO, Ellman PI, Warren PS, Smith RL, Hawkins AS, Linden J, Kron IL, Tribble CG, Kern JA. (2004). The evolution of ischemic spinal cord injury in function, cytoarchitecture, and inflammation and the effects of adenosine A2A receptor activation. *J Thorac Cardiovasc Surg*. Vol. 128, No. 6, 925-32.
- Rokkas CK, Helfrich LR Jr, Lobner DC, Choi DW, Kouchoukos NT. (1994). Dextrorphan inhibits the release of excitatory amino acids during spinal cord ischemia. *Ann Thorac Surg*. Vol. 58, No. 2, 312-9.
- Rokkas CK, Kouchoukos NT. (2001). As originally published in 1994: dextrorphan inhibits the release of excitatory amino acids during spinal cord ischemia. Updated in 2001. *Ann Thorac Surg*. Vol. 71, No. 4, 1397-8
- Safi HJ, Campbell MP, Miller CC 3rd, Iliopoulos DC, Khojnejhad A, Letsou GV, Asimacopoulos PJ. (1997). Cerebral spinal fluid drainage and distal aortic perfusion decrease the incidence of neurological deficit: the results of 343 descending and thoracoabdominal aortic aneurysm repairs. *Eur J Vasc Endovasc Surg*. Vol. 14, No. 2, 118-24.
- Safi HJ, Miller CC 3rd, Azizzadeh A, Iliopoulos DC. (1997). Observations on delayed neurologic deficit after thoracoabdominal aortic aneurysm repair. *J Vasc Surg*. Vol. 26, No. 4, 616-22.
- Safi HJ, Winnerkvist A, Miller CC 3rd, Iliopoulos DC, Reardon MJ, Espada R, Baldwin JC. (1998). Effect of extended cross-clamp time during thoracoabdominal aortic aneurysm repair. *Ann Thorac Surg*. Vol. 66, No. 4, 1204-9.
- Safi HJ, Miller CC 3rd. (1999). Spinal cord protection in descending thoracic and thoracoabdominal aortic repair. *Ann Thorac Surg*. Vol. 67, No. 6, 1937-9
- Safi HJ, Miller CC 3rd, Huynh TT, Estrera AL, Porat EE, Winnerkvist AN, Allen BS, Hassoun HT, Moore FA. (2003). Distal aortic perfusion and cerebrospinal fluid drainage for thoracoabdominal and descending thoracic aortic repair: ten years of organ protection. *Ann Surg*. Vol. 238, No. 3, 372-80.
- Safi HJ, Estrera AL, Miller CC, Huynh TT, Porat EE, Azizzadeh A, Meada R, Goodrick JS. (2005). Evolution of risk for neurologic deficit after descending and thoracoabdominal aortic repair. *Ann Thorac Surg*. Vol. 80, No. 6, 2173-9.
- Sasaki S, Alessandrini F, Lodi R, McCully JD, LoCicero J. (1996). Improvement of pulmonary graft after storage for twentyfour hours by in vivo administration of lazaroïd U74389G: functional and morphologic analysis. *J Heart Lung Transplant*. Vol. 15, No. 1, 35- 42.

- Schepens MA, Defauw JJ, Hamerlijnc RP, De Geest R, Vermeulen FE. (1994) Surgical treatment of thoracoabdominal aortic aneurysms by simple crossclamping. Risk factors and late results. *J Thorac Cardiovasc Surg.* Vol. 107, No. 1, 134-42.
- Schepens MA, Heijmen RH, Ranschaert W, Sonker U, Morshuis WJ. (2009). Thoracoabdominal aortic aneurysm repair: results of conventional open surgery. *Eur J Vasc Endovasc Surg.* Vol. 37, No. 6, 640-5.
- Schittek A, Bennink GB, Cooley DA, Langford LA. (1992). Spinal cord protection with intravenous nimodipine. A functional and morphologic evaluation. *J Thorac Cardiovasc Surg.* Vol. 104, No. 4, 1100-5.
- Seibel PS, Theodore P, Kron IL, Tribble CG. (1993). Regional adenosine attenuates postischemic spinal cord injury. *J Vasc Surg.* Vol. 18, No. 2, 153-8.
- Shiia N, Yasuda K, Matsui Y, Sakuma M, Sasaki S. (1995). Spinal cord protection during thoracoabdominal aortic aneurysm repair: results of selective reconstruction of the critical segmental arteries guided by evoked spinal cord potential monitoring. *J Vasc Surg.* Vol. 21, No. 6, 970-5.
- Shiia N, Matsuzaki K, Kunihara T, Yasuda K. (2005). Use of a soft reservoir bag in a fully heparin-coated closed-loop cardiopulmonary bypass system for distal aortic perfusion during aortic surgery. *J Artif Organs.* Vol. 8, No. 2, 85-90.
- Shiia N, Matsuzaki K, Kunihara T, Sugiki H. (2006). Heparin reduction with the use of cardiotomy suction is associated with hyperfibrinolysis during distal aortic perfusion with a heparin-coated semi-closed cardiopulmonary bypass system. *J Artif Organs.* Vol. 9, No. 4, 214-9.
- Shiia N, Kunihara T, Matsuzaki K, Yasuda K. (2005). Evolving strategy and results of spinal cord protection in type I and II thoracoabdominal aortic aneurysm repair. *Ann Thorac Cardiovasc Surg.* Vol. 11, No. 3, 178-85.
- Shimizu H, Mori A, Yamada T, Ishikawa A, Okano H, Takeda J, Yozu R. (2010). Regional spinal cord cooling using a countercurrent closed-lumen epidural catheter. *Ann Thorac Surg.* Vol. 89, No. 4, 1312-3.
- Shine T & Nugent M. (1990). Sodium nitroprusside decreases spinal cord perfusion pressure during descending thoracic aortic cross-clamping in the dog. *J Cardiothorac Anesth.* Vol. 4, No. 2, 185-93.
- Strauch JT, Lauten A, Spielvogel D, Rinke S, Zhang N, Weisz D, Bodian CA, Griep RB. (2004). Mild hypothermia protects the spinal cord from ischemic injury in a chronic porcine model. *Eur J Cardiothorac Surg.* Vol. 25, No. 5, 708-15.
- Svensson LG, Klepp P, Hinder RA. (1986). Spinal cord anatomy of the baboon—comparison with man and implications for spinal cord blood flow during thoracic aortic cross-clamping. *S Afr J Surg.* Vol. 24, No. 1, 32-4.
- Svensson LG, Crawford ES, Hess KR, Coselli JS, Safi HJ. Experience with 1509 patients undergoing thoracoabdominal aortic operations. (1993). *J Vasc Surg.* Vol. 17, No. 2, 357-68.
- Svensson LG. New and future approaches for spinal cord protection. (1993). *Semin Thorac Cardiovasc Surg.* Vol. 9, No. 3, 206-21.
- Svensson LG, Hess KR, D'Agostino RS, Entrup MH, Hreib K, Kimmel WA, Nadolny E, Shahian DM. (1998). Reduction of neurologic injury after high-risk thoracoabdominal aortic operation. *Ann Thorac Surg.* Vol. 66, No. 1, 132-8.

- Svensson LG. (2005). Paralysis after aortic surgery: in search of lost cord function. *Surgeon*. Vol. 3, No. 6, 396-405.
- Tachibana T, Shiiya N, Kunihara T, Wakamatsu Y, Kudo AF, Ooka T, Watanabe S, Yasuda K. (2005). Immunophilin ligands FK506 and cyclosporine A improve neurologic and histopathologic outcome after transient spinal cord ischemia in rabbits. *J Thorac Cardiovasc Surg*. Vol. 129, No. 1, 123-8.
- Uotani K, Yamada N, Kono AK, Taniguchi T, Sugimoto K, Fujii M, Kitagawa A, Okita Y, Naito H, Sugimura K. (2008). Preoperative visualization of the artery of Adamkiewicz by intra-arterial CT angiography. *AJNR Am J Neuroradiol*. Vol. 29, No. 2, 314-8.
- Vacanti FX, Ames A 3rd. (1984). Mild hypothermia and Mg⁺⁺ protect against irreversible damage during CNS ischemia. *Stroke*. Vol. 15, No. 4, 695-98.
- Wakamatsu Y, Shiiya N, Kunihara T, Watanabe S, Yasuda, K. (2001). The adenosine triphosphate-sensitive potassium channel opener nicorandil protects the ischemic rabbit spinal cord. *J Thorac Cardiovasc Surg* Vol. 122, No. 4, 728-33.
- Wynn MM, Mell MW, Tefera G, Hoch JR, Acher CW. (2009). Complications of spinal fluid drainage in thoracoabdominal aortic aneurysm repair: a report of 486 patients treated from 1987 to 2008. *J Vasc Surg*. Vol. 49, No. 1, 29-34.
- Yone K, Sakou T, Kawauchi Y. (1999). The effect of Lipo prostaglandin E1 on cauda equina blood flow in patients with lumbar spinal canal stenosis: myeloscopic observation. *Spinal Cord*. Vol. 37, No. 4, 269-74.
- Yoshioka K, Niinuma H, Ehara S, Nakajima T, Nakamura M, Kawazoe K. (2006). MR angiography and CT angiography of the artery of Adamkiewicz: state of the art. *Radiographics*. Vol. 26, Suppl. 1, S63-73.
- Zoli S, Roder F, Etz CD, Brenner RM, Bodian CA, Lin HM, Di Luozzo G, Griep RB. (2010). Predicting the risk of paraplegia after thoracic and thoracoabdominal aneurysm repair. *Ann Thorac Surg*. Vol. 90, No. 4, 1237-44.

IntechOpen



Diagnosis and Treatment of Abdominal and Thoracic Aortic Aneurysms Including the Ascending Aorta and the Aortic Arch

Edited by Prof. Reinhart Grundmann

ISBN 978-953-307-524-2

Hard cover, 208 pages

Publisher InTech

Published online 22, June, 2011

Published in print edition June, 2011

This book considers diagnosis and treatment of abdominal and thoracic aortic aneurysms. It addresses vascular and cardiothoracic surgeons and interventional radiologists, but also anyone engaged in vascular medicine. The book focuses amongst other things on operations in the ascending aorta and the aortic arch. Surgical procedures in this area have received increasing attention in the last few years and have been subjected to several modifications. Especially the development of interventional radiological endovascular techniques that reduce the invasive nature of surgery as well as complication rates led to rapid advancements. Thoracoabdominal aortic aneurysm (TAAA) repair still remains a challenging operation since it necessitates extended exposure of the aorta and reimplantation of the vital aortic branches. Among possible postoperative complications, spinal cord injury (SCI) seems one of the most formidable morbidities. Strategies for TAAA repair and the best and most reasonable approach to prevent SCI after TAAA repair are presented.

How to reference

In order to correctly reference this scholarly work, feel free to copy and paste the following:

Takashi Kunihara, Suguru Kubota, Satoru Wakasa, Norihiko Shiiya and Yoshiro Matsui (2011). Prevention of Spinal Cord Injury After Thoracoabdominal Aortic Aneurysm Repair, *Diagnosis and Treatment of Abdominal and Thoracic Aortic Aneurysms Including the Ascending Aorta and the Aortic Arch*, Prof. Reinhart Grundmann (Ed.), ISBN: 978-953-307-524-2, InTech, Available from: <http://www.intechopen.com/books/diagnosis-and-treatment-of-abdominal-and-thoracic-aortic-aneurysms-including-the-ascending-aorta-and-the-aortic-arch/prevention-of-spinal-cord-injury-after-thoracoabdominal-aortic-aneurysm-repair>

INTECH
open science | open minds

InTech Europe

University Campus STeP Ri
Slavka Krautzeka 83/A
51000 Rijeka, Croatia
Phone: +385 (51) 770 447
Fax: +385 (51) 686 166
www.intechopen.com

InTech China

Unit 405, Office Block, Hotel Equatorial Shanghai
No.65, Yan An Road (West), Shanghai, 200040, China
中国上海市延安西路65号上海国际贵都大饭店办公楼405单元
Phone: +86-21-62489820
Fax: +86-21-62489821

© 2011 The Author(s). Licensee IntechOpen. This is an open access article distributed under the terms of the [Creative Commons Attribution 3.0 License](#), which permits unrestricted use, distribution, and reproduction in any medium, provided the original work is properly cited.

IntechOpen

IntechOpen