

We are IntechOpen, the world's leading publisher of Open Access books Built by scientists, for scientists

4,800

Open access books available

122,000

International authors and editors

135M

Downloads

Our authors are among the

154

Countries delivered to

TOP 1%

most cited scientists

12.2%

Contributors from top 500 universities



WEB OF SCIENCE™

Selection of our books indexed in the Book Citation Index
in Web of Science™ Core Collection (BKCI)

Interested in publishing with us?
Contact book.department@intechopen.com

Numbers displayed above are based on latest data collected.

For more information visit www.intechopen.com



***Mycoplasma pneumoniae* as an Under- Recognized Agent of Vasculitic Disorders**

Mitsuo Narita

*Department of Pediatrics, Sapporo Tokushukai Hospital
Japan*

1. Introduction

Mycoplasma pneumoniae, commonly known as a major causative agent of primary atypical pneumonia, also causes various kinds of extrapulmonary manifestations involving almost all the organs of the human body. The author has classified the extrapulmonary manifestations due to *M. pneumoniae* infection into three categories: the first is a direct type in which locally induced cytokines play a role, the second is an indirect type in which immune modulation such as autoimmunity plays a role, and the third is a vascular occlusion type in which vasculitis and/or thrombosis with or without systemic hypercoagulable state plays a role [Narita, 2009, 2010]. This classification system is intended to facilitate the understanding of the pathogenesis of extrapulmonary manifestations due to *M. pneumoniae* infection. A diagram depicting the possible ways in which *M. pneumoniae* can induce these three types of extrapulmonary manifestations in relation to the possible pathomechanism of pneumonia is shown in Fig 1. Further concrete explanations of each mechanism, based on the accumulated in-vitro and in-vivo data, are provided in the following sections. Of particular interest is the fact that *M. pneumoniae* can cause many kinds of vasculitic/thrombotic disorders. *Mycoplasma pneumoniae* may locally affect a vascular wall by inducing cytokines and chemokines such as tumor necrosis factor- α and interleukin-8, which cause local vasculitic and/or thrombotic vascular occlusion without systemic hypercoagulable state. Alternatively, generalized thrombotic vascular occlusion can occur as a result of a systemic hypercoagulable state which is in turn a consequence of immune modulation leading to the activation of chemical mediators such as complements and fibrin D-dimer.

Although it is already well known that *M. pneumoniae* can cause a few coagulation abnormality disorders such as disseminated intravascular coagulation and stroke, *M. pneumoniae* remains under-recognized as a causative agent for many other vasculitic/thrombotic disorders involving various organs of the human body. One reason for this must be that the ability of *M. pneumoniae* to cause vasculitic/thrombotic vascular disorders through the local operation of chemical mediators such as cytokines in the absence of an apparent systemic hypercoagulable state is not yet widely known.

In this chapter, the author presents organ-specific and systemic manifestations of vasculitic/thrombotic disorders that may be associated with *M. pneumoniae* infection.

Comments are made principally on the etiology by which *M. pneumoniae* acts as a pathogenic agent for each disease.

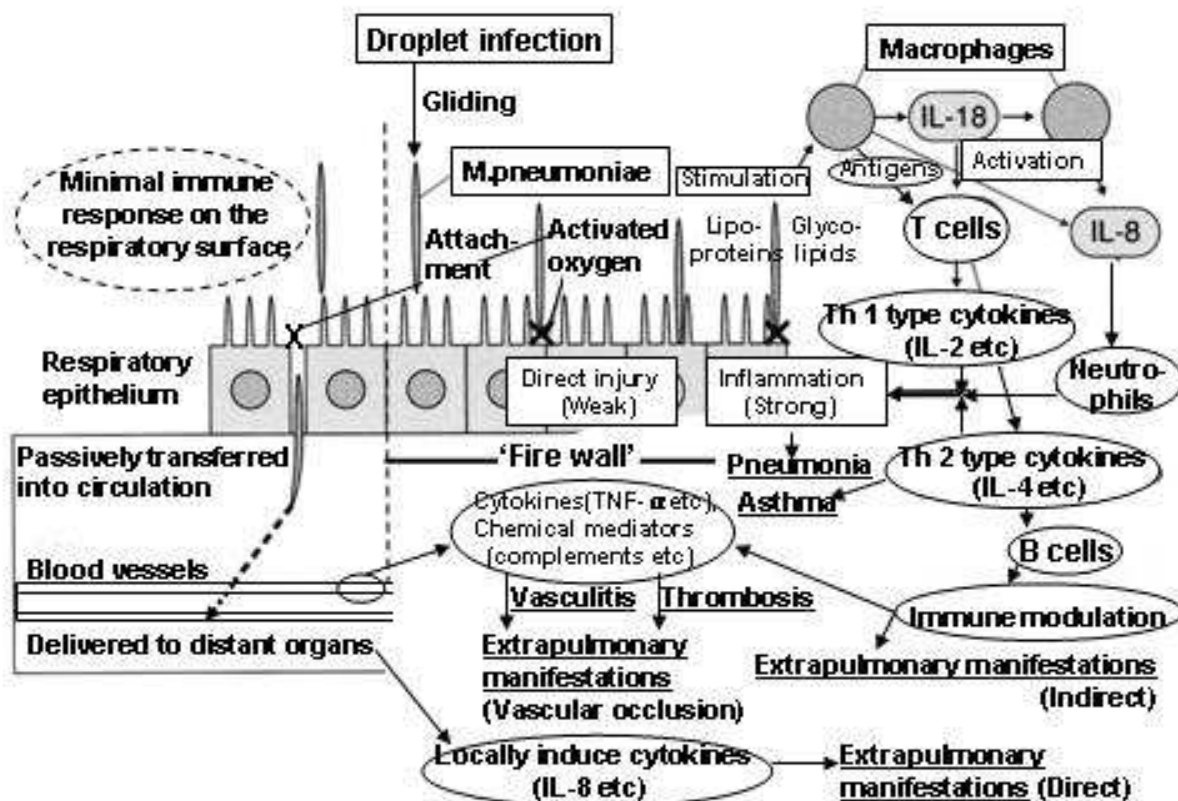


Fig. 1. Pathomechanism of vasculitic/thrombotic disorders caused by *M. pneumoniae* infection (Modified from ref. Narita, 2009. For details, see text).

2. Mechanism of vasculitic disorders due to *M. pneumoniae* infection

2.1 Respiratory infection and hematogenous dissemination

Mycoplasma pneumoniae is one of the smallest free-living bacteria. It possesses only a minor ability to injure respiratory epithelial cells by producing an excess of activated oxygen within the infected cells [for review, see Waites & Talkington, 2004]. Recent evidence has shown that *M. pneumoniae* produces the community acquired respiratory distress syndrome toxin, but its pathogenic role in human illness still remains to be elucidated [Hardy et al., 2009; Kannan & Baseman, 2006]. Nevertheless, *M. pneumoniae* is a major pathogen of primary atypical pneumonia as well as a number of extrapulmonary diseases. In this context, many previous works have disclosed that the cell membrane of *M. pneumoniae* contains lipoproteins which are potent inducers of cytokines equivalent to bacterial lipopolysaccharides [for review, see Sánchez-Vargas & Gómez-Duarte, 2008; Yang et al., 2004]. Thus it is currently understood that *M. pneumoniae* pneumonia results from the operation of the host immune system, specifically of various kinds of cytokines, rather than from direct injury by the organism itself; in other words, *M. pneumoniae* pneumonia develops via immune pathogenesis.

Following an initial droplet infection to the lower respiratory tract below the larynx, *M. pneumoniae* begins to propagate on the respiratory surface with ciliated epithelium [Krunkosky et al., 2007]. This event facilitates non-specific recognition of the organism by the innate immunity of the host through Toll-like receptors 1, 2, and 6, among which Toll-like receptor 2 plays a major role in initiating intracellular signal transmission [Shimizu, 2005]. *Mycoplasma pneumoniae* infection then leads to pneumonia by inducing various kinds of cytokines. Among a number of cytokines reported to be associated with the pathomechanism of *M. pneumoniae* pneumonia, the author and coworkers have demonstrated that the macrophage-derived cytokines interleukin-18 and interleukin-8 play significant roles in the development of pneumonia and are directly related to disease severity [Narita et al., 2000, 2001a; Tanaka et al., 2002]. Interleukin-18 is an immune regulatory cytokine that functions as an activator of T cells and a subsequent cascade of T helper-1 and T helper-2 type cytokines [Tanaka et al., 1996]. Interleukin-8 is an inflammatory cytokine and functions as an activator of neutrophils. Several lines of recent in-vitro evidence have supported the pathogenic importance of interleukin-8 in the development of the clinical picture of *M. pneumoniae* respiratory infection [Chmura et al., 2008; Sohn et al., 2005; Yang et al., 2002]. From this perspective, the activation of interleukin-8 by *M. pneumoniae* is one of the key steps in inducing the vasculitic disorders which are the main subject of this chapter.

As regards the presence of pneumonia in relation to the development of extrapulmonary diseases, the author and coworkers have found, using polymerase chain reaction methodology [Narita et al., 1992], that the genome of *M. pneumoniae* can be detected more frequently in serum from patients without pneumonia than in serum from patients with pneumonia [Narita et al., 1996]. This means that pneumonia, which is a consequence of the local host immune response occurring on the respiratory surface, plays an important role as a kind of fire-wall preventing dissemination of the organism beyond the respiratory tract [Cartner et al., 1998; Tanaka et al., 1996]. In this regard, it is important to note that direct-type extrapulmonary manifestations not infrequently occur in the absence of pneumonia, which is a hallmark of mycoplasmal infection. This must be another reason why *M. pneumoniae* is under-recognized as a vasculitic agent: in the absence of pneumonia, mycoplasmal infection is not suspected and the patient is not further tested for *M. pneumoniae* serology.

2.2 Direct mechanisms of vasculitic/thrombotic vascular occlusion

M. pneumoniae, following its passive transfer into the circulation through the gaps that result from direct yet modest injury to the respiratory epithelial cells, is delivered to the distant vessels and organs, where it activates various inflammatory substances which then elicit vasculitis. These inflammatory substances include interleukin-8, tumor necrosis factor- α , macrophage inflammatory peptide-1 α [Hardy et al., 2001], intercellular adhesion molecule-1 [Krunkosky et al., 2007], and regulated upon activation, normal T cells expression and secreted [Dakhama et al., 2003], among others. Tumor necrosis factor- α has been observed to be induced by *M. pneumoniae* in vitro from an early period of investigation [Arai et al., 1990; Kita et al., 1992]. This cytokine, along with interleukin-8, must play a pivotal role in eliciting vasculitic/thrombotic vascular occlusion. In this context, it is of some interest that the community acquired respiratory distress syndrome toxin can also induce the production of interleukin-8, macrophage inflammatory peptide-1 α , and regulated upon activation, normal T cells expression and secreted [Hardy et al., 2009]. This toxin also might play some role in

the development of vascular disorders. As regards the vascular occlusion-type manifestations with direct mechanisms, only occasionally has *M. pneumoniae* been found by culture or by polymerase chain reaction at the site of disease manifestation, typically, in the cerebrospinal fluid from patients with central nervous system manifestations.

2.3 Indirect mechanisms of vasculitic/thrombotic vascular occlusion

Mycoplasma pneumoniae contains potent immunogenic substances such as glycolipids, glycoproteins, and phospholipids within its cytoplasm. Macrophages, following phagocytosis of the organism, present these various kinds of mycoplasmal antigens to immunocompetent cells causing immune modulation which subsequently elicits autoimmunity through these antigens' molecular mimicry of various human cell components [for review, see Yang et al., 2004; Waites & Talkington, 2004]. From the perspective of vasculopathy due to *M. pneumoniae*, the most important aspect of this process must be the production of antiphospholipid (anticardiolipin) antibodies [Graw-Panzer et al., 2009; Nagashima et al., 2010; Snowden et al., 1990; Witmer et al., 2007]. Production of these antibodies is well known to occur during the course of autoimmune disorders such as systemic lupus erythematosus and to induce hypercoagulable state resulting in vasculopathy. As mentioned in the following sections, this ability of *M. pneumoniae* to induce antiphospholipid (anticardiolipin) antibodies is an important key in unraveling the indirect pathomechanisms of the vasculitic disorders caused by *M. pneumoniae*.

Mycoplasma pneumoniae can also form immune complexes [Biberfeld & Norberg, 1974; Mizutani & Mizutani, 1984], which activate complements and platelets, inducing coagulopathy, or affect the vascular epithelium, eliciting vasculitis. This ability of *M. pneumoniae* to form immune complexes is another important key to understanding the pathomechanisms of the vasculitic disorders caused by *M. pneumoniae*. To summarize, the immune modulations mentioned in this section can in several ways activate platelets, complements, and coagulation factors, leading to systemic or local hypercoagulable state. In vascular occlusion-type manifestations with indirect mechanisms, *M. pneumoniae* itself cannot typically be found at disease manifestation sites, though this is not the case in disease manifestations with direct mechanisms.

3. Vasculitic/thrombotic disorders due to *M. pneumoniae* infection

In Table 1, vascular occlusion-type extrapulmonary manifestations due to *M. pneumoniae* infection are classified according to type of pathomechanism, that is, direct or indirect, and according to the organ system which is mainly affected. Kawasaki disease, which involves multiple-organs in its manifestations, which include skin rash, lymphadenitis, and coronary aneurysm, is included in the cardiovascular category because of its disease severity.

In the following sections, comments are made on how these disorders can be considered consequences of *M. pneumoniae* infection. Since *M. pneumoniae* is a ubiquitous agent in the general population, the possibility of accidental coinfection by *M. pneumoniae* during the course of an unassociated disease should always be taken into account. One must remember to distinguish clearly between what *M. pneumoniae* can do and what it cannot do on the basis of its biological abilities. This chapter preferentially includes papers reporting vasculitic/thrombotic disorders for which at least one possible pathomechanism could reasonably be considered.

System	Direct mechanism	Indirect mechanism
Cardiovascular		Kawasaki disease, Cardiac thrombus, Temporal arteritis
Dermatological		Anaphylactoid purpura, Cutaneous vasculitis
Digestive		Pancreatitis
Hematological/ Hematopoietic		Disseminated intravascular coagulation, Thrombocytopenia, Splenic infarct
Musculoskeletal	Arthritis/ Arthropathy*, Rhabdomyolysis*	Arthritis/ Arthropathy*, Rhabdomyolysis*
Nervous	Stroke*, Striatal necrosis, Psychological disorders, Acute disseminated encephalomyelitis*, Transverse myelitis*	Stroke*, Acute disseminated encephalomyelitis*, Transverse myelitis*, Facial nerve palsy
Respiratory		Pulmonary embolism
Sensory	Sudden hearing loss	
Urogenital	Priapism	

* Mechanisms of both types (direct and indirect) can be postulated for these disorders.

Table 1. Vasculitic/thrombotic disorders caused by *M. pneumoniae* infection

3.1 Cardiovascular system

Although the existence of a link between acute or chronic *M. pneumoniae* infection and the development of atherosclerosis or coronary heart disease has been a matter for debate in the past, a connection between these conditions now seems less likely on the basis of recent evidence [Barski et al., 2010; Weiss et al., 2006] and is not included in this chapter. This question must be answered with certainty through future research.

3.1.1 Kawasaki disease

Kawasaki disease is a febrile illness mainly affecting infants and younger children; it is characterized by persistent fever (lasting longer than 5 days) that is nonresponsive to antibiotics; bilateral ocular conjunctivitis; redness of the lips, tongue (strawberry tongue) and oral cavity; changes in the peripheral extremities (indurative edema and desquamation); polymorphous exanthema of the body; and nonpurulent cervical lymph node swelling. It has been considered a systemic vasculitic disease with a predilection for the coronary arteries, resulting in the development of coronary aneurysm in the most severe cases [for review, see Pinna et al., 2008; Wood & Tulloh, 2009]. Though only a very small number of cases have been reported from Western countries [Leen & Ling, 1996; Vitale et al., 2010], reports of Kawasaki disease in association with *M. pneumoniae* infection are not infrequent in the Japanese literature. Kawasaki disease was first described from Japan [Kawasaki et al., 1974] and must have an inclination to the Asian ethnicity. Based on this assumption, there

may be some inherent difference in genetic background in terms of the link between *M. pneumoniae* infection and susceptibility to Kawasaki disease. Although the pathomechanism of Kawasaki disease itself is not yet fully understood, the disease is generally believed to be immune-mediated [Pinna et al., 2008; Wood & Tulloh, 2009]. *Mycoplasma pneumoniae* has several arrays for immunomodulation, including cytokine production and T cell/B cell activation, and thereby could be a trigger of Kawasaki disease.

According to the previous case reports, which are mostly from Japan, pneumonia may or may not be present in *M. pneumoniae* infection-associated Kawasaki disease. Thus, even in the absence of pneumonia, *M. pneumoniae* infection must be considered in Kawasaki disease particularly when it is encountered during an epidemic of *M. pneumoniae* infection. Coronary arteries are not severely affected in most cases [Leen & Ling, 1996; Narita et al., 2001a; Sakai et al., 2007]; there has been only one exception, namely, an aneurysm in a single case reported from Taiwan [Wang et al., 2001].

3.1.2 Cardiac thrombus

Although it is only a single case to date, a large cardiac thrombus in the right ventricle has recently been reported in association with *M. pneumoniae* infection; it was successfully removed through cardiac surgery [Nagashima et al., 2010]. In this case, antiphospholipid antibodies (anticardiolipin IgM) were detected in the acute phase of infection but disappeared subsequently during convalescence; this observation supports the idea of a causal relation between *M. pneumoniae* infection and the production of antiphospholipid antibodies.

3.1.3 Temporal arteritis

One epidemiological study in Denmark has shown a close link between distinct peak incidences of temporal arteritis and two epidemics of *M. pneumoniae* infection [Elling et al., 1996]. Although neither additional case reports nor subsequent further clinical studies seem to exist, it is highly possible given the ability of *M. pneumoniae* to elicit vasculitis that *M. pneumoniae* is also a triggering agent for temporal arteritis.

3.2 Dermatological system

3.2.1 Anaphylactoid purpura

Anaphylactoid purpura, also called allergic purpura or Schönlein-Henoch purpura, is an allergic inflammation of the systemic capillary vessels most commonly affecting children, which is characterized by nonthrombocytopenic purpura, most remarkably on the bilateral lower extremities. This systemic disorder of the capillary vessels is not restricted to the skin; rather it also leads to microvascular bleeding manifesting as arthropathy (pain, swelling), gastrointestinal symptoms (severe abdominal pain, intestinal bleeding), and renal involvement (hematuria, nephritis) etc. It is possible that several infections can elicit these allergic reactions, and *M. pneumoniae*-infection-associated anaphylactoid purpura has sporadically been reported [Ghosh & Clements, 1992; Kano et al., 2007]. Considering the immunomodulatory properties of *M. pneumoniae*, it is reasonable to assume that *M. pneumoniae* can cause anaphylactoid purpura.

3.2.2 Cutaneous vasculitis

A few cases of cutaneous vasculitis, which is characterized by skin manifestations represented by erythematous macropapular rash resembling that observed in erythema

multiforme, and by histological findings compatible with vasculitis such as leukocytoclastic vasculitis, have been reported in association with *M. pneumoniae* infection. Interestingly, cutaneous vasculitis due to *M. pneumoniae* was always accompanied by involvement of other organs; specifically, retinal vasculitis [Greco et al., 2007], polyarthrititis [Perez et al., 1997], encephalitis [Perez & Montes, 2002], and acute respiratory distress syndrome, erythema multiforme, and pancreatitis [Van Bever et al., 1992]. This suggests either that skin biopsy, which is essential for the diagnosis of cutaneous vasculitis, is not likely to be performed unless other systemic diseases are present, or that cutaneous vasculitis occurs inherently as a part of systemic inflammation. In fact, immune complex-mediated activation of platelets has been postulated as an etiology for it [Perez & Montes, 2002].

3.3 Digestive system

3.3.1 Pancreatitis

Pancreatitis, which is often accompanied by other diseases affecting multiple organs [Daxböck et al., 2002; Van Bever et al., 1992], has been included among the extrapulmonary manifestations of *M. pneumoniae* infection, but its exact etiology when associated with *M. pneumoniae* infection remains unknown. Although an autoimmune-mediated mechanism has been postulated, no concrete evidence supporting this has been obtained. Van Bever et al. have suggested that pancreatitis is a consequence of ischemia, that is, persistent shock [Van Bever et al., 1992], in which case it could in a broad sense be classified as a vascular occlusion (cessation of blood supply)-type extrapulmonary manifestation.

3.4 Hematological/Hematopoietic system

3.4.1 Disseminated intravascular coagulation

Disseminated intravascular coagulation is a representative vascular occlusion-type extrapulmonary manifestation [Chryssanthopoulos et al., 2001; De Vos et al., 1974; Koletsky & Weinstein, 1980; Kountouras et al., 2003; Maisel et al., 1967; Nilsson et al., 1971]. Although the exact mechanism of this disorder when it occurs in association with *M. pneumoniae* infection remains unclear, it must be a consequence of some kind of immune dysregulation, perhaps of the release of coagulative substances (i.e. thromboplastin) from damaged lung tissue [Maisel et al., 1967; Nilsson et al., 1971], immune complex-mediated activation of complements [Chryssanthopoulos et al., 2001; De Vos et al., 1974], or stimulation of procoagulant activity among mononuclear cells, which can be induced by lipoglycans of *M. pneumoniae* [Fumarola, 1997]. Among those disorders that arise due to *M. pneumoniae* infection but are fundamentally benign in nature, disseminated intravascular coagulation is one of the most serious conditions, as it can lead to multiorgan failure with an occasional fatal outcome.

3.4.2 Thrombocytopenia/Thrombocytopenic purpura

Enough cases of thrombocytopenia with or without purpura due to *M. pneumoniae* infection have been reported that literature reviews have been published on this subject [Okoli et al., 2009; Venkatesan et al., 1996]. In one case, isolated thrombocytopenia preceded disseminated intravascular coagulation [Chiou et al., 1997]. Several immune-mediated etiologies have been considered, including the production of cross-reactive antibodies between mycoplasmal antigens and the von Willebrand factor-cleaving metalloprotease [Bar

Meir et al., 2000], microvascular platelet thrombosis [Cameron et al., 1992], the production of anti-platelet antibodies of some kind [Chen et al., 2004; Venkatesan et al., 1996], and the production of autoantibodies to the I antigen, which is expressed not only on erythrocytes but also on platelet surfaces [Gursel et al., 2009]. The formation of immune complexes may also play a role in the pathomechanism [Veenhoven et al., 1990].

Hemophagocytic syndrome, which is characterized by erythrophagocytosis in the bone marrow and believed to be a consequence of immune dysregulation, has been reported in association with *M. pneumoniae* infection. Although hemophagocytic syndrome in itself is not a vasculitic disease, this disorder predisposes patients to thrombocytopenia through thrombophagocytosis with hyperactivation of cytokines [Mizukane et al., 2001] or through formation of microthrombi [Bruch et al., 2001].

3.4.3 Splenic infarct

One reported case of splenic infarct occurred during the course of *M. pneumoniae* infection and was associated with the production of antiphospholipid antibodies [Witmer et al., 2007]. It must be emphasized that although an autoimmune etiology of this type occurring in association with *M. pneumoniae* infection has been undetectable to date, so that the possibility of its existence has been overlooked, such an etiology might underlie several thrombotic disorders involving various organs other than the spleen.

3.5 Musculoskeletal system

3.5.1 Arthritis/arthropathy

Arthropathy is frequently encountered during the course of systemic diseases which affect the microvasculature of large joints such as anaphylactoid purpura or thrombocytopenic purpura, both of which have been mentioned in preceding sections. Apart from this, arthritis is a common manifestation of *M. pneumoniae* infection [Sánchez-Vargas & Gómez-Duarte, 2008; Waites & Talkington, 2004]. Both monoarthritis and polyarthritis have been reported. It is possible that local inflammation elicited by *M. pneumoniae* through the function of cytokines contributes to the disease manifestation affecting the microvasculature of joints.

3.5.2 Rhabdomyolysis

Rhabdomyolysis is characterized by swollen, painful muscles, elevated serum creatine phosphokinase concentrations, hyperkalaemia, hypocalcaemia, and myoglobinuria occasionally leading to renal dysfunction. Infections have been included in the panel of causes, and *M. pneumoniae* infection-associated rhabdomyolysis has not infrequently been reported [Berger & Wadowksy, 2000; Daxböck et al., 2002; Decaux et al., 1980; Minami et al., 2003, Rothstein & Kenny, 1979; Weng et al., 2009]. A central role in the development of this disease condition has been assigned to tumor necrosis factor- α , which can cause acute proteolysis [Knochel, 1993] and which can be induced by *M. pneumoniae*. Microthrombosis has also been identified as a possible contributing factor to disease progression [Knochel, 1993]. On an interesting related note, rhabdomyolysis due to *M. pneumoniae* infection has occasionally been accompanied by neurological manifestations, in one case with acute disseminated encephalomyelitis [Decaux et al., 1980] and in two cases with transverse myelitis [Rothstein & Kenny, 1979; Weng et al., 2009]; the etiology of both of these

neurological manifestations are presumed to involve vasculopathy (see next section). Regardless of whether they have an etiological link with *M. pneumoniae*-associated rhabdomyolysis, these neurological manifestations deserve further study on the assumption that there are common pathogenetic factors leading to vascular damage.

3.6 Nervous system

Nervous system manifestations are the most frequently reported type of extrapulmonary manifestations due to *M. pneumoniae* infection. *Mycoplasma pneumoniae* can cause neurologic symptoms through vasculitis or vascular occlusion with or without systemic hypercoagulative state. With regard to direct mechanisms, the author and coworkers have demonstrated that interleukin-6 and interleukin-8 play a significant role in the development of neurologic manifestations [Narita et al., 2005]. Moreover, interleukin-6 and interleukin-8 must be produced intrathecally, because elevated levels of these cytokines were observed in acute-phase cerebrospinal fluids without concomitant elevation in sera [Narita et al., 2005]. Rather unexpectedly, tumor necrosis factor- α and interferon- γ , which are the key cytokines in the development of neurologic diseases associated with bacterial or viral infections, were not elevated at all in acute-phase cerebrospinal fluids from patients with *M. pneumoniae* infection. These observations suggest that the pathomechanisms involved in mycoplasmal central nervous system manifestations are distinct from those involved in central nervous system diseases due to bacterial or viral infections.

3.6.1 Stroke

Stroke can occur in children [Fu et al., 1998; Lee et al., 2009; Leonardi et al., 2005; Ovetchkine et al., 2002; Parker et al., 1981; Tanir et al., 2006; Visudhiphan et al., 1992] as well as in adults [Mulder & Spierings, 1987; Padovan et al., 2001; Senda et al., 2010; Snowden et al., 1990; Sočan et al., 2001; Sotgiu et al., 2003]. The middle cerebral arteries are most often affected [Fu et al., 1998; Leonardi et al., 2005; Mulder & Spierings, 1987; Parker et al., 1981; Senda et al., 2010; Sotgiu et al., 2003], though the internal carotid arteries are affected in a few cases [Lee et al., 2009; Tanir et al., 2006; Visudhiphan et al., 1992]. Although the presence of systemic hypercoagulable state has been reported in a few cases, evidenced by disseminated intravascular coagulation [Mulder & Spierings, 1987] or by the production of antiphospholipid (anticardiolipin) antibodies [Senda et al., 2010; Snowden et al., 1990; Tanir et al., 2006], most cases occur in the absence of such conditions. Accordingly, many authors have suggested the presence of local vasculitis leading to vascular occlusion as an etiology. In fact, *M. pneumoniae* was isolated from the cerebrospinal fluid of a stroke patient [Sočan et al., 2001], and its genome has been detected in the cerebrospinal fluid as well [Padovan et al., 2001], reinforcing the theory of a direct mechanism. In addition, a case of multiple stenosis in the entire right Sylvian territory, suggesting the presence of vasculitis, has been reported [Ovetchkine et al., 2002]. Hematogenously-transferred *M. pneumoniae* must elicit cerebral vasculitis through the operation of inflammatory cytokines such as interleukin-8.

3.6.2 Striatal necrosis

Striatal necrosis is a peculiar central nervous system disease characterized by alteration of consciousness, extrapyramidal symptoms, and magnetic resonance imaging abnormality of

the bilateral striata (the caudate and putamen nuclei). It has been reported in association with *M. pneumoniae* infection [Sakoulas, 2001; Saitoh et al., 1993; van Buijen & Uhl, 2003; Zambrino et al., 2000]. Chorea or choreiform movements may be a neurological consequence of striatal damage [Al-Mateen et al., 1988; Decaux et al., 1980; Zambrino et al., 2000]. Concerning its etiology, it has been reported that no patients with *M. pneumoniae*-associated striatal necrosis have also exhibited systemic hypercoagulable state. A similar disease called acute necrotizing encephalopathy affecting the bilateral thalami is believed to stem from vascular injury in the absence of a thrombotic mechanism [Mizuguchi et al., 1995], and a few cases of bilateral thalamic necrosis strongly resembling acute necrotizing encephalopathy have been reported in association with *M. pneumoniae* infection [Ashtekar et al., 2003; Perez et al., 2002]. It can reasonably be postulated that the pathomechanism underlying striatal necrosis must be local vasculitis induced by *M. pneumoniae* through the operation of cytokines and chemokines and leading eventually to vascular occlusion. In fact, cerebrospinal fluid from a patient with this disease was found to contain the genome of *M. pneumoniae* [Saitoh et al., 1993], which suggested a direct mechanism. Moreover, two reported cases of the involuntary movement disorder Tourette syndrome have been accompanied by the detectable presence of the *M. pneumoniae* genome in cerebrospinal fluid [Müller et al., 2000]. This strongly suggests that Tourette syndrome associated with *M. pneumoniae* infection is a result of vasculopathy in the basal ganglia resulting from a direct type mechanism inducing vascular occlusion. The accumulated evidence strongly suggests a vasculitic vascular occlusion mechanism for extrapyramidal diseases with involuntary movements as common manifestations.

3.6.3 Psychological disorders

Kluver-Bucy syndrome is a rare neurobehavioral syndrome which has been described in association with several neurologic disorders that cause destruction or dysfunction of the temporal lobe(s). It is characterized by psychic blindness, a strong urge to examine all subjects by mouth, and altered sexual behavior, among others. One case has been reported in association with *M. pneumoniae* infection [Auvichayapat et al., 2006]. This disorder was originally reported in rhesus monkeys following temporal lobectomy. It can reasonably be assumed that the transient interruption of blood supply to the temporal lobe caused by *M. pneumoniae* infection elicits the clinical manifestation of Kluver-Bucy syndrome.

3.6.4 Acute disseminated encephalomyelitis

Acute disseminated encephalomyelitis is a life-threatening disease which involves extensive lesions spreading over the brain and spinal cord. Because of its diverse distribution of affected areas, an indirect mechanism has been postulated, namely, immune complex-mediated vasculopathy [Behan et al., 1986; Guleria et al., 2005; Gupta et al., 2009]. On the other hand, recent studies on patients with acute disseminated encephalomyelitis have demonstrated the presence of *M. pneumoniae* genome in the cerebrospinal fluid [Matsumoto et al., 2009; Riedel et al., 2001; Yiş et al., 2008], or the presence of *M. pneumoniae* antigens inside the macrophages in the brain tissue [Stamm et al., 2008]. Thus it is highly possible that a direct mechanism, namely, vasculitis as a consequence of cytokine activation by *M. pneumoniae*, is responsible for some instances of acute disseminated encephalomyelitis.

3.6.5 Transverse myelitis

As in the case of acute disseminated encephalomyelitis, indirect immunological mechanisms such as immune complex-mediated injury leading to vasculopathy have been postulated as etiologies for transverse myelitis [Behan et al., 1986; Tsiodras et al., 2006]. As in acute disseminated encephalomyelitis, recent studies using polymerase chain reaction have reported the successful detection of the genome of *M. pneumoniae* in cerebrospinal fluid from patients with transverse myelitis [Abele-Horn et al., 1998; Goebels et al., 2001]. The possibility that vasculitis as a consequence of local cytokine activation at the site of inflammation by *M. pneumoniae* is an etiology of transverse myelitis must not be ignored.

3.6.6 Facial nerve palsy

A single case of facial nerve palsy in association with *M. pneumoniae* infection with production of antiphospholipid antibodies has been reported [Snowden et al., 1990]. This suggests that vasculopathy of the peripheral vessels resulting from the production of these autoantibodies leading to neural damage can be a cause of cranial, and possibly also peripheral, nerve palsies.

3.7 Respiratory system

3.7.1 Pulmonary embolism

A few cases of pulmonary embolism have been reported in association with *M. pneumoniae* infection [Graw-Panzer et al., 2009; Sterner and Biberfeld, 1969]. In one case with a documented popliteal venous thrombosis, the production of antiphospholipid (anticardiolipin) antibodies was demonstrated to be an underlying mechanism [Graw-Panzer et al., 2009]. As this chapter has repeatedly mentioned, the production of such antibodies must play a crucial role in many aspects of *M. pneumoniae* infection.

3.8 Sensory system

3.8.1 Sudden hearing loss

A possible link between sudden hearing loss and *M. pneumoniae* infection [García Berrocal et al., 2000] is interesting in terms of what it can tell us about pathomechanisms. Sudden hearing loss has two major etiologies; direct neural damage as in the case of infection with the mumps virus, and vascular damage leading to neural dysfunction. García Berrocal et al. have reported that, although the mumps virus is the most frequent of the infectious causes implicated in sudden hearing loss, *M. pneumoniae* is the second. Assuming the vascular etiology of sudden hearing loss, it is highly possible that vasculitis or thrombosis caused by *M. pneumoniae* infection occurring within cochlear branches of a labyrinthine artery could cause neural dysfunction that would lead to sudden hearing loss. Not a few cases of sudden hearing loss due to *M. pneumoniae* infection might have been overlooked.

3.9 Urogenital system

3.9.1 Priapism

Priapism as a consequence of obstruction of the outflow of blood through the dorsal vein of the penis may be a unique, vascular occlusion-type extrapulmonary manifestation of *M. pneumoniae* infection. Although there has only been a single case report [Hirshberg et al., 1996], it is highly possible that *M. pneumoniae* can cause this disease, considering the ability of *M. pneumoniae* to elicit vascular occlusion not only within arteries but also within veins.

4. Diagnosis and treatment of vasculitic disorders due to *M. pneumoniae* infection

4.1 Diagnosis of vasculitic disorders due to *M. pneumoniae* infection

Diagnosis of vasculitic disorders due to *M. pneumoniae* infection should be made primarily by serologically rather than molecular detection methodologies, for two major reasons. Firstly, *M. pneumoniae* is not always present at the site of vascular damage, except in conditions associated with direct vascular occlusion such as striatal necrosis and stroke, where a tiny amount of *M. pneumoniae* may be detected in cerebrospinal fluid by culture [Sočan et al., 2001] or by polymerase chain reaction [Padovan et al., 2001; Saitoh et al., 1993]. Secondly, respiratory samples such as oropharyngeal swabs, which are routinely utilized for molecular detection of infectious organisms, are not always adequate for the diagnosis of extrapulmonary manifestations with very little or no respiratory symptoms such as cough and sputa. It must be remembered that extrapulmonary manifestations due to *M. pneumoniae* infection occur not infrequently in the absence of pneumonia or even in the absence of respiratory symptoms.

In the serological diagnosis of *M. pneumoniae* infection, it is important to recall that antibodies to *M. pneumoniae* (that is, both the IgM- and IgG-class antibodies which are available for serological testing in routine clinical practice) can persist at detectable levels in the serum for several months or even years after the acute phase of infection [Eun et al., 2008; Lind & Bentzon, 1991]. In addition, given that the human can be infected with *M. pneumoniae* several times during his or her lifetime with or without clinical symptoms, it seems likely that there are many asymptomatic antibody carriers in the general population [Foy, 1993], assuming the fact that antibody responses are evoked during each instance of infection [Eun et al., 2008; Ito et al., 2001; Kung et al., 2007]. Thus, testing paired acute- and convalescent- phase sera using quantitative methods such as the complement fixation test, the particle agglutination test, and the enzyme-linked immunosorbent assay to show a significant increase in antibody titers is required for the precise diagnosis of a current, rather than a recent past, *M. pneumoniae* infection [Gnarpe et al., 1992]. Diagnosis by a single high titer of antibodies to *M. pneumoniae* alone, or by a single positive IgM test result alone, would be misleading because either of these tests can respond to evidence of a recent past infection and may return positive results when there is no current infection.

4.2 Treatment of vasculitic disorders due to *M. pneumoniae* infection

A strategy for the treatment of *M. pneumoniae* infection-associated vascular disorders has unfortunately not yet been established. Therapy is fundamentally palliative and may or may not include anticoagulative or fibrinolytic treatment. Treatments specific to particular diseases, such as high-dose intravenous immunoglobulin infusions for Kawasaki disease, have been administered when indicated. The use of macrolide antibiotics, which have not only antibiotic effects against *M. pneumoniae* but also immunomodulatory effects [for review, see Amsden, 2005], is reasonable considering the likelihood of an immune pathogenesis of the extrapulmonary manifestations of *M. pneumoniae* infection. In this context, steroid therapy in combination with antibiotic therapy is also recommended, and appears promising as a treatment for the extrapulmonary manifestations of *M. pneumoniae* because of its immunomodulatory effects [Cimolai, 2006]; it has been shown to have

beneficial effects on experimental respiratory infection by *M. pneumoniae* [Tagliabue et al., 2008].

The successful practical application of immunomodulatory agents such as steroids or immunoglobulins in the treatment of vascular occlusion-type extrapulmonary manifestations of *M. pneumoniae* infection has been reported in not a few instances. In these cases, neurological disorders such as acute disseminated encephalomyelitis or transverse myelitis and thrombocytopenic disorders such as disseminated intravascular coagulation or thrombocytopenic purpura are most often treated by immunomodulatory agents because of the severity of these diseases. Some authors have reported that therapy with immunomodulatory agents was very effective, while others have reported that the effects are uncertain. Although it cannot be expected that immunomodulatory agents will affect thrombotic disorders that are already established, it is clear that they must have some beneficial effects on vasculitic disorders during ongoing inflammation. Additional accumulation of data will be necessary to construct a therapeutic strategy for the treatment of vascular occlusion-type extrapulmonary manifestations of *M. pneumoniae* infection.

4.3 Prognosis of vasculitic disorders due to *M. pneumoniae* infection

Prognosis of vasculitic disorders due to *M. pneumoniae* infection is variable depending on the disease manifestations. While the clinical symptoms of *M. pneumoniae* infection are immune-mediated, and can therefore generally be considered self-limiting toward a favorable outcome, some cases with fatal outcomes have been reported. Most of these were cases with neurological and hematological manifestations; disseminated intravascular coagulation was particularly strongly associated with fatal outcome. Delay in the diagnosis of *M. pneumoniae* infection might be a devastating factor in severe cases. Therefore, it must always be recalled that *M. pneumoniae* infection cause vasculitic disorders even in the absence of pneumonia, particularly when these vasculitic disorders are encountered during an epidemic of *M. pneumoniae* infection.

5. Conclusion

This chapter has discussed the ability of *M. pneumoniae* to cause various kinds of vascular occlusion-type extrapulmonary manifestations as a consequence of immune modulations such as cytokine production, lymphocyte proliferation, and immune complex formation. Such cases probably occur far more frequently than they are recognized. These vascular diseases may occur in the absence of pneumonia or even in the absence of respiratory symptoms, with or without systemic hypercoagulable state. With this in mind, the possibility of *M. pneumoniae* infection must be considered in diagnosing vasculitic/thrombotic disorders, particularly when such disorders are encountered during an epidemic period or within an endemic region of *M. pneumoniae* infection. Mycoplasmal infections are strictly species-specific. For example, rodents are natural hosts of *M. pulmonis* but not of *M. pneumoniae*, and although they can serve as a model for respiratory infection they do not develop extrapulmonary manifestations. To date, the only versatile animal models that permit the study of the extrapulmonary manifestations seen in humans are exceptional cases such as chimpanzee models [Barile et al., 1994]. For this reason, the continued accumulation of human case reports is crucially important to ensure further progress in this field.

6. References

- Abele-Horn, M, Franck, W, Busch, U, Nitschko, H, Roos, R, Heesemann, J. (1998). Transverse myelitis associated with *Mycoplasma pneumoniae* infection. *Clin Infect Dis*, 26 (4), 909-912.
- Al-Mateen, M, Gibbs, M, Dietrich, R, Mitchell, WG, Menkes, JH. (1988). Encephalitis lethargica-like illness in a girl with mycoplasma infection. *Neurology*, 38 (7), 1155-1158.
- Amsden, GW. (2005). Anti-inflammatory effects of macrolides- an underappreciated benefit in the treatment of community-acquired respiratory tract infections and chronic inflammatory pulmonary conditions? *J Antimicrob Chemother*, 55 (1), 10-21.
- Arai, S, Furukawa, M, Munakata, T, Kuwano, K, Inoue, H, Miyazaki, T. (1990). Enhancement of cytotoxicity of active macrophages by Mycoplasma: role of Mycoplasma-associated induction of tumor necrosis factor- α (TNF- α) in macrophages. *Microbiol Immunol*, 34 (3), 231-243.
- Ashtekar, CS, Jaspan, T, Thomas, D, Weston, V, Gayatri, NA, Whitehouse, WP. (2003). Acute bilateral thalamic necrosis in a child with *Mycoplasma pneumoniae*. *Dev Med Child Neurol*, 45 (9), 634-637.
- Auvichayapat, N, Auvichayapat, P, Watanatorn, J, Thamaroj, J, Jitpimolmard, S. (2006). Kluver-Bucy syndrome after mycoplasmal bronchitis. *Epilep Behav*, 8 (1), 320-322.
- Bar Meir, E, Amital, H, Levy, Y, Kneller, A, Bar-Dayan, Y, Schoenfeld, Y. (2000). *Mycoplasma pneumoniae*-induced thrombotic thrombocytopenic purpura. *Acta Haematol*, 103 (2), 112-115.
- Barile, MF, Kapatais-Zoumbos, K, Snoy, P, Grabowski, MW, Sneller, M, Miller, L, Chandler, DKF. (1994). Experimentally induced septic arthritis in chimpanzees infected with *Mycoplasma hominis*, *Mycoplasma pneumoniae*, and *Ureaplasma urealyticum*. *Clin Infect Dis*, 18 (5), 694-703.
- Barski, L, Nevzorov, R, Horowitz, J, Horowitz, S. (2010). Antibodies to various mycoplasmas in patients with coronary heart disease. *Isr Med Assoc J*, 12 (7), 396-399.
- Behan, PO, Feldman, RG, Segerra, JM, Draper, IT. (1986). Neurological aspects of mycoplasmal infection. *Acta Neurol Scand* 74 (4), 314-322.
- Berger, RP, Wadowksy, RM. (2000). Rhabdomyolysis associated with infection by *Mycoplasma pneumoniae*: a case report. *Pediatrics*, 105 (2), 433-436.
- Biberfeld, G, Norberg, R. (1974). Circulating immune complexes in *Mycoplasma pneumoniae* infection. *J Immunol*, 112 (1), 413-415.
- Bruch, LA, Jefferson, RJ, Pike, MG, Gould, SJ, Squier, W. (2001). *Mycoplasma pneumoniae* infection, meningoencephalitis, and hemophagocytosis. *Pediatr Neurol*, 25 (1), 67-70.
- Cameron, D, Welsby, P, Turner, M. (1992). Thrombotic thrombocytopenic purpura due to *Mycoplasma pneumoniae*. *Postgrad Med J*, 68 (799), 393-394.
- Cartner, SC, Lindsey, JR, Gibbs-Erwin, J, Cassell, GH, Simecka, JW. (1998). Roles of innate and adaptive immunity in respiratory mycoplasmosis. *Infect Immun*, 66 (8), 3485-3591.
- Chen, CJ, Juan, CJ, Hsu, ML, Lai, YS, Lin, SP, Cheng, SN. (2004). *Mycoplasma pneumoniae* infection presenting as neutropenia, thrombocytopenia, and acute hepatitis in a child. *J Microbiol Immunol Infect*, 37 (2), 128-130.

- Chiou, C-C, Liu, Y-C, Lin, H-H, Hsieh, K-S. (1997). *Mycoplasma pneumoniae* infection complicated by lung abscess, pleural effusion, thrombocytopenia and disseminated intravascular coagulation. *Pediatr Infect Dis J*, 16 (3), 327-329.
- Chmura, K, Bai, X, Nakamura, M, Kandasamy, P, McGibney, M, Kuronuma, K, Mitsuzawa, H, Voelker, DR, Chan, ED. (2008). Induction of IL-8 by *Mycoplasma pneumoniae* membrane in BEAS-2B cells. *Am J Physiol Lung Cell Mol Physiol*, 295 (1), L220-230.
- Chryssanthopoulos, C, Eboriadou, M, Monti, K, Soubassi, V, Sava, K. (2001). Fatal disseminated intravascular coagulation caused by *Mycoplasma pneumoniae*. *Pediatr Infect Dis J*, 20 (6), 634-635.
- Cimolai, N. (2006). Corticosteroids and complicated *Mycoplasma pneumoniae* infection. *Pediatr Pulmonol*, 41 (10), 1008-1009.
- Dakhama, A, Kraft M, Martin, RJ, Gelfand, EW. (2003). Induction of regulated upon activation, normal T cells expression and secreted (RANTES) and transforming growth factor- β 1 in airway epithelial cells by *Mycoplasma pneumoniae*. *Am J Respir Cell Mol Biol*, 29 (3 Pt 1), 344-351.
- Daxböck, F, Brunner, G, Popper, H, Krause R, Schmid, K, Krejs, GJ, Wenisch, C. (2002). A case of lung transplantation following *Mycoplasma pneumoniae* infection. *Eur J Clin Microbiol Infect Dis*, 21 (4), 318-322.
- De Vos, M, Van Nimmen, L, Baele, G. (1974). Disseminated intravascular coagulation during a fatal *Mycoplasma pneumoniae* infection. *Acta Haemat*, 52 (2), 120-125.
- Decaux, G, Szyper, M, Ectors, M, Cornil, A, Franken, L. (1980). Central nervous system complications of mycoplasma pneumoniae. *J Neurol Neurosurg Psychiatry*, 43 (10), 883-887.
- Elling, P, Olsson, AT, Elling, H. (1996). Synchronous variation of the incidence of temporal arteritis and polymyalgia rheumatica in different regions of Denmark; association with epidemics of *Mycoplasma pneumoniae* infection. *J Rheumatol*, 23 (1), 112-119.
- Eun, BW, Kim, NH, Choi, EH, Lee, HJ. (2008). *Mycoplasma pneumoniae* in Korean children: the epidemiology of pneumonia over an 18-year period. *J Infect*, 56 (5), 326-331.
- Foy, HM. (1993). Infections caused by *Mycoplasma pneumoniae* and possible carrier state in different populations of patients. *Clin Infect Dis*, 17(Suppl 1), S37-46.
- Fu, M, Wong, KS, Lam, WWM, Wong, GWK. (1998). Middle cerebral artery occlusion after recent *Mycoplasma pneumoniae* infection. *J Neurol Sci*, 157 (1), 113-115.
- Fumarola, D. (1997). Intravascular coagulation and *Mycoplasma pneumoniae* infection. *Pediatr Infect Dis J*, 16 (10), 1012-1013.
- García Berrocal, JR, Ramírez-Camacho, R, Portero, F, Vargas, JA. (2000). Role of viral and *Mycoplasma pneumoniae* infection in idiopathic sudden sensorineural hearing loss. *Acta Otolaryngol*, 120 (7), 835-839.
- Ghosh, K, Clements, GB. (1992). Surveillance of *Mycoplasma pneumoniae* infections in Scotland 1986-1991. *J Infect*, 25 (2), 221-227.
- Gnarpe, J, Lundbäck, A, Sundelöf, B, Gnarpe, H. (1992). Prevalence of *Mycoplasma pneumoniae* in subjectively healthy individuals. *Scand J Infect Dis*, 24 (2), 161-164.
- Goebels, N, Helmchen, C, Abele-Horn, M, Gasser, T, Pfister, H-W. (2001). Extensive myelitis associated with *Mycoplasma pneumoniae* infection: magnetic resonance imaging and clinical long-term follow-up. *J Neurol*, 248 (3), 204-208.

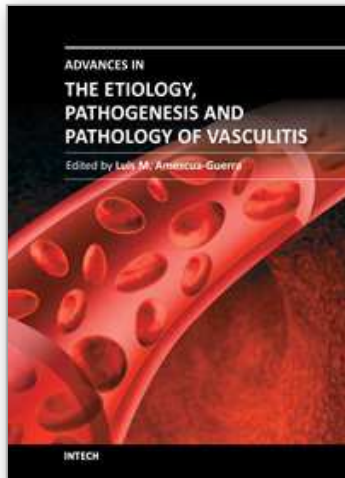
- Graw-Panzer, KD, Verma, S, Rao, S, Miller, ST, Lee, H. (2009). Venous thrombosis and pulmonary embolism in a child with pneumonia due to *Mycoplasma pneumoniae*. *J Natl Med Assoc*, 101 (9), 956-958.
- Greco, F, Sorge, A, Salvo, V, Sorge, G. (2007). Cutaneous vasculitis associated with *Mycoplasma pneumoniae* infection: case report and literature review. *Clin Pediatr (Phila)*, 46 (5), 451-453.
- Guleria, R, Nisar, N, Chawla, TC, Biswas, NR. (2005). *Mycoplasma pneumoniae* and central nervous system complications: a review. *J Lab Clin Med*, 146 (2), 55-63.
- Gupta, A, Kimber, T, Crompton, JL, Karagiannis, A. (2009). Acute disseminated encephalomyelitis secondary to *Mycoplasma pneumoniae*. *Intern Med J*, 39 (1), 68-69.
- Gursel, O, Altun, D, Atay, AA, Bedir, O, Kurekci, AE. (2009). *Mycoplasma pneumoniae* infection associated with pancytopenia. A case report. *J Pediatr Hematol Oncol*, 31 (10), 760-762.
- Hardy, RD, Jafri, HS, Olsen, K, Wordemann, M, Hatfield, J, Rogers, BB, Patel, P, Duffy, L, Cassell, G, McCracken, GH, Ramilo, O. (2001). Elevated cytokine and chemokine levels and prolonged pulmonary airflow resistance in a murine *Mycoplasma pneumoniae* pneumonia model: a microbiologic, histologic, immunologic, and respiratory plethysmographic profile. *Infect Immun*, 69 (6), 3869-3876.
- Hardy, RD, Coalson, JJ, Peters, J, Chaparro, A, Techasaensiri, C, Cantwell, AM, Kannan, TR, Basemann, JB, Dube, PH. (2009). Analysis of pulmonary inflammation and function in the mouse and baboon after exposure to *Mycoplasma pneumoniae* CARDS toxin. *PLoS ONE*, 4 (10), e7562.
- Hirshberg, SJ, Charles, RS, Ettinger, JB. (1996). Pediatric priapism associated with *Mycoplasma pneumoniae*. *Urology* 47 (5), 745-746.
- Ito, I, Ishida, T, Osawa, M, Arita, M, Hashimoto, T, Hongo, T, Mishima, M. (2001). Culturally verified *Mycoplasma pneumoniae* pneumonia in Japan: a long-term observation from 1979-99. *Epidemiol Infect*, 127 (2), 365-367.
- Kannan, TR, Baseman, JB. (2006). ADP-ribosylating and vacuolating cytotoxin of *Mycoplasma pneumoniae* represents unique virulence determinant among bacterial pathogens. *Proc Natl Acad Sci*, 103 (17), 6724-6729.
- Kano, Y, Mitsuyama, Y, Hirahara, K, Shiohara, T. (2007). *Mycoplasma pneumoniae* infection-induced erythema nodosum, anaphylactoid purpura, and acute urticaria in 3 people in a single family. *J Am Acad Dermatol*, 57 (2 Suppl), S33-35.
- Kawasaki, T, Kosaki, F, Okawa S, Shigematsu, I, Yanagawa, H. (1974). A new infantile acute febrile mucocutaneous lymph node syndrome (MLNS) prevailing in Japan. *Pediatrics*, 54 (3), 271-276.
- Kita, M, Ohmoto, Y, Hirai, Y, Yamaguchi, N, Imanishi, J. (1992). Induction of cytokines in human peripheral blood mononuclear cells by Mycoplasmas. *Microbiol Immunol*, 36 (5), 507-516.
- Knochel, JP. (1993). Mechanisms of rhabdomyolysis. *Curr Opin Rheumatol*, 5 (6), 725-731.
- Koletsky, RJ, Weinstein, AJ. (1980). Fulminant *Mycoplasma pneumoniae* infection. *Am Rev Respir Dis*, 122 (3), 491-496.
- Kountouras, D, Deutsch, M, Emmanuel, T, Georgiadis, G, Koskinas, J. (2003). Fulminant *Mycoplasma pneumoniae* infection with multi-organ involvement: a case report. *Eur J Int Med*, 14 (5), 329-331.

- Krunkosky, TM, Jordan, JL, Chambers, E, Krause, DC. (2007). *Mycoplasma pneumoniae* host-pathogen studies in an air-liquid culture of differentiated human airway epithelial cells. *Microb Pathog*, 42 (2-3), 98-103.
- Kung, C-M, Wang, H-L. (2007). Seroprevalence of *Mycoplasma pneumoniae* in healthy adolescents in Taiwan. (2007). *Jpn J Infect Dis*, 60 (6), 352-354.
- Lee, C-Y, Huang, Y-Y, Huang, F-L, Liu, F-C, Chen, P-Y. (2009). *Mycoplasma pneumoniae*-associated cerebral infarction in a child. *J Trop Pediatr*, 55 (4), 272-275.
- Leen, C, Ling, S. (1996). Mycoplasma infection and Kawasaki disease. *Arch Dis Child*, 75 (3), 266-267.
- Leonardi, S, Pavone, P, Rotolo, N, La Rosa, M. (2005). Stroke in two children with *Mycoplasma pneumoniae* infection. A causal or casual relationship? *Pediatr Infect Dis J*, 24 (9), 843-845.
- Lind, K, Bentzon, MW. (1991). Ten and a half years seroepidemiology of *Mycoplasma pneumoniae* infection in Denmark. *Epidemiol Infect*, 107 (1), 189-199.
- Maisel, JC, Babbitt, LH, John, TJ. (1967). Fatal *Mycoplasma pneumoniae* infection with isolation of organisms from lung. *J Am Med Assoc*, 202 (4), 139-142.
- Matsumoto, N, Takahashi, S, Toriumi, N, Sarashina, T, Makita, Y, Tachibana, Y, Fujieda, K. (2009). Acute disseminated encephalomyelitis in an infant with incontinentia pigmenti. *Brain Dev*, 31 (8), 625-628.
- Minami, K, Maeda, H, Yanagawa, T, Suzuki, H, Izumi, G, Yoshikawa, N. (2003). Rhabdomyolysis associated with *Mycoplasma pneumoniae* infection. *Pediatr Infect Dis J*, 22 (3), 291-293.
- Mizuguchi, M, Abe, J, Mikkaichi, K, Noma, S, Yoshida, K, Yamanaka, T, Kamoshita, S. (1995). Acute necrotizing encephalopathy of childhood: a new syndrome presenting with multifocal, symmetric brain lesions. *J Neurol Neurosurg Psychiatry*, 58 (5), 555-561.
- Mizukane, R, Kadota, J, Yamaguchi, T, Kiya, T, Fukushima, H, Nakatomi, M, Kohno, S. (2002). An elderly patient with hemophagocytic syndrome due to severe *Mycoplasma pneumoniae* with marked hypercytokinemia. *Respiration*, 69 (1), 87-91.
- Mizutani, H, Mizutani, H. (1984). Circulating immune complexes in patients with mycoplasmal pneumonia. *Am Rev Respir Dis*, 130 (4), 627-629.
- Mulder, LJMM, Spierings, ELH. (1987). Stroke in a young adult with *Mycoplasma pneumoniae* infection complicated by intravascular coagulation. *Neurology*, 37 (8), 1430-1431.
- Müller, N, Riedel, M, Förderreuther, S, Blendinger, C, Abele-Horn, M. (2000). Tourette's syndrome and *Mycoplasma pneumoniae* infection. *Am J Psychiatry*, 157 (3), 481-482.
- Nagashima, M, Higaki, T, Satoh, H, Nakano, T. (2010). Cardiac thrombus associated with *Mycoplasma pneumoniae* infection. *Interact Cardiovasc Thoracic Surg*, 11 (6), 849-851.
- Narita, M, Matsuzono, Y, Togashi, T, Kajii, N. (1992). DNA diagnosis of central nervous system infection by *Mycoplasma pneumoniae*. *Pediatrics*, 90 (2), 250-253.
- Narita, M, Matsuzono, Y, Itakura, O, Togashi, T, Kikuta, H. (1996). Survey of mycoplasmal bacteremia detected in children by polymerase chain reaction. *Clin Infect Dis*, 23 (3), 522-525.
- Narita, M, Tanaka, H, Abe, S, Yamada, S, Kubota, M, Togashi, T. (2000). Close association between pulmonary disease manifestation in *Mycoplasma pneumoniae* infection and

- enhanced local production of interleukin-18 in the lung, independent of gamma interferon. *Clin Diagn Lab Immunol*, 7 (6), 909-914.
- Narita, M, Yamada, S, Nakayama, T, Sawada, H, Nakajima, M, Sageshima, S. (2001a). Two cases of lymphadenopathy with liver dysfunction due to *Mycoplasma pneumoniae* infection with mycoplasmal bacteraemia without pneumonia. *J Infect*, 42 (2), 154-156.
- Narita, M, Tanaka, H, Yamada, S, Abe, S, Ariga, T, Sakiyama, Y. (2001b). Significant role of interleukin-8 in pathogenesis of pulmonary disease due to *Mycoplasma pneumoniae* infection. *Clin Diagn Lab Immunol*, 8 (5), 1028-1030.
- Narita, M, Tanaka, H, Togashi, T, Abe, S. (2005). Cytokines involved in CNS manifestations caused by *Mycoplasma pneumoniae*. *Pediatr Neurol*, 33 (2), 105-109.
- Narita, M. (2009). Pathogenesis of neurologic manifestations of *Mycoplasma pneumoniae* infection. *Pediatr Neurol*, 41 (3), 159-66.
- Narita, M. (2010). Pathogenesis of extrapulmonary manifestations of *Mycoplasma pneumoniae* infection with special reference to pneumonia. *J Infect Chemother*, 16 (3), 162-169.
- Nilsson, IM, Rausing, A, Denneberg, T, Christensson, P. (1971). Intravascular coagulation and acute renal failure in a child with mycoplasma infection. *Acta Med Scand*, 189 (5), 359-365.
- Okoli, K, Gupta, A, Irani, F, Kasmani, R. (2009). Immune thrombocytopenia associated with *Mycoplasma pneumoniae* infection: a case report and review of literature. *Blood Coagul Fibrinolysis*, 20 (7), 595-598.
- Ovetchkine, P, Brugières, P, Seradj, A, Reinert, P, Cohen, R. (2002). An 8-y-old boy with acute stroke and radiological signs of cerebral vasculitis after recent *Mycoplasma pneumoniae* infection. *Scand J Infect Dis*, 34 (4), 307-309.
- Padovan, CS, Pfister, H-W, Bense, S, Fingerle, V, Abele-Horn, M. (2001). Detection of *Mycoplasma pneumoniae* DNA in cerebrospinal fluid of a patient with *M. pneumoniae* infection- "associated" stroke. *Clin Infect Dis*, 33 (10), e119-121.
- Parker, P, Puck, J, Fernandez, F. (1981). Cerebral infarction associated with *Mycoplasma pneumoniae*. *Pediatrics*, 67 (3), 373-375.
- Perez, C, Mendoza, H, Hernandez, R, Valcayo, A, Guarch, R. (1997). Leukocytoclastic vasculitis and polyarthritis associated with *Mycoplasma pneumoniae* infection. *Clin Infect Dis*, 25 (1) 154-155.
- Perez, C, Montes, M. (2002). Cutaneous leukocytoclastic vasculitis and encephalitis associated with *Mycoplasma pneumoniae* infection. *Arch Intern Med*, 162 (3), 352-354.
- Pinna, GS, Kafetzis, DA, Tselkas, OI, Skevaki, CL. (2008). Kawasaki disease: an overview. *Curr Opin Infect Dis*, 21 (3), 263-270.
- Riedel, K, Kempf, VAJ, Bechtold, A, Klimmer, M. (2001). Acute disseminated encephalomyelitis (ADEM) due to *Mycoplasma pneumoniae* infection in an adolescent. *Infection*, 29 (4), 240-242.
- Rothstein, TL, Kenny, GE. (1979). Cranial neuropathy, myeloradiculopathy, and myositis. Complications of *Mycoplasma pneumoniae* infection. *Arch Neurol*, 36 (8), 476-477.
- Saitoh, S, Wada, T, Narita, M, Kohsaka, S, Mizukami, S, Togashi, T, Kajii, N. (1993). *Mycoplasma pneumoniae* infection may cause striatal lesions leading to acute neurologic dysfunction. *Neurology*, 43 (10), 2150-2151.

- Sakai, R, Sakaguchi, S, Oguchi S, Aoyanagi, Y, Suzuki, K, Wada, M, Kuriya, T, Watanabe, H, Takada, M. (2007). Three cases of Kawasaki disease complicated by *Mycoplasma pneumoniae* infection. *Shonika Rinsho*, 60 (7), 1591-1596 (Japanese with English abstract).
- Sakoulas, G. (2001). Brainstem and striatal encephalitis complicating *Mycoplasma pneumoniae* pneumonia: possible benefit of intravenous immunoglobulin. *Pediatr Infect Dis J*, 20 (5), 543-545.
- Sánchez-Vargas, FM, Gómez-Duarte, OG. (2008). *Mycoplasma pneumoniae*- an emerging extra-pulmonary pathogen. *Clin Microbiol Infect*, 14 (2), 105-115.
- Senda, J, Ito, M, Atsuta, N, Watanabe, H, Hattori, N, Kawai, H, Sobue, G. (2010). Paradoxical brain embolism induced by *Mycoplasma pneumoniae* infection with deep venous thrombus. *Inter Med*, 49 (18), 2003-2005.
- Shimizu, T, Kida, Y, Kuwano, K. (2005). A dipalmitoylated lipoprotein from *Mycoplasma pneumoniae* activates NF- κ B through TLR1, TLR2, and TLR6. *J Immunol*, 175 (7), 4641-4646.
- Snowden, N, Wilson, PB, Longson, M, Pumphrey, RSH. (1990). Antiphospholipid antibodies and *Mycoplasma pneumoniae* infection. *Postgrad Med J*, 66 (775), 356-362.
- Sočan, M, Ravnik, I, Benčina, D, Dovč, P, Zakotnik, B, Jazbec, J. (2001). Neurological symptoms in patients whose cerebrospinal fluid is culture- and/or polymerase chain reaction-positive for *Mycoplasma pneumoniae*. *Clin Infect Dis*, 32 (2), e31-35.
- Sohn, MH, Lee, KE, Choi, SY, Kwon, BC, Chang, MW, Kim, K-E. (2005). Effect of *Mycoplasma pneumoniae* lysate on interleukin-8 gene expression in human respiratory epithelial cells. *Chest*, 128 (1), 322-326.
- Sotgiu, S, Pugliatti, M, Rosati, G, Deiana, GA, Sechi, GP. (2003). Neurological disorders associated with *Mycoplasma pneumoniae* infection. *Eur J Neurol*, 10 (2), 165-168.
- Stamm, B, Moschopoulos, M, Hungerbuehler, H, Guarner, J, Genrich, GL, Zaki, SR. (2008). Neuroinvasion by *Mycoplasma pneumoniae* in acute disseminated encephalomyelitis. *Emerg Infect Dis*, 14 (4), 641-643.
- Sterner, G, Biberfeld, G. (1969). Central nervous system complications of *Mycoplasma pneumoniae* infection. *Scand J Infect Dis*, 1 (3), 203-208.
- Tagliabue, C, Salvatore, CM, Techasaensiri, C, Mejias, A, Torres, JP, Katz, K, Gomez, AM, Esposito, S, Principi, N, Hardy, RD. (2008). The impact of steroids given with macrolide therapy on experimental *Mycoplasma pneumoniae* respiratory infection. *J Infect Dis*, 198 (8), 1180-1188.
- Tanaka, H, Honma, S, Abe, S, Tamura, H. (1996). Effects of interleukin-2 and cyclosporin A on pathologic features in *Mycoplasma pneumoniae*. *Am J Respir Crit Care Med*, 154 (6), 1908-1912.
- Tanaka, H, Narita, M, Teramoto, S, Saikai, T, Oashi, K, Igarashi, T, Abe, S. (2002). Role of interleukin-18 and T-helper type 1 cytokines in the development of *Mycoplasma pneumoniae* pneumonia in adults. *Chest*, 121 (5), 1493-1497.
- Tanir, G, Aydemir, C, Yilmaz, D, Tuygun, N. (2006). Internal carotid artery occlusion associated with *Mycoplasma pneumoniae* infection in a child. *Turk J Pediatr*, 48 (2), 166-171.

- Tsiodras, S, Kelesidis, Th, Kelesidis, I, Voumbourakis, K Giamarellou, H. (2006). *Mycoplasma pneumoniae*-associated myelitis: a comprehensive review. *Eur J Neurol*, 13 (2), 112-124.
- Van Bever, HP, Van Doorn, JWD, Demey, HE. (1992). Adult respiratory distress syndrome associated with *Mycoplasma pneumoniae* infection. *Eur J Pediatr*, 151 (3), 227-228.
- van Buiren, M, Uhl, M. (2003). Bilateral striatal necrosis associated with *Mycoplasma pneumoniae* infection. *New Engl J Med*, 348 (8), 720.
- Veenhoven, WA, Smithuis, RH, Kerst, AJ. (1990). Thrombocytopenia associated with *Mycoplasma pneumoniae* infection. *Neth J Med*, 37 (1-2), 75-76.
- Venkatesan, P, Patel, V, Collingham, KE, Ellis, CJ. (1996). Fatal thrombocytopenia associated with *Mycoplasma pneumoniae* infection. *J Infect*, 33 (2), 115-117.
- Visudhiphan, P, Chiemchanya, S, Sirinavin, S. (1992). Internal carotid artery occlusion associated with *Mycoplasma pneumoniae* infection. *Pediatr Neurol*, 8 (3), 237-239.
- Vitale, EA, La Torre, F, Calcagno, G, Infriciori, G, Fede, C, Conti, G, Chimenz, R, Falcini, F. (2010). *Mycoplasma pneumoniae*: a possible trigger of Kawasaki disease or a mere coincidental association? Report of the first four Italian cases. *Minerva Pediatr*, 62 (6), 605-607.
- Waites, KB, Talkington, DF. (2004). *Mycoplasma pneumoniae* and its role as a human pathogen. *Clin Microbiol Rev*, 17 (4), 697-728.
- Wang, JN, Wang, SM, Liu, CC, Wu, JM. (2001). *Mycoplasma pneumoniae* infection associated with Kawasaki disease. *Acta Paediatr*, 90 (5), 594-595.
- Weiss, TW, Kvakana, H, Kaun, C, Prager, M, Speidl, WS, Zorn, G, Pfaffenberger, S, Huk, I, Maurer, G, Huber, K, Wojta, J. (2006). No evidence for a direct role of *Helicobacter pylori* and *Mycoplasma pneumoniae* in carotid artery atherosclerosis. *J Clin Pathol*, 59 (11), 1186-1190.
- Weng, W-C, Peng, SS-F, Wang, S-B, Chou, Y-T, Lee, W-T. (2009). *Mycoplasma pneumoniae*-associated transverse myelitis and rhabdomyolysis. *Pediatr Neurol*, 40 (2), 128-130.
- Witmer, CM, Steenhoff, AP, Shah, SS, Raffini, LJ. (2007). *Mycoplasma pneumoniae*, splenic infarct, and transient antiphospholipid antibodies: a new association? *Pediatrics*, 119 (1), e292-295.
- Wood, LE, Tulloh, RM. (2009). Kawasaki disease in children. *Heart*, 95 (10), 787-792.
- Yang, J, Hooper, WC, Phillips, DJ, Talkington, DF (2002). Regulation of proinflammatory cytokines in human lung epithelial cells infected with *Mycoplasma pneumoniae*. *Infect Immun*, 70 (7), 3649-3655.
- Yang, J, Hooper, WC, Phillips, DJ, Talkington, DF. (2004). Cytokines in *Mycoplasma pneumoniae* infections. *Cytokine Growth Fac Rev*, 15 (2-3), 157-168.
- Yiş, U, Kurul, SH, Çakmakçi, H, Dirik, E. (2008). *Mycoplasma pneumoniae*: nervous system complications in childhood and review of the literature. *Eur J Pediatr*, 167 (9), 973-978.
- Zambrino, CA, Zorzi, G, Lanzi, G, Uggetti, C, Egitto, MG. (2000). Bilateral striatal necrosis associated with *Mycoplasma pneumoniae* infection in an adolescent: clinical and neuroradiologic follow up. *Mov Disord*, 15 (5), 1023-1026.



Advances in the Etiology, Pathogenesis and Pathology of Vasculitis

Edited by Dr. Luis M Amezcua-Guerra

ISBN 978-953-307-651-5

Hard cover, 438 pages

Publisher InTech

Published online 17, October, 2011

Published in print edition October, 2011

This book represents the culmination of the efforts of a group of outstanding experts in vasculitis from all over the world, who have endeavored to devote their work to this book by keeping both the text and the accompanying figures and tables lucid and memorable. Here, you will find an amalgam between evidence-based medicine to one based on eminence, through an exciting combination of original contributions, structured reviews, overviews, state-of-the-art articles, and even the proposal of novel pathogenetic models of disease. The book contains contributions on the etiology and pathology of vasculitis, the potential role of endothelial cells and cytokines in vascular damage and repair as well as summaries of the latest information on several primary and secondary vasculitis syndromes. It also covers selected topics such as organ-specific vasculitic involvement and quality of life issues in vasculitis. The editor and each of the authors invite you to share this journey through one of the most exciting fields of the medicine, the world of Vasculitis.

How to reference

In order to correctly reference this scholarly work, feel free to copy and paste the following:

Mitsuo Narita (2011). Mycoplasma pneumoniae as an Under- Recognized Agent of Vasculitic Disorders, Advances in the Etiology, Pathogenesis and Pathology of Vasculitis, Dr. Luis M Amezcua-Guerra (Ed.), ISBN: 978-953-307-651-5, InTech, Available from: <http://www.intechopen.com/books/advances-in-the-etiology-pathogenesis-and-pathology-of-vasculitis/mycoplasma-pneumoniae-as-an-under-recognized-agent-of-vasculitic-disorders>

INTECH
open science | open minds

InTech Europe

University Campus STeP Ri
Slavka Krautzeka 83/A
51000 Rijeka, Croatia
Phone: +385 (51) 770 447
Fax: +385 (51) 686 166
www.intechopen.com

InTech China

Unit 405, Office Block, Hotel Equatorial Shanghai
No.65, Yan An Road (West), Shanghai, 200040, China
中国上海市延安西路65号上海国际贵都大饭店办公楼405单元
Phone: +86-21-62489820
Fax: +86-21-62489821

© 2011 The Author(s). Licensee IntechOpen. This is an open access article distributed under the terms of the [Creative Commons Attribution 3.0 License](#), which permits unrestricted use, distribution, and reproduction in any medium, provided the original work is properly cited.

IntechOpen

IntechOpen