

# We are IntechOpen, the world's leading publisher of Open Access books Built by scientists, for scientists

## 4,800

Open access books available

## 122,000

International authors and editors

## 135M

Downloads

Our authors are among the

## 154

Countries delivered to

## TOP 1%

most cited scientists

## 12.2%

Contributors from top 500 universities

**WEB OF SCIENCE™**Selection of our books indexed in the Book Citation Index  
in Web of Science™ Core Collection (BKCI)

## Interested in publishing with us? Contact [book.department@intechopen.com](mailto:book.department@intechopen.com)

Numbers displayed above are based on latest data collected.

For more information visit [www.intechopen.com](http://www.intechopen.com)

## Bone Substitutes

Jesus Torres<sup>1</sup>, Faleh Tamimi<sup>2</sup>, Mohammad Alkhraisat<sup>3</sup>,  
Juan Carlos Prados-Frutos<sup>1</sup> and Enrique Lopez-Cabarcos<sup>3</sup>

<sup>1</sup>Universidad Rey Juan Carlos,

<sup>3</sup>Universidad Complutense,

<sup>2</sup>McGill University,

<sup>1,3</sup>Spain

<sup>2</sup>Canada

### 1. Introduction

In daily clinical practise we frequently encounter situations in which the bone volume is insufficient for an ideal dental implant placement. Bone regeneration can provide the structural support necessary in these cases. Procedures such as sinus lifting and alveolar ridge augmentation have reached high levels of predictability and already are of major importance in implant practise. Interest for bone substitutes for alveolar ridge augmentation or preservation appears in the early 1980's alongside the development of endosseous dental implants. Although first studies regarding bone substitutes dates from 1920 by Albee (Albee, 1920), until 1980's there are very few studies in reference this issue. From 1980's until nowadays an exponential number of studies about bone substitutes have been made.

The reason for this increasing interest in bone substitutes stems from the fact that about 10-20% of the patients that need treatments with dental implants, require bone regeneration procedures before implant placement. Moreover, more than 60% of the population in industrialized countries need dental prosthetic replacements (Peterson, 2006), ideally with implants. This is the reason why the market of dental implants is experiencing an increase of approximately 15% every year.

Bone regeneration procedures are becoming an almost daily practice in dentistry all around the world as a result of the wide acceptance of dental implants as the "ideal" option for oral rehabilitation. Bone regeneration procedures are critical for the success of dental implant treatments in cases where there is a deficiency in bone width and/or height. The cornerstone in these treatments is the use of bone substitutes to create a bone mantle that covers the screw to enhance implant stability and treatment outcome. In this chapter, we will discuss the different types of bone substitutes and recent developments achieved to enhance the outcomes of bone regeneration procedures with the newest available biomaterials.

The term "bone graft" was defined by Muschler (Bauer, 2000) as: "any implanted material that alone or in combination with other materials promotes a bone healing response by providing osteogenic, osteoinductive or osteoconductive properties". An osteogenic material can be defined as one that has inherent capacity to form bone, which implies to contain living cells that are capable of differentiation into bone cells. An osteoinductive material

provides biologic signals capable to induce local cells to enter a pathway of differentiation leading to mature osteoblasts. An osteoconductive biomaterial provides a three-dimensional interconnected scaffold where local bone tissue may regenerate new living bone. However, osteoconductive biomaterials are unable to form bone or to induce its formation.

Another property that is interesting to find especially in bone substitutes is biodegradability. This is defined as the capacity of degradation of a particle by two mechanisms principally; through a passive chemical degradation or dissolution, and through active cellular activity mediated by osteoclast and/or macrophages. Moreover, the biological properties of bone substitute biomaterials are also influenced by their porosity, surface geometry and surface chemistry. The events leading to bone healing and regeneration are influenced by all the variables mentioned above. These properties are related to the biomaterial itself, however, host factors such as bone quality, vascularity of the graft bed and tobacco addiction may also influence the final outcome of a bone regeneration procedure with a bone substitute.

## 2. Biomaterials used for bone regeneration in implant dentistry

Bone graft materials can be divided in four large groups: Autografts, Allografts, Xenografts and Synthetic biomaterials.

### 2.1 Autograft

“Autograft” refers to bone tissue harvested from, and implanted in the same individual. Accordingly, autograft is a bone tissue that is separated from one site and implanted in other location in the same individual. The cellular component of trabecular bone graft includes few osteoblasts and a high number of precursor cells that survive the transplantation. These precursor cells explain the osteogenic potential of bone autograft. Autograft is considered the “gold standard” in bone regeneration due to its properties of osteoconduction, osteoinduction, osteogenicity and osteointegration. However there are major drawbacks to the use of this sort of ideal bone graft, namely the necessity of a second surgery to retrieve the bone graft at the donor site, with its associated morbidity; the increasing surgery time, the restrictions in quantity and shape of the bone graft, and the additional cost (Arrington, 1996; Giannoudis, 2005).

Autografts are subdivided in two groups: cancellous autografts and cortical autografts. *Cancellous autografts* are retrieved mainly from cancellous bone, and upon transplantation, the majority of cells present in the grafts die as result of ischemia. However, the mesenchymal stem cells present in the bone marrow are resistant to ischemia and may survive the grafting procedure. The stem cells capacity of survival and proliferation after exposure to changes in the oxygen tension, pH and cytochine environment are the main reason behind the reliability of cancellous bone autograft interventions. The incorporation of such type of autograft is speed, about 8 weeks (Virolainen, 1995).

*Cortical autografts* are segments of cortical bone composed of necrotic bone that provides an osteoconductive support for bone formation, but does not supply significant amounts of living cells. For this reason, revascularization and integration of cortical autografts is slow. The main advantage of cortical autografts is the mechanical support that provides at the graft site (Bauer & Muchler, 2000), while its incorporation is slower than cancellous autografts.

Bone graft	Properties			
	Origin	Availability	Reabsorption	Graft's form
<b>Extraoral Autograft</b>				
Calvaria	IM	+++	++	Block/Particulate
Iliac crest	EC	+++	+++	Block/Particulate
Tibia	EC	+++	+++	Particulate
<b>Intraoral Autograft</b>				
Ramus	IM	++	++	Block
Sinifisis	IM	+	++	Block/Particulate
Tuberosity	IM	+	+++	Particulate

IM: Intramembranous bone, EC: Endochondral bone

Table 1. Summary of bone autograft properties as a function of their anatomical origin

**2.2 Allografts: Freeze dried bone allograft (FDBA) and demineralized freeze dried bone allograft (DFDBA)**

Allograft is defined as tissue that has been harvested from one individual and implanted into another individual of the same species (Eppley, 2005). The use of cadaver bone for grafting is known as bone allograft and it is considered by some the best available alternative to autografts due its similarly characteristics. Despite the superior properties of autografts, allografts are usually preferred by patients as bone grafting material because they the problems associated to donor site surgery in autografts.. Allografts are obtained from cadaver tissue banks for mineralized freeze-dried (FDBA) or decalcified freeze-dried (DFDBA) bone.. Both FDBA and DFDBA are obtained from cortical bone of long bones due to its high content of bone inductive proteins and less antigenic activity than cancellous bone. Bone allografts come in various configurations, including powder, cortical chips, cancellous cubes, and cortical granules among others (Eppley, 2005). The granulated form is btained by milling the cortical bone under sterile conditions to obtain a particle size ranging from 250 to 750 µm. Moreover, allografts have been recently made available in different block forms; although their mechanical properties remains slightly lower than those of autograft cortical blocks.

Once the allograft is harvested they are processed through several methods including physical debridement to remove soft tissue and reduced cellular load, ultrasonic washing to remove remnant cells and blood, ethanol treatment in order to denaturalize proteins and viral deactivation, antibiotic wash to kill bacteria, and sterilization through gamma radiation and ethylene oxide for spore elimination (Khan, 2005). FDBA are washed in antibiotic twice for 1 hour, frozen at -70C° and dried up to 5% of water (Kao, 2007). During

this process microfractures form along the allografts' collagen fibers, resulting in a decreased in its mechanical properties, for this reason it is advised to rehydrate allografts before use to regain some of the lost properties (Kao, 2007). Processed bone allografts do not include any living cells, and therefore, they lack osteogenic activity. Allografts are essentially osteoconductive, and depending how they are processed, they may have some osteoinductive properties (Stevenson, 1999).

*FDDBA*: Mineralized bone matrix has no active bone morphogenetic proteins (BMPs) and therefore it lacks osteoinductive properties, although it has osteoconductive properties. Graft incorporation is qualitatively similar to autograft, but occur more slowly. Cortical allografts will incorporate and eventually resemble their autograft counterpart although with more unremodeled necrotic bone present in allografts (Stevenson, 1999). Milled forms present an open structure that facilitate invasion by blood cells, enhance graft incorporation and allows mixing with blood, platelet concentrates and other graft materials forming composites.

*DFDBA*: DFDBA forms are processed by acid demineralization in 0.5 to 0.6 molar hydrochloric acid as a result, 40% of the mineral content is removed leaving the organic matrix intact. This process preserves the BMPs present in bone, and therefore maintains some of the inherent osteoinductive properties (Khan, 2000). Moreover, the collagen matrix present in DFDBA acts as a scaffold that provides osteoconductive properties alone side the osteoinductive behavior. Osteoinductivity of DFDBA was first described by Urist et al, after observing endochondral bone formation on DFDBA when placed in soft tissue. It has since been discovered that BMPs are the factors responsible for the novo bone formation (Reddi, 1998). BMPs are associated with the organic matrix of bone and embedded within mineral content, so demineralised process increases its bioavailability. BMPs attract mesenchymal stem cells and induce them to differentiate into chondrocytes leading into endochondral bone formation. Endochondral bone formation is attributed to a osteoinductivity response, while intra-membranous bone formation is indicative of an osteoconductive response. Nevertheless, osteoinductivity of DFDBA has been recently questioned, since it seems that this property is highly dependent on the manufacturing procedures (Drosos, 2007)

The main advantage of allografts include easy availability, avoiding the need of harvesting a patient donor site, reduced costs in terms of anesthesia (general anesthesia is not needed) and reduced surgical time. However, the use of cadaver bone for grafting is avoided by many clinicians due to its potential risk of infectious disease. Nevertheless, allografts have been used for more than 25 years without any reported incidence of disease transmission. The risk of HIV infection through allograft implantation has been estimated to be 1 in 1.6 million, compared with the risk of 1 in 450.000 in blood transfusions (Khan, 2000). DFDBA forms may have even less risk of disease transmission than FDDBA, because demineralization allows most affective removal of viruses and blood elements reducing immunological reactions (Eppley, 2005). Moreover the establishment of better equipped tissue banks has allowed an increase in the use of bone allografts, and there is a current tendency by many surgeons to replace autografts by bone allograft (Albert, 2006).

Allografts are available in the form of granules and blocks. Allograft granules' appearance is similar to other bone substitute granules, and they are ideal to fill bone cavities as alveolar bone defects and maxillary sinus. On the other hand, allograft blocks are especially useful in both vertical and horizontal bone augmentation procedures.



Bone graft	Properties			
	Structural strength	Osteogenesis	Osteoconductor	Osteoinductor
<b>Autograft</b>				
Cancellous	No	+++	+++	+++
Cortical	+++	++	++	++
<b>Allograft</b>				
Cancellous	No	No	++	+
Cortical	+++	No	++	No

Table 2. Comparison between bone autograft and allograft according to their properties

### 2.3 Xenografts: Anorganic bovine bone (ABB)

Bone xenograft is defined a bone tissue harvested from one species and implanted into a different species. One of the most commonly used xenografts is anorganic bovine bone (ABB). ABB is a biomaterial with major long-term success reports in the bone regeneration literature and it has been extensively used in the clinics for over 20 years (Frame et al., 1987). ABB has an ultrastructural composition similar to human bone, it is composed of almost pure hydroxyapatite, and it is chemically treated to remove all organic components so it can be used as a graft material without causing host immune response (Mish et al., 1993). ABB is thermally and chemically treated in order to extract organic constituents and thereby eliminating its antigenicity and potential inflammatory response by the host bone (Cohen et al., 1994). The structure consists of a wide interconnective pore system with a particle size of 0.25 to 1 mm that can easily be invaded by blood vessels resulting in osteoblastic migration. . ABB is up to 75% porous and has a high specific surface area of almost 100 m<sup>2</sup>/g that results in increased angiogenesis, enhances new bone growth (Hammerle et al., 1997; Rodriguez, 2003), and excellent osteoconduction properties. However, its highly porous consistency sometimes compromises its mechanical properties and its initial stability. ABB lacks osteoinductive properties, and its presentation in form of granules makes it difficult to hold on surgical sites. Moreover, it is non resorbable *in vivo*. Indeed, ABB might need several years (3-6 years) of implantation before showing some slow *in vivo* resorption through osteoclast activity, (Skoglung et al, reported that granules were present even after 44 months (Skoglund., 1997) . The presence of unresorbed granules within the newly formed bone is undesired because it affects the quality of the newly formed bone by interfering with its remodelling, compromising its osteointegration capacity with dental implants.

Although ABB is mostly used in form of granules, xenografts blocks design are also available. Xenogenic derived bone block have already been reported to achieve vertical bone augmentation in the mandible. However, these materials are quite brittle and fragile. This mechanical inconvenience not only complicates the surgical technique but it also hinders the bone graft healing process (Simion et al 2006; Felice et al., 2009). Other types of xenogenic

(porcine) bone block seems to show better mechanical properties and low risk of fracture while screwing. (Simion et al., 2009). Generally speaking, the use of xenogenic bone blocks is still under evaluation and at this moment there is not sufficient information regarding its *in vivo* behaviour.

## 2.4 Synthetic calcium phosphates

Calcium phosphates constitute synthetic biomaterials that chemically resemble the bone mineral. Calcium phosphate biomaterials are widely selected to regenerate bone tissue due to their biocompatibility, osteointegration and osteoconductivity (Alkhraisat et al., 2008). We can make a classification of calcium phosphates in order to its  $\text{Ca}^{2+}$  and P compounds.

**Calcium Phosphates (CaP)**

**Ca<sup>2+</sup>**

CaP	Properties			
	Biocompatible	Reabsorbible	Osteoconductor	Osteoinductor
AP	+++	-	+++	-
CAP	+++	+	+++	-
$\beta$ -TCP	++	++	+++	+
DCPD	++	+++	+++	-
BCP	+++	++	+++	+

Table 3. Summary of synthetic calcium phosphate bone substitutes arranged to their chemical composition and biological properties

Regarding this classification is interesting to know that materials which contains high levels of  $\text{Ca}^{2+}$  ions have alkaline Ph and therefore shows low resorption capability as hidroxiapatite (AP), while materials with low levels of  $\text{Ca}^{2+}$  ions have acid Ph and shows high resorption properties, as dicalcium phosphate forms.

According to their preparation, calcium phosphate could be divided into high temperature (ceramics of tricalcium phosphates, hydroxyapatite and biphasic calcium phosphate) and low temperature (cements) calcium phosphates. Such bone substitutes differ in the degradation rate *in vivo*, strength, alkalinity and acidity, and crystallographic structure. Generally, they are fragile materials and should be used in non-load bearing areas.

Hydroxyapatite and  $\beta$ -tricalcium phosphate ( $\beta$ -TCP) are the ceramics mostly recruited clinically to treat bone defects and voids. Biologically, stoichiometric hydroxyapatite of Ca/P ratio of 1.67 is highly stable and its very slow degradation is mediated by phagocytosis [Constantino & Freidman, 1997]. Such handicap is managed by introducing impurities like carbonate ions, silicon ions and other ionic species present in the bone mineral [Alkhraisat et al., 2008]. Structurally, porous hydroxyapatite was introduced to resemble native bone architecture, improve the degradability and enhance tissue reaction of angiogenesis and new bone in-growth. This resulted in engineering apatite and calcium carbonate of live species to produce a hydroxyapatite conserving the macro and microporous architecture of the source. An example of such technology is the anorganic bovine bone, coral apatite and algae apatite.

Since the experiments reported by Albee and Morrison (Albee, 1920), research and development projects have been dedicated to explore the potential of  $\beta$ -TCP ceramic bone substitute.  $\beta$ -TCP has Ca/P ratio of 1.5 and is more resorbable than hydroxyapatite. This higher degradability is related to higher solubility that aid phagocytosis to induce biomaterial replacement with new bone.

Biphasic calcium phosphate (BCP) is engineered to combine the advantages of both hydroxyapatite and  $\beta$ -TCP. A relation of 60% hydroxyapatite and 40%  $\beta$ -TCP is the most common among commercial biphasic calcium phosphate.

These ceramics are presented in porous granular and block forms and they are difficult to reshape. The granules have a size range between 0.2 mm and 1mm.

The lack of adaptability of calcium phosphate ceramics was solved by Brown and co-workers when they developed calcium phosphate cement (Brown & Chow, 1985). This cement is the mixture of calcium phosphate powders that upon reacting with aqueous phase produce new calcium phosphate. The chemical reaction that produce this new phase is termed setting reaction and the consistency of the cement is progressed from paste-like to solid structure by the entanglement of the setting product. This enable the cement to be moulded, adapt intimately to the bone defect borders and permits the development of injectable preparation for minimally invasive surgery. Such cements are biocompatible, degradable and osteoconductive (Figure 1) (Alkhraisat et al., 2008).

Calcium phosphate cements are classified according to the setting reaction end-product to hydroxyapatite and brushite cements. Hydroxyapatite cement is first developed by Brown and co-workers and since then variuos formulation have been developed and patented. Of such formulations are tetracalcium phosphate/dicalcium phosphate anhydrous (DCPA) system and  $\alpha$ -TCP based system. The setting reaction of hydroxyapatite cement occurs at neutral pH which is biologically favourable. The hydroxyapatite as setting product is low-crystalline and the stoichiometry can be varied to produce calcium deficient-hydroxyapatite (Ca/P ratio less than 1.67). These features and the development of carbonated apatite cement improve the degradability of hydroxyapatite cement.

Since their development by Mirtchi and co-workers, brushite cements are recieveing much interest as bone substitute in the recent years [Mirtchi, 1990]. These cements are obtained by various combinations, such as  $\beta$ -TCP + monocalcium phosphate monohydrate (MCPM) and  $\beta$ -TCP + phosphoric acid. The setting reaction of these cements is a continuous dissolution/precipitation mechanism at low pH values as brushite precipitates at pH <6 [Alkhraisat et al., 2010]. The relatively short setting time of brushite cements compared with hydroxyapatite forming pastes depends on both the higher solubility of the cement raw materials and the higher rate of brushite crystal growth ( $3.32 \times 10^{-4} \text{ mol min}^{-1} \text{ m}^{-2}$ ) [compared with hydroxyapatite ( $2.7 \times 10^{-7} \text{ mol min}^{-1} \text{ m}^{-2}$ ) (Zawackiet al., 1996).

The main advantage of brushite is its higher degradability compared to hydroxyapatite that stems from higher solubility at physiological conditions. However, in vivo brushite transformation to hydroxyapatite is kinetically favourable and additives are patented to inhibit such transformation [Alkhraisat et al., 2010]. This fact have raised the attention to the anhydrous form of brushite, monetite, that is prepared by drying brushite. Monetite is more stable than brushite due to its lower solubility and in vivo transformation to hydroxyapatite was not reported ensuring a predictable degradability (Tamimi et al., 2009).



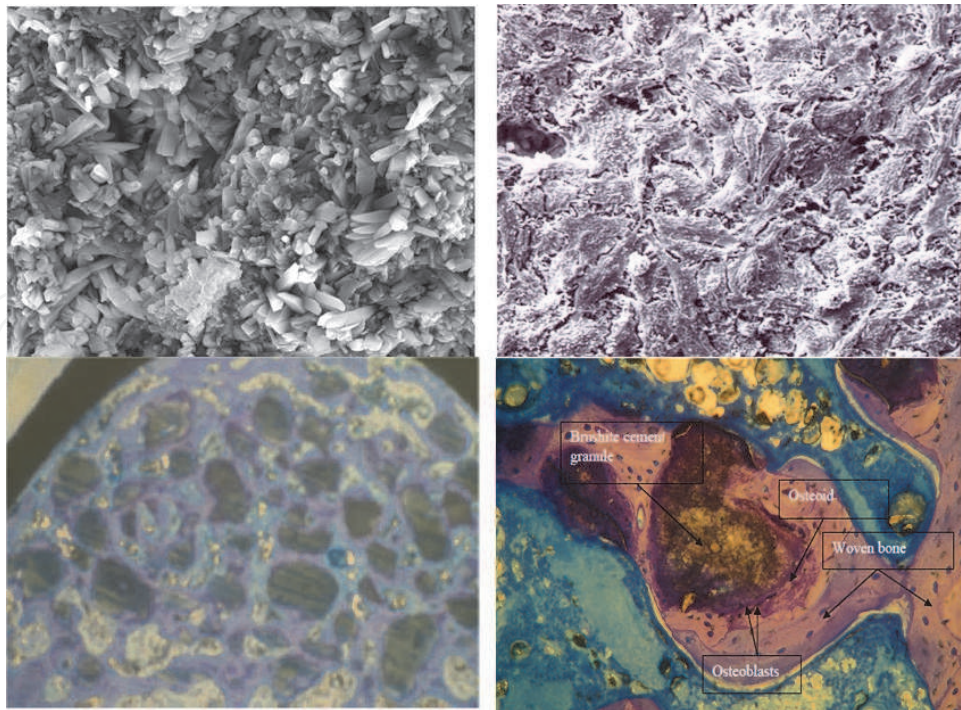


Fig. 1. The microcrystalline structure of dicalcium phosphate dihydrate cement provide support for osteoblasts growth and proliferation that permits bone formation on and between calcium phosphate granulate.

Recently, calcium phosphates are shown to be efficient as local drug and bioactives delivery system [Alkhraisat et al., 2010).and the technology is now available to prepare custom-made bone calcium phosphate based on patient's CT scan data to fit in a bone defect [Klammert et al., 2010). These biomaterials are the corner-stone in the development of 3D-porous scaffold in combination with organic components to resemble the inorganic-organic harmony of bone. Such scaffolds are designed to support the growth and differentiation of stem cells for their application in the emerging field of regenerative medicine.

## 2.5 Bio glass

Bioglass, also known as bioactive glass, is the commercial name for the first calcium substituted silicon oxide that was marketed as a bone regeneration material over 30 years ago. This material was developed by researchers working for the US army during the Vietnam War as a biomaterial for repairing bone loss in injured combat soldiers (Välimäki & Aro, 2006). In plain language bioglass is a glass similar to that in the windows of your house, but with a large portion of calcium in its chemical structure. It has a large surface area that is alkaline and highly reactive to serum ions. This feature enables it to interact with serum, allowing a very fast precipitation of hydroxyapatite on its surface once implanted *in vivo*. This phenomenon is called *bioactivity*, and is one of the unique characteristics of Bioglass that allows a quick integration to bone tissue.

Bioglass is suitable for bone regeneration in dental implant surgery; moreover, it is purely synthetic therefore it does not present problems regarding transmission of infectious diseases. However, its granule format is difficult to handle due to the repulsive charges between the highly charged surfaces the granules. This renders its clinical handling more demanding than other biomaterials (Välimäki & Aro, 2006).

The critical component of bioglass is SiO<sub>2</sub> which constitutes 45-60% of its weight. The first bioglass developed for bone regeneration was based on 4 components: SiO<sub>2</sub>, Na<sub>2</sub>O, CaO and P<sub>2</sub>O<sub>5</sub>. However, this composition tends to crystallize, and was modified to a more stable glass composed of: Na<sub>2</sub>O-K<sub>2</sub>O-MgO-CaO-B<sub>2</sub>O<sub>3</sub>-P<sub>2</sub>O<sub>5</sub>-SiO<sub>2</sub>. In vivo experiments have shown that implantation of bioglass in bone defects causes an inhibition in bone formation during the early healing stages, but it eventually doubles the amount of bone formed when no biomaterial is used.

Moreover, bioglass experiences severe resorption during the first 2 weeks after implantation. However, beyond this point its resorption rate stabilizes.

Upon implantation, the smaller ions present in bioglass (i.e. Na<sup>+</sup> and K<sup>+</sup>) tend to leach to the extracellular fluids. This results in a rich Si layer coating the biomaterial. Ca<sup>2+</sup> and PO<sub>4</sub><sup>3-</sup> ions from the body fluids then react and precipitate on the Si rich layer, forming a thin coat of hydroxyapatite. The calcium phosphate layer adsorbs proteins. And these extracellular properties attract macrophages stem cells and osteoprogenitor cells (Välimäki & Aro, 2006).

Bioactive glass can be used in form of granules or as preformed cones designed for placement into fresh sockets to maintain the alveolar ridge (Stanley et al., 1997). It has shown clinical success in vertical bone augmentation procedures, in regeneration intra-bony defects and in the preservation of alveolar sockets (Gatti et al., 2006). However, even though it is resorbable and promotes bone formation, its bone regeneration capacity in maxillofacial surgery has been shown to be lower than Calcium phosphate biomaterials (Santos et al., 2010).

### 3. Surgical procedures that require the use of bone substitutes

#### 3.1 Sinus lift

Bone augmentation in sinus lifting procedures requires the use of bone regeneration biomaterials that would enable bone formation within the maxillary sinus. Ideally besides good osteoconductive properties, biomaterials used for sinus lifting should be easy to handle, and have a limited *in vivo* resorption. Underneath we discuss the main bone substitutes that have been employed in sinus lift bone augmentation procedures

*Autograft:* The use of bone autografts are recommended when treating large pneumatized sinuses and a short treatment period is required. The healing period in such situations is 3-4 months shorter than when other bone substitutes are used (7-9 months). Also the use of autografts is an option when patients reject the use of allograft or bovine bone. Several studies have reported high rate of success using autografts from either endochondral or intramembranous origin. (Daelemans et al., 1997). Intramembranous bone has been shown to resorb less readily than endochondral bone (Hardesty et al., 1990). Despite the excellent clinical results obtained with autografts, a high degree of morbidity has been reported in such procedures. In order to diminish the morbidity and also the high resorption rate of autografts, many clinicians use autografts in combination with other bone substitutes in different proportions, and obtaining promising results.

*Autografts combined with ABB:* Studies evaluating the use of bone autografts in combination with ABB, have shown great results in terms of percentage of newly formed bone in the sinus and subsequent implant success rate. Bone formation is higher when a major percentage of autograft is added (48%) and significantly lower amounts of vital bone forms when autograft is used in minimal proportions. Froum et al. observed a statistically significant increase in vital bone formation when as little as 20% autologous bone was added to ABB compared with ABB alone. Nevertheless, a high percentage of bone volume

formation within the sinus is not a crucial parameter regarding the subsequent success rate of the dental implants. Indeed, bone volumes as low as 24% have shown to be sufficient for successful osteointegration of dental implants placed in augmented maxillary sinuses (Esposito et al., 2010).

<b>Vital bone formation with different types of graft in sinus augmentation</b>			
<i>Authors</i>	<i>ABB:Autograft</i>	<i>Healing time (months)</i>	<i>Vital bone (%)</i>
<i>Hallman et al 2002</i>	100 Autograft	6-9	37
<i>John et al 2004</i>	100 Autograft	3-8	53
<i>Mish &amp; Krauser 2003</i>	20:80	4-9	48
<i>Mish &amp; Krauser 2003</i>	40:60	4-9	36
<i>Mish &amp; Krauser 2003</i>	60:40	4-9	38
<i>Galindo et al 2010</i>	80:20	6-9	46
<i>Hallman et al 2002</i>	80:20	6-9	41
<i>Froum et al 2008</i>	100 ABB	6	22
<i>Hallman et al 2002</i>	100 ABB	6-9	39
<i>John et al 2004</i>	100 ABB	3-8	29

Table 4. Overview of different composite graft material in sinus lift technique

*Allografts:* Despite the risk of disease transmission associated with its use, approximately 350,000 to 400,000 bone allograft procedures are performed in the United States, Out of which 100,000 are dental related. The use of Allografts in sinus augmentation procedures has shown high success rates. (Avila et al., 2010). The percentage of bone volume obtained with FDBA in sinus lifting procedures is 23%. Moreover, the success rate of implants placed in the maxillary sinuses following bone augmentation with solely applied allograft has been shown to be a 97.7% in three years follow up (Minichetti et al., 2008). On the other hand, Peleg et al reported a 100% success rate over 160 implants placed in 63 grafted sinuses using as graft material autogenous graft harvested from symphysis with DFDBA combined in 1:1 ratio after a 4 year follow up (Peleg et al., 1999).

DFDBA was compared with autograft in sinus augmentation procedures; DFDBA showed 29% of new bone formation compared to a 40% achieved with autograft (Kao 11). Froum also studies the differences between FDBA and ABB, observing a high vital bone formation (28%) in FDBA grafted sinuses compared to a 12% in ABB grafted ones'. (Froum et al., 2006). No differences have been observed between DFDBA and FDBA in terms of percentage of vital bone formation in the maxillary sinus.

*Anorganic bovine bone (ABB):* ABB is a biocompatible and osteoconductive anorganic bovine bone (ABB), that provides an ideal scaffold for new bone formation (Hammerle et al., 1998, Piatelli et al., 1999). It has been extensively used in maxillary sinus floor augmentation (Valentini et al., 2003, Wallace et al., 2005) with high clinical success rates (Carmagnola et al., 2003). Comparative studies by Hallman et al and Valentini and Abensur observed higher survival rates for implants placed in sinuses grafted with 100% ABB compared with sinuses grafted with 100% autograft (Hallman., 2002, Valentini., 2003). Also Froum reports higher implant survival rate in sinuses grafted with ABB alone than those grafted with a composite of ABB+DFDBA (Froum et al., 2006). In a recent study Torres et al observed a 97% implant success rate in 286 implants placed in 144 sinuses grafted with ABB alone or ABB+PRP. Overall, 96.2% of ABB and 98.6% of ABB+PRP implant success was obtained during the monitoring period and differences were not found between sites grafted with and without



PRP in the 87 patients studied. (Torres et al., 2009). Regarding vital bone formation achieved with ABB in maxillary sinuses, Scarano et al compared ABB to autograft bone in maxillary sinus augmentation procedures. In this study, 6 months after the initial intervention, ABB resulted in 39% new bone formation compared to 40% with autograft. Although the results of new bone generation were very similar, 31% of the grafted Bio-Oss was still present at the graft site compared to only 18% of autograft (Scarano et al., 2006). (Fig 2)

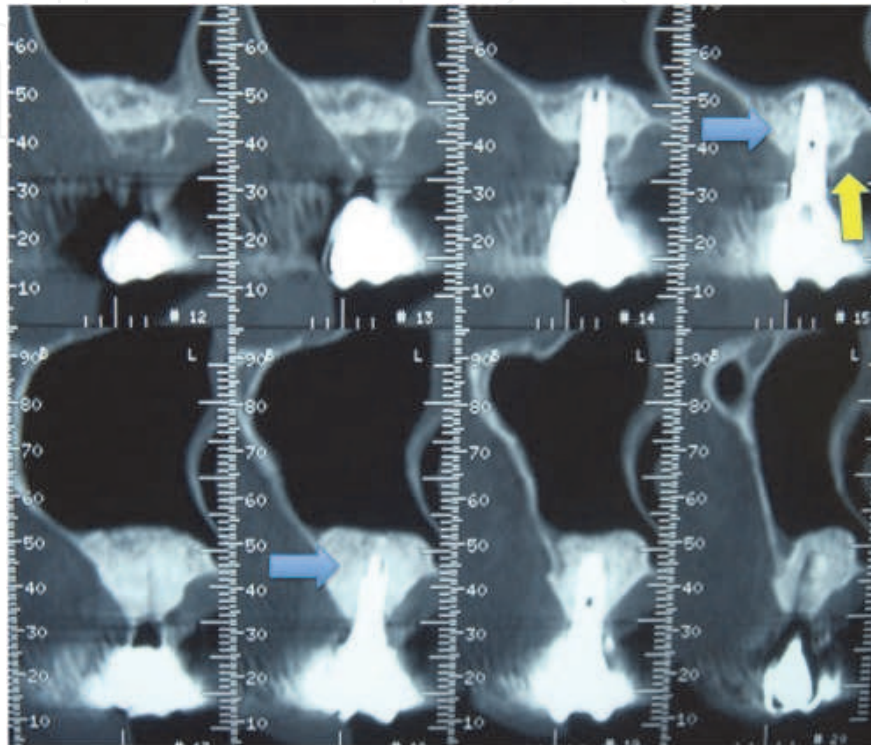


Fig. 2. Slow resorption of ABB particles could be observed after 24 months of implant's placement. Blue arrow shows remanent ABB graft. Yellow arrow shows residual host bone

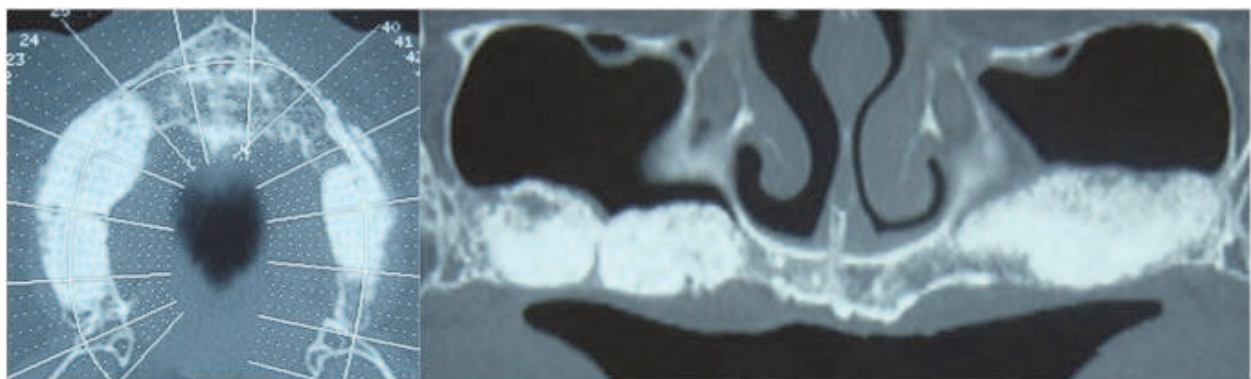


Fig. 3. Bilateral sinus augmentation performed with ABB alone as graft material.

Synthetic calcium phosphate such as  $\beta$ -TCP ceramic granules have also been used in sinus augmentation techniques with high rate of implant success. In a comparative study, Simunek et al showed that a higher proportion of the new vital bone was achieved with ABB (34.2%) compared to  $\beta$ -TCP (21.4%). (Simunek et al. 2008)

However Szabó et al in another comparative study between  $\beta$ -TCP ceramic granules versus autograft observe that vital bone areas were 36% and 38%, respectively.(Szabó et al. 2005) Rapidly resorbable biomaterials are not recommended for sinus lift procedures since the maxillary sinus is a non functional site for bone to form, and in the absence of mechanical load any bone augmentation achieved is likely to be lost if the scaffold provided by the biomaterial resorbs. For these reasons the most suitable biomaterials for sinus lifting procedures are osteoconductive biomaterials with limited or non resorption properties such as granules of ABB,  $\beta$ -TCP, hydroxyapatite, biphasic calcium phosphate and Bioglass. In a recent systematic review performed by Esposito, it was concluded that ABB and  $\beta$ -TCP might be as effective as bone autografts for augmenting atrophic maxillary sinuses. Therefore these biomaterials might be used as replacement for autogenous bone grafting (Esposito et al. 2010).(Fig 3)

### **3.2 Alveolar ridge augmentation**

#### **3.2.1 Onlay bone grafts**

##### **Onlay bone grafts**

Onlay bone grafting is the most predictable technique available for bone augmentation of the alveolar ridge. This procedure is used to augment bone before or at the time of implant placement to ensure proper implant osteointegration (Rocchietta et al. 2008)

Onlay bone grafting is achieved by fixing a biomaterial in the shape of a block directly onto the bone surface of the alveolar ridge, and covered with the periosteum and oral mucosa. This procedure requires a biomaterial strong enough to bear direct occlusal forces and allow screw fixation. Besides, the biomaterial should also be bioresorbable and osteoconductive.

Currently the best available biomaterial for onlay bone grafting is the autologous bone graft. Autologous onlay bone grafts can be harvested from extra-oral or intra-oral bones (Rocchietta et al., 2008). Onlay grafts of autologous bone can resorb once implanted, limiting the amount of bone volume available for dental implant stabilization. In this sense, intra-oral grafts are always preferred, since they tend to resorb less than extra-oral bone grafts after implantation (Rocchietta et al., 2008).

The limited amount of autologous bone available for grafting alongside the morbidity associated to the donor site has driven the need for developing alternative materials. Accordingly, alloplastic, allogenic and xenogenic onlay blocks have been recently developed and tested showing promising results. Several animal studies have shown that blocks made of either allogenic materials, hydroxyapatite, tricalcium phosphate or monetite are capable of achieving vertical bone augmentation in onlay bone graft procedures (Tamura et al., 2007, Tamimi et al., 2009, Fujita et al., 2003, Hetherington et al., 1996). Moreover, clinical studies have confirmed the great potential of allogenic bone blocks as biomaterials for onlay bone augmentation (Waasdorp et al., 2010)

In order to achieve success with an onlay bone graft procedure, the onlay blocks have to be firmly secured to the recipient bone surfaces with osteosynthesis screws. These screws used for onlay bone grafts are made of either titanium or of a resorbable biomaterial. Titanium screws are stronger, but they require a second surgery for removal before implant placement, sometimes resulting in screw fracture during removal. Resorbable screws are weaker but do not need to be removed. Both screw systems offer predictable clinical results (Quereshy et al., 2010).



Usually, onlay bone grafts are placed without the use of barrier membranes. This fact renders the onlay sensitive to masticatory forces, and requires the patients not to wear any removable prosthesis after the regeneration procedure for a period of at least 2 months (Rocchietta et al., 2008). For this reason, recent studies have tested the benefits of covering onlay bone grafts with resorbable membranes. This novel procedure, been shown to be beneficial in preventing grafts resorption due to masticatory forces (Rocchietta et al., 2008). (Fig 4,5)

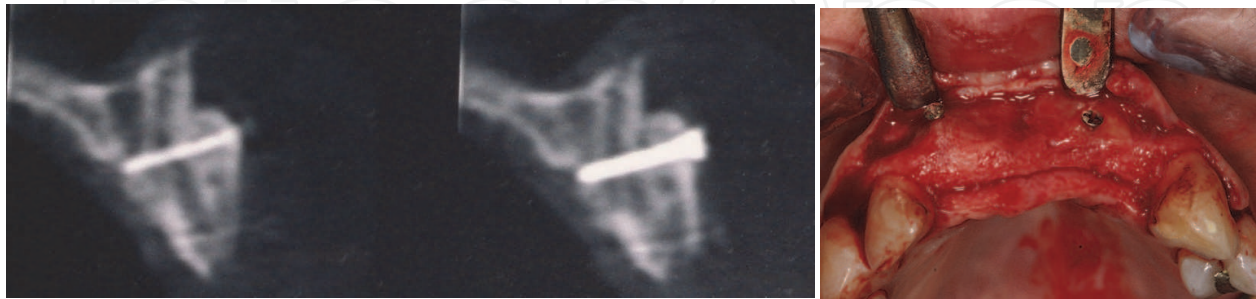


Fig. 4. Slightly resorption with autogenous intraoral bone in the most coronal part of the graft is observed in a patient where no membrane was used.

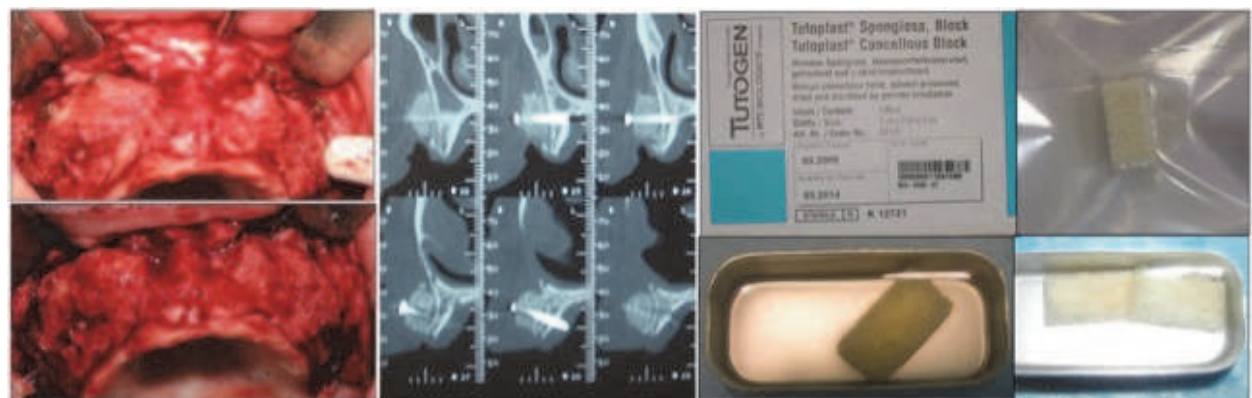


Fig. 5. Remodelling of allograft has been produced after 4 month. Grafts of right side of the patient were covered by a membrane conserving all the volume, while left side graft's were not covered observing more resorption in this side.

### 3.2.2 Guided bone regeneration & titanium mesh

Guided bone regeneration (GBR) and Titanium mesh technique (Ti-mesh) provide bone augmentation of the alveolar ridge and create the conditions needed for better aesthetic and higher rate of dental implants success. In order to achieve high rates of success in GBR and Ti-mesh procedures, there are three major issues that need to be addressed: coagulum maintenance, free tension flap closure and an adequate biomaterial selection.

In the treatment of large defects autografts are considered the gold standard, since they have osteoinductive, osteoconductive, osteogenic properties and no risk of immunologic rejection. In view of mechanical properties, cancellous bone grafts still clearly surpassed by ABB, coral, or synthetic bone substitute. However, it provides a high amount of vital stem cells and proteins, such as BMPs, that result in osteogenesis and osteoinduction, therefore GBR with particulated autografts is a safe and predictable treatment (Urban et al., 2009).

Autografts combined with ABB have been used with success in GBR (Table 5). However in the last years different studies have shown that even allografts alone offer reliable results in

large defects, with less cost on the patient. In a study performed by Dahlin they conclude that reconstruction of atrophic maxillae with DFDB using the GBR technique can be performed with an equal success as iliac crest autografts (Dahlin., 2010)

Allografts, alloplasts or xenografts are considered appropriate candidates for small defects (Fig 6, 7). Allograft bone, is the most popular alternative to autogenous bone. It offers the substantial advantage of allowing the patient to avoid a second surgical procedure, with the attendant risks of pain, complications, and morbidity. Available in various shapes and sizes, allograft bone also has fewer supply restrictions than autograft material. Synthetic bone graft materials (alloplasts) constitute a third category of widely used bone-grafting materials, including such non-human, artificially produced materials as calcium sulfate, calcium phosphate, hydroxyapatite, and bioactive glass. Their advantages consist on their abundant supply, long shelf lives, and lack of potential disease transmission. Their capacity to predictably regenerate bone has not yet been demonstrated consistently. Xenografts constitute the final category of bone-grafting materials in common use. Derived from animal sources, xenografts have been developed largely in response to the donor site complications associated with autografts, as well as the limited supplies of both autogenous and allograft material. Porous bovine-derived material is by far the most common variety of xenograft in use today. Such material has been demonstrated to be highly biocompatible. Histologic analysis has found bovine bone particles to be well incorporated within newly regenerated grafted bone and a high degree of osseointegration

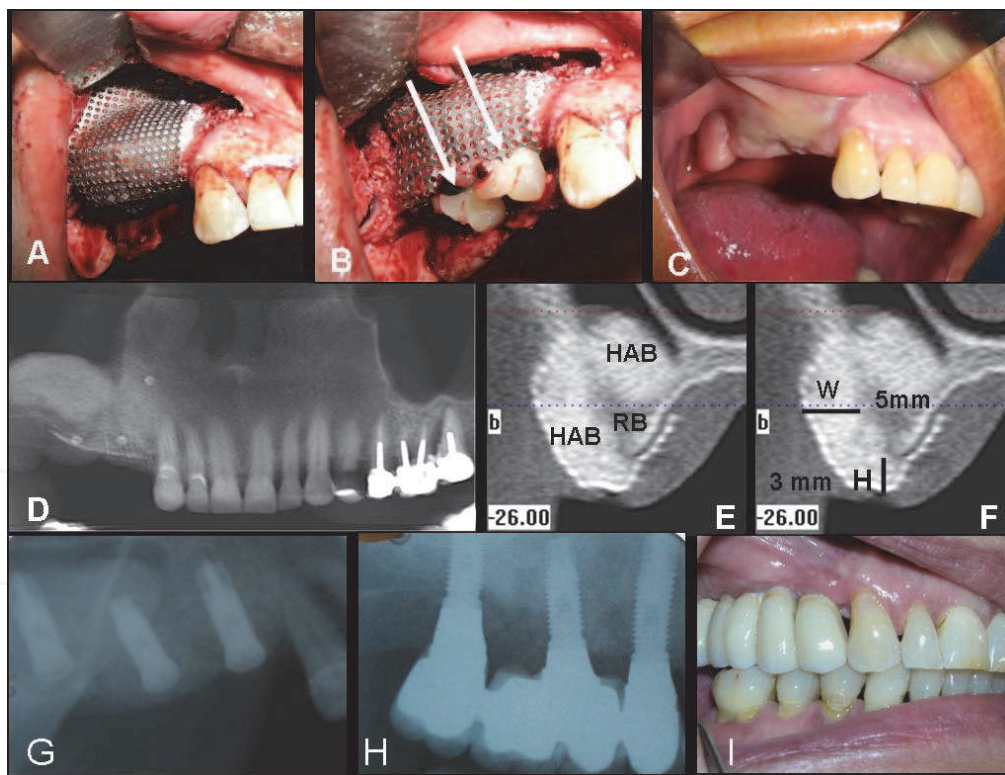


Fig. 6. A. Ti mesh augmentation procedure in upper maxilla using ABB alone as graft material. B. PRP covering Ti mesh in order to enhance soft tissue healing. C. Soft tissue healing after six month of surgery. D,E, F. TC scan images showing horizontal (5 mm) and vertical (3 mm) bone augmentation achieved. G,H,I. Implant's placement and prosthesis evaluation radiography. I. Image of prosthesis rehabilitation.



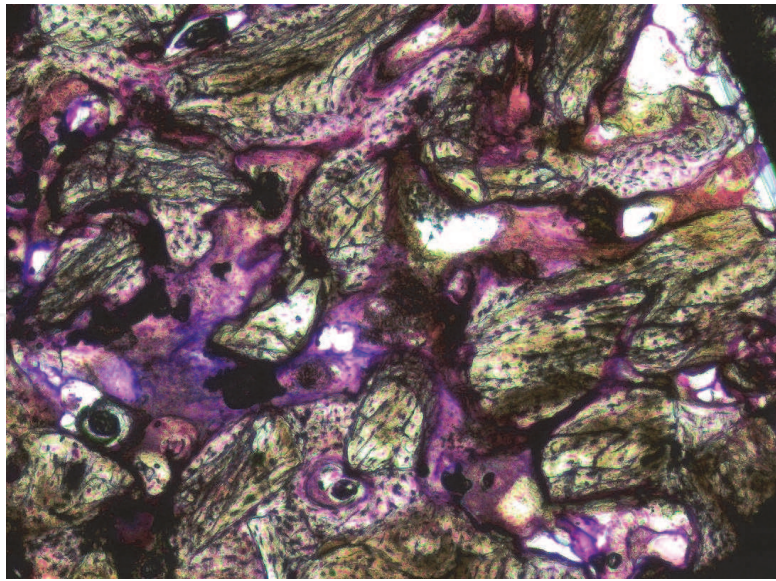


Fig. 7. ABB particles surrounded by newly formed bone in a Ti-mesh bone augmentation procedure where ABB alone was used as graft material.

Type of Graft (%)	ABW (mm)	ABH (mm)	Survival (%)	Success (%)	References
AB (100)	ID	ID	ID	ID	Von Arx et al 1996
AB (100)	5.65	ID	ID	100	Malchiodi et al 1998
AB (100) *	ID	5	ID	ID	Rocuzzo et al 2004
AB (100) *	ID	4.8	100	100	Rocuzzo et al 2007
AB/ABB (50/50)	ID	ID	98.3	ID	Maiorana et al 2001
AB/ABB (70/30)	4.16	3.71	100	100	Pieri et al 2008
AB/ABB (70/30)	ID	ID	100	100	Corinaldesi et al 2007
AB/ABB (ID)	3.71	2.86	ID	ID	Profusaefs & Lozana 2006
ABB (100)	ID	5.2	100	ID	Artzi et al 2003

*Pts: patients; BAP: bone augmentation procedures; ABW: average bone width gained; ABH: average bone height gained; AB: autologous bone; ID: insufficient data; \*: block grafts.*

Table 5. Summary of clinical studies reporting the amount bone gained, type of graft and complications rate using the Ti-mesh technique. (Modified from Torres et al 2010)

### 3.3 Treating fenestrations and dehiscence

Particulate autogenous bone, anorganic bovine bone and FDBA have been proposed for treatment such defects in combination with GBR technique.

## 4. Summary

Since the introduction of dental implants, bone grafting has become an important procedure required for the treatment of patients with limited bone availability. Bone autograft, alone or together with other bone substitutes, has been the biomaterial of choice for clinicians

worldwide. However different xenogenic, allogenic and synthetic biomaterials have shown promising results in many bone augmentation procedures.

The bone substitute needed for each bone regeneration procedure must be selected based on the individual's characteristics, and the surgical procedure it self. Factors such as the osteogenic potential of the host residual bone, systemic health of patients, and morphology of the defects, will delimit the ideal bone substitute for each situation. For example in sinus augmentation, allografts, xenografts and synthetic calcium phosphates have been used as alternative to autografts with high rate of implants success and survival. On the other hand, when major alveolar ridge augmentations are required autograft onlay block are the most predictable biomaterials, although autograft granules mixed in different proportions with ABB in GBR procedures have also a high rate of success.

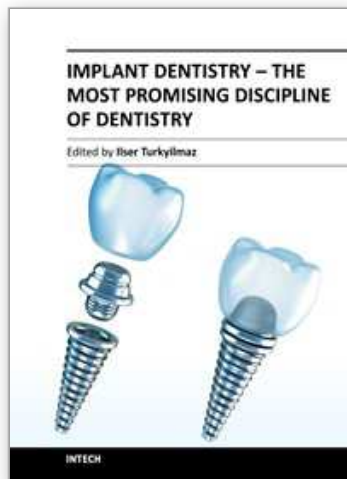
## 5. References

- Albee FH. (1920). *Ann Surg.*;71(1):32-9.
- Albert A, Leemrijse T, Druetz V, Delloye C. & Cornu O. (2006). *Acta Orthop Belg*; 72(6):734-40.
- Alkhraisat MH, Rueda C, Jerez LB, Tamimi Mariño F, Torres J, Gbureck U & Lopez Cabarcos E. (2010).. *Acta Biomater*;6:257-65.].
- Alkhraisat MH, Moseke C, Blanco L, Barralet JE, Lopez-Cabarcos E. & Gbureck U. (2008). *Biomaterials*;29:4691-7.
- Alkhraisat MH, Mariño FT, Retama JR, Jerez LB. & López-Cabarcos E.(2008). *J Biomed Mater Res*;84:710-7
- Artzi, Z ., Dayan, D., Alpern, Y. & Nemcovsky C.E. (2003). *International Journal Oral Maxillofacial Implants* 18,440-446
- Arrington ED, Smith WJ, Chambers HG, Bucknell AL. & Davino NA.(1996). *Clin Orthop Relat Res*;(329):300-9.
- Avila G, Neiva R, Misch CE, Galindo-Moreno P, Benavides E, Rudek I & Wang HL. (2010).*Implant Dent*;19(4):330-41.
- Bauer TW. & Muschler GF.(2000).. *Clin Orthop Relat Res*;(371):10-27. .
- Brown W. & Chow L. (1985). Dental restorative cement pastes. US Patent No. 4518430
- Cammack GV 2nd, Nevins M, Clem DS 3rd, Hatch JP & Mellonig JT. (2005). *Int J Periodontics Restorative Dent*;25(3):231-7.
- Cohen RE, Mullarky RH, Noble B, Comeau RL. & Neiders ME. (1994) *J Periodontol*; 65; 1008-15
- Constantino PD & Freidman CD. (1997).. *Otolaryngol Clin North Am*;27:1037-1073
- Carmagnola, D., Adriaens, P. & Berglundh, T. (2003). *Clinical Oral Implants Research* 14, 137-143
- Corinaldesi G., Pieri F., Marchetti C., Fini M., Aldini N. N. & Giardino R. (2007). *Journal of Periodontology* 78,1477-1484.
- Daelemans P, Hermans M, Godet F. & Malevez C.(1996). *Clin Oral Implants Res*;7(2):162-9.
- Dahlin C, Simion M. & Hatano N.(2010). *Clin Implant Dent Relat Res*;12(4):263-70
- Drosos GI, Kazakos KI, Kouzoumpasis P & Verettas DA.(2007). *Injury*;38 Suppl 4:S13-21.
- Eppley BL, Pietrzak WS. & Blanton MW.(2005). *J Craniofac Surg*;16(6):981-9.
- Esposito M, Piattelli M, Pistilli R, Pellegrino G. & Felice P.(2010). *Eur J Oral Implantol*;3(4):297-305.
- Felice P, Marchetti C, Iezzi G, Piattelli A, Worthington H, Pellegrino G. & Esposito M (2009).. *Clinical Oral Implants Research*; 20;1386-93

- Frame JW, Rout PG. & Browne RM.(1987). *J Oral Maxillofac Surg*;45(9):771-8.
- Froum SJ, Wallace SS, Elian N, Cho SC & Tarnow DP.(2006). *Int J Periodontics Restorative Dent*;26(6):543-51.
- Froum SJ, Wallace SS, Cho SC, Elian N & Tarnow DP.(2008).. *Int J Periodontics Restorative Dent*.;28(3):273-81.
- Fujita R, Yokoyama A, Kawasaki T & Kohgo T.(2003).. *J Oral Maxillofac Surg*;61(9):1045-53.
- Galindo-Moreno P, Moreno-Riestra I, Avila G, Fernández-Barbero JE, Mesa F, Aguilar M, Wang HL. & O'Valle F.(2010).. *Clin Oral Implants Res*.;21(1):122-8.
- Gatti AM, Simonetti LA, Monari E, Guidi S. & Greenspan D.(2006). *J Biomater Appl*;20(4):325-39.
- Giannoudis PV, Dinopoulos H. & Tsiridis E.(2005). *Injury*;36 Suppl 3:S20-7.
- Hallman M, Sennerby L. & Lundgren S.(2002). *J Oral Maxillofac Surg*;60(3):277-84.
- Hämmerle, C.H., Chiantella, G.C., Karring, T. & Lang, N.P. (1998) *Clinical Oral Implants Research*; 9: 151-162
- Hämmerle CH, Olah AJ, Schmid J, Flückiger L, Gogolewski S, Winkler JR. & Lang NP.(1997). *Clin Oral Implants Res*;8(3):198-207
- Hetherington HE, Hollinger JO, Morris MR. & Panje WR.(1996). *Ann Otol Rhinol Laryngol*.;105(7):568-73.
- John HD. & Wenz B.(2004). *Int J Oral Maxillofac Implants*;19(2):199-207.
- Khan SN, Tomin E. & Lane JM.(2000). *Orthop Clin North Am*;31(3):389-98
- Kao ST. & Scott DD.(2007). *Oral Maxillofac Surg Clin North Am*;19(4):513-21
- Klammert U, Gbureck U, Vorndran E, Rödiger J, Meyer-Marcotty P. & Kübler AC. (2010).. *J Craniomaxillofac Surg*;38:565-70.
- Maiorana C., Santoro F., Rabagliati M.& Salina S. (2001). *International Journal Oral Maxillofacial Implants* 16,427-432.
- Malchiodi L., Scarano A., Quaranta M. & Piattelli A. (1998). *International Journal Oral Maxillofacial Implants* 13,701-705.
- Minichetti JC, D'Amore JC. & Hong AY.(2008). *J Oral Implantol*.;34(3):135-41.
- Mirtchi AA, Lemaitre J & Terao N.(1990).. *Biomaterials*:10:475-480
- Misch CE. & Dietsch F.(1993). *Dent Implantol Update*;4(12):93-7
- Moore WR, Graves SE. & Bain GI.(2001). *ANZ J Surg*;71(6):354-61
- Peleg M, Mazor Z. & Garg AK.(1999). *Int J Oral Maxillofac Implants*;14(4):549-56.
- Petersson K, Pamenius M, Eliasson A, Narby B, Holender F, Palmqvist S. & Håkansson J.(2006). *Swed Dent J*.;30(2):77-86
- Piattelli, M., Favero, G.A., Scarano, A., Orsini, G. & Piattelli, A. (1999) *International Journal of Oral and Maxillofacial Implants* 14, 835-840.
- Pieri F., Corinaldesi G., Fini M, Aldini N. N., Giardino R. & Marchetti C. (2008). *Journal of Periodontology* 79,2093-2103.
- Proussaefs P. & Lozada J. (2006). *Journal of Oral Implantology* 32,237-247.
- Reddi AH.(1998). *Clin Orthop Relat Res*;(355 Suppl):S66-72.
- Quereshy FA, Dhaliwal HS, El SA, Horan MP. & Dhaliwal SS.(2010). *J Oral Maxillofac Surg*;68(10):2497-502.
- Rocchietta I, Fontana F. & Simion M.(2008). *J Clin Periodontol*;35(8 Suppl):203-15.
- Rocuzzo M., Ramieri G., Spada M. C., Bianchi S. D. & Berrone S. (2004). *Clinical Oral Implants Research* 15,73-81



- Roccuzzo, M., Ramieri, G., Bunino, M. & Berrone S. (2007). *Clinical Oral Implants Research*. 18,286-294
- Rodriguez A, Anastassov GE, Lee H, Buchbinder D. & Wettan H.(2003). *J Oral Maxillofac Surg.*;61(2):157-63
- Santos FA, Pochapski MT, Martins MC, Zenóbio EG, Spolidoro LC. & Marcantonio E Jr.(2010). *Clin Implant Dent Relat Res*;12(1):18-25.
- Scarano A, Degidi M, Iezzi G, Pecora G, Piattelli M, Orsini G, Caputi S, Perrotti V, Mangano C.& Piattelli A.(2006). *.Implant Dent*;15(2):197-207.
- Simunek A, Kopecka D, Somanathan RV, Pilathadka S. & Brazda T.(2008). *Int J Oral Maxillofac Implants*;23(5):935-42.
- Simion M, Rocchietta I, Kim D, Nevins M. & Fiorellini (2006). *International Journal Periodontics and Restorative Dentistry*;26: :415-23
- Simion M, Nevins M, Rocchietta I, Fontana F, Maschera E, Schupbach P & Kim DM (2009).. *International Journal Periodontics and Restorative Dentistry*;29: 245-55.
- Simunek A, Kopecka D, Somanathan RV, Pilathadka S. & Brazda T.(2008). *Int J Oral Maxillofac Implants*;23(5):935-42.
- Skoglund A, Hising P. & Young C.(1997). *Int J Oral Maxillofac Implants*;12(2):194-9.
- Stanley HR, Hall MB, Clark AE, King CJ 3rd, Hench LL. & Berte JJ.(1997). *Int J Oral Maxillofac Implants*;12(1):95-105
- Stevenson S.(1999). *Orthop Clin North Am.*;30(4):543-52.
- Szabó G, Huys L, Coulthard P, Maiorana C, Garagiola U, Barabás J, Németh Z, Hrabák K. & Suba Z.(2005). *Int J Oral Maxillofac Implants*;20(3):371-81.
- Tamimi F, Torres J, Gbureck U, Lopez-Cabarcos E, Bassett DC, Alkhraisat MH. & Barralet JE.(2009). *Biomaterials*;30(31):6318-26.
- Tamura K, Sato S, Kishida M, Asano S, Murai M. & Ito K.(2007).. *J Periodontol*;78(2):315-21.
- Torres, J., Tamimi, F., Martinez, P.P., Alkhraisat, M.H., Linares, R., Hernández, G., Torres-Macho, J. & López-Cabarcos, E. (2009). *Journal of Clinical Periodontology* 36, 677-687.
- Urban IA, Jovanovic SA. & Lozada JL.(2009). *Int J Oral Maxillofac Implants*;24(3):502-10.
- Valentini, P. & Abensur, D.J. (2003) *International Journal of Oral and Maxillofacial Implants* 18, 556-560.
- Välimäki VV. & Aro HT.(2006). *Scand J Surg*;95(2):95-102.
- Virolainen P, Perälä M, Vuorio E. & Aro H.(1995). *Clin Orthop Relat Res*;(317):263-72.
- Von Arx T., Hardt N. & Wallkamm B. (1996 *International Journal Oral Maxillofacial Implants* 11,387-394.
- Waasdorp J. & Reynolds MA.(2010). *Int J Oral Maxillofac Implants*;25(3):525-31.
- Wallace RH. (2000). *The European Journal of Prosthodontic and Restorative Dentistry* 8, 103-106
- Zawacki SJ, Koutsoukos PB, Salimi NH. & Nancollas GH.(1996). vol. (323). Am Chem Soc Symp Series;. p. 650-62.



## **Implant Dentistry - The Most Promising Discipline of Dentistry**

Edited by Prof. Işer Turkyılmaz

ISBN 978-953-307-481-8

Hard cover, 476 pages

**Publisher** InTech

**Published online** 30, September, 2011

**Published in print edition** September, 2011

Since Dr. Branemark presented the osseointegration concept with dental implants, implant dentistry has changed and improved dramatically. The use of dental implants has skyrocketed in the past thirty years. As the benefits of therapy became apparent, implant treatment earned a widespread acceptance. The need for dental implants has resulted in a rapid expansion of the market worldwide. To date, general dentists and a variety of specialists offer implants as a solution to partial and complete edentulism. Implant dentistry continues to advance with the development of new surgical and prosthodontic techniques. The purpose of *Implant Dentistry - The Most Promising Discipline of Dentistry* is to present a contemporary resource for dentists who want to replace missing teeth with dental implants. It is a text that integrates common threads among basic science, clinical experience and future concepts. This book consists of twenty-one chapters divided into four sections.

### **How to reference**

In order to correctly reference this scholarly work, feel free to copy and paste the following:

Jesus Torres, Faleh Tamimi, Mohammad Alkhraisat, Juan Carlos Prados-Frutos and Enrique Lopez-Cabarcos (2011). Bone Substitutes, *Implant Dentistry - The Most Promising Discipline of Dentistry*, Prof. Işer Turkyılmaz (Ed.), ISBN: 978-953-307-481-8, InTech, Available from: <http://www.intechopen.com/books/implant-dentistry-the-most-promising-discipline-of-dentistry/bone-substitutes>

**INTECH**  
open science | open minds

### **InTech Europe**

University Campus STeP Ri  
Slavka Krautzeka 83/A  
51000 Rijeka, Croatia  
Phone: +385 (51) 770 447  
Fax: +385 (51) 686 166  
[www.intechopen.com](http://www.intechopen.com)

### **InTech China**

Unit 405, Office Block, Hotel Equatorial Shanghai  
No.65, Yan An Road (West), Shanghai, 200040, China  
中国上海市延安西路65号上海国际贵都大饭店办公楼405单元  
Phone: +86-21-62489820  
Fax: +86-21-62489821

© 2011 The Author(s). Licensee IntechOpen. This chapter is distributed under the terms of the [Creative Commons Attribution-NonCommercial-ShareAlike-3.0 License](#), which permits use, distribution and reproduction for non-commercial purposes, provided the original is properly cited and derivative works building on this content are distributed under the same license.

IntechOpen

IntechOpen