

We are IntechOpen, the world's leading publisher of Open Access books Built by scientists, for scientists

4,800

Open access books available

122,000

International authors and editors

135M

Downloads

Our authors are among the

154

Countries delivered to

TOP 1%

most cited scientists

12.2%

Contributors from top 500 universities



WEB OF SCIENCE™

Selection of our books indexed in the Book Citation Index
in Web of Science™ Core Collection (BKCI)

Interested in publishing with us?
Contact book.department@intechopen.com

Numbers displayed above are based on latest data collected.

For more information visit www.intechopen.com



Myoclonic Epilepsy in Lysosomal Storage Disorders

Andrea Dardis and Bruno Bembi

*Regional Coordinator Centre for Rare Diseases
University Hospital "Santa Maria della Misericordia" of
Udine Piazzale, Santa Maria della Misericordia, Udine,
Italy*

1. Introduction

Progressive myoclonic epilepsy (PME) constitutes an heterogeneous group of diseases, usually of genetic origin, which begins in childhood and adolescence and presents a variable evolution, ranging from slowly to rapidly progressive forms with refractory seizures and death within few years (Marseille Consensus Group, 1990). Despite its broad spectrum of manifestations, patients affected with PME share some common specific clinical and electrophysiological features, such as: myoclonus, multiple type of seizures, delay or regression of psychomotor development, cerebellar ataxia, slow background activity on electroencephalogram (EEG), spikes and waves induced by intermittent photo-stimulation and sensory evoked giant potentials (Marseille Consensus Group, 1990).

From the genetic point of view, PME occurs in disorders presenting different genetic inheritance, including: the dentatorubralpallidolusyan atrophy (DRPLA), a disease of trinucleotide repeats, the myoclonic epilepsy with ragged red fibers (MERRF), a mitochondrial disease and autosomal recessive disorders, which may be divided in two main categories: non-lysosomal-related diseases such as Lafora disease and lysosomal-related-disease such as lysosomal storage disorders (LSDs).

Lysosomal storage disorders are severe genetic diseases caused by the defective activity of lysosomal proteins, cofactors or integral membrane proteins, which result in the intra-lysosomal accumulation of undegraded metabolites such as sphingolipids, cholesterol, glycoproteins, mucopolysaccharides or glycogen. Even if they are individually rare, the combined frequency of LSDs is estimated to be approximately 1 in 8000 live births (Meilke et al., 1999; Poorthuis et al., 1999; Applegarth et al., 2000; Dionisi-Vici et al., 2002; Pinto et al., 2004; Poupetova et al., 2010).

More than 50 LSDs have been described to date (Staretz-Chacham et al., 2009). Although they are characterized by a wide spectrum of clinical phenotypes, many of these disorders present with severe progressive neurological impairment. Among the neurological symptoms, the presence of PME has been reported in different LSDs, including Gaucher disease, action myoclonus-renal failure syndrome, neuronal ceroid lipofuscinoses, sialidosis, Niemann Pick type C disease, and GM2 gangliosidosis. Each of these LSDs is characterized by a series of specific signs and symptoms. However, many of them share some clinical and biochemical features, such as the presence of signs of neurological impairments other than PME or organ disorders, which may be useful in the diagnosis of patients presenting with PME due to LSD.

Although LSDs are the main cause of the inherited form of PME, lysosomal defects are poorly known as a cause of PME and the differential diagnosis might be challenging, particularly in adult patients who may present a milder form of the diseases.

Therefore, the aim of this review is to overview the clinical and molecular findings in patients with PME affected with LSDs and their therapeutic options.

2. Gaucher disease (GD)

GD, the most frequent LSD, is an autosomal recessive inherited disease due to the deficiency in the lysosomal hydrolase, acid β -glucosidase (GBA). The enzyme is present in the lysosomes of all nucleated cells and cleaves the β -glucosidic linkage of glucosylceramide (GlcCer) yielding glucose and ceramide. GBA deficiency leads to the progressive lysosomal accumulation of GlcCer and other glycosphingolipids (GSLs) and subsequent multi-organ dysfunction. The storage predominantly occurs in cells of the monocyte-macrophage lineage, but an increase in GlcCer concentration is detectable in most of the body tissues (Beutler & Grabowski, 2001).

GD is panethnic (Beutler & Grabowski, 2001; Zimran et al., 1992; Cox & Shofield, 1997; Erikson, 1986) and presents an incidence of one case per 60,000 live births in the general population (Meikle et al., 1999). However, it is the most frequent genetic disease in the Ashkenazi Jewish population where it shows a incidence of one case per 850 live births (Beutler et al., 1993).

2.1 Clinical aspects

The disease has been classically classified in three major clinical variants based on the presence and progression of central nervous system involvement. Type 1 GD (MIM# 230800), the most common phenotype, is characterized by enlargement and dysfunction of liver and spleen, displacement of normal bone marrow by storage cells and bone damage leading to infarctions and fractures. Although type 1 GD is considered a non-neuropathic form, there is increasing evidence that neurological involvement (i.e. Parkinson syndrome, seizures, oligophrenia, perceptive deafness) can occur. Type 2 GD (MIM# 230900) is a rare phenotype associated with an acute neurodegenerative course and death at a very early age. These patients commonly present during the first month of life with evidence of brainstem dysfunction consisting in supranuclear gaze palsy and hepatosplenomegaly followed by progressive deterioration, opisthotonus dysphagia, pyramidal signs, failure to thrive and cachexia. They may also have interstitial lung disease and repeated respiratory infections. Type 3, the chronic neuronopathic GD (MIM# 231000), comprises an extremely heterogeneous group of patients who present with either mild or severe systemic disease associated with some form of neurological involvement and with an onset of symptoms that might range from childhood to early adulthood (Beutler & Grabowski, 2001). A most consistent finding in patients affected with this form of GD is an abnormality of the horizontal gaze. Among GD3 patients it has been widely demonstrated the existence of a subgroup of patients sharing the rare finding of PME (Rapin et al., 1986; Seeman et al., 1996; Garvey et al., 2001; Park et al., 2003; Kraoua et al., 2010, Tylki-Szymanska et al., 2010). Published data from the International Collaborative Gaucher Group showed the presence of myoclonic epilepsy in 3 out of 121 patients who had suffered from seizures when first assessed. However, a study performed in a French cohort of 10 patients affected with GD3

showed the presence of PME in 2 (Kraoua et al., 2010). Similarly, unpublished data collected from GD3 patients followed in our Center showed that 3 out of 13 developed PME.

The analysis of the clinical phenotype in a group of 16 GD3 patients presenting with PME, showed that this is not an homogeneous phenotype. In fact, many clinical features found among this group were quite variable including age, sex, ethnic background, degree of visceral, skeletal, cognitive and cerebellar involvement and MRI findings. However, a clinical finding shared by all patients was the slowing of the horizontal saccadic eye movements, a feature present in GD3 patients that was independent of the extent of non-neurological manifestations. In addition, another finding shared among these patients was the abnormal EEG, often with generalized seizures. As disease progressed many of them developed ataxia, dementia and spasticity (Park et al., 2003).

2.2 Molecular aspects

Human GBA is a peripheral membrane glycoprotein. The mature non-glycosylated polypeptide is composed of 497 aminoacids with a molecular weight of about 56 kD while the glycosylated enzyme has a molecular weight of 63 kD (Leonova and Grabowski, 2000).

The human *GBA1* gene (GBA; MIM# 606463; GenBank accession no. J03059.1) of approximately 7.5 kb is located on chromosome 1q21 and contains 11 exons. A highly homologous 5.5 kb-pseudogene (GBAP; MIM# 606463; GenBank accession no. J03060.1) is located 16 kb downstream from the active gene (Horowitz et al., 1989). The *GBA* mRNA has two in-frame ATG translational sites located in exons 1 and 2 (Sorge et al., 1985). Both are efficiently translated and produce two polypeptides with signal peptides of 39 and 19 residues, respectively (Sorge et al., 1987; Pasmanik-Chor et al., 1996).

More than 300 mutations in the *GBA* gene have been reported to date, including all kinds of defects such as single base changes, splicing alterations, insertions, partial and total deletions, gene-pseudogene rearrangements (www.hgmd.org; Stenson et al., 2003).

Mutations N370S, 84GG, L444P, IVS2+1G>A account for 90% of mutant alleles in the Jewish population while they represent fewer than 75% of alleles among non-Jewish Caucasian patients with some differences in defined subpopulations (Beutler & Gelbart, 1993; Grabowski & Horowitz, 1997). In any case N370S and L444P alleles are the most prevalent throughout most population.

Although, no consistent correlation between the genotype and phenotype has been found, some general conclusions can be drawn regarding the neuroprotective nature of the N370S mutation and the association between the L444P allele and the severe phenotype.

The molecular study of the *GBA1* gene in a cohort of 16 GD3 patients with PME showed also within this subgroup a remarkable genotype heterogeneity even among patients with similar clinical presentation. However, an interesting finding of this study was the fact that while 72% of 122 GD3 patients included in the International Gaucher Registry carry the p.L444P/p.L444P genotype, only one out of 16 GD3 patients with PME presented this genotype, suggesting that the most frequent genotype found in GD3 patients would be underrepresented among GD3 patients with PME. In contrast, some rare mutants were encountered among GD3 patients with PME. In particular three point mutations seems to be associated with this phenotype, the V394L, N188S and G377S, suggesting that GD3 patients carrying one of these mutations in the absence of the N370S mutation should be carefully evaluated for PME (Park et al., 2003).

The correlation between the presence of N188S and the occurrence of PME in GD3 patients has been further supported by the work of Kowarz et al. showing a high frequency of the N188S mutation in a series of 17 GD3 patients with PME (Kowarz et al., 2005). In addition, the N188S/S107L genotype was also found in a GD3 patient with visual seizures and PME (Filocamo et al., 2004).

Mutation N188S was first described in Korean and Chinese Type I GD patients (Kim et al., 1996). Later, it was demonstrated by *in vitro* expression experiments that the GBA protein carrying the N188S mutation retained a high residual enzymatic activity (67% of control, Montfort et al., 2004). Furthermore, the residual GBA activity found in cultured fibroblasts obtained from a GD3 patient with PME who presented the N188S mutation was 24% of control (Park et al., 2003). The reasons for this apparent discordance between the residual activity and the clinical phenotype are not fully understood. However, the association between the presence of N188S mutation and PME in GD suggests that despite the high residual activity the mutation might alter the protein structure, binding, post-translational processing or might modify the role of other proteins involved in the etiology of the PME.

3. Action myoclonus-renal failure syndrome (AMRF)

AMRF (MIM 254900) is a lethal inherited form of PME associated with renal failure. It was initially described in French- Canadians but it has been reported in patients with various ethnic origins (Andermann et al., 1986; Badhwar et al., 2004). It is caused by the deficiency of the lysosomal integral membrane protein type 2 (LIMP-2) (Berkovic et al., 2008, Balreira et al., 2008), an ubiquitously expressed transmembrane protein (Fujita et al., 1992) mainly found in the lysosomes and late endosomes (Fukuda, 1991), that mediates the mannose 6-phosphate-independent targeting of GBA to the lysosomes (Reczek et al., 2007). The deficient activity of LIMP-2 leads to the mistarget of the GBA protein, which can not reach the lysosome. In fact, this condition is characterized by pathological levels of GBA activity in fibroblasts, normal or slightly reduced levels in leukocytes, but increased levels in plasma (Balreira et al., 2008; Dardis et al., 2009).

3.1 Clinical aspects

Clinically it presents at the age of 15-25 years with proteinuria evolving to renal failure and/or with neurological symptoms.

The renal pathology is characterized by focal glomerulosclerosis and sometimes with features of glomerular collapse, while the main neurological symptoms are tremor, action myoclonus, seizures and later ataxia without intellectual impairment.

In most ARMF patients reported until recently, the neurological and renal features developed simultaneously or the renal symptoms appeared first. However, mutations in the *SCARB2* gene (encoded LIMP-2 protein) have been demonstrated in a group of five AMRF patients who developed neurological symptoms before the appearance of the renal symptoms. When neurological symptoms develop first, the renal disease begun after 3 to 11 years and always by the age of 30 years (Dibbens et al., 2009, Dardis et al., 2009). These findings stressed the concept that a sorting defect of the GBA enzyme should be always considered in patients with PME of unknown etiology even in the absence of renal impairment (Dibbens et al., 2009, Dardis et al., 2009)

3.2 Molecular aspects

LIMP-2 is a 478 residue type III transmembrane protein (Fujita et al., 1991) comprised of about 400 aminoacid luminal domain, two transmembrane domains and a cytosolic domain of 20 residues. It presents a highly glycosylated loop within the lysosomal lumen (Eskelinen et al., 2003). It has been recently demonstrated that the binding region to the GBA protein is located between aminoacids 145 and 288 within the luminal domain of LIMP-2, which probably mediates the binding in a carbohydrate independent manner (Blanz et al., 2010).

In humans LIMP-2 is encoded by the *SCARB2* gene (NM_005506) located on chromosome 4q13-21 (Reczek et al., 2007). To date, 12 mutations in the *SCARB2* gene have been reported in 11 patients affected by AMRF (Berkovic et al., 2008; Balreira et al., 2008; Dardis et al., 2009; Dibbens et al., 2009). Among these mutations, five are located in intronic regions and may affect the mRNA splicing process, three are non sense, three are small deletions or insertions that cause a shift in the reading frame and one is missense.

The impact of two nonsense mutations, W178X (c.533G.A) and Q288X (c.862C.T), one frameshift mutation, W146SfsX16 (c.435_436insAG), and the missense mutation H363N, on the LIMP-2 trafficking and binding properties was analyzed in vitro. Both nonsense mutations and the frameshift mutation led to the synthesis of truncated proteins that were retained in the endoplasmic reticulum. When the interaction between these LIMP-2 mutants and the GBA was analyzed, it was found that while the Q288X mutant retained its binding capacity, the mutants W146SfsX16 and W178X, lost their ability to bind the GBA almost entirely.

The H363N mutant protein was retained in the ER and its expression level was reduced with respect to wild-type. Unexpectedly, the H363N mutant seems to bind GBA even more efficiently than wild-type LIMP-2 (Blanz et al., 2010).

Although the number of patients affected by AMRF studied to date is quite limited it seems that there is no correlation between the genotype and the clinical presentation of the disease. Studies in large series of patients as well as longer periods of clinical follow up are needed to better understand the molecular bases and the phenotypic expression of this disease.

4. Neuronal ceroid lipofuscinoses

The neuronal ceroid lipofuscinosis (NCLs) are a group of severe progressive neurodegenerative diseases, which present an incidence in Scandinavian countries of 1:12000 live births while the worldwide incidence is 1:100000 (Santavuori, 1988). NCLs are caused by mutations in at least ten human genes, eight of which have been characterized (*CLN1*, *CLN2*, *CLN3*, *CLN5*, *CLN6*, *CLN7*, *CLN8*, *CLN10*) (Jalanko et al., 2009). Although they constitute a genetically heterogeneous group, they share some clinical and histopathological characteristics. All NCLs present a degeneration of nerve cells mainly in the cerebral and cerebellar cortex and the accumulation of autofluorescent ceroid lipopigments both in the neural and peripheral tissues.

NCLs are considered lysosomal diseases since the ceroid lipopigments accumulate within the lysosomes and many proteins that are deficient in the NCLs are localized within the lysosomes (Futerman et al., 2004; Kytölä et al., 2006). However, the accumulated material is not a disease specific substrate and the main storage material is the c subunit of the mitochondrial ATP synthase or the sphingolipid activator proteins A and D (saposin A and D) (Tyynelä et al., 1993; Elleder et al., 1997).

4.1 Clinical aspects

Clinically, they are progressive neurological diseases characterized almost in all cases by a combination of retinopathy, dementia and epilepsy. They have been originally clinically classified according to the age at onset in four main forms: infantile (INCL), late infantile (LINCL), juvenile (JNCL) and adult (ANCL). However, they are currently classified on the bases of the genetic defect (Wisniewski et al., 2001; Haltia, 2003, Mole et al., 2005, Jalanko et al., 2009, Kohlschütter & Schulz, 2009) (Table 1).

The clinical spectrum of NCL1 includes all four forms. Patients with NCL2 can present the late infantile or juvenile phenotype. The late infantile presentation has been reported in NCL5, NCL6, NCL7, NCL 8; the juvenile presentation has been reported in NCL3 and NCL9 and the adult phenotype has been reported in CLN4 (Table 1).

The ultrastructural pattern of accumulated lipopigment is different in different types of NCL: NCL1 and NCL10 present a pattern referred as granular osmiophilic deposits (GROD), while NCL2 and NCL3 are characterized by the presence of curvilinear (CLP) and fingerprint (FPP) profiles, respectively. The other forms, NCL4, NCL 5, NCL 6, NCL 7, and NCL8, show a mixed combination of CLP, FPP and rectilinear profiles (RLP) (Table 1).

Despite the wide molecular heterogeneity, the clinical findings are quite monomorphic. In fact, neuromotor impairment (tremor, ataxia, myoclonus, dysarthria, speech loss), ocular involvement (pigmentary retinal degeneration, optic atrophy, blindness), myoclonic epilepsy, progressive mental deterioration and behavior modifications are common clinical signs shared by all forms of NCLs. The main clinical signs and symptoms are summarized in table 1.

| NCL | Clinical phenotype | Storage pattern | Clinical signs |
|---------------------------|----------------------------|-----------------|---|
| NCL1 | ICLN LINCL/JNCL ANCL | GROD | muscular hypotonia, growth impairment, psychomotor deterioration, ataxia, myoclonic jerks, seizures, retinal blindness, microcephaly. ataxia, myoclonic jerks, seizures, vision deterioration, mental deterioration. ataxia, parkinsonism, verbal impairment, pigmentary retinopathy, tunnel vision, depression, hallucinations, mental deterioration |
| NCL2 | LINCL/JNCL | CLP | spasticity, ataxia, myoclonus, seizures, optic atrophy, rapid mental deterioration, dementia; no vacuolated lymphocytes |
| NCL 3 (Batten disease) | JNCL | FPP | motor deterioration, dysarthria, parkinsonism, myoclonus, seizures, pigmentary retinopathy, optic atrophy with rapid visual loss, early mental deterioration |
| NCL4 | ANCL | | motor deterioration, athetoid movements, myoclonic epilepsy (in type A), tonic-clonic seizures, hearing impairment, mental deterioration, dementia, psychosis, stupors. No visual impairment (generally). |

| NCL | Clinical phenotype | Storage pattern | Clinical signs |
|---------------------------|-------------------------|-----------------|---|
| NCL5 (Finnish variant) | LINCL | CLP, FPP | loss of strength, tremor, language deterioration, ataxia, myoclonic epilepsy, visual failure, blindness, behavioral changes, mental retardation. Rapid disease progression |
| NCL6 | LINCL | RLP, FPP | ataxia, myoclonic jerks, seizures, vision deterioration, mental deterioration |
| NCL7 | LINCL | RLP, FPP | axial rigidity, hesitation in movement initiation, coarse postural tremor, myoclonus, speech impairment, loss of vision, aggressive behaviour, memory impairment, mental deterioration |
| NCL8 | LINCL | CLP | motor impairment, myoclonus, seizures, speech impairment, loss of vision, behavioral changes, mental deterioration <i>Northern epilepsy variant</i> : progressive epilepsy with generalized tonic-clonic seizures, mental deterioration; No visual involvement |
| NCL9 | JNCL | | declining vision, ataxia, seizures, motor and language impairment, cognitive decline |
| NCL10 | LINCL Congenital | GROD | ataxia, loss of motor functions at early school age progressive cognitive decline, loss of speech, pigmentary retinopathy, retinal atrophy, rigidity, tremor, status epilepticus, apnea, microcephaly, precocious death |

INCL: infantile, LINCL: late infantile, JNCL: juvenile, ANCL: adult, GROD: granular osmiophilic deposits; CLP: curvilinear profiles; FPP: fingerprint profiles; RLP: rectilinear profiles.

Table 1. NCLs classification, age at onset, storage pattern and clinical signs.

As other neurodegenerative disorders, which manifest during the first year of life, generalized hypotonia and psychomotor regression are the first clinical signs of classic INCL. They are generally accompanied by head growth impairment (leading to microcephaly), seizure and myoclonic jerks. Behavior and sleep disturbance are frequently reported. Disease progression leads to visual and language deterioration. Death usually occurs within the first decade of life (Williams et al., 2006).

The late-infantile forms present with a similar clinic phenotype, showing progressive neurological deterioration during pre-school age. The classical late-infantile form of NCL2, generally begins during the second year of life, with slow cognitive regression and language deterioration. Epilepsy appears later, becoming rapidly intractable and accompanied with cognitive loss, myoclonic jerks and retinopathy. Patient autonomy is completely lost within the age of 6-8 and death occurs within adolescence period (Zhong et al., 2000; Steinfeld et al., 2002; Kohan et al., 2009).

Two major distinct phenotypes have been described for classical juvenile phenotype of NCL3 (Batten disease), according to the patient's genotype: a. patients carrying the 1-kb deletion in homozygous, (firstly described in Finland and Northern Europe), and b. patients carrying a compound of 1-kb deletion with other mutations (Munroe et al., 1997).

In homozygous patients, visual impairment represent the onset sign, appearing during the first school years, with a pigmentary retinopathy; frequently a first diagnosis of retinitis pigmentosa or cone dystrophy is made. Often the cognitive skills are normal until teenage period, with subsequent deterioration and development of generalized or partial epilepsy, responsive to therapy. Behavior becomes aggressive; mood disturbance and psychotic symptoms are present. With disease progression, motor skills regress as well as speech articulation and parkinsonism and myoclonus become prominent.

In compound heterozygous patients, visual impairment is also the first accused symptom, but cognitive and motor deterioration are less pronounced and slower. Some patient have been reported as completely free from motor and cognitive signs (Lauronen et al. 1999, Jarvela et al. 1999).

Adult phenotypes are described in NCL1 and in the very rare form of NCL4 (Kukfs disease) (Martin, 1991; Ruchoux & Goebel, 1996). In the NCL1 patients, neurological and mental degeneration, depression, retinal and optic atrophy have been described, while the ocular involvement is not present in NCL4.

Absence of visual impairment, has also been reported in NCL8. This form comprises a subgroup of patients (described as Northern Epilepsy Variant) who develop generalized tonic-clonic epilepsy during early school age, followed by progressive mental retardation. With ageing epilepsy severity decreases but cognitive deterioration is maintained. Survival may last to fifth-sixth decade (Herva et al., 2000) .

Finally, a rare congenital form of NCL has been described in NCL10 (Siintola et al., 2006). Clinical course is characterized by microcephaly and severe neurological involvement (rigidity, tremor, status epilepticus) in the first hours of life. Respiratory insufficiency and apnea crisis follow with precocious death (generally within the first weeks of life).

Electrophysiological exams (EEG, ERG, VEP, ABR, SSP) show a wide spectrum of abnormalities in the different phenotypes (Topçu et al., 2004; Weleber et al., 2004; Caraballo et al., 2005; Collins et al., 2006). While brain imaging studies show a variable degree of cerebral and cerebellum atrophy accompanied with abnormalities in the signal pattern of the periventricular white matter and other brain areas (thalami, basal ganglia and putamen) (D'Incerti, 2000; Santavuori et al., 2001; Vanhanen et al., 2004).

4.2 Molecular aspects

NCLs are caused by mutations in at least 10 different recessively inherited human genes. Eight of them have been identified. These genes encode soluble or transmembrane proteins localized to the endoplasmic reticulum (ER) or the endosomal/lysosomal organelles.

The genes involved in the NCLs, their chromosomal localization, the encoded proteins and the storage materials are summarized in table 2.

The human *CLN1* gene has been located to chromosome 1p32 and encodes a palmitoyl protein thioesterase (PPT1), an enzyme that removes palmitate residues from proteins (Vesa et al., 1995). The enzyme consists in a 306 aminoacid polypeptide including a N-terminal signal sequence which is cleaved cotraslationally. Overexpressed PPT1 is directed to late-endosomes/lysosomes via mannose-6-phosphate receptor (M6PR) mediated pathway in non neuron cells (Verkruyse & Hofmann, 1996; Hellsten et al., 1996). It has not been demonstrated that this pathway is utilize to target the PPT1 in neurons. However, PPT1 has been found as part of the human brain mannose 6-phosphoproteasome (Sleet et al., 2005).

Most NCL1 patients accumulate autofluorescent lysosomal deposits, consisting mainly in sphingolipids activation proteins A and D.

In neurons palmitoylation targets proteins for transport to nerve terminals and regulates trafficking at synapses (Huang et al., 2005). It is worth of note that PPT1 has been detected in non lysosomal compartments such as cells soma, varicosities and presynaptic terminals (Lehtovirta et al., 2001; Ahtiainen et al., 2003).

| Gene | Chromosome | Protein | Main storage material |
|--------------|--------------|---|---------------------------|
| <i>CNL1</i> | 1p32 | palmitoyl protein thioesterase (PPT1), lysosomal enzyme | Saposins A and D |
| <i>CNL2</i> | 11p12 | riptideptidil peptidase 1 (TPP1), lysosomal enzyme | Subunit c of ATP synthase |
| <i>CNL3</i> | 16p12 | CNL3, lysosomal transmembrane protein | Subunit c of ATP synthase |
| <i>CNL5</i> | 13q21-q32 | CNL5, lysosomal soluble protein | Subunit c of ATP synthase |
| <i>CNL6</i> | 15q23 | CNL6, transmembrane ER protein | Subunit c of ATP synthase |
| <i>CNL7</i> | 4q28.1-q28.2 | CNL7, lysosomal transmembrane protein | Subunit c of ATP synthase |
| <i>CNL8</i> | 8p23 | CNL8, transmembrane ER protein | Subunit c of ATP synthase |
| <i>CNL10</i> | 11p15.5 | CTSD, cathepsin D, lysosomal enzyme | Saposins A and D |

Table 2. NCL genes, localization, encoded proteins and storage materials (Jalanko & Braulke, 2009)

To date, 48 disease causing mutations distributed throughout the entire *CLN1* gene have been described (<http://www.ucl.ac.uk/ncl>), most of them have been found in individual families. The only exception is represented by the missense mutation (c.364A>T, R122W), which has been found in most Finnish families. Most mutations cause the severe infantile form of NCL (MIM256730). However, mutations causing late infantile, juvenile and adult form have also been reported. No clear correlation between the phenotype and the genotype has been demonstrated (Das et al., 1998; Mitchison et al., 1998; van Diggelen et al., 2001; Williams et al., 2006).

The human *CLN2* gene has been located to chromosome 11p12 and encodes the CLN2 protein tripeptidil peptidase 1 (TPP1) (Sleat et al., 1997), a lysosomal hydrolase that removes tripeptides from the N-terminus of small polypeptides (Golabek et al., 2006) such as the subunit c of mitochondrial ATP synthase. TPP1 consists in a 563 aminoacids, which includes a 19 aminoacid signal peptide and a 176 aminoacid prosegment that is autocatalytically cleaved within the lysosomes (Golabek et al., 2003). It is transported to the lysosomes in a M6PR-dependent manner (Chang et al., 2008).

The storage bodies contain mainly the subunit c of mitochondrial ATP synthase and to a less extent saposin A and D.

To date, 72 disease-causing mutations have been reported (<http://www.ucl.ac.uk/ncl>) leading to the classic late infantile NCL or Jansky-Bielschowsky disease (MIM 204500). Among them, the splice site mutation c.509-1G>C and the nonsense mutation c.622C>T (R208X) are quite frequent (Mole et al., 2005) and they result in very similar phenotypes.

The human *CLN3* has been located to chromosome 16p12 and encodes an integral membrane glycoprotein of 438 aminoacids (International Batten Disease Consortium, 1995). It possesses six transmembrane domains and the glycosilation varies in different tissues (Ezaki et al., 2003; Storch et al., 2007). Overexpressed CLN3 protein is localized in the lysosomes in non neuronal cells while it is detected in the endosomal/lysosomal structures and in the synaptosome in neurons (Kyttala et al., 2004; Luiro et al., 2001). In addition, CLN3 protein has also been detected in the plasma membrane and in lipid rafts (Rakheja et al., 2004; Rusyn et al., 2008). Many different functions have been attributed to CLN3 protein, including lysosomal acidification (Holopainen et al., 2001), lysosomal import of basic aminoacids (Kim et al., 2003), autophagy (Cao et al., 2006), membrane fusion, vesicular transport, cytoskeletal organization (Brooks et al., 2003; Luiro et al., 2006) and apoptosis (Persaud-Sawin & Boustany, 2005; Wang et al., 2011).

The storage deposits contain mainly subunit c of the mitochondrial ATP Synthase (Lake & Hall, 1993). NCL3 is the only NCL typified by vacuolated lymphocytes (Mole et al., 2005)

So far, 49 disease causing mutations have been described in the *CLN3* gene (<http://www.ucl.ac.uk/ncl>), causing the juvenile NCL or Batten disease (MIM 204200). Many patients present the ancestral 1 kb deletion mutation, which results in the deletion of 2 exons. This mutation is predicted to produce an inactive truncated protein. However, it has been recently proposed that this mutated protein may retain some degree of residual function (Kitzmuller et al., 2008).

The human *CLN5* gene has been located to chromosome 13q21-q32 and encodes a 407 aminoacid polypeptide. Sequence analysis shows the presence of four initiation methionines and the production of four different polypeptides with a molecular weight ranging from 39 to 47 kDa has been described (Vesa et al., 2002). The human CLN5 contains mannose-6-phosphate residues on high-mannose type oligosaccharides, suggesting that at least some variants would be soluble. (Sleat et al., 2006). Overexpressed protein is localized to lysosomes, however it has also been detected in axons in neuronal cells (Holmberg et al., 2004). It has been demonstrated that CLN5 interacts with both NCL2 and NCL3 (Vesa et al., 2002).

The main storage component in NCL5 patients is the subunit c of the mitochondrial ATP Synthase (Tyynela et al., 1997).

Mutations in the *CLN5* gene cause the Finnish variant form of late infantile NCL (MIM 256731). Twenty seven mutations have been reported to date (<http://www.ucl.ac.uk/ncl>). A frequent mutation consists in a 2bp deletion in exon 4 (c.1175delAT) and has been found in 94% of Finnish NCL5 alleles.

The human *CLN6* gene has been located to chromosome 15q23 and encodes a 311 amino acid non glycosylated membrane protein. It is localized in the ER and in neuronal cells it is additionally found along neural extension in subdomains of a tubular ER network. It contains a N-terminal cytoplasmic domain, seven putative transmembrane domains and a C-terminal luminal domain (Heine et al., 2004; Mole et al., 2004).

The main storage component in NCL6 cells is the subunit c of the mitochondrial ATP Synthase (Elleder et al., 2006).

Forty six disease mutations have been described to cause a late infantile variant of NCL (MIM601780) (<http://www.ucl.ac.uk/ncl>). The nonsense mutation c.214G>T (p.E72X) has been demonstrated to be highly frequent in patients from Costa Rica probably due to founder effect (Gao et al., 2002; Wheeler et al., 2002).

The human *CLN7* gene has been recently located to chromosome 4q28.1-q28.2 and encodes a transmembrane protein of 518 amino acids. The CLN7 protein belongs to the major facilitator superfamily (MFS), which transport specific substrates. However, its specific substrate has not been identified yet (Kasho et al., 2006). Overexpressed CLN7 is located in lysosomes (Siintola et al., 2007).

Mutations in the CLN7 gene cause a variant late infantile NCL (MIM610951). Twenty-three disease-causing mutations have been described to date (<http://www.ucl.ac.uk/ncl>). Mutations in CLN7 gene have been initially described in Turkish patients (Siintola et al., 2007) and therefore it has been considered the Turkish variant late infantile NCL. However, it has been recently shown that CLN7 defects are geographically widespread (Aiello et al., 2009; Aldahmesh et al., 2009; Stogmann et al., 2009; Kousi et al., 2009). The missense mutation c.881C>A (p.T294K) was found in most patients of Romany origin previously studied by Elleder et al. (Elleder et al., 1997). Haplotype analysis of these patients was consistent with the existence of a common founder effect (Kousi et al., 2009).

The human *CLN8* gene has been located to chromosome 8p23 (Ranta et al., 1999). It encodes a non glycosylated membrane protein of 286 amino acids. The CLN8 protein belongs to the TRAM-Lag1p-CLN8 (TLC) family. Members of this family are involved in the biosynthesis, metabolisms, transport and sensing of lipids (Winter & Ponting, 2002). However, the function of the CLN8 is not known.

The overexpressed protein has been localized in the ER but it seems to shuttle between ER and the ER-Golgi intermediate complex (ERGIC) (Lonka et al., 2000). The storage material in NCL8 patients consists mainly in the subunit c of the mitochondrial ATP Synthase.

Sixteen mutations in the CLN8 gene have been reported to date (<http://www.ucl.ac.uk/ncl>). They have been identified in Finnish families with Northern Epilepsy (Ranta et al., 1999) and in patients of other ethnic origins affected with a more severe variant of NCL (Ranta et al., 2004; Cannelli et al., 2006; Vantaggiato et al., 2009; Kousi et al., 2009; Reinardt et al., 2010; Zelnik et al., 2007; Mole et al., 2005). All but one Finnish patient present the missense mutation c.70C>G (p.R24G) in homozygous, suggesting that this mutation would be associated to a protracted and atypical NCL (Ranta et al., 1999).

The human *CLN10* gene has been located to chromosome 11p15.5 and encodes the major lysosomal aspartic protease cathepsin D (CTSD). The CLN10 protein consists in 412 amino acids and it is synthesized as a proenzyme, which becomes posttranslationally modified by glycosylation and proteolysis leading to intermediates and mature forms (Gieselmann et al., 1985). Depending on the cell type it is trafficking to the lysosomes as a M6PR dependent or independent manner (Dittmer et al., 1999). CTSD is involved in limited proteolysis in the lysosomes and several proteins function as CTSD substrates, including

prosaposin that can be cleaved to saposins A, B, C and D (Gopalakrishnan et al., 2004). Most patients accumulate autofluorescent lysosomal deposits with GRODs. Only four disease-causing mutations have been described to date (<http://www.ucl.ac.uk/ncl>).

5. Sialidosis

Sialidosis (MIM#256550) is a LSD caused by the inherited deficiency of the lysosomal enzyme alpha-N-acetyl-neuraminidase-1 (NEU1), which cleaves the terminal sialic acid residues of several oligosaccharides and polypeptides.

Therefore, the deficiency of NEU1 leads to the accumulation of sialic acid (N-acetylneuraminic acid) covalently linked to oligosaccharides and/or glycoproteins. This aspect distinguishes sialidoses from sialurias, in which the neuraminidase activity is normal or elevated with a storage and excretion of 'free' sialic acid, rather than 'bound' forms.

5.1 Clinical aspects

A systematic classification of Sialidosis has been provided by Lowden and O'Brien in 1979, who divided them in two main clinical variants: Type I, the milder form of the disease, which lacks the physical changes (normosomatic) and Type II, a more severe form with an earlier onset, which can be subdivided in 2 different phenotypes: congenital/neonatal and juvenile forms.

Patients affected with type I sialidosis, (normomorphous or 'cherry-red-spot, myoclonus syndrome'), generally manifest first clinical signs during school-age period or early adulthood. Progressive reduction of visual acuity, red-green and night blindness, bilateral cherry-red spots, punctate corneal opacity and nystagmus, are prominent symptoms. Ocular involvement is accompanied or followed by the appearance of motor impairment, with walking difficulties and myoclonus. Some cases may present seizures. In contrast with type II forms, these patients generally do not present dysmorphisms or bone dysplasia and they have a normal intelligence. Survival is usually long.

Type II congenital sialidosis may manifest in utero with foetal hydrops or foetal ascites while the neonatal form is characterised by diffused edema, hepatosplenomegaly, ascites and Hurler's like clinical signs: facial dysmorphisms, umbilical and inguinal hernias, short trunk with a prominent sternum, kyphosis, and dysostosis multiplex (Froissart et al., 2005). Severe dysmorphism (coarse facies, pectus carinatum, short trunk, exaggerated thoracic kyphosis, and waddling gait) as well as growth delay characterize also infantile phenotypes, cherry-red spot, corneal opacity, hearing loss, progressive neurodegeneration and cognitive deterioration with myoclonic seizures. Skeletal imaging shows dysostosis multiplex with vertebral abnormalities and generalized osteoporosis. Renal involvement, nephrosialidosis, may be present in some patients with proteinuria evolving to nephrotic syndrome (Okada et al., 1983).

Juvenile onset is characterized by less pronounced dysmorphic signs with muscular hypotonia and hypotrophy, ataxia, and myoclonic seizures. Cherry-red spots and corneal opacities are constantly present, as well as hearing loss. Pyramidal syndrome with cerebellar anomalies and peripheral neuropathy have been described. Mental retardation is constant. Survival rarely exceed the second, third decade of life (Winter et al., 1980; Caciotti et al., 2009; Canafoglia et al., 2011).

5.2 Molecular aspects

The human *NEU1* gene (Gen Bank AF040958) has been located to chromosome 6p21.3 within the region of the major histocompatibility complex (Bonten et al., 1996; Pshezhetsky et al., 1997). It contains 6 exons and spans approximately 3.5 kb of genomic DNA (Milner et al., 1997).

The *NEU1* gene encodes a protein of 415 aminoacids including a signal sequence, a central hydrophobic core and a more polar c-terminal domain (Bonten et al., 1996). After the removal of the signal peptide and glycosilation the protein would have a molecular mass of 45 kD. In fact, western blot studies have demonstrated the presence of two major bands of 44 -45 kD which yielded a 40 kD protein after de-glycosilation (Bonten et al., 1996). *NEU1* exists as a multienzyme complex with at least two other proteins, β -galactosidase and the protective protein/cathepsin A (PPCA) (d'Azzo et al., 2001). The association with PPCA is necessary for its enzymatic activity. The association with PPCA stabilizes the active conformation of *NEU1* in lysosomes. Moreover, since *NEU1* is poorly mannose 6-phosphorylated, it depends on PPCA for its correct compartmentalization and catalytic activation in lysosomes (van der Spoel et al., 1998; van der Spoel et al., 2000; Yamamoto et al., 1987).

About 45 different mutations in *NEU1* gene have been reported to date (<http://www.hgmd.org/>). Almost all of them have been found in single families and most of them are missense mutations. Bonten et al. have studied the impact of some missense mutations on *NEU1* protein distribution and catalytic activity and they classified these mutant proteins in 3 groups: 1-catalytically inactive and not lysosomal; 2-catalytically inactive and lysosomal and 3-catalytically active and lysosomal. A good correlation between the residual activity of mutant proteins and the severity of the disease has been found. In fact, patients with the severe type II infantile form presented mutations from group 1 while those with a mild form of type I disease had at least one mutation from group 3. Mutations from group 2 were found mainly in patients with the juvenile form of type II sialidosis with an intermediate phenotype (Bonten et al., 2000).

6. Niemann pick type C (NPC) disease

Niemann Pick type C (NPC) disease (NPC1, MIM 257220; NPC2, MIM 607625) is an autosomal recessive neurodegenerative lysosomal storage disorder, caused by the abnormal function of NPC1 or NPC2 protein. Both proteins are involved in the intracellular trafficking of cholesterol and other lipids. The deficiency of either of them leads to the accumulation of the endocytosed unesterified cholesterol within the lysosomes (Patterson et al., 2001).

Endocytosed low density lipoproteins are delivered to the late endosomes/lysosomes where they are hydrolyzed. In normal cells, free cholesterol is transported to the plasma membrane or to the endoplasmic reticulum through the action of NPC1 and NPC2 proteins. In NPC cells cholesterol accumulate within the lysosomes and the subsequent induction of all low-density lipoprotein cholesterol-mediated homeostatic responses, including cholesterol esterification, is compromised.

In addition NPC-deficient cells also accumulate gangliosides and other GSLs. These findings show that the defect in NPC cells encompasses a global transport error. In fact, while unesterified cholesterol is the main lipid accumulated in peripheral tissues, GM₃, GM₂ and glucosylceramide are the mayor lipids accumulated in brain of NPC patients (Zervas et al., 2001a).

Approximately 95% of NPC patients present mutations in *NPC1* gene (MIM 607623) (Carstea et al., 1993; Vanier et al., 1996), while the other 5% of patients present mutations in *NPC2* gene (MIM 601015) (Naureckiene et al., 2000)

The incidence of NPC disease has been difficult to assess. Estimates of incidences ranging from 0,66 to 0,83 per 100000 were proposed for France, UK and Germany based on the diagnoses made over a period 1988-2002. This incidence is probably underestimated since the wide clinical spectrum of NPC disease was not recognized until the early 90's and no specific laboratory testing was available until the mid 80s. A probably more realistic incidence of 0,96/100000 was recently calculated considering the total amount of cases diagnosed in France from 2000-2009 (including prenatal cases from terminated pregnancies) vs the number of birth during the same period. However, this data is likely to be still underestimated due to the presence of atypical phenotypes that may not be recognized, in particular among adult patients (Patterson, 2001; Vanier and Millat, 2003).

6.1 Clinical aspects

Clinically, NPC disease presents a highly variable phenotype ranging from fetal to adult age. It is classically a neurovisceral condition, characterized by liver and/or spleen enlargement, and neurological or psychiatric manifestations. Systemic disease, when present, always precedes the neurological symptoms. However, it is absent in about 15% of patients and in about half of the adult onset patients (Vanier 2010).

It is important to point out that the course of the systemic signs is independent of that of the course of the neurological symptoms and that disease progression and lifespan are always correlated with the age at onset of the neurological symptoms.

Even if initial manifestations may be systemic, neurological, or psychiatric, the disease has been classified according to the age at onset of neurological symptoms. Although the neurological forms of the disease may be considered as a continuous of phenotypes, the disease has been classically classified in a severe infantile form (onset before 2 y of age), a late infantile form (onset between 3-5 y of age), a juvenile form (onset between 5 and 16 y) and an adult form (onset at age >16 y) (Patterson et al., 2001; Vanier & Millat, 2003).

A perinatal form of NPC has also been described. This form is characterized by the presence of prolonged neonatal cholestatic icterus, appearing within the first weeks of life and often associated with progressive hepatosplenomegaly (Kelly et al., 1993; Vanier et al., 1998; Yerushalmi et al., 2002). In most cases, the icterus spontaneously resolves at 2-4 month of age while the hepatosplenomegaly remains for a variable period. In about 10% of patients the icterus worsens leading to liver failure and death within the first 6 month of age (Vanier et al., 1998). Some patients, in particular those presenting mutations in *NPC2* gene, may present with hepatosplenomegaly in association with a severe respiratory insufficiency, which in most cases is fatal. It is important to note that NPC patients do not present neurological symptoms during the neonatal period. However, an important observation to consider during the genetic counseling is the fact that in many cases patients who die during the perinatal period have siblings affected with the infantile or juvenile neurological form (Vanier & Susuki, 1998; Vanier and Millat, 2003).

Patients affected with early infantile form (3 month to < 2 years) almost invariably present with isolated hepatosplenomegaly during the first month of age followed by delay of development motor milestones, which presents at around 8-9 month of age, and central hypotonia. Subsequent clinical course includes loss of acquired motor skills, spasticity with

pyramidal tract involvement, hearing loss (Wraith et al., 2009). Seizures are uncommon in these patients and they usually die during the first 5 years of age (Vanier 2010).

In late infantile forms (2 to <6 years), hepatosplenomegaly is usually present. Language delay is frequent and these children often present gait problems, frequent falls and clumsiness. Cataplexy is quite frequent and vertical supranuclear gaze palsy (VSGP) is usually present but it may not be recognized at this early stage. Progressive ataxia is followed by dystonia, dysphagia, dysarthria and central hypotonia. Hearing loss has been described (Wraith et al., 2009; Vanier 2010). A significant proportion of patients develop seizures, partial, generalized or both. In general these patients respond to standard antiepileptic treatment but some cases may be refractory to therapy. Severe epilepsy has a bad prognosis and shortens the lifespan of patients. As disease progress patients develop pyramidal signs, spasticity and swallowing problems. In most cases patients die between 7 to 12 years of age (Vanier 2010).

The juvenile form (6 to 15 years) is in many countries the most frequent form of the disease. Moderate splenomegaly or hepatosplenomegaly is frequently present and may have been detected at early time. However, in at least 10% of the cases organomegaly is not present. School failure, learning disability and behavioral problems are the most common signs. VSGP is almost invariably present and may be the first sign. As the disease progress the children present frequent falls, clumsiness and develop progressive ataxia, dysarthria, dystonia, dysphagia. Cataplexy and myoclonus are other common symptoms. About half of the patients with this form develop seizures (partial and/or generalized). At late stage patients develop Pyramidal signs, spasticity and swallowing problems (Wraith et al., 2009; Vanier 2010).

Even if during the last years many patients affected with the adult form (>15 years) of the disease have been reported, this diagnosis has been probably underestimated. Organomegaly or isolated splenomegaly are rare in adult patients and VSGP is usually present. The most common clinical presentation is similar to that of a juvenile form but attenuated. However, it is worth of note that about one third of patients present with psychiatric signs that may appear several years before the onset neurological symptoms. During this period the neurological examination may be normal. Among the psychiatric signs, paranoid delusions and auditory or visual hallucinations are the most commonly described. Other psychiatric signs that may be present in these patients are depressive syndrome, behavioral problems with aggressiveness, social isolation, bipolar disorders, obsessive compulsive disorders. Epilepsy is not very common in this group of patients (15%) and the course is similar to that in the juvenile form (Vanier 2010).

6.2 Molecular aspects

As mentioned above, two disease-causing genes, *NPC1* (NM000271) and *NPC2* (NM006432) have been identified (Steinberg et al., 1994; Vanier et al., 1996; Cartsea et al., 1997). About 95% of human NPC disease is caused by mutations in the *NPC1* gene (Naureckiene et al., 2000). *NPC1* gene, located on chromosome 18q11-q12, encodes a large membrane glycoprotein of 1278 aminoacids containing 13 transmembrane domains and located predominantly in late endosomes (Davies & Ioannou, 2000). It presents a sterol sensing domain (SSD), which shows extensive homology with the sterol sensing domains (SSD) found in SREBP cleavage activating protein (SCAP) and 3-hydroxy-3-methyl-glutaryl coenzyme A (HMG-CoA) reductase, two cholesterol regulated proteins. The SSD domain appears to have important functional

significance (Watari, et al., 1999). Two luminal functional important domains have been identified: a cysteine-rich loop with a ring-finger motif which harbours about 1/3 of the mutations described in patients and a highly conserved N-terminal domain with a leucine zipper motif which has been shown to possess a cholesterol-binding domain (Davies & Ioannou, 2000). In fact, it has recently been demonstrated that a water soluble fragment of NPC1 is able to bind cholesterol and oxysterols (Infante et al., 2008a; Infante et al., 2008b). The mature NPC1 protein has 14 potential glycosylation sites and shows a size of 170 and 190 kDa. The *NPC2* gene is mapped to chromosome 14q24.3 and encodes a small soluble protein present in the lumen of the lysosomes (Naureckiene et al., 2000, Vanier & Millat 2004).

It possesses a hydrophobic pocket that has the property to bind cholesterol (Vanier & Millat, 2004).

Although it is well known that NPC1 and NPC2 participate together in mediating the egress of cholesterol from endo/lysosomes, the precise mechanism by which these proteins function is not fully understood. It has been demonstrated that a water soluble fragment of NPC1 binds cholesterol in an orientation opposite to NPC2. Based on these results, the following working model was proposed to explain the egress of cholesterol derived from receptor mediated endocytosis of LDL from lysosomes: after liberation from LDL, cholesterol is bound by NPC2 which carries it to the lysosomal membrane, where it transfers to the N-terminal domain of the membrane bound NPC1 (Kwon et al., 2009).

The mutational spectrum of *NPC1* gene is very heterogeneous and to date more than 290 mutations have been reported (<http://npc.fzk.de/>; Runz et al., 2008). Among them, the mutant allele I1061T is quite frequent in Western Europe and US (Millat et al. 1999, Sun et al. 2001, Park et al. 2003) where it accounts for 20-25% of the alleles. However, it seems to be much less frequent in Italy and Spain (Fernandez- Valero et al., 2005; Fancello et al., 2009; Macias-Vidal et al., 2010), suggesting that there is a gradient of increasing frequency of the p.I1061T mutation from southeast to northwest Europe.

Two other relatively frequent mutations, p.P1007A and p.G992W, have been reported to be associated to the biochemical "variant phenotype" (see section 9), characterized by a milder cholesterol trafficking impairment. The p.G992W mutation is typical of patients from Nova-Scotia but it has been found in patients from other origins (Millat et al., 2001; Ribeiro et al., 2001; Fernandez- Valero et al., 2005; Fancello et al., 2009).

Phenotype-genotype correlation studies are quite difficult to perform due to the very limited number of patients carrying the same genotype. However, some general consideration can be made. It has been shown that the genotype correlates with the neurological form of the disease and not with the systemic manifestations. While a good correlation has been found between the nonsense or frameshift mutations and the more severe infantile form of the disease, the phenotype is more variable in patients carrying missense mutation. However, the presence of missense mutations in the sterol sensing domain of the protein correlates with the more severe form of the disease.

It has been proposed that in the homoallelic state mutation I1061T is associated with a severe impairment of cholesterol trafficking and correlates with the juvenile neurologic form of the disease, while in the heteroallelic state, the final phenotype depends on the mutation present in the second allele but until recently it had never been found in the severe infantile neurologic form. However, a study performed in a Spanish cohort of 30 patients affected with NPC has demonstrated the presence of the p.I1061T mutation in homozygosis in a patient affected with the severe infantile form (Macias-Vidal, 2010).

So far, only 19 mutations have been reported in the *NPC2* gene. Among them the most frequent mutation is the p.E20X. A good correlation between the severity of the mutation and the clinical course of the disease has been found.

Most reported patients affected with mutations in the *NPC2* gene presented a very severe fatal form of the disease leading to death within the first years of life. Only few patients presenting a slower disease progression and a longer survival have been described so far (Klunemann et al., 2002; Millat et al., 2001; Millat et al., 2005).

7. GM2 gangliosidosis

GM2 gangliosidoses are a group of recessive disorders characterized by accumulation of GM2 ganglioside in neuronal cells due to the deficient activity of human β -hexosaminidases (β -N-acetylhexosaminidase, EC3.2.1.52, Hex), lysosomal hydrolases that cleave the terminal N-acetylhexosamine residues from GM2 gangliosides bound to the GM2 activator protein. Two major isoenzymes exist: Hex A consisting of one α and one β subunit encoded by *HEXA* and *HEXB* genes, respectively, and Hex B consisting of two β subunits. In vivo, the GM2/GM2 activator complex is a substrate only for the Hex A isoenzyme. Mutations in either *HEXA* or *HEXB* genes or in the *GM2A* gene (that encodes for the GM2 activator protein) result in GM2 gangliosidosis.

In particular, mutations in the *HEXA* gene cause Tay Sachs disease (TSD; MIM 272800), characterized by deficiency of Hex A activity, while mutations in the *HEXB* gene lead to Sandhoff disease (SD; MIM 26880), characterized by combined deficiency of Hex A and Hex B activities. On the other hand, mutations in the *GM2A* gene cause GM2 activator deficiency, characterized by normal Hex A and Hex B activities but the inability to form a functional GM2/GM2 activator complex. Only few patients with a defect in the *GM2A* gene have been reported whereas most patients affected by GM2 gangliosidosis present mutations in *HEXA* or *HEXB* genes.

While SD disease is panethnic, the incidence of TSD is about one in 3600 Ashkenazi Jewish, corresponding to a carrier frequency of 1 in 30. Among Sephardic Jews and all non-Jews, the disease incidence has been observed to be about 100 times less common, corresponding to a tenfold lower carrier frequency (between 1/250 and 1/300).

7.1 Clinical aspects

The clinical phenotypes associated with each biochemical variant vary widely from the infantile onset of rapidly progressive neurodegenerative forms, leading to death before the fourth year of life, to the later onset forms, a progressive neurological condition compatible with survival into childhood or long survival (Gravel et al., 2001)

For TSD, three main phenotypes have been identified: classic infantile, juvenile and chronic or adult forms. Signs of the classic infantile TSD are generally evident within the first semester of life. In general noise hypersensitivity with startle response precedes psychomotor retardation, generalized hypotonia, growing of head circumference leading to macrocephalia, amurosis and myoclonic epilepsy. Cherry red spots may be present at fundoscopic examination. The peripheral organs are spared from storage process. Disease progression leads to a very severe neurological degeneration until decerebration state. The juvenile form has a later onset, generally between the age of 2-6 years, presenting with behavior modifications and progressive cognitive impairment. Ataxia become evident and

the disease progresses to decerebrate rigidity. Unlike classic form, blindness is not obligatory. Death occurred between ages 5 and 15 years. Finally, in the adult phenotype the disease may be silent for a prolonged period, becoming evident during school-age. However, the diagnosis may be delayed until adulthood. Clinical presentation is variegated, some patients present with symptoms of atypical Friedreich ataxia, while in others a clinical picture suggestive of Kugelberg-Welander phenotype (progressive leg weakness and fasciculations) was described. A different pattern of motor impairment (including: ataxia, progressive gait disturbance, clumsiness, generalized weakness, mild spasticity, dystonia, dysarthria, tremor involuntary jerks) and cognitive deterioration (loss of memory and comprehension, dementia) has been detected. In some patients mental capacity and behaviour are normal (Neudorfer et al., 2005; Maegawa et al., 2006).

Imaging studies on TSD patients showed different findings in the three different forms, an involvement of basal ganglia and thalamus with cortical atrophy has been detected in classic infantile form, while both juvenile and adult phenotypes do not present basal ganglia abnormalities but show a cortical and cerebellar atrophy, the later characteristic of adult form (Grosso et al., 2003; Inglese et al., 2005; Aydin et al., 2005; Maegawa et al. 2006).

Neurophysiological studies showed a variable pattern of EEG abnormalities with an early progressive loss of the VEP in infantile form. Saccadic abnormalities and impairment of smooth pursuit have also been observed at the evaluation of eye movements in some patients (Rapin 1986; Rucker et al. 2004).

In SD clinical findings are indistinguishable from those of TSD. In infantile onset, startle reaction, psychomotor deterioration, early blindness, macrocephaly, cherry red spots are all present. The course of the disease is rapidly fatal, with death within the third year of life. In late-onset forms, cognitive and mental involvement (school difficulties, emotional lability, intermittent psychosis, confusional state) as well as neurological deterioration (muscle weakness, muscle atrophy, fasciculations, supranuclear gaze palsy, muscular atrophy, hyperreflexia, myoclonic jerks, seizures) have been described. Imaging and neurophysiological studies are similar to TSD (Yüksel et al., 1999; Alkan et al., 2003; Hendriksz et al., 2004; Jain et al., 2010)

7.2 Molecular aspects

The human *HEXA* gene (MIM# 606869) is located on chromosome 15q23-q24 and contains 14 exons. More than 100 mutations have been identified to cause TSD disease, including single base substitutions, small deletions, small duplications/insertions, partial gene deletions, splicing alterations and complex gene rearrangements (<http://www.hexdb.mcgill.ca/hexadb>; <http://www.hgmd.org/>; Stenson et al., 2003). Most of these alterations are “private” mutations and have been detected in single or very few families. Others are present in small isolated populations and only a few have been frequently found in diverse populations. In the Ashkenazi Jewish population three distinct *HEXA* mutations are responsible for 98% of all mutant alleles: the most common four-bases duplication c.1274_1277dupTATC and the splicing mutation c.1421+1G>C (IVS12+1G>C) account for 81% and 15% of alleles, respectively; the alteration in exon 7 c.805G>A (p.G269S), associated with the late onset form of the disease, has been found in approximately 2% of alleles (Kaback et al., 1993). Among the non-Jewish populations the mutation pattern is completely different. Only 30% of the alleles are due to the duplication c.1274_1277dupTATC, none present the IVS12+1G>C and about 5% carry the G269S

mutation (Kaback et al., 1993). By contrast, the abnormal splicing mutation c.1073+1G>A (IVS9+1G>A), absent among the Jewish population, is found in about 15% of the non-Jewish carriers (Akerman et al., 1992). There are mutations in the *HEXA* gene causing the B1 Variant, associated with the late onset form of TSD. This biochemical phenotype is characterized by a Hex A isoenzyme catalytically inactive against the physiological substrate, GM2 ganglioside, but active towards commonly used synthetic substrate (4-methylumbelliferyl β -N-acetylglucosaminide) (Tutor, 2004). Concerning the *HEXA* mutations associated with the B1 Variant, the most common is the c.533G>A (p.R178H) that was first found predominantly in Portuguese patients (dos Santos et al., 1991; Gravel et al., 2001) and which has been subsequently detected in individuals with different European backgrounds (Montalvo et al., 2006).

Human *HEXB* gene has been located to chromosome 5q13 (MIM 26880) and contains 14 exons distributed over about 40 kb of DNA. To date, about 40 different mutations have been identified to cause SD, most of the have been identified in individual families (<http://www.hexdb.mcgill.ca/hexadb>; <http://www.hgmd.org/>). However, a common mutation found in patients with different ethnic backgrounds is a deletion at the 5' end of the gene that removes 16 kb of DNA including the *HEXB* promoter, exons 1–5, and part of intron, which account for about 27% of SD alleles (Neote et al., 1988; Bolhuis & Bikker, 1992). This mutation seems to be quite unfrequent in Italian SD patients. Among this population the most frequent mutation is the c.850C>T (p.R284X) present in 27% of the affected alleles. The high frequency of this mutation is probably due to a founder effect (Zampieri et al., 2009).

Although the number of SD patients characterized to date is quite small to perform an analysis of phenotype/genotype correlation, it is of note that missense mutations p.P504S, p.R505Q and p.R533H, seem to be associated to the late onset form of the disease (Maegawa et al., 2006). In addition, the missense mutation p. D459A has been recently discovered in six patients with a rare juvenile SD variant (Wang et al., 2008).

8. Differential diagnosis

The diagnosis of the specific LSD present in patients affected with PME may be challenging. However, the correct diagnosis is crucial in order to implement the best available therapeutic options and to provide an accurate genetic counselling.

Although each LSD presents with specific signs and symptoms, some general features should prompt the physician to suspect the presence of a LSD in a patient with PME:

1- a familiar history suggestive of a genetic disease, 2- association with other signs of neurological impairment, 3- the presence of visceral involvement.

The visceral and neurologic signs most frequently associated to PME in LSD are shown in table 3. At physical examination, dysmorphism is a constant feature of sialidosis type II. Visceral storage represents a major sign of GD and sialidosis, while is generally less evident in NPC, where protracted jaundice is a highly suggestive sign that must be searched during patient anamnesis. Macrocephaly is a diagnostic sign in the infantile TSD, where abnormal growing of head circumference becomes evident with disease progression. With disease progression, ataxic motor impairment is generally detected in all of them, with dystonic movements evident in NPC, NCL and GM2 gangliosidosis, while dysarthria is detectable in AMRF, NPC and GM2 gangliosidosis. Parkinsonian syndrome may be present in adult patients with NCL. Involvement of ocular system is widely described in many LSD, both at

functional and tissue storage levels. Supranuclear gaze palsy is pathognomonic in NPC, but is also present in GD3 and AMFR, while blindness affects particularly infantile TSD and NCL (infantile NCL1 and late-infantile NCL Finnish variant, CLN5); green-red and nocturnal visual loss may be present in type 1 sialidosis. Signs of retinal storage are detectable in form of cherry-red spot (in Sialidosis and GM2), pigmentary degeneration (diagnostic sign in NCL) and optic atrophy (NCL and GM2 gangliosidosis). Degeneration of mental capacities with different grade of severity are constantly present in all these pathologies, while skeleton is severely involved by in sialidosis and usually mildly affected in GD3. Finally, renal failure characterizes the late phase of AMFR, but in form of nephritic syndrome may affect sialidosis type 2.

| | GD3 | AMFR | NPC | NCL | Sialidosi | GM2 gangliosidosis |
|----------------------|-----|------|-----|-----|-----------|--------------------|
| dysmorphisms | | - | - | - | + | - |
| visceral storage | + | - | + | - | + | - |
| protracted jaundice | - | - | + | - | - | - |
| macrocephaly | - | - | - | - | - | + |
| ataxia | + | + | + | + | + | + |
| dystonia | - | - | + | + | - | + |
| dysarthria | - | + | + | - | - | + |
| parkinsonism | - | - | - | + | - | - |
| gaze palsy | + | + | + | - | - | - |
| blindness | - | - | - | + | + | + |
| cherry red spot | - | - | - | - | + | + |
| retinal degeneration | - | - | - | + | - | - |
| optic atrophy | - | - | - | + | - | + |
| mental deterioration | + | + | + | + | + | + |
| skeletal involvement | + | - | - | - | + | - |
| renal involvement | - | + | - | - | + | - |

Table 3. visceral and neurologic signs most frequently associated to PME in LSD

8.1 Laboratory diagnosis

Routine laboratory tests result usually normal in patients with LSDs, with just few exceptions summarized in table 4.

On the other hand, in patients with PME in whom the presence of a LSD is suspected, some relative simple tests may be performed (Table 4). The assessment of chitotriosidase activity in serum, a marker of macrophage activation, is substantially elevated in patients affected with GD and may be slightly elevated in patients with NPC disease. In addition, a recent report described the presence of high levels of chitotriosidase activity in 2 patients affected

with sialidosis type II (Caciotti et al., 2009). However, about 30% of individual from various genetic origins carry a chitotriosidase gene with a 24 bp duplication that prevents the production of the enzyme. Therefore, about 6% of the population is homozygous for this mutant allele and completely lack chitotriosidase activity.

Patients affected with sialidosis excrete increased amount of several oligosaccharides and sialylglycopeptides derived from glycoproteins. Since the metabolic defect in these patients results in the inability to cleave sialic acid, the accumulated oligosaccharides are rich in sialic acid. Thus, a first screening test that may be performed when a sialidosis is suspected is the analysis of oligosaccharides in urine by thin layer chromatography (TLC). Staining of oligosaccharides resolved by TLC reveals a abnormal pattern in affected patients. However, abnormal patters of urine oligosaccharides are also found in patients affected with other disorders of glycoprotein degradation. In addition it is also possible to analyze the presence of sialic acid containing oligosaccharides by staining the TLC plates with resorcinol (Holmes & O'Brien, 1979).

| LSD | Non specific laboratory findings |
|---------------------|--|
| Gaucher | Anemia, thrombocytopenia, Minor elevation of liver enzymes Elevation of acid phosphatase, angiotensin converting enzyme (ACE) and ferritin Elevation serum chitotriosidase activity |
| AMRF | Proteinuria |
| Niemann Pick type C | Reduced plasma levels of HDL-cholesterol Moderate elevation of serum chitotriosidase activity |
| Sialidosis | Elevation of serum chitotriosidase. Abnormal pattern of urin oligosaccharides |

Table 4. Non specific laboratory findings in patients affected with LSDs that may present with PME.

The presence of glycolipid-laden macrophages in various tissues is a hallmark of GD. In particular the presence of these “Gaucher cells” in bone marrow aspirates provide a strong support for this diagnosis. However, these cells have to be distinguished from those present in other disorders that exhibit pathological macrophages as a hallmark, such as the sea blue histiocyte syndrome or NPC disease. In addition, foam cells may also be present in bone marrow samples of patients affected with sialidosis. Although the examination of bone marrow aspiration may be useful for the diagnosis of GD, NPC disease and sialidosis, it should not be necessarily the initial diagnostic test considering the invasiveness of the procedure.

8.1.1 Specific test

A schematic approach to the laboratory diagnosis of the specific LSDs discussed in this chapter is represented in figure 1.

The suspect of **GD** can be confirmed by the assessment of GBA activity in peripheral blood leukocytes or cultured fibroblasts. A residual activity below 15 % of the mean normal activity is diagnostic.

However, it is important to keep in mind that **AMRF** is caused by a mistargeting of GBA enzyme due to a defect in its receptor LIMP-2 and therefore patients affected by this disorder

also show low levels of GBA activity in fibroblasts but slightly reduced or normal in peripheral blood leukocytes. AMRF should always be considered in patients with reduced intracellular GBA activity in the absence of other markers of Gaucher disease, such as elevated serum chitotriosidase activity or the presence of "Gaucher" cells in bone marrow.

The determination of GBA activity in serum should be performed in order to provide a differential diagnosis since it is elevated only in patients affected with AMRF (Dardis et al., 2009).

In both cases the molecular analysis of *GBA* or *SCARB-2* gene should be carried out in order to confirm the diagnosis and to provide a genetic counseling.

The diagnostic approach of **NCL** depends on the type of defect that is suspected. As shown in figure 1, the diagnosis of **NCL 1, NCL2 and NCL10** can be achieved by the assessment of PPT1, TPP1 or Cathepsin D activity in leukocytes or cultured fibroblasts. If **NCL3** is suspected, the diagnosis can be confirmed by the presence of typical vacuoles in the cytoplasm of the patient lymphocytes, which are detectable on a regular blood smear (Kohlschütter & Schulz, 2009).

In the case of **NCL5, NCL6, NCL7 and NCL8** it is advisable to investigate the presence of storage material by electron microscopic examination of skin biopsy material or isolated lymphocytes as a first approach and then proceed to the molecular genetic studies. The definitive diagnosis in all cases is reached by the molecular analysis of the corresponding genes (Kohlschütter & Schulz, 2009).

The definitive diagnosis of **sialidosis** is achieved by measuring the NEU1 activity in fresh samples of blood leukocytes or cultured fibroblasts. Special care should be taken to ensure that the tissue to be examined has not been frozen or exposed to prolonged sonication since the neuraminidase is quite unstable (Den Tandt & Brossemer, 1984). The residual enzymatic activity is extremely low or absent in patients affected with sialidosis independently of the severity of the clinical phenotype. On the contrary, a good correlation between the genotype and the phenotype has been found, therefore the molecular analysis of the *NEU1* may provide useful information about disease severity and progression, which is particularly relevant to provide a better genetic counseling.

It is important to keep in mind that also the Galactosialidosis, a LSD associated with combined deficiency of NEU1 and β -galactosidase due to the defect of the protective protein /cathepsin A (PPCA), results in reduced levels of NEU1 activity. However, in this case the levels of NEU1 are not as low as in sialidosis and they are associated with low levels of β -galactosidase activity.

The diagnosis of NPC disease may be quite challenging. It is time consuming and should be performed by specialized centers with the required experience.

The biochemical diagnosis is based on the demonstration of the impaired intracellular cholesterol transport and homeostasis in fibroblasts in culture. The filipin test is considered the more specific and sensitive assay. Cells are cultured in the presence of LDL enriched medium and then fixed and stained with filipin, a molecule that has a high affinity for unesterified cholesterol (Blanchette-Mackie et al., 1988). In patients with NPC disease, fluorescence microscopic examination of stained cells shows in most of them, the presence of strong fluorescent perinuclear vesicles evidencing the intralysosomal accumulation of cholesterol. The majority of NPC patients present this "classical" biochemical pattern. However, about 20% of NPC patients present a milder level of unesterified cholesterol storage, presenting the so called "variant" biochemical phenotype. The diagnosis in these

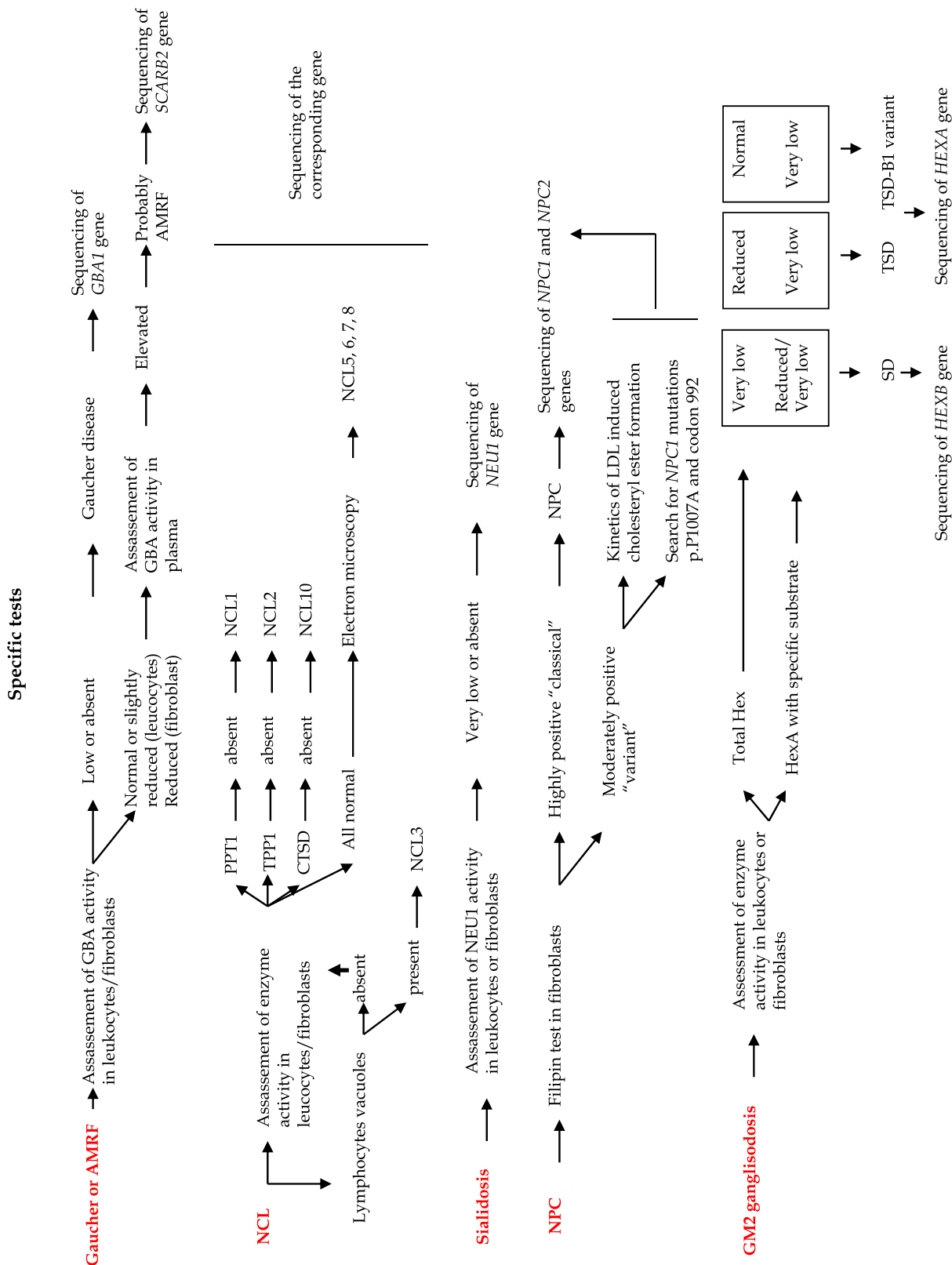


Fig. 1. Schematic representation of the laboratory diagnostic strategy in suspected cases of PME due to LSD

patients may be difficult. Measurement of the LDL-induced rate of cholesterol esterification may be used as a secondary test. However, while very low levels rates of esterification are detected in cell lines with a "classical" biochemical phenotype only a mild or non-significant impairment is detected in those with a "variant" phenotype. Therefore, in these cases mutational analysis of *NPC1* and *NPC2* are necessary in order to provide a definitive diagnosis. Since some mutations of *NPC1* gene have been associated to the variant biochemical phenotype (see 6.2), it is advisable to screen the presence of these mutations in patients presenting a variant phenotype.

Finally, the molecular analysis should be performed in all newly diagnosed patients since molecular genetic studies are the highly preferred strategy for prenatal diagnosis, and the only reliable one for identification of carriers in blood relatives (Vanier et al., 2010).

The suspect of **GM2 gangliosidosis** can be confirmed by the measurement of β -hexosaminidases activities in blood leukocytes or cultured fibroblasts. From the biochemical point of view, the differential diagnosis between SD and TSD, the most common causes of GM2 gangliosidosis, can be performed by the assessment of total Hex activity, the HEX activity after heat inactivation and the specific assay of the HexA isoenzyme in leukocytes or fibroblasts. The synthetic substrate usually used is the 4-methylumbelliferyl N- acetyl β -glucosaminide which can be digested by both HexA (α/β heterodimero) and HexB (β/β homodimero) isoenzymes and it is used to determine the total Hex activity. Since the HexA is thermolabile, it can be inactivated by heating the sample at 50°. The activity against the 4-methylumbelliferyl N- acetyl β -glucosaminide after heat inactivation is represented only by HexB. This value is used to determine the % of HexA and HexB activity. The specific activity of Hex A isoenzyme can be measured using the synthetic substrate, 4-methylumbelliferyl N- acetyl β -glucosamine 6-sulfate (MUGS) (Bayleran, et al., 1984). Sandhoff disease is characterized by the impairment of both HexA and HexB activities and therefore total Hex activity is very low. A residual Hex A activity may be detected in these patients due the presence of HexS, consisting in two α subunits, which is not deficient in SD and is also active towards the synthetic substrate.

Tay Sachs disease is confirmed by the presence of reduced levels of total Hex and very low levels of HexA. It is important to keep in mind that the B1 variant of Tay Sachs is characterized by the presence of an Hex A isoenzyme catalytically inactive against the physiological substrate, GM2 ganglioside, but active towards commonly used synthetic substrate 4-methylumbelliferyl -N-acetyl β -glucosaminide (Tutor, 2004). Biochemical identification of these patients requires always the use of the specific substrate MUGS. (Bayleran et al., 1984).

In the case of normal Hex activities a deficiency of the GM2 activator protein should be suspected. In this case, the definitive diagnosis is achieved by the molecular analysis of the *GM2A* gene.

In patients with a biochemical diagnosis of SD and TSD it is advisable to perform the molecular analysis of *HEXA* or *HEXB* genes, respectively, in order to confirm the diagnosis and to provide genetic counseling. In addition in patients with a biochemical pattern compatible with a diagnosis of TSD disease it is important to exclude the presence of a pseudodeficiency due to specific mutations (p.R247W and p.R249W) in the *HEXA* gene. These protein variants are inactive towards the synthetic substrates but active towards the natural substrate, GM2 ganglioside (Triggs-Raine et al., 1992; Cao et al., 1993).

9. Therapeutic options

Twenty years ago the availability of enzyme replacement therapy (ERT) for GD opened a new era for the treatment of LSDs, giving to the patients a concrete hope for recovering (Brady, 2006; Connock et al. 2006). However, clinical history of GD demonstrated the limited effect of ERT on neurological phenotypes. The difficulty to cross the blood-brain barrier for macromolecule such glycoproteins prevent the neuronal access to the intravenous infused enzyme. Despite the good efficacy in correcting the visceral and hematological alterations of the disease also in neurological phenotypes, only a very limited number of patients seem to benefit from ERT, showing an improvement of EEG pattern and a stabilization of neurological conditions. Quite all of them carried the L444P mutation in homozygosis. On the contrary very few are GD3 patients presenting with myoclonic epilepsy that carry these mutation in homozygosis or heterozygosis with other rare mutations. Therefore, myoclonic epilepsy represents a unfavorable prognostic factor in GD3 (Altarescu et al., 2001). Despite the negative results obtained by Schiffmann et al. (2008), Capablo et al. (2007) showed an improvement of neurologic conditions and EEG pattern as well as a decrease of the epileptic crisis in patients who presented with myoclonic seizures and the L444P/E326K+N188S phenotype, after 12 month treatment with combined ERT and substrate reduction therapy (SRT). Recently, Accardo et al. (2010), demonstrated the recovery of saccades in two GD3 sisters in course of SRT. The availability of small molecules capable to cross the blood-brain barrier might widening therapeutic prospective in neuronopathic GD.

Glycosphingolipids reduction therapy may represent a strategy also for other glycosphingolipidosis, like NPC and GM2 gangliosidosis (Platt et al., 2005; Platt & Lachmann, 2009).

Different clinical experiences have been reported in literature concerning SRT in NPC patients. The results of clinical trials performed both in pediatric and adult patients showed a significant improvement of swallowing and saccades, as well as an overall stabilization of neurological conditions (Patterson et al. 2007; Galanaud et al. 2009). Substrate reduction therapy has also been used to reduce glycosphingolipids synthesis in GM2 gangliosidosis patients (Bembi et al., 2006; Shapiro et al., 2009), both in infantile and late-onset forms, without any evidence of measurable benefits.

Very recently a Clarke JT et al. (2011) have demonstrated an in vivo enhancement of Hex A activity in a group of late-onset GM2 patients (TSD and Sandhoff) treated with pyrimethamine for a period of 16 weeks. The study was aimed to analyze drug safety and no data on clinical results are available at present.

Apart from symptomatic and supportive therapy, no specific treatments are at present available for NCL and sialidosis, even if preclinical therapeutic programs are ongoing, based on enzyme and gene therapy, stem cell replacement and immunotherapy (Wang et al, 2005; Hobert & Dawson, 2006).

10. Conclusions

LSDs are the main cause of the inherited form of PME. However, they are poorly known as a cause of PME and the differential diagnosis might be challenging. An accurate diagnosis is crucial to provide the best therapeutic approach and an appropriate genetic counselling.

Therefore, in this chapter we have discussed the main clinical and molecular findings in patients with PME affected by LSDs.

It is important to highlight that even if each LSD present with specific signs, some general features should prompt the physician to suspect the presence of a LSD in a patient with PME, such as 1- a familiar history suggestive of a genetic disease, 2- association with other signs of neurological impairment, 3- the presence of visceral involvement.

In the suspect of a LSDs as a cause of PME, specific tests should be performed in specialized laboratories in order to provide an accurate biochemical diagnosis. In addition, the identification of the genes involved in most of these disorders offers the possibility to perform a molecular diagnosis. This type of analysis is quite laborious and time consuming since in most cases the complete sequencing of the affected gene is needed. However, molecular genetic studies are the only reliable tests for the identification of carriers in blood relatives and it is the highly preferred strategy for prenatal diagnosis.

Over the last years a lot of progresses in the understanding of the clinical features and the genetic bases of LSDs have been done. However, very little is known about their pathogenetic mechanisms. In fact, the elucidation of the molecular pathways leading to the neuronal degeneration and the development of therapeutic strategies for these diseases remain the main challenge for the future.

11. References

- Accardo A., Pensiero S., Ciana G., Parentin F., Bembi B. (2010) Eye movement impairment recovery in a Gaucher patient treated with miglustat. *Neurology Research International*, Epub 2010 Sep 26, ISSN 2090-1852.
- Ahtiainen L., Van Diggelen OP., Jalanko A. & Kopra O. (2003) Palmitoyl protein thioesterase 1 is targeted to the axons in neurons. *Journal of Comparative Neurology*, Vol. 455, No. 3 (Jan), pp. 368-77, ISSN 0021-9967.
- Aiello C., Terracciano A., Simonati A., Discepoli G., Cannelli N., Claps D., Crow YJ., Bianchi M., Kitzmuller C., Longo D., Tavoni A., Franzoni E., Tessa A., Veneselli E, Boldrini R., Filocamo M., Williams RE., Bertini ES., Biancheri R., Carrozzo R., Mole SE. & Santorelli FM. (2009) Mutations in MFSD8/CLN7 are a frequent cause of variant-late infantile neuronal ceroid lipofuscinosis. *Human Mutation*, Vol. 30, No. 3 (Mar), pp. E530-40, ISSN 1059-7794.
- Akerman BR., Zielenski J., Triggs-Raine BL., Prencce EM., Natowicz MR., Lim-Steele JS., Kaback MM., Mules EH., Thomas GH., Clarke JT., et al. (1992) A mutation common in non-Jewish Tay-Sachs disease: frequency and RNA studies. *Human Mutation*, Vol. 1, No. 4, pp. 303-9, ISSN 1059-7794.
- Aldahmesh MA., Al-Hassnan ZN., Aldosari M. & Alkuraya FS. (2009) Neuronal ceroid lipofuscinosis caused by MFSD8 mutations: a common theme emerging. *Neurogenetics*, Vol. 10, No. 4 (Oct), pp. 307-11, ISSN 0167-7063.
- Alkan A., Kutlu R., Yakinici C., Sigirci A., Aslan M. & Sarac K. (2003) Infantile Sandhoff's disease: multivoxel magnetic resonance spectroscopy findings. *Child Neurology*, Vol. 18, No. 6 (Jun), pp. 425-8, ISSN 0887-8994.
- Altarescu G., Hill S., Wiggs E., Jeffries N., Kreps C., Parker CC., Brady RO., Barton NW. & Schiffmann R. (2001) The efficacy of enzyme replacement therapy in patients with

- chronic neuronopathic Gaucher's disease. *Journal of Pediatrics*, Vol. 138, No. 4 (Apr), pp. 539-47, ISSN 0022-3476.
- Andermann E., Andermann F., Carpenter S., Wolfe LS., Nelson R., Patry G., & Boileau J. (1986) Action myoclonus-renal failure syndrome: a previously unrecognized neurological disorder unmasked by advances in nephrology. *Advances in Neurology*, Vol. 43, pp. 87-103, ISSN 0091-3952.
- Applegarth DA., Toone JR, & Lowry RB. (2000) Incidence of inborn errors of metabolism in British Columbia, 1969-1996. *Pediatrics*, Vol. 105, No. 1 (Jan), pp. e10, ISSN 1098-4275.
- Aydin K., Bakir B., Tatli B., Terzibasoglu E. & Ozmen M. (2005) Proton MR spectroscopy in three children with Tay-Sachs disease. *Pediatric Radiology*, Vol. 35, No. 11 (Nov), pp. 1081-5, ISSN 0301-0449.
- Badhwar A., Berkovic SF., Dowling JP., Gonzales M., Narayanan S., Brodtmann A., Berzen L., Caviness J., Trenkwalder C., Winkelmann J., Rivest J., Lambert M., Hernandez-Cossio O., Carpenter S., Andermann F., & Andermann E. (2004) Action myoclonus-renal failure syndrome: characterization of a unique cerebro-renal disorder. *Brain*, Vol 127, No. 10 (Oct), pp. 2173-82, ISSN 0006-8950.
- Balreira A., Gaspar P., Caiola D., Chaves J., Beirão I., Lima JL., Azevedo JE., & Miranda MC. (2008) A nonsense mutation in the LIMP-2 gene associated with progressive myoclonic epilepsy and nephrotic syndrome. *Human Molecular Genetics*, Vol. 17, No. 14 (Jul), pp.2238-43, ISSN 0964-6906.
- Bayleran J., Hechtman P. & Saray W. (1984) Synthesis of 4-methylumbelliferyl-beta-D-N-acetylglucosamine-6-sulfate and its use in classification of GM2 gangliosidosis genotypes. *Clinica Chimica Acta*, Vol. 143, No. 2 (Nov), pp. 73-89, ISSN 0009-9120.
- Bembi B., Marchetti F., Guerci V., Ciana G., Addobbati R., Grasso D., Barone R., Cariati R., Fernandez-Guillen L., Butters T. & Pittis MG. (2006) Substrate reduction therapy in the infantile form of Tay-Sachs disease. *Neurology*, Vol. 66, No. 2 (Jan), pp. 278-80, ISSN 0028-3878.
- Berkovic SF, Dibbens LM, Oshlack A, Silver JD, Katerelos M, Vears DF, Lüllmann-Rauch R, Blanz J, Zhang KW, Stankovich J, Kalnins RM, Dowling JP, Andermann E, Andermann F, Faldini E, D'Hooge R, Vadlamudi L, Macdonell RA, Hodgson BL, Bayly MA, Savige J, Mulley JC, Smyth GK, Power DA, Saftig P, Bahlo M. (2008) Array-based gene discovery with three unrelated subjects shows SCARB2/LIMP-2 deficiency causes myoclonus epilepsy and glomerulosclerosis. *The American Journal of Human Genetics*, Vol.82, No. 3 (Mar), pp. 673-84, ISSN 0002-9297.
- Beutler E. & Grabowski G.A. (2001) Gaucher disease. The Metabolic and Molecular Basis of Inherited Disease Vol. III, 8th ed. Scriver CR., Beaudet AL., Sly WS., Valle D., editors, 3635-68, NY, McGraw-Hill, New York.
- Beutler E., & Gelbart T. (1993) Gaucher disease mutations in non-Jewish patients. *British Journal of Haematology*, Vol. 85, No. 2 (Oct), pp.401-5, , ISSN 0007-1048.
- Beutler E., Nguyen NJ., Henneberger MW., Smolec JM., McPherson RA., West C., & Gelbart T. (1993) Gaucher disease: gene frequencies in the Ashkenazi Jewish population. *The American Journal of Human Genetics*, Vol. 52, No. 1 (Jan), pp. 85-8, ISSN 0002-9297.
- Blanchette-Mackie EJ., Dwyer NK., Amende LM., Kruth HS., Butler JD., Sokol J., Comly ME., Vanier MT., August JT., Brady RO. & Penchev P. (1988) Type-C Niemann-Pick disease: low density lipoprotein uptake is associated with premature cholesterol

- accumulation in the Golgi complex and excessive cholesterol storage in lysosomes. *Proceedings of the National Academy of Science U S A*, Vol. 85, No. 21 (Nov), pp. 8022-6, ISSN 0073-6600.
- Blanz J., Groth J., Zachos C., Wehling C., Saftig P., & Schwake M. (2010) Disease-causing mutations within the lysosomal integral membrane protein type 2 (LIMP-2) reveal the nature of binding to its ligand beta-glucocerebrosidase. *Human Molecular Genetics*, Vol. 19, No. 4 (Feb), pp. 563-72, ISSN 0964-6906.
- Bolhuis PA. & Bikker H. (1992) Deletion of the 5'-region in one or two alleles of HEXB in 15 out of 30 patients with Sandhoff disease. *Human Genetics*, Vol. 90, No. 3 (Nov), pp. 328-9, ISSN 0340-6717.
- Bonten E., van der Spoel A., Fornerod M., Grosveld G., & d'Azzo A. (1996) Characterization of human lysosomal neuraminidase defines the molecular basis of the metabolic storage disorder sialidosis. *Genes & Development*, Vol. 10, No. 24 (Dec), pp. 3156-69, ISSN 0890-9369.
- Bonten EJ., Arts WF., Beck M., Covanis A., Donati MA., Parini R., Zammarchi E., & d'Azzo A. (2000) Novel mutations in lysosomal neuraminidase identify functional domains and determine clinical severity in sialidosis. *Human Molecular Genetics*, Vol. 9, No. 18 (Nov), pp. 2715-25, ISSN 0964-6906.
- Brady RO. (2006) Enzyme replacement for lysosomal diseases. *Annual Review of Medicine*, Vol.57, pp. 283-96, ISSN 0066-4219.
- Brooks AI., Chattopadhyay S., Mitchison HM., Nussbaum RL. & Pearce DA. (2003) Functional categorization of gene expression changes in the cerebellum of a Cln3-knockout mouse model for Batten disease. *Molecular Genetics and Metabolism*, Vol. 78, No. 1 (Jan), pp. 17-30, ISSN 1096- 7192.
- Caciotti A., Di Rocco M., Filocamo M., Grossi S., Traverso F., d'Azzo A., Cavicchi C., Messeri A., Guerrini R., Zammarchi E., Donati MA. & Morrone A. (2009) Type II sialidosis: review of the clinical spectrum and identification of a new splicing defect with chitotriosidase assessment in two patients. *Journal of Neurology*, Vol. 256, No. 11 (Nov), pp. 1911-5, ISSN 0340-5354.
- Cannelli N., Cassandrini D., Bertini E., Striano P., Fusco L., Gaggero R., Specchio N., Biancheri R., Vigevano F., Bruno C., Simonati A., Zara F. & Santorelli FM. (2006) Novel mutations in CLN8 in Italian variant late infantile neuronal ceroid lipofuscinosis: Another genetic hit in the Mediterranean. *Neurogenetics*, Vol. 7, No. 2 (May), pp. 111-7, ISSN 0167-7063.
- Cao Y., Espinola JA., Fossale E., Massey AC., Cuervo AM., MacDonald ME & Cotman SL. (2006) Autophagy is disrupted in a knock-in mouse model of juvenile neuronal ceroid lipofuscinosis. *Journal of Biological Chemistry*, Vol. 281, No. 29 (Jul), pp. 20483-93, ISSN 0021-9258.
- Cao Z., Natowicz MR., Kaback MM., Lim-Steele JS., Prenc EM., Brown D., Chabot T. & Triggs-Raine BL. (1993) A second mutation associated with apparent beta-hexosaminidase A pseudodeficiency: identification and frequency estimation. *The American Journal of Human Genetics*, Vol. 53, No. 6 (Dec), pp. 1198-205, ISSN 0002-9297.
- Capablo JL., Franco R., de Cabezón AS., Alfonso P., Pocovi M. & Giraldo P. (2007) Neurologic improvement in a type 3 Gaucher disease patient treated with

- imiglucerase/miglustat combination. *Epilepsia*, Vol. 48, No. 7 (Jul), pp. 1406-8, ISSN 0013-9580.
- Caraballo R., Sologuestua A., Ruggieri VL., Monges S., Cersósimo R., Taratuto AL., Medina C. & Fejerman N. (2005) Clinical and electroencephalographic aspects of late infantile neuronal ceroid lipofuscinosis. *Revista de Neurologia*, Vol. 40, No. 3 (Feb) , pp. 135-40, ISSN 0210-0010.
- Carstea ED., Polymeropoulos MH., Parker CC., Detera-Wadleigh SD., O'Neill RR., Patterson MC, Goldin E., Xiao H., Straub RE., Vanier MT., et al. (1993) Linkage of Niemann-Pick disease type C to human chromosome 18. *Proceedings of the National Academy of Science U S A*, Vol. 90, No. 5 (Mar), pp. 2002-4, ISSN 0073-6600.
- Chang M., Cooper JD., Sleat DE., Cheng SH., Dodge JC., Passini MA., Lobel P & Davidson BL. (2008) Intraventricular enzyme replacement improves disease phenotypes in a mouse model of late infantile neuronal ceroid lipofuscinosis. *Molecular Therapy*, Vol. 16, No. 4 (Apr), pp. 649-56, ISSN 0969-7128.
- Clarke JT., Mahuran DJ., Sathe S., Kolodny EH., Rigat BA., Raiman JA. & Tropak MB. (2011) An open-label Phase I/II clinical trial of pyrimethamine for the treatment of patients affected with chronic GM2 gangliosidosis (Tay-Sachs or Sandhoff variants). *Molecular Genetics and Metabolism*, Vol. 102, No. 1 (Jan), pp. 6-12, ISSN 1096-7192.
- Collins J., Holder GE., Herbert H. & Adams GG. (2006) Batten disease: features to facilitate early diagnosis. *British Journal of Ophthalmology*, Vol. 90, No. 9 (Sep), pp.1119-24, ISSN 0007-1161.
- Connock M., Burls A., Frew E., Fry-Smith A., Juarez-Garcia A., McCabe C., Wailoo A., Abrams K., Cooper N., Sutton A., O'Hagan A. & Moore D. (2006) The clinical effectiveness and cost-effectiveness of enzyme replacement therapy for Gaucher's disease: a systematic review. *Health Technology Assessment*, Vol 10, No. 24 (Jul), pp. :iii-iv, ix-136, ISSN 1366-5278.
- Cox TM., & Schofield JP. (1997) Gaucher's disease: clinical features and natural history. *Bailliere's Clinical Haematology*, Vol. 10, No. 4 (Dec), pp. 657-89, ISSN 0950-3536.
- Dardis A., Filocamo M., Grossi S., Ciana G., Franceschetti S, Dominissini S., Rubboli G., Di Rocco M., & Bembi B. (2009) Biochemical and molecular findings in a patient with myoclonic epilepsy due to a mistarget of the beta-glucosidase enzyme. *Molecular Genetics and Metabolism*, Vol. 97, No. 4 (Aug), pp. 309-11, ISSN 1096-7192.
- Das AK., Becerra CH., Yi W., Lu JY., Siakotos AN., Wisniewski KE. & Hofmann SL. (1998) Molecular genetics of palmitoyl-protein thioesterase deficiency in the U.S. *Journal of Clinical Investigation*, Vol. 15, No.2 (Jul), pp. 361-70, ISSN 0021-9738.
- Davies JP. & Ioannou YA. (2000) Topological analysis of Niemann-Pick C1 protein reveals that the membrane orientation of the putative sterol-sensing domain is identical to those of 3-hydroxy-3-methylglutaryl-CoA reductase and sterol regulatory element binding protein cleavage-activating protein. *Journal of Biological Chemistry*, Vol. 275, No. 32 (Aug), pp. 24367-74, ISSN 0021-9258.
- d'Azzo A., Andria G., Strisciuglio P. & Galjaard H. (2001). Galactosialidosis. The Metabolic and Molecular Basis of Inherited Disease Vol. III, 8th ed. Scriver CR., Beaudet AL., Sly WS., Valle D., editors, 3811-26, NY, McGraw-Hill, New York.

- Den Tandt WR. & Brossmer R. (1984) Determination of methylumbelliferyl-N-acetylneuraminic acid sialidase for clinical purposes. *Journal of Clinical Chemistry and Clinical Biochemistry*, Vol. 22, No. 2 (Feb), pp. 189-93, ISSN 0939-4974.
- Dibbens LM., Michelucci R., Gambardella A., Andermann F., Rubboli G., Bayly MA., Joensuu T., Vears DF., Franceschetti S., Canafoglia L., Wallace R., Bassuk AG., Power DA., Tassinari CA., Andermann E., Lehesjoki AE., & Berkovic SF. (2009) SCARB2 mutations in progressive myoclonus epilepsy (PME) without renal failure. *Annals of Neurology*, Vol. 66, No. 4 (Oct), pp. 532-6, ISSN 0364-5134.
- D'Incerti L. (2000) MRI in neuronal ceroid lipofuscinosis. *Neurological Science*, Vol. 21, (3 Suppl), pp. S71-3, ISSN 1590-1874.
- Dionisi-Vici C., Rizzo C., Burlina AB., Caruso U., Sabetta G., Uziel G. & Abeni D. (2002) Inborn errors of metabolism in the Italian pediatric population: a national retrospective survey. *Journal of Pediatrics*, Vol. 140, No. 3 (Mar), pp. 321-7, ISSN 0022-3476.
- Dittmer F., Ulbrich EJ., Hafner A., Schmahl W., Meister T., Pohlmann R. & von Figura K. (1999) Alternative mechanisms for trafficking of lysosomal enzymes in mannose 6-phosphate receptor-deficient mice are cell type-specific. *Journal of Cell Science*, Vol. 112, No. 10 (May), pp. 1591-7, ISSN 0021-9533.
- dos Santos MR., Tanaka A., Sá Miranda MC., Ribeiro MG., Maia M. & Suzuki K. (1991) GM2-gangliosidosis B1 variant: analysis of beta-hexosaminidase alpha gene mutations in 11 patients from a defined region in Portugal. *The American Journal of Human Genetics*, Vol. 49, No. 4 (Oct), pp. 886-90, ISSN 0002-9297.
- Elleder M., Franc J., Kraus J., Nevšimalová S., Sixtová K. & Zeman J. (1997) Neuronal ceroid lipofuscinosis in the Czech Republic: analysis of 57 cases. Report of the 'Prague NCL group'. *European Journal of Paediatric Neurology*, Vol. 1, No. 4, pp. 109-14, ISSN 1090-3798.
- Erikson A. (1986) Gaucher disease-Norrbottnian type (III). Neuropaediatric and neurobiological aspects of clinical patterns and treatment. *Acta Paediatrica Scandinavica Supplement*, Vol. 326, pp. 1-42, ISSN 0300-8843.
- Eskelinen EL., Tanaka Y., & Saftig P. (2003) At the acidic edge: emerging functions for lysosomal membrane proteins. *Trends in Cell Biology*, Vol. 13, No. 3 (Mar), pp. 137-45, ISSN 0962-8924.
- Ezaki J., Takeda-Ezaki M., Koike M., Ohsawa Y., Taka H., Mineki R., Murayama K., Uchiyama Y, Ueno T. & Kominami E. (2003) Characterization of Cln3p, the gene product responsible for juvenile neuronal ceroid lipofuscinosis, as a lysosomal integral membrane glycoprotein. *Journal of Neurochemistry*, Vol. 87, No 5 (Dec), pp. 1296-308, ISSN 0022-3042.
- Fancello T., Dardis A., Rosano C., Tarugi P., Tappino B., Zampieri S., Pinotti E., Corsolini F., Fecarotta S., D'Amico A., Di Rocco M., Uziel G., Calandra S., Bembi B. & Filocamo M. (2009) Molecular analysis of NPC1 and NPC2 gene in 34 Niemann-Pick C Italian patients: identification and structural modeling of novel mutations. *Neurogenetics*, Vol. 10, No. 3 (Jul), pp. 229-39, ISSN 0167-7063.
- Fernandez-Valero EM., Ballart A., Iturriaga C., Lluçh M., Macias J., Vanier MT., Pineda M. & Coll MJ. (2005) Identification of 25 new mutations in 40 unrelated Spanish Niemann-Pick type C patients: genotype-phenotype correlations. *Clinical Genetics*, Vol. 68, No. 3 (Sep), pp. 245-54, ISSN 0009-9163.

- Filocamo M., Mazzotti R., Stroppiano M., Grossi S., Dravet C., & Guerrini R. (2004) Early visual seizures and progressive myoclonus epilepsy in neuronopathic Gaucher disease due to a rare compound heterozygosity (N188S/S107L). *Epilepsia*, Vol. 45, No. 9 (Sep), pp.1154-7, ISSN 0013-9580.
- Franceschetti S., Uziel G., Ciano C., Scaioli V., Guerrini R., Visani E. & Panzica F. (2011) Characterization of severe action myoclonus in sialidoses. *Epilepsy Research*, Vol. 94, No. 1-2 (Mar), pp. 86-93, ISSN 0920-1211.
- Froissart R., Cheillan D., Bouvier R., Turret S., Bonnet V., Piraud M. & Maire I. (2005) Clinical, morphological, and molecular aspects of sialic acid storage disease manifesting in utero. *Journal of Medical Genetics*, Vol. 42, No. 11 (Nov), pp. 829-36, ISSN 00222593.
- Fujita H., Tanaka Y., Noguchi Y., Kono A., Himeno M., & Kato K. (1991) Isolation and sequencing of a cDNA clone encoding rat liver lysosomal cathepsin D and the structure of three forms of mature enzymes. *Biochemical and Biophysical Research Communications*, Vol. 179, No. 1 (Aug), pp.190-6, ISSN 0006-291X
- Fukuda M. (1991) Lysosomal membrane glycoproteins. Structure, biosynthesis, and intracellular trafficking. *Journal of Biological Chemistry*, Vol. 266, No. 32 (Nov), pp.1327-30, ISSN 0021-9258.
- Futerman AH. & van Meer G. (2004) The cell biology of lysosomal storage disorders. *Nature Reviews Molecular Cell Biology*, Vol. 5, No. 7 (Jul), pp. 554-65, ISSN 1471-0072.
- Galanaud D., Tourbah A., Lehericy S., Leveque N., Heron B., Billette de Villemeur T., Guffon N., Feillet F., Baumann N., Vanier MT. & Sedel F. (2009) 24 month-treatment with miglustat of three patients with Niemann-Pick disease type C: follow up using brain spectroscopy. *Molecular Genetics and Metabolism*, Vol. 96, No. 2 (Feb), pp. 55-8, ISSN 1096-7192.
- Gao H., Boustany RM., Espinola JA., Cotman SL., Srinidhi L., Antonellis KA., Gillis T., Qin X., Liu S., Donahue LR., Bronson RT., Faust JR., Stout D., Haines JL., Lerner TJ & MacDonald ME. (2002) Mutations in a novel CLN6-encoded transmembrane protein cause variant neuronal ceroid lipofuscinosis in man and mouse. *The American Journal of Human Genetics*, Vol. 70, No. 2 (Feb), pp. 324-35, ISSN 0002-9297.
- Garvey MA., Toro C., Goldstein S., Altarescu G., Wiggs EA., Hallett M., & Schiffmann R. (2001) Somatosensory evoked potentials as a marker of disease burden in type 3 Gaucher disease. *Neurology*, Vol. 13, No. 56 (Feb), pp. 391-4, ISSN 0028-3878.
- Gieselmann V., Hasilik A. & von Figura K. (1985) Processing of human cathepsin D in lysosomes in vitro. *Journal of Biological Chemistry*, Vol. 260, No. 5 (Mar), pp. 3215-20, ISSN 0021-9258.
- Golabek AA & Kida E. (2006) Tripeptidyl-peptidase I in health and disease. *Biological Chemistry*, Vol. 387, No 8 (Aug), pp. 1091-9, ISSN 1431-6730.
- Golabek AA., Kida E., Walus M., Wujek P., Mehta P & Wisniewski KE. (2003) Biosynthesis, glycosylation, and enzymatic processing in vivo of human tripeptidyl-peptidase I. *Journal of Biological Chemistry*, Vol. 278, No 9 (Feb). pp. 7135-45, ISSN 0021-9258.
- Gopalakrishnan MM., Grosch HW., Locatelli-Hoops S., Werth N., Smolenová E., Nettersheim M., Sandhoff K. & Hasilik A. (2004) Purified recombinant human prosaposin forms oligomers that bind procathepsin D and affect its autoactivation. *Biochemical Journal*, Vol. 383, No. 3 (Nov), pp. 507-15, ISSN 0264-6021.

- Grabowski GA., & Horowitz M. (1997) Gaucher's disease: molecular, genetic and enzymological aspects. *Baillieres in Clinical Haematology*, Vol. 10, No. 4 (Dec), pp.635-56, ISSN 0950-3536.
- Gravel RA., Kaback MM., Proia RL., Sandhoff K., Suzuki K. & Suzuki K. (2001) The GM2 gangliosidosis. *The Metabolic and Molecular Bases of Inherited Diseases* Vol. III, 8th ed. Scriver CR., Beaudet AL., Sly WS., Valle D., editors, 3827-76, NY, McGraw-Hill, New York.
- Grosso S., Farnetani MA., Berardi R., Margollicci M., Galluzzi P., Vivarelli R., Morgese G. & Ballestri P. (2003) GM2 gangliosidosis variant B1 neuroradiological findings. *Journal of Neurology*, Vol. 250, No. 1 (Jan), pp. 17-21, ISSN 0340-5354.
- Haltia M. (2003) The neuronal ceroid-lipofuscinoses. *Journal of Neuropathology & Experimental Neurology*, Vol. 62, No. 1 (Jan), pp. 1-13, ISSN 0022-3069.
- Heine C., Koch B., Storch S., Kohlschütter A., Palmer DN. & Braulke T. (2004) Defective endoplasmic reticulum-resident membrane protein CLN6 affects lysosomal degradation of endocytosed arylsulfatase A. *Journal of Biological Chemistry*, Vol. 279, No 21 (May), pp. 22347-52, ISSN 0021-9258.
- Hellsten E., Vesa J., Olkkonen VM., Jalanko A. & Peltonen L. (1996) Human palmitoyl protein thioesterase: evidence for lysosomal targeting of the enzyme and disturbed cellular routing in infantile neuronal ceroid lipofuscinosis. *EMBO Journal*, Vol. 15, No. 19 (Oct), pp. 5240-5, ISSN 0261-4189.
- Hendriksz CJ., Corry PC., Wraith JE., Besley GT., Cooper A. & Ferrie CD. (2004) Juvenile Sandhoff disease--nine new cases and a review of the literature. *Journal of Inherited Metabolic Disease*, Vol. 27, No. 2, pp. 241-9, ISSN 0141-8955.
- Herva R., Tyynelä J., Hirvasniemi A., Syrjäkallio-Ylitalo M. & Haltia M. (2000) Northern epilepsy: a novel form of neuronal ceroid-lipofuscinosis. *Brain Pathology*, Vol. 10, No. 2 (Apr), pp. :215-22, ISSN 1015-6305.
- Hobert JA. & Dawson G. (2006) Neuronal ceroid lipofuscinoses therapeutic strategies: past, present and future. *Biochimica et Biophysica Acta*, Vol. 1762, No. 10 (Oct), pp. 945-53, ISSN 0304-4165.
- Holmberg V., Jalanko A., Isosomppi J., Fabritius AL., Peltonen L. & Kopra O. (2004) The mouse ortholog of the neuronal ceroid lipofuscinosis CLN5 gene encodes a soluble lysosomal glycoprotein expressed in the developing brain. *Neurobiology of Disease*, Vol. 16, No. 1 (Jun), pp. 29-40, ISSN 0969-9961.
- Holmes EW. & O'Brien JS. (1979) Separation of glycoprotein-derived oligosaccharides by thin-layer chromatography. *Analytical Biochemistry*, Vol. 93, No. 1 (Feb), pp. 167-70, ISSN 0003-2697.
- Holopainen JM., Saarikoski J., Kinnunen PK & Järvelä I. (2001) Elevated lysosomal pH in neuronal ceroid lipofuscinoses (NCLs). *European Journal of Biochemistry*, Vol. 268, No. 22 (Nov), pp. 5851-6, ISSN: 0014-2956.
- Horowitz, M., Wilder S., Horowitz Z., Reiner O., Gelbart T., & Beutler E. (1989) The human glucocerebrosidase gene and pseudogene: structure and evolution. *Genomics*, Vol 4, No. 1 (Jan), pp. 87-96, ISSN 0888-7543.
- Huang K. & El-Husseini A. (2005) Modulation of neuronal protein trafficking and function by palmitoylation. *Current Opinion in Neurobiology*, Vol. 15, No. 5 (Oct), pp. 527-35, ISSN 0959-4388.

- Infante RE., Abi-Mosleh L., Radhakrishnan A., Dale JD., Brown MS. & Goldstein JL. (2008a) Purified NPC1 protein. I. Binding of cholesterol and oxysterols to a 1278-amino acid membrane protein. *Journal of Biological Chemistry*, Vol. 283, No. 2 (Jan), pp. 1052-63, ISSN 0021-9258.
- Infante RE., Radhakrishnan A., Abi-Mosleh L., Kinch LN., Wang ML., Grishin NV., Goldstein JL. & Brown MS.(2008b) Purified NPC1 protein: II. Localization of sterol binding to a 240-amino acid soluble luminal loop. *Journal of Biological Chemistry*, Vol. 283, No. 2 (Jan), pp. 1064-75, ISSN 0021-9258.
- Inglese M., Nusbaum AO., Pastores GM., Gianutsos J., Kolodny EH. & Gonen O. (2005) MR imaging and proton spectroscopy of neuronal injury in late-onset GM2 gangliosidosis. *American Journal of Neuroradiology*, Vol. 26, No. 8 (Sep), pp. 2037-42, ISSN 0195-6108.
- International Batten Disease Consortium. (1995) Isolation of a novel gene underlying Batten disease, CLN3. The International Batten Disease Consortium. *Cell*, Vol. 82, No. 6 (Sep), pp. 949-57, ISSN 0092-8674.
- Jain A., Kohli A. & Sachan D. (2010) Infantile Sandhoff's disease with peripheral neuropathy. *Pediatric Neurology*, Vol. 42, No. 6 (Jun), pp. 459-61, ISSN 1098-3600.
- Jalanko A. & Braulke T. (2009) Neuronal ceroid lipofuscinoses. *Biochimica et Biophysica Acta*, Vol. 1793, No. 4 (Apr), pp. 697-709, ISSN 0304-4165.
- Järvelä I., Autti T., Lamminranta S., Aberg L., Raininko R. & Santavuori P. (1999) Clinical and magnetic resonance imaging findings in Batten disease: analysis of the major mutation (1.02-kb deletion). *Annals of Neurology*, Vol. 42, No. 5 (Nov), pp. 799-802, ISSN 0364-5134.
- Kaback M., Lim-Steele J., Dabholkar D., Brown D., Levy N. & Zeiger K. (1993) Tay-Sachs disease--carrier screening, prenatal diagnosis, and the molecular era. An international perspective, 1970 to 1993. The International TSD Data Collection Network. *JAMA*, Vol. 270, No. 19 (Nov), pp. 2307-15, ISSN 00987484.
- Kasho VN., Smirnova IN. & Kaback HR. (2006) Sequence alignment and homology threading reveals prokaryotic and eukaryotic proteins similar to lactose permease. *Journal of Molecular Biology*, Vol. 358, No. 4 (May), pp. 1060-70, ISSN 0022-2836.
- Kelly DA., Portmann B., Mowat AP., Sherlock S. & Lake BD. (1993) Niemann-Pick disease type C: diagnosis and outcome in children, with particular reference to liver disease. *Journal of Pediatrics*, Vol. 123, No. 2 (Aug), pp. 242-7, ISSN 0022-3476.
- Kim JW., Liou BB., Lai MY., Ponce E., & Grabowski GA. (1996) Gaucher disease: identification of three new mutations in the Korean and Chinese (Taiwanese) populations. *Human Mutation*, Vol. 7, No. 3, pp.214-218, ISSN 1059-7794.
- Kim Y., Ramirez-Montealegre D. & Pearce DA. (2003) A role in vacuolar arginine transport for yeast Btn1p and for human CLN3, the protein defective in Batten disease. *Proceedings of the National Academy of Science U S A*, Vol. 100, No. 26 (Dec), pp. 15458-62, ISSN 0073-6600.
- Kitzmüller C., Haines RL., Codlin S., Cutler DF. & Mole SE. (2008) A function retained by the common mutant CLN3 protein is responsible for the late onset of juvenile neuronal ceroid lipofuscinosis. *Human Molecular Genetics*, Vol. 17, No.2 (Jan), pp. 303-12, ISSN 0964-6906.
- Klünemann HH., Elleder M., Kaminski WE., Snow K., Peyser JM., O'Brien JF., Munoz D., Schmitz G., Klein HE. & Pendlebury WW. (2002) Frontal lobe atrophy due to a

- mutation in the cholesterol binding protein HE1/NPC2. *Annals of Neurology*, Vol. 52, No. 6, pp. 743-9, ISSN 0364-5134.
- Kohan R., Cismondi IA., Kremer RD., Muller VJ., Guelbert N., Anzolini VT., Fietz MJ., Ramírez AM. & Halac IN. (2009) An integrated strategy for the diagnosis of neuronal ceroid lipofuscinosis types 1 (CLN1) and 2 (CLN2) in eleven Latin American patients. *Clinical Genetics*, Vol. 76, No. 4 (Oct), pp. 372-82, ISSN 0009-9163.
- Kohlschütter A & Schulz A. (2009) Towards understanding the neuronal ceroid lipofuscinoses. *Brain & Development*, Vol. 31, No. 7 (Aug), pp. 499-502, ISSN 0387-7604.
- Kousi M., Siintola E., Dvorakova L., Vlaskova H., Turnbull J., Topcu M., Yuksel D., Gokben S., Minassian BA., Elleder M., Mole SE. & Lehesjoki AE. (2009) Mutations in CLN7/MFSD8 are a common cause of variant late-infantile neuronal ceroid lipofuscinosis. *Brain*, Vol. 132, No. 3 (Mar), pp. 810-9, ISSN 0006-8950.
- Kowarz L., Goker-Alpan O., Banerjee-Basu S., LaMarca ME., Kinlaw L., Schiffmann R., Baxevanis AD., & Sidransky E. (2005) Gaucher mutation N188S is associated with myoclonic epilepsy. *Human Mutation*, Vol. 26, No. 3 (Sep), pp. 271-3, ISSN 1059-7794.
- Kraoua I., Sedel F., Caillaud C., Froissart R., Stirnemann J., Chaurand G., Flodrops H., Tari S., Gourfinkel-An I., Mathieu S., Belmatoug N., Billette de Villemeur T., & Mignot C. (2010) French experience of type 3 Gaucher disease: Phenotypic diversity and neurological outcome of 10 patients. *Brain & Development*, Vol. 33, No. 3 (Feb), pp. 131-9, ISSN 0387-7604.
- Kwon HJ., Abi-Mosleh L., Wang ML., Deisenhofer J., Goldstein JL., Brown MS. & Infante RE. (2009) Structure of N-terminal domain of NPC1 reveals distinct subdomains for binding and transfer of cholesterol. *Cell*, Vol. 137, No. 7 (Jun), pp. 1213-24, ISSN 0092-8674.
- Kyttälä A., Ihrke G., Vesa J., Schell MJ. & Luzio JP. (2004) Two motifs target Batten disease protein CLN3 to lysosomes in transfected nonneuronal and neuronal cells. *Molecular Biology of the Cell*, Vol. 15, No. 3 (Mar), pp. 1313-23, ISSN 1059-1524.
- Kyttälä A., Lahtinen U., Braulke T. & Hofmann SL. (2006) Functional biology of the neuronal ceroid lipofuscinoses (NCL) proteins. *Biochimica et Biophysica Acta*, Vol. 1726, No. 10 (Oct), pp. 920-33, ISSN 0304-4165.
- Lake BD & Hall NA. (1993) Immunolocalization studies of subunit c in late-infantile and juvenile Batten disease. *Journal of Inherited Metabolic Disease*, Vol. 16, No. 2, pp. 263-6, ISSN 0141-8955.
- Lauronen L., Munroe PB., Järvelä I., Autti T., Mitchison HM., O'Rawe AM., Gardiner RM., Mole SE., Puranen J., Häkkinen AM., Kirveskari E. & Santavuori P. (1999) Delayed classic and protracted phenotypes of compound heterozygous juvenile neuronal ceroid lipofuscinosis. *Neurology*, Vol. 52, No. 2 (Jan), pp. 360-5, ISSN 0028-3878.
- Lehtovirta M., Kyttälä A., Eskelinen EL., Hess M., Heinonen O. & Jalanko A. (2001) Palmitoyl protein thioesterase (PPT) localizes into synaptosomes and synaptic vesicles in neurons: implications for infantile neuronal ceroid lipofuscinosis (INCL). *Human Molecular Genetics*, Vol. 10, No. 1 (Jan), pp. 69-75, ISSN 0964-6906.
- Leonova T., & Grabowski GA. (2000) Fate and sorting of acid beta-glucosidase in transgenic mammalian cells. *Molecular Genetics and Metabolism*, Vol. 70, No. 4 (Aug), pp: 281-94, ISSN 1096-7192.

- Lonka L., Kyttälä A., Ranta S., Jalanko A. & Lehesjoki AE. (2000) The neuronal ceroid lipofuscinosis CLN8 membrane protein is a resident of the endoplasmic reticulum. *Human Molecular Genetics*, Vol. 9, No. 11 (Jul), pp. 1691-7, ISSN 0964-6906.
- Lowden JA. & O'Brien JS. (1979) Sialidosis: a review of human neuraminidase deficiency. *American Journal of Human Genetics*, Vol. 31, No. 1 (Jan), pp. 1-18, ISSN 0002-9297.
- Luiro K, Kopra O, Lehtovirta M, Jalanko A. (2001) CLN3 protein is targeted to neuronal synapses but excluded from synaptic vesicles: new clues to Batten disease. *Human Molecular Genetics*, Vol. 10, No. 19 (Sep), pp. 2123-31, ISSN 0964-6906.
- Luiro K., Kopra O., Blom T., Gentile M., Mitchison HM., Hovatta I., Törnquist K. & Jalanko A. (2006) Batten disease (JNCL) is linked to disturbances in mitochondrial, cytoskeletal, and synaptic compartments. *Journal of Neuroscience Research*, Vol. 84, No. 5 (Oct), pp. 1124-38, ISSN 0360-4012.
- Macías-Vidal J., Rodríguez-Pascau L., Sánchez-Ollé G., Lluch M., Vilageliu L., Grinberg D., Coll MJ.; the Spanish NPC Working Group. (2010) Molecular analysis of 30 Niemann-Pick type C patients from Spain. *Clinical Genetics*, Jul 6. [Epub ahead of print], ISSN 0009-9163.
- Maegawa GH., Stockley T., Tropak M., Banwell B., Blaser S., Kok F., Giugliani R., Mahuran D. & Clarke JT. (2006) The natural history of juvenile or subacute GM2 gangliosidosis: 21 new cases and literature review of 134 previously reported. *Pediatrics*, Vol. 118, No. 5 (Nov), pp. 1550-62, ISSN 0031-4005.
- Marseille Consensus Group. (1990) Classification of progressive myoclonus epilepsies and related disorders. *Annals of Neurology*, Vol. 28, No. 1 (Jul), pp. 113-6, ISSN 0364-5134.
- Martin JJ. (1991) Adult type of neuronal ceroid lipofuscinosis. *Developmental Neuroscience*, Vol. 13, No. 4-5, pp.331-8, ISSN 0378-5866.
- Meikle PJ., Hopwood JJ., Clague AE., & Carey WF. (1999) Prevalence of lysosomal storage disorders. *Journal of American Medical Association*, Vol. 281, No. 3 (Jan), pp. 249-54, ISSN 0098-7484.
- Millat G., Marçais C., Rafi MA., Yamamoto T., Morris JA., Pentchev PG., Ohno K., Wenger DA. & Vanier MT. (1999) Niemann-Pick C1 disease: the I1061T substitution is a frequent mutant allele in patients of Western European descent and correlates with a classic juvenile phenotype. *The American Journal of Human Genetics*, Vol. 65, No. 5 (Nov), pp. 1321-9, ISSN 0002-9297.
- Millat G., Bailo N., Molinero S., Rodriguez C., Chikh K. & Vanier MT. (2005) Niemann-Pick C disease: use of denaturing high performance liquid chromatography for the detection of NPC1 and NPC2 genetic variations and impact on management of patients and families. *Molecular Genetics and Metabolism*, Vol. 86, No. 1-2 (Sep-Oct), pp. 220-32, ISSN 1096-7192.
- Millat G., Chikh K., Naureckiene S., Sleat DE., Fensom AH., Higaki K., Elleder M., Lobel P. & Vanier MT. (2001) Niemann-Pick disease type C: spectrum of HE1 mutations and genotype/phenotype correlations in the NPC2 group. *The American Journal of Human Genetics*, Vol. 69, No. 5 (Nov), pp. 1013-21, ISSN 0002-9297.
- Milner CM., Smith SV., Carrillo MB., Taylor GL., Hollinshead M., & Campbell RD. (1997) Identification of a sialidase encoded in the human major histocompatibility complex. *Journal of Biological Chemistry*, Vol. 272, No. 7 (Feb), pp. 4549-58, ISSN 0021-9258.

- Mistry P. & Germain DP. Therapeutic goals in Gaucher disease. (2006) *Revue de médecine interne*. Vol. 27, Suppl 1 (Mar), pp. S30-8, ISSN 0248-8663.
- Mitchison HM., Hofmann SL., Becerra CH., Munroe PB., Lake BD., Crow YJ., Stephenson JB., Williams RE., Hofman IL., Taschner PE., Martin JJ., Philippart M., Andermann E., Andermann F., Mole SE., Gardiner RM. & O'Rawe AM. (1998) Mutations in the palmitoyl-protein thioesterase gene (PPT; CLN1) causing juvenile neuronal ceroid lipofuscinosis with granular osmiophilic deposits. *Human Molecular Genetics*, Vol. 7, No 2 (Feb), pp. 291-7, ISSN 0964-6906.
- Mole SE., Michaux G., Codlin S., Wheeler RB., Sharp JD. & Cutler DF. (2004) CLN6, which is associated with a lysosomal storage disease, is an endoplasmic reticulum protein. *Experimental Cell Research*, Vol. 298, No. 2 (Aug), pp. 399-406, ISSN 0014-4827.
- Mole SE., Williams RE & Goebel HH. (2005) Correlations between genotype, ultrastructural morphology and clinical phenotype in the neuronal ceroid lipofuscinoses. *Neurogenetics*, Vol. 6, No. 3 (Sep), pp. 107-26, ISSN 0167-7063.
- Montalvo AL., Filocamo M., Vlahovicek K., Dardis A., Lualdi S., Corsolini F., Bembi B. & Pittis MG. (2005) Molecular analysis of the HEXA gene in Italian patients with infantile and late onset Tay-Sachs disease: detection of fourteen novel alleles. *Human Mutation*, Vol. 26, No. 3 (Sep), pp. 282-90, ISSN 1059-7794.
- Montfort M., Chabás A., Vilageliu L., & Grinberg D. (2004) Functional analysis of 13 GBA mutant alleles identified in Gaucher disease patients: Pathogenic changes and "modifier" polymorphisms. *Human Mutation*, Vol. 23, No. 6 (Jun). pp. 567-75, ISSN 1059-7794.
- Munroe PB., Mitchison HM., O'Rawe AM., Anderson JW., Boustany RM., Lerner TJ., Taschner PE., de Vos N., Breuning MH., Gardiner RM., Mole SE. (1997) Spectrum of mutations in the Batten disease gene, CLN3. *American Journal of Human Genetics*, Vol. 61, No. 2 (Aug), pp. 310-6, ISSN 0002-9297.
- Naureckiene S., Sleat DE., Lackland H., Fensom A., Vanier MT., Wattiaux R., Jadot M., & Lobel P. (2000) Identification of HE1 as the second gene of Niemann-Pick C disease. *Science*, Vol. 290, No. 5500 (Dec), pp. 2298-301, ISSN 0036-8075.
- Neote K., Bapat B., Dumbrille-Ross A., Troxel C., Schuster SM., Mahuran DJ. & Gravel RA. (1988) Characterization of the human HEXB gene encoding lysosomal beta-hexosaminidase. *Genomics*, Vol. 3, No. 4 (Nov), pp. 279-86, ISSN 0888-7543.
- Neudorfer O., Pastores GM., Zeng BJ., Gianutsos J., Zaroff CM. & Kolodny EH. (2005) Late-onset Tay-Sachs disease: phenotypic characterization and genotypic correlations in 21 affected patients. *Genetics in Medicine*, Vol. 7, No. 2 (Feb), 119-23, ISSN 1098-3600.
- Okada S., Sugino H., Kato T., Yutaka T., Koike M., Dezawa T., Yamano T. & Yabuuchi H. (1983) A severe infantile sialidosis (beta-galactosidase-alpha-neuraminidase deficiency) mimicking GM1-gangliosidosis type 1. *European Journal of Pediatrics*, Vol. 140, No. 4 (Sep), pp. 295-8, ISSN 0340-6199.
- Park JK., Orvisky E., Tayebi N., Kaneski C., Lamarca ME., Stubblefield BK., Martin BM., Schiffmann R., & Sidransky E. (2003) Myoclonic epilepsy in Gaucher disease: genotype-phenotype insights from a rare patient subgroup. *Pediatric Research*, Vol. 53; No. 3 (Mar), pp. 387-95, ISSN 0971-9032.
- Park WD., O'Brien JF., Lundquist PA., Kraft DL., Vockley CW., Karnes PS., Patterson MC. & Snow K. (2003) Identification of 58 novel mutations in Niemann-Pick disease type

- C: correlation with biochemical phenotype and importance of PTC1-like domains in NPC1. *Human Mutation*, Vol. 22, No. 4 (Oct), pp. 313-25, ISSN 1059-7794.
- Pasmanik-Chor M., Elroy-Stein O., Aerts H., Agmon V., Gatt S., & Horowitz M. (1996) Overexpression of human glucocerebrosidase containing different-sized leaders. *Biochemical Journal*, Vol.1, No. 317 (Jul), pp.81-8, ISSN 0264-6021.
- Patterson MC, Vanier MT, Suzuki K, Morris JA, Carstea E, Neufeld EB., Blanchette-Mackie JE. & Pentchev P. (2001). Niemann- Pick Disease type C: a lipid trafficking disorder. *The metabolic and molecular bases of inherited disease* Vol. III, 8th ed. Scriver CR., Beaudet AL., Sly WS., Valle D., editors, 3611-34. 3635-68, NY, McGraw-Hill, New York.
- Patterson MC., Vecchio D., Prady H., Abel L. & Wraith JE. (2007) Miglustat for treatment of Niemann-Pick C disease: a randomised controlled study. *Lancet Neurology*, Vol. 6, No. 9 (Sep), pp. 765-72, ISSN 1474-4422.
- Persaud-Sawin DA. & Boustany RM. (2005) Cell death pathways in juvenile Batten disease. *Apoptosis*, Vol. 10, No. 5 (Oct), pp. 973-85, ISSN 1360-8185.
- Pinto R., Caseiro C., Lemos M., Lopes L., Fontes A., Ribeiro H., Pinto E., Silva E., Rocha S., Marcão A., Ribeiro I., Lacerda L., Ribeiro G., Amaral O. & Sá Miranda MC. (2004) Prevalence of lysosomal storage diseases in Portugal. *European Journal of Human Genetics*, Vol. 12, No. 2 (Feb), pp. 87-92, ISSN 1018-4813.
- Platt FM. & Lachmann RH. (2009) Treating lysosomal storage disorders: current practice and future prospects. *Biochimica et Biophysica Acta*, Vol. 1793, No. 4 (Apr), pp. 737-45, ISSN 0304-4165.
- Platt FM., Jeyakumar M., Andersson U., Dwek RA. & Butters TD. (2005) New developments in treating glycosphingolipid storage diseases. *Advances in Experimental Medicine and Biology*, Vol. 564, pp. 117-26, ISSN 0065-2598.
- Poorthuis BJ., Wevers RA., Kleijer WJ., Groener JE., de Jong JG., van Weely S., Niezen-Koning KE. & van Diggelen OP. (1999). The frequency of lysosomal storage diseases in The Netherlands. *Human Genetics*, Vol. 105, No. 1-2, (Jul-Aug), pp. 151-6, ISSN 0340-6717.
- Poupetová H., Ledvinová J., Berná L., Dvoráková L., Kozich V. & Elleder M. (2010) The birth prevalence of lysosomal storage disorders in the Czech Republic: comparison with data in different populations. *Disease*, Vol. 33, No. 4 (Aug), pp. 387-96, ISSN 0141-8955.
- Pshezhetsky AV., Richard C., Michaud L., Igdoura S., Wang S., Elsliger MA., Qu J., Leclerc D., Gravel R., Dallaire L., & Potier M. (1997) Cloning, expression and chromosomal mapping of human lysosomal sialidase and characterization of mutations in sialidosis. *Nature Genetics*, Vol.15, No. 3 (Mar), pp. 316-20, ISSN 1061-4036.
- Rakheja D., Narayan SB., Pastor JV. & Bennett MJ. (2004) CLN3P, the Batten disease protein, localizes to membrane lipid rafts (detergent-resistant membranes). *Biochemical and Biophysical Research Communication*, Vol. 317, No. 4 (May), pp. 988-91, ISSN 0006-291X.
- Ranta S., Topcu M., Tegelberg S., Tan H., Ustübutün A., Saatci I., Dufke A., Enders H., Pohl K., Alembik Y., Mitchell WA., Mole SE. & Lehesjoki AE. (2004) Variant late infantile neuronal ceroid lipofuscinosis in a subset of Turkish patients is allelic to Northern epilepsy. *Human Mutation*, Vol. 23, No. 4 (Apr), pp. 300-5, ISSN 1059-7794.
- Ranta S., Zhang Y., Ross B., Lonka L., Takkunen E., Messer A., Sharp J., Wheeler R., Kusumi K., Mole S., Liu W., Soares MB., Bonaldo MF., Hirvasniemi A., de la Chapelle A.,


- Gilliam TC. & Lehesjoki AE. (1999) The neuronal ceroid lipofuscinoses in human EPMR and mnd mutant mice are associated with mutations in CLN8. *Nature Genetics*, Vol. 23, No. 2 (Oct), pp. 233-6, ISSN 1061-4036.
- Rapin I. (1986) Myoclonus in neuronal storage and Lafora diseases. *Advances in Neurology*. Vol. 43, pp. 65-85, ISSN 0091-3952.
- Reczek D., Schwake M., Schröder J., Hughes H., Blanz J., Jin X., Brondyk W., Van Patten S., Edmunds T., & Saftig P. (2007) LIMP-2 is a receptor for lysosomal mannose-6-phosphate-independent targeting of beta-glucocerebrosidase. *Cell*, Vol. 131, No. 4 (Nov), pp. 770-83, ISSN 0092-8674.
- Reinhardt K., Grapp M., Schlachter K., Brück W., Gärtner J. & Steinfeld R. (2010) Novel CLN8 mutations confirm the clinical and ethnic diversity of late infantile neuronal ceroid lipofuscinosis. *Clinical Genetics*, Vol. 77, No. 1 (Jan), pp. 79-85, ISSN 0009-9163.
- Ribeiro I., Marcão A., Amaral O., Sá Miranda MC., Vanier MT. & Millat G. (2001) Niemann-Pick type C disease: NPC1 mutations associated with severe and mild cellular cholesterol trafficking alterations. *Human Genetics*, Vol. 109, No. 1 (Jul), pp. 24-32, ISSN 0002-9297.
- Ruchoux MM. & Goebel HH. (1996) Diagnostic (clinical and morphological) criteria for adult neuronal ceroid-lipofuscinosis (Kufs' disease). *Neuropathology and Applied Neurobiology*, Vol 23, No. 3 (Jun), pp. 262-3, ISSN 0305-1846.
- Rucker JC., Shapiro BE., Han YH., Kumar AN., Garbutt S., Keller EL. & Leigh RJ. 2004 Neuro-ophthalmology of late-onset Tay-Sachs disease (LOTS). *Neurology*, Vol. 63, No. 10 (Nov), pp. 1918-26, ISSN 0028-3878.
- Runz H., Dolle D., Schlitter AM. & Zschocke J. (2008) NPC-db, a Niemann-Pick type C disease gene variation database. *Human Mutation*, Vol. 29, No. 3 (Mar), pp. 345-50, ISSN 1059-7794.
- Rusyn E., Mousallem T., Persaud-Sawin DA., Miller S. & Boustany RM. (2008) CLN3p impacts galactosylceramide transport, raft morphology, and lipid content. *Pediatric Research*, Vol. 63, No. 6 (Jun), pp. 625-31, ISSN-0971-9032.
- Santavuori P. (1988) Neuronal ceroid-lipofuscinoses in childhood. *Brain & Development*, Vol. 10, No. 2, pp. 80-3, ISSN 0387-7604.
- Schiffmann R., Fitzgibbon EJ., Harris C., DeVile C., Davies EH., Abel L., van Schaik IN., Benko W., Timmons M., Ries M. & Vellodi A. (2008) Randomized, controlled trial of miglustat in Gaucher's disease type 3. *Annals of Neurology*. Nov, Vol. 64, No.5, pp: 514-22, ISSN 0364-5134.
- Seeman PJ., Finckh U., Höppner J., Lakner V., Liebisch I., Grau G., & Rolfs A. (1996) Two new missense mutations in a non-Jewish Caucasian family with type 3 Gaucher disease. *Neurology*. Vol. 46, No. 4 (April), pp. 1102-7, ISSN 0028-3878.
- Shapiro BE., Pastores GM., Gianutsos J., Luzy C. & Kolodny EH. (2009) Miglustat in late-onset Tay-Sachs disease: a 12-month, randomized, controlled clinical study with 24 months of extended treatment. *Genetics in Medicine*, Vol. 11, No. 6 (Jun), pp. 425-33, ISSN 1098-3600.
- Siintola E., Partanen S., Strömme P., Haapanen A., Haltia M., Maehlen J., Lehesjoki AE. & Tyynelä J. (2006) Cathepsin D deficiency underlies congenital human neuronal ceroid-lipofuscinosis. *Brain*, Vol. 129, No. 6 (Jun), pp. 1438-45, ISSN 0006-8950.
- Siintola E., Topcu M., Aula N., Lohi H., Minassian BA., Paterson AD., Liu XQ., Wilson C., Lahtinen U., Anttonen AK. & Lehesjoki AE. (2007) The novel neuronal ceroid

- lipofuscinosis gene MFSD8 encodes a putative lysosomal transporter. *The American Journal of Human Genetics*, Vol. 81, No. 1 (Jul), pp. 136-46, ISSN 0002-9297.
- Sleat DE., Donnelly RJ., Lackland H., Liu CG., Sohar I., Pullarkat RK. & Lobel P. (1997). Association of mutations in a lysosomal protein with classical late-infantile neuronal ceroid lipofuscinosis. *Science*, Vol. 277, No 5333, (Sep), pp. 1802-5, ISSN 0036-8075.
- Sleat DE., Lackland H., Wang Y., Sohar I., Xiao G., Li H. & Lobel P. (2005) The human brain mannose 6-phosphate glycoproteome: a complex mixture composed of multiple isoforms of many soluble lysosomal proteins. *Proteomics*, Vol.5, No. 6 (Apr), pp. 1520-32, ISSN 1615-9861.
- Sleat DE., Zheng H., Qian M. & Lobel P. (2006) Identification of sites of mannose 6-phosphorylation on lysosomal proteins. *Molecular & Cellular Proteomics*, Vol. 5, No. 4 (Apr), pp. 686-701, ISSN 1535-9476.
- Sorge J., West C., Westwood B., & Beutler E. (1985) Molecular cloning and nucleotide sequence of human glucocerebrosidase cDNA. *Proceedings of the National Academy of Science USA*, Vol. 82, No. 21 (Nov.), pp. 7289-93, ISSN 0073-6600.
- Sorge JA., West C., Kuhl W., Treger L., Beutler E. (1987) The human glucocerebrosidase gene has two functional ATG initiator codons. *The American Journal of Human Genetics*, Vol. 41, No. 6 (Dec), pp.1016-24, ISSN 0002-9297.
- Staretz-Chacham O., Lang TC., LaMarca ME., Krasnewich D. & Sidransky E. (2009) Lysosomal storage disorders in the newborn. *Pediatrics*, Vol. 123, No. 4 (Apr), pp. 1191-207, ISSN 0031-4005.
- Steinberg SJ., Ward CP. & Fensom AH. (1994) Complementation studies in Niemann-Pick disease type C indicate the existence of a second group. *Journal of Medical Genetics*, Vol. 31, No. 4 (Apr), pp. 317-20, ISSN 0022-2593.
- Steinfeld R., Heim P., von Gregory H., Meyer K., Ullrich K., Goebel HH. & Kohlschütter A. (2002) Late infantile neuronal ceroid lipofuscinosis: quantitative description of the clinical course in patients with CLN2 mutations. *American Journal of Medical Genetics*, Vol 112, No. 4 (Nov), pp. 347-54, ISSN 1552-4841.
- Stenson PD., Ball EV., Mort M., Phillips AD., Shiel JA., Thomas NS., Abeyasinghe S., Krawczak M., & Cooper DN. (2003) Human Gene Mutation Database (HGMD): 2003 update. *Human Mutation*, Vol. 21 No. 6, pp. 577-81, ISSN 1059-7794.
- Stogmann E., El Tawil S., Wagenstaller J., Gaber A., Edris S., Abdelhady A., Assem-Hilger E., Leutmezer F., Bonelli S., Baumgartner C., Zimprich F., Strom TM & Zimprich A. (2009) A novel mutation in the MFSD8 gene in late infantile neuronal ceroid lipofuscinosis. *Neurogenetics*, Vol. 10, No. 1 (Feb), pp. 73-7, ISSN 0167-7063.
- Storch S., Pohl S., Quitsch A., Falley K. & Braulke T. (2007) C-terminal prenylation of the CLN3 membrane glycoprotein is required for efficient endosomal sorting to lysosomes. *Traffic*, Vol. 8, No. 4 (Apr), pp. 431-44, ISSN 1398-9219.
- Sun X., Marks DL., Park WD., Wheatley CL., Puri V., O'Brien JF., Kraft DL., Lundquist PA., Patterson MC., Pagano RE. & Snow K. (2001) Niemann-Pick C variant detection by altered sphingolipid trafficking and correlation with mutations within a specific domain of NPC1. *The American Journal of Human Genetics*, Vol. 68, No. 6 (Jun), pp. 1361-72, ISSN 0002-9297.
- Topçu M., Tan H., Yalnizoğlu D., Usubütün A., Saatçi I., Aynaci M., Anlar B., Topaloğlu H., Turanlı G., Köse G. & Aysun S. (2004) Evaluation of 36 patients from Turkey with

- neuronal ceroid lipofuscinosis: clinical, neurophysiological, neuroradiological and histopathologic studies. *Turkish Journal of Pediatrics*, Vol. 46, No. 1 (Jan-Mar), pp. 1-10, ISSN 0041-4301.
- Triggs-Raine BL., Mules EH., Kaback MM., Lim-Steele JS., Dowling CE., Akerman BR., Natowicz MR., Grebner EE., Navon R., Welch JP., et al. (1992) A pseudodeficiency allele common in non-Jewish Tay-Sachs carriers: implications for carrier screening. *The American Journal of Human Genetics*, Vol. 51, No. 4 (Oct), pp. 793-801, ISSN 0002-9297.
- Tutor JC. (2004) Biochemical characterization of the GM2 gangliosidosis B1 variant. *Brazilian Journal of Medical and Biological Research*, Vol. 37, No. 6 (Jun), pp. 777-83.
- Tylki-Szymańska A., Vellodi A., El-Beshlawy A., Cole JA., & Kolodny E. (2010) Neuronopathic Gaucher disease: demographic and clinical features of 131 patients enrolled in the International Collaborative Gaucher Group Neurological Outcomes Subregistry. *Journal of Inherited Metabolic Diseases*, Vol. 33, No. 4 (Aug), pp. 339-46, ISSN 0141-8955.
- Tyynelä J., Palmer DN., Baumann M. & Haltia M. (1993) Storage of saposins A and D in infantile neuronal ceroid-lipofuscinosis. *FEBS Letters*, Vol. 330, No. 1 (Sep), pp. 8-12, ISSN 0014-5793.
- Tyynelä J., Suopanki J., Santavuori P., Baumann M. & Haltia M. (1997) Variant late infantile neuronal ceroid-lipofuscinosis: pathology and biochemistry. *Journal of Neuropathology & Experimental Neurology*, Vol. 56, No. 4 (Apr), pp. 369-75, ISSN 0022-3069.
- Van der Spoel A., Bonten E., & d'Azzo A. (1998) Transport of human lysosomal neuraminidase to mature lysosomes requires protective protein/cathepsin A. *EMBO Journal*, Vol. 17, No. 6 (Mar), pp. 1588-97, ISSN 0261-4189.
- van der Spoel A., Bonten E., & d'Azzo A. (2000) Processing of lysosomal beta-galactosidase. The C-terminal precursor fragment is an essential domain of the mature enzyme. *Journal of Biological Chemistry*, Vol. 275, No. 14 (Apr), pp. 10035-40, ISSN 0021-9258.
- van Diggelen OP., Thobois S., Tilikete C., Zabet MT., Keulemans JL., van Bunderen PA., Taschner PE., Losekoot M. & Voznyi YV. (2001) Adult neuronal ceroid lipofuscinosis with palmitoyl-protein thioesterase deficiency: first adult-onset patients of a childhood disease. *Annals of Neurology*, Vol. 15, No.2 (Aug), pp. 269-72, ISSN 0364-5134.
- Vanhanen SL., Puranen J., Autti T., Raininko R., Liewendahl K., Nikkinen P., Santavuori P., Suominen P., Vuori K. & Häkkinen AM. (2004) Neuroradiological findings (MRS, MRI, SPECT) in infantile neuronal ceroid-lipofuscinosis (infantile CLN1) at different stages of the disease. *Neuropediatrics*, Vol. 35, No. 1 (Feb), pp. 27-35, ISSN 0174-304X.
- Vanier MT & Millat G. (2003) Niemann-Pick disease type C. *Clinical Genetics*, Vol. 64, No. 4
- Vanier MT. & Millat G. (2004) Structure and function of the NPC2 protein. *Biochimica et Biophysica Acta*, Vol. 1685, No. 1-3 (Oct), pp. 14-21, ISSN 0304-4165.
- Vanier MT. & Suzuki K. (1998) Recent advances in elucidating Niemann-Pick C disease. *Brain Pathology*, Vol 8, No. 1 (Jan), pp. 63-74, ISSN 1015-6305.
- Vanier MT. (2010) Niemann-Pick disease type C. *Orphanet Journal of Rare Diseases*, Vol. 5, 16 (Jun), ISSN 1750-1172.

- Vanier MT., & Suzuki K. (1998) Recent advances in elucidating Niemann-Pick C disease. *Brain Pathology*, Vol. 8, No. 1 (Jan), pp. 163-74, ISSN 1015-6305.
- Vanier MT., Duthel S., Rodriguez-Lafrasse C., Pentchev P., & Carstea ED. (1996) Genetic heterogeneity in Niemann-Pick C disease: a study using somatic cell hybridization and linkage analysis. *The American Journal of Human Genetics*, Vol. 58, No. 1 (Jan), pp. 118-25, ISSN 0002-9297.
- Vantaggiato C., Redaelli F., Falcone S., Perrotta C., Tonelli A., Bondioni S., Morbin M., Riva D., Saletti V., Bonaglia MC., Giorda R., Bresolin N., Clementi E. & Bassi MT. (2009) A novel CLN8 mutation in late-infantile-onset neuronal ceroid lipofuscinosis (LINCL) reveals aspects of CLN8 neurobiological function. *Human Mutation*, Vol. 30, No. 7 (Jul), pp. 1104-16, ISSN 1059-7794.
- Verkruyse LA. & Hofmann SL. (1996) Lysosomal targeting of palmitoyl-protein thioesterase. *Journal of Biological Chemistry*, Vol. 271, No. 26 (Jun), pp. 15831-6, ISSN 0021-9258.
- Vesa J., Chin MH., Oelgeschläger K., Isosomppi J., DellAngelica EC., Jalanko A. & Peltonen L. (2002) Neuronal ceroid lipofuscinoses are connected at molecular level: interaction of CLN5 protein with CLN2 and CLN3. *Molecular Biology of the Cell*, Vol. 13, No.7 (Jul), pp. 2410-20, ISSN 1059-1524.
- Vesa J., Hellsten E., Verkruyse LA., Camp LA., Rapola J., Santavuori P., Hofmann SL. & Peltonen L. (1995) Mutations in the palmitoyl protein thioesterase gene causing infantile neuronal ceroid lipofuscinosis. *Nature*, Vol. 376, No. 6541 (Aug), pp. 584-7, ISSN 0028-0836.
- Wang D., Bonten EJ., Yogalingam G., Mann L. & d'Azzo A. (2005) Short-term, high dose enzyme replacement therapy in sialidosis mice. *Molecular Genetics and Metabolism*, Vol. 85, No. 3 (Jul), pp. 181-9, ISSN 1096-7192.
- Wang SZ., Cachón-González MB., Stein PE., Lachmann RH., Corry PC., Wraith JE. & Cox TM. (2008) A novel HEXB mutation and its structural effects in juvenile Sandhoff disease. *Molecular Genetics and Metabolism*, Vol. 95, No. 4 (Dec), pp. 236-8, ISSN 1096-7192.
- Watari H., Blanchette-Mackie EJ., Dwyer NK., Watari M., Neufeld EB., Patel S., Pentchev PG. & Strauss JF 3rd. (1999) Mutations in the leucine zipper motif and sterol-sensing domain inactivate the Niemann-Pick C1 glycoprotein. *Journal of Biological Chemistry*, Vol. 274, No 31 (Jul), pp. 21861-6, ISSN 0021-9258.
- Weleber RG., Gupta N., Trzupek KM., Wepner MS., Kurz DE. & Milam AH. (2004) Electroretinographic and clinicopathologic correlations of retinal dysfunction in infantile neuronal ceroid lipofuscinosis (infantile Batten disease). *Molecular Genetics and Metabolism*, Vol. 83, No. 1-2 (Sep-Oct), pp. 128-37, ISSN 1096-7192.
- Wheeler RB., Sharp JD., Schultz RA., Joslin JM., Williams RE. & Mole SE. (2002) The gene mutated in variant late-infantile neuronal ceroid lipofuscinosis (CLN6) and in *nclf* mutant mice encodes a novel predicted transmembrane protein. *The American Journal of Human Genetics*, Vol. 70, No. 2 (Feb), pp. 537-42, ISSN 0002-9297.
- Williams RE., Aberg L., Autti T., Goebel HH., Kohlschütter A. & Lönnqvist T. (2006) Diagnosis of the neuronal ceroid lipofuscinoses: an update. *Biochimica et Biophysica Acta*, Vol. 1762, No. 10 (Oct), pp. 865-72, ISSN 0304-4165.
- Winter E. & Ponting CP. (2002). TRAM, LAG1 and CLN8: members of a novel family of lipid-sensing domains? *Trends Biochemical Science*, Vol. 27, No. 8, (Aug), pp. 381-3, ISSN 0968-0004.

- Winter RM., Swallow DM., Baraitser M. & Purkiss P. (1980) Sialidosis type 2 (acid neuraminidase deficiency): clinical and biochemical features of a further case. *Clinical Genetics*, Vol. 18, No. 3 (Sep), pp. :203-10, ISSN 0009-9163.
- Wisniewski KE., Kida E., Golabek AA., Kaczmarek W., Connell F. & Zhong N. (2001) Neuronal ceroid lipofuscinoses: classification and diagnosis. *Advances in Genetics*, Vol. 45, pp. 1-34, ISSN 0065-2660.
- Wraith JE., Baumgartner MR., Bembi B., Covanis A., Levade T., Mengel E., Pineda M., Sedel F., Topçu M., Vanier MT., Widner H., Wijburg FA. & Patterson MC. (2009) Recommendations on the diagnosis and management of Niemann-Pick disease type C. *Molecular Genetics and Metabolism*, Vol. 98, No. 1 (Sep-Oct), pp. 152-65, ISSN 1096-7192.
- Yamamoto Y., & Nishimura K. (1987) Copurification and separation of beta-galactosidase and sialidase from porcine testis. *International Journal of Biochemistry*, Vol. 19, No. 5, pp. 435-42, ISSN 0020-711X.
- Yerushalmi B., Sokol RJ., Narkewicz MR., Smith D., Ashmead JW. & Wenger DA. (2002) Niemann-pick disease type C in neonatal cholestasis at a North American Center. *Journal of Pediatric Gastroenterology and Nutrition*, Vol. 35, No. 1 (Jul), pp. 44-50, ISSN 1536-4801.
- Yüksel A., Yalçinkaya C., Işlak C., Gündüz E. & Seven M. (1999) Neuroimaging findings of four patients with Sandhoff disease. *Pediatric Neurology*, Vol. 21, No. 2 (Aug), pp. 562-5, ISSN 0887-8994.
- Zelnik N., Mahajna M., Iancu TC., Sharony R. & Zeigler M. (2007) A novel mutation of the CLN8 gene: is there a Mediterranean phenotype? *Pediatric Neurology*, Vol. 36, No. 3 (Jun), pp. 411-3, ISSN 0887-8994.
- Zervas M., Dobrenis K., & Walkley SU. (2001) Neurons in Niemann-Pick disease type C accumulate gangliosides as well as unesterified cholesterol and undergo dendritic and axonal alterations. *Journal of Neuropathology & Experimental Neurology*, Vol. 60, No. 1 (Jan), pp 49-64, ISSN 0022-3069.
- Zhong N., Moroziewicz DN., Ju W., Jurkiewicz A., Johnston L., Wisniewski KE. & Brown WT. (2000) Heterogeneity of late-infantile neuronal ceroid lipofuscinosis. *Genetics in Medicine*, Vol. 2, No. 6 (Nov-Dec), pp. 312-8, ISSN 1098-3600.
- Zimran A., Gelbart T., Garver P., Thurston D., Saven A., & Beutler E. (1992) Gaucher disease. Clinical, laboratory, radiologic, and genetic features of 53 patients. *Medicine (Baltimore)*, Vol. 71, No. 6 (Nov.), pp. 337-53, ISSN 0025-7974.



Novel Aspects on Epilepsy

Edited by Prof. Humberto Foyaca-Sibat

ISBN 978-953-307-678-2

Hard cover, 338 pages

Publisher InTech

Published online 12, October, 2011

Published in print edition October, 2011

This book covers novel aspects of epilepsy without ignoring its foundation and therefore, apart from the classic issues that cannot be missing in any book about epilepsy, we introduced novel aspects related with epilepsy and neurocysticercosis as a leading cause of epilepsy in developing countries. We are looking forward with confidence and pride in the vital role that this book has to play for a new vision and mission. Therefore, we introduce novel aspects of epilepsy related to its impact on reproductive functions, oral health and epilepsy secondary to tuberous sclerosis, mitochondrial disorders and lisosomal storage disorders.

How to reference

In order to correctly reference this scholarly work, feel free to copy and paste the following:

Andrea Dardis and Bruno Bembi (2011). Myoclonic Epilepsy in Lysosomal Storage Disorders, Novel Aspects on Epilepsy, Prof. Humberto Foyaca-Sibat (Ed.), ISBN: 978-953-307-678-2, InTech, Available from: <http://www.intechopen.com/books/novel-aspects-on-epilepsy/myoclonic-epilepsy-in-lysosomal-storage-disorders>

INTECH
open science | open minds

InTech Europe

University Campus STeP Ri
Slavka Krautzeka 83/A
51000 Rijeka, Croatia
Phone: +385 (51) 770 447
Fax: +385 (51) 686 166
www.intechopen.com

InTech China

Unit 405, Office Block, Hotel Equatorial Shanghai
No.65, Yan An Road (West), Shanghai, 200040, China
中国上海市延安西路65号上海国际贵都大饭店办公楼405单元
Phone: +86-21-62489820
Fax: +86-21-62489821

© 2011 The Author(s). Licensee IntechOpen. This is an open access article distributed under the terms of the [Creative Commons Attribution 3.0 License](#), which permits unrestricted use, distribution, and reproduction in any medium, provided the original work is properly cited.

IntechOpen

IntechOpen