

We are IntechOpen, the world's leading publisher of Open Access books Built by scientists, for scientists

4,800

Open access books available

122,000

International authors and editors

135M

Downloads

Our authors are among the

154

Countries delivered to

TOP 1%

most cited scientists

12.2%

Contributors from top 500 universities



WEB OF SCIENCE™

Selection of our books indexed in the Book Citation Index
in Web of Science™ Core Collection (BKCI)

Interested in publishing with us?
Contact book.department@intechopen.com

Numbers displayed above are based on latest data collected.

For more information visit www.intechopen.com



Tuberous Sclerosis Complex

Teguh Haryo Sasongko¹, Nik Mohd Ariff Nik Abdul Malik¹,
Nur Farrah Dila Ismail¹ and Salmi Abd. Razak²

¹Human Genome Center and

²Department of Pediatrics, School of Medical Sciences,
Universiti Sains Malaysia
Malaysia

1. Introduction

TSC (OMIM#191100) is an autosomal dominant disorder characterized by a broad phenotypic spectrum including epilepsy, mental retardation, skin lesions and tumors in various organs. The broad phenotypic spectrum reflected the development of hamartomas in multiple organs throughout the body (Schwartz et al., 2008). The incidence of TSC has been reported to be 1 in approximately 6000 (Osborne et al., 1991). However, its true incidence is not known because of a number of undiagnosed cases consisting mostly of mildly affected or asymptomatic individuals (Osborne et al., 1991).

Two-thirds of TSC patients have sporadic mutations and only about one-third is familial. The genes in which abnormalities are found are called *TSC1* and *TSC2*. Both genes have been studied by multigenerational linkage analysis (Fryer et al., 1987 and Kandt et al., 1992). *TSC1* is located at position 9q34, and encodes a protein called hamartin, with an mRNA transcript of 8.6 kb containing 23 exons and encompassing 55 kb of DNA (van Slegtenhorst et al., 1997). *TSC2* is located at position 16p13.3, and encodes a protein called tuberin, with an mRNA transcript of 5.5 kb, containing 41 exons and encompassing 40 kb of DNA (Eur TS Consortium, 1993).

2. Clinical diagnosis of tuberous sclerosis complex

There are major and minor clinical features (Table 1) that enable clinicians to clinically diagnose TSC. The clinical diagnosis is made when two major features, or one major and two minor ones, can be shown (Table 2). Sometimes, an antenatal diagnosis can be made based on fetal ultrasound and MRI, which show cardiac and brain lesions (Roach et al., 1998).

Most patients are diagnosed in infancy or early childhood. A **definitive** diagnosis of TSC can be made when two major features or one major feature plus two minor features are demonstrated (Hyman, 2000 and Roach, 1998). Additional diagnostic categories include **probable** TSC when one major feature and one minor feature are present, and **possible** TSC when either one major feature or two or more minor features are present (Hyman, 2000 and Roach, 1998). However, as hamartomas are individually rare in the population without TSC, the presence of hamartomas in two different organ systems is considered by some clinicians to be sufficient for the diagnosis (O'Callaghan, 2000).

MAJOR FEATURES					MINOR FEATURES			
Features	Description	Diagnosis, location	Age of onset	Prevalence	Features	Description	Diagnosis, location	Prevalence
Facial angiofibromas or forehead plaque (Schwartz et al., 2007)	Red to pink papules with a smooth surface, symmetrically distributed over the centropalpebral areas, sparing the upper lips	Histologic (head)	Second to fifth year of life; more prominent with age	74.5%	Multiple, randomly distributed pits in dental enamel (Mennel et al., 2007)	Dental pits are pits in the enamel of the permanent teeth. They occur more frequently in individuals with TSC than in people who do not have TSC.	Direct inspection of the labial surfaces of the incisor and canine teeth	48 - 100%.
Non-traumatic ungula or periungual fibroma (Schwartz et al., 2007)	Skin-colored or reddish nodules seen on the lateral nail groove, nail plate, or along the proximal nail folds; more commonly found on the toes than on the fingers	Histologic (fingers and toes)	Puberty or soon after; more common with age	15.1%	Hamartomatous rectal polyps (Young & Povey, 1998)	These polyps are common and do not cause symptoms. Their distinctive appearance and distribution readily distinguish them from other types of rectal polyp and emphasize their importance as a potentially useful clinical marker of TSC	Histologic (rectum)	78%
Hypomelanotic macules (three or more) (Schwartz et al., 2007)	Leaf-shaped or polygonal white spots, enhanced by Wood's lamp examination; more common on the trunk and buttocks	Histologic (skin)	At birth or infancy Earliest cutaneous lesion appeared	97.2%	Cerebral white matter radial (Xu et al., 1996)	Most lesions are best seen on proton density-weighted images as bright spots.	MRI (brain)	15%
Shagreen patch (connective tissue nevus) (Schwartz et al., 2007)	Slightly elevated patch or plaque, usually found on the dorsal body surfaces, especially the lumbosacral area; its rough surface resembles an orange peel. Represents a connective tissue nevus, sometimes called collagenoma	Histologic (skin)	Rare during infancy, tend to increase in size and number with age	48.1%	Gingival fibromas (Mennel et al., 2007)	These small fibrous nodules of the oral cavity are most commonly evident on the gingiva, especially in the anterior segment of the upper jaw but also on the buccal mucosa and dorsal surface of the tongue.	Oral (gums)	32%
Multiple retinal nodular hamartomas (Xu et al., 1995)	Retinal hamartoma is a common finding in tuberous sclerosis, but the symptomatic changes of this lesion have rarely been described.	Ocular (eyes)	Infancy	9.7%	Non-retinal hamartoma (Mennel et al., 2007)	Hamartomatous formation in other organs than the kidney.	Histologic (Liver, spleen)	
Cortical tuber (Mennel et al., 2007)	Cortical tubers are the most characteristic lesions of tuberous sclerosis at pathologic examination. Varying in size from millimeters to several centimeters, tubers are rounded or wart-like protrusions of single or adjacent gyri, very firm to touch and pale in color	MRI (brain)	During fetus development	95%	Retinal achromic patch (Mennel et al., 2007)	Greyish or yellowish-white lesion in the back of the globe on the ophthalmic examination. A differential diagnosis for a calcified globe mass on a CT scan.	CT Scan (eyes)	12%

MAJOR FEATURES					MINOR FEATURES			
Features	Description	Diagnosis, location	Age of onset	Prevalence	Features	Description	Diagnosis, location	Prevalence
Subependymal nodule (Mennel et al., 2007)	Occur in the third and fourth ventricular walls, but most are found in the lateral ventricular walls, near the sulcus terminalis, with their deeper parts embedded in the caudate or thalamus.	MRI (brain)	Increases with the age of the patient	95%	Confetti-like skin lesions (Mennel et al., 2007)	Multiple, 1-2 mm white spots symmetrically distributed over extremities	Histologic (skin)	2.8%
SEGA (Mennel et al., 2007) (SEGAs)	This type of tumor develops in approximately 15% of individuals with tuberous sclerosis. Typically, SEGAs do not occur in very young children, and the chance for their growth decreases after age 20.	Radio-graphy (brain)	Child to adolescent	15%	Multiple renal cysts (Inoue, 1998)	Like AMLs, they are frequently multiple and bilateral. However, renal cysts are more likely to become symptomatic than AMLs. Polycystic kidney disease may also occur. It is a more severe, distinct entity with innumerable cysts that enlarge, replace renal parenchyma, and cause renal insufficiency and hypertension typically at an early age	Histologic (kidney)	17% (children) 47% (adults)
Cardiac rhabdomyoma, single or multiple	Rhabdomyomas are benign tumors of striated muscle	Echocardiography	Grow during the second half of pregnancy and regress after birth	90% (newborn) 20% (adult)				
Lymphangiomyomatosis (Schwartz et al., 2007)	Rare lung disease that results in a proliferation of disorderly smooth muscle growth (leiomyoma) throughout the bronchioles, alveolar septa, perivascular spaces, and lymphatics	Histologic (lung)	Adolescent to adult	49%				
Renal angiomyolipoma (Schwartz et al., 2007)	Renal angiomyolipoma is a benign neoplasm that may grow massive in TSC patients.	Histologic (kidneys)	Adolescent to adult	80%				

Table 1. Major and Minor Features of Tuberous Sclerosis Complex.

Clinical Diagnosis	Characteristic
Definite TSC	Either two major features or one major plus two minor features
Probable TSC	One major plus one minor features
Possible TSC	Either one major features or two or more minor features

Table 2. Clinical Diagnosis of TSC. There are several differential diagnosis of TSC :

- a. Multiple Endocrine Neoplasia type I (MEN-I) in which multiple angiofibromas, confetti-like hypopigmented macules, and multiple gingival papules are also seen.
- b. Hypopigmented macules in TSC resemble nevus anemicus and nevus depigmentosus.
- c. Renal Carcinoma may also be caused by mutations within VHL (cause VHL disease) or MET (cause HPRC) genes, although with different pathologic findings. The renal cell carcinomas in TSC are morphologically heterogenous, including clear cell, papillary, and chromophobic tumors. VHL patients almost exclusively develop clear cell carcinoma, while HPRC patients develop almost exclusively papillary tumors.

3. Epilepsy in tuberous sclerosis complex

Epilepsy was once included in tuberous sclerosis triad along with mental retardation and adenoma sebaceum (Provenzale, 1991). Although removed from the diagnostic criteria, epilepsy remains a dominant feature in tuberous sclerosis, covering up to 60% - 90% of TSC cases. Genetic factors play important contributions in the manifestation of epilepsy in TSC. It has recently been described that inactivation of *TSC2* causes more severe epilepsy phenotype than inactivation of *TSC1* in a mouse model of tuberous sclerosis and suggested that the difference in phenotype may be related to the degree to which *TSC1* and *TSC2* inactivation causes abnormal mTOR activation (Zheng, 2010).

Based on clinical features alone, TSC patients may experience a wide variety of ictal symptoms. Two syndromes are usually noted: infantile spasms (Christophea et al., 2000), which then evolve into partial or mixed epilepsies (Dabora et al., 2001) and partial seizures, typically starting later in childhood. The high incidence of infantile spasms in TSC has long been emphasized. Infantile spasms have been reported to be the presenting symptoms in up to 69% of patients with TSC. Infantile spasms in TSC usually have their onset between 4 to 6 months of age (Curatolo et al., 2001 and Fukushima et al 2001). TSC has been found in 7%-25% of infants with symptomatic West syndrome. West syndrome classically consists of the clinical-electroencephalographic triad of spasms (the seizure type), hypsarrhythmia and mental deficiencies. The main types of spasms (flexor, extensor, mixed) may occur in infant with TSC, but focal features such as head turning, nystagmus, tonic eye deviation or unilateral limb movement differentiate them from classical infantile spasms. Partial seizures predominate with the increasing age (Curatolo, 2001 and Jambaque et al., 1991).

Location of tubers on MRI often correlates with EEG discharges. Tubers consist of dysplastic neurons and glial cells that distort the normal cortical architecture, causing them to be highly epileptogenic (Christopher et al., 2000). Jambaque and colleagues found that an initial presentation with infantile spasms, refractory seizures and mental retardation or behaviour

disorder were all more likely in children with greater numbers of cortical tubers. The classic interictal EEG pattern of patients with epileptic spasm is hypsarrhythmia. Hypsarrhythmia was originally defined by Gibbs and Gibbs in 1950 as completely chaotic and disorganized background pattern consisting of high amplitude slow waves and spikes that are asynchronous, non-rhythmic and variable in duration and topography. The spikes usually alternate randomly between focal, multifocal and generalized discharges at different moments within a brief record. It is most pronounced in slow-wave sleep. Ictal recordings of spasms can demonstrate a focal increase in spikes and polyspikes at the onset, with an abrupt generalized slow followed by electro decrement or generalized lower amplitude fast activity coincident with the spasm itself. Curatolo has theorized the following sequence of events. Electrographic onset of spasms is more common from the posterior temporal and occipital regions than from other locations. Subsequent partial seizures tend to arise from the frontal or anterior temporal regions.

Drug selection should be tailored to both clinical and EEG attributes observed. Antiepileptic drug monotherapy is used whenever possible. Vigabatrin may be especially effective for infantile spasms in patients with TSC, with some series reporting complete control occurring in about 95% of patients (Aicardi, 1996 and Hancock, 1999). Vigabatrin produces its antiepileptic effect by irreversibly inhibiting the enzyme GABA-aminotransferase. This results in increased brain and spinal fluid concentration of the inhibitory neurotransmitter GABA. Unfortunately, recent reports of visual-field constriction associated with vigabatrin therapy may limit its use and may prevent from becoming an approved treatment in United States and other countries (Krauss et al., 1998). Other evidence from randomized controlled studies includes using ACTH and corticosteroids for infantile spasms. Chronic use of benzodiazepines and barbiturates should be avoided if possible owing to their cognitive and behavioural adverse effects. Other medications useful to treat seizures in TSC include lamotrigine, felbamate, topiramate, carbamazepine and levetiracetam. When anticonvulsant options have been exhausted, alternative treatment such as ketogenic diet may be tried. If severely disabling seizures are present with consistent electroclinical and imaging data suggesting a confined area of seizure onset, surgical treatment should be considered. The most common surgical procedures offered to TSC patient include topectomies, gyrectomies or wider lobar resection as well as multiple subpial transection. Vagal nerve stimulation is a surgical option restricted to TSC patients with intractable epilepsy who fail to meet the criteria for resective surgery.

4. Molecular diagnosis of tuberous sclerosis complex

Despite the comprehensive criteria for clinical diagnosis of TSC, molecular analyses of both causing genes remain of importance. Mutation analysis in TSC patients is useful 1) to confirm a clinical diagnosis of TSC, especially in young patients in whom many clinical features have yet to develop, 2) in families with sporadic cases of TSC, mutation analysis may provide reassurance that the rest of the family members do not carry the mutation. However, such testing does not provide complete reassurance in regard to the possibility of having the second child with TSC, even when the parents do not appear to carry the mutation, and 3) to perform prenatal diagnosis, in families with either a child or a parent with a known mutation.

5. *TSC1* and *TSC2* genes variation spectrum

Table 3 and 4 summarized updates on the variation spectrum within *TSC1* and *TSC2* and review their characteristics. The information was accessed from the LOVD for Tuberous Sclerosis (<http://chromium.liacs.nl/LOVD2/TSC/home.php>) on 3 April 2011 (Fokkema et al, 2005). There are 468 unique *TSC1* sequence variations and 1222 unique *TSC2* sequence variations reported. Tables 1 and 2 listed up all unique sequence variations of *TSC1* and *TSC2* respectively, along with their variation types and information of pathogenicity.

Types Pathogenicity (R/C)*	Types					Total
	Substitution	Insertion	Deletion	Duplication	Insertion / Deletion	
-/-	12	Nil	Nil	1	Nil	13
-/-?	Nil	1	2	1	Nil	4
-/?	1	Nil	Nil	Nil	Nil	1
-/+?	1	Nil	Nil	Nil	Nil	1
-?/-	1	Nil	Nil	Nil	Nil	1
-?/-?	9	Nil	Nil	Nil	Nil	9
-?/?	6	Nil	Nil	Nil	Nil	6
-?/+?	1	Nil	Nil	Nil	Nil	1
?/-	5	Nil	Nil	Nil	Nil	5
?/-?	5	Nil	Nil	Nil	Nil	5
?/?	23	Nil	Nil	Nil	Nil	23
?/+?	2	Nil	1	Nil	Nil	3
?/+	Nil	Nil	Nil	1	Nil	1
+?/?	5	Nil	2	Nil	Nil	7
+?/+?	4	Nil	Nil	Nil	Nil	4
+?/+	2	Nil	Nil	1	Nil	3
+/-	4	Nil	Nil	Nil	Nil	4
+/?	3	1	3	Nil	1	8
+/+?	16	Nil	7	2	Nil	25
+/+	133	12	146	51	2	344
Total	233	14	161	57	3	468

*R/C = Reported/Concluded. "Reported Pathogenicity" refers to the pathogenicity as published by the authors in the original paper or as submitted to the LOVD-TSC database if the data has not been published. "Concluded Pathogenicity" refers to the pathogenicity that the curators of the database have assigned to the variant. (Personal Communication with the LOVD-TSC Database Curator; Dr. Rosemary Ekong). "-" = no known pathogenicity; "-?" = probably no pathogenicity; "+" = pathogenic; "+?" = probably pathogenic; "??" = unknown pathogenicity.

Table 3. *TSC1* sequence variations and their pathogenicity.

Types Pathogenicity (R/C)*	Types					Total
	Substitution	Insertion	Deletion	Duplication	Insertion / Deletion	
-/-	154	2	8	6	1	171
-/-?	42	1	2	2	Nil	47
-/?	96	Nil	Nil	Nil	Nil	96
-/+?	1	Nil	Nil	Nil	Nil	1
-?/-	7	Nil	Nil	Nil	Nil	7
-?/?	14	Nil	Nil	Nil	Nil	14
-?/?	1	Nil	Nil	Nil	Nil	1
?/-	5	Nil	1	Nil	Nil	6
?/?	17	Nil	1	Nil	Nil	18
?/?	46	1	5	3	1	56
?/+?	13	Nil	1	Nil	Nil	14
?/+	13	Nil	4	2	Nil	19
+?/?	15	1	1	1	1	19
+?/+?	19	1	6	Nil	Nil	26
+?/+	1	1	5	1	1	9
+/-	6	Nil	2	Nil	Nil	8
+/?	22	Nil	5	3	Nil	30
+/+?	60	2	16	3	7	88
+/+	303	33	148	103	Nil	587
-/+	1	Nil	1	Nil	Nil	2
+?/-	1	Nil	Nil	Nil	Nil	1
+?/?	1	Nil	Nil	Nil	Nil	1
+/?	1	Nil	Nil	Nil	Nil	1
Total	839	42	206	124	11	1222

*R/C = Reported/Concluded. "Reported Pathogenicity" refers to the pathogenicity as published by the authors in the original paper or as submitted to the LOVD-TSC database if the data has not been published. "Concluded Pathogenicity" refers to the pathogenicity that the curators of the database have assigned to the variant. (Personal Communication with the LOVD-TSC Database Curator; Dr. Rosemary Ekong). "-" = no known pathogenicity; "-?" = probably no pathogenicity; "+" = pathogenic; "+?" = probably pathogenic; "?" = unknown pathogenicity.

Table 4. *TSC2* sequence variations and their pathogenicity.

In *TSC1*, the most prevalent types of variations found are substitution (49.8%) followed by deletion (34.4%). Of 468 unique variations reported in *TSC1*, 73.5% (344) had their pathogenicity determined. In *TSC2*, the most prevalent types of variations found are also substitution (68.7%) followed by deletion (16.9%). Of 1222 unique variations reported in *TSC2*, only less than half (48%) had their pathogenicity determined. Different gene sizes of *TSC1* and *TSC2* may explain the fact that more variations occurred in *TSC2* than in *TSC1*.

Perhaps because of more chances of the variations to occur along considerable length of intronic portions within *TSC2*, less pathogenicity variations can be conclusively determined. The tables showed that of 1690 *TSC1* and *TSC2* variations reported, only 27.7% (468) were found in *TSC1*. There are some explanations for the fact that up to date more *TSC2* variations were found compared to *TSC1*:

- a. According to Knudson's hypothesis, loss of heterozygosity (LOH) of a tumor suppressor gene is necessary for tumor progression. Recent investigations of somatic mutations in a variety of TSC hamartomas support classification of the TSC genes as tumor suppressor genes. Loss of Heterozygosity (LOH) in *TSC1* hamartomas are rare compared to that in *TSC2* hamartomas (Cheadle et al., 2000). This may reflect the low frequency of *TSC1* diseases.
- b. Several large studies reported that *TSC1* mutations are presented with less severe phenotype than *TSC2* mutations. In 1991, Osborne and colleagues outlined that although TSC incidence is reported as 1 in approximately 6000, the true incidence of TSC is not known because of a number of undiagnosed cases consisting mostly of mildly affected or asymptomatic individuals. It is probable that this portion of patients harbored *TSC1* mutations, accounting for the small number of *TSC1* mutations found until today.
- c. *TSC2* coding region is about 1.5 times longer than *TSC1* and has approximately twice the number of splice sites, affording a proportionally increased opportunity for all manner of small mutations.

6. Molecular pathogenesis of TSC

Up to 85% of TSC cases are due to mutations in either *TSC1* or *TSC2* genes which lead to a truncated protein with a loss of function mechanism. Investigation of somatic mutations in a variety of TSC hamartomas supports classification of the *TSC1* and *TSC2* as tumor suppressor genes (Cheadle et al., 2000). Mutations in *TSC1* and *TSC2* affect neuronal proliferation, differentiation, and migration (Crino et al., 1999). The identification of the *TSC1* and *TSC2* genes and their encoded proteins, hamartin and tuberlin respectively, has aided in understanding the molecular pathogenesis of TSC where hamartomatous formation is the outcome.

Both hamartin and tuberlin are widely expressed in normal tissues including brain, liver, and kidney. Hamartin is highly expressed in G0-arrested cells and throughout the ongoing cell cycle (Crino, 2004). Alterations in tuberlin expression have been reported in patients with TSC. Immunoreactivity of tuberlin is reduced in the brain with TSC. Loss of hamartin and tuberlin formation due to *TSC1* and *TSC2* mutations can enhance proliferation of neural and astrocytic precursor cells and increased in cell size characteristic of dysplastic neurons and giant cells. When either of the *TSC1* or *TSC2* genes is inactivated, G1 is shortened and tissues become hypertropic (Potter et al., 2001). Over-expression of either hamartin or tuberlin can lengthen G1 and inhibits cell proliferation (Tapon et al., 2001).

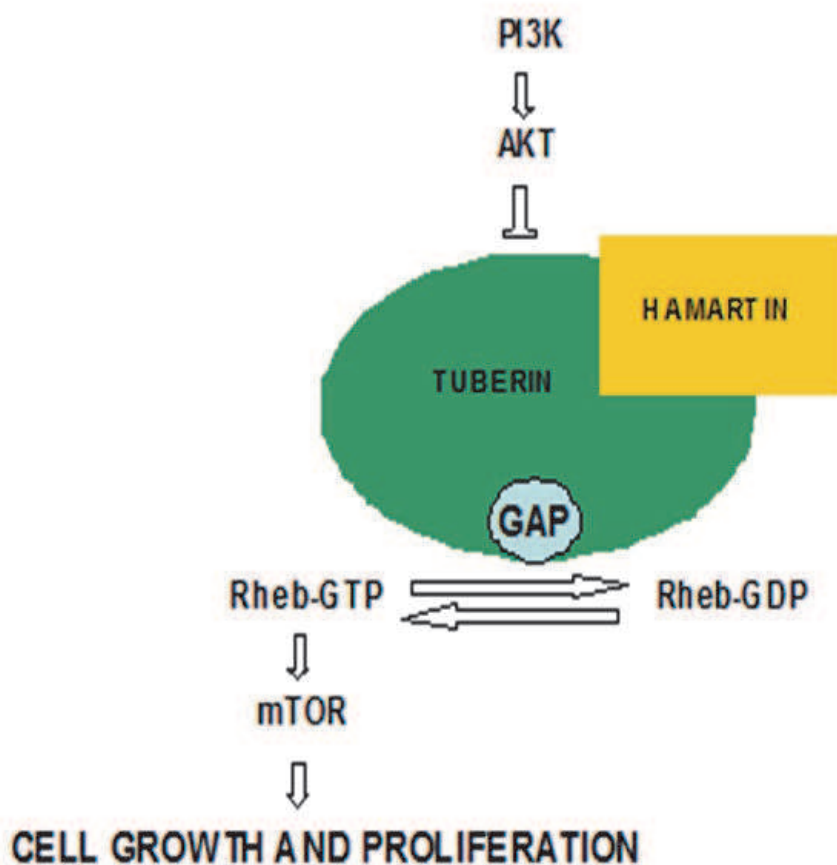
Many studies indicated that hamartin and tuberlin, encoded by *TSC1* and *TSC2* genes respectively, function as a complex. The complex has a stable interaction with stoichiometry of 1:1. The tight binding interaction between the two proteins formed a tumour suppressor heterodimer (Kwiatkowiak, 2008). Hamartin and tuberlin have been found to physically associate with one another in vivo. Disruption in either one of the two genes may result in a truncated protein with the loss in controlling the cell growth and proliferation. The 130 kDa hamartin contains a putative transmembrane domain. Hamartin's membrane bound protein

and two coiled-coil domains are necessary for its association with tuberin (van Slegtenhorst et al., 1997 and van Slegtenhorst et al., 1998).

Although *TSC1*- or *TSC2*-specific functions are possible, it seems that the predominant biochemical activity of these proteins is exerted by an equimolar complex, which regulates the state of GTP-loading of the rheb GTPase, and thereby regulates mTOR activation in the cell. As most hamartomas in TSC develop through a two-hit inactivation mechanisms (Knudson's hypothesis for tumor suppressor genes, including *TSC1* and *TSC2*), it appears likely that somatic mutations in *TSC1* are less common than those in *TSC2*, just as the rate of germline mutation in *TSC1* is much lower than that in *TSC2*. Thus, fewer and/or less severe clinical manifestations would be seen in *TSC1* patients.

LOH is very common within TSC hamartomas, except for cardiac or brain. In both organs, study says that wildtype hamartin and tuberin are present. LOH is an event by which within the affected cells, the genomic DNA loss its heterozygosity, becoming homozygous for the mutation. In other cells (unaffected cells) the genomic DNA shows heterozygous for the mutation. To analyze the occurrence of LOH it is necessary to perform mutation analysis on the genomic DNA extracted from the affected cells as well as from the unaffected cells.

After the discovery of *TSC1* and *TSC2* and their encoded proteins, several downstream protein cascades that might be affected by the pathogenesis of the disease, such as the pathway of mTOR (mammalian target of rapamycin), were identified.



Tee A.R. et al. 2003. *Curr Biol* 13:1259-68

Fig. 1. Hamartin and tuberin as tumor suppressor gene.

Figure 1 illustrated the roles of hamartin and tuberlin in cell metabolism describing that disruption in either of both genes may result in loss of the control of cell growth and proliferation. Hamartin-tuberlin complex inhibits the mTOR which is a key regulator in the signalling pathway of cell proliferation and organ size (Kwiatkowski, 2008). It has been reported that the complex regulates mTOR via hydrolysis of Rheb-GTP into its inactive GDP bound state, Rheb-GDP (Rosner et al., 2004 and Tee et al., 2003).

Tuberlin and hamartin form an intracellular complex which activates GTPase, reducing stimulation of mTOR. mTOR detects signals of nutrient availability, hypoxia, or growth factor stimulation, and is part of many cell processes, such as cell-cycle progression, transcription and translation control, and nutrient uptake. It phosphorylates, among other proteins, S6K1 and eukaryotic translation initiation factor 4E-BP1. S6K1 is a kinase that activates ribosomal subunit protein S6, leading to ribosome recruitment and protein translation. 4E-BP1 inhibits activity of eukaryotic translation initiation factor 4E (eIF4E) and, when phosphorylated by mTOR, releases eIF4E from its control.

The complex inhibits mTOR by acting as a GAP toward Rheb, which promotes hydrolysis of Rheb-GTP, converting it to an inactive GDP bound state. Without its active GTP bound state, Rheb cannot stimulate mTOR-mediated signalling to downstream components S6K1 and 4E-BP1. The mechanism is reversed with the presence of amino acids which activates Rheb-GEF. RhebGEF converts Rheb-GDP to its active Rheb-GTP and promotes mTOR signalling. Akt inactivates TSC tumor suppressor complex by phosphorylation of *TSC2* (Tee et al., 2003).

Common *TSC2* mutations result in the loss of the GAP domain of tuberlin through C-terminal truncations, whereas some point mutations are clustered within the GAP domain. It is also reported that, an intact GAP domain of tuberlin is crucial for association with hamartin in the formation of tuberlin-hamartin heterodimers. The heterodimers will inhibit Rheb-induced mTOR signalling and can also function as a GAP toward Rheb. Higher proportion of the active GTP bound form of Rheb can likely be found within TSC patients. It is the result of non-functional tuberlin-hamartin heterodimers where the genes failed to encode for a functional protein (van Slegtenhorst et al., 1998).

The 200kDa (1806 amino acids) tuberlin is homologous to the GTPase activating proteins (GAP) rap1GAP and mSpa1 where it contains relatively hydrophobic N-terminal domain and conserved 163 amino acids region close to the C-terminus. Rap1GAP is the member of Ras-related protein and functions in regulation of DNA synthesis and cell-cycle transition. The GAP activity of functional tuberlin can regulate the effects of Rap1 on G to S phase transition during cell division. Thus, it implies that *TSC2* mutations may result in constitutive activation of Rap1 (Wienecke et al., 1996 and Wienecke et al., 1997).

Tuberlin also has been demonstrated to interact with rab5. Rab5 is a cytosolic protein, is an effector for the endosomal small GTPase and therefore involved in endocytic fusion events (Stenmark et al., 1995). Consistently with the finding, tuberlin has also been shown to act as a GTPase activating protein for rab5 and reduce the fluid-phase endocytosis (Xiao et al., 1997).

As for 130 kDa (1164 amino acids) hamartin, it has hydrophilic protein with no significant homology to tuberlin or other known vertebrate protein. Van Slegtenhorst and colleagues have investigated the association between endogenous hamartin and tuberlin and they found out that both proteins play a closely related role (van Slegtenhorst et al., 1998). The methods used in the study suggest that inactivation of hamartin and tuberlin may prevent the formation of a functional protein complex.

Hamartin was recently identified as an interactor with the cytoskeletal proteins, ERM family (Lamb et al., 2000). The function loss can alternatively compromise neural migration via

interaction with ERM or actin binding proteins. It was also shown to activate the GTPase Rho and regulates focal adhesion and stress fiber formation. Hamartin activates the GTPase Rho via the overlapping region of Rho's amino acid and hamartin's tuberin-interaction domain (Lamb et al., 2000). The dysregulation of signalling by the Rho family of GTPase is said to have a critical role in cancer cell migration, invasion, and metastasis (Clark et al., 2000; Evers et al., 2000; Royal et al., 2000 and Schmitz et al., 2000).

It has also been recently shown that the functional complex interact with G2/M cyclin-dependant kinase 1 and its regulatory cyclins. Thus, mutation in either both genes may alter the kinetics of cell divisions (Catania et al., 2001). The functional heteromeric complex of hamartin and tuberin also plays important role in modulating the pathways of insulin receptor-or insulin-like growth factor-mediated signalling. The pathway functions downstream of the cell signalling molecule Akt, also play roles in regulating cell growth and potentially cell size.

7. Studies on therapeutics options for TSC

At present, the management of TSC is symptomatic. Some of TSC manifestations have been subjected to drug therapies but they are still in the developmental stage (Yates et al., 2006). Table 5 summarized several drugs under investigation for their efficacy towards Tuberous Sclerosis Complex.

The discovery of mTOR (mammalian target of rapamycin) pathway upregulation in tuberous-sclerosis-associated tumours presents new possibilities for treatment strategies. A TSC mouse treated with rapamycin, also known as sirolimus, was found to have its learning and memory deficits improved (Ehninger et al., 2008).

Sirolimus is a macrolide antibiotic that acts as an mTOR kinase inhibitor. It is isolated from *Streptomyces hygroscopicus*. Sirolimus and its analogs have been shown to make the dysregulated mTOR pathway return to normal in cells that lack *TSC1* or *TSC2*. Several results from in-vitro or in-vivo animal studies suggest that sirolimus or its analogues might be effective in the treatment of various manifestations of tuberous sclerosis such as skin lesions (Rauktytys et al., 2008), lymphangiomyomatosis (Goncharova et al., 2006 and Bissler et al., 2008), renal angiomyolipomas (Lee et al., 2006; Herry et al., 2007 and Wienecke et al., 2006), renal-cell carcinoma (Robb et al., 2007), subependymal giant-cell astrocytomas (Franz et al., 2006) or even polycystic kidney disease (Weimbs et al., 2006).

However, angiomyolipomas increased in volume after the therapy was discontinued, and some patients taking sirolimus experienced serious adverse events (Bissler et al., 2008; Herry et al., 2007 and Wienecke et al., 2006).

Recently, other classes of drugs have also been found to be possible therapeutic options for TSC. Interferon gamma and interferon alpha interact with mTOR, leading to deactivation of the translational repressor 4E-BP1, which could be beneficial for the treatment of tuberous sclerosis (Kaur et al., 2007). Other classes of drugs ranging from those which can alter amino acids metabolism, inhibit VEGF signalling and inhibit microtubules were also studied. Presence or absence of amino acids is an important regulator of mTOR pathway signalling (Avruch et al., 2006).

For example, L-asparaginase, a hydrolase enzyme and one of the most important agents used in multidrug chemotherapy for the treatment of cancer. It is mainly used to treat human leukemic cells in acute lymphoblastic leukemia. L-asparaginase has been found to

Drug	Mechanism of action	Treatment	Adverse effects	Studies
Sirolimus/ Everolimus	Bind to cytosolic protein FK-binding protein 12 (FKBP12) and inhibits mTOR pathway by directly binding to mTOR complex 1	-Specifically subependymal giant cell astrocytomas in adults and angiomyolipomas in children	Increase risk of nephrotoxicity and opportunistic infections	Raukys et al., 2007; Lee et al., 2006; Lee et al., 2007; Kenerson et al., 2005; Smowleski et al., 2005; Woodrum et al., 2010; Messina et al., 2007
Interferon gamma/ Interferon alpha	Deactivate translational repressor 4E-BP1 and inhibits mTOR pathway	-Mostly patient with angiomyolipomas	Immunosuppression, particularly through neutropenia and certain infections	Lee et al., 2006; Lee et al., 2007; Kenerson et al., 2005
L-Asparaginase/ Asparaginase	4E-BP1 and 4E-BP1	-Mainly lymphoma (Hodgkin lymphoma and acute lymphoblastic leukemia) -Possible treatment for TSC	Can cause allergic and hypersensitivity, possible anaphylaxis	Iiboshi et al., 1999; Woodrum et al., 2010
Sorafenib in combination with rapamycin	Block VEGF-R	Advance renal cell and hepatocellular carcinoma	Possible skin-rash, hand-foot skin reactions, diarrhea and hypertension	Brugarolas et al., 2003; Lee et al., 2009
Sunitinib	Targets VEGF-R and platelet derived growth factor receptor (PDGF-R)	-Metastatic renal cell carcinoma (Motzer et al., 2007) gastrointestinal stromal tumors -Possible treatment for TSC	Generally well-tolerated, manageable and low incidence. Possible fatigue, diarrhea, nausea, hypertension and stomatitis	Motzer et al., 2007; Demetri et al., 2006; Woodrum et al., 2010
Bevacizumab	Can binds to all VEGF isoforms and produce inhibitory effects	-Colon, breast, normal lung cancer and glioblastoma -Possible treatment for TSC	Possible coronary artery disease, peripheral artery disease and hypertension	Yang et al., 2003; Wang et al., 2004; Woodrum et al., 2010

Table 5. Potential drugs under investigations for the therapy of TSC.

reduce the levels of mTOR pathway's target p70 S6 kinase and 4EBP-1 (Iiboshi et al., 1999). The reduction indicates that L-Asparaginase can be a possible therapeutic option for TSC.

VEGF is thought to play important role in the pathogenesis of TSC since tumors associated with TSC are vascular. *TSC2* has also been found to have association with increased levels of VEGF in cultured cells (Brogarolas et al., 2002). Since VEGF signalling is important in the TSC pathogenesis, combination of VEGF inhibitors with mTOR inhibitor analogs may provide a promising treatment.

Sorafenib is one of VEGF inhibitors. It is an oral targeted kinase inhibitor that blocks VEGF-R. In TSC tumor preclinical study by Lee and colleagues, combination of Sorafenib and Sirolimus was found more effective than single agent (Lee et al., 2009). Other VEGF inhibitor is Sunitinib which also inhibit platelet derived VEGF-R. It is a receptor tyrosine kinase inhibitor. Bevacizumab, a recombinant humanised monoclonal antibody, is also a VEGF-R inhibitor. Both Sunitinib and Bevacizumab produce inhibitory effects to VEGF-R signalling pathway and may be useful for TSC treatment.

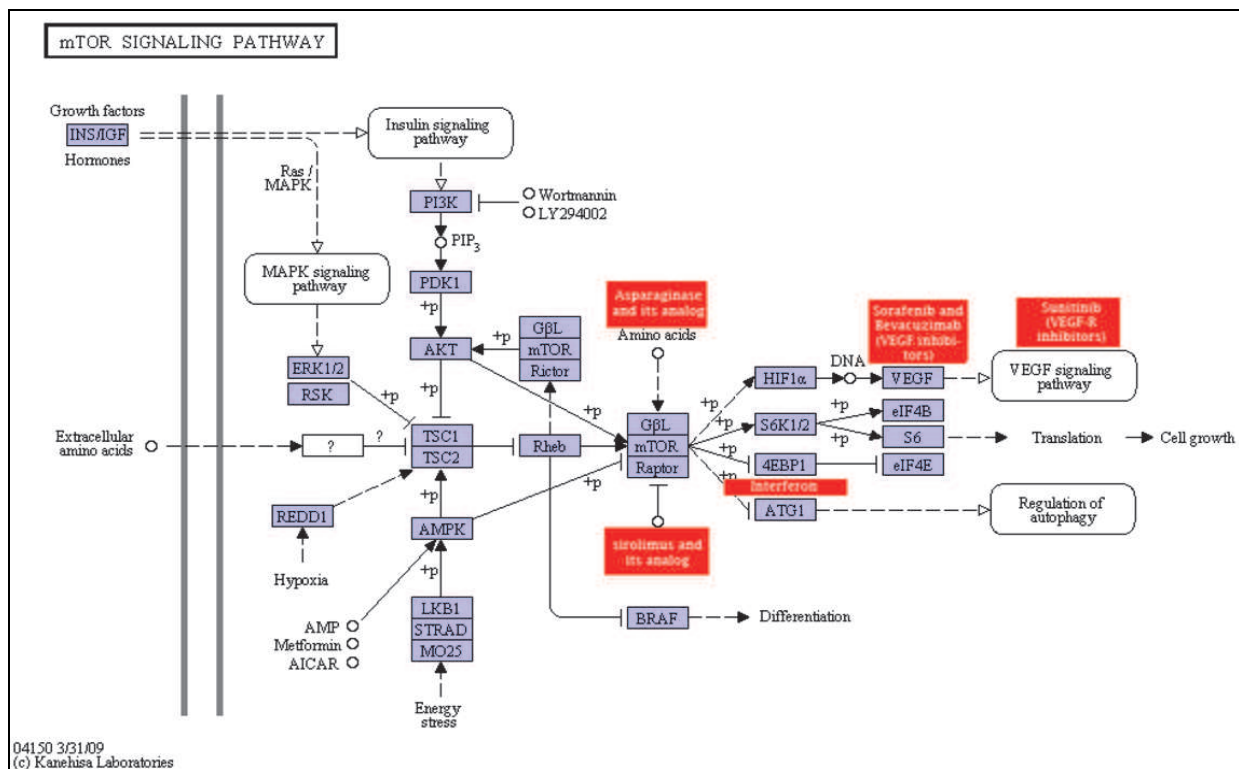


Fig. 2. Interaction of possible therapeutic options with various pathways in TSC pathogenesis (http://www.genome.jp/dbget-bin/www_bget?map04150).

8. Abbreviations

4E-BP1	: 4E Binding Protein 1
ACTH	: adrenocorticotrophic hormone
AML	: angiomyolipoma
DNA	: deoxyribonucleic acid
EEG	: Electroencephalography
ERM	: Exin-radixin-moesin

GABA	: gamma-aminobutyric acid
kb	: kilobase pair
LOH	: Loss of Heterozygosity
LOVD	: Leiden Open Variation Database
MRI	: Magnetic Resonance Imaging
mRNA	: messenger ribonucleic acid
mTOR	: mammalian target of rapamycin
Rheb	: Ras homologue enriched in brain
TSC	: Tuberous Sclerosis Complex
TSC1	: Tuberous Sclerosis Complex gene 1
TSC2	: Tuberous Sclerosis Complex 2
VEGF	: vascular endothelial growth factor
VEGF-R	: vascular endothelial growth factor receptor

9. References


- Aicardi, J., Mumford, J.P., Dumas, C. and Wood, S. (1996). Vigabatrin as initial therapy for infantile spasms: a European Retrospective Survey, *Epilepsia*, 37(7):638-42.
- Avruch, J., Hara, k., Lin, Y., Liu, M., Long, X., Ortiz-Vega, S. & Yonezawa, K. (2006). Insulin and amino-acid regulation of mTOR signalling and kinase activity through the Rheb GTPase, *Oncogene*. 25:6361-72.
- Bissler, J.J., McCormack, F.X., Young, L.R., Elwing, JM., Chuck, G., Leonard, J.M., Schmithorst, V.J., Laor, T., Brody, A.S., Bean, J., Salisbury, S. & Franz, D.N. (2008). Sirolimus for angiomyolipoma in tuberous sclerosis complex or lymphangiomyomatosis, *N Engl J Med*. 358(2):140-51.
- Brugarolas, J.B., Vazquez, F., Reddy, A., Sellers, W.R. & Kaelin, W.G.Jr. (2003). TSC2 regulates VEGF through mTOR-dependent and -independent pathways, *Cancer Cell*. 4(2):147-58.
- Catania MG, Mischel PS and Vinters HV. (2001). Hamartina and tuberlin interaction with the G2/M cyclin-independent kinase CDK1 and its regulatory cyclins A and B, *J Neuropathol Exp Neurol*. 60(7):711-23.
- Catania, M.G., Johnson, M.W., Liau, L.M., Kremen, T.J., deVillis, J.S. & Vinters, H.V. (2001). Hamartin expression and interaction with tuberlin in tumour cell lines and primary cultures, *J Neurosci Res*. 63:276-83.
- Cheadle, J.P., Reeve, M.P., Sampson, J.R. & Kwiatkowski, D.J. (2000). Molecular genetics advances in tuberous sclerosis, *Hum Gen*. 107(2):97-114.
- Christophe, C., SeAkhrab, T., Rypens, F., Zierrisen, F., Chrisriaens, F., & Dan, B. (2000). MRI spectrum of cortical malformations in tuberous sclerosis complex, *Brain & Development* 22. 487±493, 18.
- Christophe, C., Sekhara, T. & Rypens, F. (2000). MRI spectrum of cortical malformations in tuberous sclerosis complex, *Brain Dev*. 22:487 -493.
- Clark, G.J., Kinch, M.S., Rogers-Graham, K., Sebt, S.M., Hamilton, A.D. & Der, C.J. (1997). The RAS-related protein Rheb is farnesylated and antagonizes Ras signalling and transformation, *J Biol Chem*. 272:10608-10715.
- Crino, P.B. & Henske, E.P. (1999). New developments in the neurobiology of the tuberous sclerosis complex, *Neurology*. 53(7):1384-90.
- Crino, P.B. (2004). Molecular pathogenesis of tuber formation in tuberous sclerosis complex, *J Child Journal*. 4:105(3):357-68.

- Curatolo, P. (1996). Neurological manifestation of tuberous sclerosis complex, *Childs Nerv Syst.* 12: 515 – 521
- Curatolo, P. (2001). Infantile spasms in tuberous sclerosis complex, *Brain Dev.* 173:502-507
- Curatolo, P. (2001). Vigabatrin for tuberous sclerosis complex, *Brain dev.* 23:649-653
- Dabora, S.L., Jozwiak, S. & Franz, D.N. (2001). Mutational analysis in a cohort of 224 tuberous sclerosis patients indicates increased severity of *TSC2*, compared with *TSC1*, disease in multiple organs, *Am J Hum Genet.* 68: 64–80.
- Demetri, G.D., van Oosterom, A.T., Garrett, C.R., Blackstein, M.E., Shah, M.H., Verweij, J., McArthur, G., Judson, I.R., Heinrich, M.C., Morgan, J.A., Desai, J., Fletcher, C.D., George, S., Bello, C.L., Huang, X., Baum, C.M. & Casali, P.G. (2006). Efficacy and safety of sunitinib in patients with advanced gastrointestinal stromal tumour after failure of imatinib: a randomised controlled trial, *Lancet.* 368(9544):1329-38.
- Ehninger, D., Han, S., Shilyansky, C., Zhou, Y., Li, W., Kwiatkowski, D.J., Ramesh, V. & Silva, A.J. (2008). Reversal of learning deficits in a *TSC2*+/- mouse model of tuberous sclerosis, *Nat Med.* 14(8):843-8.
- European Chromosome 16 Tuberous Sclerosis Consortium. (1993). Identification and characterization of the tuberous sclerosis gene on chromosome 16, *Cell* 75: 1305–15.
- Evers, E.E., Zondag, G.C., Malliri, A., Price, L.S., ten Klooster, J.P., van der Kemmen, R.A. & Collard, J.G. (2000). Rho family proteins in cell adhesion and cell migration, *Eur J Cancer.* 36(10):1269-74.
- Fokkema, I.F.A.C., Den Dunnen, J.T. & Taschner, P.E.M. (2005). LOVD: easy creation of a locus-specific sequence variation database using an "LSDB-in-a-Box" approach, *Hum Mutat.* 2005 Aug;26(2):63-8.
- Franz, D.N. (1998). Diagnosis and management of tuberous sclerosis complex, *Sem Pediatr Neurol.* 5:253-268
- Franz, D.N., Leonard, J., Tudor, C., Chuck, G., Care, M., Sethuraman, G., Dinopoulos, A., Thomas, G. & Crone, K.R. (2006). Rapamycin causes regression of astrocytomas in tuberous sclerosis complex, *Ann Neurol.* 59:490-498.
- Fryer, A.E., Chalmers, A. & Connor, J.M. (1987). Evidence that the gene for tuberous sclerosis is on chromosome 9, *Lancet* 1: 659–61.
- Fukushima, K., Inoue, Y. & Fujiwara, T. (2001). Long term follow up study on Wst syndrome associated with tuberous sclerosis, *Brain Dev* 23:698-704.
- Goncharova, E.A., Goncharova, D.A., Spait, M., Noonan, D.J., Talovskava, E., Esterhas, A. & Krymskava, V.P. (2006). Abnormal growth of smooth muscle-like cells in lymphangiomyomatosis: Role for tumor suppressor *TSC*, *Am J Respir Cell Mol Biol*, 34(5):561-72.
- Hancock, E., Tomkins, S., Sampson, J. & Osborne, J. (1999). Lymphangiomyomatosis and tuberous sclerosis (original research articles), *Respiratory medicine*, volume 96, issue 1, January 1999, 7-13.
- Herry, I., Neukirch, C., Debray, M.P., Mignon, F. & Crestani, B. (2007). Dramatic effect of sirolimus on renal angiomyolipomas in a patient with tuberous sclerosis complex, *Eur J Intern Med*, 18:76-77.
- Hymann, M. & Whittemore, V. (1996). Tuberous Sclerosis Complex: A Review: Diagnosis, *Clinical Genetics* ;150:36-40.
- Iiboshi, Y., Papst, P.J., Hunger, S.P. & Terada, N. (1999). L-asparaginase inhibits the rapamycin-targeted signalling pathway, *Biochem Biophys Res Commun*, 260(2):534-9.
- Inoue, Y., Nemoto, Y., Murata, R., Tashiro, T., Shakudo, M., Kohne, K. & et al. (1998). CT and MR imaging of Cerebral Tuberous Sclerosis, *Brain & Development*, 209–221 (3).

- Jambaque, I., Cusmai, R. & Curatolo, P. (1991). Neuropsychological aspects of tuberous sclerosis in relation to epilepsy and MRI findings, *Dev Med Child Neurol* 33:398-705.
- Jiang, X. & Yeung, R.S. (2006). Regulation of microtubule-dependant protein transport by the TSC2/mammalian target of rapamycin pathway, *Cancer Res*, 66(10):5258-69.
- Kandt, R.S., Haines, J.L. & Smith, M. (1992). Linkage of an important gene locus for tuberous sclerosis to a chromosome 16 marker for polycystic kidney disease, *Nat Genet* 2: 37-41.
- Kanehisa Laboratory, pathway map04150, mTOR signalling pathway[Online]. [Accessed on 8th March 2011]. Available from GenomeNet: http://www.genome.jp/dbget-bin/www_bget?map04150
- Kaur, S., Lal, L., Sassano, A., Majchrzak-Kita, B., Srikanth, M., Baker, D.P., Petroulakis, E., Hay, N., Sonenberg, N, Fish, E.N. & Plataniias, L.C. (2007). Regulatory effects of mammalian target of rapamycin-activated pathways in type I and type II interferon signalling, *J Biol Chem*, 282(3):1757-68.
- Kenerson, H., Dundon, T.A. & Yeung, R.S. (2005). Effects of rapamycin in the Eker rat model of tuberous sclerosis complex, *Pediatr Res*, 57:67-75.
- Kenerson, H.L., Aicher, L.D. & True L. (2002). Activated mammalian target of rapamycin pathway in the pathogenesis of tuberous sclerosis complex renal tumours, *Cancer Res*, 62:5645-5650.
- Kwiatkowski, D.J. (2003). Tuberous sclerosis: from tubers to mTOR, *Ann Hum Genet* ;67:87-96
- Kwiatkowski, D.J. (2005). TSC1, TSC2, TSC3? Or mosaicism, *Eur J Hum Genet*, 13(6):695-6.
- Lamb, R.F., Roy, C. & Diefenbach, T.J. (2000). The TSC1 tumour suppressor hamartin regulates cell adhesion through ERM proteins and the GTPase Rho, *Nat Cell Biol*, 2:281-287.
- Lee, L., Sudentas, P. & Dabora, S.L. (2006). Combination of a rapamycin analog (CCI-779) and interferon-gamma is more effective than single agents in treating a mouse model of tuberous sclerosis complex, *Gene Chromosome Cancer*, 45:933-944.
- Lee, L., Sudentas, P., Donohue, B., Asrican, K., Worku, A., Walker, V., Sun, Y., Schmidt, K., Albert, M.S., El-Hashemite, N., Lader, A.S., Onda, H., Zhang, H., Kwiatkowski, D.J. & Dabora, S.L. (2005). Efficacy of rapamycin analog (CCI-779) and IFN-gamma in tuberous sclerosis mouse models, *Genes Chromosomes Cancer*, 42:213-227.
- Lee, N., Woodrum, C., Nobil, A., Rauktys, A., Messina, M.P. & Dabora, S.L. (2009). Rapamycin weekly maintenance dosing and the potential efficacy of combination sorafenib plus rapamycin but not atorvastatin or doxyxycline in tuberous sclerosis preclinical models, *BMC Pharmacol*, 9:8.
- McManus, E.J. & Alessi, D.R. (2002). A complex tale of PKB mediated S6K regulation, *Nat Cell Biol*, 4:E214-E216.
- Mennel, S., Meyer, C.H., Peter, S., Schmidt, J.C. & Kroll, P. (2007). Current treatment modalities for exudative retinal hamartomas secondary to tuberous sclerosis: Review of the literature, *Acta Ophthalmol Scand*; 85(2):127-32
- Messina, M.P., Rauktys, A., Lee, L. & Dabora, S.L. (2007). Tuberous sclerosis preclinical studies: timing of treatment, combination of a rapamycin analog (CCI-779) and interferon-gamma, and comparison of rapamycin to CCI-779, *BMC Pharmacol*, 7:14.
- Motzer, R.J., Hutson, T.E., Tomczak, P., Michaelson, M.D., Bukowski, R.M., Rixe, O., Oudard, S., Negrier, S., Szczylik, C., Kim, S.T., Chen, I., Bycott, P.W., Baum, C.M. & Figlin, R.A. (2007). Sunitinib versus interferon alfa in metastatic renal cell carcinoma, *N Engl J Med*, 356(2):154-24.
- O'Callaghan, F. (2000). Tuberous sclerosis complex, *Paediatrics and Child Health*, 18:1.

- Osborne, J.P., Fryer, A. & Webb, D. (1991). Epidemiology of tuberous sclerosis, *Ann N Y Acad Science* ;615:125-7
- Potter, C.J., Huang, H. & Xu, T. (2001). Drosophila *TSC1* functions with *TSC2* to antagonize insulin signalling in regulating cell growth, cell proliferation and organ size, *Cell*, 4:105(3):357-68.
- Provenzale, J. & DeLuca S.A. (1991). Tuberous Sclerosis, *Am Fam Physician* 43:470-2.
- Rauktys, A., Lee, N., Lee, L. & Dabora, S.L. (2008). Topical rapamycin inhibits sclerosis tumor growth in a nude mouse model, *BMC Dermatology*, 8:1 doi:10.1186/1471-5945-8-1.
- Roach, E.S., Gomez, M.R. & Northrup, H. (1998). Tuberous sclerosis complex consensus conference: revised clinical diagnostic criteria, *J Child Neurol* 13: 624-28.
- Rosner, M., Freilinger, A. & Hengstschlager, M. (2004). Proteins interacting with tuberous sclerosis gene products, *Amino Acids*, 27(2):119-28.
- Royal, I., Lamarche-Vane, N., Lamorte, L., Kaibuchi, K. & Park, M. (2000). Activation of *cdc42*, *rac*, *PAK*, and *rho*-kinase in response to hepatocyte growth factor differentially regulates epithelial cell colony spreading and dissociation, *Mol Biol Cell*, 11(5):1709-25.
- Schmitz, A.A., Govek, E.E., Bottner, B. & Aelst, L. (2000). Rho GTPases: signalling , migration and invasion, *Exp Cell Res*, 261(1):1-12.
- Schwartz, R.A., Fernandez, G., Kotulska, K. & Jozwiak, S. (2007). Tuberous Sclerosis Complex. Advances in diagnosis, genetics and managements (Review articles), *Journal of the American Academy of Dermatology*, volume 57, Issue 2, 189-202.
- Smolewski, P. (2006). Recent developments in targeting the mammalian target of rapamycin (mTOR) kinase pathway, *Anticancer Drugs*, 17:487-494.
- Stenmark, H., Vitale, G., Ullrich, P. & Zerial, M. (1995). Rabaptin-5 is a direct effector of the small GTPase Rab5 in endocytic membrane fusion, *Cell*, 83(3):423-32.
- Tapon, N., Ito, N., Dickson, J.B., Treisman, J.E. & Hariharan, I.K. (2001). The drosophila tuberous sclerosis complex gene homologs restrict cell growth and cell proliferation, *Cell*, 105(3):345-55.
- Tee, A.R., Anjum, R. & Blenis, J. (2003). Inactivation of the tuberous sclerosis complex-1 and -2 gene products occurs by phosphoinositide s-kinase/Akt-dependent and - independent phosphorylation of tuberin, *J Biol Chem*, 278(39):37288-96.
- Tee, A.R., Fingar, D.C., Manning, B.D., Kwiatkowski, D.J., Cantley, L.C. & Blenis, J. (2002). Tuberous sclerosis complex-1 and -2 gene products function together to inhibit mammalian target of rapamycin (mTOR)-mediated downstream signalling, *Proc Natl Acad Sci USA* 99, 13572-13576.
- Tee, A.R., Manning, B.D., Roux, P.P., Cantley, L.C. & Blenis, J. (2003). Tuberous sclerosis gene products, *Amino Acids* 27:119-128.
- Tee, A.R., Manning, B.D., Roux, P.P., Cently, L.C. & Blenis, J. (2003). Tuberous sclerosis complex gene products, Tuberin and Hamartin, control mTOR signalling by acting as GTPase activating protein complex toward Rheb, *Curr Biol*, 13(15):1259-68.
- van Slegtenhorst, M., de Hoogt, R. & Herman, C. (1997). Identification of the tuberous sclerosis gene *TSC1* on chromosome 9q34, *Science*, 277:805-808.
- van Slegtenhorst, M., de Hoogt, R., Hermans, C., Nellist, M., Janssen, B., Verhoef, S., Lindhout, D., van den Ouweland, A., Halley, D., Young, J., Burley, M., Jeremiah, S., Woodward, K., Nahmias, J., Fox, M., Ekong, R., Osborne, J., Wolfe, J., Povey, S., Snell, R.G., Cheadle, J.P., Jones, A.C., Tachataki, M., Ravine, D., Sampson, J.R., Reeve, M.P., Richardson, P., Wilmer, F., Munro, C., Hawkins, T.L., Sepp, T., Ali,

- J.B., Ward, S., Green, A.J., Yates, J.R., Kwiatkowska, J., Henske, E.P., Short, M.P., Haines, J.H., Jozwiak, S. & Kwiatkowski, D.J. (1997). Identification of the tuberous sclerosis gene, *TSC1* on chromosome 9q34, *Science*, 277(5327):805-8.
- van Slegtenhorst, M., Nellist, M., Nagelkerken, B., Cheadle, J., Snell, R., van den Ouwland, A., Reuser, A., Sampson, J., Halley, D. & van der Sluijs. (1998). Interaction between hamartin and tuberin, the *TSC1* and *TSC2* gene products, *Hum Mol Genet*, 7(6):1053-7.
- Wang, Y., Fei, D., Vanderlaan, M. & Song, A. (2004). Biological activity of bevacizumab, a humanized anti-VEGF antibody in vitro, *Angiogenesis*, 7(4):335-45.
- Weimbs, T. (2006). Regulation of mTOR by polycystin-1: is polycystic kidney disease a case of futile repair?, *Cell cycle*, 5(21):2425-9.
- Wienecke, R., Fackler, I., Linsenmaier, U., Mayer, K., Licht, T. & Kretzler, M. (2006). Antitumoral activity of rapamycin in renal angiomyolipoma associated with tuberous sclerosis complex, *Am J Kidney Dis*, 48:e27-9.
- Wienecke, R., Maize, J.C.Jr., Reed, J.A., de Gunzburg, J., Yeung, R.S. & DeClue, J.E. (1997). Expression of the *TSC2* product tuberin and its target Rap1 in normal human tissues, *Am J Pathol*, 150(1):43-50.
- Wienecke, R., Maize, J.C.Jr., Shoarinejad, F., Vass, W.C., Reed, J., Bonafacino, J.S., Resau, J.H., de Gunzburg, J., Yeung, R.S. & DeClue, J.E. (1996). Co-localization of the *TSC2* product tuberin with its target Rap1 in the golgi apparatus, *Oncogene*, 13(5):913-23.
- Woodrum, C., Nobil, A. & Dabora SL. (2010). Comparison of three rapamycin dosing schedules in A/J *Tsc2*^{+/-} mice and improved survival with angiogenesis inhibitor or asparaginase treatment in mice with subcutaneous tuberous sclerosis related tumors, *Journal of Translational Medicine*, 8:14.
- Xiao, G.H., Shoarinejad, F., Jin, F., Golemis, E.A. & Yeung, R.S. (1997). The tuberous sclerosis 2 gene product, tuberin, function as a Rab5 GTPase activating protein (GAP) in modulating endocytosis, *J Biol Chem*, 272(10):6097-100.
- Xu, L., Sterner, C., Maheshwar, M.M., Wilson, P.J., Nellist, M., Short, P.M., Haines, J.L., Sampson, J.R. & Ramesh, V. (1995). Alternative splicing of the tuberous sclerosis 2 (*TSC2*) gene in human and mouse tissues, *Genomics* 27:475-480
- Xu, L., Sterner, C., Maheshwar, M.M., Wilson, P.J., Nellist, M., Short, P.M., Haines, J.L., Sampson, J.R. & Ramesh, V. (1995) New insights into the role of the tuberous sclerosis genes in leukemia. *Leukemia Research* 33 (2009) 883-885. Alternative splicing of the tuberous sclerosis 2 (*TSC2*) gene in human and mouse tissues, *Genomics* 27:475-480
- Yang, J.C., Haworth, L., Sherry, R.M., Hwu, P., Schwartzentruber, D.J., Topalian, S.L., Steinberg, S.M., Chen, H.X. & Rosenberg, S.A. (2003). A randomized trial of bevacizumab, an anti-vascular endothelial growth factor antibody, for metastatic renal cancer, *N Engl J Med*, 349(5):427-34.
- Yates, J.R. (2006). Tuberous sclerosis, *Eur J Hum Genet*, 14(10):1065-73.
- Young, J. & Povey, S. (1998). The genetic basis of tuberous sclerosis, *Mol. Med.* 313-319.
- Young, L.R., Inoe, Y. & McCormack, F.X. (2008). Diagnostic potential of serum VEGF-D for lymphangiomyomatosis, *N Engl J Med*, 358(2):199-200.
- Zheng, L.H., Rensing, N.R., Zhang, B., Gutmann, D.H., Gambello, M.J. & Wong, M. (2010). *TSC2* gene inactivation in a mouse model of Tuberous Sclerosis Complex, *Hum Mol Genet; Nov 9 [Epub ahead of print]*, 20(3):445-54.



Novel Aspects on Epilepsy

Edited by Prof. Humberto Foyaca-Sibat

ISBN 978-953-307-678-2

Hard cover, 338 pages

Publisher InTech

Published online 12, October, 2011

Published in print edition October, 2011

This book covers novel aspects of epilepsy without ignoring its foundation and therefore, apart from the classic issues that cannot be missing in any book about epilepsy, we introduced novel aspects related with epilepsy and neurocysticercosis as a leading cause of epilepsy in developing countries. We are looking forward with confidence and pride in the vital role that this book has to play for a new vision and mission. Therefore, we introduce novel aspects of epilepsy related to its impact on reproductive functions, oral health and epilepsy secondary to tuberous sclerosis, mitochondrial disorders and lisosomal storage disorders.

How to reference

In order to correctly reference this scholarly work, feel free to copy and paste the following:

Teguh Haryo Sasongko, Nik Mohd Ariff Nik Abdul Malik, Nur Farrah Dila Ismail and Salmi Abd. Razak (2011). Tuberous Sclerosis Complex, Novel Aspects on Epilepsy, Prof. Humberto Foyaca-Sibat (Ed.), ISBN: 978-953-307-678-2, InTech, Available from: <http://www.intechopen.com/books/novel-aspects-on-epilepsy/tuberous-sclerosis-complex>

INTECH
open science | open minds

InTech Europe

University Campus STeP Ri
Slavka Krautzeka 83/A
51000 Rijeka, Croatia
Phone: +385 (51) 770 447
Fax: +385 (51) 686 166
www.intechopen.com

InTech China

Unit 405, Office Block, Hotel Equatorial Shanghai
No.65, Yan An Road (West), Shanghai, 200040, China
中国上海市延安西路65号上海国际贵都大饭店办公楼405单元
Phone: +86-21-62489820
Fax: +86-21-62489821

© 2011 The Author(s). Licensee IntechOpen. This is an open access article distributed under the terms of the [Creative Commons Attribution 3.0 License](#), which permits unrestricted use, distribution, and reproduction in any medium, provided the original work is properly cited.

IntechOpen

IntechOpen