

# We are IntechOpen, the world's leading publisher of Open Access books Built by scientists, for scientists

**4,800**

Open access books available

**122,000**

International authors and editors

**135M**

Downloads

Our authors are among the

**154**

Countries delivered to

**TOP 1%**

most cited scientists

**12.2%**

Contributors from top 500 universities



**WEB OF SCIENCE™**

Selection of our books indexed in the Book Citation Index  
in Web of Science™ Core Collection (BKCI)

Interested in publishing with us?  
Contact [book.department@intechopen.com](mailto:book.department@intechopen.com)

Numbers displayed above are based on latest data collected.

For more information visit [www.intechopen.com](http://www.intechopen.com)



## Is Neo-Rectum a Better Option for Low Rectal Cancers?

Fazl Q. Parray, Umar Farouqi and Nisar A. Chowdri  
*Department of Surgery, Sher-I-Kashmir Institute of Medical Sciences, Srinagar  
 India*

### 1. Introduction

Distances have been traveled on foot, by boat, carts, bus, car, trains, or by aero planes but what matters ultimately after the travel is "Time & Quality". Same logic applies to surgical treatment. Orthodox surgeons criticize technology, question new procedures and are reluctant to accept new modalities. They may not be wrong but may neither be "right." What they believe in is a typical Cooperian thought.

- "If you are too fond of new remedies, first you will not cure your patients; Secondly, you will have no patients to cure " (A Cooper, 1768-1841) But we believe in guiding the technology rather than vice versa and we should question new procedures till evidence based. We should accept and try evidence based modalities, be technology friendly, or get outdated. Our belief is;
- "If you are not too fond of new remedies you will have no patients to cure"

Colorectal Carcinomas lead to 655,000 deaths per year. It is the third most common form of cancer and second leading cause of cancer-related death. Cancer rectum continues to be a dreadful malignancy. 5 year survival inspite of aggressive modalities has improved only from 50% to 75%.

### 2. Historical aspects

Czerny is credited with abdominoperineal excision for rectal carcinoma in 1884. Krate gave the concept of trans sacral approach for rectal resection in 1885. Sir Ernest Miles the British surgeon in 1908 improved on the concept of abdominoperineal excision (APR) for rectal carcinoma on basis of "Anatomic rectal carcinoma" studies and introduced the concept of "Zone Of Upward Spread" and stressed on Wide Perineal Excision. (Lancet 1908; 2:1812-3)

In recent times pathological studies of Dukes and Westhues demonstrated "Central lymphogenic spreading" in early developing carcinoma rectum hence the era of sphincter preserving procedures started. (Br. J. Surg 1930; 17:643-8, Arch Klin Chir 1930; 161:582-91)

Dixon (Mayo Clinic, 1930) devised low anterior resection (LAR) for treatment of favorable tumors of mid-rectum and it became the procedure of choice and after comparison of results viz-a-viz morbidity, mortality or local recurrence no difference was found by several studies. (Goliger et al Br. J Surg 1951; 39:199-211, Parks AG. Proc R Soc Med 1972; 69:975-6, Goliger JC. Adv Surg 1979; 13:1-31 )

Until 1970s most thought that 5cm distal margin from the tumor is a must for achieving distal tumor free margin but Williams et al(1983) described that distal spread of tumor >2cm in less than 2.5% of excised tumors after extensive pathological & clinical studies of sphincter saving procedures and concluded that a distal margin of 2 cm is safe. (Pollet WG, Nichollas RJ. *Ann Surg* 1963; 198:159-63; Fain SN et al. *Arch Surg* 1975; 110:1079-82)

Studies also confirmed 2cm distal margin did not compromise survival and overall results were similar for LAR vs. APR.

### 3. Treatment modalities

Various surgical treatment modalities which can be offered to the patient with cancer rectum at present are:

- Colostomy / Ileostomy
- APR
- Neoadjuvant to downstage
- Anterior resection; LAR; ultra low anterior resection (ULAR) +/- followed by adjuvant treatment
- Trans anal local resection
- Trans anal endoscopic microsurgery (TEMS )
- Trans sacral resection

In recent times LAR got more popular because it is a sphincter saving procedure and distal resection margin (DRM) needs to be only 2 cms. Use of staplers popularized the procedure because staplers reached more than the hand. The resection is followed by end to side anastomosis or end to end anastomosis .Then came the era of Oncological concern. The embryology predicates that cancer spread will remain within the mesorectum and fascia. This fascia provides the surgeon with a “navigation system” on which the efficient performance of total mesorectal excision (TME) is based.

Oncologically correct surgical treatment for carcinoma middle and lower third of rectum is total mesorectal excision (TME) and it was William Heald who gave this concept based on “Zone Of Downward Spread”. (Quirke P et al. *Lancet* 1986; 2:996-9; Malloy RG et al. *Dis Colon Rectum* 1992; 35:462-4)

But most the new surgical procedures always come with a price and that is what proved exactly true even for LAR; it lead to loss of “rectal reservoir function”. This new entity was named as “Anterior Resection Syndrome” (ARS). It comprises of

- Functional disorders
- Difficulty in postoperative stool evacuation
- High stool frequency
- Decreased continence for gas and liquid
- Increased stool urge, clustering
- Feel of incomplete evacuation

Hence, a complex mixture of anal and neo-rectal dysfunction is common during the phase of adaptation in the first postoperative year.( Predersen IK et al. *Ann Surg* 1986; 204:133-5; Lewis WG et al. *Dis Colon Rectum* 1995; 38:259-63; Miller S et al. *Br J Surg* 1995; 82:1327-30)

### 4. Reservoir

A need for a neo-rectal reservoir was felt to overcome the problem of ARS. Lazorthes et al and Parc et al in 1986 designed a “Colonic J Pouch” (CJP) to address these problems. Even

though nothing can replace a natural reservoir but this type of pouch is aimed at achieving at least an artificial reservoir to improve the overall quality of life (QOL). (Parc R et al Br J Surg 1986; 73:139-41, Hida J et al Dis Colon Rectum 1996; 39:986-91)

## 5. Preoperative assessment

It comprises of

- General physical examination(GPE)
- Digital rectal examination( DRE)
- Proctoscopic examination(PE), Sigmoidoscopy, Colonoscopy with biopsy
- Baseline hematology and biochemistry
- Carcino embryonic antigen(CEA ) levels
- Ultrasonography(USG),Multidetector computerized tomogram(MDCT),Endorectal Coil magnetic resonance imaging(Ec MRI),Trans rectal ultrasonography (TRUS)
- Neoadjuvant for locally advanced tumors

## 6. Indications

T2, T3 lesions 4 - 12 cm. from anal verge

T3 +/-T4 lesions down staged after neo-adjuvant

## 7. Contraindications

- Narrow pelvis
- Bulky sphincters
- Pregnancy
- Locally advanced cancers
- Sphincter tone is already lost or low
- Mucinous or poorly differentiated carcinoma

## 8. Preoperative counseling

- Consent for surgical procedure with possibility of permanent or temporary stoma to be explained, stoma sites to be discussed and marked preoperatively
- Stoma therapist involvement encouraged in the preoperative period for marking the sites and psychologically preparing the patient
- Possibility of inoperability also to be explained
- Bowel preparation done one day prior to surgery
- Intra venous antibiotics (3rd generation cephalosporin) used at the time of induction after test dose
- J pouch pros and cons explained to the patient and his attendants
- Staplers use to be discussed because of the cost factor and the complications associated with their use

## 9. Intra operative management

All such procedures should be planned under general anesthesia (GA) supplemented with epidural analgesia. A provision for ureteral stents intraoperatively has to be kept in mind in

case of surrounding desmoplasia or a recurrent cancer. A Foley's catheter should always be put in the bladder to keep it deflated during the procedure. Patient should be placed in modified lithotomy position with legs in stirrups. A pneumatic compression stocking with use of low molecular weight heparin will always be an added guard against deep venous thrombosis. Always remember to do a DRE under GA to reassess the tumor with a special emphasis on degree of involvement of anal sphincters, the level of distal edge of the tumor and response of the tumor to neo-adjuvant treatment if at all that was used.

Proper operation theatre headlights and lighted retractors will always be a great help to facilitate the procedure. Other gadgets of immense importance in pelvic surgery would be Balfour or Bookwalter retractors, Saint Mark pelvic retractor, long instruments, highly trained assistant, presence of an experienced 2nd surgeon and a regular team.

## 10. Intra operative decision

Intraoperative findings may necessitate a change in plan. Never try to be egoistic about sphincter saving procedures in case there arise some technical difficulties on table. Use midline incision, head down position for performing laparotomy. Proper packing of small gut, use of self retaining retractors and proper mobilization of rectosigmoid area is a must. A decision about sphincter saving or sphincter sacrificing after mobilizing rectum should be revised.

## 11. Mobilization of colon

Rectosigmoid is retracted to right. Peritoneal attachment on left incised along avascular plane, left ureter and gonadal vessels are isolated. Transilluminate to identify avascular plane (Holy plane) adjacent to inferior mesenteric artery (IMA). Peritoneum is incised on either side (fig 1). High ligation of IMA may provide a complete nodal harvest but at the cost of autonomic nerve plexus injury. Low ligation is done distal to left colic artery (LCA) it ensures better supply to proximal colon and saves nerve injury at base of IMA but at the cost of complete nodal harvest. Ligate IMA and start posterior dissection in holy avascular plane. Aim at total mesorectal excision (TME) with nerve preservation. The key to posterior dissection is sharp dissection of avascular plane and allow air to enter areolar tissue. Follow the air for dissection. Preserve superior hypogastric plexus at sacral promontory, pre aortic and inferior mesenteric plexus at the base of IMA. Hypogastric nerves can be identified at sacral promontory. These nerves descend in presacral space in a "wishbone shape". Preserve them for postoperative sexual and urinary function. Attention to "Nerve preservation" will retain sexual function in males > 60%; in females up to 86 %.(Havenga K et al. J Am Coll Surg: 1996; 182:495)

Rectrosacral fascia is divided under vision to the level of coccyx (fig 2). Dissect in posterior to lateral direction. Nervi erigentes should be preserved on lateral pelvic sidewalls. Middle rectal artery (MRA) which may or may not be a content of lateral ligaments should be fulgured or ligated. Final attachments are divided anterolaterally. Nerve sparing resection improves QOL in patients of rectal carcinoma. The lateral ligament of the rectum is a definite anatomic entity. Some studies suggest that the ligament contains a few nerve fibers but no significant blood vessels. (Pak-art DCR 2005)

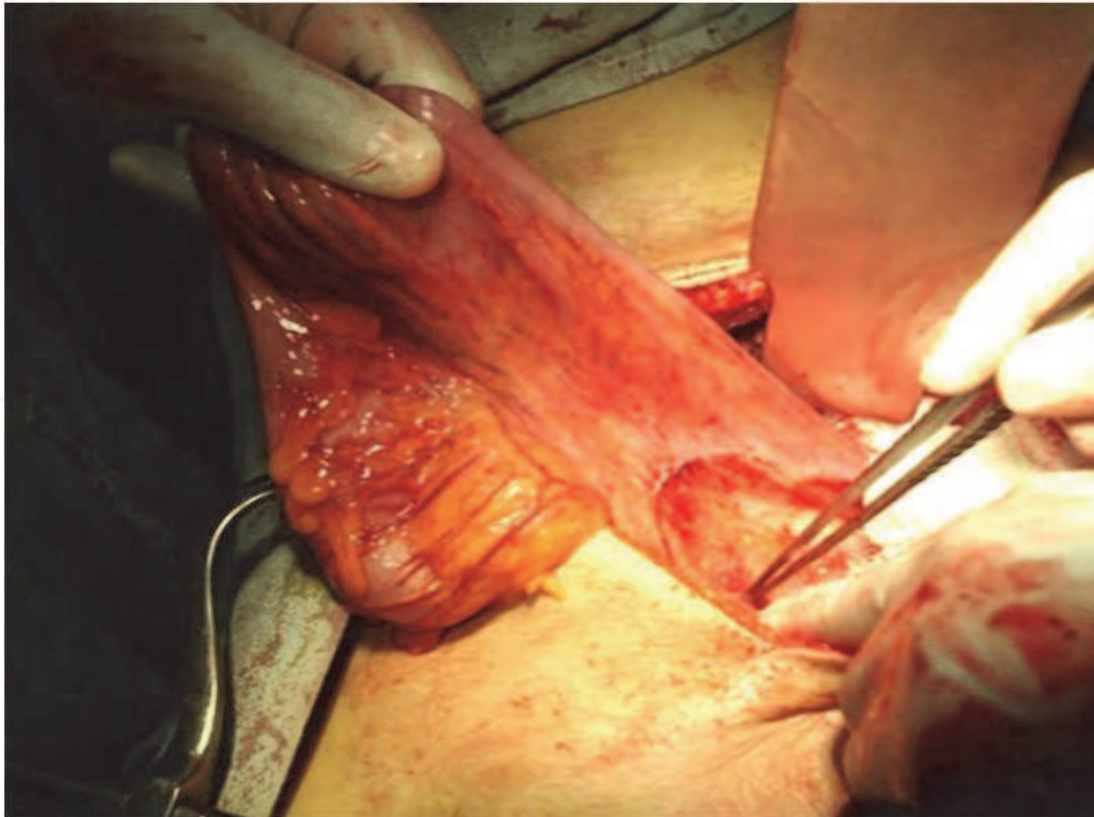


Fig. 1. Operative photograph showing mobilization of rectosigmoid

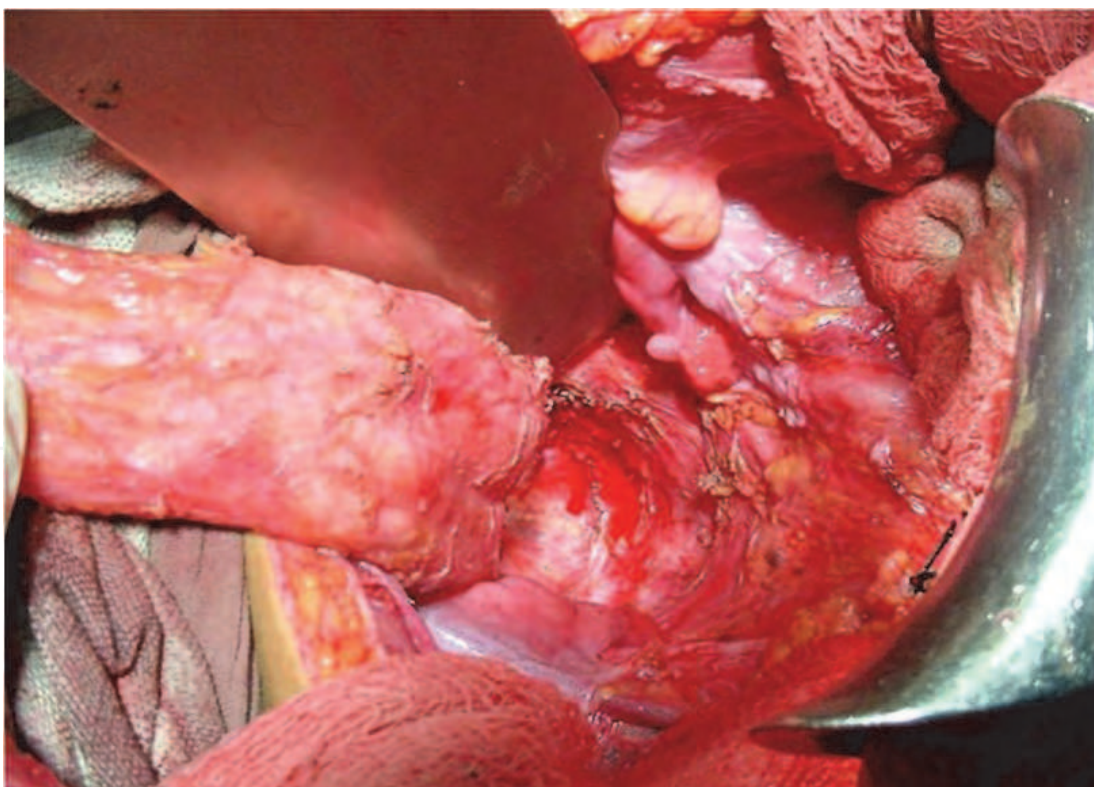

Fig. 2. Operative photograph showing posterior dissection

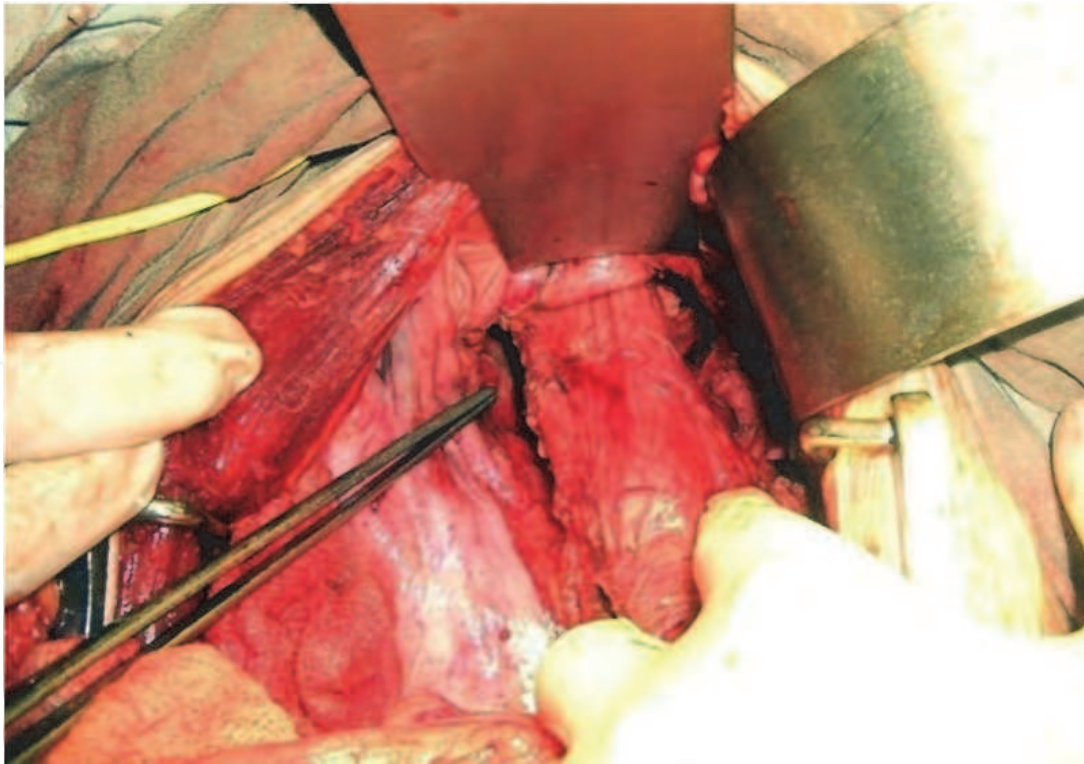


Fig. 3. Operative photograph showing anterior dissection

Mesorectum appears to be adherent to inferior hypogastric plexus at 11 and 2 o'clock position so one needs to be careful and meticulous while dissecting at these positions. Anterior Dissection should be done last of all. Exposure is facilitated by reverse trendlenburg position. Open cul de sac and incise Denonviller's fascia. Use deep pelvic retractors to protect seminal vesicles and prostate in males and posterior wall of vagina in females (Fig 3).

- Cut well, see well and your patient will get well (Charles Aubrey Pannet)

Proximal end is usually cut at junction of descending and sigmoid colon. Cut with a linear cutter 55 mm /75mm(Ethicon); 60 mm/80mm (auto suture).Proximal limb is arranged in J configuration with 2 or 3 sutures (seromuscular).A 2 cm hole is made at base of J pouch. Linear cutter is disengaged and put in 2 limbs of J pouch. Length recommended for each limb is 5 - 10 cm. Linear cutter is fired after approximating the two limbs.

## 12. Assessment of distal margin

Revise your decision again at this juncture about sphincter saving or sphincter sacrificing surgery. Two components to distal margin should be taken into consideration. Intramural where 2.0 cm margin is adequate and mesorectal where a margin of 5 cm is considered to be adequate .Stanskey clamp should be applied on proximal side for staplers to avoid any spillage of contents. Linear articulating stapler (access 55), contour or roticulator is used for dividing rectum leaving a closed rectal cuff for anastomosis (fig 4). Specimen is removed.Washes given with cetrimide / saline.

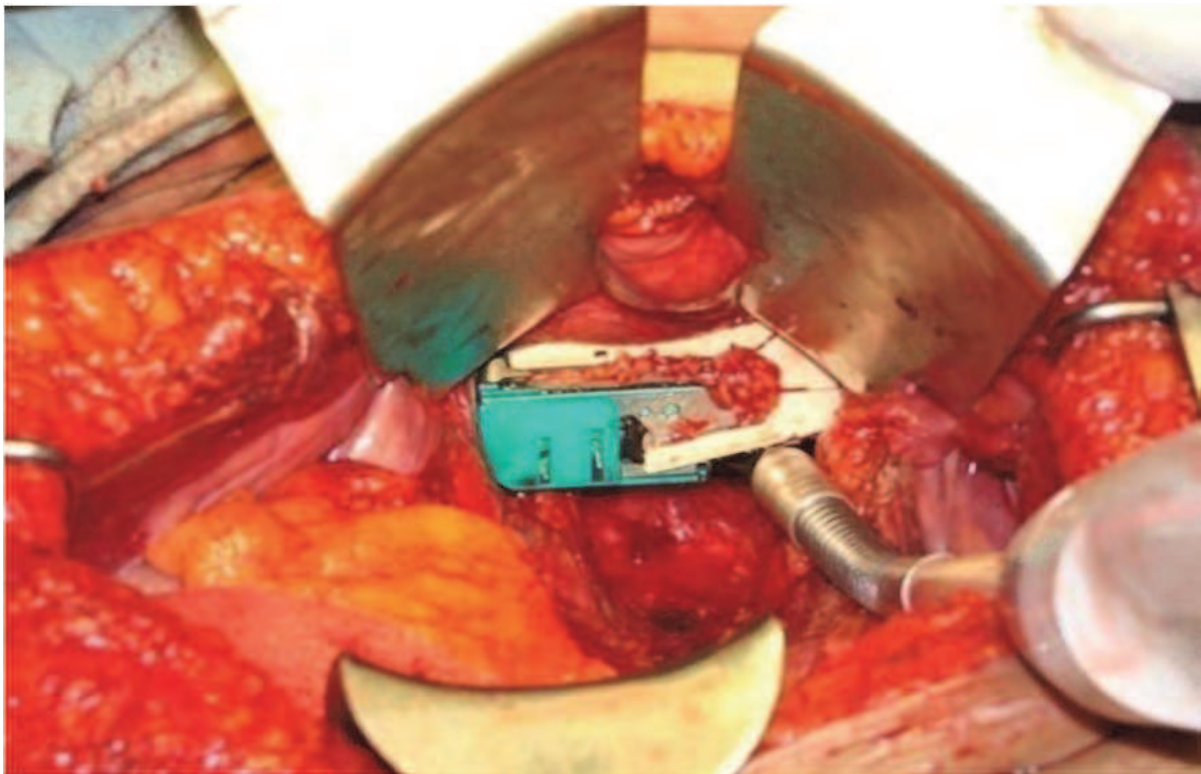


Fig. 4. Stapler "Access 55" used for distal end

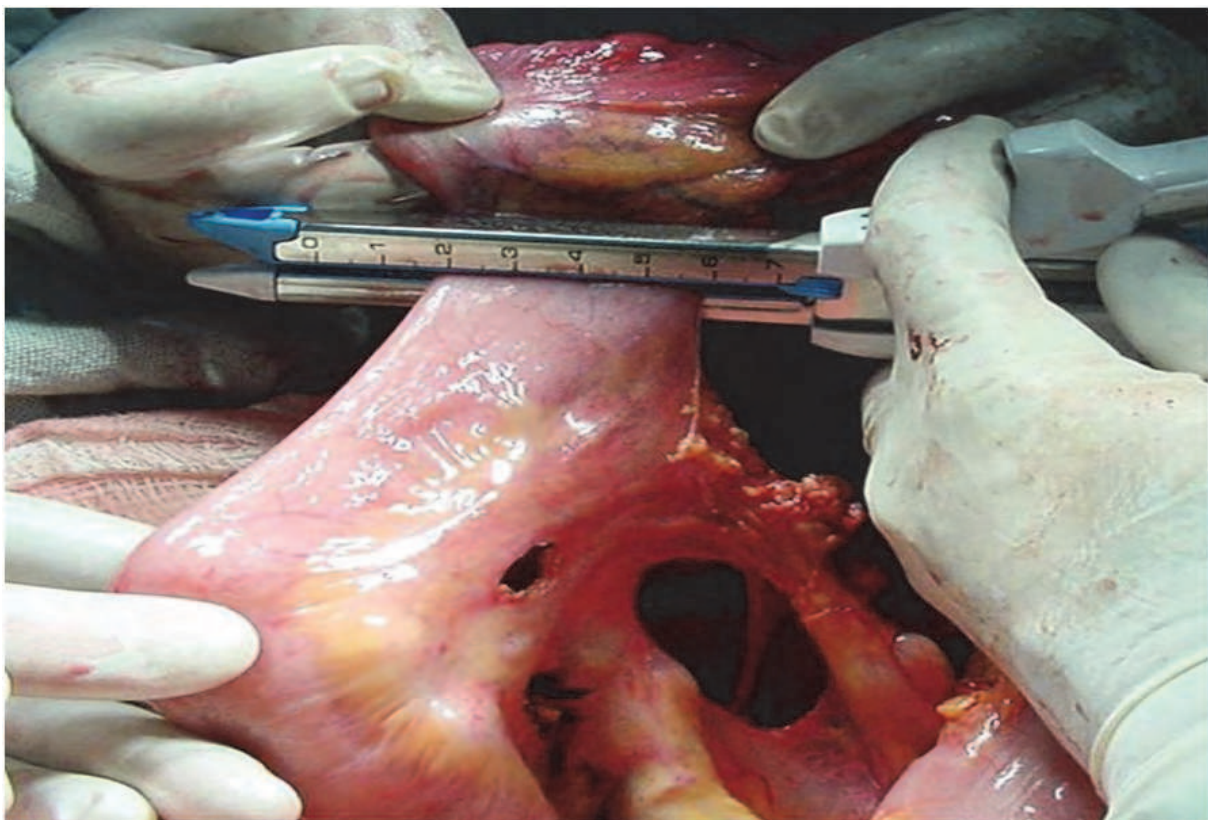


Fig. 5. Mesenteric windows made to gain length



### 13. How to gain length

First assess the mobility of the colon apex of J should be 6 cm down the symphysis pubis. If not, then skeletonize the vessels. Make windows in the mesentery (Fig 5). Mobilize the left lateral peritoneal attachments. Mobilize the splenic flexure of the colon. Cut any withholding vessels after using a vascular clamp for 5 minutes. Ensure good vascularity of the segment to be used for construction of J pouch. In case of any doubts about the vascularity give up the idea.

### 14. Creation of anastomosis

In J pouch the anastomosis is always end to side (Baker technique). Hand sewn anastomosis is technically difficult in low rectal cancers. Ideal is to use a circular stapler CDH (circular detachable head) or CEEA (circular end to end anastomosis) for completion of anastomosis. Functional results are good for proximal anastomosis and suboptimal for low anastomosis. Hence, J pouch or coloplasty is carried out to serve the function of a neo-rectum and improve the overall functional results. Use Staplers only after formal training.

- “A fool with a tool is still a fool”

### 15. J pouch

We prefer 6 – 8 cm. limbs. Engage the two limbs of stapler in two limbs of colon. Maintain proper orientation. Push down the mesentery before locking the staplers. Fire and hold the instruments for 2 minutes to achieve a good hemostasis (fig 6). Examine the staple line, if there are any oozers ligate them with absorbable sutures. Use the same hole of “J” to engage the anvil of CDH / CEEA. Hold the anvil with an artery forceps. Put a purse string stitch of 1<sup>0</sup> Prolene around the anvil (fig 7). Close CDH/ CEEA with rotating knob. Dilate anal canal gently using 2% xylocaine. Then push “CDH” gently till you can see the circular head abutting against stapled line. Select the appropriate place of entry of the knob which may be anterior or posterior. Keep on opening the rotator head till the knob makes an entry into the perineum till main operator sees the orange cuff. Engage the assembly of anvil spring loaded self locking shaft into the trocar projecting out of staple housing of rectal side till you hear an audible click (Fig 8). Keep on rotating the knob of CDH till the tissues of two sides approximate and on the instrument you can see a green line appearing in the gap setting scale of the stapler indicating the proper approximation of tissues. Fire the stapler and wait for two minutes for complete hemostasis (Fig 9). Unlock the knob and make two complete 180 degree turns. Remove the stapler from the anorectum with fishtailing movements. Examine for 2 complete doughnuts. Send the excised specimen and two labeled doughnuts for histopathological examination (HPE). Fill the pelvis with saline. Inject air per rectum and look for any air leaks. If you have any doubts, cover it with an ileostomy. Covering ileostomy is preferred in cases of very low anastomosis as leak rates are quite high for very low anastomosis. Even though the covering ileostomy has been found not to decrease the leak rates but saves the patient from the catastrophe of fecal peritonitis in case of any leaks from the anastomosis. Patients in the post operative or follow up period can be subjected to a contrast study using water soluble contrast to demonstrate the anatomy and angulation of pouch ( Fig-10, Pouchogram).

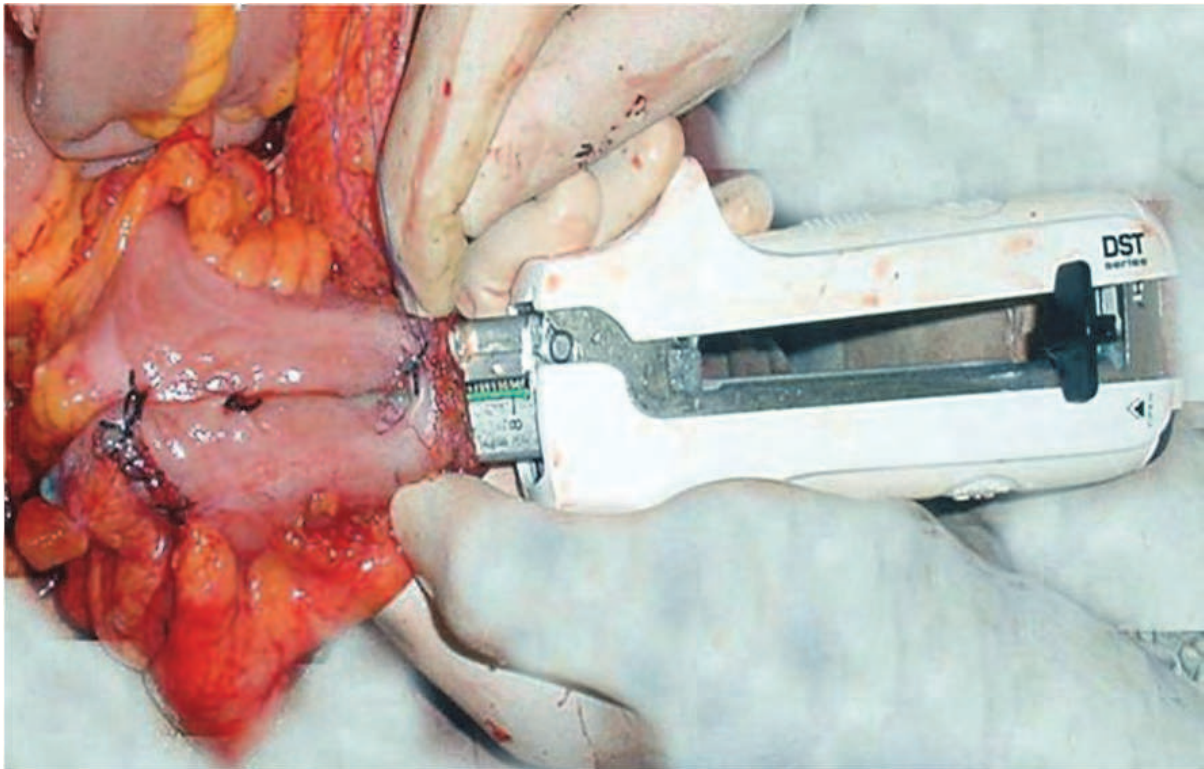


Fig. 6. Linear Stapler for J Pouch

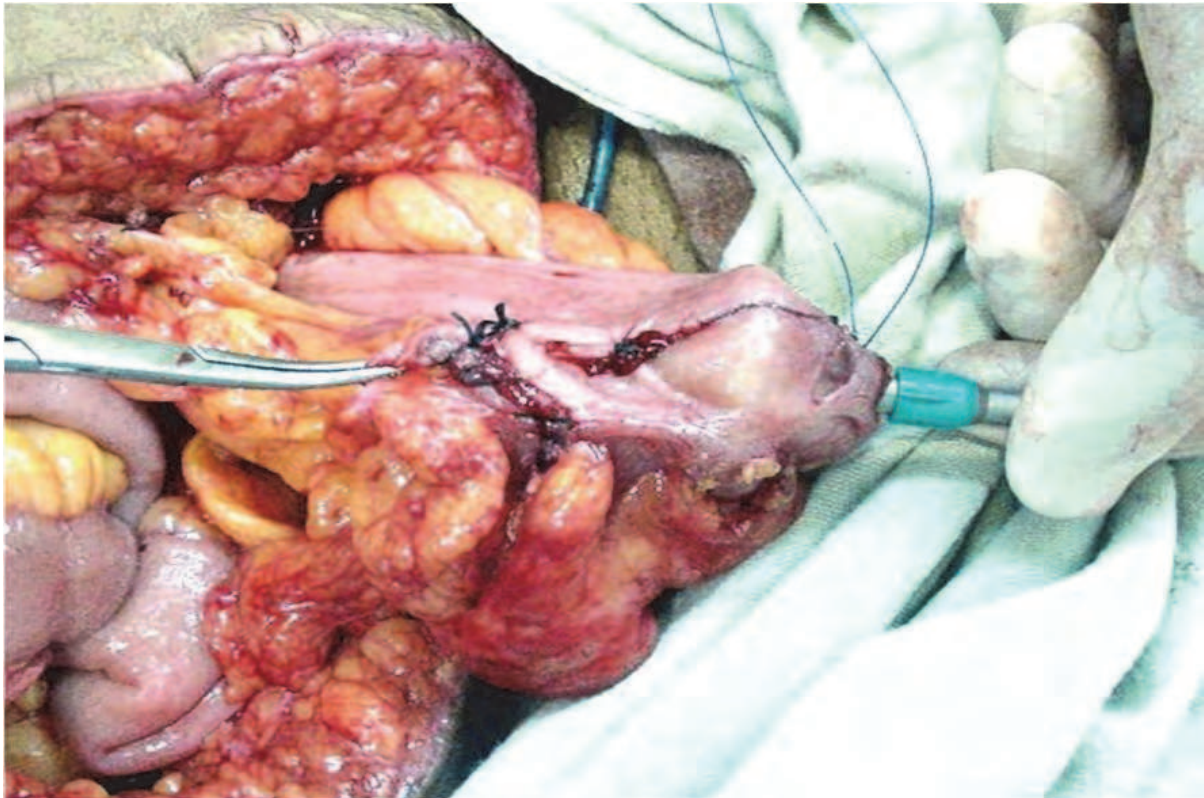


Fig. 7. Anvil fixation in base of J Pouch

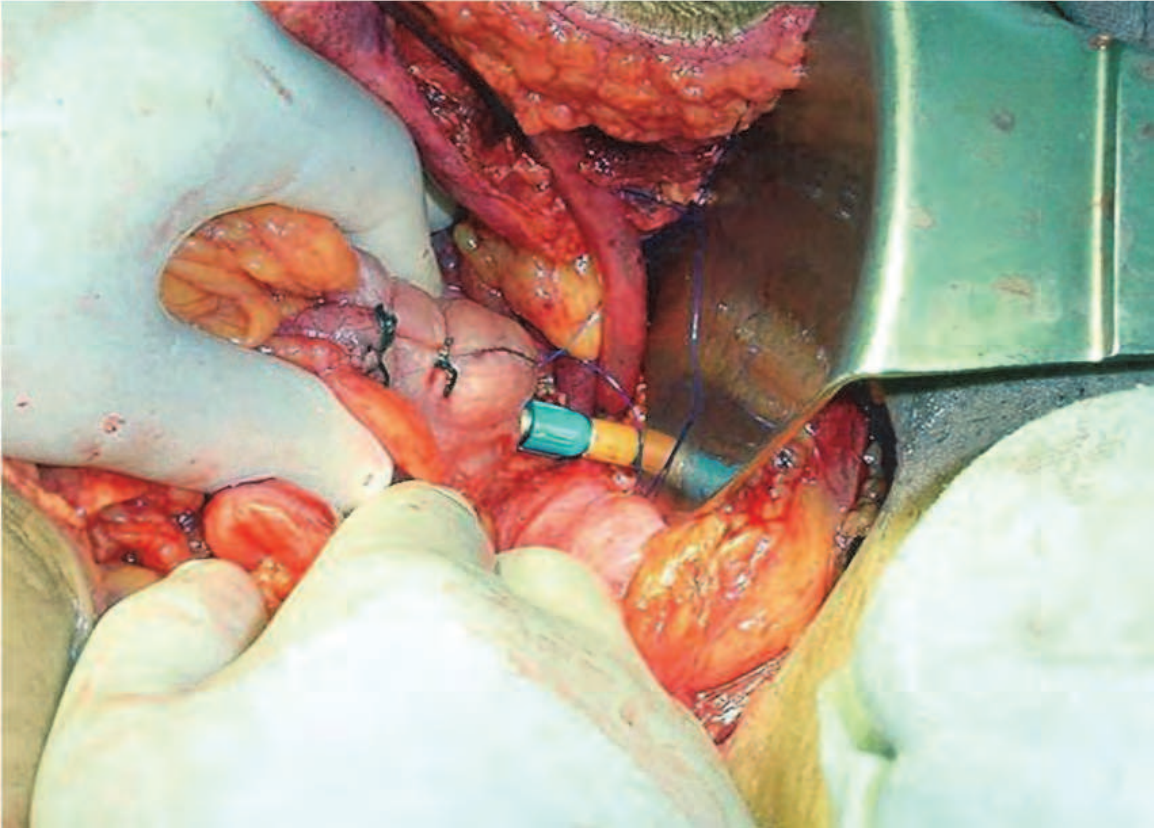


Fig. 8. Fixation of anvil into the trocar projecting out of staple housing of rectal side.

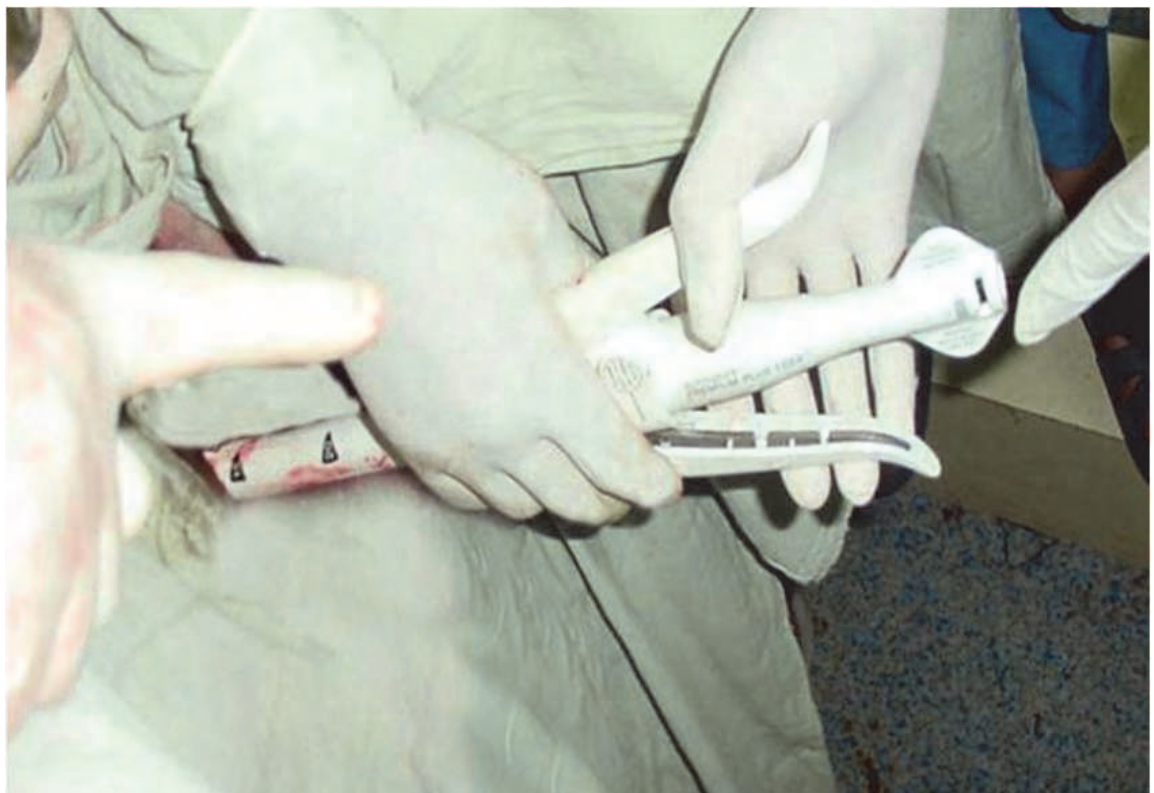

Fig. 9. Firing CDH/CEEA

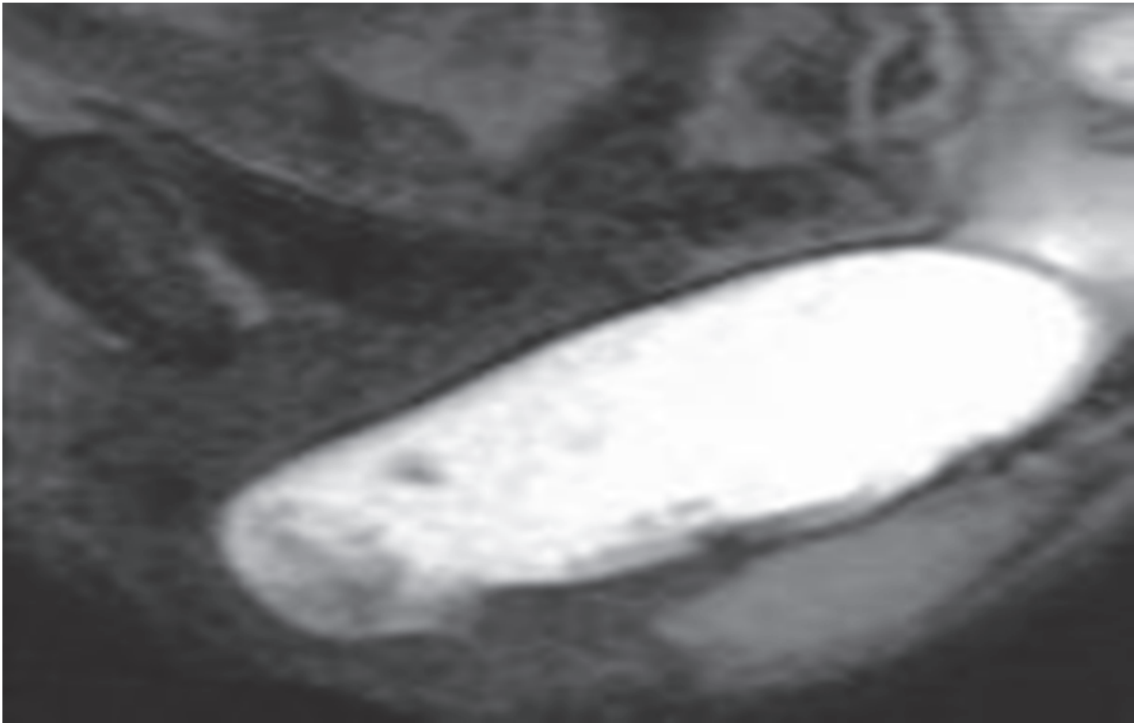


Fig. 10. Contrast study of the Pouch on follow up(Pouchogram)

## 16. Our experience at SKIMS

We conducted a Prospective randomized study in our tertiary care hospital. 22 patients were assigned to Colonic J Pouch( CJP) group and 20 patients to Straight anastomosis (SA) group and the two groups were compared on basis of:

- Functional outcome
- Composite incontinence score
- QOL
- Anastamotic leak was 3.3 times more common in the SA group.
- Anastamotic strictures were 2.3 times more common in the SA group.
- The frequency of bowel movement per 24 hours was less in the CJP group.
- CJP group had no nocturnal bowel movements at six months.
- CJP was able to defer defecation better than the SA group.
- Retarding medication use more common in SA group.
- Bulking medication use more common in CJP group.
- CJP patients were better able to differentiate between gas and stool.
- There was an increased ability to evacuate bowel within 15 minutes in SA group
- The CJP patients were more continent to gases, liquids and solids at 2 and 6 months duration.
- All these findings were statistically significant
- Stastical methods used were Fischers exact test, Chi square using SPSS 15

## 17. Laparoscopic TME

Laparoscopic ultralow anterior resection could be offered routinely and completed safely in Western populations, where obesity and adhesions from previous abdominal surgery is

common. A laparoscopic technique readily allowed visual identification of the autonomic nerves in the abdomen over the aorta, which could then be followed down into the pelvis. If the pelvis was deep, inversion of the 30° laparoscope in the “upside down” position facilitated incision of Waldeyer’s fascia. Further randomized, controlled studies that include assessing five-year cancer survival/recurrence, pelvic nerve dysfunction, and bowel function are needed before laparoscopic ultralow anterior resection becomes widely accepted.

(Selvindos PB & HO YK.DCR 2008;51(11))

Laparoscopic assisted surgery for colorectal cancer has been widely adopted without data from large scale randomized trials to support its use. MRC CLASICC trial –a multicentre, randomized controlled trial compared short term end points of conventional versus laparoscopic assisted surgery in patients with colorectal cancer to predict long term outcomes. They found that the conversion rate for rectal cancer after laparoscopy is 34% in patients undergoing anterior resection, circumferential resection margin( CRM) positivity was greater in the laparoscopic than in the open surgery group 16 [12%] of 129 Individuals versus four [6%] of 64, respectively but this difference was not significant (95% CI -2.1 to 14.4%, p=0.19).They concluded that there are ‘impaired short-term outcomes after laparoscopic assisted anterior resection for cancer of the rectum and still do not yet justify its routine use’. (Lancet 2005; 365:1718-26)

What we believe in is that don’t run before being able to walk.

## 18. Discussion

APR was once the operation of choice for a low rectal cancer but the development of LAR and circular stapler increasingly allowed restorative surgery with preservation of anal sphincters but unfortunately many patients pay the price for avoidance of a permanent stoma by developing ARS as already described. Various studies were undertaken to understand the real cause of this syndrome. The majority used anorectal manometry as an investigative tool to investigate these patients. The three features appearing most frequently are reduced anal tone, loss of rectoanal inhibitory reflex (RAIR) (Iwai N et al.DCR 1982; 25:652-9), and reduced rectal compliance. (Batignani G.DCR 1991; 34:329-35).Rectal compliance seems to be the only feature susceptible to change by alteration of rectal volume. In 1986 Lazorthes et al and Parc and colleagues (Parc et al;BJS 1986;73:139-141)described that formation of a CJP fashioned from sigmoid or descending colon would obviate much of the dysfunction associated with the low straight anastomosis by increasing neorectal volume. In recent times the CJP is becoming the operation of choice for the cancers of low rectum. Despite its increasing popularity still some misconceptions exist about its routine use outcome and evacuation problems. But the evidence in literature suggests that CJP is safer because of the reduction in the incidence of anastomotic leaks, better functional outcome with reduced frequency and better continence. (Dennet ER and Parry BR; DCR 1999 June, vol 42).Since the colonic pouch reduces the incidence of leaks so automatically the incidence of strictures is decreased. As all of us know that anastomotic integrity and healing is dependant mainly on good vascularity, technique and avoiding tension on anastomosis. Tension can be decreased by adequate mobilization which most of the times needs complete mobilization of the splenic flexure of colon and blood supply is improved by use of colonic J pouch as was proved by the use of laser doppler flowmetry during surgery. ( Hallbook O et al;BJS 1996;83:389-92).

Evidence also suggests that if sigmoid colon is used for pouch construction it is presumed to cause excessive functional problems. The reasons for these functional problems can be that sigmoid colon is a high pressure segment and is more prone to develop severe motility dysfunction as compared to descending colon pouches. (Seow-Choen F, Goh HS; BJS 1995;82:608-10). Sigmoid colon is also more prone to develop diverticulosis which makes it more thickened and rigid and not suitable for the construction of J pouch. Besides high ligation of inferior mesenteric artery may render the sigmoid colon ischemic and not fit for use.

One of the main advantages cited in literature for colonic J pouch is the decreased daytime and nocturnal frequency of bowel as compared to straight anastomosis. This has been proved time and again by the comparative studies done from time to time. Lazorthes et al found that after one year, 86% patients with colonic J pouch had a bowel frequency less than 3 stools per day compared to only 33% of patients with a straight anastomosis. Parc et al described a mean of 1-6 bowel movements per day after 1 month and 1.1 per day after 3 months in a group of 31 patients with a CJP. This was further substantiated by studies of Ho et al, Seon Choen et al and Nicholls et al. Harris et al in their study found that the median frequency of bowel movements at night time was zero in the CJP patients compared to SA group. This was at 0-4 years and 5-9 years duration on follow up. Routine work schedule in the busy life makes it imperative for the person to be able to hold his stools for some time till he finds a toilet to ease out. Inability to do so has its own social and psychological stigmas. According to Dennet and Parry (DCR 1999;42:804-811) 14 studies report on post operative urgency after CJP but in only 10 of them it is compared to a SA group. From this comparison it appears that CJP is almost a near perfect solution to post operative urgency but Ho et al reports no significant improvement. Incontinence is one of the major determinants of functional outcome after low anterior resection and it was found from most of the studies that continence to gases, liquids and solids improves significantly after the construction of colonic J pouch especially in very low rectal cancers. It was further substantiated by observing a significant difference in their composite incontinence score at 2 months and one year. (Hallbook et al; Ann Surg 1996;224:58-65). Most of the studies definitely are in favor of a better functional outcome with CJP as compared to SA especially when the rectal cancer is of low variety and post resection the anastomotic line is below 8 cms on DRE. For higher lesions usually the lower or some part of midrectum may be preserved hence the reservoir is not needed and the functional outcome may not show any advantage over SA. (Table-1)

**Colonic reservoir:** Meta analysis (BJS-2006): The conclusion of meta analysis was that CJP after anterior resection has significant functional advantages over SA and this persisted over time and seems to be the procedure of choice.

Another study on **Colonic J-pouch anal anastomosis** after ultralow anterior resection proved that Colonic J-pouch anal anastomosis decreases the severity of fecal incontinence and improves the quality of life. (World J Gastroenterol 2005 May;11(17):2570-2573 )

One study compared Colonic J Pouch versus Coloplasty following resection of distal rectal cancer and found similar functional results in the coloplasty group compared to the J-pouch group. (Dis Colon Rectum. 2003 Sep;46(9))

**Colonic J-Pouch, Coloplasty, Side-to-End Anastomosis:** Meta-Analysis proved that CJP is able to obviate some of the functional problems of SA, it comes with an additional problem of pouch evacuation. Therefore, alternative techniques, such as transverse coloplasty pouch and side-to-end coloanal anastomosis, have been adopted. (Seminars in Colon and Rectal Surgery. Aug 2009; Volume 20, Issue 2, Pages 69-72)

### 18.1 Remaining surgical issues in rectal cancer

We have to improve outcome in very low cancer, improve sphincter preservation technique sentinel node technique which is still questionable in colorectal cancers and needs to be assessed in future studies and at the same time ascertain the validity of laparoscopic resection which at present as per the latest studies based on randomized trials is still inferior to open surgery.

Laparoscopic Colorectal Surgery is still associated with a higher intraoperative complication rate than Open Surgery. (Tarik S et al *Annals of Surgery*: January 2011; 253 (1): 35–43)

Author		Number	Stool frequency Per 24 hours	Continent no.(%)
Lazorthes et al	Pouch	15	1.7±0.67*	12 (80)
	Control	36	3 ± 1.25	28 (78)
Cohen	Pouch	23	1- 4	19 (83)
Hallbook et al	Pouch	42	2 (1.3-2.3)	^
	Control	47	Median (Interquartile range) 3.5(2.4 - 4.50)	^
Hida et al				
(5 cm)	Pouch	20	^	^
(10 cm)	Pouch	20	^	^
Lazorthes et al				
	(6 cm)	Pouch	14	1.8±1.1
(10 cm)	Pouch	17	2 ± 1.6	12 (70)
Joo et al	Pouch	26	2.4 ± 1.3	^
	Control	30	4 ± 2	^

^ = a functional score is given for continence is given rather than raw data.

Unless otherwise stated the stool frequency is mean (range) or ± standard deviation.

\* Values that are statistically significant

Table 1. Functional outcome after coloanal J-Pouch anastomosis (Dennet and Parry; *DCR*, 1999 June, Vol 42)

### 18.2 Problems with CJP

- Surgeons need proper training to use staples. Many a times surgeons try new procedures in technology boom without properly learning them in animal laboratories which is a dangerous trend and puts their patient at a greater risk which may at times be life threatening.
- Learning curve - Rectal cancer surgeries as such are technically demanding procedures. The problems are further compounded in presence of obesity, narrow pelvis, redosurgery and low rectal cancers. Hence all surgeons go through a long learning curve to master these procedures and then only they should think of going for any further advances like CJP or coloplasty.
- Patient selection - This is very important from technical point of view. In case you have selected a very obese patient, patient with previous adhesions, narrow pelvis, bulky sphincters or patients with diverticulosis; you will definitely get discouraged to adopt

the procedure, hence a proper patient selection especially in the initial days is very important.

- Volume of the centre – This is one of the biggest contributory factors which can make you to master a particular surgery but in case the volume of the centre for a particular disease is quite less then it is not worthwhile trying these technically demanding procedures.
- Ideal pouch size to be decided – Initially most of the surgeons who adopted this procedure would prefer a 10 cm limb of the J pouch but with the rising number of evacuation problems the recent trend is to go for 5 cm limb. We believe this size compromises with the neorectal volume, hence we prefer a limb of 6-8cms which balances between the volume and evacuation.
- Evacuation problems – arise because of the peristaltic wave travelling in its natural direction, so the wave travels to other limb of J rather than going in the direction of anal canal. The problem gets further aggravated by the long size of a limb, so the remedial measures are already discussed in the proceeding paragraph. Besides these patients may many a time need the support of a bulk laxative to facilitate the evacuation. Horizontal angling of the pouch during the act of defecation can become another contributory factor in failure of pouch evacuation, however, this problem can be overcome by fixation of the pouch with presacral fascia.
- Technically not possible in all – Many factors like thick mesocolon, adhesions, failure to gain adequate length, narrow pelvis, poor vascularity may pose some technical difficulties to construct a pouch.
- Pouch failure – Some pouches inspite of a good construction may fail to evacuate and inspite of the support of enemas and laxatives may not be helped so may need a revision surgery in the form of APR.
- Cost factor – This continues to be a concern in resource poor countries. The staplers cost a good bit of money which still is out of reach of the most in this part of globe.
- It is just the beginning.

### 18.3 Is CJP a gold standard?

We believe that it is too early probably to say that, it will need larger trials, long term follow up to really label it as a gold standard. Even though there is so much of evidence in its favor but still the evidence is not enough to establish its supremacy and justify its routine use in all cases of low cancer rectum but it is an evidence based option so needs to be tried on larger series.

## 19. Acknowledgement

Prof G Q Peer who always trusted and believed in me and infused confidence in me at critical junctures. Prof Nazir A Wani Ex Dean Faculty, Chairman Surgical division at SKIMS my guide, teacher who always persuaded and inculcated the craft of writing in me and always encouraged me to do better in life.

Prof Khursheed Alam Wani –Head Dept of Surgery at SKIMS who always encouraged and facilitated my research work and kept on appreciating my good work at all junctures.

Dr Sameer H Naqash, Dr Ajaz A Malik and Dr Rouf A Wani my dearest colleagues in the department who always stood by me morally and professionally during the study period.



My revered parents for their love, affection and blessing.

My beloved wife Nighat who is a big psychological, emotional and moral support for my all academic work and my sweet kids Shaheem and Liqa who always bear with me in my hours of toil at the cost of their time. My dearest students who always gave me lots of love and respect and made me to do better.

Mr. Farooq A Nadaf for the computer execution and the proper design of this book chapter with utmost commitment, sincerity and dedication.

## 20. References


- Alois Fürst, Silvia Suttner, Ayman Agha, Alexander Beham and Karl-Walter Jauch. Colonic J- Pouch vs. Coloplasty Following Resection of Distal Rectal Cancer Early Results of a Prospective, Randomized, Pilot Study. *Dis Colon Rectum*. 2003 Sep; 46(9).
- Batignani G, Monaci I, Ficari F, Tonelli F. What affects continence after anterior resection of the rectum? *Dis colon rectum* 1991; 34:329-35.
- Dukes CE. The spread of cancer of the rectum. *Br J Surg* 1930; 17:643-8.
- Dennett ER, Parry BR. Misconceptions about the colonic J pouch. *Dis colon rectum* 1999;42:804-811.
- Fain SN, Patin CS, Morgenstern L. Use of a mechanical suturing apparatus in low colorectal anastomosis. *Arch Surg*. 1975 Sep; 110(9):1079-82.
- Golihrt JC, Dukes CE, Bussey HJ. Local recurrences after sphincter saving excisions for carcinoma of the rectum and Rectosigmoid *Br J Surg*. 1951 Nov; 39(155):199-211.
- Goligher JC. Recent trends in the practice of sphincter-saving excision for carcinoma of the rectum. *Adv Surg*.1979; 13:1-31.
- Guillou PJ, Quirke P, Thorpe H, Walker J, Jayne DG, Smith AM, Heath RM, Brown JM. MRC CLASICC trial group. Short-term endpoints of conventional versus laparoscopic-assisted surgery in patients with colorectal cancer (MRC CLASICC trial): multicentre, randomised controlled trial. *Lancet* 2005 May; 365 (9472): 1718-26.
- Hallbook O, Pahlman L, Krog M, Wexner SD, Sjodahl R. Randomized comparison of straight and colonic J pouch anastomosis after low anterior resection. *Ann Surg* 1996; 224:58-65.
- Hallbook O, Johansson K, Sydahl R. Laser Doppler blood flow measurement in rectal resection for carcinoma; Comparison between straight and colonic J pouch reconstruction. *Br J Surg* 1996; 83:389-92.
- Hida J, Yasutomi M, Fujimoto K, Okuno K, Ieda S, Machidera N, Kubo R, Shindo K, Koh K. Functional outcome after low anterior resection with low anastomosis for rectal cancer using the colonic J-pouch. Prospective randomized study for determination of optimum pouch size. *Dis Colon Rectum*. 1996 Sep; 39(9):986-91.
- Ho YH, Tan M, Seow Cheon F. Prospective randomized controlled study of clinical function and anorectal physiology after low anterior resection. Comparison of straight and colonic J pouch anastomosis. *Br J Surg* 1996; 83:978-980
- Harris GJ, Lavery IC, Fazio VW. Function of a colonic J pouch continues to improve with time. *Br J Surg* 2001; 88:1623-27.

- Iwai N, Hashimoto K, Yamne T, Kojima O, Nishioka B, Fujita Y, et al. Physiologic states of anorectum following sphincter saving resection for carcinoma of the rectum. *Dis colon rectum* 1982; 25:625-9.
- Lazorthes F, Fages P, Chiotasso P, Lemozy J, Bloom E. Resection of the rectum with construction of a colonic reservoir and coloanal anastomosis for carcinoma of the rectum. *Br J Surg* 1986; 73:136-138
- Lewis WG, Martin IG, Williamson ME, Stephenson BM, Holdsworth PJ, Finan PJ, Johnston D. Why do some patients experience poor functional results after anterior resection of the rectum for carcinoma? *Dis Colon Rectum*. 1995 Mar; 38(3):259-63.
- Miles WE. A method for performing abdomino-perineal excision for carcinoma of the rectum and the terminal portion of the pelvic colon. *Lancet*. 1908; 1812-1813.
- Molloy RG, Moran KT, Coulter J, Waldron R, Kirwan WO. Mechanism of sphincter impairment following low anterior resection. *Dis Colon Rectum*. 1992 May; 35(5):462-4.
- Miller AS, Lewis WG, Williamson ME, Holdsworth PJ, Johnston D, Finan PJ. Factors that influence functional outcome after coloanal anastomosis for carcinoma of the rectum. *Br J Surg*. 1995 Oct; 82(10):1327-30.
- Nicholls RJ, Lubowoski DZ, Donalson DR. Comparison of colonic reservoir and straight coloanal reconstruction after rectal excision. *Br J Surg* 1988; 75:318-320
- Ooi BS, Lai JH. Colonic J-Pouch, Coloplasty, Side-to-End Anastomosis: Meta-Analysis and Comparison of Outcomes. *Seminars in Colon and Rectal Surgery* 2009 June; 20(2):69-72.
- Parks AG. Transanal technique in low rectal anastomosis. *Proc R Soc Med*. 1972 Nov; 65(11):975-6.
- Pollett WG, Nicholls RJ. The relationship between the extent of distal clearance and survival and local recurrence rates after curative anterior resection for carcinoma of the rectum. *Ann Surg*. 1983 Aug; 198(2):159-63.
- Parc R, Tiret E, Frileux P, Moszkowski E, Loygue J. Resection and colo-anal anastomosis with colonic reservoir for rectal carcinoma. *Br J Surg*. 1986 Feb; 73(2):139-41.
- Pedersen IK, Christiansen J, Hint K, Jensen P, Olsen J, Mortensen PE. Anorectal function after low anterior resection for carcinoma. *Ann Surg*. 1986 Aug; 204(2):133-5.
- Park JG, Lee MR, Lim SB, Hong CW, Yoon SN, Kang SB, Heo SC, Jeong SY, Park KJ. Colonic Jpouch anal anastomosis after ultralow anterior resection with upper sphincter excision for low-lying rectal cancer. *World J Gastroenterol*. 2005 May; 11(17):2570-3.
- P. Wille-Jørgensen. Meta-analysis of colonic reservoirs versus straight coloanal anastomosis after anterior resection. *Br J Surg* 2006; 93: 19-32.
- Quirke P, Dixon MF, Durdey P, Williams NS. Local recurrence of rectal adenocarcinoma due to inadequate surgical resection. *Lancet* 1986; 2: 996-9.
- Seon Choen F, Goh HS. Prospective randomized trial comparing J colonic pouch anal anastomosis and straight coloanal reconstruction. *Br J Surg* 1995; 82:608-610
- Selvindos PB, Ho YH. Laparoscopic ultralow resection with colonic J pouch anal anastomosis. *Dis colon rectum* 2008; 51(11):1710-1711

- Tarik S, Arman K, Sanket S, Ian B P, Hill, Andrew G. Laparoscopic colorectal surgery is associated with a higher intraoperative complication rate than open surgery. *Annals of Surgery*; 2011 January; 253 (1): 35–43.
- Westhues H. Uber die Entstehung und Vermeidung des lokalen Rektumkarzinom-Rezidivs. *Arch Klin Chir* 1930; 161:582–91.

IntechOpen

IntechOpen



## **Rectal Cancer - A Multidisciplinary Approach to Management**

Edited by Dr. Giulio A. Santoro

ISBN 978-953-307-758-1

Hard cover, 410 pages

**Publisher** InTech

**Published online** 10, October, 2011

**Published in print edition** October, 2011

Dramatic improvements in medicine over the last few years have resulted in more reliable and accessible diagnostics and treatment of rectal cancer. Given the complex physiopathology of this tumor, the approach should not be limited to a single specialty but should involve a number of specialties (surgery, gastroenterology, radiology, biology, oncology, radiotherapy, nuclear medicine, physiotherapy) in an integrated fashion. The subtitle of this book "A Multidisciplinary Approach to Management" encompasses this concept. We have endeavored, with the help of an international group of contributors, to provide an up-to-date and authoritative account of the management of rectal tumor.

### **How to reference**

In order to correctly reference this scholarly work, feel free to copy and paste the following:

Fazl Q. Parray, Umar Farouqi and Nisar A. Chowdri (2011). Is Neo-Rectum a Better Option for Low Rectal Cancers?, Rectal Cancer - A Multidisciplinary Approach to Management, Dr. Giulio A. Santoro (Ed.), ISBN: 978-953-307-758-1, InTech, Available from: <http://www.intechopen.com/books/rectal-cancer-a-multidisciplinary-approach-to-management/is-neo-rectum-a-better-option-for-low-rectal-cancers->

**INTECH**  
open science | open minds

### **InTech Europe**

University Campus STeP Ri  
Slavka Krautzeka 83/A  
51000 Rijeka, Croatia  
Phone: +385 (51) 770 447  
Fax: +385 (51) 686 166  
[www.intechopen.com](http://www.intechopen.com)

### **InTech China**

Unit 405, Office Block, Hotel Equatorial Shanghai  
No.65, Yan An Road (West), Shanghai, 200040, China  
中国上海市延安西路65号上海国际贵都大饭店办公楼405单元  
Phone: +86-21-62489820  
Fax: +86-21-62489821

© 2011 The Author(s). Licensee IntechOpen. This is an open access article distributed under the terms of the [Creative Commons Attribution 3.0 License](#), which permits unrestricted use, distribution, and reproduction in any medium, provided the original work is properly cited.

IntechOpen

IntechOpen