

We are IntechOpen, the world's leading publisher of Open Access books Built by scientists, for scientists

4,800

Open access books available

122,000

International authors and editors

135M

Downloads

Our authors are among the

154

Countries delivered to

TOP 1%

most cited scientists

12.2%

Contributors from top 500 universities

**WEB OF SCIENCE™**Selection of our books indexed in the Book Citation Index
in Web of Science™ Core Collection (BKCI)

Interested in publishing with us?
Contact book.department@intechopen.com

Numbers displayed above are based on latest data collected.

For more information visit www.intechopen.com

Preoperative Staging of Rectal Cancer: Role of Endorectal Ultrasound

Miro A.G.F.¹, Grobler S.² and Santoro G.A.³

¹Department of General Surgery, Ascalesi Hospital, Naples

²Department of Surgery, Universital Hospital, Bloemfontein,

³Department of Surgery, Regional Hospital, Treviso

^{1,3}Italy

²South Africa

1. Introduction

Preoperative staging of rectal cancer by endorectal ultrasonography (ERUS) was first described by Feifel and Hildebrandt in 1985 (1). Since then, ultrasonographic imaging of rectal wall has been widely accepted as the reference method for local staging of rectal cancer, and is now proposed as mandatory for preoperative staging purposes in the guidelines of the main scientific societies (2-7).

The technique has witnessed a constant evolution due to the systematic efforts of researchers in defining the normal anatomy of rectal wall and perirectal anatomic structures, in differentiating early cancers from advanced neoplasms and in defining pathological from reactive perirectal nodes. ERUS is faced with the challenge of improved imaging of the perirectal structures. The relationship of the tumor to the mesorectal fascia has emerged as one of the most powerful risk factors of outcome in terms of local relapse as the tumor distance from the mesorectal fascia is predictor of circumferential resection margin (CRM) (8).

2. Equipment

ERUS is an operator-dependent examination whose accuracy closely relates to the operator experience. It is an easy-to-learn procedure for accurate staging (9). ERUS has many advantages over CT and MRI. Firstly, ERUS probe is placed in close proximity to the area to be studied so that resolution and imaging quality are greatly enhanced. Secondly, it is an office procedure of short time consuming and is well tolerated by patients. Thirdly, it is relatively low cost.

In order to obtain meaningful images, the operator must have an overall understanding and therefore correct use of the controls of the ultrasound device and of the probe. Many types of ultrasound probes have been used to evaluate the rectal wall and the anal canal. Most of these were developed to examine the prostate gland and are not ideal for evaluating the wall of the rectum and the adjacent structures. Images of the rectal wall and of the adjacent structures are best achieved with radial probes with a 360° field of view with a frequency range of 6-16 MHz and a focal length (depth of penetration) of 2-5cm. We currently use a BK

medical scanner (BK Medical A/S, Mileparken 34, DK-2730 Herlev, Denmark), with mechanical anorectal transducers types 2050 and 2052. Inside the head of these probes, two crystals are assembled back to back. The assembly can rotate inside the transducer to give a 360° field of view and can be moved inward and outward for a distance of 60mm for a 3D automatic acquisition. The full length of acquisition is achieved by touching two buttons at the base of the transducer, without any discomfort for the patient and without any movement of the transducer. The probe is long enough (270mm) to cover the entire length of the rectum and to reach into the sigmoid colon.

In routine clinical scanning, the operator works in a two-dimensional (2D) plane. Newer probes, with automatic three-dimensional (3D) acquisition and special dedicated software (BK 3Di), give a spatial, high-resolution, 3D reconstruction combining a series of closely spaced 2D images. The advantages of 3D imaging is that the 3D volume can be freely rotated, rendered, tilted and sliced to allow the operator to infinitely vary the different section parameters and visualize the lesion at different angles and in different planes (coronal, frontal, axial) to get the most information from the data. After 3D acquisition, it is immediately possible to select coronal as well as sagittal views. The data can be saved, exported, reviewed and manipulated to derive comprehensive images of the study area. Multiplanar reformatting is probably the most useful mean of displaying the structures. With 3D reconstruction it is then possible to measure the tumor size and to evaluate the relations of the tumor with respect to bowel layers and perirectal anatomic structures. In addition the 3D dataset can be manipulated to render images with enhanced surface features (surface render mode) as well as depth features (opacity, luminance, thickness and filter settings), so as to best delineate the tumor and its surroundings.

3. Technique

ERUS is usually performed with the patient positioned in the left lateral decubitus (Sims position). Before inserting the probe into the rectum, a digital rectal examination must be performed to identify size, morphology and location of the tumor, if it is low enough. If there is a stenotic annular lesion, the finger can determine whether it will allow easy passage of the probe (11, 12). The transducer is covered by a latex balloon (water standoff condom) that is held in place over a transducer collar by two round rubber rings. Before starting the procedure, the balloon is filled with degassed water to remove air bubbles. Inflating the balloon with degassed water during the procedure (at varying volumes, due to different diameters of rectal ampulla) allows acoustic coupling between the transducer and the rectal wall. When using the 2050 probe, it is mandatory to introduce the transducer through a dedicated proctoscope, inserted into the rectum to pass the proximal border of the rectal mass. This also ensures distension of the balloon around the tip of ultrasound probe as it extends from the distal tip of the proctoscope. Reusable metal sigmoidoscopes or disposable proctoscope (A.4522, Sapimed, Alessandria, Italy) (13) are available. The use of dedicated proctoscope facilitates the positioning of the probe or easy passage of the probe into strictures as well as observation of its exact localization with respect to the distance from the anal verge.

The entire shaft of the balloon-covered probe is coated with a layer of warm ultrasound gel. The probe tip is gently inserted through the proctoscope to reach the base and the balloon inflated with water. The patient should be instructed before the examination that no pain should be experienced. Under no circumstances should force be used to advance the probe.

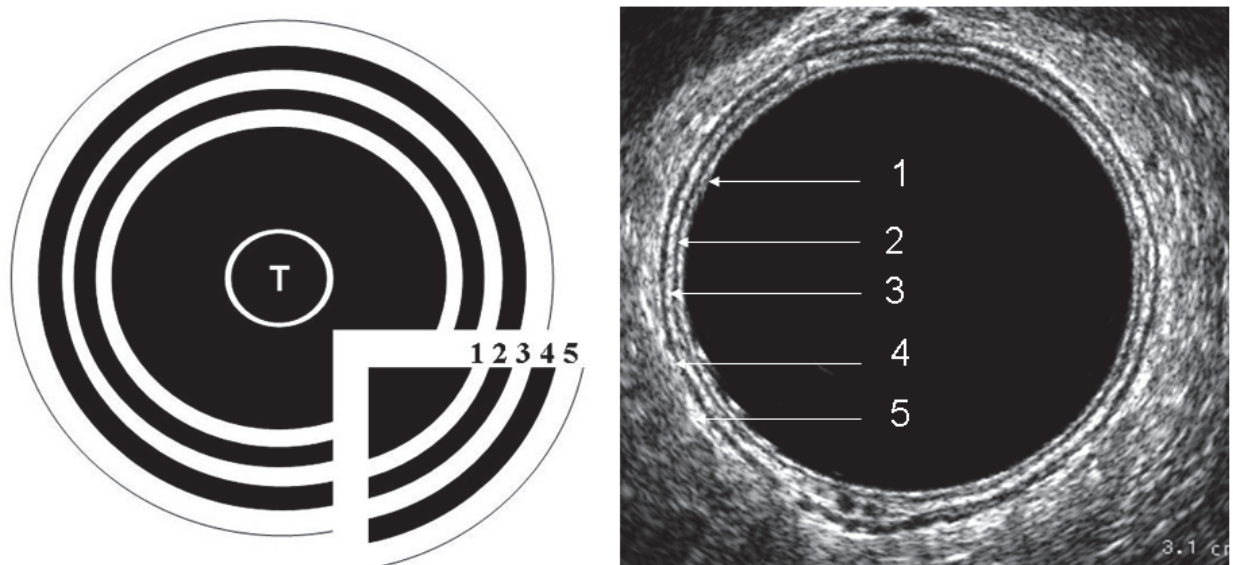
The examiner should never try to push the tip through a narrow stenotic lesion. However, in most instances, passage can be achieved although the volume of the fluid in the balloon should be substantially reduced in order to withdraw the probe through the stenotic portion of a lesion. In some instances it may be necessary to use a smaller probe, 7mm in diameter (vs. 17mm of the 2050 B-K probe). The amount of water used to fill the balloon is usually 50-60 ml, but sometimes it may be increased to provide complete acoustic coupling with the rectal wall. The examiner should never distend the balloon with more than 150ml of degassed water, as it may rupture. If this occurs, the probe must be removed from the rectum and cleaned, a new balloon installed, and the whole procedure restarted. If air, blood or stool gets between the balloon and the rectal wall, it will prevent correct visualization of the rectal wall. To avoid this, we administer an enema two hours before the examination. The rectum can also be gently irrigated prior to passage of the probe. It may, however, be necessary to remove the probe to further irrigate the rectum under direct vision to achieve the complete cleansing of the rectum. The proctoscope and ultrasound probe may then be reintroduced to repeat the ultrasound examination with optimal images.

With the patient is in the Sims position, by convention, we report the image in a clockwise manner; the anterior aspect of the rectum will be superior (12 o'clock) on the screen, right lateral will be left (9 o'clock) on the screen, left lateral will be right (3 o'clock) on the screen, and posterior will be inferior (6 o'clock) on the screen (as in the image on the axial CT scan). Once the 20cm scored mark on the shaft of the probe is at the proximal end of the proctoscope, the proctoscope is then pulled back on the probe as far as possible, thus exposing the transducer for at least 4 cm beyond the end of the proctoscope. The balloon is then instilled with 30-60cc of water, the volume of fluid usually needed to gain optimal imaging. Higher frequencies provide better resolution of the sphincter muscles and of the rectal wall layers, whereas pararectal tissue and lymph nodes are more accurately assessed using lower frequencies. To achieve the most accurate staging, biopsy should be performed after ERUS or at least three weeks before, otherwise, the accuracy of the exam could be significantly altered by edema or clots that could interfere with the correct evaluation of the case, understaging or overstaging the neoplasm (14). For a correct examination it is of particular importance to keep the probe at the center of the rectal ampulla, with the balloon filled. The entire tumor should be scanned because depth of infiltration could vary at different points of the tumor itself. The perirectal fat is examined for suspicious lymph nodes. The search for lymph nodes should be made in the proximal part of the tumor (15). 3D spatial reconstruction will aid in the differentiation between nodes and vascular structures. Images are usually obtained using an ultrasound frequency of 10 to 16MHz, depending on which part of the rectum is being examined. Higher frequencies provide better resolution of the sphincter muscles and the rectal wall layer, whereas pararectal tissues and lymph nodes are more accurately assessed using lower frequencies (16). Complications of this technique have not been reported. Manipulation of the tumor by a transducer often exacerbates tumor bleeding for a short period. The possibility of perforation through the tumor by a rigid probe is always a hazard, but so far, it has not been reported.

4. Ultrasound anatomy

Sonographic characteristics of the rectal wall have been well described (1, 17). It consists of five layers, three hyperechoic layers separated by two hypoechoic layers (Figure 1). Debate

continues over how these two sets of layers correspond. The first hyperechoic line correspond to the interface between the balloon and the mucosa. The second hypoechoic line corresponds to the mucosa, muscularis mucosa, and submucosa. The third hyperechoic line represents an interface between the submucosa and muscularis propria. The fourth hypoechoic line represents the muscularis propria. The fifth hyperechoic line represents an interface between the muscularis propria and perirectal fat/serosa (17). Good visualization depends on maintaining the probe in the centre of lumen of the rectum and having adequate distension of the water-filled balloon with good acoustic contact with rectal wall. Attention must be focused on the third hyperechoic layer. Once it has been ascertained that the middle hyperechoic line is broken, then an invasive lesion is recognised and attention is then turned to the thickness of the muscularis propria and the integrity of the outer hyperechoic line to see if the perirectal fat is invaded. Rectal tumors appears as hypoechoic lesions that infiltrate, interrupt and distort different wall layers and are staged according to the level of invasion through the rectal wall. The fibrofatty tissue surrounding the rectum contains blood vessels, nerves and lymphatics and has an inhomogeneous echo pattern. Very small, 2-3mm, round to oval hypoechoic lymph nodes may be seen and must be distinguished from blood vessels, which are also circular hypoechoic areas, but when followed longitudinally, they are seen to extend further than the corresponding diameter and can often be seen to branch and elongate in a longitudinal fashion, confirming that this is a blood vessel and not a node.



- 1: Interface, hyperechoic; 2: Mucosa/Muscularis M., hypoechoic
 3: Submucosa, hyperechoic; 4: Muscularis propria, hypoechoic
 5: Perirectal Fat/ Serosa, hyperechoic

Fig. 1. The sonographic five-layer structure of the rectal wall consists of three hyperechoic layers separated by two hypoechoic layers

Metastatic lymph nodes appear as hypoechoic round masses in mesorectal fat. They tend to be larger, not homogeneous and more round, with well-defined borders. Rifkin has suggested that if nodes measure more than 3mm they are suspicious for metastatic disease (18). The pattern, however is not specific, and lymph nodes enlarged by inflammation may have an identical pattern (1). Normal lymph nodes are probably not visualized. Prominent draining veins are also hypoechoic, but in some instances can mimic a node, although their branching configuration makes the vascular structures easily detectable with 3D reconstruction. If there is any doubt, it can be used probe that can provide Doppler interrogation. In addition, with appropriate wire guides, needle aspirates for cytological assessment (FNAC) can be obtained. ERUS also may visualize perirectal anatomical structures. The upper anal canal has as landmark the puborectalis muscle. Additional structures that may be seen include the seminal vessels, prostate, bladder, and urethra in males and the vagina, uterus and bladder in females. Loops of small bowel may occasionally be noted.

Tranperineal and endovaginal ultrasound may be complementary modalities of imaging, but are more useful in assessing structural and functional aspects of the pelvic floor.

5. Rectal cancer staging

On ERUS, rectal tumors are staged according to the level of invasion through the rectal wall, corresponding to the stages of the TNM classification. To differentiate between ultrasonographic staging and pathologic staging, ultrasound stages are labeled with the prefix "u". Hildebrandt (1) was the first to propose an ultrasonographic staging of rectal cancer according to the TNM classification (Table 1). In this staging were proposed only two N stages: N0 if no nodes involved are present and N1 if metastatic nodes are identified.

uT0	Benign lesion or in situ neoplasm
uT1	Cancer infiltrating submucosa
uT2	Cancer infiltrating muscularis propria
uT3	Cancer infiltrating the rectal wall through serosa or perirectal fat
uT4	Cancer infiltrating perirectal organs or structures
uN0	No regional metastatic nodes
uN1	Metastatic nodes

Table 1. Ultrasonographic staging of rectal cancer by Hildebrandt and Feifel

In general ultrasonographic practice, it can be very difficult to make a clear distinction between a deep tumor of one T-stage and an early tumor of the next T-stage. For this reason, a revised ultrasonographic rectal staging was proposed by the Sloan Kettering Cancer Center (19). Sub-stages for indeterminate depth of tumor invasion (T) were described and the presence of perirectal nodes was defined as: definite, probable, or equivocal (Table 2).

uT0	Benign lesion or in situ neoplasm
uTw	Benign lesion or cancer initially infiltrating submucosa
uT1	Cancer infiltrating submucosa
uTx	Advanced T1 or early T2 tumor
uT2	Cancer infiltrating muscularis propria
uTy	Advanced T2 or early T3 tumor
uT3	Cancer infiltrating the rectal wall through serosa or perirectal fat
uTz	Advanced T3 or early T4 tumor
uT4	Cancer infiltrating perirectal organs or structures
uN0	No regional metastatic nodes
uN1	<3 malignant perirectal lymph nodes
uN2	>3 malignant perirectal lymph nodes
uNx	Perirectal nodes not evaluable

Table 2. Ultrasonographic staging of rectal cancer by Sloan Kettering Cancer Center

5.1 Stage uT0: Villous adenoma

Sonographic evaluation of a villous rectal lesion is useful in determining the presence of infiltrating tumor. The presence of an intact hyperechoic submucosal interface indicates lack of tumor invasion into the submucosa (Figure 2). Heintz et al. (20) believe that ERUS cannot distinguish between villous adenoma and invasive cancers because neither the muscularis mucosae nor the submucosa are sonographically visible and the first hypoechoic layer corresponds anatomically to the mucosa and the submucosa. They suggest that uT0 and uT1 tumors, which manifest as a broadening of the first hypoechoic layer, should be classified together. Instead, Adams and Wong (21) disagree with this interpretation and consider the first hypoechoic layer as the mucosa and muscularis mucosae and the middle hyperechoic layer as the submucosa. Consequently, these authors consider lesions that expand the inner hypoechoic layer but are surrounded by a uniform middle hyperechoic layer to be villous adenoma; lesions that expand the inner hypoechoic layer and have distinct echo defects of the middle hyperechoic layer are considered uT1 tumors. Technical difficulties associated with scanning villous adenoma may be due to very large lesions that tend to attenuate rectal layers and lesions with a very large exophytic component (Figure 3). In large carpeting lesions, careful evaluation of the entire tumor is necessary to ensure that a small area of invasion has not been overlooked. In some polyps, the complex structure produces fixed artefacts over a portion of the rectal wall, obscuring the image. Snare biopsy of lesions before referral to ERUS produces a burn artifact, that may lead to tumor overstaging.

5.2 Stage uT1: Submucosal invasion

If a tumor arises in a polyp it is important to determine whether the stalk is invaded. Differences in classification are reported between Western and Japanese pathologists. In 1985 Haggit et al. (22) divided the depth of invasion into four levels:

Level 0, carcinoma in situ or intramucosal carcinoma;

Level 1, carcinoma invading through the muscularis mucosa into the submucosa but limited to the head of the polyp;

Level 2, carcinoma invading the level of the neck of the adenoma;

Level 3, carcinoma invading any part of the stalk;

Level 4, carcinoma invading into the submucosa of the bowel wall below the stalk of the polyp. By definition, all sessile polyps with invasive adenocarcinoma are Level 4.

They studied 129 patients with pTis to pT1 colorectal tumors and noted that Level 4 invasion was a statistically significant factor ($p < 0.001$) predicting positive nodes. Similar results were reported by Nivatvongs et al. (23) on 151 patients with pT1 colorectal tumors undergoing bowel resection in which invasion into the submucosa of the bowel wall at the base of the stalk (Level 4) was the single most significant risk factor for positive nodes. For sessile polyps the risk was 10% and for pedunculated polyps 27%. Suzuki et al. (24) determined the risk of lymph node metastases in 65 patients having Haggitt's Level 4 invasion into the submucosa. Lymph node metastasis was noted in 11 (16.9%) of the 65 patients, however the width of submucosal invasion was significantly greater in node-positive than in node-negative patients ($p = 0.001$). When 5mm wide submucosal invasion was used as an indicator for intestinal resection, 37 patients were found to have indications for bowel resection and 11 (29.7%) had lymph node metastases. The positive predictive value increased from 17 to 30% when the width of submucosal invasion was added to Haggitt's Level 4 as an indicator for bowel resection. Seitz et al. (25) suggested that Haggitt's classification applies well for pedunculated polyps, however it should not be used for malignant sessile polyps.

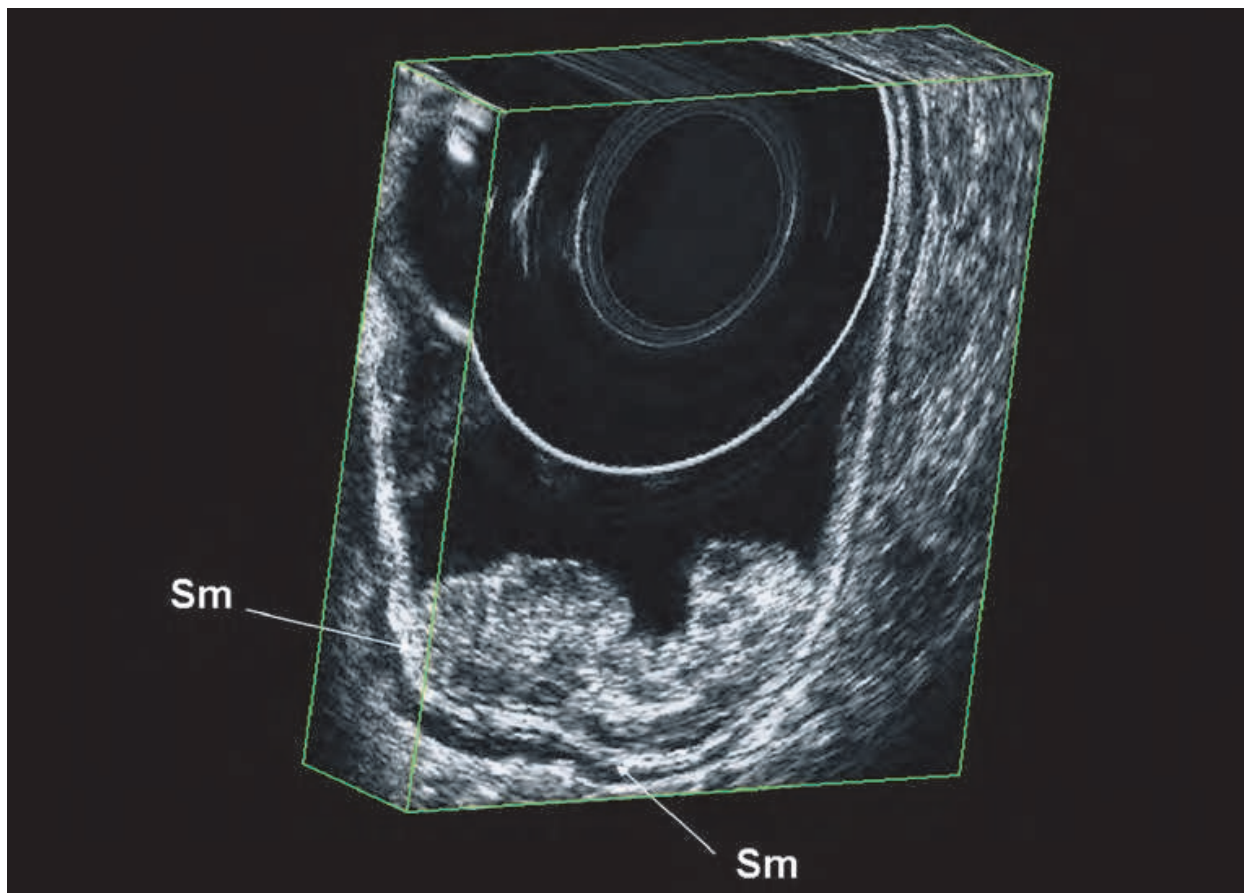


Fig. 2. Villous rectal lesion are characterized at ultrasonography by a broadening of the first hypoechoic layer and an intact hyperechoic submucosal interface

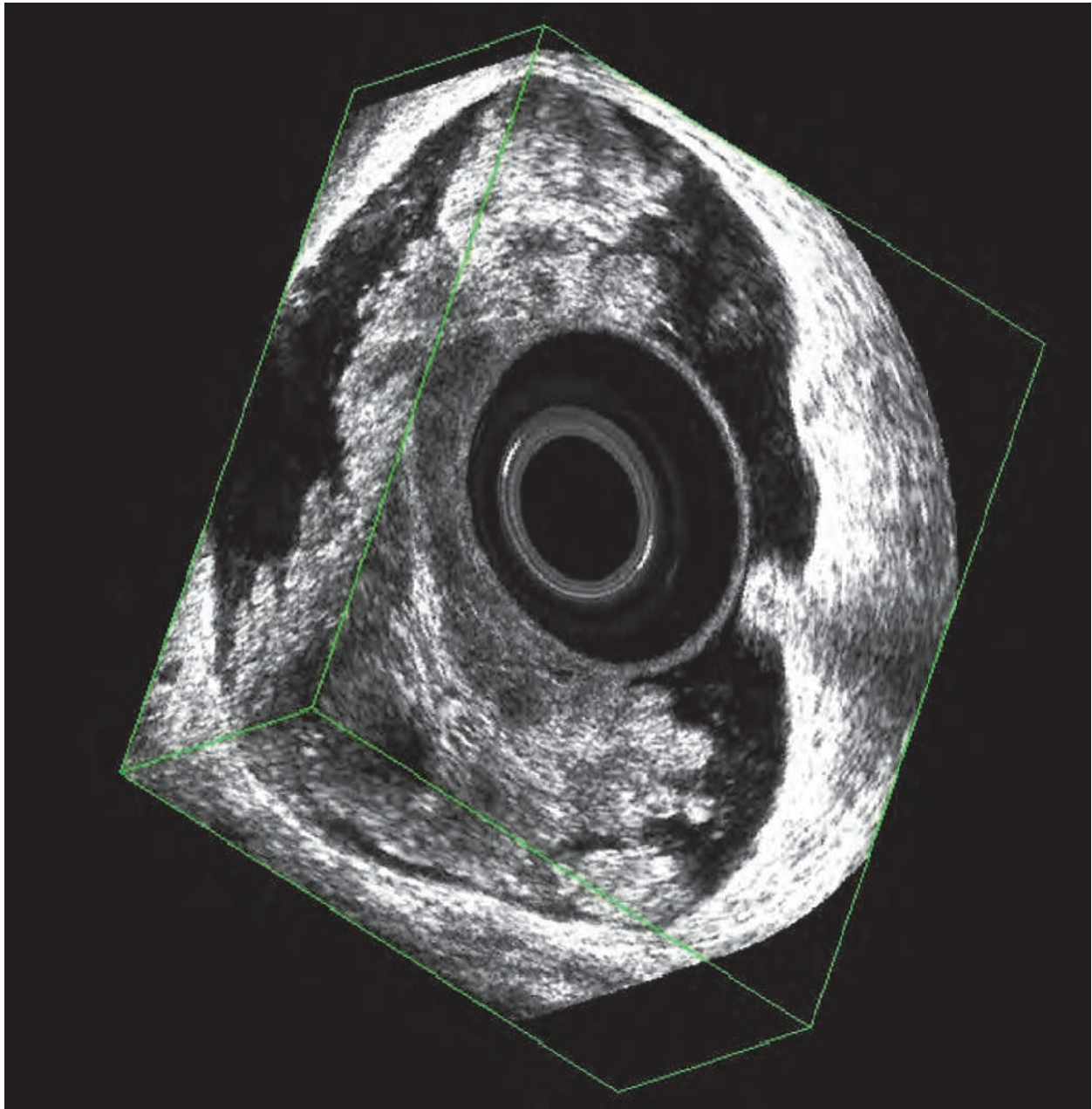


Fig. 3. Very large exophytic villous adenoma may cause technical difficulties during scanning

Kudo et al. (26) were the first to differentiate three different types of early invasive cancers:

1. SM-1 tumor, invading the superior third of the submucosa;
2. SM-2 tumor, invading the superficial two thirds of the submucosa;
3. SM-3 tumor, invading the deep third of the submucosa.

Type SM-1 tumors were further subdivided in three subtypes:

1. SM-1a: invasion is $<1/4$ of the submucosa;
2. SM-1b: invasion is $<1/2$ of the submucosa;
3. SM-1c: invasion is $>1/2$ of the submucosa.

Kikuchi et al. (27) found that the risk of lymph node metastasis was 0% for SM-1 lesions, 10% for SM-2 lesions and 25% for SM-3 lesions ($p < 0.001$). In their study the SM-3 was the

only independent risk factor for lymph node metastasis. Akasu et al. (28) recently proposed a classification of the depth of submucosal cancer into two groups:

1. SM-slight (SM-s), tumor invasion limited to the upper third of the submucosa;
2. SM-massive (SM-m), tumor invasion extended to the middle or lower third of the submucosa.

In their series, the prevalence of lymph node metastasis in pTis, pT1-slight and pT1-massive were 0%, 0% and 22%, respectively. Thus massive submucosal invasion can be considered a risk factor for lymph node metastasis. They suggested that patients with massive submucosal invasion are best treated by radical surgery. A recent study from Mayo Clinic confirmed these data (29). Among patients with T1 carcinoma in the middle or lower third of the rectum the multivariate risk factors for long-term, cancer-free survival was invasion into the lower third of the submucosa. For lesions with SM-3 invasion, the radical surgical resection group had lower rates of distant metastasis and better survival compared with patients who underwent local excision (29, 30). Therefore a decision whether to perform radical surgery or local excision or polypectomy should be based principally on assessment of submucosal invasion depth.

Our ERUS criteria to determine the depth of tumor invasion are as follows:

1. benign lesion (uT0): hypoechoic mass within the second hypoechoic mucosal layer. The submucosal hyperechoic layer remains intact around the entire breadth of the tumor; Carcinoma in situ (pTis) is included in this group because it cannot be differentiated from benign adenoma by ultrasound imaging alone;
2. submucosal cancer (uT1): tumor invading the submucosal layer. These lesions are stratified into two subtypes: uT1-slight (slightly irregularity of the submucosa) (Figure 4) and uT1-massive (massive irregularity) (Figure 5). Small focal disruption of the submucosal layer but with the fourth hypoechoic muscular layer intact are also classified as uT1-massive tumor;
3. lesions with distinct break of the submucosal layer and invasion of the muscular layer (uT2).

Over- and under-staging of rectal tumors continues to be a problem with ERUS due to a variety of well-documented causes as reported by Adams and Wong (21) and Kim et al. (31). A source of error can be due to the compression of the rectal wall by the water-filled balloon. To prevent any distortion of the lesion or separation of the balloon from the rectal wall with the interposition of non-conductive air between the probe and the rectum, a sufficient quantity of water can be instilled to fill the entire rectum. In this case the transducer is covered with a condom that does not cause compression of the rectal wall as with the balloon. A source of errors in the evaluation of early rectal cancer by ERUS can also frequently be caused by examiner misinterpretation or a tendency to overestimate a malignant lesion because of concern for under-treatment despite clear ERUS imaging.

5.3 Stage uT2: Invasion of the muscular layer

Sonographic diagnosis of tumor invasion of the muscularis propria is based on thickening of this layer (Figure 6). The muscularis propria is represented by a thin hypoechoic layer adjacent to the hyperechoic submucosal interface. As the tumor is also hypoechoic, early muscular invasion is difficult to detect. The surrounding hyperechoic layer corresponding to the perirectal fat interface remains intact. Lymph node metastases occur in approximately 15-20% of patients with T2 tumors. ERUS is important to distinguish uT2 and uT1 lesions, because local therapy is not routinely recommended for uT2 rectal lesions (30).

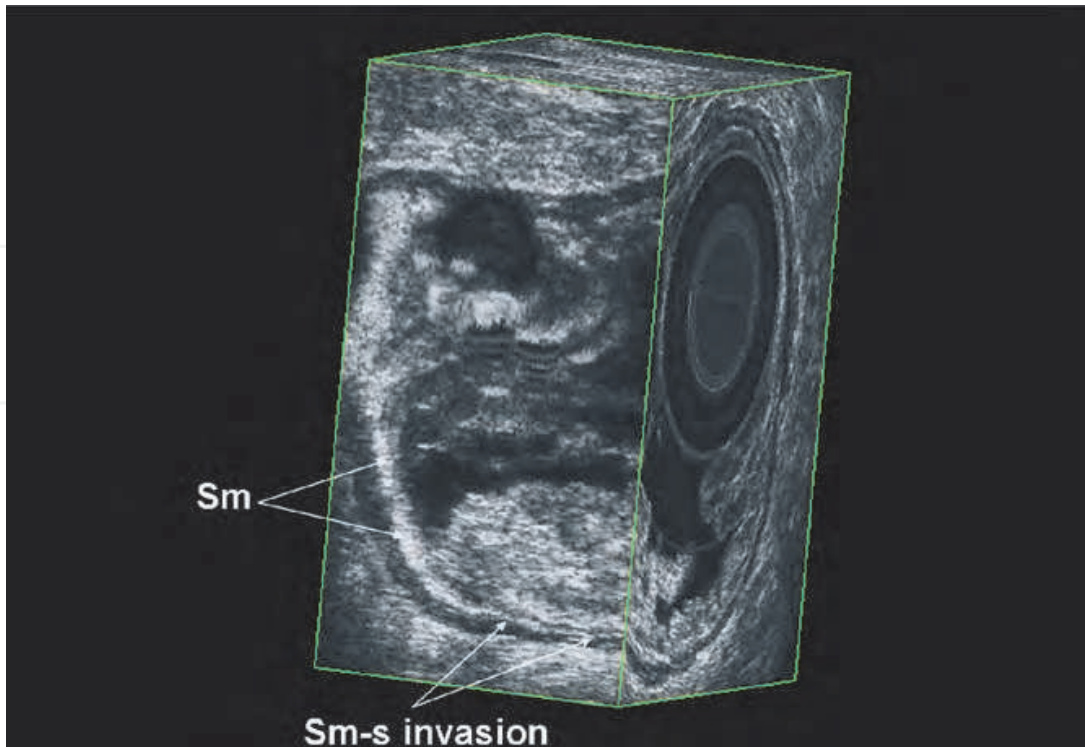


Fig. 4. uT1-slight cancer are characterized at ultrasonography by a broadening of the first hypoechoic layer and a slightly irregularity of the hyperechoic submucosal interface

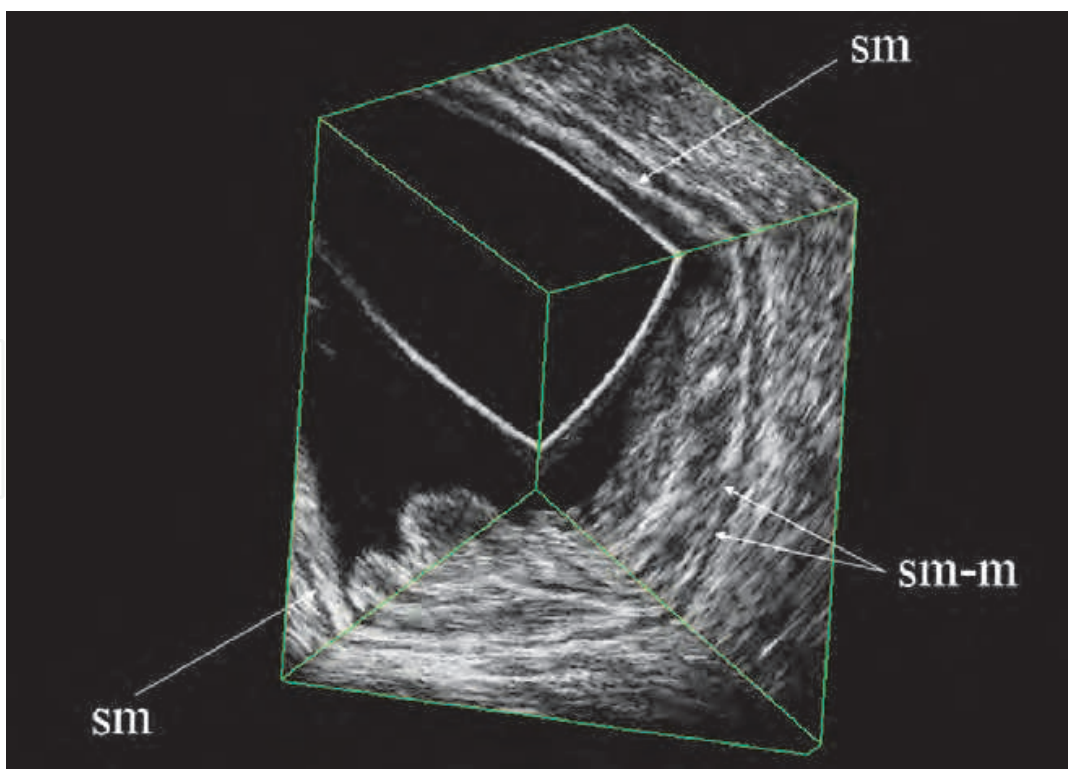


Fig. 5. uT1-massive cancer are characterized at ultrasonography by a broadening of the first hypoechoic layer and a massive irregularity or a small focal disruption of the hyperechoic submucosal interface. The fourth hypoechoic muscular layer appears intact

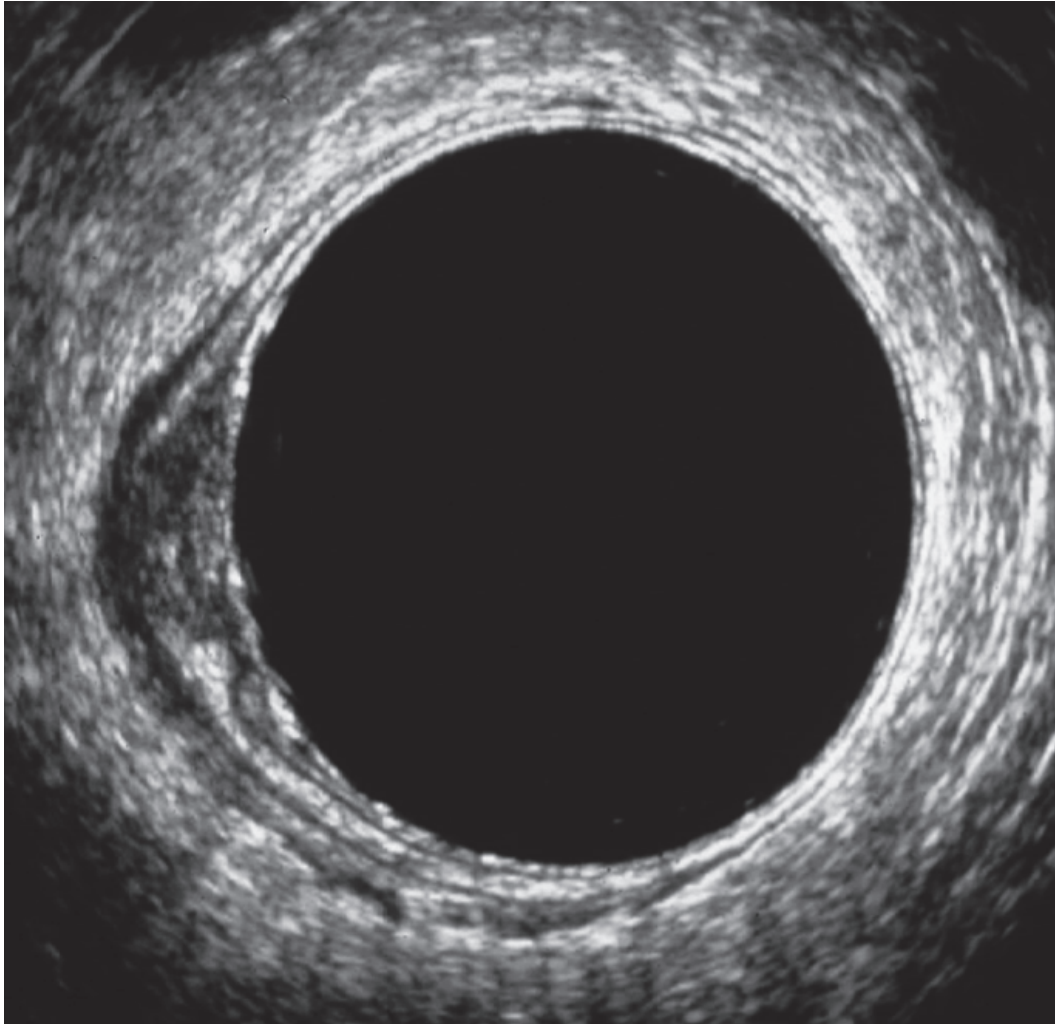


Fig. 6. Sonographic diagnosis of tumor invasion of the muscularis propria (uT2) is based on thickening of this layer

Overstaging is a particular problem with T2 tumors. Among the interpretative errors, severe inflammatory infiltrate underlying a tumor, which is sonographically indistinguishable from malignant tissue, can prohibit accurate evaluation of tumor invasion and appears to cause inevitable errors (32, 33). Understaging, on the other hand, may be caused by a failure to detect microscopic cancer infiltration owing to the limits of resolution of the equipment (32, 33, 34).

5.4 Stage uT3: Perirectal fat invasion

Perirectal fat invasion is diagnosed sonographically by the presence of irregularity of the outer hyperechoic layer that corresponds to the perirectal fat interface. These findings should be associated with disruption of the hyperechoic layer corresponding to the submucosa and thickening of the hyperechoic layer representing the muscularis propria (Figure 7). Contiguous organs are not involved. About 10% of such tumors are, however, accompanied by a narrowing of the lumen or angulation that may render it difficult or impossible to advance the probe proximal to the tumor. To perform a complete staging by ERUS, a residual lumen of 2cm is necessary. Under these circumstances the study may be incomplete and the presence of enlarged lymph nodes may not be ascertained accurately

because nodes are often located proximal to the tumor. The prevalence of regional lymph node metastases in uT3 tumors is approximately 30-50%.

The recognition of perirectal fat invasion is an important determination to select appropriate patients for pre-operative combined chemotherapy and radiation therapy followed by surgery. One of the most important drawbacks in endosonographic staging is the distinction between T2 tumors invading most of the muscularis propria and T3 tumor which slightly invades the perirectal fat. Indeed most errors are understaging of small pT3 tumors or overstaging of pT2 tumors (35, 36).

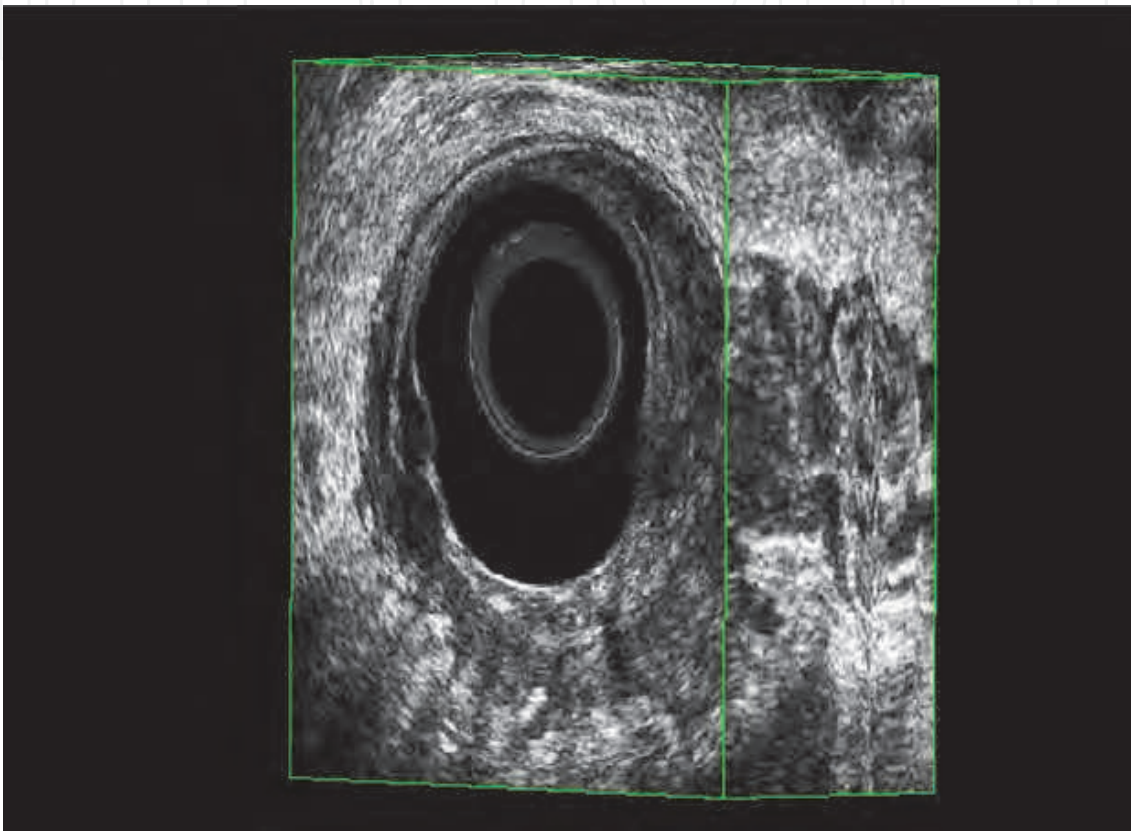


Fig. 7. Perirectal fat invasion (uT3) is diagnosed sonographically by the presence of irregularity of the outer hyperechoic layer that corresponds to the perirectal fat interface

5.5 Stage uT4: Extensive local invasion

uT4 lesions are locally invasive into contiguous organs such as bladder, uterus, cervix, vagina, prostate and seminal vesicles (Figure 8). These advanced lesions are clinically fixed or tethered. Sonographically there is a loss of the normal hyperechoic interface between the tumor and the adjacent organ. The inability of ERUS to distinguish between malignant infiltration or peritumoral inflammation results in a somewhat lower staging accuracy with regard to T4 cancers. Frank stenosis also precludes precise endosonographic evaluation and angulation of the probe to the tumor axis also can cause misinterpretation.

5.6 Stage uN1-2: Lymph node metastases

Metastatic involvement of the mesorectal lymph nodes is a major independent prognostic factor. It has been observed that the presence of more than three nodes is associated with a

poor prognosis. Moreover, identification of a metastatic perirectal lymph node is important as these patients may benefit from pre-operative adjuvant radiotherapy and some of the early T1 or T2 lesions with mesorectal node involvement are not suitable for local excision. Sonographic evaluation of lymph node metastases is somewhat less accurate than depth of invasion (16, 18, 19, 34, 35). Undetectable or benign appearing lymph nodes are classified as uN0. Malignant appearing lymph nodes are classified as uN1 (<3 lymph nodes) or uN2 (>3 lymph nodes). Normal, non-enlarged perirectal nodes are not usually seen on ERUS. The criteria used to identify metastatic lymph nodes in most of the studies are echogenicity, border demarcation and node diameter. Inflamed, enlarged lymph nodes appear hypoechoic, with ill defined borders. Most of the sound energy is reflected because the lymphatic tissue has not changed. In contrast, metastatic lymph nodes that have been completely replaced by the tumor do not provide the normal tissue architecture and appear hypoechoic with an echogenicity similar to the primary tumor. Malignant lymph nodes tend to be round in shape rather than oval, have discrete borders and are most commonly found adjacent to the primary tumor or in the mesorectum proximal to the tumor (15) (Figure 9).

The sonographic features of lymph nodes generally can be distinguished into four groups:

1. if lymph nodes are not visible by ultrasound, the probability of lymph node metastasis is low;
2. hyperechoic lymph nodes are often benign and result from non-specific inflammatory changes;
3. hypoechoic lymph nodes larger than 5mm are highly suggestive for lymph node metastasis;
4. lymph nodes larger than 5mm with mixed echogenic patterns cannot be classified accurately but should be considered metastatic.

On size characteristic alone, sonographically detected nodes in the mesorectum greater than 5mm in diameter have a 50-70% chance of being involved, whereas those smaller than 4mm have less than 20% chance. However, up to 20% of patients have involved nodes of less than 3mm, limiting the accuracy of the technique. Hulsmans et al (37) studied several features by correlating pathologic and sonographic findings in the lymph nodes of specimens obtained from a series of 21 consecutive patients with resected rectal cancer. These features included ratio of long axis to short axis diameter, referred as to roundness index; lobulations (multiple notches); echogenicity; not homogeneous; border delineation; presence of an echo-poor rim (the outer rim being more hypoechoic than the rest of the node); presence of a peripheral halo; and presence of a hilar reflection. The authors showed that three ultrasonographic features of a node significantly correlated to it being benign or malignant at histopathologic examination are: short axis diameter, degree of inhomogeneity and the presence or absence of hilar reflection.

Overstaging and understaging may occur during assessment of lymph node involvement. Edematous lymph nodes transmit more sound energy and have an echogenicity similar to metastases. The cross-sectional appearance of blood vessels in the perirectal fat may be commonly confused with positive lymph nodes. The sonographic continuity of hypoechoic vessels over a distance greater than the cross-sectional diameter is the criterion used to distinguish vessels from hypoechoic lymph nodes. With careful scanning, blood vessels appear to branch or extend longitudinally. In addition, it may be difficult to differentiate islands of tumor outside the bowel wall from involved nodes. With careful scanning, one can demonstrate continuity with the main tumor that may not have been recognised initially. Even with an improved understanding of the characteristic of malignant lymph

node and utilizing criteria of shape, echogenicity and border features, micrometastases and granulomatous inflammation will remain difficult, if not impossible, to differentiate by ERUS. If a whole node is replaced by tumor or the node is enlarged secondary to it, detection is more likely. However, if only a small deposit or a micrometastasis is present in a node, the characteristics of the node are unlikely to be sufficiently altered to allow detection. This explains in part the lower accuracy rate for lymph node detection with current, conventional ultrasonography. Grossly malignant lymph nodes located at a distance from the primary tumor also remain undetected if they exceed the depth of penetration of the transducer. This is particularly true for nodes in the proximal mesorectum out of the length of the probe. To obtain high sensitivity and high specificity, the combination of a small cutoff value and ERUS-guided fine needle aspiration biopsy may be helpful.

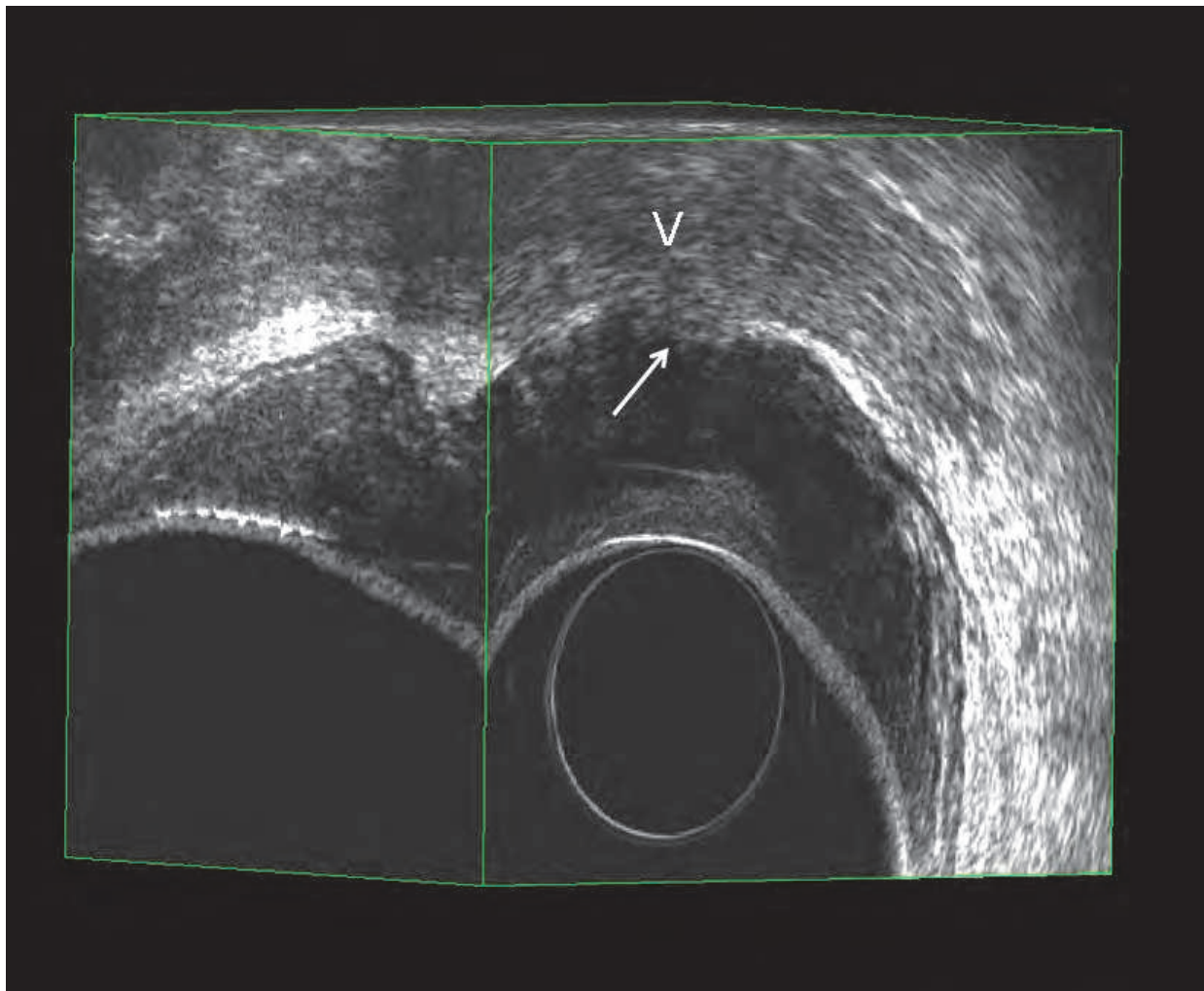


Fig. 8. uT4 lesion with invasion of the vaginal wall

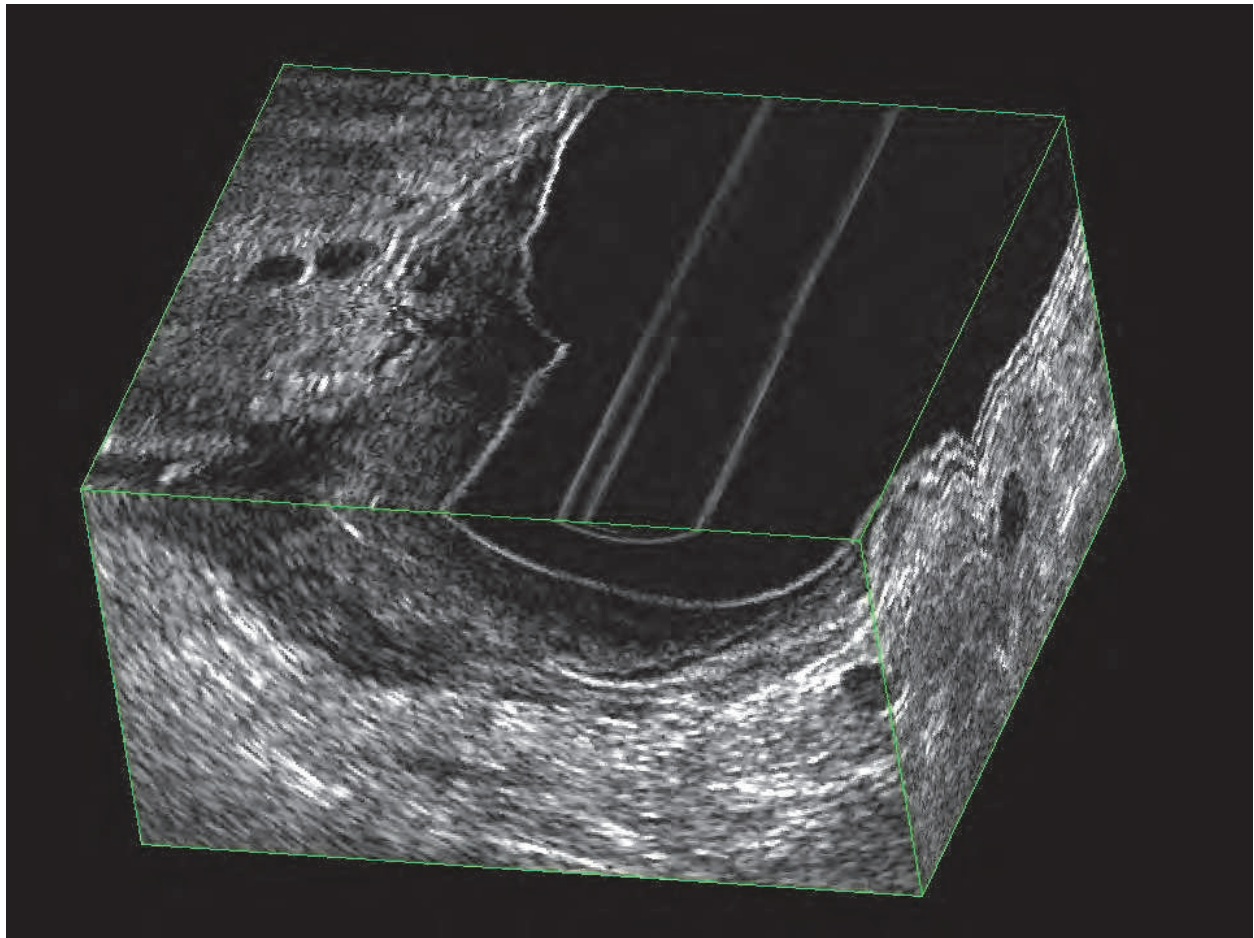


Fig. 9. Malignant lymph nodes appear as round hypoechoic structure, with discrete borders, adjacent to the primary tumor

6. Discussion

The improved understanding of rectal cancer biologic behavior mandates for a correct staging of the disease to allow tailored treatment in relation to the stage of the tumor. There is general agreement that villous adenomas with focal areas of carcinoma in situ and early T1 rectal cancers are best treated with local surgery, whereas advanced T1 and T2 rectal cancers because of the well known risk of associated nodal metastases, are best cured with radical surgery. Early T3 cancers may be safely treated with radical surgery alone or a short course of preoperative radiotherapy, while advanced T3, T3N1-2, T4N0-1-2 lesions mandate neoadjuvant chemotherapy-radiotherapy regimens to attempt to downstage the tumours (38, 39). Furthermore, staging is linked to ultimate prognostic outcome of the patient.

Systemic staging of rectal cancer is best achieved by contrast-enhanced thoraco-abdomino-pelvic multidetector CT scan. This is justified by the general availability of the device, the costs and the short duration time of the examination required to achieve good quality images and for the ability to reconstruct images into planes other than the axial plan alone (e.g. sagittal, frontal, oblique planes). For local staging of rectal cancer, CT accuracy is limited by the intrinsic difficulty to define the layers of rectal wall and thus the depth of penetration of the lesion. In the study of Rifkin et al. (18), 81 patients underwent CT and ERUS for staging purposes of rectal cancer; the accuracy of CT in assessing depth of rectal

wall invasion was 53%, compared with 72% for ERUS. Beynon et al. (40) compared ERUS to CT for the evaluation of mesorectal nodal status; they found that the accuracy of CT was only 57%, compared with 87% for ERUS. More recently Herzog et al. (41) examined 87 patients who underwent both CT and ERUS; they found accuracy of CT to be 74.7%, whereas ERUS had an accuracy of 90.8%. In the study of Goldman et al. (42) the accuracy in defining perirectal fat invasion was 52% for CT scanning vs. 81% for ERUS; the accuracy was respectively 64% vs. 68% for lymph node metastases. The best results in rectal staging with CT scan are reported by Civelli et al. (43) with an accuracy of 86.8% for T3 stage, a sensitivity of 100% and a specificity of 78.7%. In lymph node staging, the referred accuracy was 73.6%, sensitivity was 52.6% and specificity was 85.3%. In summary, the accuracy of CT is highly variable and should not be used as a sole method of staging rectal cancer (42).

ERUS is currently the most widely used and effective staging modality in the local assessment of rectal cancer. Its accuracy in numerous trials ranges from 80 to 95% for T-staging and 70 to 75% for N-staging, levels that are slightly higher than the respective 75 to 85% and 60 to 70% reported with MRI (44). In experienced hands, ERUS can accurately measure size, circumference and distance of the tumor from various anatomic landmarks (e.g. sphincters, prostate, vagina, seminal vesicles, mesorectal fascia, etc.) and gives indications to radiotherapists to plan irradiation fields (depth and length of infiltration). Furthermore it is capable of examining the anal sphincters for defects as well as tumor infiltration, allowing the surgeon to decide whether a sphincter-saving resection is safe or feasible (45). The accuracy of ERUS has been assessed in many studies and the main evidence emerged has been that T-staging accuracy varies relative to tumor stage. ERUS tends to be less accurate in staging T2 rectal cancers that are often overstaged (44, 46, 47). Orrom et al. (48) evaluated 59 patient who underwent ERUS and radical resection for rectal cancer. The patients were divided into three categories chronologically based on user experience. Group 1 had no standardization of the operator who performed the exam. The accuracy of this group was only 58%, with 37% of lesions that were overstaged and 4% of tumors that were understaged. Group 2 was based on a better standardization in the performance of the exam. In this group a proctoscope was used to improve localization of the rectal cancer. The accuracy increased to 77%, with 20% of cancers overstaged and 3% understaged. Group 3 adopted the widely accepted division of rectal wall into five layers. Accuracy rate increased to 95% with only 5% overstaging and no understaging. Garcia-Aguilar et al. (47) undertook a large retrospective study to assess the accuracy of ERUS on 545 patients, who underwent rectal surgery without neoadjuvant treatment. The overall accuracy of ERUS in assessing depth of penetration of the tumor into the rectal wall was 69%, with 18% of tumors overstaged and 13% understaged. Furthermore, ERUS correctly staged most villous adenomas (accuracy 87%) but less than half of T1 tumors (accuracy 47%). A selection bias of this study is represented by the exclusion from the final analysis of all patients (270 patients) who received neoadjuvant radiation/chemotherapy. A systematic literature review from Worrell et al. (49) showed that ERUS correctly established a cancer diagnosis in 81% of 62 biopsy-negative rectal adenomas which had focal carcinoma on histopathology. Beynon (50) examined 111 patients, of whom 100 underwent surgical resection; the accuracy was 93% for tumor staging, and the sensitivity for T3 and T4 stage was 98.7%. Overstaging occurred in 5% cases and understaging occurred 2% of cases. Two recent meta-analysis, based the first on 11 studies reported that the sensitivity of ERUS in correctly staging T1, T2, T3, T4 rectal cancers was 84%, 76%, 88%, 87% respectively (51). The

second recent meta-analysis comprised 31 studies and reported ERUS sensitivity rate related to the stage of 76%, 75%, 88% and 87% respectively (52).

The sensitivity and specificity of ERUS in staging rectal cancer after polypectomy was evaluated in two papers. Garcia-Aguilar et al. (53) assessed 63 patients with malignant rectal polyps removed by snare excision at colonoscopy. ERUS accuracy in evaluating the presence of residual cancer in the rectal wall was 54%, with 39% of positive predictive value and 65% of negative predictive value. Furthermore ERUS accurately identified metastatic lymph nodes in two of three patients who had radical surgery. ERUS was more useful than polyp morphologic and histologic criteria to determine the presence of residual cancer in the rectal wall. Kruskal et al. (54) reported 18 patients who had ERUS staging before surgical resection for adenocarcinoma discovered in polypectomy specimens (5 transanal surgery, 13 endoscopic surgery). ERUS correctly predicted T stage in eight patients (44%); seven tumors (39%) were overstaged and three tumors (17%) were understaged. In this study, ERUS showed a sensitivity of 94%, specificity of 50%, accuracy of 89%, positive predictive value of 94% and negative predictive value of 50%. They concluded that ERUS facilitates surgical planning and should be considered the technique of choice in staging this patient population, always keeping in mind the limits of ERUS staging when performed after biopsy or polypectomy (edema, blood clots, and inflammatory reaction) could interfere with a good imaging, leading to over- or understaging the tumor.

A recent study (55) evaluated 142 patients to characterize slight or massive irregularity of the hyperechoic submucosal layer to differentiate uT1-slight or uT1 massive tumors. ERUS correctly detected the depth of invasion in 87.2% of patients with a concordance between ultrasonographic and histopathologic staging of kappa 0.81 (95% confidence interval). The recognition of early from massive T1 rectal cancers consequently selected the appropriate management in 95.2% of cases. Akasu et al. (28) reported the result of a study on 154 patients with early stage rectal cancer preoperatively evaluated with ERUS. Sensitivity, specificity and overall accuracy rates for detection of slight or massive submucosal invasion were 99%, 74%, 96% and 98%, 88%, 97% respectively. Pikarsky (56) from Cleveland Clinic showed that ERUS confirmed the histopathologic diagnosis of rectal villous tumor without evidence of malignancy in 26 out of 27 patients. Konishi et al. (57) reported that the overall accuracy of ERUS-based evaluation of tumor invasion depth was 60% in villous lesions and 91% in non-villous lesions. In differentiating mucosa neoplasias (M)/ submucosal cancers with slight invasion (SM-s) from non M/SM-s the accuracy of ERUS in villous and non-villous lesions was 66% and 96%, respectively. Akahoshi et al. (58) improved the accuracy of ERUS by using a high-frequency ultrasound probe (12MHz). The depth of invasion was correctly assessed in 87% (46/53) of pT1 tumors. Stark et al. (59) reported their experience with high multifrequency probes. The sensitivity of ERUS with regard to invasion was 89% (16/18), specificity 88% (37/42), and accuracy 88% (53/60). They concluded that rectal endosonography can distinguish between benign rectal lesions and early invasive rectal cancers. Similar results were reported by Hunerbein et al. (60) with a high frequency miniprobe in the staging of colonic tumors. The infiltration depth was correctly classified in 78 of 88 patients (accuracy, 87%). We conducted a prospective study to compare accuracy of 3D-ERUS with high frequency probe to conventional 2D-ERUS in the preoperative staging of early invasive rectal cancer (61): eighty-nine consecutive patients with rectal villous lesions were examined using both 3D-ERUS and conventional 2D-ERUS. All lesions were resected either endoscopically or surgically. Malignant transformation was found in 35 rectal villous adenomas at histological examination. 2D-ERUS correctly determined the

depth of invasion of villous polyps in 6 of 7 M neoplasias (85.7%), 8 of 12 SM-s lesions (66.6%) and 12 of 16 SM-m lesions (75%), whereas the accuracy of 3D-ERUS was 85.7% for M neoplasias, 83.3% for SM-s and 87.5% for SM-m lesions. Overall accuracy of the 2D-ERUS based evaluation of villous lesions was lower than that of 3D-ERUS based evaluation (27/35, 77.1%, vs. 30/35, 85.7%), however there was no significant difference ($p=0.5$). In the evaluation of SM-s lesions the accuracy of 3D-ERUS was significantly superior to 2D-ERUS based evaluation ($p<0.029$). Tumor location and gross morphology (sessile or pedunculated) did not correlate with the accuracy of the T-staging. Eight of 54 pT0 tumors (14.8%) were overstaged by 2D-ERUS, while 5 of 54 (9.2%) were overstaged by 3D-ERUS. The prevalence of lymph node metastases in M, SM-s and SM-m lesions were 0%, 0% and 12.5%, respectively. These findings showed 3D-ERUS to have a significant advantage over 2D-ERUS for the accurate evaluation of superficial submucosal cancer invasion. Stereoscopic visualization provided easier and more complete understanding of depth of submucosal invasion.

Overstaging is a particular problem with T2 tumors. Peritumoral inflammation and desmoplastic changes are commonly causes of error, as both are difficult to differentiate from actual tumor borders. Overstaging may also be the result of preoperative biopsies, that can create hematomas, edema, clots due to bleeding and disrupt sonographic anatomy. Fear of understaging is another cause that has been described as responsible of overstaging in T2 rectal cancers (63). In general, the time interval between performance of diagnostic tests and the reference test (pathology on surgical specimen) should be short. A longer period between the performance of the diagnostic test and the reference test will lead to a greater change in the disease status and decrease in the discriminatory power of the diagnostic test. Potential bias of several studies is that the time elapsed between test and surgery was not described or was longer than the ideal of one week. In a prospective study Sailer et al. (62) examined the value of ERUS in the preoperative staging of 160 rectal tumors. For T2 tumors, the sensitivity was only 41% and the specificity 92% as the majority of pT2 rectal cancers were overstaged (uT3). The authors concluded that ERUS is not helpful in the assessment of T2 carcinomas. Katsura et al (64) reported that the predictive value of positive rate in the assessment of rectal wall invasion by ERUS was 96.2% in uT1 and 87.5% in uT2.

3D-ERUS offers a significant advantage over conventional 2D-ERUS for the accurate evaluation of rectal cancer. In a preliminary study, Kim et al. (65) showed that the accuracy of 3D-ERUS was 90.9% for pT2 whereas that of 2D-ERUS was 84.8%. It is of note that the classification system is highly reproducible through the use of cut-off points that are usually straightforward histologically, such as the distinction between T2 and T3 tumor depending on the invasion of the mesorectum or not. This does not always easily transfer to staging through imaging. All imaging methods are good enough to show the bulk of the tumor, but have difficulty in predicting the microscopic invasion of an interface. It is therefore unrealistic to expect 100% accuracy from imaging technology in predicting a histologic classification (66). Glaser et al. (67) reported that the sensitivity of ERUS for detection of perirectal fat infiltration (uT3) was 97%, specificity was 90% and positive predictive value was 90%. The inability of ERUS to distinguish between fat infiltration or peritumoral inflammation results in somewhat lower staging accuracy with regard to T4 cancers. In conclusion, the overall agreement between uT-stage and pTstage in the larger studies is 63% to 69%, with 12% to 15% understaging and 18% to 24% overstaging (44, 47, 68, 69). In these series there was understaging of uT1 between 6% to 24%, and of uT2 tumor from 16% to 30%. Overstaging in uT3 occurred in 20% to 28% of cases.

There is a marked reduction in survival rate in patients with rectal cancer and nodal metastases. Ultrasonographic criteria for distinguishing malignant from inflammatory lymph nodes are a source of controversy. The criteria of echogenicity and border characteristics are subjective, although at least one study has shown that as many as 72% of nodes with hypoechoic patterns are metastatic (70). Nodal size as a criterion to consider a node to be metastatic is a matter of debate. Whilst metastatic lymph nodes tend to be larger than normal nodes, the 3 to 5mm diameter used as a cutoff is quite arbitrary. Kim et al. (51) reported that roughly 18% of nodes measuring less than 5mm in diameter harboured metastases. Akasu et al. (28) found that the incidence of metastasis in nodes with diameter around 2mm, 3 to 5mm and >6mm was 9.5%, 47% and 87%, respectively. These data suggest that ERUS can miss up to 20% of these smaller nodes. The accuracy of ERUS in assessing lymph node involvement varies from 58% to 86% (35). In a recent meta-analysis by Puli et al. (71), in which only studies confirmed by surgical histology were selected, the sensitivity of ERUS in diagnosing nodal involvement by rectal cancers was 73.2% and specificity was 75.8%. In this meta-analysis was evaluated also the influence of fine needle aspiration (FNA) during the procedure that resulted in very low or not complications. However, there were not enough studies to draw definitive conclusions on the accuracy of FNA. The potential bias of this meta-analysis was that all the studies were either retrospective or consecutive, but no prospective studies were included. The authors concluded that sensitivity and specificity of ERUS for nodal involvement was moderate. It performs better when there is no anatomic nodal invasion than in the presence of anatomic nodal invasion. Further refinement in ERUS technologies and re-evaluation of diagnostic criteria based on prospective studies are needed to improve our diagnostic accuracy. The theoretic additional value of ERUS-guided FNA on suspicious nodes, was addressed by Siddiqui et al. (71). They found no benefits in using FNA, because all perirectal node large enough to be visualized by ERUS were confirmed to harbour metastases. In their initial experience of ultrasonographic rectal staging, Holdsworth et al. (72) used a 5.5MHz transducer. They identified lymph node metastases with a sensitivity of 57% and specificity of 64%, concluding that the technique is not reliable to identify metastases. With the growing experience of the operator, the modernization of the probes (introduction of multifrequencies probes) and with the introduction of 3D-dedicated software, Kim et al. (65) reported that lymph node metastases were accurately predicted by 3D-ERUS in 84.8% of patients, whereas 2D-ERUS predicted the disorder in 66.7%. Although their findings did not show 3D-ERUS to have a statistically significant advantage over 2D-ERUS, stereoscopic visualization provided easier and more complete understanding of lymph nodes.

Accuracy of ERUS is highly dependent on operator experience. The capability to perform an accurate examination is crucial for the acquisition of high quality images and for the interpretation of the study. The presence of an uniform acoustic contact is essential for the production of good ultrasonographic images. The position of the probe in relation to the tumor is critical. Whether tumor site (in terms of height) and position (with respect to rectal circumference) has an influence on the reliability of ERUS staging is not settled as yet. Sentovich et al. (74) and Senesse at al. (75) reported significantly better result for tumors of the distal third. The reason for the less accurate staging in the lower rectum is a technical one, because it is the difficult to reach all sites of the rectum with a rigid probe. This consideration prompted us to develop a new dedicated proctoscope to allow easy passage of

the probe above the rectal lesion. We performed a prospective study to determine whether tumor site and tumor position would influence the accuracy of 3D-ERUS staging. (13). ERUS was performed on 173 consecutive patients with primary rectal cancer. In 65 patients the tumor was located 0.1-6cm from the anal verge (lower rectal tumor), 77 patients had tumors 7-12cm from the anal verge (middle rectal tumor) and 31 tumors were 13-18cm from the anal verge (upper rectal tumors). With regard to position, 46 tumors were situated anteriorly, 30 in the left lateral wall, 43 posteriorly and 42 in the right lateral wall. In 12 patients the tumor occupied two-thirds of the rectal circumference. All lesions were resected either endoscopically or surgically. ERUS correctly predicted the depth of invasion in 62/65 (95.3%) lower rectal tumors, 74/77 (96.1%) middle rectal tumors and 28/31 (90.3%) upper rectal tumors. With regard to position, accuracy was 93.4% for tumors located anteriorly, 90.4% for tumors in the right lateral rectal wall, 90.6% for tumors located posteriorly and 86.6% for tumors in the left lateral rectal wall. The accuracy of 3D-ERUS for lymph node metastases, assessed in 142 patients, was 44/46 (95.6%) for lower rectal tumors, 61/65 (93.8%) for middle rectal tumors and 28/31 (90.3%) for upper rectal tumors. Our analysis showed that there was no difference between the different positions, which means that all tumors are equally amenable to ERUS staging if they are within reach of the probe. Tumors situated on the haustral folds are often overstaged because of artifacts induced by tangential imaging. Air bubbles trapped from unfilled space in the rectal vault due to insufficient inflation, produce strong acoustic shadowing and prevent visualization of deeper tissues (75). The impact of tumor level on ERUS accuracy is controversial. Sailer et al. (76) have suggested impaired visualization of tumors located in both the proximal and distal rectum. In their study, 162 tumors were divided into three groups based on tumor location. Reduced accuracy in the staging of low rectal tumors has been attributed to the anatomy of the rectum, who makes it difficult to maintain uniform acoustic contact and proper orientation of the probe. Another explanation is poor definition of the five sonographic layers just above the dentate line, particularly along the posterior wall (47, 75).

A number of comparative studies have been performed to assess the efficacy of ERUS and MRI. Some studies have shown clear supremacy of ERUS, whereas other have shown little difference. MRI as with CT, is accurate in assessing spread of the tumor beyond the rectal wall, invasion of contiguous structures, spread to regional lymph nodes or distant metastases. The lateral pelvic nodes, such as the obturator nodes, are located too far from the rectum to be imaged effectively with ERUS. Therefore, possible advantages of MRI may lie with assessment of the lateral pelvic lymph nodes, pelvic wall invasion and involvement of levator ani muscle. Previously, MRI was not able to delineate the layers of the rectal wall. With high resolution techniques, thin slice MRI can be used to measure the depth of extramural spread accurately, with good correlation with corresponding pathology measurement in surgical specimens (78). Furthermore the relationship of tumor to the mesorectal fascia can be evaluated so that CRM positive status can be predicted when tumor is imaged within 1mm from the mesorectal fascia. Brown et al. (79) evaluated the effectiveness of digital examination, ERUS and MRI in staging rectal cancer in 98 patients undergoing total mesorectal excision with pathology as the gold standard. ERUS correctly identified 14 out of 31 (45%) tumors with favorable prognosis (in two cases extramural depth was overestimated; in the remaining 15 patients, failure to reach the tumor using the EUS probe resulted in inability to assess tumor depth). In this category of patients, MRI

correctly identified all patients. In the preoperative identification of tumors with unfavorable prognosis, ERUS correctly identified 32 out of 39 (82%) patients and MRI correctly identified 33 out of 39 (85%) tumors. In the preoperative identification of locally advanced tumors (28 cases), only one was successfully identified using ERUS; in 12 patients, tumor could not be assessed because not reached by the probe or because of pain experienced by the patient. In 15 patients, tumor deposits involving the mesorectal fascia had not been identified. MRI successfully identified 22 out of 28 patients with locally advanced tumors. In four patients, nodes close to the mesorectal fascia had not been detected. In each of these cases, nodes were partially replaced by small tumor foci that were not resolved on MR images. In two patients tumor was thought to have breached the wall anteriorly by <1mm, but histopathologic examination showed stage pT4 peritoneal infiltration by the tumor. In a meta-analysis by Bipat et al (80), ERUS was found to be the most accurate staging modality when compared to CT and MRI imaging for evaluation of local invasion of rectal cancer. For lymph node involvement, the results were comparable, with low sensitivity values. ERUS was used to evaluate only perirectal or mesorectal lymph nodes, whereas CT and MRI were also used to evaluate iliac and mesenteric or retroperitoneal lymph nodes. In a large recent European multicenter study (81), MRI showed an agreement in T-staging of 57% with 19% overstaging and 24% understaging. It was also very accurate in predicting the extramural depth of tumor invading the mesorectum. MRI was able to identify large T3 and T4 tumors and invasion of the mesorectal fascia. Because of the accurate depiction of large tumoral mass, it is often said that with MRI "what you see is what you get" (66). Most failures of MRI occur in the differentiation between T1 and T2 lesions and between T2 and borderline T3 lesions. A T1 tumor cannot be reliably distinguished from T2 because the submucosal layer is generally not visualized on phased array MRI. Like ERUS, MRI has some difficulty in differentiating lesions on the border of T2 and T3 from a desmoplastic reaction. MRI with endorectal coils has been studied in a number of small size studies for the evaluation and staging of rectal tumors (82). With the addition of endorectal surface coils to conventional MR imaging, spatial resolution has increased and anatomic definition improved. T2-weighted turbo spin-echo sequences allow to distinguish the five layers of the rectal wall. Rectal carcinoma in T2-weighted turbo spin-echo sequences has medium-to-low signal intensity, higher than the muscular layer. MRI and ERUS demonstrate similar efficacy in the preoperative staging of rectal tumors. Overall accuracy rates of 70-90% have been reported for staging of rectal tumors using MRI with endorectal coils. However, coils are too expensive and not used worldwide. A further limitation of MRI with endoanal coils is the inability to advance the coil through a stricture caused by advanced rectal cancer. In the evaluation of lymph nodes, MRI does not offer significant improvement in accuracy rates compared with ERUS.

In conclusion, ERUS is currently the best modality for the preoperative staging of rectal cancer. It is not alternative, but rather complementary to high-resolution MRI. Future improvements may include the possibility to visualize the mesorectal fascia or to better evaluate lymph nodes less than 5mm in diameter. ERUS is much less expensive than MRI and it can be readily used in the office, immediately providing important information for treatment planning. MRI has the advantage, over ERUS, that the images can be more easily interpreted and evaluated by other radiologists, clinicians and oncologists. The images can also be used by radiotherapists for planning the radiotherapy fields and by surgeons to guide the resection in advanced cases.

7. References

- [1] Hildebrandt U, Feifel G. Preoperative staging of rectal cancer by intrarectal ultrasound. *Dis Colon Rectum* 1985; 28: 42-46
- [2] Benson AB 3rd, Choti MA, Cohen AM, et al. NCCN practice guidelines for colorectal cancer. *Oncology* 2000; 14: 203-212
- [3] Glimelius B, Oliveira J. Rectal cancer: ESMO clinical recommendations for diagnosis, treatment and follow-up. *Ann Oncol* 2008; 19 (Suppl 2): ii31- ii32
- [4] Van Cutsem E, Dicato M, Haustermans K, et al. The diagnosis and management of rectal cancer: expert discussion and recommendations derived from the 9th World Congress on Gastrointestinal Cancer, Barcelona 2007. *Ann Oncol* 2008; 19 (Suppl 6): vi1-vi8
- [5] Engstrom PF, Arnoletti JP, Benson AB 3rd et al. NCCN clinical practice in oncology: rectal cancer. *J Natl Compr Canc Netw* 2009; 7: 838-881
- [6] DCCG Danish national guidelines for rectal cancer treatment 2009. <http://www.kirurgiskselskab.dk/dks/krc.htm#top>
- [7] Association Francaise de Chirurgie. French national guidelines for rectal cancer treatment. *Gastroenterol Clin Biol* 2007; 31:1s9-1s22
- [8] Norwegian Gastrointestinal Cancer Group. Kontrollopplegg ved kolorektalcancer (Norwegian Guidelines) 2007. Available at <http://www.ngicg.no/gronnbok/gronnbok.htm>
- [9] Glimelius B, Beets-Tan R, Blomqvist L, et al. Mesorectal fascia instead of circumferential resection margin in preoperative staging of rectal cancer. *J Clin Oncol* 2011; 29: 1-2
- [10] Li JC, Liu SY, Lo AW, et al. The learning curve for endorectal ultrasonography in rectal cancer staging. *Surg Endosc* 2010; 24: 3054-3059
- [11] Lohnert MSS, Doniec JM, Henne-Bruns D. Effectiveness of endoluminal sonography in the identification of occult local rectal cancer recurrences. *Dis Colon Rectum* 2000; 43: 483-491
- [12] Saclarides TJ. Endorectal ultrasound. *Surg Clin North Am* 1998; 78: 237-249
- [13] Santoro GA, D'Elia A, Battistella G, Di Falco G. The use of a dedicated rectosigmoidoscope for ultrasound staging of tumours of the upper and middle third of the rectum. *Colorectal Dis* 2007; 9: 61-66
- [14] Goertz RS, Fein M, Sailer M. Impact of biopsy on the accuracy of endorectal ultrasound staging of rectal tumors. *Dis Colon Rectum* 2008; 51: 1125-1129
- [15] Koh DH, Brown G, Temple L et al. Distribution of mesorectal lymph nodes in rectal cancer: in vivo MR imaging compared with histopathological examination: initial observation. *Eur Radiol* 2005; 15: 1650-1657
- [16] Shaffazin DM, Wong WD. Endorectal ultrasound in the preoperative evaluation of rectal cancer. *Clin Colorectal Cancer* 2004; 4: 124-132
- [17] Kim HJ, Wong WD. Role of endorectal ultrasound in the conservative management of rectal cancers. *Semin Surg Oncol* 2000; 19: 358-366
- [18] Rifkin MD, Ehrlich SM, and Marks G. Staging of rectal carcinoma: prospective comparison of endorectal US and CT. *Radiology* 1989; 170: 319-322
- [19] Rivadeneira DE, Wong WD. Preoperative staging of rectal cancer. *Clin Colon Rectal Surg* 2002; 1: 17-26
- [20] Heintz A, Buess G, Frank K, et al. Endoluminal ultrasonic examination of sessile polyps and early carcinomas of the rectum. *Surg Endosc* 1989; 3: 92-95


- [21] Adams WJ, Wong WD. Endorectal ultrasonic detection of malignancy within rectal villous lesions. *Dis Colon Rectum* 1995; 38: 1093-1096
- [22] Haggit RC, Glotzbach RE, Soffer RE, Wrouble LD. Prognostic factors in colorectal carcinomas arising in adenomas: implications for lesions removed by endoscopic polypectomy. *Gastroenterology* 1985; 89: 328-336
- [23] Nivatvongs S, Rojanasakul A, Reiman HM et al. The risk of lymph node metastasis in colorectal polyps with invasive adenocarcinoma. *Dis Colon Rectum* 1991; 34: 323-328
- [24] Suzuki T, Sadahiro S, Marukoyama S, et al. Risk of lymph node and distant metastases in patients with early invasive colorectal cancer classified as Haggit's level 4 invasion: image analysis of submucosal layer invasion. *Dis Colon Rectum* 2003; 46: 203-208
- [25] Seitz U, Bohnacker S, Seewald S, et al. Is endoscopic polypectomy an adequate therapy for malignant colorectal adenomas? Presentation of 114 patients and review of the literature. *Dis Colon Rectum* 2004; 47: 1789-1797
- [26] Kudo S. Endoscopic mucosal resection of flat and depressed types of early colorectal cancer. *Endoscopy* 1993; 25: 455-461
- [27] Kikuchi R, Takano M, Takagi K et al. Management of early invasive colorectal cancer: risk of recurrence and clinical guidelines. *Dis Colon Rectum* 1995; 38: 710-717
- [28] Akasu T, Kondo H, Moriya Y et al. Endorectal ultrasonography and treatment of early stage rectal cancer. *World J Surg* 2000; 24: 1061-1068
- [29] Nascimbeni R, Nivatvongs S, Larson DR, Burgart LJ. Long-term survival after local excision for T1 carcinoma of the rectum. *Dis Colon Rectum* 2004; 47: 1773-1779
- [30] Mellgren A, Sirivongs P, Rothenberger DA, et al. Is local excision adequate therapy for early rectal cancer? *Dis Colon Rectum* 2000; 43: 1064-1071
- [31] Kim J, Yu CS, Jung HY et al. Source of error in the evaluation of early rectal cancer by endoluminal ultrasonography. *Dis Colon Rectum* 2001; 44: 1302-1309
- [32] Maier AG, Barton PB, Neuhold NR et al. Peritumoral tissue reaction at transrectal US as a possible cause of overstaging in rectal cancer: histopathologic correlation. *Radiology* 1997; 203: 785-789
- [33] Hulsmans FJH, Tio TL, Fockens P et al. Assessment of tumor infiltration depth in rectal cancer with transrectal sonography: caution is necessary. *Radiology* 1994; 190: 715-720
- [34] Solomon MJ, McLeod RS, Cohen EK et al. Reliability and validity studies of endoluminal ultrasonography for anorectal disorders. *Dis Colon Rectum* 1994; 37: 546-551
- [35] Santoro GA, Di Falco G. Endorectal ultrasound in the preparative staging of rectal cancer. In: Santoro GA, Di Falco G (eds). *Atlas of endoanal and endorectal ultrasonography*. Springer-Verlag Italia, Milan 2004: 11-21
- [36] Muthusamy VA, Chang KJ. Optimal methods for staging rectal cancer. *Clin Cancer Res* 2007; 13: 6877-6884
- [37] Hulsmans FJ, Bosma PA, Mulder PJ et al. Perirectal lymph nodes in rectal cancer: in vitro correlation of sonographic parameters in histologic findings. *Radiology* 1992; 184: 553

- [38] Janjan NA, Crane C, Feig BW, et al. Improved overall survival among responders to preoperative chemoradiation for locally advanced rectal cancer. *Am J Clin Oncol* 2001; 24: 107-112
- [39] Sitzler PJ, Seow-Choen F, Ho YH, et al. Lymph node involvement and tumor depth in rectal cancers: an analysis of 805 patients. *Dis Colon Rectum* 1997; 40: 1472-1476
- [40] Beynon J, Mortensen NJ, Foy DM, et al. Preoperative assessment of mesorectal lymph node involvement in rectal cancer. *Br J Surg* 1989; 76: 276-279
- [41] Herzog U, von Flue M, Tondelli P, et al. How accurate is endorectal ultrasound in the preoperative staging of rectal cancer? *Dis Colon Rectum* 1993; 36: 127-134
- [42] Goldman S, Arvidsson H, Norming U, et al. Transrectal ultrasound and computer tomography in preoperative staging of lower rectal adenocarcinoma. *Gastrointest Radiol* 1991; 16: 259-263
- [43] Civelli EM, Gallino G, Mariani L, et al. Double-contrast barium enema and computerized tomography in the preoperative evaluation of rectal carcinoma: are they still useful diagnostic procedures? *Tumori* 2000; 86: 389-392
- [44] Ptok H, Marush F, Meyer F, et al. Feasibility and accuracy of TRUS in the pre-treatment staging for rectal carcinoma in general practice. *Eur J Surg Oncol* 2006; 32: 420-425
- [45] Rieger N, Tjandra J, Solomon M. Endoanal and endorectal ultrasound: applications in colorectal surgery. *ANZ J Surg* 2004; 74: 671-675
- [46] Kim NK, Kim MJ, Yun SH, et al. Comparative study of transrectal ultrasonography, pelvic computerized tomography, and magnetic resonance imaging in preoperative staging of rectal cancer. *Dis Colon Rectum* 1999; 42: 770-775
- [47] Garcia-Aguilar J, Pollack J, Lee SH, et al. Accuracy of endorectal ultrasonography in preoperative staging of rectal tumors. *Dis Colon Rectum* 2002; 45:10-15
- [48] Orrom WJ, Wong WD, Rothenberger DA, et al. Endorectal ultrasound in the preoperative staging of rectal tumors. A learning experience. *Dis Colon Rectum* 1990; 33: 654-659
- [49] Worrell S, Horvath K, Blakemore T, Flum D. Endorectal ultrasound detection of focal carcinoma within rectal adenomas. *Am J Surg* 2004; 187: 625-629
- [50] Baynon J. An evaluation of the role of rectal endosonography in rectal cancer. *Ann R Coll Surg Engl* 1989; 71: 131-139
- [51] Kim JC, Kim HC, Yu SC, et al. Efficacy of 3-dimensional endorectal ultrasonography compared with conventional ultrasonography and computed tomography in preoperative rectal cancer staging. *Am J Surg* 2006; 192: 89-97
- [52] Assenat T, Thézenas S, Samalin E, et al. The value of endoscopic rectal ultrasound in predicting the lateral clearance and outcome in patients with lower third rectal adenocarcinoma. *Endoscopy* 2007; 39: 309-313
- [53] Garcia-Aguilar J, Hernández de Anad E, Rothenberger DA et al. Endorectal ultrasound in the management of patients with malignant rectal polyps. *Dis Colon Rectum* 2005; 48: 910-917
- [54] Kruskal JB, Sentovich SM, Kane RA. Staging of rectal polyps after polypectomy: usefulness of endorectal US. *Radiology* 1999; 211: 31-35
- [55] Santoro GA, Gizzi G, Pellegrini L et al. The value of high-resolution three-dimensional endorectal ultrasonography in the management of submucosal invasive rectal cancer. *Dis Colon Rectum* 2009; 52: 1837-1843

- [56] Pikarsky A, Wexner S, Lebensart P, et al. The use of rectal ultrasound for the correct diagnosis and treatment of rectal villous tumors. *Am J Surg* 2000; 179: 261-265
- [57] Konishi K, Akita Y, Kaneko K, et al. Evaluation of endoscopic ultrasonography in colorectal villous lesions. *Int J Colorectal Dis* 2003; 18: 19-24
- [58] Akahoshi K, Yoshinaga S, Soejima a, et al. Transit endoscopic ultrasound of colorectal cancer using 12MHz catheter probe. *Br J Radiol* 2001; 74: 1017-1022
- [59] Starck M, Bohe M, Simanaitis M, Valentin L. Rectal endosonography can distinguish benign rectal lesions and invasive early rectal cancers. *Colorectal Dis* 2003; 5: 246-250
- [60] Hunerbein M, Handke T, Ulmer C, Schlag PM. Impact of miniprobe ultrasonography on planning of minimally invasive surgery for gastric and colonic tumors. *Surg Endosc* 2004; 18: 601-605
- [61] Santoro GA, Bara Egan D, Di Falco G. Three dimensional endorectal ultrasonography in the evaluation of early invasive rectal cancer. *Colorectal Dis* 2004; 6 (Suppl 2): 20
- [62] Sailer M, Leppert R, Kramer M, et al. The value of endorectal ultrasound in the assessment of adenomas, T1- and T2-carcinomas. *Int J Colorectal Dis* 1997; 12: 214-219
- [63] Massari M, De Simone M, Cioffi U, et al. Value and limits of endorectal ultrasonography for preoperative staging of rectal carcinoma. *Surg Laparosc Endosc*. 1998; 8: 438-444
- [64] Katsura Y, Yamada K, Ishizawa T et al, Endorectal ultrasonography for the assessment of wall invasion and lymph node metastasis in rectal cancer. *Dis Colon Rectum* 1992; 35: 362-368
- [65] Kim JC, Cho YK, Kim SY, et al. Comparative study of three-dimensional and conventional rectal ultrasonography for the assessment of wall invasion and lymph node metastasis in rectal cancer. *Surg Endosc* 2002; 16: 1280-1285
- [66] Beets GL, Beets-Tan RGH. Pretherapy imaging of rectal cancers: ERUS or MRI? *Surg Oncol Clin N Am* 2010; 19: 733-741
- [67] Glaser F, Schlag P, Herfarth CH. Endorectal ultrasonography for the assessment of invasion of rectal tumors and lymph node involvement. *Br J Surg* 1990; 77: 883-887
- [68] Marusch F, Koch A, Schmidt U, et al. Routine use of transrectal ultrasound in rectal carcinoma: results of a prospective multicenter study. *Endoscopy* 2002; 34: 385-390
- [69] Kauer WK, Prantl L, Ditter HJ et al. The value of endosonographic rectal carcinoma staging in routine diagnostics: a 10-year analysis. *Surg Endosc* 2004;18: 1075-1078
- [70] Badger SA, Devlin PB, NeillyPJ, Gilliland R. Preoperative staging of rectal carcinoma by endorectal ultrasound: is there a learning curve? *Int J Colorectal Dis* 2007; 22: 1261-1268
- [71] Puli SR, Reddy JBK, Bechtold ML, et al. Accuracy of endoscopic ultrasound to diagnose nodal invasion by rectal cancers. a meta-analysis and systematic review. *Ann Surg Oncol* 2009; 16: 1255-1265
- [72] Siddiqui AA, Fayiga Y, Huerta S. The role of endoscopic ultrasound in the evaluation of rectal cancer. *Int Semin Surg Oncol* 2006; 3: 36-42
- [73] Holdsworth PJ, Johnston D, Chalmers AG et al. Endoluminal ultrasound and computer tomography in the staging of rectal cancer. *Br J Surg* 1988; 75: 1019-1022
- [74] Sentovich S, Blatchford G, Falk P et al. Transrectal ultrasound of rectal tumore. *Am J Surg* 1993; 166: 638-641

- [75] Senesse P, Khemissa F, Lemanski C, et al. Contribution of endorectal ultrasonography in preoperative evaluation for very low rectal cancer. *Gastroenterol Clin Biol* 2001; 25: 24-28
- [76] Edelman BR, Weiser MR. Endorectal ultrasound: its role in the diagnosis and treatment of rectalcancer. *Clin Colon Rectal Surg* 2008; 21: 167-177
- [77] Sailer M, Leppert R, Bussen D, et al. Influence of tumor position on accuracy of endorectal ultrasound imaging. *Dis Colon Rectum* 1997; 40: 1180-1186
- [78] Brown G, Radcliffe AG, Newcombe RG et al. Preoperative assessment of prognostic factors in rectal cancer using high resolution magnetic resonance imaging. *Br J Surg* 2003; 90: 355-364
- [79] Brown G, Davies S, Williams GT et al. Effectiveness of preoperative staging in rectal cancer: digital rectal examination, endoluminal ultrasound or magnetic resonance imaging? *Br J Cancer* 2004; 91: 23-29
- [80] Bipat S, Glas AS, Slors FJM, et al. Rectal cancer: local staging and assessment of lymph node involvement with endoluminal US, CT and MR imaging. a meta-analysis. *Radiology* 2004; 232: 773-783
- [81] MERCURY Study Group. Extramural depth of tumor invasion at thin-section MR in patients with rectal cancer: results of the MERCURY study. *Radiology* 2007; 243: 132-139
- [82] Meyenberger C, Huch Boni RA, Bertschinger P et al. Endoscopic ultrasound and endorectal magnetic resonance imaging: a prospective, comparative study for preoperative staging and follow-up of rectal cancer. *Endoscopy* 1995; 27: 469-479

IntechOpen



Rectal Cancer - A Multidisciplinary Approach to Management

Edited by Dr. Giulio A. Santoro

ISBN 978-953-307-758-1

Hard cover, 410 pages

Publisher InTech

Published online 10, October, 2011

Published in print edition October, 2011

Dramatic improvements in medicine over the last few years have resulted in more reliable and accessible diagnostics and treatment of rectal cancer. Given the complex physiopathology of this tumor, the approach should not be limited to a single specialty but should involve a number of specialties (surgery, gastroenterology, radiology, biology, oncology, radiotherapy, nuclear medicine, physiotherapy) in an integrated fashion. The subtitle of this book "A Multidisciplinary Approach to Management" encompasses this concept. We have endeavored, with the help of an international group of contributors, to provide an up-to-date and authoritative account of the management of rectal tumor.

How to reference

In order to correctly reference this scholarly work, feel free to copy and paste the following:

Miro A.G.F., Grobler S. and Santoro G.A. (2011). Preoperative Staging of Rectal Cancer: Role of Endorectal Ultrasound, Rectal Cancer - A Multidisciplinary Approach to Management, Dr. Giulio A. Santoro (Ed.), ISBN: 978-953-307-758-1, InTech, Available from: <http://www.intechopen.com/books/rectal-cancer-a-multidisciplinary-approach-to-management/preoperative-staging-of-rectal-cancer-role-of-endorectal-ultrasound>

INTECH
open science | open minds

InTech Europe

University Campus STeP Ri
Slavka Krautzeka 83/A
51000 Rijeka, Croatia
Phone: +385 (51) 770 447
Fax: +385 (51) 686 166
www.intechopen.com

InTech China

Unit 405, Office Block, Hotel Equatorial Shanghai
No.65, Yan An Road (West), Shanghai, 200040, China
中国上海市延安西路65号上海国际贵都大饭店办公楼405单元
Phone: +86-21-62489820
Fax: +86-21-62489821

© 2011 The Author(s). Licensee IntechOpen. This is an open access article distributed under the terms of the [Creative Commons Attribution 3.0 License](#), which permits unrestricted use, distribution, and reproduction in any medium, provided the original work is properly cited.

IntechOpen

IntechOpen