

We are IntechOpen, the world's leading publisher of Open Access books Built by scientists, for scientists

4,800

Open access books available

122,000

International authors and editors

135M

Downloads

Our authors are among the

154

Countries delivered to

TOP 1%

most cited scientists

12.2%

Contributors from top 500 universities



WEB OF SCIENCE™

Selection of our books indexed in the Book Citation Index
in Web of Science™ Core Collection (BKCI)

Interested in publishing with us?
Contact book.department@intechopen.com

Numbers displayed above are based on latest data collected.

For more information visit www.intechopen.com



Evaluation of Radiofrequency Ablation as a Method for Treatment of Hepatocellular Carcinoma

Heba Mohamed Abdella

Tropical Medicine, Faculty of Medicine, Ain Shams University, Cairo, Egypt

1. Introduction

Hepatocellular carcinoma is the fifth most common neoplasm in the World and the third most common cause of cancer related death (1). It accounts for 7.4% of all cancers in males and 3.2% of all cancers in females (2).

An early diagnosis of HCC is required for the institution of treatments considered to be curative. On this basis, screening of each patient with liver cirrhosis should be performed by ultrasound and by measurements of serum alphafetoprotein (AFP) at 6-months interval (3). There are different methods for active management of HCC, many factors related to the tumour itself and to the patient may make a tumour unresectable (4).

Radio frequency ablation (RFA) is the most common therapy used in patients not suitable for resection. In RFA, an electric current that is passed into the tumour tissue via an electrode tip results in heat generation and coagulative necrosis (5). The advantage of radio frequency is the small number of sessions needed to obtain tumour necrosis (6). The aim of the present study was to evaluate the radiofrequency thermal ablation as a method for treatment of hepatocellular carcinoma.

2. Patients and methods

This retrospective study was carried out at Ain-Shams University Hospital (Hepatoma unit), including patients attending the unit during the period between January 2004 to January 2006.

All patients were subjected to the following:

1. *Full history with special emphasis on the newly developed persistent right upper abdominal pain, and unexplained hepatic decompensation*
2. *Full clinical examination including:*
 - A. *General examination : with stress on signs of liver cell failure including jaundice, flapping tremors, plamar erythema, lower limb edema*
 - B. *Local abdominal examination: with special stress on the presence of signs suggestive of hepatic malignancy e.g. hepatic mass and hepatic bruit.*

3. *Laboratory investigations:*

Complete blood picture, liver profile, coagulation profile, hepatitis markers, serum blood glucose, and renal function tests.

Tumour markers including AFP, CA and CEA antigens for exclusion of metastasis from the GIT.

4. *Radiological evaluation:*

- a. Pelviabdominal U.S. examination;

To evaluate the number, size, and location of the hepatic focal lesions, and to exclude portal vein thrombosis, hepatic vein obstruction, porta-hepatis or coeliac lymph node enlargement, and ascites.

- b. Abdominal tri-phasic spiral C.T. scan to accurately evaluate the pattern of enhancement of the focal lesions, vascular or biliary invasion specially portal vein thrombosis. The suggestive criteria for HCC were considered present when there was enhancement of the focal lesion with the I.V dye so it appeared hyperdense in the arterial phase, then it became hypodense in both portovenous and delayed phases due to the wash out of the dye from the focal lesion.

The above mentioned findings were used as a reference for evaluation of the response after ablation.

- c. Chest x-ray to exclude pulmonary metastases.

Patients were stratified according to Child-Pugh Classification ⁽⁷⁾

Diagnosis of HCC was done based on the presence of at least 2 of 3 of the following criteria:

1. Hepatic focal lesion detected by abdominal ultrasound and has positive criteria of HCC in spiral CT scan.
2. Alphafetoprotein >200ng/ml (8).
3. Guided biopsy from the focal lesion was performed when one of the above mentioned criteria was missed.

Seventy four patients with proved hepatocellular carcinoma were selected for treatment by ultrasound-guided percutaneous radiofrequency ablation according the following inclusion criteria;

1. Patients with unresectable hepatic malignancies.
2. No evidence of extra-hepatic disease.
3. Absence of vascular or biliary invasion.
4. Presence of not more than 2 focal lesions, each is less than 5cm.
5. Child-Pugh's class A, and B.
6. Tumours in position where the electrode can be inserted and held safely.

Absolute contra-indications include:

- Sever debilitation.
- Active infection.
- Uncorrectable coagulopathy.
- Pregnancy.

After imaging study, patients were divided into 2 groups according to the number of focal lesions:

Group I: patients with single hepatic focal lesion.

Group II: patients with 2 hepatic focal lesions.

Premaneuver assessment: Patients were admitted to Tropical Medicine Department for Premaneuver assessment including cardiac and chest examination, ECG, blood pressure and blood glucose level evaluation. Ascites in ascetic patients was also controlled by diuretics and tapping if needed.

Radiofrequency ablation systems:

The two machines used in this study were:

- a. The RITA model 1500RF.
- b. RF 2000 system, produced by the RadioTherapeutics Corporation.

Radiofrequency ablation technique:

Patients with one focal lesion were treated in single RFA setting while patients with 2 focal lesions were treated either in single or over 2 settings separated by one week, so 80 sessions were done for 80 lesions. Percutaneous radiofrequency ablation was used to treat a total of 80 lesions which were detected by U.S and C.T in the 74 patients.

Pre-ablation assessment:*General assessment:*

Medical history was revised and the laboratory test results were checked, and the ECG was interpreted with chest and cardiac examination. A peripheral I.V. line was started, and the patient was monitored for blood pressure, pulse, respiratory rate, and the peripheral oxygenation.

Ultrasound approach assessment:

Percutaneous RFA was performed with real- time US guidance by using 3.5 MHz convex probe. Pre-ablation US assessment was performed to re-evaluate the number and size of the tumours, their relationship to surrounding structures as blood vessels, bile ducts, gall bladder, diaphragm, and bowel, and to determine if a safe and adequate approach exists.

The most appropriate approach for electrode insertion was detected. For tumours located in the right lobe, an intercostal approach with the patient in the left lateral decubitus position generally was preferred. For tumours located in the left lobe, a subcostal approach was used most often. The procedure was done in the interventional radiology unit (a special sterilized unit) containing the ultrasound machine (Siemens, Toshiba), the services of general anesthesia, the radiofrequency system, and a mobile sterile table (for sterile patients and doctors' gowns, antiseptics, syringes, IV fluid, medications, and gauze). The grounding pads, representing the dispersive electrode, were placed on the patient's thighs and properly connected to the generator. The system was tested to be sure working.

Anesthesia and medications:

Local anesthesia was performed from the entry site on the skin to the liver capsule along the needle track with 10 ml of 2% xylocaine. Skin was pricked it has small sterile lancet. Most of the patients undergone RFA were treated under general intravenous anesthesia.

Needle electrode placement:

The needle electrode was introduced into the liver through the skin incision under U.S. or C.T. guidance. After verifying the positioning of the needle electrode, the multiple arrays were deployed and the needle electrode was connected to the RF generator.

Treatment strategy:

The objective in treating the tumours was to ablate the entire tumour as well as at least 1 cm-tumour- free margin of normal liver.

The deepest ablations were performed before the superficial ones to minimize the possibility of those microbubbles might obscure visualization of the deepest portions of the tumour and thus prevent completion of the ablation. The hilar portion of the tumour was ablated initially in order to destroy the inflow of blood supplying the tumour.

The needle electrode was first placed at the most posterior margin and at one side of the tumour, then to the other side. Multiple overlapping ablations were then sequentially performed progressing superficially and then laterally at 2-2.5 cm intervals within the tumour until the tumour and 1 cm-free margin had been successfully ablated.

As we start RFA session a hyper-echoic focus developed around the un-insulated portion of the electrode. This was attributed to tissue vaporization and cavitations. The area of echogenicity was round; most often progressively increased in size over the course of ablation and generally enveloped the entire tumour with variable extensions in the surrounding liver by the end of the treatment.

In some cases, the hyper-echoic focus did not develop progressively but appeared rather suddenly and was accompanied with an audible popping sound emanating from the liver.

Cool down:

When the timer runs out the generator will automatically go into Cool Down mode for 30 seconds (5 minutes on the generator display), when the Cool Down is complete, the temperatures from all leads must be above 70°C, if not we continue ablation for another 5 minutes at target temperature, or we can rotate the device 45 degree to check temperature and continue ablation if still temp below 70°C.

Track ablation:

In most of our cases we ablate the tract before removal of the needle.

Post Ablation care:

IV antiemetic was given if needed, Strong IV analgesics were given to pain as pethidine hydrochloride 50 mg or tramadol. All patients were observed clinically for 2-3 hours in the Radiology department to detect any acute complications and to start IV fluid. Prophylactic antibiotic were started, amoxicillin-clavulanic acid (augmentin) or ceftazidime (fortum), and metronidazole (flagyl), and continued for 3 days.

Post treatment follow up

All patients underwent dynamic CT scan 1 month after completion of the therapy to detect any residual enhancing tumour tissue. If any area suspicious for viable tissue was detected, the patient was retreated by RFA of this area. Then, follow up CT was done after 3 months, then every 6 months to detect any local recurrence in the ablated tumour or de novo lesion. Alphafetoprotein level was assessed accompanying performance of CT. After 1 month if its level was still elevated, it indicated incomplete tumour ablation. Follow up after complete ablation was to detect any minor elevations which detect recurrence.

3. Results

Table 1 shows the demographic and clinical data of the studied patients.

Thirty one patients had their AFP level above the diagnostic value (200ng/ml), while the remaining 43 patients had AFP level less than 200. The ($M \pm SD$) of serum alphafetoprotein level (AFP) was 12086 ± 7345 ng/ml and ranged between 1.8 ng/ml and 350000 ng/ml, as shown in **table 2** which illustrates also the remaining liver profile. All patients were positive for hepatitis C antibody and negative for HbsAg. HbcAb was detected in 7 patients. Abdominal ultrasound findings are shown in **table 3**. The findings of spiral CT in this study were similar to that of abdominal ultrasound as regard the number, site and diameter of the hepatic focal lesion. In this study, the spiral CT criteria suggestive for HCC were present in 63 cases (85.1%) and absent in 14 cases (14.9%) (they were proved to be HCC by biopsy).

Forty two Patients (56.8%) were within Child Pugh class A and 32 patients (43.2%) were within Child Pugh class B (patients in Child class B were with minimal and controlled ascites).

Tumour character: The seventy four patients included in the study were divided into 2 groups according to the number of focal lesions in each patient. Sixty eight patients form group I and had only one focal lesion (68 lesions) and the maximum diameter of the tumours was 3 cm or less in 42 patients and was from 3-5 cm in 26 patients. Group II formed

of patients with 2 hepatic focal lesions and included 6 patients with 12 focal lesions. In group II, the maximum diameter of the tumours was 3 cm or less in 6 lesions of 6 patients and was from 3-5 cm in another 6 lesions of the same 6 patients (**Table 3**).

Age	Mean	55.5 years
	± SD	7.8 years
Gender	No. of the patient	%
Males	57	77%
Females	17	23%
Symptoms		
Rt. Hypochondrial pain	58	78.3%
Loss of appetite	25	33.8%
Itching	9	12.2%
Loss of weight	21	28.4%
Jaundice	23	31.1%
Ascites	11	14.9%
Fever	10	13.5%
Easy fatigability	35	47.3%
Risk factors for infection with hepatitis viruses.		
Schistosomiasis & treatment with tartar emetic	40	54.1%
Blood transfusion	28	37.8%
Surgical operations	38	51.4%
Dental procedures	24	32.4%
General Examination		
Pallor	6	8.1%
Jaundice	30	40.5%
Flapping Tremors	11	14.8%
Palmar erythema	25	33.8%
Lower Limb edema	36	48.6%
Abdominal Examination		
Palpable liver	44	59.4%
Tender liver	0	0%
Ascites	10	13.5%
Splenomegaly	13	17.6%

Table 1. Demographic and clinical data of the studied patients.

	Mean	± SD
AFP	12086	7345
ALT (IU/L)	66.8	32.5
AST (IU/L)	94.8	36.4
Albumin (gm/dL)	2.9	0.4
Bilirubin (mg/dL)	1.7	0.6

Table 2. Laboratory findings of the studied patients.

		GI (n=68), 68 lesions	GII (n=6), 12lesions
Lesion <3cm	No. of patients	42	6
	No. of lesions	42	6
Lesion 3-5cm	No. of patients	26	6
	No. of lesions	26	6

Table 3. Tumour character in the studied patients:

Results of treatment with Radiofrequency ablation:

During the first follow up done one month after ablation, 68 patients (91.9%) showed complete ablation with no evidence of residual and 6 patients (8.1 %) showed incomplete ablation [3 patients in group I and 3 patients in group II, all of them with lesion diameter 3-5cm] (Table 4)

	Group I (68 patients, 68 lesions)				Group II (6 patients, 12 lesions)			
	<3cm		3-5cm		<3cm		3-5cm	
	Number of patients	Number of lesions	Number of patients	Number of lesions	Number of patients	Number of lesions	Number of patients	Number of lesions
	42	42	26	26	6	6	6	6
Complete ablation	42 (100%)	42 (100%)	23 (88.4%)	23 (88.4%)	6 (100%)	6 (100%)	3 (50%)	3 (50%)
Partial ablation	0 (0%)	0 (0%)	3 (11.5%)	3 (11.5%)	0 (0%)	0 (0%)	3 (50%)	3 (50%)

Table 4. Results of RFA after one month

During the second follow up done after 3 months, 71 patients (95.9 %) had no evidence of local or distant recurrence. Local recurrence occurred in 3 patients in group I (4.1%).

During the third follow up done after 6 months, 70 patients (94.6%) showed no evidence of recurrence and 4 patients (5.4%) [2 patients in group I and 2 patients in group II] had a new focal lesion at distant sites of the liver.

During the fourth follow up done after 12 months, 72 patients (97.3%) showed no evidence of recurrence and 2 patients (2.7%) had a new focal lesion at other sites of the liver both were in group II (Table 5).

	Group I (n=68 patients)		Group II (n=6 patients)	
	Local recurrence	Distant recurrence	Local recurrence	Distant recurrence
3 months	3	0	0	0
6 months	0	2	0	2
12 months	0	0	0	2

Table 5. Results of 3, 6 and 12 months follow up after RFA

The residual of the tumour was managed by a second session of RFA. All local or distant recurrences were managed by a second RFA session when in suitable site except in one patients was near a biliary radicle, so managed with intralesional ethanol injection.

***Follow up of Laboratory investigation:**

As regards the liver enzymes, ALT was significantly elevated one month after RFA sessions (92.8 ± 36.4 IU/L) more than before ablation ($P < 0.01$), the same was noticed for AST which was also significantly higher (98 ± 32.5 IU/L) ($P < 0.01$). During the second follow up done after 3 months, ALT and AST returned to base line levels.

Three months after RFA, serum albumin was higher and ranged between 2.8-4.5 gm/dl with ($M \pm SD: 0.2 \pm 0.4$ gm/dl), serum bilirubin was lower and ranged between 0.6-1.9 mg/dl with ($M \pm SD: 0.9 \pm 0.4$ gm/dL).

Before treatment with RFA serum AFP values were elevated (>200 ng/mL) in 31 patients (41.8%). **Table 6** shows the patients with AFP level >200 during the follow up period after ablation.

	AFP>200ng/ml	
	No. of patients	%
Before RFA	31	41.8%
One month after RFA	17	22.9%
After three months	9	12.2%
After 6 months	5	6.7%
After 12 months	3	4.1%

Table 6. Patients with AFP>200ng/ml before and after RFA.

There were no fatal complications related to RFA treatment. Nearly all the patients experienced post-ablation right hypochondrial pain that was controlled by analgesics, and nausea (70 patients, 94.5%), which was controlled by antiemetics. Also, nearly all experienced post - ablation pyrexia for 1-3 days, which was controlled by antipyretics. Pneumonia occurred in only one patient (1.3%) and ascites developed in 2 patients (2.7%) . Only one patient developed pneumothorax due to ablation of Sub-diaphragmatic tumour and another 2 patients developed ascites within the first week post ablation.

At the end of this study after one year, survival analysis was evaluated. Two patients (2.7%) died as result of advanced liver disease. So, overall survival rate was 97.2% (72/74 patients). Disease free survival rate was 79.7% as thirteen patients (17.6%) survived with recurrent HCC and fifty nine patients (79.7%) were disease free over the follow up period (**Table 7**).

Survival status	Number of patients	%
Disease free survival patients	59	79.7%
Survived with recurrent disease	13	17.6 %
Died patients	2	2.7 %
Total number	74	100%

Table 7. Survival rates evaluation in the study

4. Discussion

Hepatocellular carcinoma (HCC) is the fifth most common neoplasm in the world and the third most common cause of cancer related death. Currently, it is the leading cause of death

among cirrhotic patients (1). The studies carried out on hepatocellular carcinoma are scarce in Egypt. Nevertheless, they presumed an upward trend for HCC among chronic liver disease (CLD) patients (9).

For the last two decades several minimally invasive interventional ablative techniques aiming at providing local destruction of the tumour have been developed. Radiofrequency thermal ablation (RFA) is a more recently developed for local tissue ablation.

This retrospective study was performed on 74 patients with hepatocellular carcinoma attending Hepatoma unit of Ain Shams University during the period between January 2004 and January 2006.

In this study, it was found that the number of male patients was higher than females (57 male and 17 females) with ratio 3.4:1 and this agrees with Sherlock and Dooley 2002 who reported that in patients with HCC males exceed females in a ratio of 4-6:1(2). Also, Marrero, 2003 stated that male population both black and white is primarily affected (10).

The newly developed persistent right hypochondrial dull aching pain was the most common complaint of patients included in this study (78.3%). This is a very important finding and it meets the finding of Hillebrand and Sandowski, 2000 who found that although the percentage of patients having specific signs and symptoms differs in high-incidence and low incidence areas of HCC, the most common complaint remains abdominal pain (4). Pain is frequent but rarely severe and is felt as a non-specific, continuous dull ache in the epigastrium, right upper quadrant, or the back. Severe pain is due to perihepatitis or involvement of the diaphragm (2).

The etiology of chronic liver disease in patients of the study was hepatitis viruses' infection (HBV and/or HCV). In Egypt, HCV seroprevalence is 55% among children who had received blood transfusions and 67% among patients on renal dialysis, and is 10% among sexually transmitted disease patients (11).

In this study, 67 patients (90.5%) were positive for HCV antibody. The prevalence of HCV antibody positive patient with HCC was found to be 62% in Spain, 65% in Italy, 29% in South Africa and 29% in United States (12).

In this study all patients were negative for HBsAg but when HBcAb IgG was assessed (which indicates past infection with HBV), it was found that HBcAb IgG was positive in 7 patients (9.5%) of the study. these results agree also with El-Zayadi et al., 2001 who placed Egypt among the countries of intermediate prevalence for HBV as HBV accounts for 10-30% of CLD and HBsAg carriage was reported in 5.6% (9).

Owing to the use of ultrasound surveillance in patients with hepatic cirrhosis, HCC is diagnosed in an increasing number of patients at an early asymptomatic stage (13). Patients with early stage HCC should be considered for any of the available curative treatment options including surgical resection, liver transplantation and percutaneous techniques of tumour ablation (14). In the recent decade, ultrasound guided percutaneous ethanol injection (PEI), as a local therapy for hepatic tumours, has gradually been replaced by intraoperative or percutaneous RFA (15). RFA was considered by many authors as superior to other existing loco regional therapies as percutaneous ethanol injection (PEI), transarterial chemoembolization (TACE) and microwave ablation (16).

In the present studying RFA was used to treat 80 tumours in 74 patients. The 80 tumours included 48 tumours (60%) less than 3 cm in diameter and 32 tumours (40%) 3-5cm in diameter.

Generally, a single ablation of 5cm in diameter could successfully destroy liver tumour smaller than 3cm plus the safety margin of 0.5-1cm⁽¹⁷⁾. In the present study, after one month of RFA, all the 48 tumours (100%) less than 3cm in diameter showed complete ablation while 26/32 (81.3%) of tumours between 3-5cm showed complete ablation and 6 tumours (18.7%) showed residual viable tumour tissue (i.e. partial or incomplete ablation). In a study by Chen et al. 2005⁽¹⁷⁾, cases with tumours larger than 3.5cm in diameter accounted for 61.8% (207/335 cases) of their study population, and they got 85.9% response rate (178/207 cases), results nearly similar to the results of the present study. The whole complete response rate for all tumours was 92.5% (74/80 tumours), the 6 incompletely ablated tumours (7.5%) were larger than 3cm in diameter. These results are also near the results of Chen et al. 2005 who reported 94.8% (723/763 tumours) total ablation rate of the initial RFA. Of the 40 incompletely ablated tumours, 33 (82.5%) were larger than 3.5cm⁽¹⁷⁾. These data support the fact that the most important factor for efficacy of RFA is the size of the tumour and the RFA could successfully ablate smaller liver tumours. **Sala et al 2004**⁽¹⁸⁾ supports this by the results of their study as they reported initial complete response of 96% in tumours 2cm or smaller and this figure decreased to almost 50% in multinodular or large HCC and this figure is similar to that reported by most referral groups⁽¹⁹⁾.

All cohort studies assessing percutaneous ablation report the appearance of viable tumour tissue within the treated nodule or its vicinity after initial complete response⁽²⁰⁾. This was met in our study as, three months after ablation local recurrence occurred in three patients in group I. Six months after ablation, 4 patients (2 in each group) showed distant recurrence and 2 other patients in group II showed another distant recurrence after one year. This event is heterogeneously defined (distance from the main nodule, location in the same segment) and named⁽²¹⁾. This is usually termed local recurrence or local tumour progression⁽²¹⁾. Sala et al 2004 reported local tumour progression in 76 patients in their series of 192 patients after initial complete response with a 1, 3, 5 years probability of 26%, 56%, and 74% respectively. Most were detected early in the follow up, but 34% were registered at 2 years and 13% were detected beyond 3 years⁽¹⁸⁾. Unfortunately, results of our study can not be compared with results of Sala et al 2004 as the follow up period here is only one year.

Even tumours 2cm or smaller can present with late failure and studies in resected tumours explain this: one third of tumours with 3cm or smaller present microscopic vascular invasion or satellites, which will almost likely not be affected by ablation and emerge as failure early or late during follow up⁽²²⁾.

At the end of the follow up period in our study (1year), the overall survival rate was 97.3% i.e. 72 patients alive and 2 patients died due to disease progression. Fifty nine patients (79.7%) represented the disease free survival while 13 patients (17.5%) lived with either local or distant recurrence.

The one year overall survival in our study was 97% which is similar to that of Shina et al., 2005⁽²³⁾ but less than **Lencioni et al., 2003**⁽²⁴⁾ which was 100%.

However our results are higher than those of **Lin et al., 2004**⁽²⁵⁾ and **Lin et al., 2005**⁽²⁶⁾ (90% , 93% respectively). At the end of the study (1 year), 15 patients (18.9%) lived with either local recurrence or denovo lesion. **Lin et al., 2003** reported 18% local recurrence at the end of their study (2 year) while over the same period **Lncioni et al ., 2003** reported only 4% local recurrence and no report on denovo lesions.

In this series nearly all the patients experienced post-ablation minor complication as right hypochondrial pain that was controlled by analgesics and nausea, which was controlled by

antiemetics Also, nearly all experienced post - ablation pyrexia for 1-3 days, which was controlled by antipyretics it agrees with **Mulier et al., 2002** ⁽²⁷⁾ reported 93% of HCC patients in his study experienced post-ablation right hypochondrial pain.

Many authors have regarded low grade fever, mild right upper quadrant pain, small asymptomatic pleural effusions and transient elevation of liver functions following hepatic RFA. In reports reviewed, other minor complications included intra or peri hepatic abscess, minor hemorrhage, ascites, myoglobinuria and thrombocytopenia ⁽²⁸⁾. In the early studies of hepatic RFA, full thickness skin burns at the grounding pad sites were noted rarely and it was considered a major complication.

Another complication which deserves discussion is percutaneous ablation needle track tumour seeding but both these complications were not met in the present study.

Only one patient developed pneumothorax due to ablation of Sub-diaphragmatic tumour and another 2 patients developed ascites within the first week post ablation.

Conclusion: Radiofrequency thermal ablation is a technology that can be applied to unresectable hepatic tumours without significant morbidity when patients and treatment approach are chosen carefully.

5. References

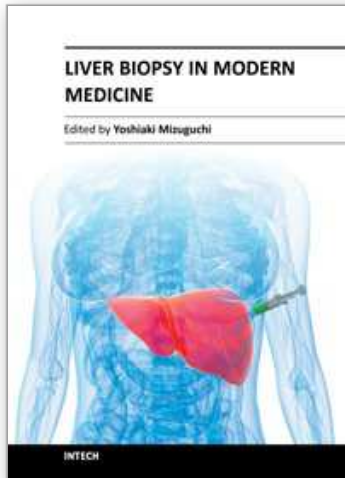
- [1] Llovet J, Fuster J and Bruix J of Barcelona Clinic Liver Cancer Group. The Barcelona Approach: Diagnosis, staging and treatment of hepatocellular carcinoma. *Liver Transplantation* 2004; 10:suppl.1 S115-120.
- [2] Sherlock S and Dooley J. Malignant liver tumours. In Sherlock and Dooley, *Diseases of the Liver and Biliary system*, 11th edition, 2002; Oxford, Blackwell Scientific Publications, P. 537-561.
- [3] Colombo M. Screening for cancer in viral hepatitis 2001; *Clin Liver Dis*; 5:109.
- [4] Hillebrand D and Sandowski S. Hepatobiliary disease. In *clinics in family practice* 2002; Volume 2, number I.W.B Saunders Company.
- [5] Rossi S, Buscarini E, Garbagnati F et al. Percutaneous treatment of small hepatic tumours by an expandable RF needle electrode. *AJR Am J Roentegenol* 1998; 170:1015-1022.
- [6] Buscarini L, Buscarini E, Di Stasi M, et al. Percutaneous radiofrequency ablation of small hepatocellular carcinoma: long term results. *Eur Radiol*; 2001; 11: 914-21.
- [7] Pugh R, Murray-Lyon I, Dowson J et al. Transection of the esophagus for bleeding esophageal varices. *Br J Surg* 1973; 60: 646-64.
- [8] Igarashi H, Aoyagi Y, Suda T, et al. Studies on the correlation among the fucosylation index, concentration of alpha-fetoprotein and des-gamma-carboxy prothrombin as prognostic indicators in hepatocellular carcinoma. *Hepatol Res.* 2003 ; 27:280-288.
- [9] El-zayadi A, Abaza H, Shawky S et al. Prevalence and epidemiological features of hepatocellular carcinoma in Egypt, a single center experience. *Hepatology Research* 2001; 19:170-179.
- [10] Marrero J. Hepatocellular carcinoma. *Curr Opin Gastroenterol* 2003; 19:243-249.
- [11] Yates S, Hafez M, Beld M et al. Hepatocellular carcinoma in Egyptians with and without history of hepatitis B virus infection: association with hepatitis C virus infection but not with HCV RNA level. *Am J Trop Med Hyg* 1999; 60:714-720.

- [12] Edamoto Y, Tani M, Kurata T et al. Hepatitis C and B virus infections in hepatocellular carcinoma. *Cancer* 1996; 77: 1787-1791.
- [13] Llovet JM, Burroughs A, Bruix J. Hepatocellular carcinoma. *Lancet* 2003; 362:1907-1917.
- [14] Bruix J, Sherman M, Llovet JM, et al. for the EASL panel of experts on HCC. Clinical management of hepatocellular, conclusions of the Barcelona-2000 EASL conference. *J Hepatol* 2001; 35:421-430.
- [15] Shi ML, Chun JL, Chen CL, et al. Radiofrequency ablation improves prognosis compared with ethanol injection for hepatocellular carcinoma less than 4cm. *gastroenterology* 2004; 127:1714-1723.
- [16] Livraghi J. Radiofrequency ablation, PEIT and TACE for hepatocellular carcinoma. *J Hepatobiliary Pancreat Surgery* 2003; 10:67-76.
- [17] Chen MH, Yang W, Yan K et al. Treatment efficacy of radiofrequency ablation of 338 patients with hepatic malignant tumours and the relevant complications. *World J Gastroenterol* 2005 ; 11: 6395-6401.
- [18] Sala M, Llovet J, Vilana R et al. Initial response to percutaneous ablation predicts survival in patients with hepatocellular carcinoma. *Hepatology* 2004; 40: 1352-1360.
- [19] Lencioni R, Pinto F, Armillotta N et al. Long term results of percutaneous ethanol injection therapy for hepatocellular carcinoma in cirrhosis: an European experience. *Eur Radiol* 1997; 7:514-519.
- [20] Pompili M, Rapaccini G, Covino M et al. Prognostic factors for survival in patients with compensated cirrhosis and small hepatocellular carcinoma after percutaneous ethanol injection therapy. *Cancer*, 2001; 92: 126-135.
- [20] Hasagawa S, Yamasaki N, Hiwaki T et al. Factors that predict intrahepatic recurrence of hepatocellular carcinoma in 81 patient initially treated by percutaneous ethanol injection. *Cancer* 1999; 86: 1682-1690.
- [21] Goldberg S, Charboneau J, Dodd G III et al. Image guided tumours ablation proposal standardization of terms and reporting criteria. *Radiology* 2003; 228:335-345.
- [22] Kojiro M. Focus on dysplastic nodules and early hepatocellular carcinoma: an Eastern point of view. *Liver Transpl* 2004; 10:S3-S8.
- [23] Shiina S, Teratani T, Obi S, et al. A randomized controlled trial of radiofrequency ablation with ethanol injection for small hepatocellular carcinoma. *Gastroenterology* 2005; 129:122-30.
- [24] Lencioni R, Allgaier H, Cioni D, et al. Small hepatocellular carcinoma in cirrhosis: randomized comparison of radiofrequency thermal ablation versus percutaneous ethanol injection. *Radiology* 2003; 228:235-240.
- [25] Lin SM, Lin CJ, Lin CC et al. Radiofrequency ablation improves prognosis compared with ethanol injection for hepatocellular carcinoma < or =4cm. *Gastroenterology* 2004; 127:1714-1723.
- [26] Lin SM, Lin CJ, Lin CC et al. Randomized controlled trial comparing radiofrequency thermal ablation, percutaneous ethanol injection and percutaneous acetic acid injection to treat hepatocellular carcinoma of 3cm or less. *Gut* 2005; 54:1151-1156.
- [27] Mulier S, Mulier P, Ni Y et al. Complications of radiofrequency coagulation of liver tumours. *Br J Surg* 200; 89: 1206-1222.

- [28] Scaife C and Curley S. Complications, local recurrence and survival rates after radiofrequency ablation for hepatic malignancies. *Surg Oncol Clin N Am* 2003; 12:243-255

IntechOpen

IntechOpen



Liver Biopsy in Modern Medicine

Edited by Dr. Yoshiaki Mizuguchi

ISBN 978-953-307-883-0

Hard cover, 378 pages

Publisher InTech

Published online 10, October, 2011

Published in print edition October, 2011

Liver biopsy, first performed by Paul Ehrlich in 1883, remains an important diagnostic procedure for the management of hepatobiliary disorders and the candidate/donated organ for transplantation. The book "Liver biopsy in Modern Medicine" comprises 21 chapters covering the various aspects of the biopsy procedure in detail and provides an up-to-date insightful coverage to the recent advances in the management of the various disorders with liver biopsy. This book will keep up with cutting edge understanding of liver biopsy to many clinicians, physicians, scientists, pharmaceuticals, engineers and other experts in a wide variety of different disciplines.

How to reference

In order to correctly reference this scholarly work, feel free to copy and paste the following:

Heba Mohamed Abdella (2011). Evaluation of Radiofrequency Ablation as a Method for Treatment of Hepatocellular Carcinoma, Liver Biopsy in Modern Medicine, Dr. Yoshiaki Mizuguchi (Ed.), ISBN: 978-953-307-883-0, InTech, Available from: <http://www.intechopen.com/books/liver-biopsy-in-modern-medicine/evaluation-of-radiofrequency-ablation-as-a-method-for-treatment-of-hepatocellular-carcinoma>

INTECH
open science | open minds

InTech Europe

University Campus STeP Ri
Slavka Krautzeka 83/A
51000 Rijeka, Croatia
Phone: +385 (51) 770 447
Fax: +385 (51) 686 166
www.intechopen.com

InTech China

Unit 405, Office Block, Hotel Equatorial Shanghai
No.65, Yan An Road (West), Shanghai, 200040, China
中国上海市延安西路65号上海国际贵都大饭店办公楼405单元
Phone: +86-21-62489820
Fax: +86-21-62489821

© 2011 The Author(s). Licensee IntechOpen. This is an open access article distributed under the terms of the [Creative Commons Attribution 3.0 License](#), which permits unrestricted use, distribution, and reproduction in any medium, provided the original work is properly cited.

IntechOpen

IntechOpen